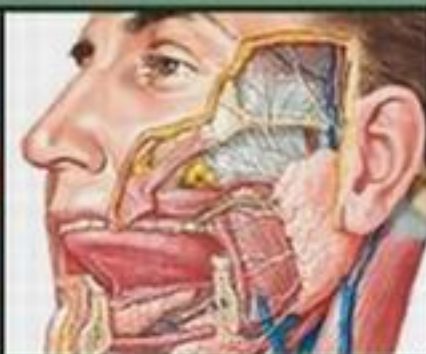
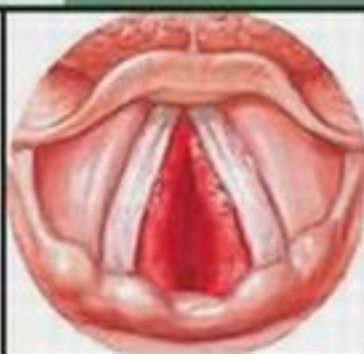
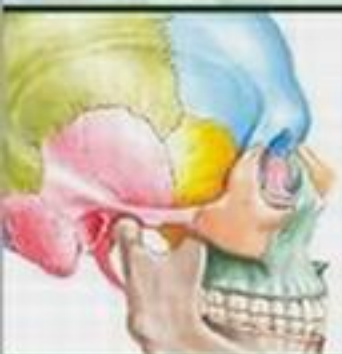


# Netter's HEAD AND NECK ANATOMY FOR DENTISTRY



NEIL S. NORTON

**2<sup>nd</sup>**  
EDITION

*F. Netter  
M.D.*



# Netter's Head and Neck Anatomy for Dentistry

2nd Edition

**Neil S. Norton, Ph.D.**

Director of Admissions  
Assistant Dean of Student Affairs  
Professor of Oral Biology  
School of Dentistry  
Creighton University  
Omaha, NE

**Illustrations by Frank H. Netter, MD**

Contributing Illustrators

Carlos A.G. Machado, MD  
John A. Craig, MD  
James A. Perkins, MS, MFA  
Kip Carter, MS, CMI  
Andrew E. B. Swift, MS, CMI  
William M. Winn, MS, FAMI  
Tiffany S. DaVanzo, MA, CMI



All rights reserved. No part of this publication may be reproduced or transmitted in any form or by any means, electronic or mechanical, including photocopying, recording, or any information storage and retrieval system, without permission in writing from the publisher. Permissions for Netter Art figures may be sought directly from Elsevier's Health Science Licensing Department in Philadelphia, PA, via email at [H.licensing@elsevier.com](mailto:H.licensing@elsevier.com).

### Notices

Knowledge and best practice in this field are constantly changing. As new research and experience broaden our understanding, changes in research methods, professional practices, or medical treatment may become necessary.

Practitioners and researchers must always rely on their own experience and knowledge in evaluating and using any information, methods, compounds, or experiments described herein. In using such information or methods they should be mindful of their own safety and the safety of others, including parties for whom they have a professional responsibility.

With respect to any drug or pharmaceutical products identified, readers are advised to check the most current information provided (i) on procedures featured or (ii) by the manufacturer of each product to be administered, to verify the recommended dose or formula, the method and duration of administration, and contraindications. It is the responsibility of practitioners, relying on their own experience and knowledge of their patients, to make diagnoses, to determine dosages and the best treatment for each individual patient, and to take all appropriate safety precautions.

To the fullest extent of the law, neither the Publisher nor the authors, contributors, or editors, assume any liability for any injury and/or damage to persons or property as a matter of products liability, negligence or otherwise, or from any use or operation of any methods, products, instructions, or ideas contained in the material herein.

### Library of Congress Cataloging-in-Publication Data

Norton, Neil Scott.

Netter's head and neck anatomy for dentistry / Neil S. Norton ; illustrations by Frank H. Netter ; contributing illustrators, Carlos A.G. Machado ... [et al.].—2nd ed.

p. ; cm.

Head and neck anatomy for dentistry

Includes bibliographical references and index.

ISBN 978-1-4377-2663-3 (pbk. : alk. paper)

I. Netter, Frank H. (Frank Henry), 1906-1991. II. Title. III. Title: Head and neck anatomy for dentistry.

[DNLM: 1. Dentistry—Atlases. 2. Head—anatomy & histology—Atlases.

3. Neck—anatomy & histology—Atlases. WU 17]

LC-classification not assigned

611'.91—dc23

2011029515

*Acquisitions Editor:* Elyse O'Grady

*Developmental Editor:* Marybeth Thiel

*Publishing Services Manager:* Catherine Jackson

*Senior Project Manager:* Carol O'Connell

*Design Direction:* Louis Forgiione

Printed in China

Last digit is the print number: 9 8 7 6 5 4 3 2 1

Working together to grow  
libraries in developing countries

[www.elsevier.com](http://www.elsevier.com) | [www.bookaid.org](http://www.bookaid.org) | [www.sabre.org](http://www.sabre.org)

ELSEVIER

BOOK AID  
International

Sabre Foundation



I dedicate this book to the following influential people in my life,

To my mother Chari, who worked tirelessly and sacrificed everything throughout her life  
so that her children would not be without.

To Elizabeth, who made me a better man. I owe you everything for all that you have  
done for me.

To my brother John, who helped raise me.

To the late Father John G. Holbrook, S.J., who helped me appreciate the importance of  
service to others. He taught me the dedicated ways of *cura personalis*, or care for the  
individual. I have tried to live by those words every day of my life.



# About the Author

**Neil S. Norton, PhD**, joined Creighton University in 1996 and is currently the Director of Admissions, Assistant Dean for Student Affairs, and Professor of Oral Biology in the School of Dentistry. After graduating Phi Beta Kappa from Randolph-Macon College with a BA in Biology he went on to receive his PhD training in Anatomy from the University of Nebraska Medical Center. Dr. Norton has been the recipient of numerous teaching awards including ten Outstanding Instructor of the Year Awards from the Freshman classes and eight Dr. Theodore J. Urban Pre-Clinical Awards, presented by graduating Senior classes for dedication and outstanding Basic Science instruction. Dr. Norton is the third professor in the history of the School of Dentistry to receive the prestigious Robert F. Kennedy Memorial Award for Teaching Achievement, the highest teaching recognition offered by the University. In 2007 Dr. Norton received the GlaxoSmithKline Sensodyne Teaching Award, the highest national teaching award given by the American Dental Education Association (ADEA). An active member of the School of Dentistry faculty, he was elected by colleagues to honorary membership in Omicron Kappa Upsilon, the Honor Dental Society whose regular membership is reserved for dentists. His teaching responsibilities include Head and Neck Anatomy, General Anatomy, Neuroscience, and Pain Control. Dr. Norton served four years as President of the University Faculty and chaired many committees, including the University Committee on Rank and Tenure and the University Committee on Academic Freedom and Responsibility. Currently he serves as the Faculty Athletic Representative for Creighton. He continues to actively publish on a variety of anatomical topics in addition to his administrative duties. He is an active member of the American Association of Clinical Anatomists (AACA) and has served as the Treasurer since 2006.



# About the Artists

## **Frank H. Netter, MD**

Frank H. Netter was born in 1906, in New York City. He studied art at the Art Student's League and the National Academy of Design before entering medical school at New York University, where he received his MD degree in 1931. During his student years, Dr. Netter's notebook sketches attracted the attention of the medical faculty and other physicians, allowing him to augment his income by illustrating articles and textbooks. He continued illustrating as a sideline after establishing a surgical practice in 1933, but he ultimately opted to give up his practice in favor of a full-time commitment to art. After service in the United States Army during World War II, Dr. Netter began his long collaboration with the CIBA Pharmaceutical Company (now Novartis Pharmaceuticals). This 45-year partnership resulted in the production of the extraordinary collection of medical art so familiar to physicians and other medical professionals worldwide.

In 2005, Elsevier, Inc., purchased the Netter Collection and all publications from Icon Learning Systems. There are now over 50 publications featuring the art of Dr. Netter available through Elsevier, Inc. (in the United States: [www.us.elsevierhealth.com/Netter](http://www.us.elsevierhealth.com/Netter) and outside the United States: [www.elsevierhealth.com](http://www.elsevierhealth.com)).

Dr. Netter's works are among the finest examples of the use of illustration in the teaching of medical concepts. The 13-book *Netter Collection of Medical Illustrations*, which includes the greater part of the more than 20,000 paintings created by Dr. Netter, became and remains one of the most famous medical works ever published. *The Netter Atlas of Human Anatomy*, first published in 1989, presents the anatomical paintings from the Netter Collection. Now translated into 16 languages, it is the anatomy atlas of choice among medical and health professions students the world over.

The Netter illustrations are appreciated not only for their aesthetic qualities, but, more important, for their intellectual content. As Dr. Netter wrote in 1949, "... clarification of a subject is the aim and goal of illustration. No matter how beautifully painted, how delicately and subtly rendered a subject may be, it is of little value as a *medical illustration* if it does not serve to make clear some medical point." Dr. Netter's planning, conception, point of view, and approach are what inform his paintings and what makes them so intellectually valuable.

Frank H. Netter, MD, physician and artist, died in 1991.

Learn more about the physician-artist whose work has inspired the Netter Reference collection at [www.netterimages.com/artist/netter.htm](http://www.netterimages.com/artist/netter.htm).

## **Carlos Machado, MD**

Carlos Machado was chosen by Novartis to be Dr. Netter's successor. He continues to be the main artist who contributes to the Netter collection of medical illustrations.

Self-taught in medical illustration, cardiologist Carlos Machado has contributed meticulous updates to some of Dr. Netter's original plates and has created many paintings of his own in the style of Netter as an extension of the Netter collection. Dr. Machado's photorealistic expertise and his keen insight into the physician/patient relationship inform his vivid and unforgettable visual style. His dedication to researching each topic and subject he paints places him among the premier medical illustrators at work today.

Learn more about his background and see more of his art at [www.netterimages.com/artist/machado.htm](http://www.netterimages.com/artist/machado.htm).

# Acknowledgments

The second edition of *Netter's Head & Neck Anatomy for Dentistry* book has been a labor of love. Like the 1st edition, it is the culmination of many hours of hard, but very satisfying, work. I am truly indebted to the help of many talented and dedicated individuals.

I started at the Creighton University School of Dentistry in 1996 and was overwhelmed by the comradery that existed at both the School and University level. I am grateful every day to be part of such a fine institution that is committed to the education of students. The support and assistance my fellow colleagues provided has been immeasurable. I would especially like to thank for their review of chapters, suggestions, and willingness to provide materials: Drs. W. Thomas Cavel, Paul Edwards, Terry Lanphier, Takanari Miyamoto, Cyndi Russell, Tarjit Saini, and Timothy McVane. I owe a very special thanks to my Dean, Dr. Wayne W. Barkmeier. He was the person willing to give a young anatomist an opportunity at Creighton, and I owe my career to Dr. Barkmeier. It was he and Dr. Frank J. Ayers who pushed me and provided me the opportunity in Admissions and Student Affairs. For that, I'll always be grateful.

Additionally, I am grateful to Dr. Laura C. Barritt who was instrumental in the creation of the Development section of the book, as well as providing various suggestions in many other chapters. Another special thanks goes to my chair, Dr. Margaret A. Jergenson. Since 1996, Dr. Jergenson and I have taught general anatomy and head and neck anatomy to freshman dental students. As a dentist, her clinical background has been invaluable in helping me appreciate head and neck anatomy from a dental perspective. Together, we have enjoyed a great time working together as the anatomical team in the School of Dentistry. I could not ask for a better colleague with whom to teach anatomy.

My sincere appreciation to my Creighton colleagues. Creighton is a family, and I have been fortunate to spend my career at such a fine university. Over the years there are a few individuals who have helped me immensely. In particular, I owe a special acknowledgment of gratitude to Frs. Richard Hauser, S.J., and Thomas Shanahan, S.J. Last, a special thanks goes to Fr. John P. Schlegel, S.J. For eleven of my fifteen years at Creighton, Fr. Schlegel served as the President of Creighton University. In my previous role as President of the University Faculty, I worked with Fr. Schlegel on many issues and was always grateful to be working for a President committed to his students, staff, and faculty.

Thank you to the reviewers who examined the chapters in the first edition and provided excellent feedback: Drs. Robert Spears, Kathleen M. Klueber, and Brian R. MacPherson, and Professor Cindy Evans. My sincere appreciation goes to friend and colleague Dr. Thomas Quinn, who offered helpful comments and words of encouragement throughout the textual writing and development of the art.

I enlisted the help of my dental students to make *Netter's Head and Neck Anatomy for Dentistry* more student-friendly. Special thanks go to Dr. Joseph Opack for providing excellent critiques on chapters and Dr. Ryan Dobbs for his assistance in keeping many of my chapters well organized and developed. Additional thanks go to Drs. Steve Midstokke and Paul Mendes for helping in the creation of some of the new pieces of art. A special thanks to Dr. Kyle D. Smith for helping select many of the new cone beam images that have been incorporated into the second edition.

This book would not be possible if not for the beautiful new artwork created by the incredible medical illustrators at Elsevier. Their hard work not only supplemented the illustrations of Dr. Frank Netter, Carlos Machado, MD, and John Craig, MD, seamlessly,

but also added to the vast Netter collection of anatomical pieces. Tiffany DaVanzo was instrumental in the creation of the new pieces in the second edition. I am very grateful to the work of Kip Carter, William Winn, and Andrew Swift. All of these illustrators helped put my vision into art. Their artistic interpretations are simply magnificent.

The Elsevier team deserves a special thanks for making this project happen, including Elyse O'Grady, Marybeth Thiel, Anne Lenehan, and Carol O'Connell. Additionally, I would like to acknowledge the work of those who helped me complete the first edition of the book: Jennifer Surich, Carolyn Kruse, and Jonathan Dimes.

A very special thanks goes to Paul Kelly. I have had the great honor and privilege of knowing Paul for the past 10 years. I remember many conversations with Paul over the years in which he encouraged me to put together an anatomical project for dentistry. I presented him with the rough outline and prospectus for a text/atlas that evolved into the first edition of this book.

Lastly, I thank all of the students whom I have instructed over my career. You have always served as a great inspiration to me. It has been an honor and privilege to be a part of your education. *Netter's Head and Neck Anatomy for Dentistry* is for you.



# Preface

*Netter's Head and Neck Anatomy for Dentistry* is a text/atlas written to help dental students and professionals learn and review head and neck anatomy. Designed for first-year dental students, it also serves to teach anatomy to students of dental hygiene as well as a review for the practicing clinician. The head and neck comprise the foundation for dental anatomical study. The many small, inter-related structures are not easily observable, which makes head and neck anatomy one of the most difficult disciplines for students to master.

This second edition has three major additions from the first edition. First is the inclusion of an introductory chapter on upper limb, thorax, and abdomen. These sections are included in dental school courses of gross anatomy, and it was a goal to create one book that would fully cover head and neck anatomy but also provide the basic anatomy needed to successfully complete the upper limb, thorax, and abdomen portions of an anatomy course. The second addition is the inclusion of over 20 radiographic images to complement the anatomy illustrations throughout the text. Radiology is an important part of the education of dental students and it is a natural addition to any anatomy text. The third addition is the inclusion of review questions that cover all of the chapters in the text. The multiple-choice questions are designed to serve as a review for the reader.

To understand the clinical significance of an anatomical concept is to understand the anatomy. It is with that in mind that a series of clinical correlates that relate to dentistry are provided at the end every chapter. Many anatomical topics covered in head and neck courses have been expanded especially for this text. A chapter has been dedicated to the temporomandibular joint. In the chapter on the oral cavity, more information has been provided for the reader on such topics as dentition. Chapters on the development of the head and neck and basic neuroscience are included to help connect with other related anatomical areas. A chapter on intraoral injections is included to help teach and reinforce an area often overlooked. The intent of these chapters is to provide the reader with a brief overview of important concepts related to head and neck anatomy.

A superb team of medical illustrators created new art to complement the anatomical illustrations of Dr. Frank H. Netter, which resulted in a more complete learning tool. Essential information is presented in tables and brief text that are integrated with the Netter art to help bridge gaps and augment the readers' knowledge of head and neck anatomy.

*Netter's Head and Neck Anatomy for Dentistry* is for those in all stages of the dental profession. My hope is that this book will provide an essential resource to readers in helping them to learn and appreciate the complex anatomy of the head and neck.

**CHAPTER 1**

# DEVELOPMENT OF THE HEAD AND NECK

Overview	2
Pharyngeal Arches	4
Pharyngeal Pouches, Membranes, and Clefts	7
Skull	10
Face	13
Palate	15
Tongue	17
Thyroid Gland	18
Clinical Correlates	19

# 1 Overview

## GENERAL INFORMATION

3 major germ layers form the initial developing embryo:

- Ectoderm
- Mesoderm
- Endoderm

Mesoderm differentiates into:

- Paraxial mesoderm
- Intermediate mesoderm
- Lateral plate mesoderm

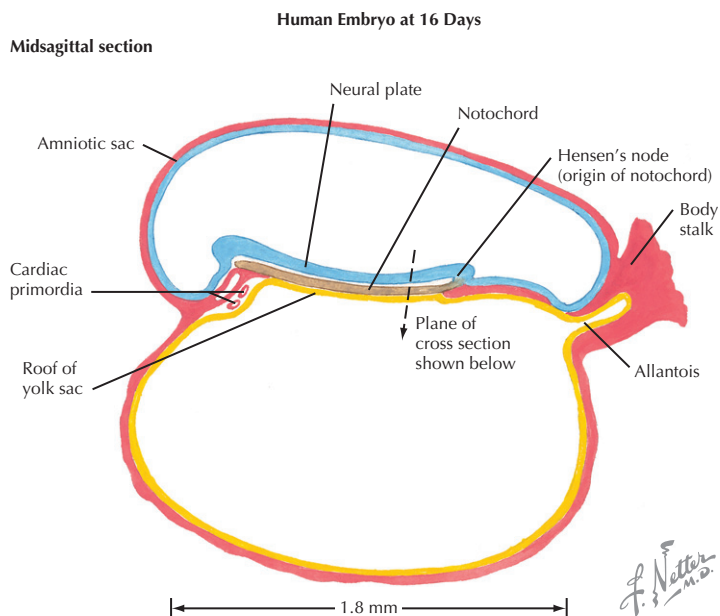
Ectoderm gives rise to 2 layers:

- Neuroectoderm
- Neural crest

The head and neck are formed by:

- Paraxial mesoderm
- Lateral plate mesoderm
- Neural crest
- Ectodermal placodes

Most of the head and neck is formed from the pharyngeal arches

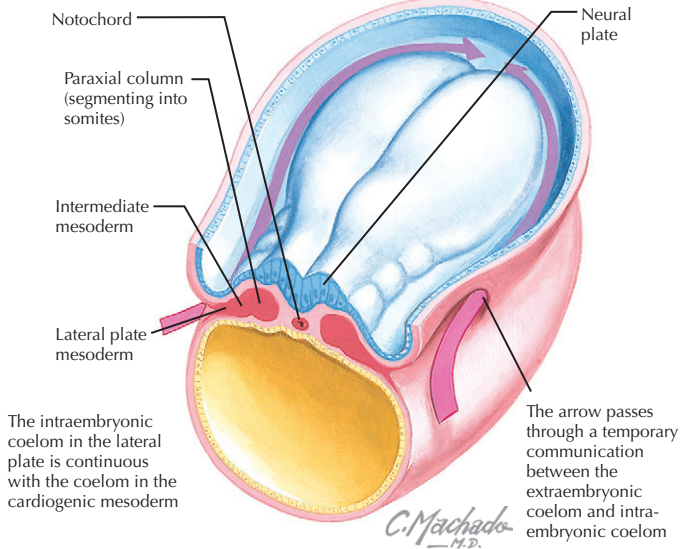




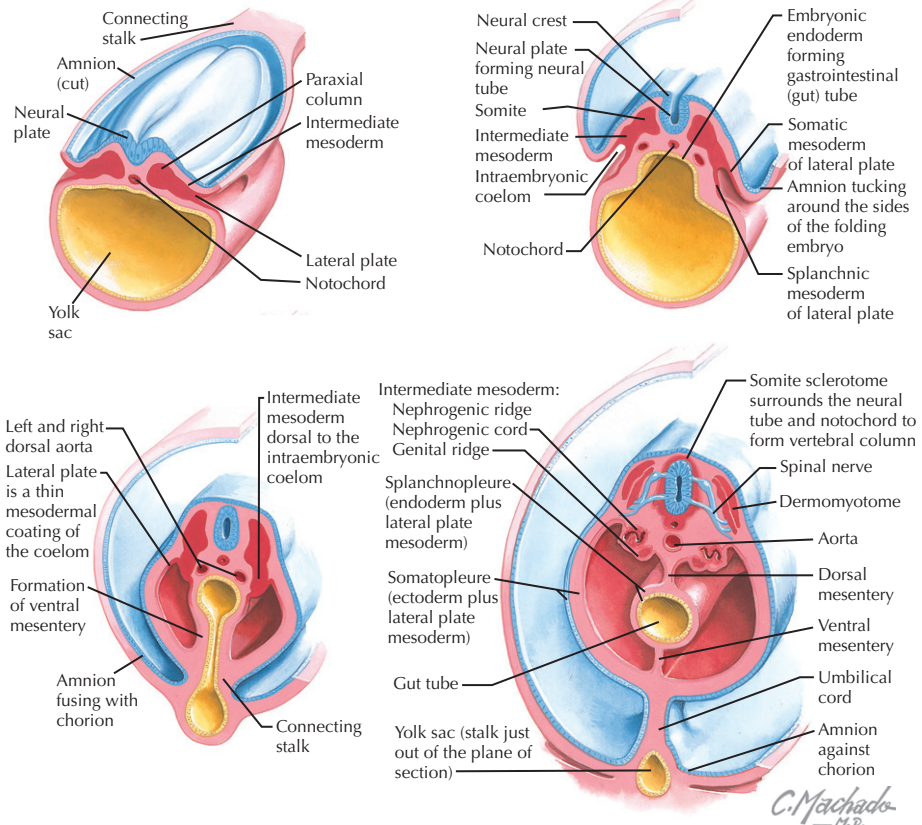
# Overview

## GENERAL INFORMATION CONTINUED

Cross section of embryo



Vertebrate Body Plan after 4 Weeks



# 1 Pharyngeal Arches

## GENERAL INFORMATION

Start forming in the 4th week of development

Develop as blocks separated by pharyngeal clefts

Initially, 6 arches develop, but the 5th regresses

Arising from the endoderm are compartments called pharyngeal pouches that extend toward the pharyngeal clefts

Help form 4 of the 5 swellings of the face:

- 2 mandibular processes (pharyngeal arch)
- 2 maxillary processes (pharyngeal arch)
- 1 frontonasal prominence

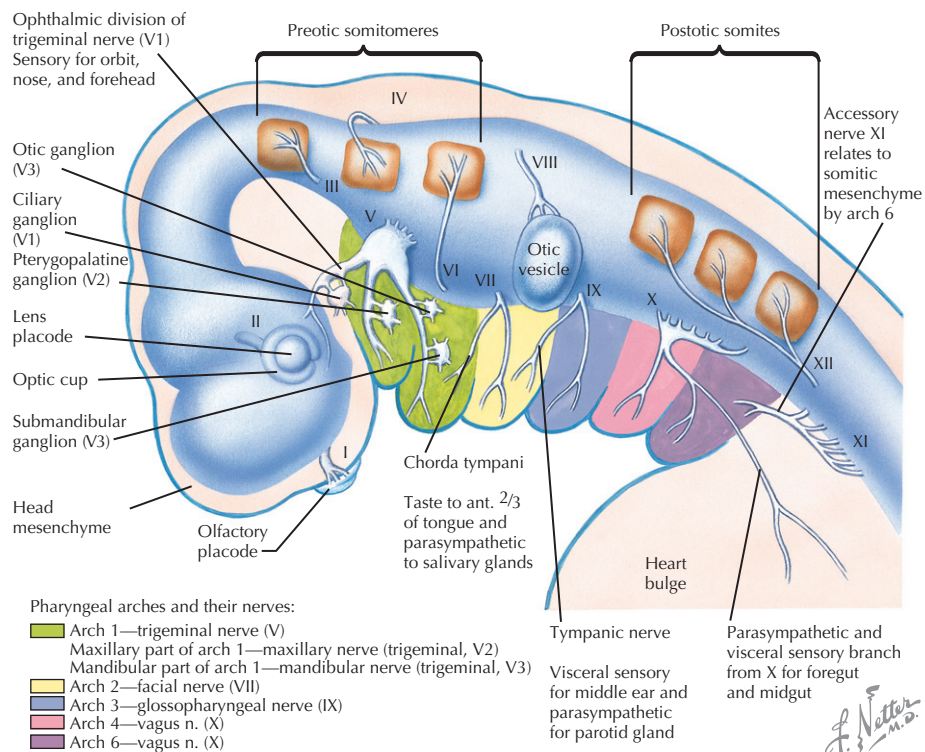
Composed of:

- External surface—ectoderm
- Internal surface—endoderm
- Central part—lateral plate mesoderm, paraxial mesoderm, neural crest

Skeletal components develop from the neural crest tissue

Muscular structures develop collectively from the mesoderm

Each arch is innervated by a cranial nerve that migrates with the muscles



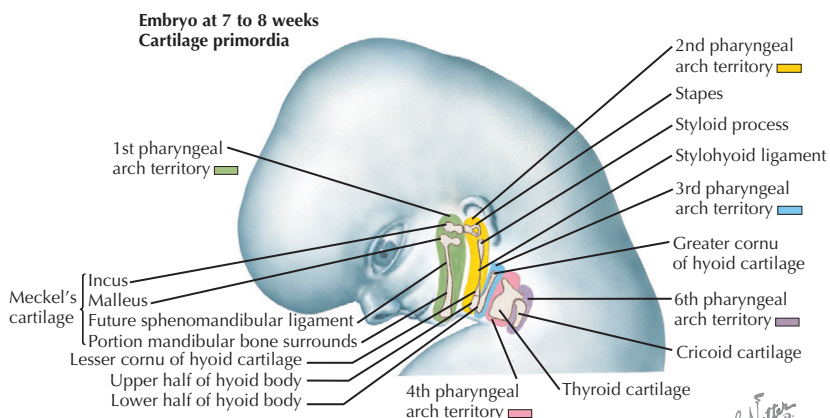
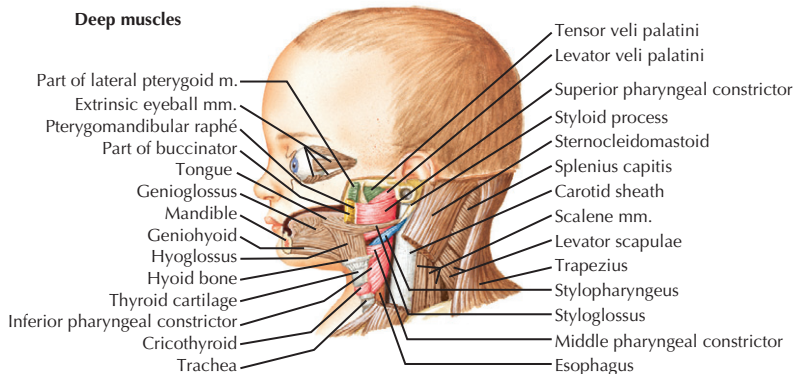
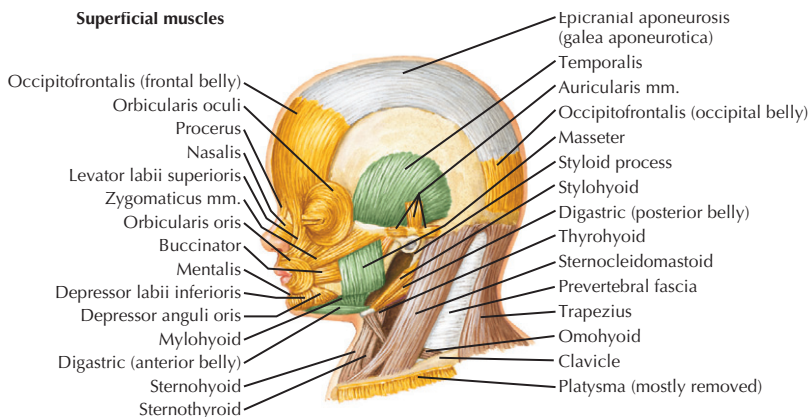
# Pharyngeal Arches

## DERIVATIVES OF THE PHARYNGEAL ARCHES

Arch	Muscles from Mesoderm	Skeletal Structures from Neural Crest	Cartilage Structures	Connective Tissue Structures	Nerve
1 Develops into: • Maxillary process • Mandibular process	Masseter Temporalis Lateral pterygoid Medial pterygoid Mylohyoid Anterior digastric Tensor tympani Tensor veli palatini	Maxilla Temporal (squamous portion) Zygoma Mandible Malleus Incus	Meckel's cartilage (degenerates in adulthood)	Sphenomandibular ligament Anterior ligament of the malleus	Trigeminal
2	Muscles of facial expression Posterior digastric Stylohyoid Stapedius	Lesser cornu of the hyoid Superior part of the hyoid body Styloid process Stapes	Reichert's cartilage	Stylohyoid ligament Connective tissue of the tonsil	Facial
3	Stylopharyngeus	Greater cornu of the hyoid Inferior part of the hyoid body		Connective tissue of the thymus and inferior parathyroid	Glossopharyngeal
4	Musculus uvulae Levator veli palatini Palatopharyngeus Palatoglossus Superior constrictor Middle constrictor Inferior constrictor Salpingopharyngeus Cricothyroid		Thyroid (from lateral plate mesoderm) Epiglottis	Connective tissue of the superior parathyroid and the thyroid	Vagus
6	Thyroarytenoid Vocalis Lateral cricoarytenoid Oblique arytenoids Transverse arytenoids Posterior cricoarytenoid Aryepiglottis Thyroepiglottis		Arytenoid Cricoid Cuneiform Corniculate (from lateral plate mesoderm)		Vagus

# 1 Pharyngeal Arches

## DERIVATIVES OF THE PHARYNGEAL ARCHES *CONTINUED*



### PHARYNGEAL ARCH BONES AND CARTILAGE

Arch #	Derivatives of Arch Cartilages
1	Malleus, incus, sphenomandibular ligament
2	Stapes, styloid process, stylohyoid ligament, upper half of hyoid
3	Lower half and greater horns of hyoid
4	Thyroid and epiglottic cartilages of larynx
6	Cricoid, arytenoid, and corniculate cartilages of larynx

# Pharyngeal Pouches, Membranes, and Clefts

## GENERAL INFORMATION

Pharyngeal pouches—4 develop from endoderm

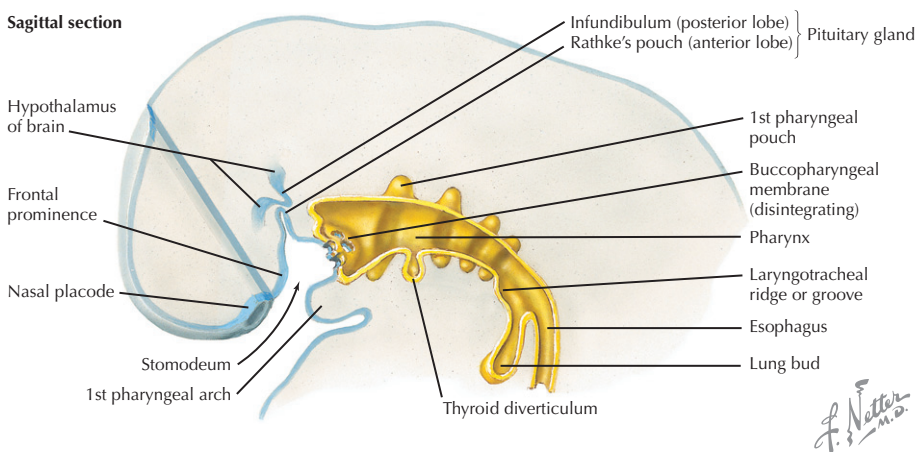
Pharyngeal clefts—each is a groove formed from ectoderm

Pharyngeal membranes—each is composed of tissue located between a pharyngeal pouch and a pharyngeal cleft; composed of external ectoderm, mesoderm and neural crest in the core, and an internal endoderm lining

## PHARYNGEAL POUCHES

Pouch	Location	Embryonic Structure	Adult Structure
1	Opposite the 1st pharyngeal cleft, separated by the 1st pharyngeal membrane	Tubotympanic recess	Epithelium of the auditory tube and tympanic cavity
2	Opposite the 2nd pharyngeal cleft, separated by the 2nd pharyngeal membrane	Primitive palatine tonsils	Tonsillar fossa Epithelium of the palatine tonsil
3	Opposite the 3rd pharyngeal cleft, separated by the 3rd pharyngeal membrane	Divides into a dorsal and a ventral part Dorsal part migrates inferiorly toward the thorax	Inferior parathyroid gland (from the dorsal part) Thymus (from the ventral part)
4	Opposite the 4th pharyngeal cleft, separated by the 4th pharyngeal membrane	Divides into a dorsal and a ventral part Ventral part is invaded by neural crest to form the parafollicular cells	Superior parathyroid gland (from the dorsal part) Ultimobranchial body (from the ventral part)

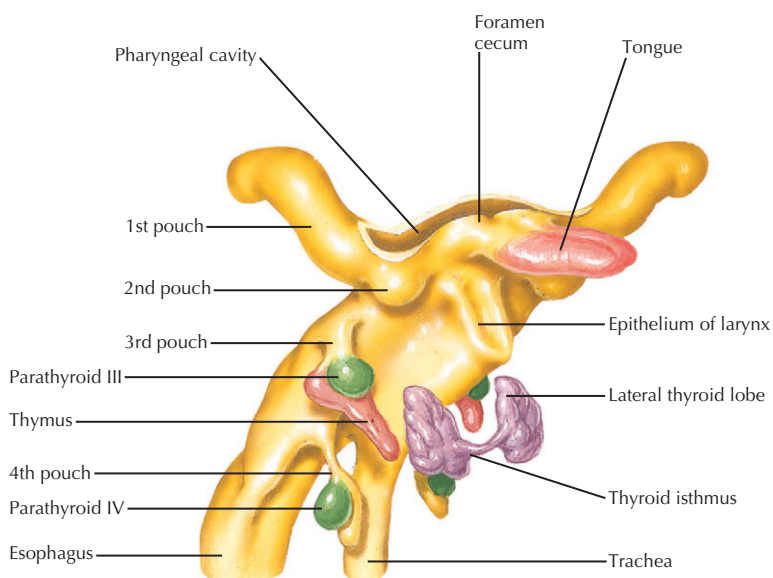
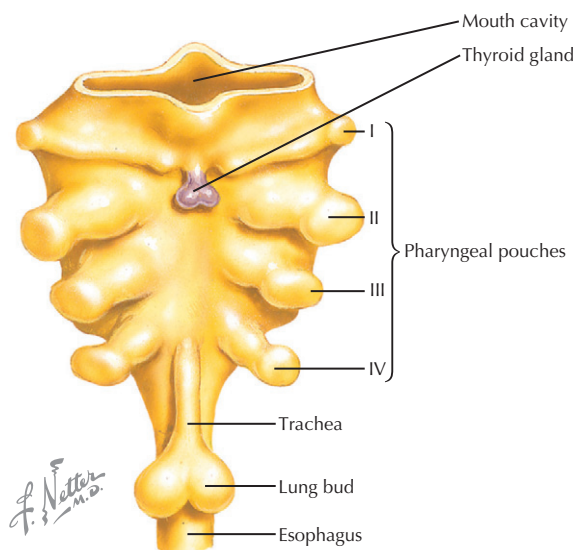
### Sagittal section





# 1 Pharyngeal Pouches, Membranes, and Clefts

## PHARYNGEAL POUCHES *CONTINUED*



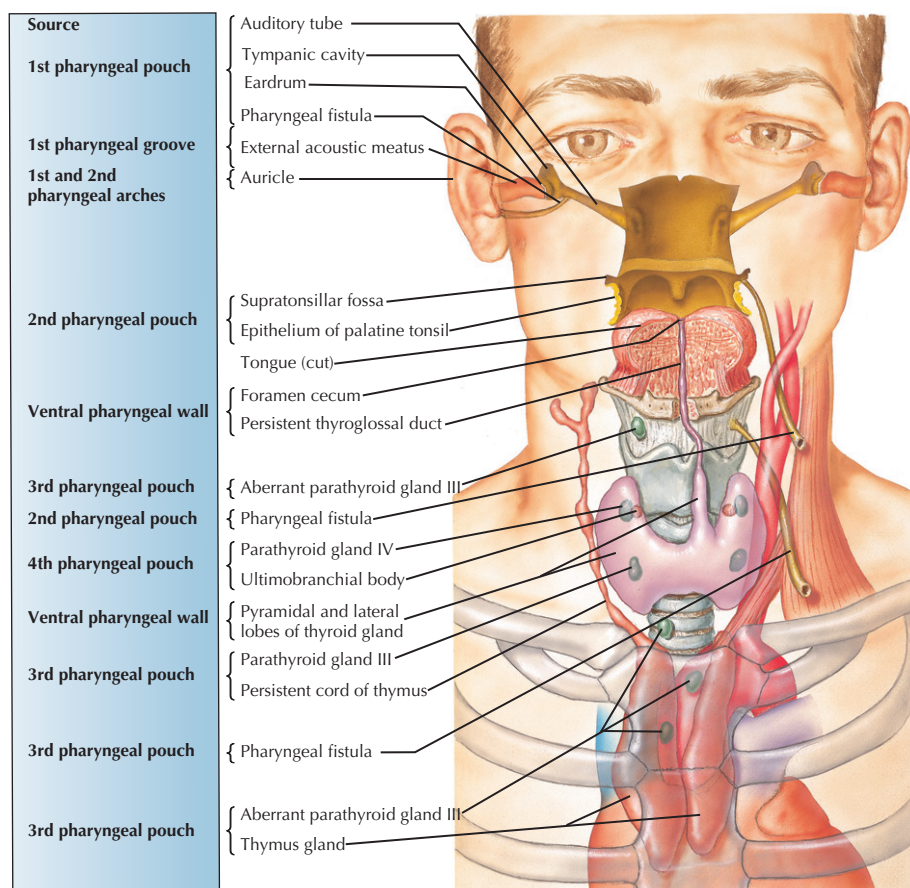
# Pharyngeal Pouches, Membranes, and Clefts

## PHARYNGEAL MEMBRANES

Membrane	Location	Adult Structure
1	Between the 1st pharyngeal cleft and the 1st pharyngeal pouch	Tympanic membrane
2	Between the 2nd pharyngeal cleft and the 2nd pharyngeal pouch	
3	Between the 3rd pharyngeal cleft and the 3rd pharyngeal pouch	
4	Between the 4th pharyngeal cleft and the 4th pharyngeal pouch	

## PHARYNGEAL CLEFTS

Cleft	Location	Adult Structure
1	A groove between the 1st and 2nd pharyngeal arches	External acoustic meatus
2	A groove between the 2nd and 3rd pharyngeal arches	Obliterated cervical sinus by the 2nd pharyngeal arch, which grows over the cleft
3	A groove between the 3rd and 4th pharyngeal arches	
4	A groove between the 4th and 6th pharyngeal arches	



*F. Netter M.D.*

# 1 Skull

## GENERAL INFORMATION

Skull is formed from:

- Lateral plate mesoderm (neck region)
- Paraxial mesoderm
- Neural crest

Bony skull is formed by either of 2 mechanisms:

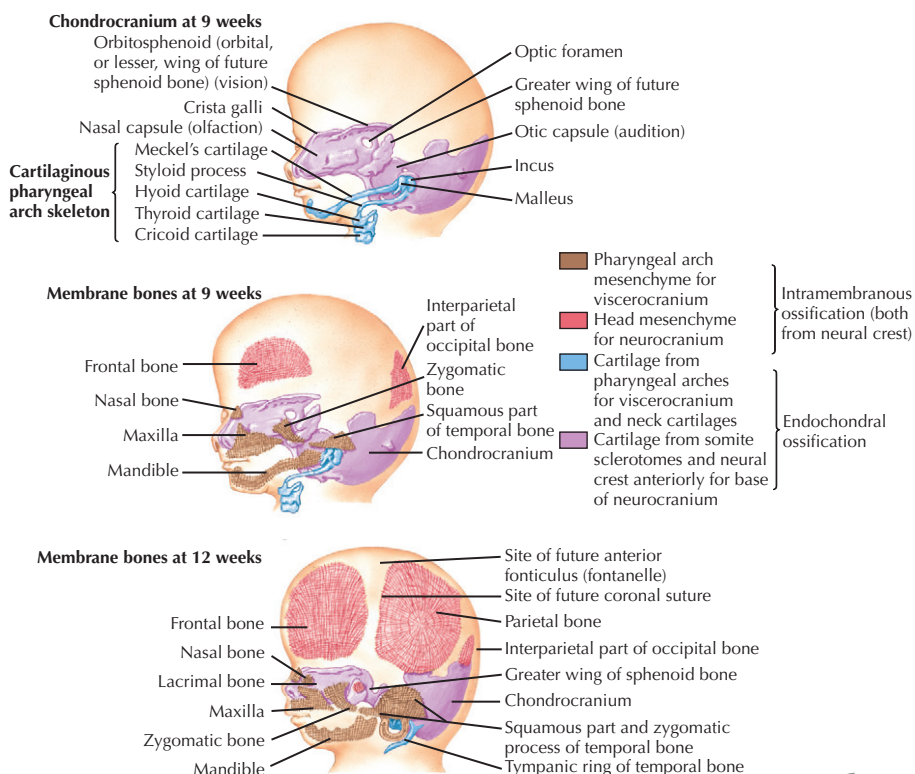
- Intramembranous ossification
- Endochondral ossification

Skull development is divided into 2 parts:

- Viscerocranium—forms the bones of the face
- Neurocranium—forms the bones of the cranial base and cranial vault and can be divided into membranous neurocranium and cartilaginous neurocranium

## VISCEROCRANIUM

Germ Layers	Origins	Adult Structure	Ossification
Neural crest	1st pharyngeal arch		
		<i>Maxillary process</i>	
		Maxilla	Intramembranous
		Temporal bone	
		Zygoma	
		Palatine	
		Lacrima	
		Vomer	
		Nasal	
		Inferior nasal concha	Endochondral
	Mandibular process	Mandible	Intramembranous and endochondral
		Sphenomandibular ligament	
		Malleus	Endochondral
		Incus	
	2nd pharyngeal arch	Styloid process	Endochondral
		Stapes	
		Hyoid	
		Stylohyoid ligament	Not ossified



*F. Netter M.D.*

## SKULL FONTANELLES

Fontanelle	Time of Closure
Anterior fontanelle (bregma)	4–26 months
Posterior fontanelle (lambda)	1–2 months
Sphenoidal fontanelle (pterion)	2–3 months
Mastoid fontanelle (asterion)	12–18 months

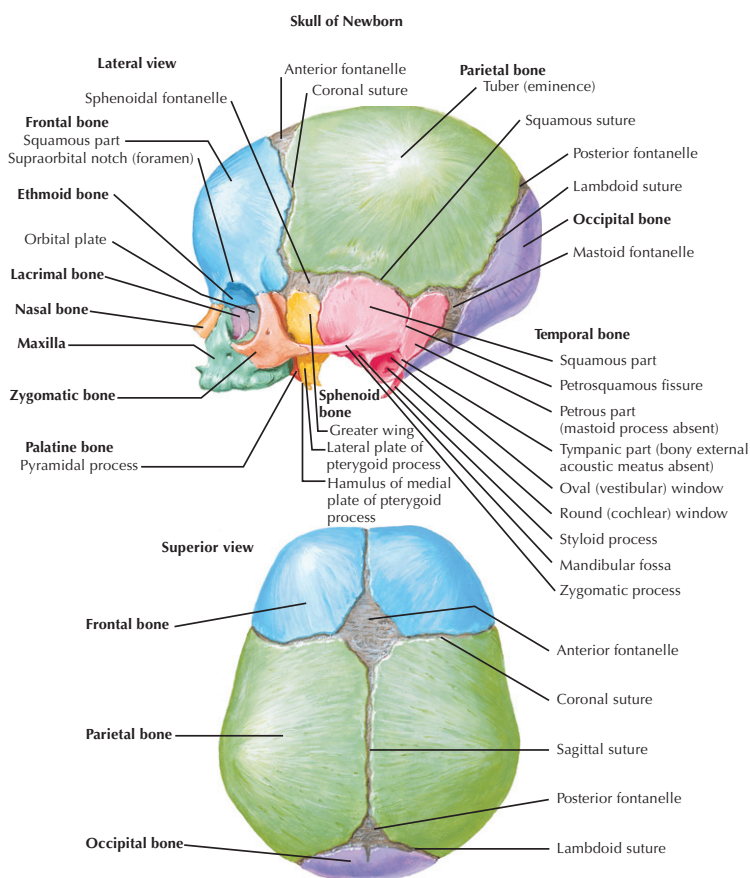
# 1 Skull

## MEMBRANOUS NEUROCRANIUM

Germ Layer	Portions of Neurocranium	Adult Structure	Ossification
Neural crest	Main portion of the roof and lateral sides of the cranial vault	Frontal bone Squamous portion of the temporal bone	Intramembranous
Paraxial mesoderm		Parietal bone Occipital bone (intraparietal portion)	

## CARTILAGINOUS NEUROCRANIUM

Germ Layer	Portions of Neurocranium	Adult Structure	Ossification
Neural crest	Prechordal Anterior to the sella turcica	Ethmoid Sphenoid	Endochondral
Paraxial mesoderm	Chordal Posterior to the sella turcica	Petrous portion of the temporal bone Mastoid process of the temporal bone Occipital bone	



# Face

## GENERAL INFORMATION

The face is formed mainly from neural crest, which makes 3 swellings that surround the stomodeum:

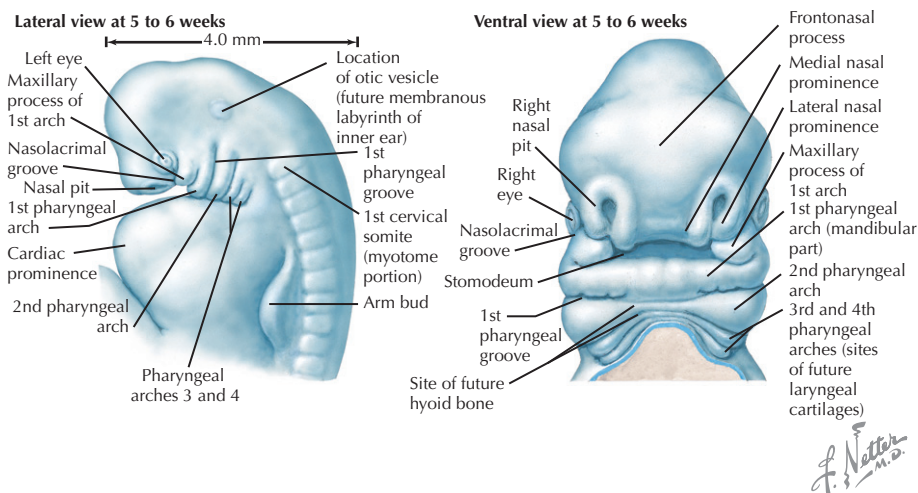
- Frontonasal prominence
- Maxillary prominence (from the 1st pharyngeal arch)
- Mandibular prominence (from the 1st pharyngeal arch)

Lateral to the frontonasal prominence, 2 additional areas of ectoderm form the 2 nasal placodes that invaginate in the center to form nasal pits, creating ridges of tissue on either side of the pits:

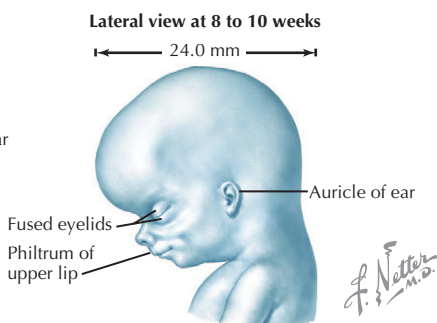
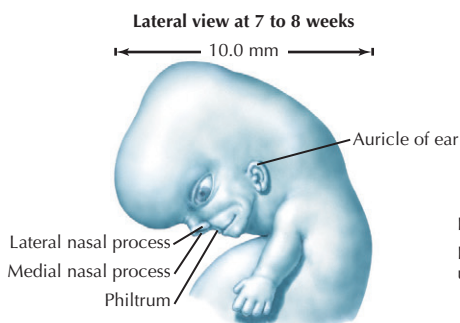
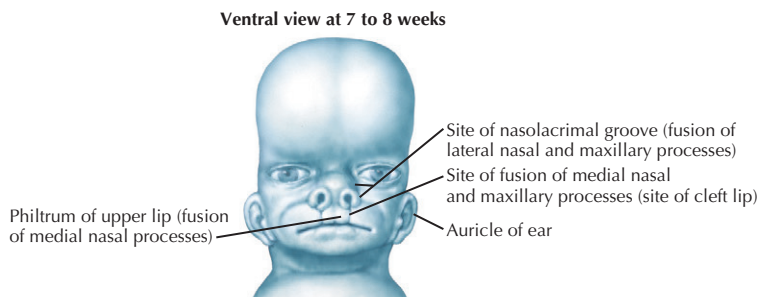
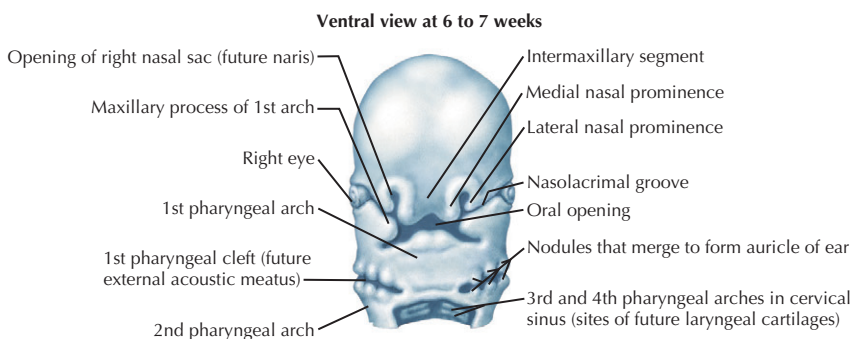
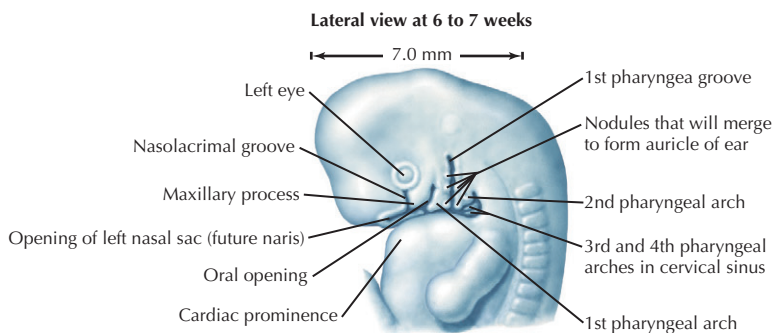
- Lateral nasal prominence
- Medial nasal prominence

Fusion of the medial nasal prominences at the midline results in formation of the intermaxillary segment

ADULT STRUCTURES OF THE FACE	
Structure(s)	Develop(s) from
Upper lip	Maxillary prominence Medial nasal prominence
Lower lip	Mandibular prominence
Lacrimal sac Nasolacrimal duct	A nasolacrimal groove that separates the lateral nasal prominence and the maxillary prominence
Nose	Frontonasal prominence Medial nasal prominence Lateral nasal prominence
Cheeks	Maxillary prominence
Philtrum Primary palate Upper jaw containing the central and lateral incisors	Intermaxillary segment



## GENERAL INFORMATION CONTINUED





# Palate

## GENERAL INFORMATION

Formed by the:

- Primary palate (intermaxillary segment)
- Secondary palate (protrusions from the maxillary prominences)

**Intermaxillary segment:** the initial portion of the palate in development; contains the central and lateral incisors

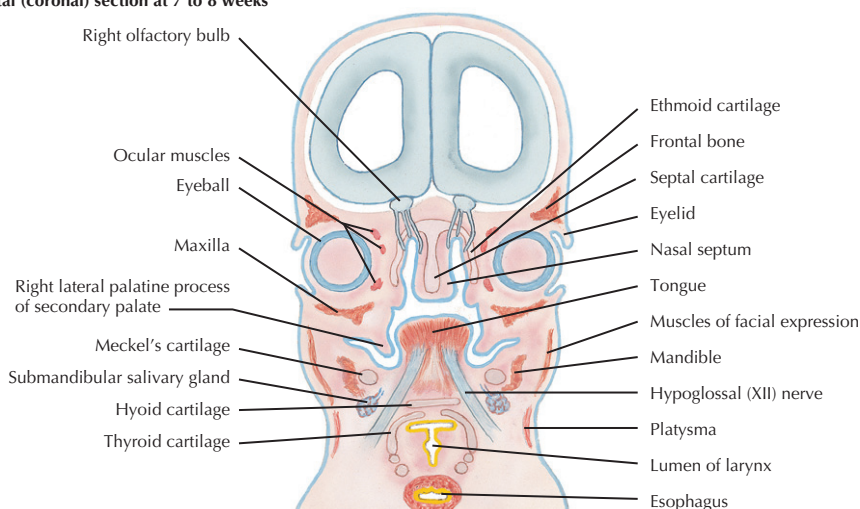
Swellings of the maxillary prominence form shelves that project medially and are separated by the tongue

When the tongue no longer occupies the space between the palatal shelves, these processes fuse together to form the secondary palate

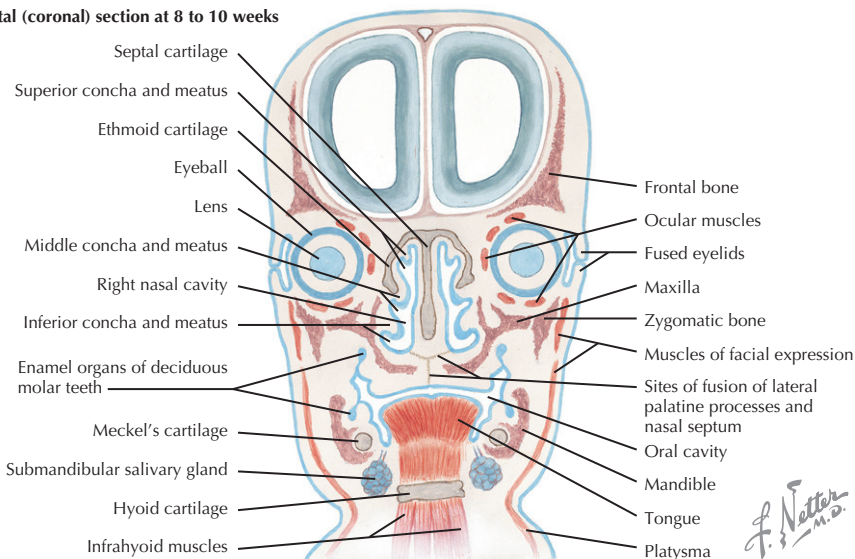
The primary and secondary palatal tissues all meet at the *incisive foramen*

Primary and secondary palates and the nasal septum fuse to form the definitive palate

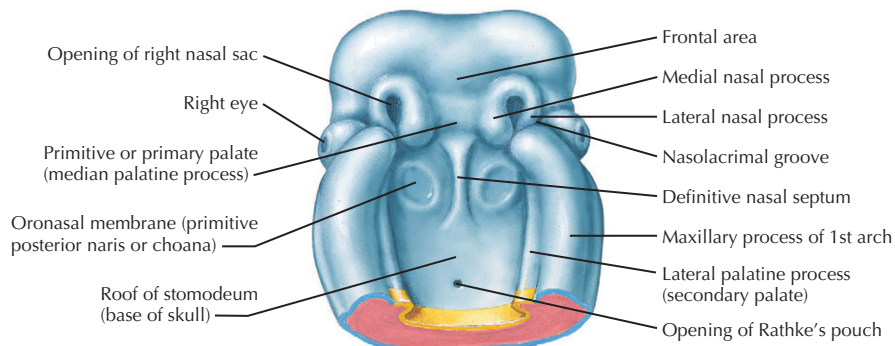
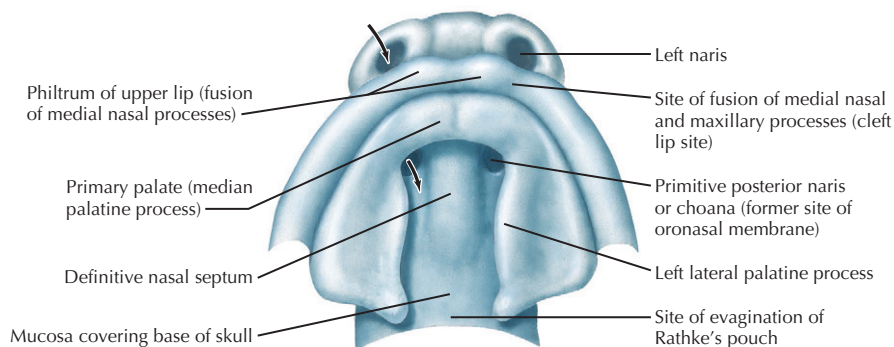
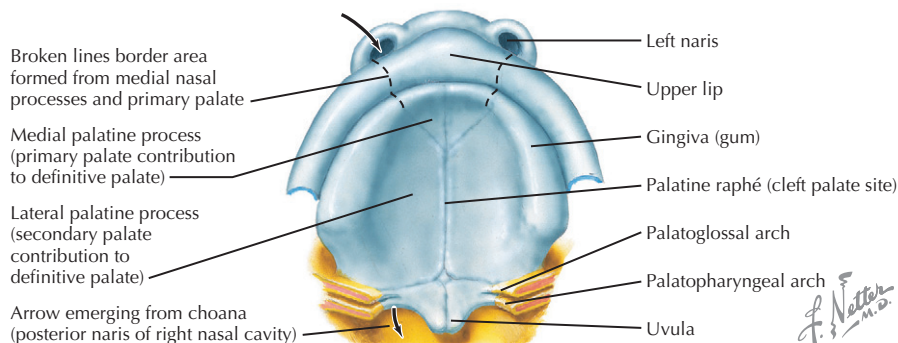
**Frontal (coronal) section at 7 to 8 weeks**



**Frontal (coronal) section at 8 to 10 weeks**





**Roof of stomodeum (inferior view; 6 to 7 weeks)****Palate formation (inferior view; 7 to 8 weeks)****Roof of oral cavity (inferior view; 8 to 10 weeks)**

# Tongue

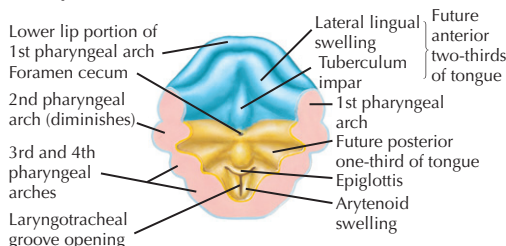
## GENERAL INFORMATION

Pharyngeal Arch	Embryonic Structure(s)	Adult Structure	Innervation
1	2 lateral lingual swellings Tuberculum impar	Anterior 2/3 of the tongue	GSA: Lingual branch of the mandibular division of the trigeminal n. SVA: Chorda tympani of the facial n.
2	Is overgrown by the 3rd arch; does not contribute to the adult tongue Very little contributes to the hypobranchial eminence	Does not contribute to the adult tongue	
3	Hypobranchial eminence	Posterior 1/3 of the tongue	GSA: Glossopharyngeal n. SVA: Glossopharyngeal n.
4	Hypobranchial eminence Epiglottic swelling Arytenoid swelling Laryngotracheal groove	Root of the tongue	GSA: Internal laryngeal branch of the vagus n. SVA: Internal laryngeal branch of the vagus n.

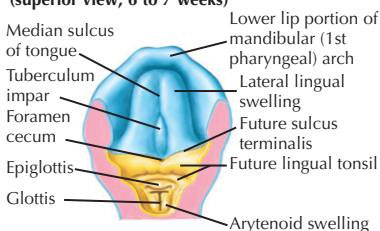
## MUSCLES

Mesoderm from the occipital somites migrates anteriorly with the hypoglossal nerve to give rise to the extrinsic and intrinsic muscles of the tongue

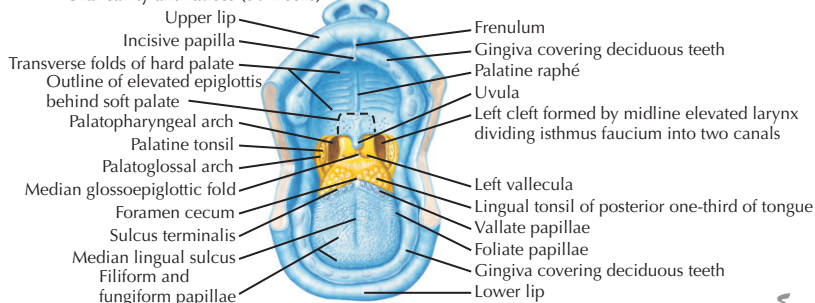
**Floor of oral cavity and pharynx (superior view; 5 to 6 weeks)**



**Floor of oral cavity and pharynx (superior view; 6 to 7 weeks)**



**Oral cavity and fauces (36 weeks)**



*F. Netter M.D.*

# 1 Thyroid Gland

## GENERAL INFORMATION

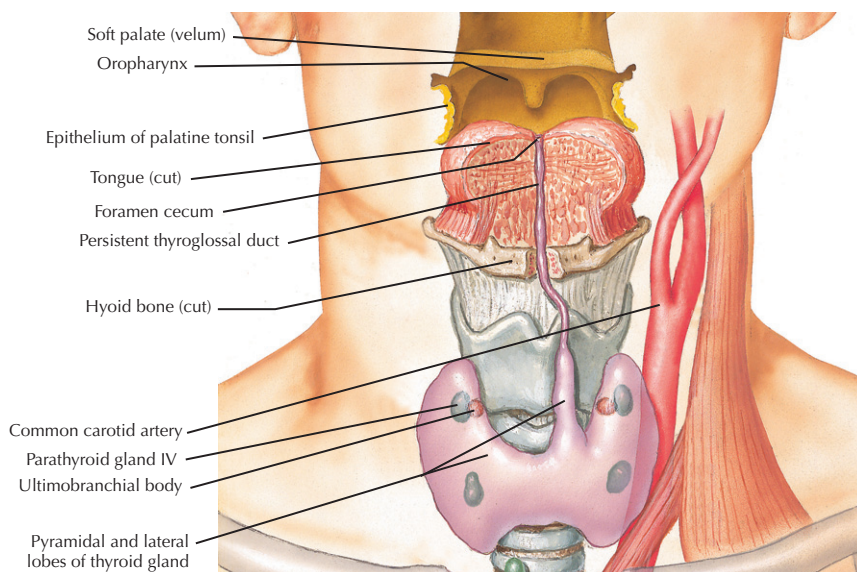
Begins as an invagination at the foramen cecum

Descends inferiorly to its final position alongside the larynx

May be connected to the foramen cecum by the thyroglossal duct

Divided into 2 lateral lobes connected by an isthmus, from which a pyramidal lobe sometimes develops

Follicular cells are derived from the endoderm; parafollicular cells are derived from the ultimobranchial body



*F. Netter M.D.*

# Clinical Correlate

## PHARYNGEAL POUCH ABNORMALITIES

### ECTOPIC THYROID

Thyroid tissue in an aberrant location

Often the only thyroid tissue in the affected person

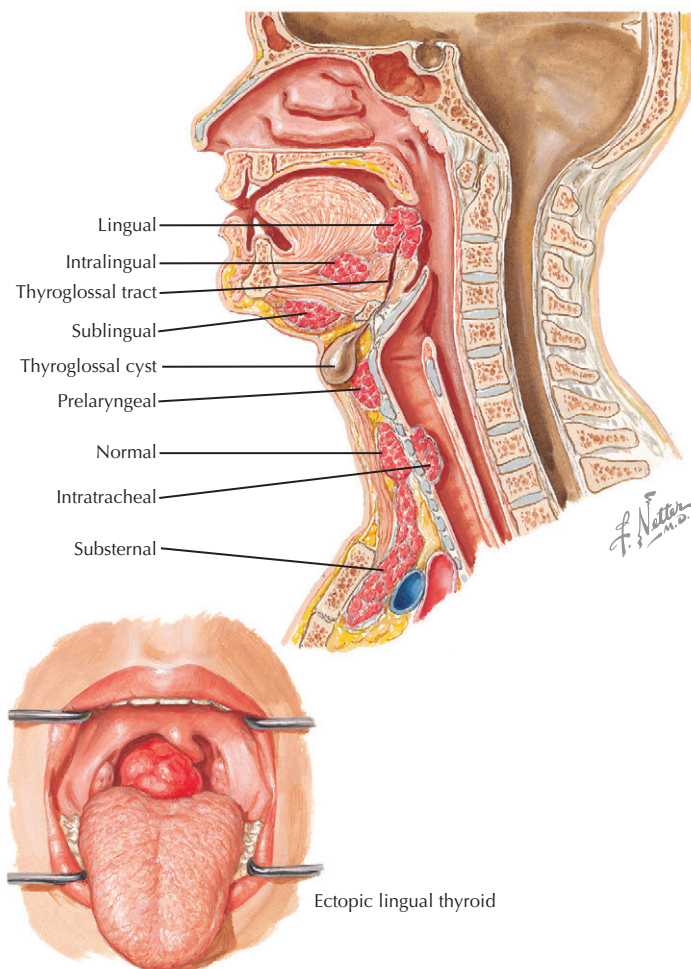
Susceptible to thyroid diseases like normal thyroid tissue

May occur anywhere along the migratory pathway of the thyroid gland beginning at the foramen cecum

Usually located at the base of the tongue (lingual thyroid)

Common locations include:

- Lingual thyroid
- Sublingual thyroid
- Thyroglossal duct remnant
- Anterior mediastinum
- Prelaryngeal
- Intralingual
- Intratracheal



# 1 Clinical Correlate

## PHARYNGEAL ARCH ABNORMALITIES

### PIERRE ROBIN

First reported as a condition characterized by micrognathia, cleft palate, and glossoptosis  
Now includes any condition with a series of anomalies caused by events initiated by a single malformation

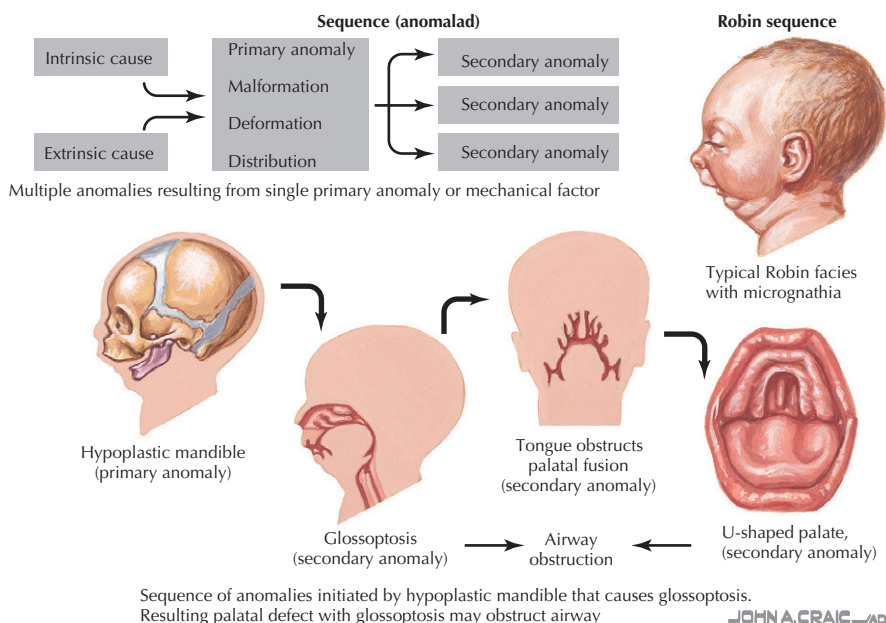
In this micrognathia, the inferior dental arch is posterior to the superior arch

The cleft palate may affect the hard and the soft palate

Glossoptosis (posterior displacement of the tongue) may cause airway obstruction or apnea

The mandible usually grows fairly quickly during childhood

Multiple surgeries typically needed to correct the cleft palate and to aid speech development in children



## Clinical Correlate

### PHARYNGEAL ARCH ABNORMALITIES *CONTINUED*

#### TREACHER COLLINS

A hereditary condition affecting the head and neck

Thought to be caused by a defect in the gene or chromosome 5

Children of an affected parent have a 50% risk of having the syndrome

Clinical manifestations include:

- Downslanting eyes
- Notching of the lower eyelids
- Hypoplastic mandible
- Hypoplastic zygomatic bones (zygomas)
- Underdeveloped or malformed ears or “sideburns,” or both, are prominent

Common associated problems include:

- Hearing loss
- Eating/breathing difficulties
- Cleft palate



Treacher Collins syndrome



# 1 Clinical Correlate

## PHARYNGEAL ARCH ABNORMALITIES *CONTINUED*

### DIGEORGE SYNDROME

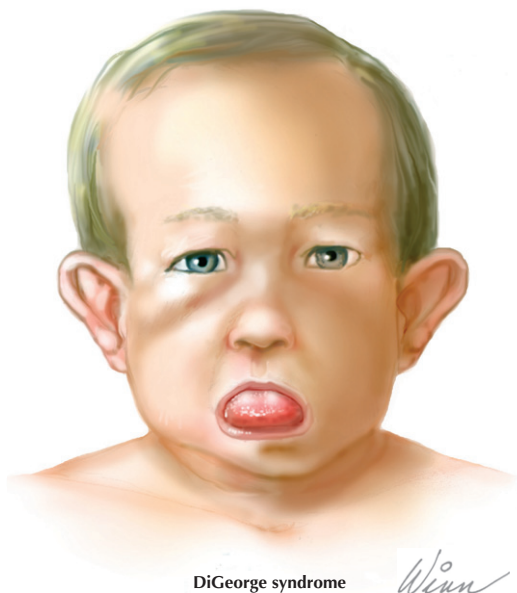A rare condition caused by a deletion on chromosome 22, characterized by a wide array of clinical manifestations

Possible explanation: proper development is dependent on migration of neural crest cells to the area of the pharyngeal pouches

Although researchers described the syndrome as abnormal development of the 3rd and 4th pharyngeal pouches, defects involving the 1st to the 6th pouches have been observed

Possible associated problems include:

- Congenital heart defects (such as tetralogy of Fallot, right infundibular stenosis, truncus arteriosus, aberrant left subclavian artery, and ventricular septal defect)
- Facial defects (such as cleft palate, microstomia, downslanting eyes, low-set ears, or hypertelorism)
- Increased vulnerability to infections (due to impaired immune system from the loss of T cells associated with absence or hypoplasia of the thymus)



DiGeorge syndrome

*Winn*

# Clinical Correlate

## CLEFT LIP AND PALATE

*Cleft lip:* a gap in the upper lip

*Cleft palate:* a gap in the palate

Classification of the developmental defect is with reference to the incisive foramen:

- Primary cleft
- Secondary cleft
- Complete cleft

Both cleft lip and cleft palate often cause difficulty with feeding and eventually speech

Surgery is the most common form of treatment for both

### PRIMARY

Occurs anterior to the incisive foramen and results from a failure of the mesenchyme in the lateral palatine process to fuse with the intermaxillary segment (primary palate)

*Common types of primary cleft:*

- Unilateral cleft lip
- Unilateral cleft alveolus
- Unilateral cleft lip and primary palate
- Bilateral cleft lip and primary palate

### SECONDARY

Occurs posterior to the incisive foramen; results from failure of the lateral palatine process to fuse together

*Common types of secondary cleft:*

- Cleft in soft palate
- Unilateral cleft in hard and soft palate
- Bilateral cleft of hard and soft palate

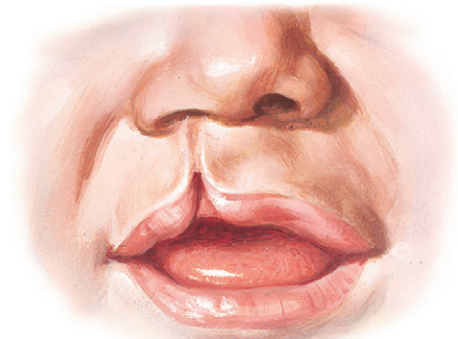### COMPLETE

Extends through the lip, the primary palate, and the lateral palatine process; results from a failure of the lateral palatine process to fuse together with each other, as well as with the nasal septum and primary palate

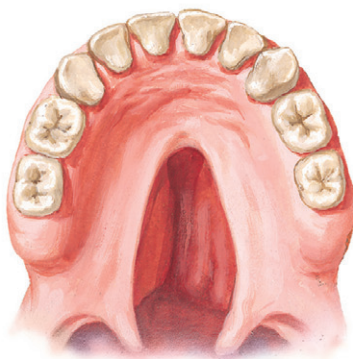
*Common types of complete cleft:*

- Unilateral cleft lip and cleft palate
- Bilateral cleft lip and cleft palate

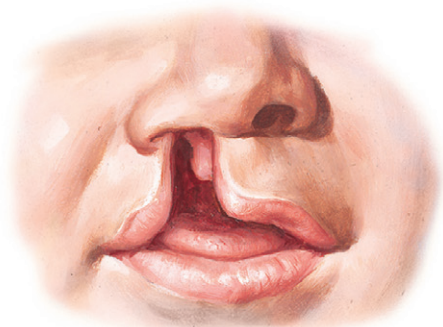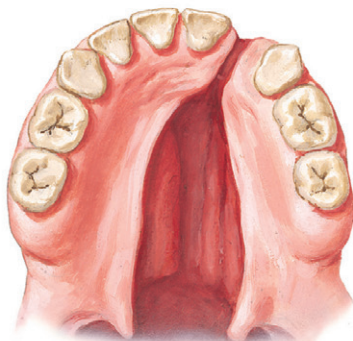

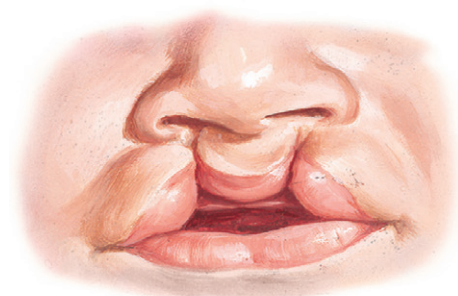


Unilateral cleft lip—partial



Partial cleft of palate

Unilateral cleft of primary palate—  
complete, involving lip and alveolar ridgeComplete cleft of secondary palate  
and unilateral cleft of primary palate

Bilateral cleft lip

*F. Netter M.D.*

## CHAPTER 2

# OSTEOLOGY

Overview	26
Bones of the Skull	28
Views and Sutures	47
Major Foramina and Fissures	51
Cervical Vertebrae	56
Clinical Correlates	61

## 2 Overview

### GENERAL INFORMATION

Most complicated bony structure in the human body

The complete bony framework of the head; includes the mandible

28 individual bones make up the skull:

- 11 are paired
- 6 are single

Wormian bones, or sutural bones, are irregularly shaped small bones found along sutures that occur naturally

### FUNCTIONS

Most important function: to protect the brain

Also protects the 5 organs of special sense:

- Olfaction
- Vision
- Taste
- Vestibular function
- Auditory function

### DIVISIONS

Two major ways to divide the bones of the skull:

- Regional
- Developmental

*Regionally*, the skull is divided into the mandible (lower jaw) and cranium (skull without the mandible)

Cranium is further divided into:

- Cranial vault—upper portion of the skull
- Cranial base—inferior portion of the skull
- Cranial cavity—interior of the skull
- Facial skeleton—bones that make up the face
- Acoustic skeleton—ear ossicles

*Developmentally*, the skull is divided into:

- Viscerocranium—the portion of the skull related to the digestive and respiratory systems
- Neurocranium—the portion of the skull that protects the brain and the 5 organs of special sense

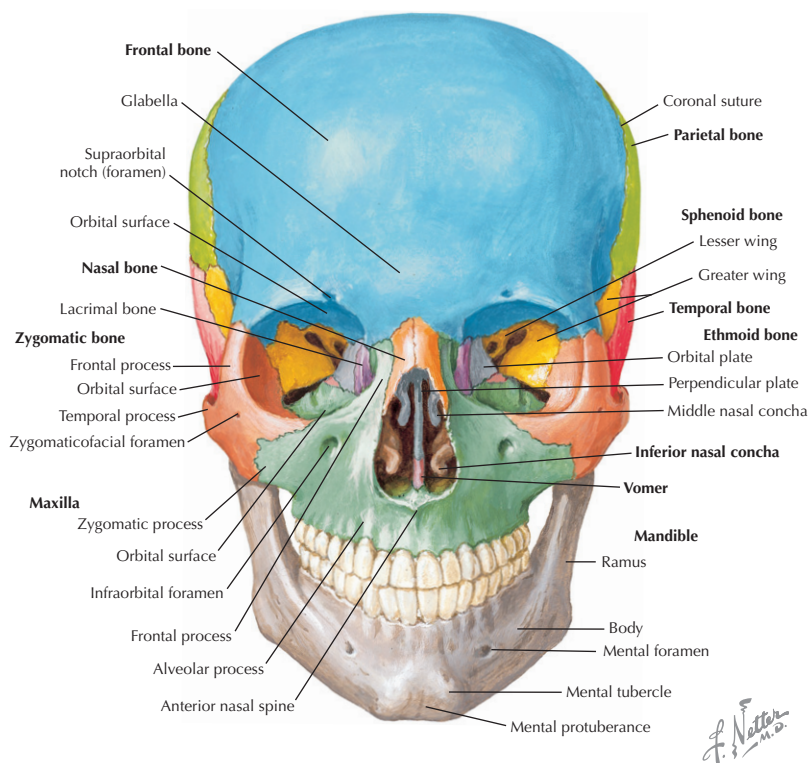
Cranial cavity divisions:

- Anterior cranial fossa—contains the frontal lobe of the brain
- Middle cranial fossa—contains the temporal lobe of the brain
- Posterior cranial fossa—contains the cerebellum

Skull is depicted by observing it from 5 views:

- Norma frontalis—the anterior view
- Norma lateralis—the lateral view
- Norma occipitalis—the posterior view
- Norma basalis—the inferior view
- Norma verticalis—the superior view

Bone	Single	Paired	Articulates with
Frontal	X		Parietal, sphenoid, zygomatic, maxilla, ethmoid, nasal, lacrimal
Parietal		X	Frontal, parietal, temporal, occipital, sphenoid
Temporal		X	Parietal, occipital, sphenoid, zygomatic, mandible
Occipital	X		Parietal, temporal, sphenoid, and atlas (C1)
Sphenoid	X		Frontal, parietal, temporal, occipital, zygomatic, maxilla, ethmoid, palatine, vomer
Zygomatic		X	Frontal, temporal, maxilla
Maxilla		X	Frontal, sphenoid, zygomatic, maxilla, ethmoid, palatine, vomer, nasal, lacrimal, inferior nasal concha
Ethmoid	X		Frontal, sphenoid, maxilla, palatine, vomer, nasal, lacrimal, inferior nasal concha
Palatine		X	Sphenoid, maxilla, ethmoid, palatine, vomer, inferior nasal concha
Vomer	X		Sphenoid, maxilla, ethmoid, palatine
Nasal		X	Frontal, maxilla, nasal
Lacrimal		X	Frontal, maxilla, ethmoid, inferior nasal concha
Inferior nasal concha		X	Maxilla, ethmoid, palatine, lacrimal
Mandible	X		Temporal

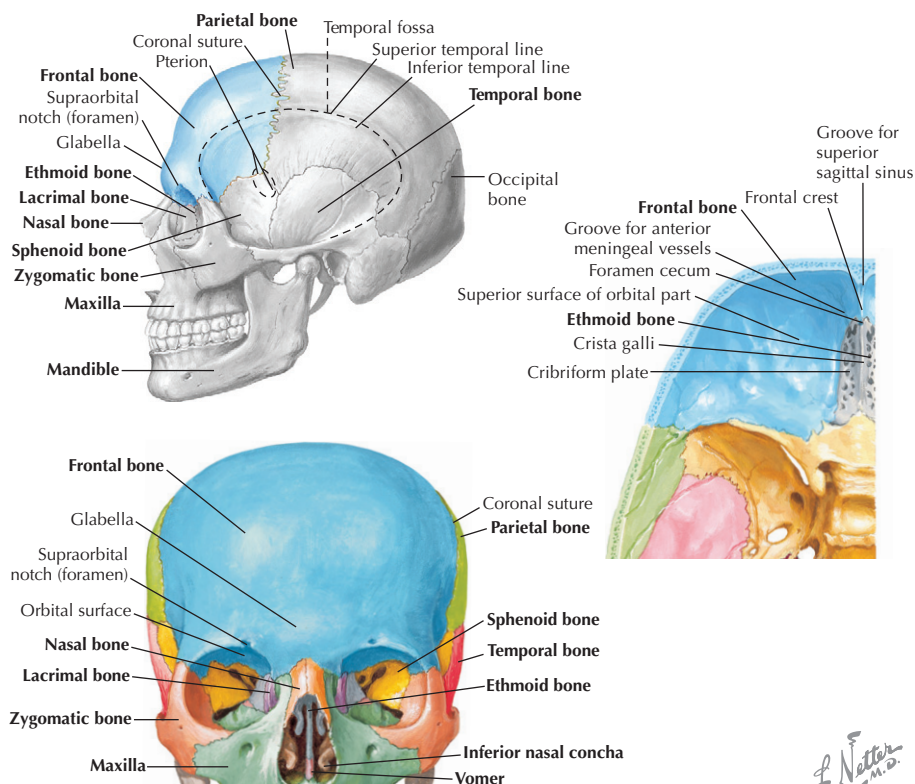


*F. Netter M.D.*

## 2 Bones of the Skull

### FRONTAL BONE

Characteristics	Parts	Ossification	Comments
Contains the frontal paranasal sinuses Has two primary centers that ossify along the frontal suture (metopic) in the 2nd year Helps form the foramen cecum, which allows passage of an emissary vein that connects to the superior sagittal sinus There is 1 frontal bone	Squamous portion	<i>For all 3 parts:</i> Intramembranous	The largest part of the frontal bone Forms the majority of the forehead Forms the supraorbital margin and the superciliary arch The zygomatic process of the frontal bone extends from the posterior part of the supraorbital margin <i>Arachnoid foveae</i> —depressions caused by arachnoid granulations that push on the dura mater, causing bone resorption on the endocranial surface
	Orbital portion		Forms the roof of the orbit and floor of the anterior cranial fossa
	Nasal portion		The trochlea of the orbit articulates with the orbital portion Articulates with the nasal bones and the frontal process of the maxilla to form the root of the nose

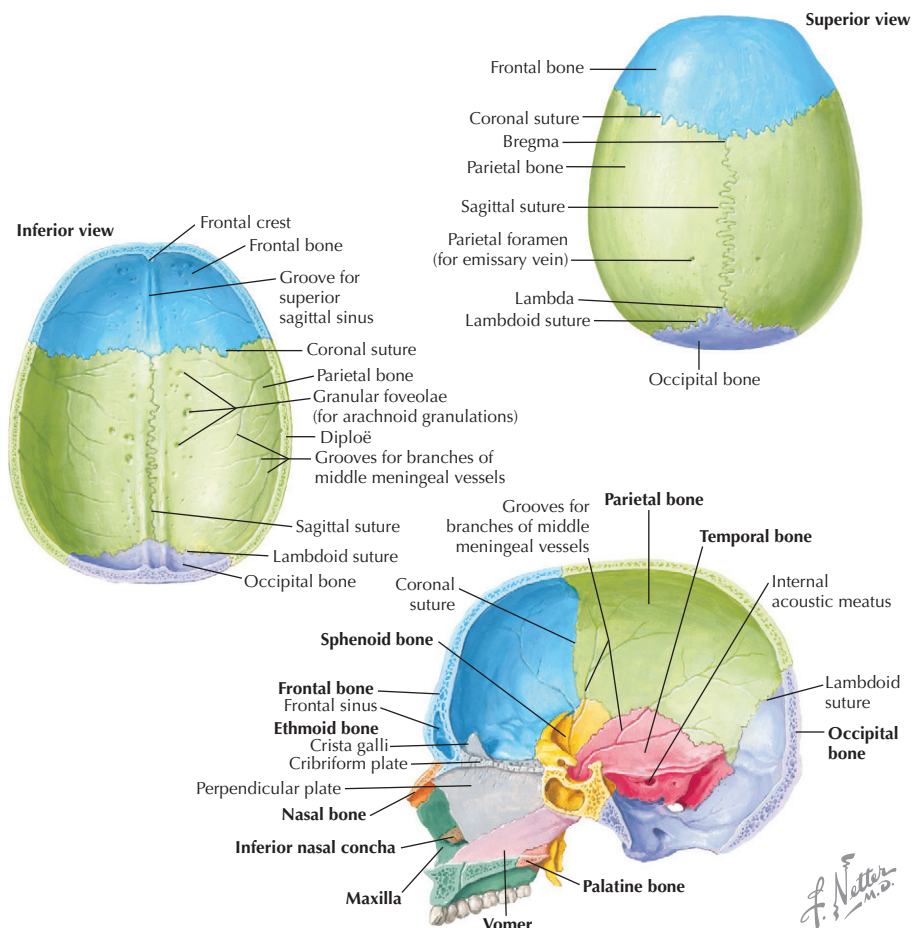


*F. Netter M.D.*

# Bones of the Skull

## PARIETAL BONE

Characteristics	Parts	Ossification	Comments
<p>Forms the majority of the cranial vault</p> <p>Provides for the attachment of the temporalis muscle</p> <p>The four corners of the parietal are not ossified at birth and give rise to the fontanelles</p> <p>There are 2 parietal bones</p>	<p>Has 4 angles:</p> <ul style="list-style-type: none"> <li>• Frontal—located at bregma</li> <li>• Sphenoid—located at pterion</li> <li>• Occipital—located at lambda</li> <li>• Mastoid—located at asterion</li> </ul>	Intramembranous	<p>Relatively square, forming the roof and sides of the cranial vault</p> <p>Endocranial surface is filled with grooves made by branches of the middle meningeal a.</p> <p>Sigmoid sulcus is a groove caused by the beginning of the transverse sinus, located at the mastoid angle</p>



## 2 Bones of the Skull

### OCCIPITAL BONE

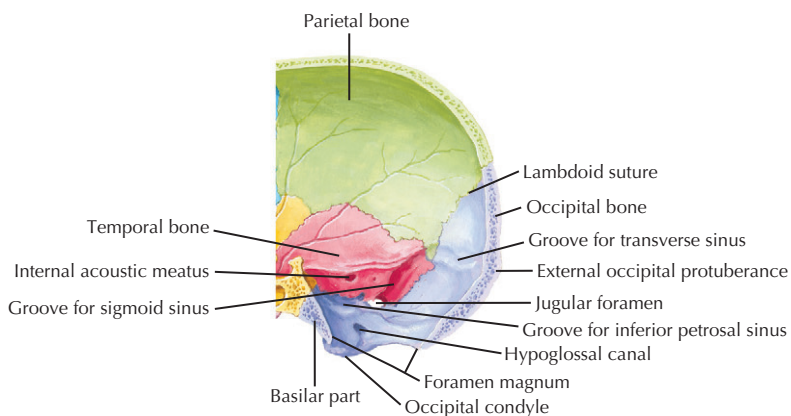
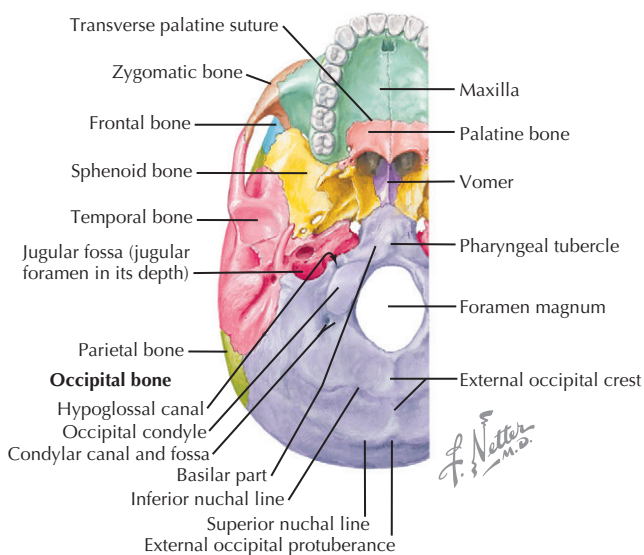
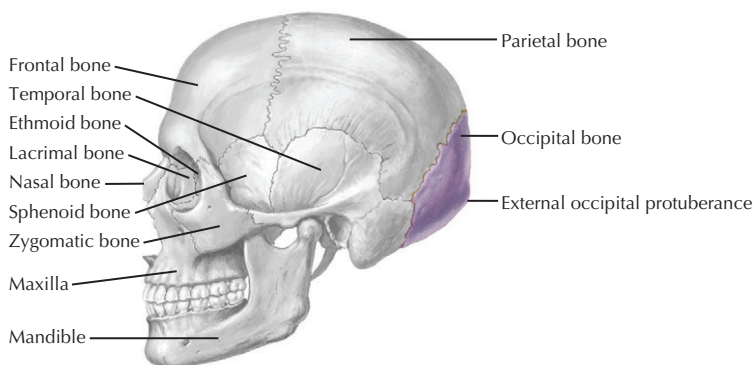
Characteristics	Parts	Ossification	Comments
<p>Forms the posterior part of the cranial vault</p> <p>Articulates with the atlas</p> <p>The squamous and lateral portions normally ossify together by year 4</p> <p>The basilar portion unites to this section at year 6</p> <p>There is 1 occipital bone</p>	Squamous portion	Intramembranous	<p>Articulates with the temporal and parietal bones</p> <p>The largest portion of the occipital bone</p> <p>Located posterior and superior to the foramen magnum</p> <p>Has the external occipital protuberance (more pronounced in males)</p> <p>Has the superior and the inferior nuchal lines</p> <p>Has grooves on the internal surface for 3 of the sinuses forming the confluence of the sinuses (the superior sagittal and the right and left transverse sinuses)</p> <p>The depression superior to the transverse sinus is for the occipital lobes of the brain</p> <p>The depression inferior to the transverse sinus is for the cerebellum</p>
	Lateral portion	Endochondral	<p>Articulates with the temporal bone</p> <p>Is the portion lateral to the foramen magnum</p> <p>Has the occipital condyles that articulate with the atlas</p> <p>Contains the hypoglossal canal</p> <p>Forms a portion of the jugular foramen</p>
	Basilar portion	Endochondral	<p>Articulates with the petrous part of the temporal and the sphenoid bones</p> <p>Is the portion immediately anterior to the foramen magnum</p> <p>Pharyngeal tubercle is part of the basilar portion that provides attachment for the superior constrictor</p> <p>Internal surface of the basilar portion is called the clivus, and part of the brainstem lies against it</p>



# Bones of the Skull

## OCCIPITAL BONE *CONTINUED*

2





## 2 Bones of the Skull

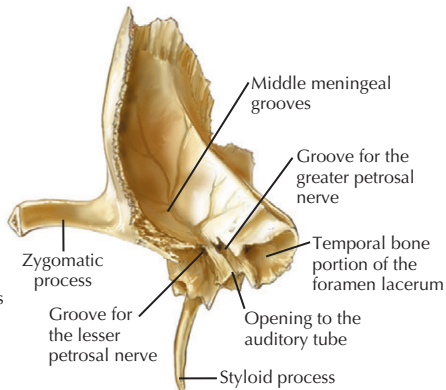
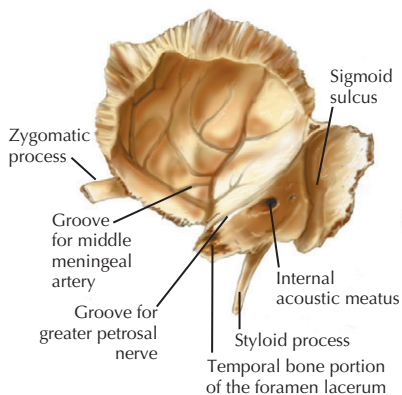
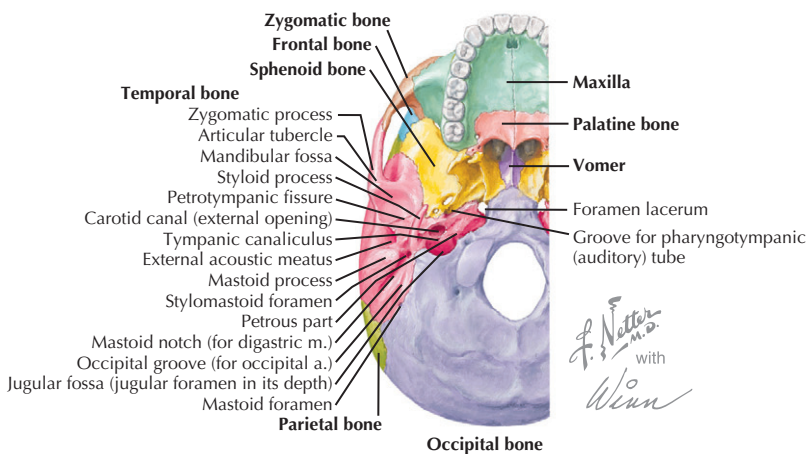
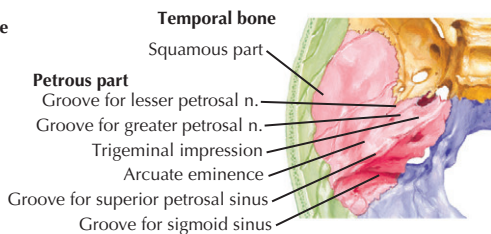
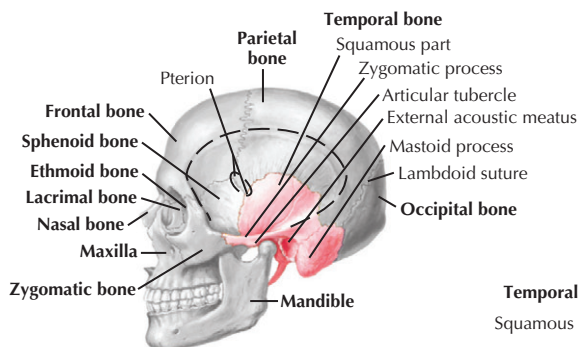
### TEMPORAL BONE

Characteristics	Parts	Ossification	Comments
<p>The paired temporal bones: Help form the base and the lateral walls of the skull House the auditory and vestibular apparatuses</p> <p>Contain mastoid air cells Each bone has 8 centers of ossification that give rise to the 3 major centers observed before birth There are 2 temporal bones</p>	Squamous part	Intramembranous	<p>The largest portion of the bone Three portions to the squamous part:</p> <ul style="list-style-type: none"> <li>• Temporal</li> <li>• Zygomatic process</li> <li>• Glenoid fossa</li> </ul> <p><i>Temporal portion</i> is the thin large area on the squamous part of the temporal</p> <p>On the internal surface of the temporal portion lies a groove for the middle meningeal a.</p> <p>The <i>zygomatic process</i> extends laterally and anteriorly from the squamous portion; it articulates with the temporal process of the zygomatic bone to make the zygomatic arch</p> <p><i>Glenoid fossa</i> is inferior and medial to the zygomatic process; it articulates with the mandibular condyle, forming the temporomandibular joint</p>
	Petrous part	Endochondral	<p>Forms the solid portion of bone The auditory and vestibular apparatuses are located within the petrous part Helps separate the temporal and the occipital lobes of the brain It extends anteriorly and medially The medial part articulates with the sphenoid bone to form the foramen lacerum Internal acoustic meatus is observed on the medial side of the petrous part Carotid canal lies on the inferior part of the petrous part Petrotympanic fissure lies between the petrous part of the temporal bone and the tympanic part of the temporal bone On the medial portion of the petrous part lie grooves for the superior and inferior petrosal sinuses On the posterior inferior surface of the petrous part lies the jugular fossa Between the jugular fossa and the carotid canal is the tympanic canaliculus The mastoid process extends posteriorly and has large mastoid air cells</p>
	Tympanic part	Intramembranous	<p>A plate of bone forming the anterior, posterior, and inferior portions of the external acoustic meatus Anterior part forms the posterior portion of the glenoid fossa</p>
	Styloid process	Endochondral	<p>A projection from the temporal bone The stylomastoid foramen lies posterior to this process</p>

# Bones of the Skull

## TEMPORAL BONE CONTINUED

2



## 2 Bones of the Skull

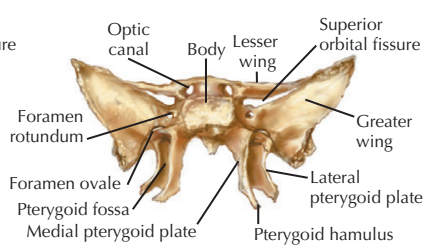
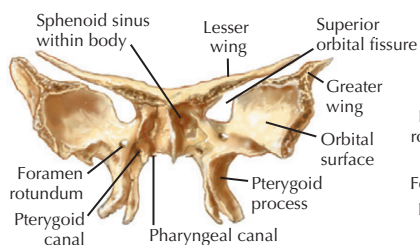
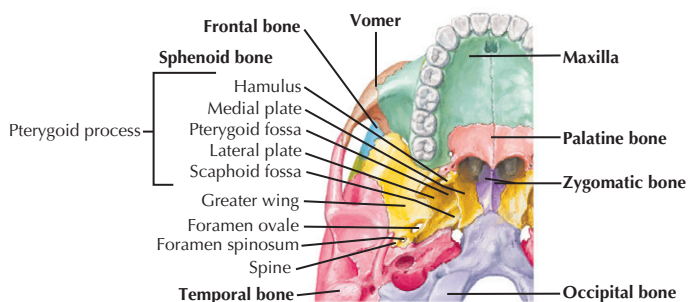
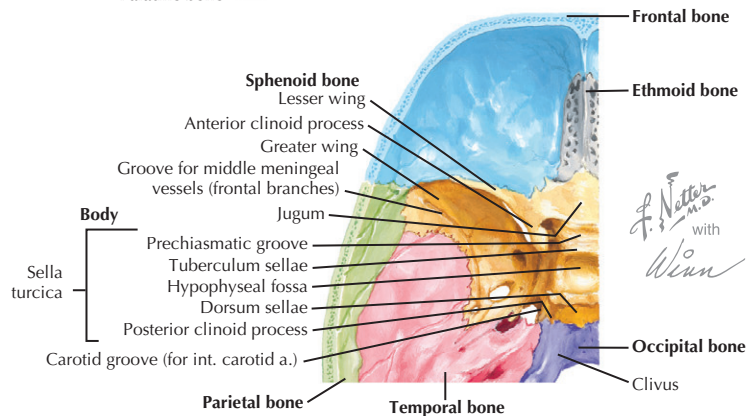
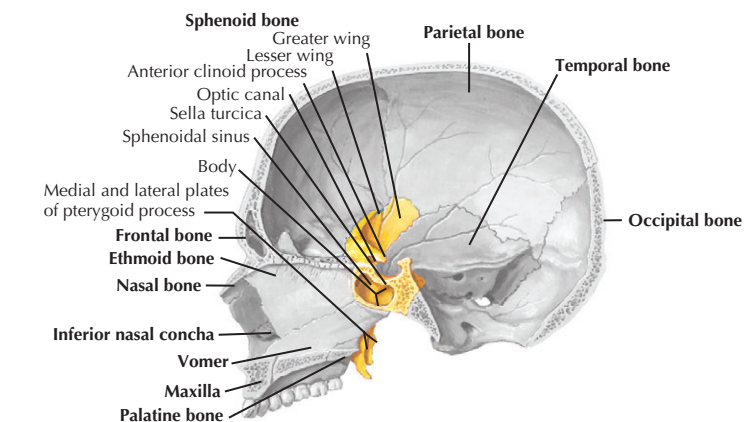
### SPHENOID BONE

Characteristics	Parts	Ossification	Comments
<p>Forms the majority of the middle portion of the cranial base</p> <p>Forms the majority of the middle cranial fossa</p> <p>Contains the sphenoid paranasal sinus</p> <p>There is 1 sphenoid bone</p>	Body	Endochondral ossification	<p>The center of the sphenoid</p> <p>Anterior portion of the body helps form part of the nasal cavity</p> <p>Superior part of the body, known as the sella turcica, is saddle-shaped and possesses the anterior and posterior clinoid processes</p> <p>Hypophyseal fossa, the deepest part of the sella turcica, houses the pituitary gland</p> <p>Dorsum sellae is a square-shaped part of the bone that lies posterior to the sella turcica</p> <p>Clivus is the portion that slopes posterior to the body</p> <p>Body contains the sphenoid paranasal sinuses</p> <p>Lateral portion of the body is covered by the cavernous sinus</p> <p>Optic canal is found in the body of the sphenoid</p>
	Greater wing	Endochondral and intramembranous ossification	<p>Extends laterally and anteriorly from the posterior portion of the body of the sphenoid</p> <p>Endocranial portion helps form a large part of the middle cranial fossa</p> <p>Lateral portion is the infratemporal surface</p> <p>Anterior portion lies in the orbit</p> <p>Contains 3 foramina:</p> <ul style="list-style-type: none"> <li>• Foramen spinosum</li> <li>• Foramen rotundum</li> <li>• Foramen ovale</li> </ul>
	Lesser wing	Endochondral ossification	<p>Extends laterally and anteriorly from the superior portion of the sphenoid body</p> <p>Separated from the greater wing by the superior orbital fissure</p>
	Pterygoid process	Intramembranous ossification	<p>Arises from the inferior surface of the body</p> <p>There are 2 pterygoid processes</p> <p>Each has a:</p> <ul style="list-style-type: none"> <li>• Lateral pterygoid plate</li> <li>• Medial pterygoid plate</li> </ul> <p>Pterygoid hamulus extends from the medial pterygoid plate</p> <p>Two canals are associated with the pterygoid process:</p> <ul style="list-style-type: none"> <li>• Pterygoid canal</li> <li>• Pharyngeal canal</li> </ul>

# Bones of the Skull

## SPHENOID BONE CONTINUED

2



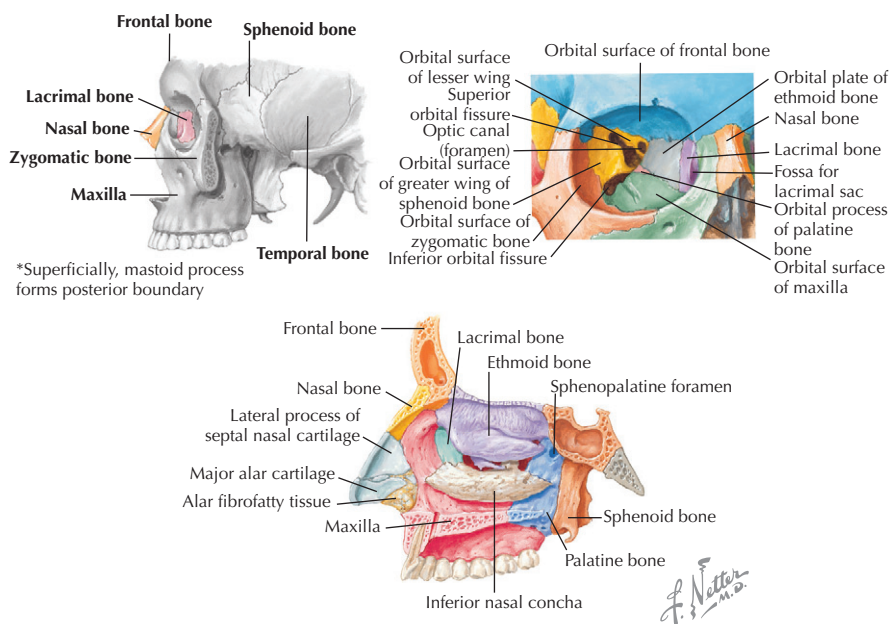
## 2 Bones of the Skull

### LACRIMAL BONE

Characteristics	Parts	Ossification	Comments
Lacrimal bone is small and rectangular in shape and very thin and fragile There are 2 lacrimal bones		Intramembranous	Forms a small portion of the medial wall of the orbit Articulates with the frontal process of the maxilla, orbital plate of the ethmoid bone, the frontal bone, and the inferior nasal concha The region that articulates with the frontal process of the maxilla forms the lacrimal fossa, the location of the lacrimal sac The inferior part of the lacrimal forms a small portion of the lateral wall of the nasal cavity

### NASAL BONE

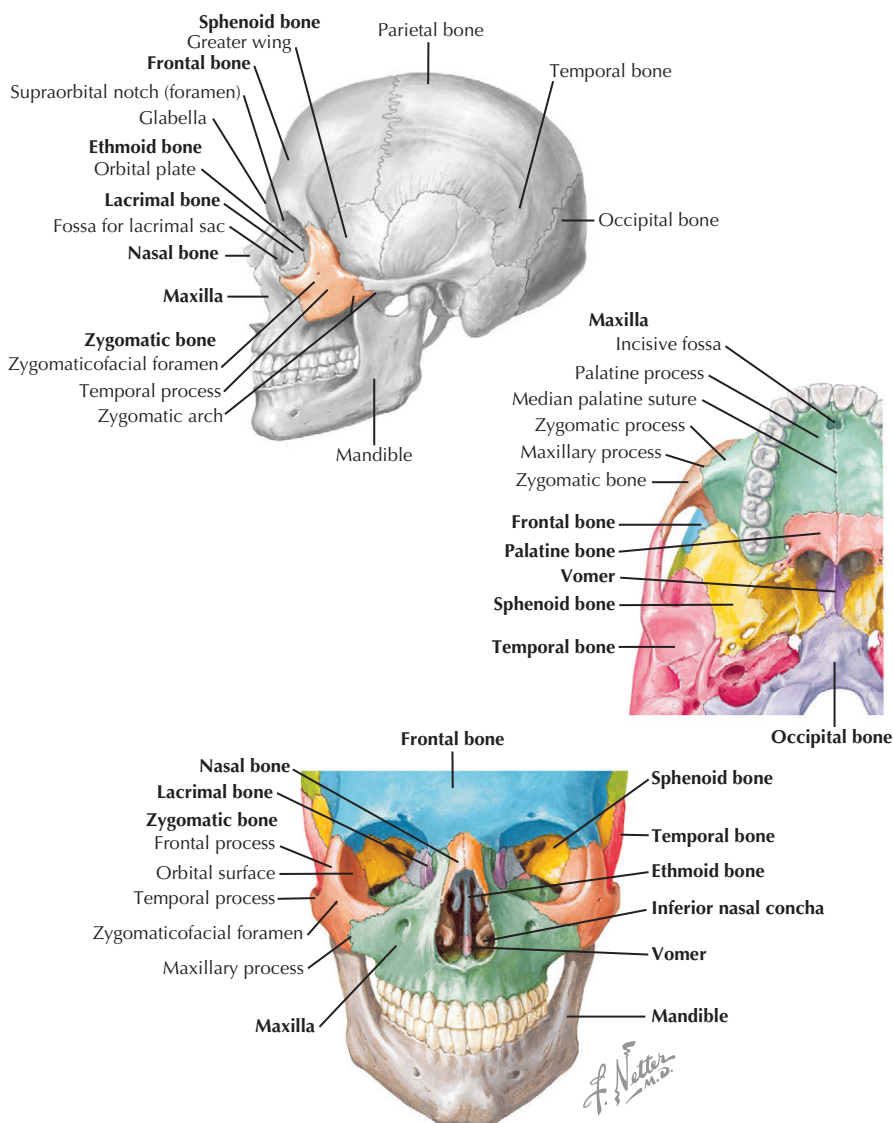
Characteristics	Parts	Ossification	Comments
Inferior portion forms the superior margin of the nasal aperture Forms the bridge of the nose There are 2 nasal bones		Intramembranous	Articulates with the nasal bone of the opposite side, the nasal portion of the frontal bone, the frontal process of the maxilla, and the perpendicular plate of the ethmoid Inferior portion of the nasal bones attaches with the lateral nasal cartilages and septal cartilage



# Bones of the Skull

## ZYGOMATIC BONE (ZYGOMA)

Characteristics	Part	Ossification	Comments
Forms the majority of the skeleton of the cheek Provides for attachment of the masseter  Three foramina in the zygoma: • Zygomatico-orbital foramen • Zygomaticofacial foramen • Zygomaticotemporal foramen There are 2 zygomatic bones	Frontal process Temporal process  Maxillary process	Intramembranous	Articulates with the frontal bone to help form the orbit Articulates with the zygomatic process of the temporal bone to form the zygomatic arch Articulates with the zygomatic process of the maxillary bone to help form the orbit



## 2 Bones of the Skull

### ETHMOID BONE

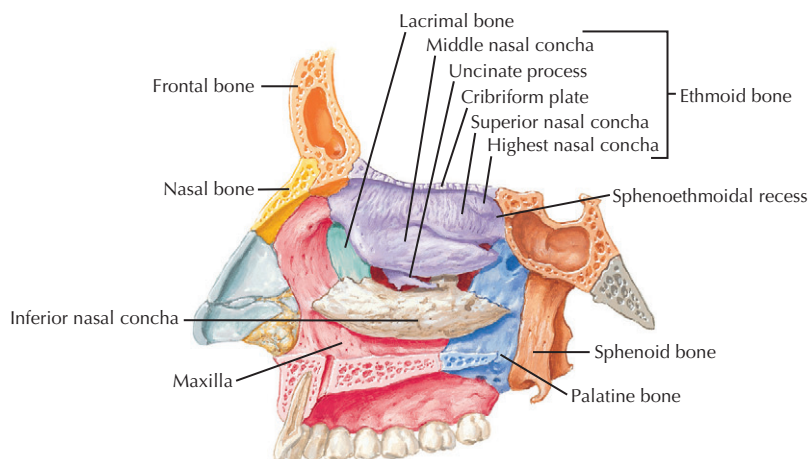
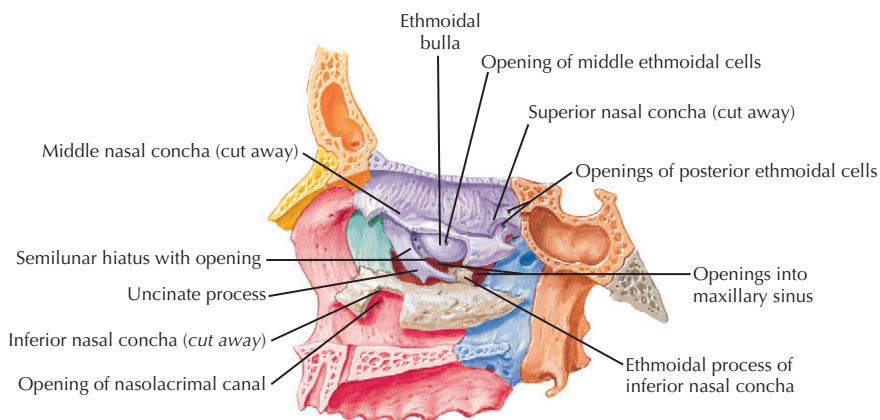
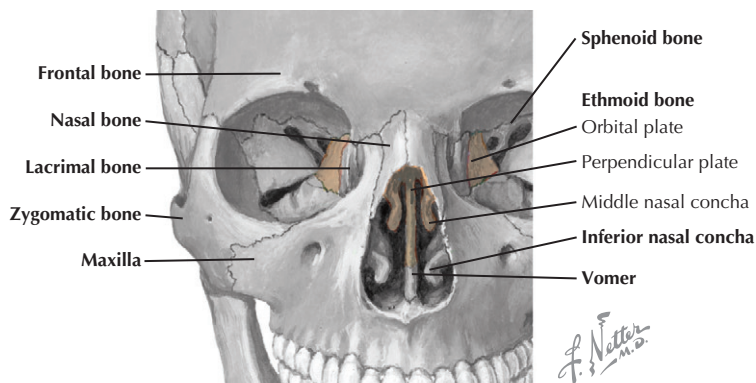
Characteristics	Part	Ossification	Comments
<p>A porous bone that forms the major portion of the middle part of the face between the orbits</p> <p>Helps form the orbit, nasal cavity, nasal septum, and anterior cranial fossa</p> <p>There is 1 ethmoid bone</p>	Perpendicular plate	Endochondral	<p>A flat plate that descends from the cribriform plate to form part of the nasal septum</p> <p>Articulates with the vomer inferiorly</p>
	Cribriform plate		<p>A horizontal bone that forms the superior surface of the ethmoid</p> <p>Contains numerous foramina for the olfactory n.</p> <p>Crista galli is a vertical plate that extends superiorly from the cribriform plate providing attachment for the falx cerebri of the meninges</p> <p>Associated with a small foramen cecum</p>
	Ethmoid labyrinth		<p>The largest part of the ethmoid bone</p> <p>Descends inferiorly from the cribriform plate</p> <p>Ethmoid paranasal sinuses are located within the ethmoid labyrinth</p> <p>Ethmoid labyrinth forms 2 major structures within the nasal cavity:</p> <ul style="list-style-type: none"> <li>• Superior nasal concha</li> <li>• Middle nasal concha</li> </ul> <p>Ethmoid bulla is the large elevation of bone located by the middle ethmoid paranasal sinuses</p> <p>Uncinate process is a curved piece of bone</p> <p>Between the uncinate process and the ethmoid bulla is the hiatus semilunaris</p>



# Bones of the Skull

## ETHMOID BONE CONTINUED

2

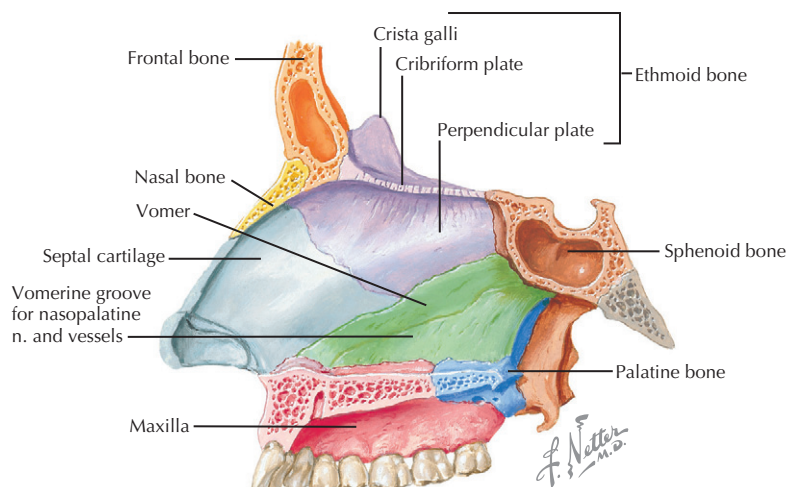
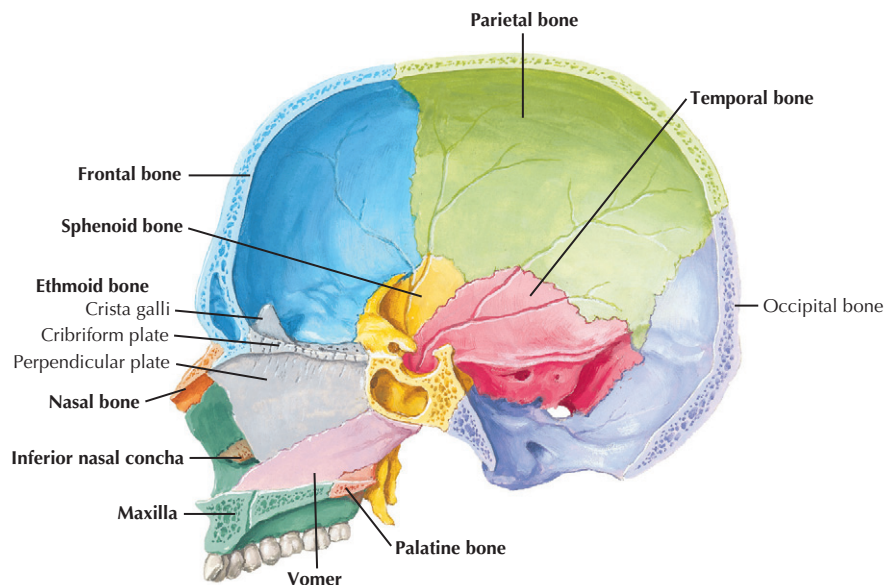




## 2 Bones of the Skull

### VOMER

Characteristics	Part	Ossification	Comments
Shaped like a "plough" Forms the posterior inferior part of the nasal septum There is 1 vomer bone		Intramembranous	Articulates with the perpendicular plate of the ethmoid, maxilla, palatine, and sphenoid bones and septal cartilage Posterior border does not articulate with any other bone



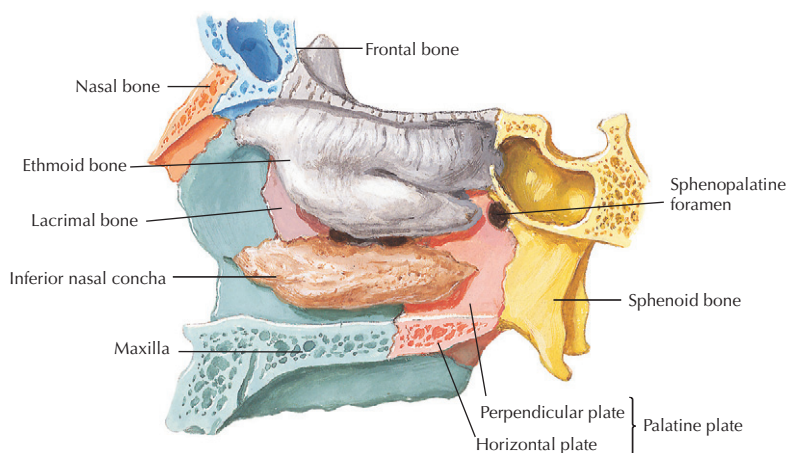
# Bones of the Skull

## INFERIOR NASAL CONCHA

Characteristics	Part	Ossification	Comments
Is described as a curved bone that forms part of the lateral wall of the nasal cavity There are 2 inferior nasal conchae		Endochondral	Lies within a curve in the lateral wall of the nasal cavity Articulates with the maxilla and perpendicular plate of the palatine, lacrimal, and ethmoid bones

## PALATINE BONE

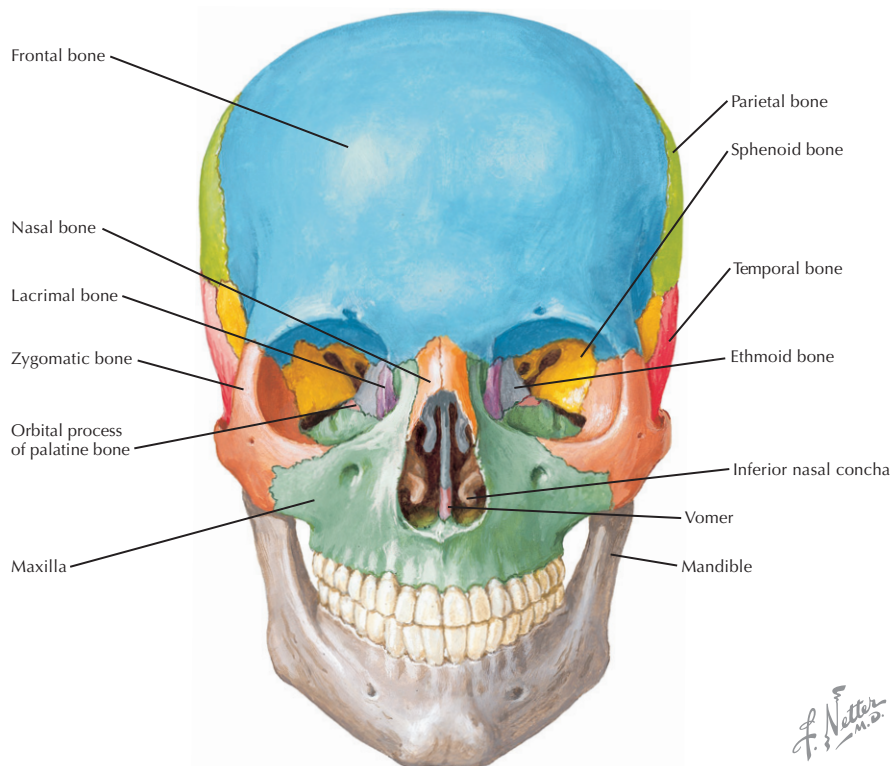
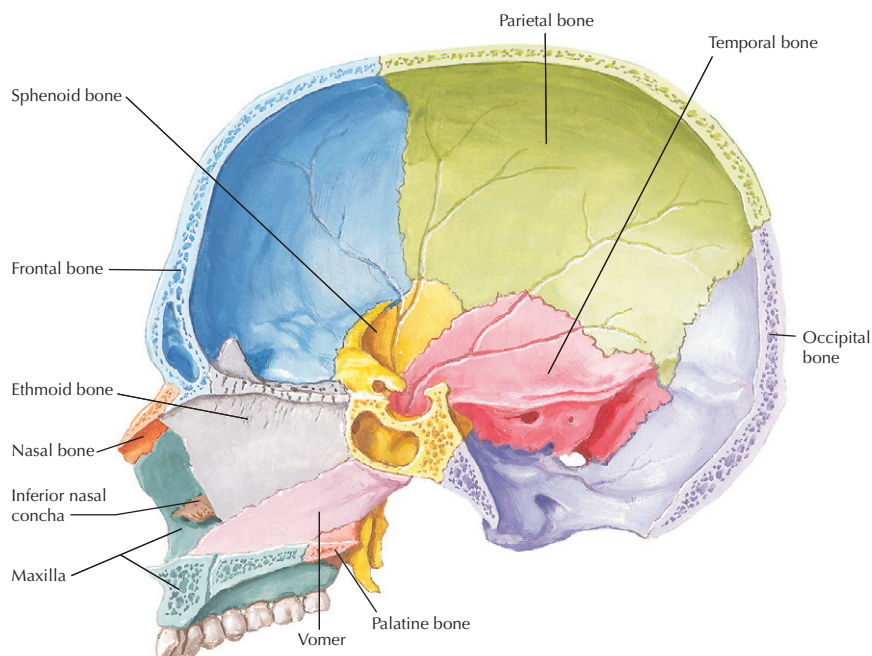
Characteristics	Part	Ossification	Comments
Forms part of the nasal cavity and the hard palate Is L-shaped There are 2 palatine bones	Perpendicular plate	Intramembranous	Is in the shape of a vertical rectangle On the superior border is a notch that articulates with the sphenoid bone, forming the sphenopalatine foramen A small orbital process helps form part of the orbit Forms part of the wall of the pterygopalatine fossa and the lateral wall of the nasal cavity Lateral wall articulates with the maxilla to form the palatine canal
	Horizontal plate		Forms the posterior portion of the hard palate Superior to the horizontal plate is the nasal cavity On the medial part, formed by both of the horizontal plates, is the posterior nasal spine Greater palatine foramen is on this plate
	Pyramidal process		Extends posteriorly and inferiorly from the junction of the perpendicular and horizontal plates of the palatine Lesser palatine foramina are located here



*F. Netter M.D.*

## 2 Bones of the Skull

### INFERIOR NASAL CONCHA CONTINUED

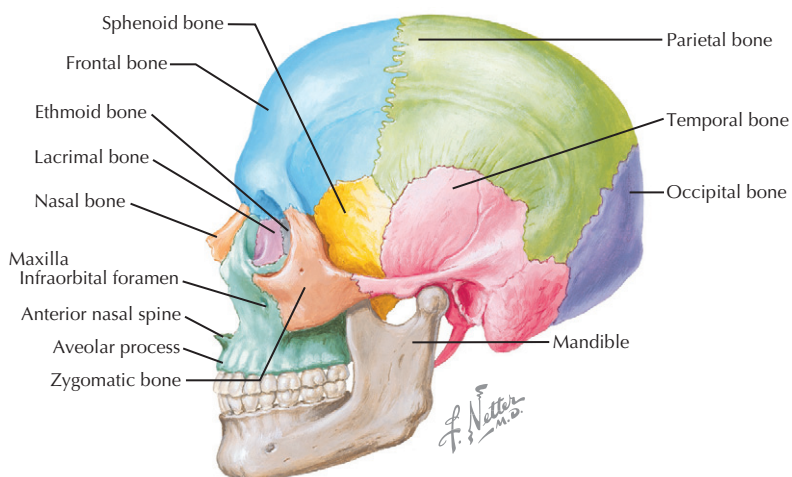


*F. Netter M.D.*

# Bones of the Skull

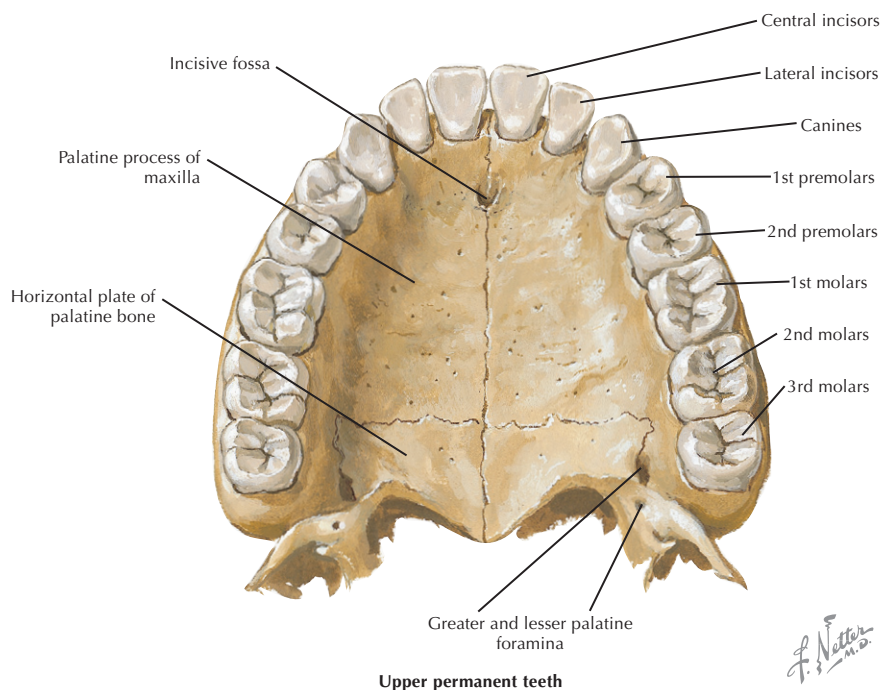
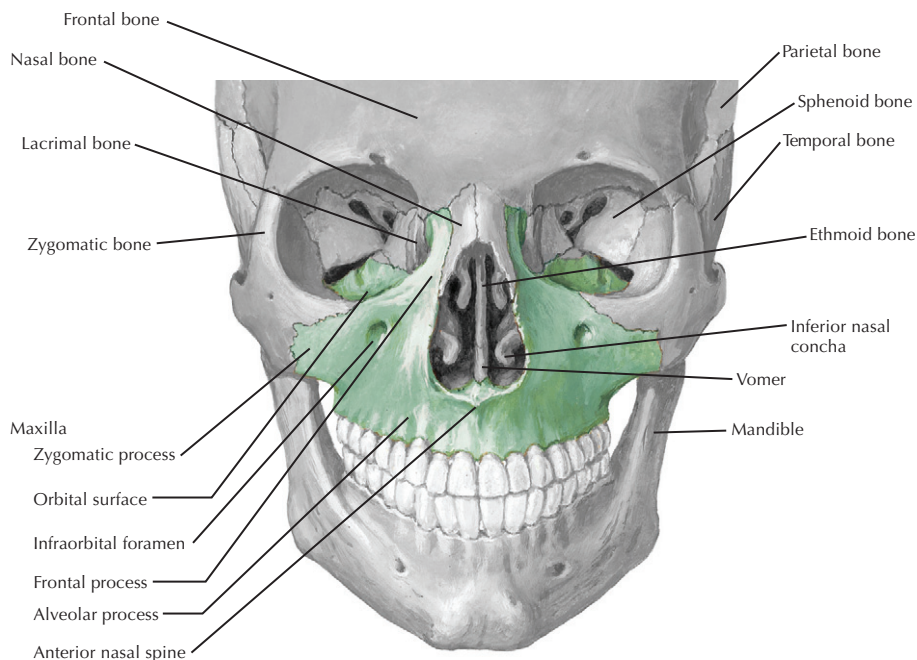
## MAXILLA

Characteristics	Part	Ossification	Comments
Forms the majority of the skeleton of the face and the upper jaw Contains the maxillary paranasal sinus Articulates with the opposite maxilla and the frontal, sphenoid, nasal, vomer, and ethmoid bones; inferior nasal concha; palatine, lacrimal, and zygomatic bones; and the septal and nasal cartilages There are 2 maxilla bones (maxillae)	Body	Intramembranous	Major part of the bone Shaped like a pyramid Contains the maxillary paranasal sinus <i>Gives rise to 4 different regions:</i> <ul style="list-style-type: none"> <li>• Orbit</li> <li>• Nasal cavity</li> <li>• Infratemporal fossa</li> <li>• Face</li> </ul> Infraorbital canal and foramen pass from the orbit region to the face region
	Frontal process		Extends superiorly to articulate with the nasal, frontal, ethmoid, and lacrimal bones Forms the posterior boundary of the lacrimal fossa
	Zygomatic process		Extends laterally to articulate with the maxillary process of the zygomatic bone
	Palatine process		Extends medially to form the majority of the hard palate Articulates with the palatine process of the opposite side and the horizontal plate of the palatine bone Incisive foramen is located in the anterior portion
	Alveolar process		The part of the maxilla that supports all of the maxillary teeth Extends inferiorly from the maxilla Each maxilla contains 5 primary and 8 permanent teeth Alveolar bone is resorbed when a tooth is lost



## 2 Bones of the Skull

### MAXILLA CONTINUED





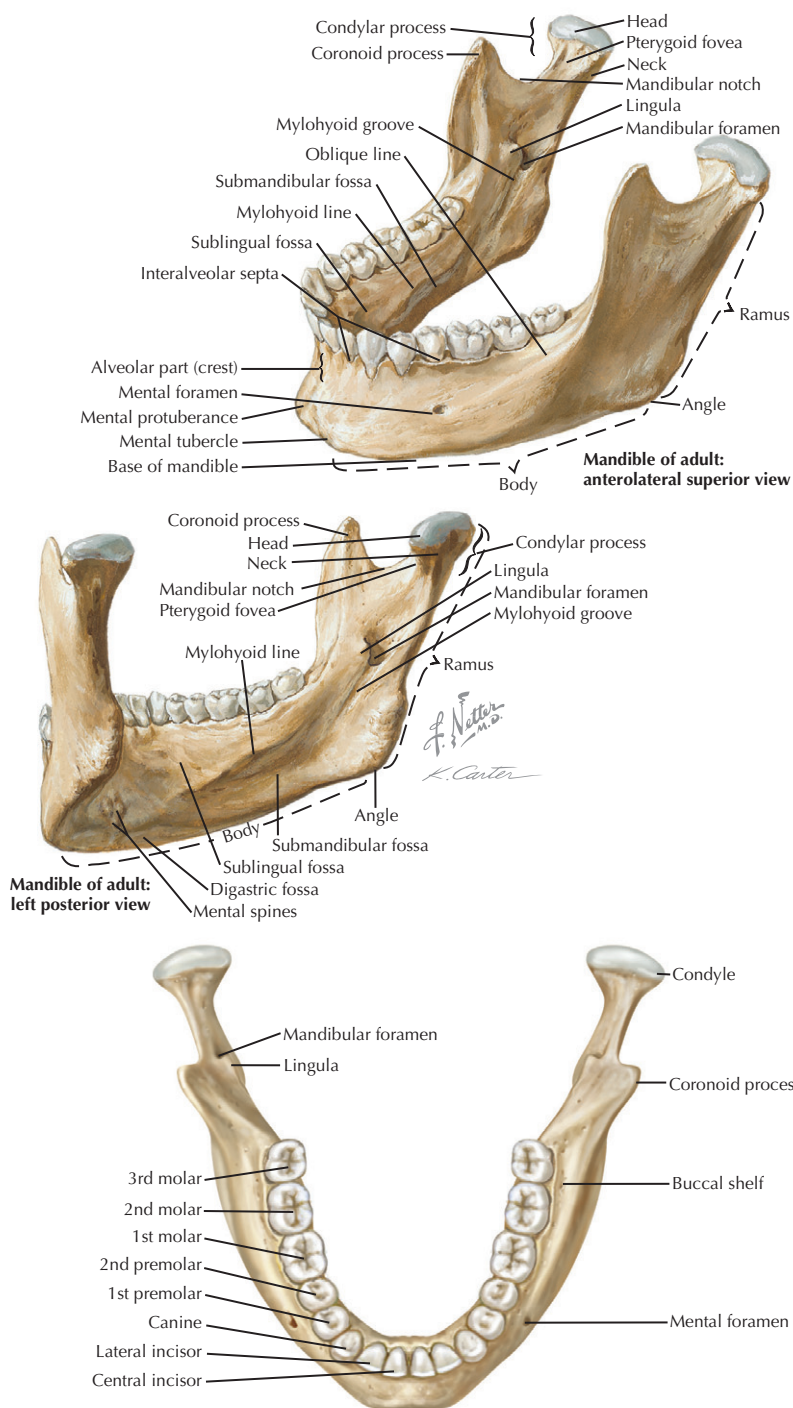
# Bones of the Skull

## MANDIBLE

Characteristics	Part	Ossification	Comments
<p>Forms the lower jaw Described as horseshoe shaped All muscles of mastication attach to the mandible There is 1 mandible</p>	Body	Intramembranous (ossifies around Meckel's cartilage)	<p>Mental foramen lies on the anterior part of the lateral surface of the body External oblique line is observed on the lateral side of the mandible On the medial side of the body lies the mylohyoid line Mylohyoid line helps divide a sublingual from a submandibular fossa Posterior border of the mylohyoid line provides for attachment of the pterygomandibular raphe At the midline on the medial side are the superior and inferior genial tubercles, as well as the digastric fossa</p>
	Ramus		<p>Meets the body of the mandible at the angle of the mandible on each side Masseter m. attaches to the lateral side Medial pterygoid m. and sphenomandibular lig. attach to the medial side Mandibular foramen is located on the medial side of the ramus Superior part divides into a coronoid process anteriorly and a condylar process posteriorly, separated by a mandibular notch</p>
	Coronoid process		<p>The anteriormost superior extension of each ramus Temporalis m. attaches to the coronoid process</p>
	Condylar process		<p>Articulates with the temporal bone in the temporomandibular joint Has a neck that forms a condyle superiorly Lateral pterygoid muscle attaches to pterygoid fovea on the neck</p>
	Alveolar process		<p>Extends superiorly from the body Created by a thick buccal and a thin lingual plate of bone The part of the mandible that supports the mandibular teeth Each side of the mandible contains 5 primary and 8 permanent teeth Alveolar bone is resorbed when a tooth is lost</p>

## 2 Bones of the Skull

### MANDIBLE CONTINUED

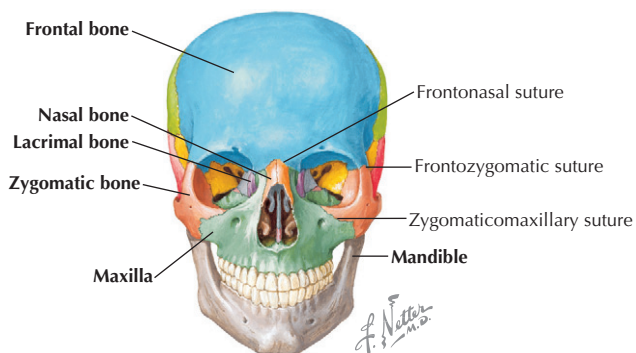




# Views and Sutures

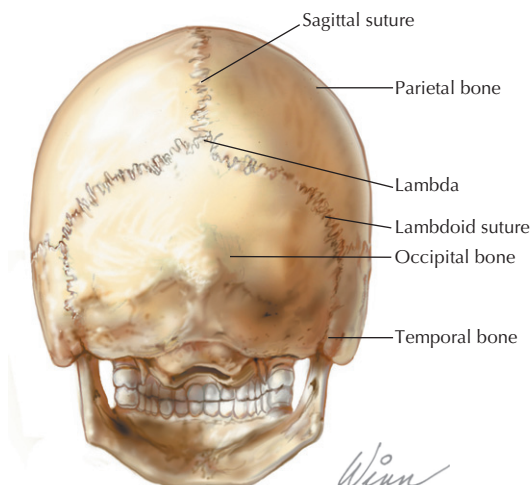
## NORMA FRONTALIS

<b>Bones</b>	Frontal Nasal Maxilla Zygomatic Mandible
<b>Sutures</b>	Frontonasal Frontozygomatic Zygomaticomaxillary Metopic



## NORMA OCCIPITALIS

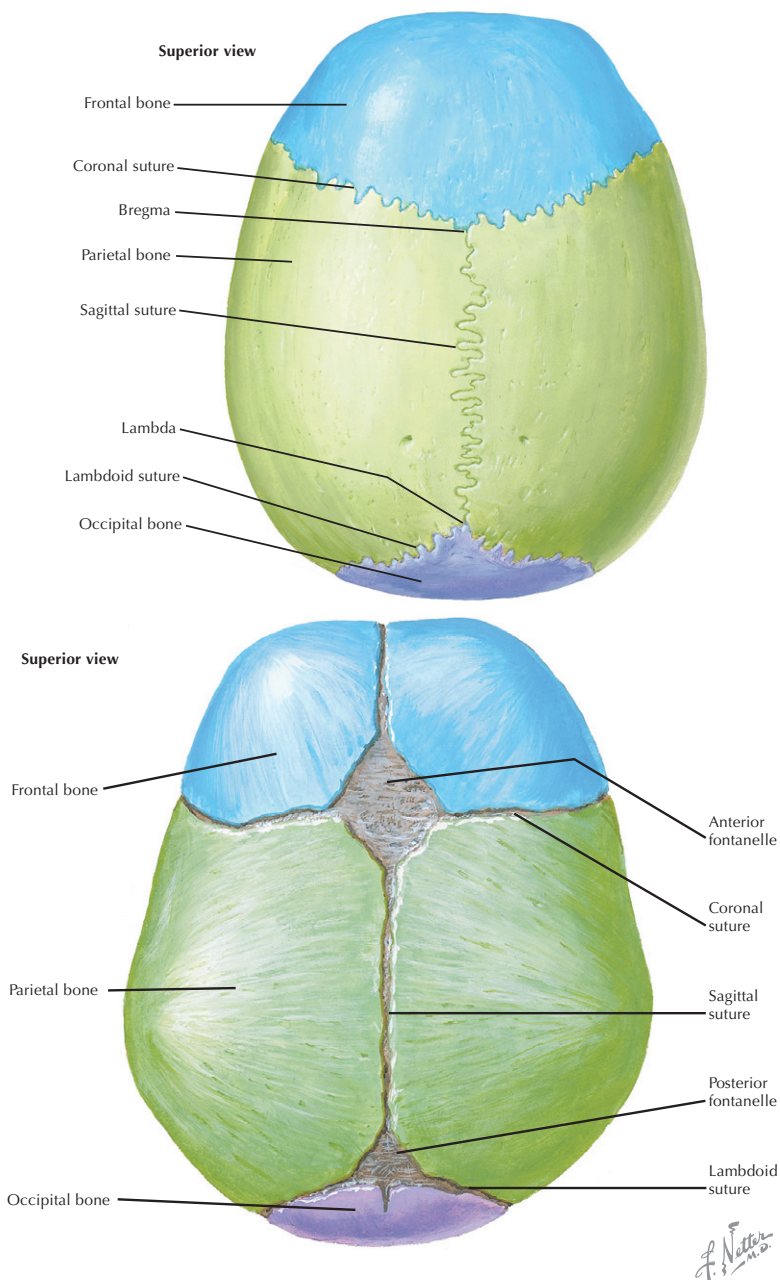
<b>Bones</b>	Parietal Occipital
<b>Sutures</b>	Sagittal Lambdoid



## 2 Views and Sutures

### NORMA VERTICALIS

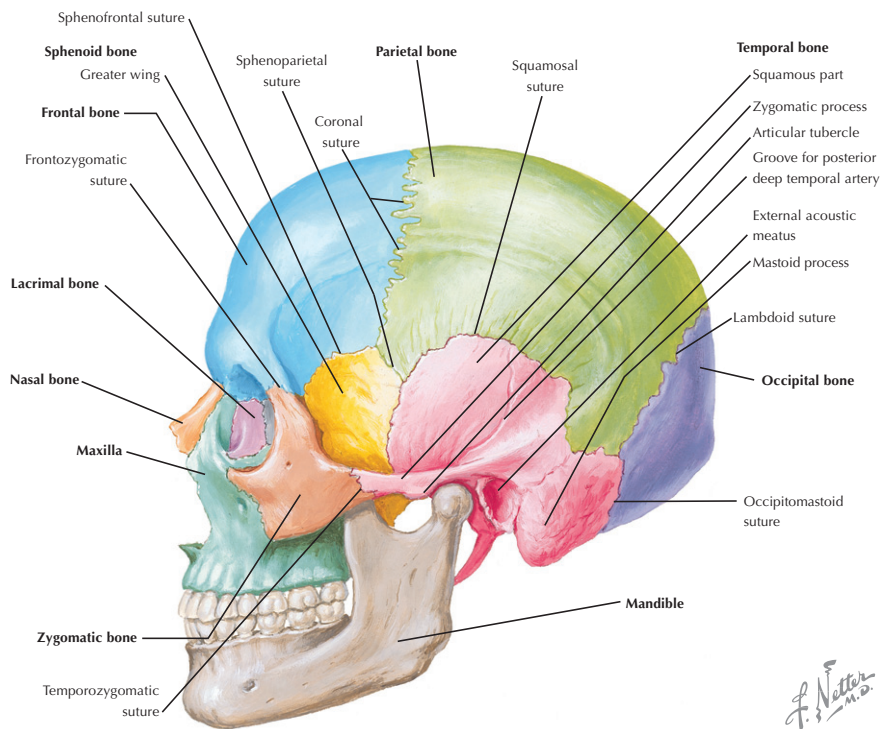
<b>Bones</b>	Frontal Parietal Occipital
<b>Sutures</b>	Coronal Sagittal Lambdoid



# Views and Sutures

## NORMA LATERALIS

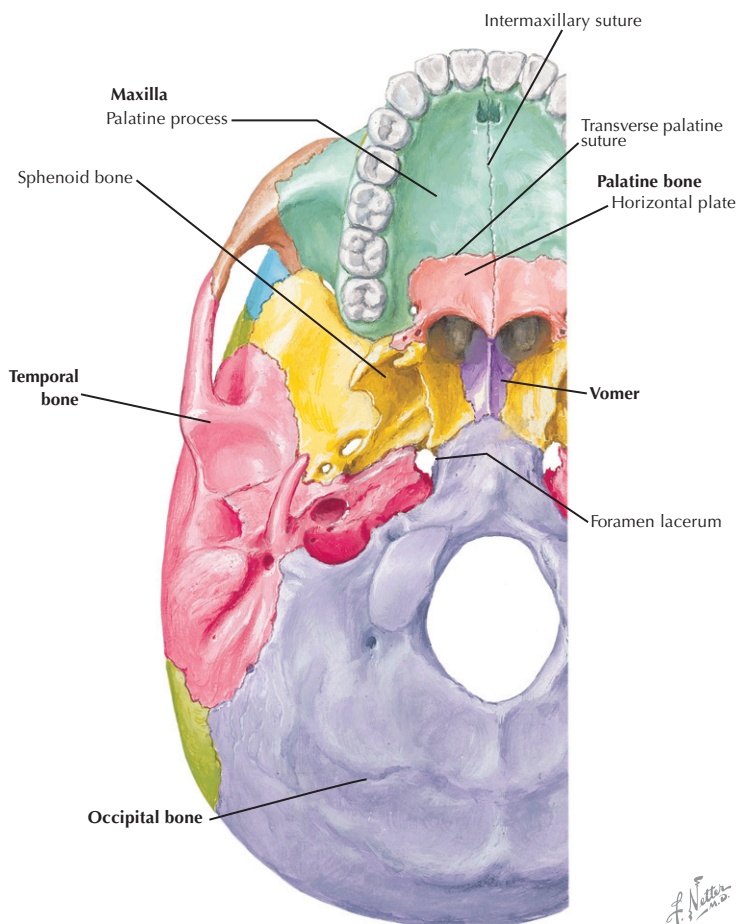
<b>Bones</b>	Frontal Parietal Lacrimal Temporal Zygomatic Maxilla Nasal Occipital Greater wing of the sphenoid Mandible
<b>Sutures</b>	Coronal Squamosal Sphenofrontal Sphenoparietal Lambdoid Occipitomastoid Temporozygomatic Frontozygomatic



## 2 Views and Sutures

### NORMA BASALIS

<b>Bones</b>	Palatine process of maxilla Occipital Temporal Horizontal plate of the palatine Greater wing of the sphenoid Vomer Medial pterygoid plate Lateral pterygoid plate
<b>Sutures</b>	Intermaxillary Transverse palatine Petro-occipital Spheno-occipital Petrosquamous Petrotympenic Squamotympanic



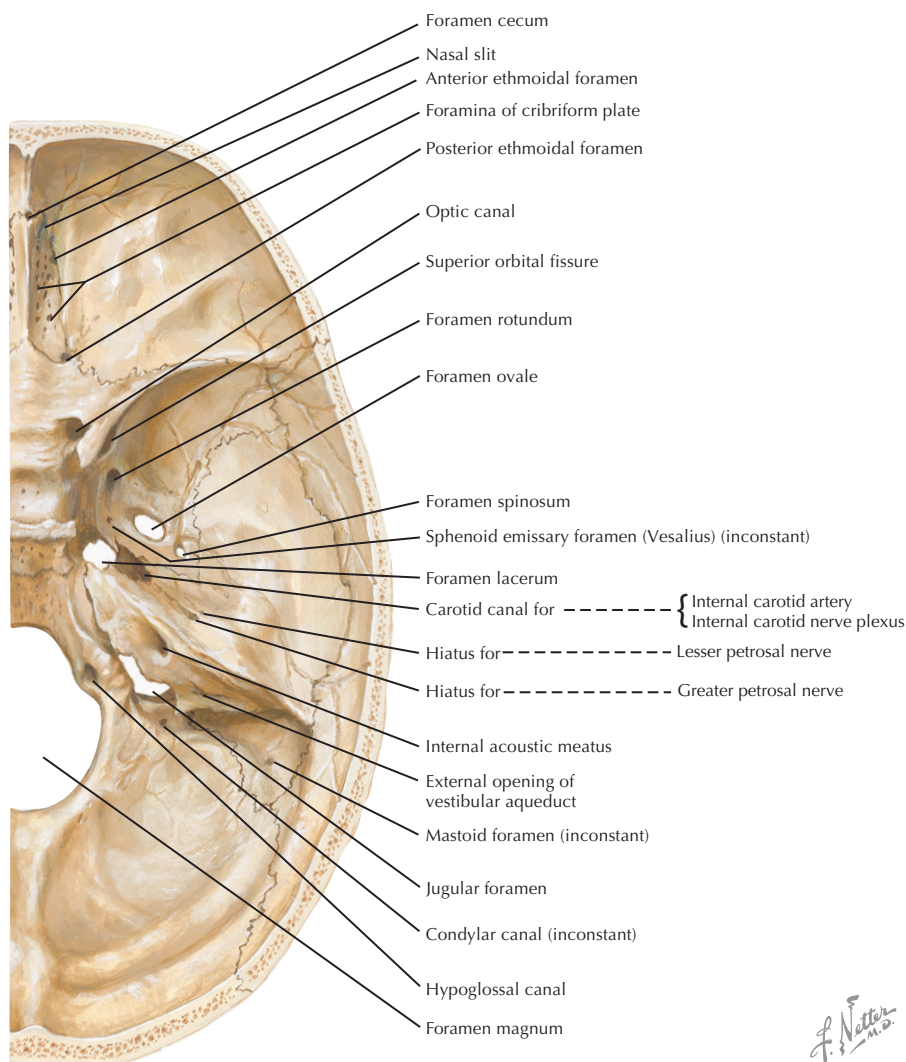
# Major Foramina and Fissures

## SUPERIOR VIEW OF THE CRANIAL BASE

Foramen/Fissure	Located in or Formed by	Structures Passing through
Cribriform plate	Ethmoid	Olfactory nn. from the olfactory bulb
Foramen cecum	Between the frontal and the ethmoid bones	Emissary v. from nasal cavity to the superior sagittal sinus
Anterior ethmoid foramen		Anterior ethmoid n. and vessels
Posterior ethmoid foramen		Posterior ethmoid n. and vessels
Optic canal	Sphenoid	Optic n., ophthalmic a.
Superior orbital fissure	Between the greater and the lesser wings of the sphenoid	Nasociliary, frontal, and lacrimal branches of the ophthalmic division of the trigeminal n., oculomotor n., trochlear n., abducens n., superior and inferior ophthalmic vv.
Foramen rotundum	Sphenoid	Maxillary division of the trigeminal n.
Foramen ovale		Mandibular division of the trigeminal n., accessory meningeal a., lesser petrosal n., emissary v.
Foramen spinosum		Middle meningeal vessels and meningeal branch of the mandibular division of the trigeminal n.
Sphenoid foramen		Emissary v.
Foramen lacerum	Articulation of the sphenoid (greater wing and body), temporal (petrous portion), and occipital (basilar portion) bones	Nothing passes through it Filled with fibrocartilage during life (although the anterior wall of the foramen has an opening for the pterygoid canal and the posterior wall has an opening for the carotid canal)
Carotid canal	Temporal (petrous portion)	Internal carotid a., internal carotid n. plexus (sympathetics)
Hiatus for the lesser petrosal n.		Lesser petrosal n.
Hiatus for the greater petrosal n.		Greater petrosal n.
Internal acoustic meatus		Facial n., vestibulocochlear n., labyrinthine a.
Opening of the vestibular aqueduct		Endolymphatic duct
Mastoid foramen	Temporal (mastoid portion)	Emissary v. (sometimes branches of the occipital a.)
Jugular foramen	Temporal (petrous portion) and occipital	Glossopharyngeal n., vagus n., spinal accessory n., inferior petrosal sinus, sigmoid sinus, posterior meningeal a.
Condylar canal	Occipital	Emissary v., meningeal branches of ascending pharyngeal a.
Hypoglossal canal		Hypoglossal n.
Foramen magnum		Medulla oblongata, vertebral arteries, spinal roots of the spinal accessory n.

## 2 Major Foramina and Fissures

### SUPERIOR VIEW OF THE CRANIAL BASE *CONTINUED*



*F. Netter M.D.*

# Major Foramina and Fissures

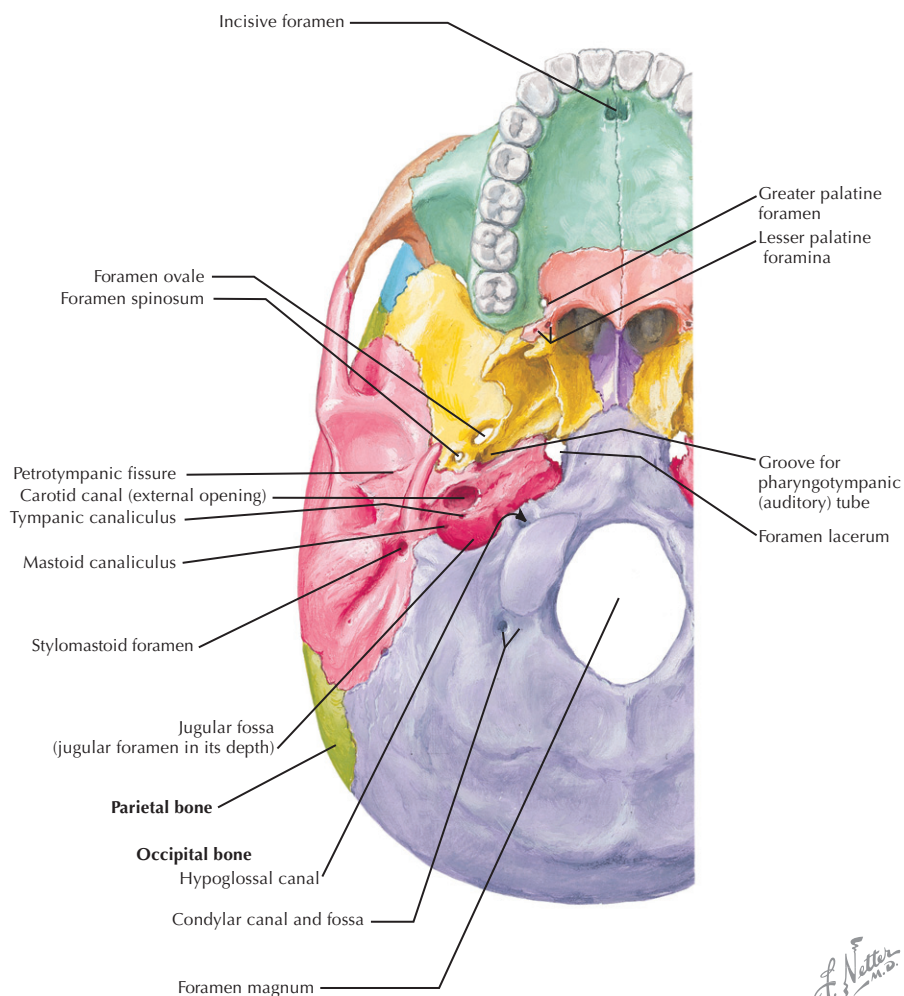
## INFERIOR VIEW OF THE CRANIAL BASE

Foramen/Fissure	Located in or Formed by	Structures Passing through
Incisive foramen	Maxilla (palatine process)	Nasopalatine n., sphenopalatine a.
Greater palatine foramen	Palatine	Greater palatine n. and vessels
Lesser palatine foramina	Palatine	Lesser palatine n. and vessels
Foramen ovale	Sphenoid	Mandibular division of the trigeminal n., accessory meningeal a., lesser petrosal n., emissary v.
Foramen spinosum	Sphenoid	Middle meningeal vessels and meningeal branch of the mandibular division of the trigeminal n.
Foramen lacerum	Articulation of the sphenoid (greater wing and body), temporal (petrous portion), and occipital (basilar portion) bones	Nothing passes through it Filled with fibrocartilage during life (although the anterior wall of the foramen has an opening for the pterygoid canal and the posterior wall has an opening for the carotid canal)
Opening for auditory tube	Temporal and sphenoid	Cartilaginous portion of the auditory tube
Carotid canal	Temporal (petrous portion)	Internal carotid a., internal carotid n. plexus (sympathetics)
Tympanic canaliculus	Temporal	Tympanic branch of the glossopharyngeal n.
Jugular foramen	Temporal (petrous portion) and occipital	Glossopharyngeal n., vagus n., spinal accessory n., inferior petrosal sinus, sigmoid sinus, posterior meningeal a.
Mastoid canaliculus	Temporal (within the jugular fossa)	Auricular branch of the vagus n.
Petrotympenic fissure	Temporal	Chorda tympani n., anterior tympanic a.
Stylomastoid foramen		Facial n., stylomastoid a.
Tympanomastoid fissure		Auricular branch of the vagus n.
Hypoglossal canal	Occipital	Hypoglossal n.
Condylar canal		Emissary v., meningeal branches of ascending pharyngeal a.
Foramen magnum		Medulla oblongata, vertebral arteries, spinal roots of the spinal accessory n.



## 2 Major Foramina and Fissures

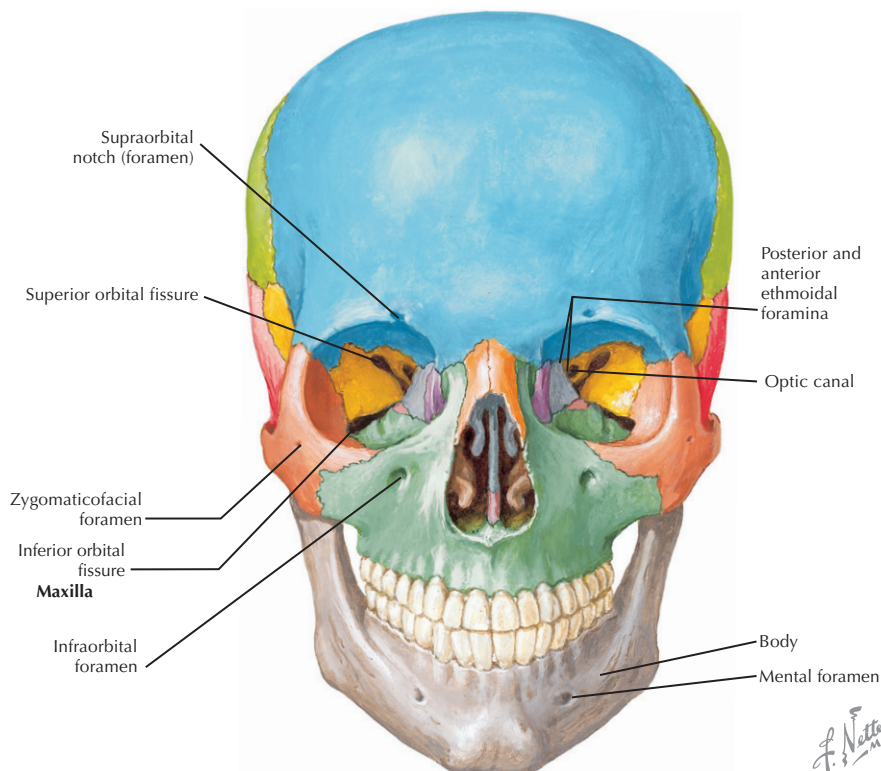
### INFERIOR VIEW OF THE CRANIAL BASE *CONTINUED*



# Major Foramina and Fissures

## ANTERIOR VIEW

Foramen/Fissure	Located in or Formed by	Structures Passing through
Supraorbital foramen	Frontal	Supraorbital n. and vessels
Optic canal	Sphenoid	Optic n., ophthalmic a.
Superior orbital fissure	Between the: <ul style="list-style-type: none"> <li>• Greater wing of the sphenoid and</li> <li>• Lesser wing of the sphenoid</li> </ul>	Nasociliary, frontal, and lacrimal branches of the ophthalmic division of the trigeminal n., oculomotor n., trochlear n., abducens n., superior and inferior ophthalmic vv.
Inferior orbital fissure	Between the: <ul style="list-style-type: none"> <li>• Greater wing of the sphenoid and</li> <li>• Maxilla and orbital portion of the palatine bones</li> </ul>	Maxillary division of the trigeminal n., zygomatic n., infraorbital vessels
Anterior ethmoid foramen	Between the: <ul style="list-style-type: none"> <li>• Frontal and</li> <li>• Ethmoid</li> </ul>	Anterior ethmoid n. and vessels
Posterior ethmoid foramen		Posterior ethmoid n. and vessels
Zygomaticofacial foramen	Zygomatic	Zygomaticofacial n. and vessels
Infraorbital foramen	Maxilla	Infraorbital n. and vessels
Mental foramen	Mandible	Mental n. and vessels



## 2 Cervical Vertebrae

### GENERAL INFORMATION

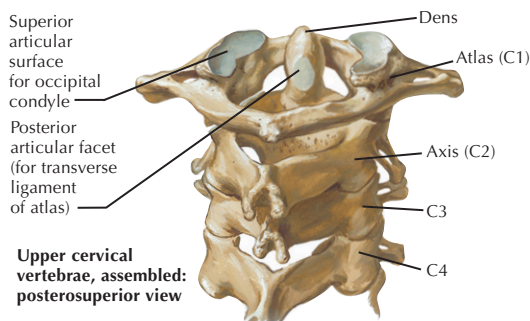
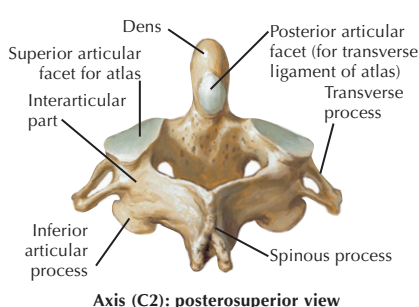
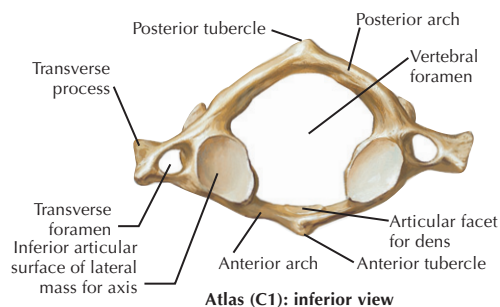
7 cervical vertebrae (C1 to C7)

The smallest vertebrae in the body

The 1st, 2nd, and 7th cervical vertebrae are unique in their shape; the 3rd to the 6th are similarly shaped

### BONES

Vertebra	Characteristics
Atlas (C1)	Supports the skull No body No spinous process Has an anterior arch and a posterior arch Large lateral masses support the occipital condyles of the skull superiorly and articulate with the axis inferiorly Foramen transversarium located in the large transverse process
Axis (C2)	Dens (odontoid process) located on the body's superior surface Foramen transversarium located in the small transverse process Spinous process is large and bifid
C3–C6	Cervical vertebrae have small bodies Pedicles project posteriorly and laterally Spinous processes are short and bifid Vertebral foramina are large and triangular Each foramen transversarium is located in the transverse process Vertebral a. enters the foramen transversarium at C6 Transverse processes each have an anterior and a posterior portion called the anterior tubercle and the posterior tubercle
C7	Also called "vertebra prominens" because its long spinous process makes it visible under the skin Long spinous process is not bifid Foramen transversarium located in the large transverse process Normally, the vertebral vessels do not pass through the foramen transversarium of C7 (the veins pass through more frequently than the arteries)

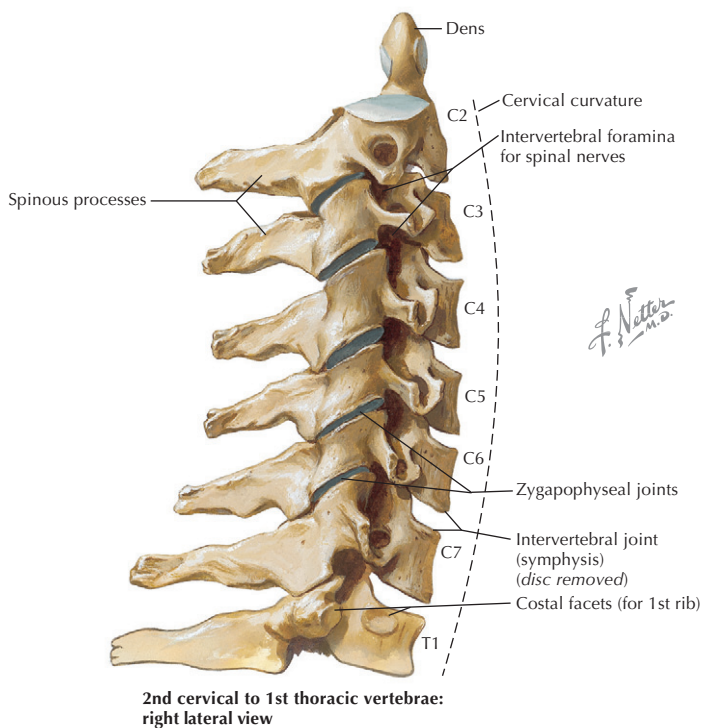
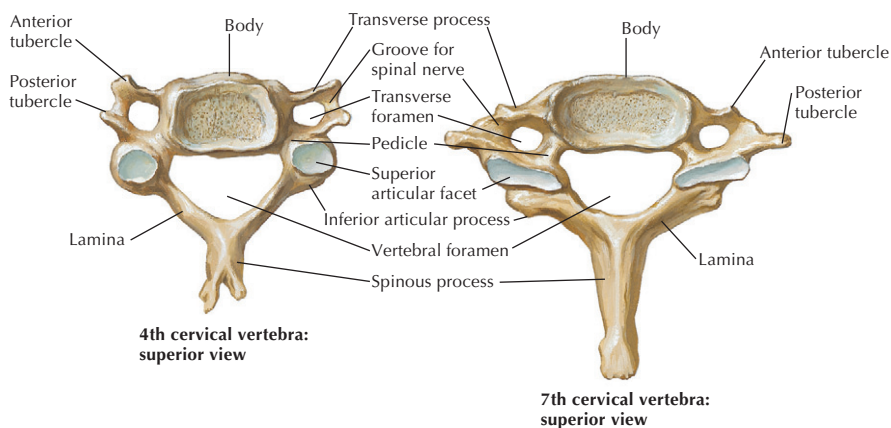


*F. Netter M.D.*

# Cervical Vertebrae

## GENERAL INFORMATION *CONTINUED*

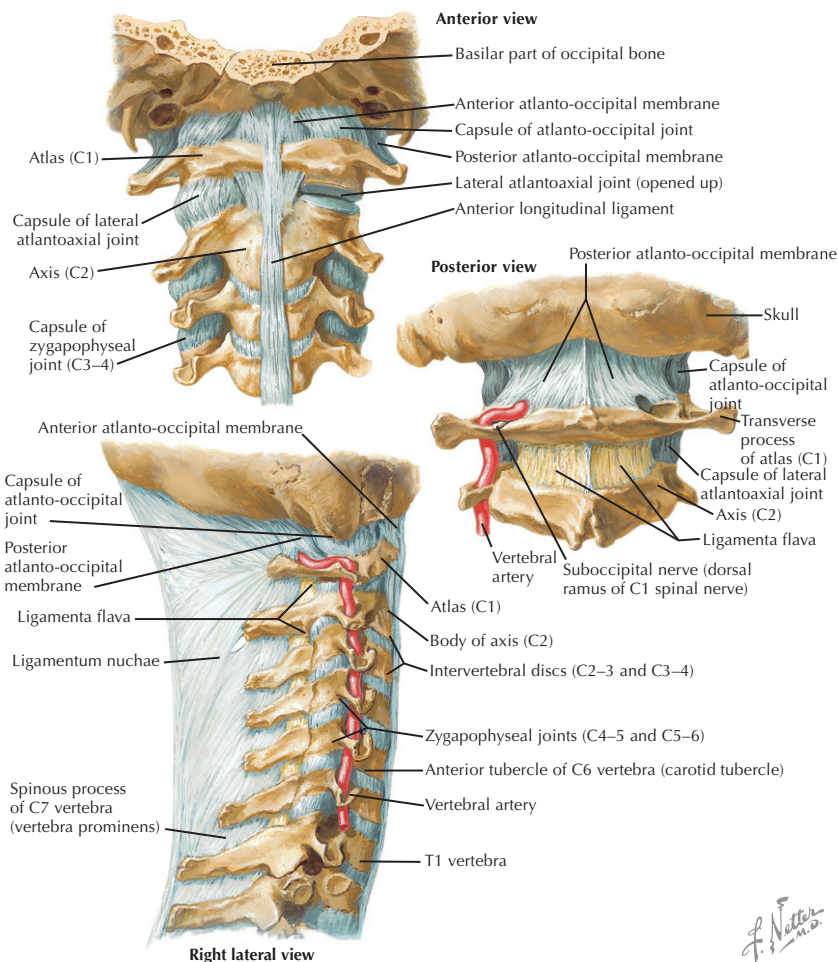
2



## 2 Cervical Vertebrae

### MAJOR EXTERNAL LIGAMENTS

Ligament(s)/Membrane(s)	Comments
Anterior longitudinal ligament	Attached to the anterior surfaces of the vertebral bodies, extending from the axis to the sacrum Superior to the axis, it is continuous with the anterior atlantoaxial lig.
Ligamenta flava	Attached to the anterior surfaces of the lamina within the vertebral foramen extending from the axis to the first sacral vertebra
Ligamentum nuchae	Extends from the external occipital protuberance and median nuchal line to the spinous process of C7 Between these attachments, it attaches to the posterior tubercle of the atlas and the spinous processes of the axis and C3–C6
Anterior atlanto-occipital membrane	Extends from the anterior margin of the foramen magnum superiorly and the anterior arch of the atlas inferiorly Continuous with the capsule of the atlanto-occipital joint laterally
Posterior atlanto-occipital membrane	Extends from the posterior margin of the foramen magnum superiorly to the posterior arch of the atlas inferiorly Allows passage of the vertebral a. on the lateral margin



*F. Netter M.D.*

# Cervical Vertebrae

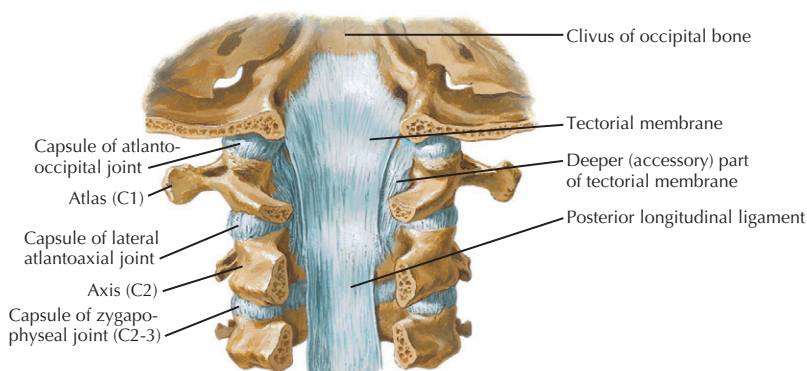
## MAJOR INTERNAL LIGAMENTS

Ligament(s)/Membrane(s)	Comments
<b>Deep Ligaments/Membranes</b>	
Alar ligament	Extends from the dens to the medial portions of the occipital condyles Also known as “check ligaments” because they limit skull rotation
Apical ligament of the dens	Extends from the dens to the anterior margin of the foramen magnum
Cruciate ligament <i>Superior longitudinal band</i>	Part of the transverse lig. of the atlas, which extends superiorly to attach to the basilar portion of the occipital bone
<i>Transverse ligament of atlas</i>	Thick ligament extending from one side of the internal surface of the anterior arch of the atlas to the other side, holding the dens in contact with the anterior arch
<i>Inferior longitudinal band</i>	Part of the transverse lig. of the atlas that extends inferiorly, attaching to the posterior body of the axis
<b>Superficial Ligaments/Membranes</b>	
Tectorial membrane	Extends from the basilar portion of the occipital bone, where it blends with the dura mater, to the posterior portion of the body of the axis Continuous inferiorly with the posterior longitudinal lig.
Posterior longitudinal ligament	Attached to the posterior surfaces of the bodies of the vertebrae extending within the vertebral foramen from the axis to the sacrum Superior to the axis, it is continuous with the tectorial membrane

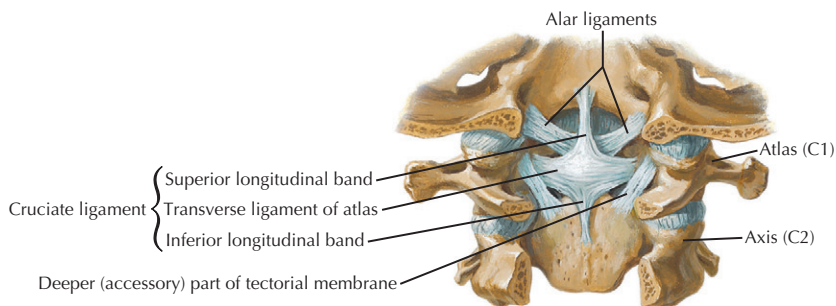


## 2 Cervical Vertebrae

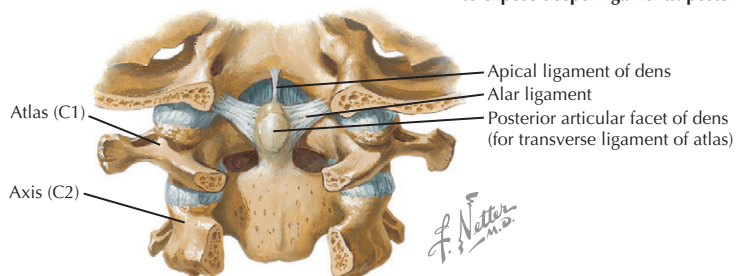
### MAJOR INTERNAL LIGAMENTS *CONTINUED*



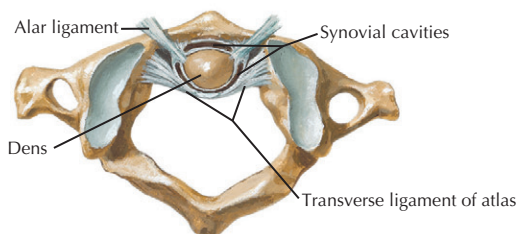
**Upper part of vertebral canal with spinous processes and parts of vertebral arches removed to expose ligaments of posterior vertebral bodies: posterior view**



**Principal part of tectorial membrane removed to expose deeper ligaments: posterior view**



**Cruciate ligament removed to show deepest ligaments: posterior view**



**Median atlantoaxial joint: superior view**



# Clinical Correlate

## ZYGOMATIC FRACTURES

Zygoma is the second most commonly fractured bone of the face after the nasal bone. Susceptible to fracture, usually due to a facial blow from a fist or trauma related to a car accident.

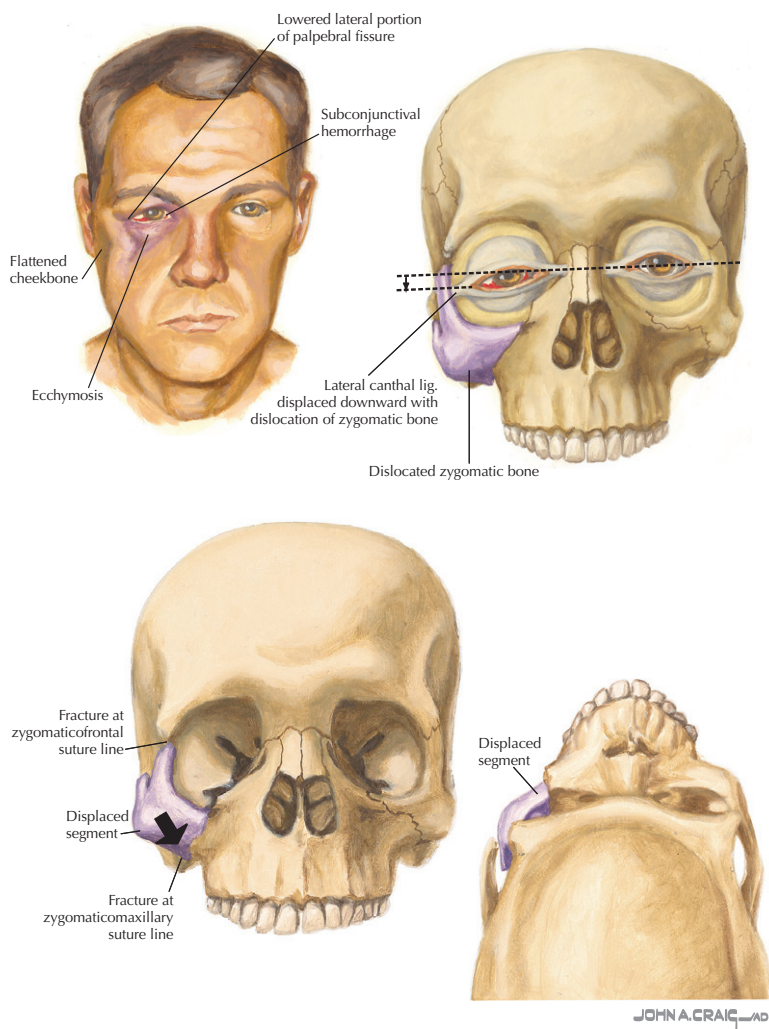
In fractures due to blows from a fist, the left zygomatic bone is more frequently fractured than the right.

Most fractures are unilateral.

May displace the zygomatic bone along the sutures, or more severe displacement in a posterior, medial, and inferior direction may occur.

Common clinical manifestations include:

- Pain
- Swelling
- Diplopia
- Paresthesia
- Depressed cheek



JOHN A. CRAIG, MD

## 2 Clinical Correlate

### LE FORT FRACTURES

Trauma to the midface usually follows 1 of 3 patterns of fracture:

- Le Fort I
- Le Fort II
- Le Fort III

#### LE FORT I

Horizontal, extending from the lateral margin of the piriform aperture to the pterygoid plates just superior to the apices of the teeth

Gives rise to a detached upper jaw relative to the rest of the maxillofacial skeleton

#### LE FORT II

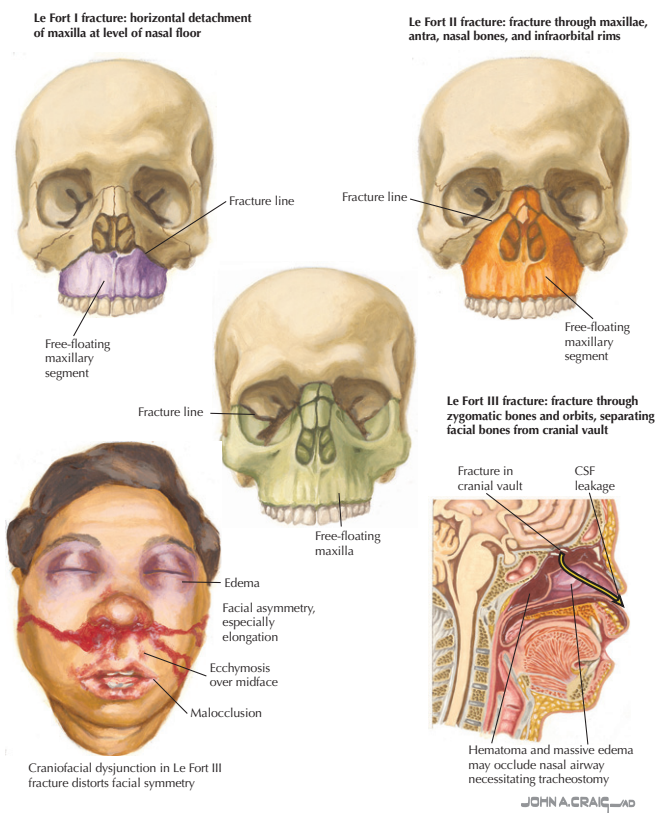
Pyramidal in outline, extending from the bridge of the nose at or inferior to the nasofrontal suture or maxilla, then inferiorly and laterally through the inferior orbital floor near the infraorbital foramen, through the anterior wall of the maxillary sinus, to the pterygoid plates

#### LE FORT III

Transverse, extending from the nasofrontal suture and frontomaxillary suture and passing posteriorly along the medial wall of the orbit through the nasolacrimal groove and ethmoid, then following the inferior orbital fissure to the lateral wall of the orbit, and extending through the frontozygomatic suture

Within the nose, the fracture extends along the perpendicular plate, vomer, and pterygoid plates

In a Le Fort III fracture, the facial skeleton is detached from the base of the skull



# Clinical Correlate

## MANDIBLE FRACTURES

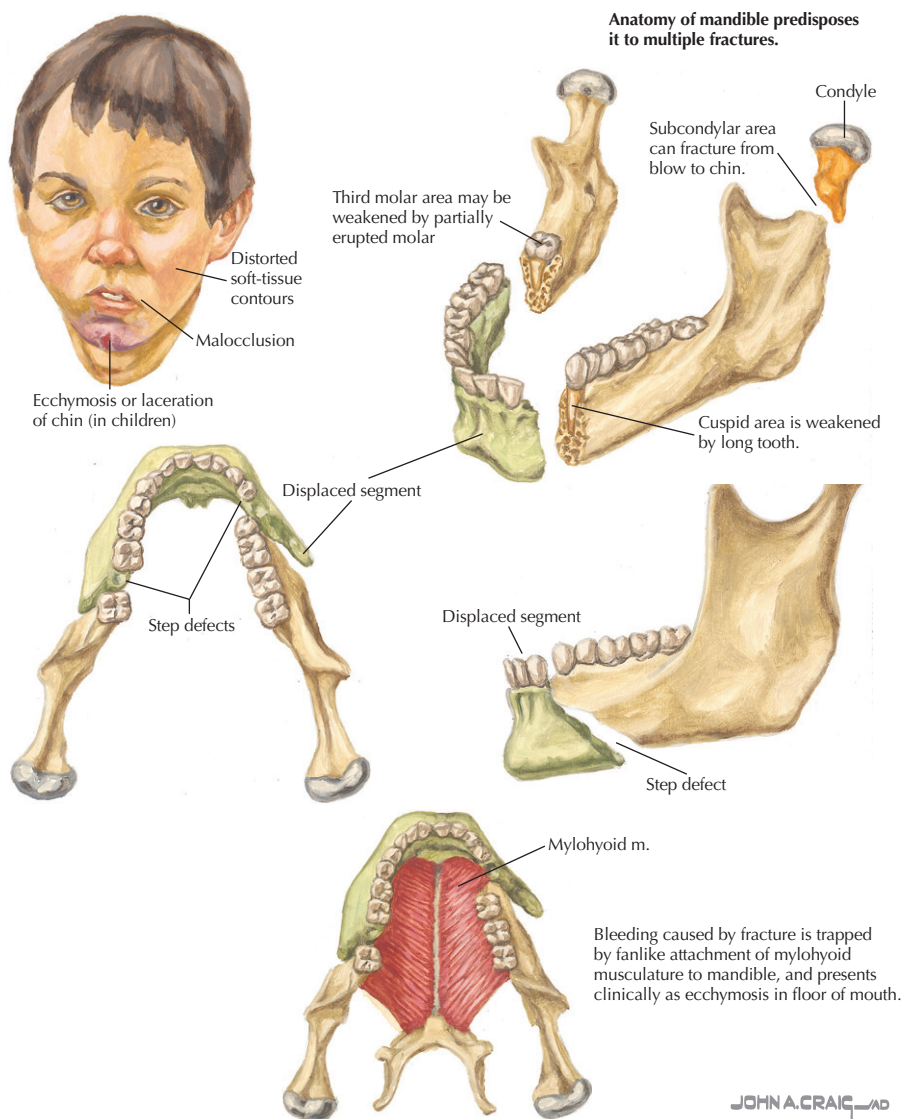
Mandible is a frequently fractured bone

Fractures result from blow from a fist or trauma incurred in motor vehicle accidents

Common sites (in decreasing order of frequency):

- Body
- Angle
- Condyle
- Symphysis
- Ramus
- Alveolus
- Coronoid process

With double mandibular fractures, the second usually is contralateral



JOHN A. CRAIG, MD

## 2 Clinical Correlate

### CERVICAL FRACTURES

Two common types of cervical fractures:

- Jefferson fracture (at C1)
- Hangman's fracture (at C2)

#### JEFFERSON FRACTURE

Involves the atlas

Results from skull compression due to axial loading, causing the atlas to burst

Most patients are neurologically intact but have severe neck pain

Vertebral artery can be compromised

Classified as stable or unstable according to whether the transverse ligament of the atlas is intact:

- *Stable fractures* can be treated with an orthosis such as a soft collar
- *Unstable fractures* are more problematic; may require cranial traction applied with use of a halo, as well as cervical fusion

#### HANGMAN'S FRACTURE

Occurs through the vertebral arch of the axis between the superior and the inferior articulating facets

A traumatic spondylolisthesis often is caused by extension of the neck with axial compression, common in car accidents

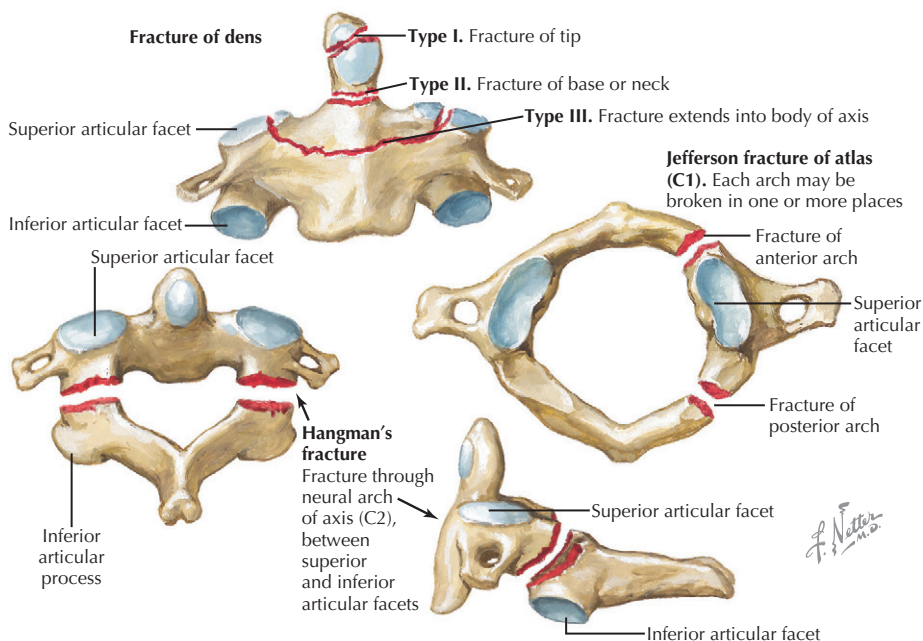
The historical hangman's fracture is caused by extension and distraction of the neck

#### ODONTOID FRACTURE

Involves the axis

Classification into 3 types:

- Type 1—fracture at the tip of the odontoid process
- Type 2—fracture along the base or the neck of the odontoid
- Type 3—fracture that passes through the body of the axis



# CHAPTER 3

## BASIC NEUROANATOMY AND CRANIAL NERVES

Nervous Tissue	66
Central Nervous System	68
Peripheral Nervous System	72
Cranial Nerves	74
Clinical Correlates	103

## 3 Nervous Tissue

### GENERAL INFORMATION

Nervous tissue is divided into 2 major cell types:

- Neurons
- Neuroglial cells (the neuroglia)

### NEURONS

The structural and functional cells in the nervous system

Respond to a nervous stimulus and conduct the stimulus along the length of the cell

A neuron's cell body is called the perikaryon, or soma

Cell bodies are classified by their location:

- Ganglion—a collection of nerve cell bodies located in the peripheral nervous system (e.g., dorsal root ganglion, trigeminal ganglion, ciliary ganglion)
- Nucleus—a collection of nerve cell bodies located in the central nervous system (e.g., Edinger-Westphal nucleus, chief sensory nucleus of cranial nerve V, motor nucleus of cranial nerve VII)

Neuron's cell bodies contain typical cellular organelles within their cytoplasm:

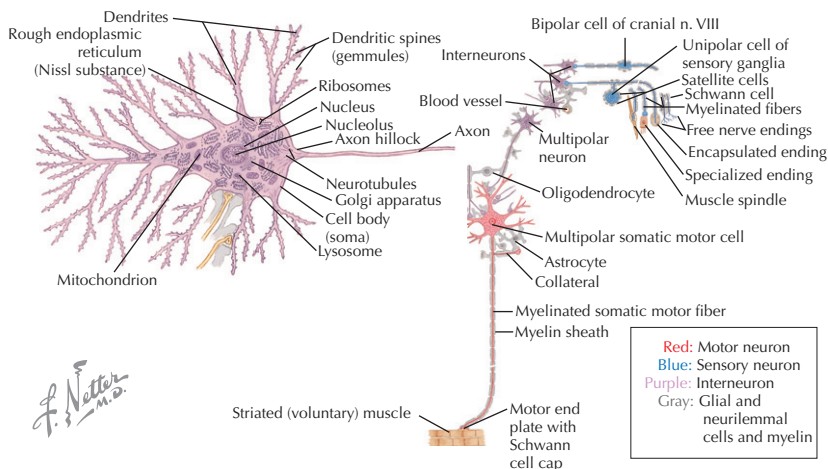
- Mitochondria
- Nucleus
- Nucleolus
- Ribosomes
- Rough endoplasmic reticulum (Nissl substance)
- Neurotubules
- Golgi apparatus
- Lysosomes

Neurons have 2 types of processes that extend from the nerve cell body:

- Dendrite—process that carries nerve impulses toward the nerve cell body; neurons may have multiple dendrites
- Axon—process that carries nerve impulses away from the nerve cell body; neurons can have *only 1* axon

3 major types of neurons:

- Unipolar—has only 1 process from the cell body (sensory neurons)
- Bipolar—has 2 processes from the cell body: 1 dendrite and 1 axon (sensory neurons; located only in the retina, olfactory epithelium, and the vestibular and cochlear ganglia)
- Multipolar—has 3 or more processes from the cell body: 2 or more dendrites and 1 axon (motor neurons and interneurons)





# Nervous Tissue

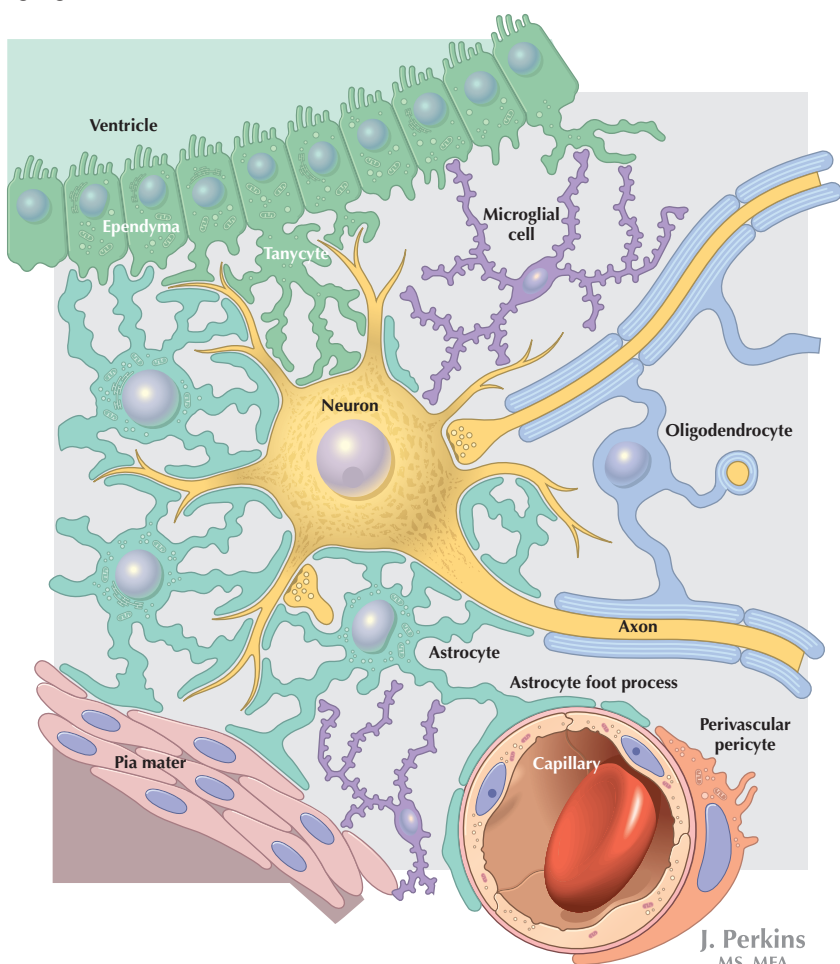
## NEUROGLIA

Neuroglia is the supporting nervous tissue for neurons, although neuroglial cells also have assistive roles in neuron function

Neuroglial cells have only 1 type of process

Classification:

- **Astrocytes**—located in the central nervous system; help keep neurons in place, provide nutritional support, regulate the extracellular matrix, form part of the blood-brain barrier
- **Oligodendrocytes**—located in the central nervous system; responsible for axon myelination in the central nervous system; 1 oligodendrocyte can myelinate 1 segment of multiple axons
- **Microglia**—located in the central nervous system; responsible for phagocytosis to remove waste
- **Schwann cells**—located in the peripheral nervous system; responsible for axon myelination in the peripheral nervous system; 1 schwann cell can myelinate 1 segment of 1 axon
- **Satellite cells**—located in the peripheral nervous system; surround the nerve cell bodies of ganglia



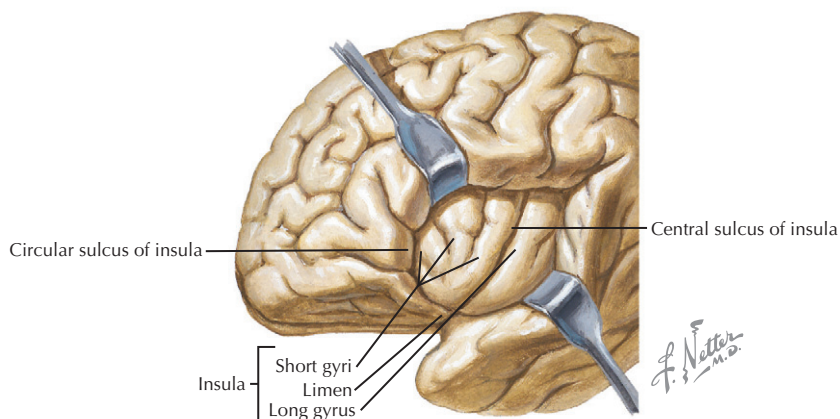
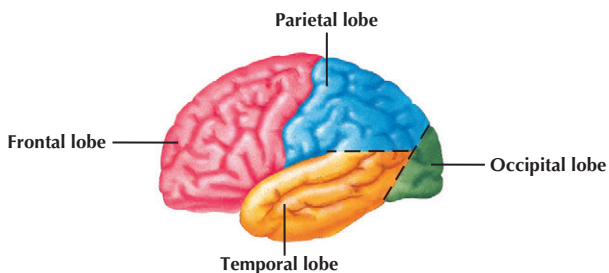
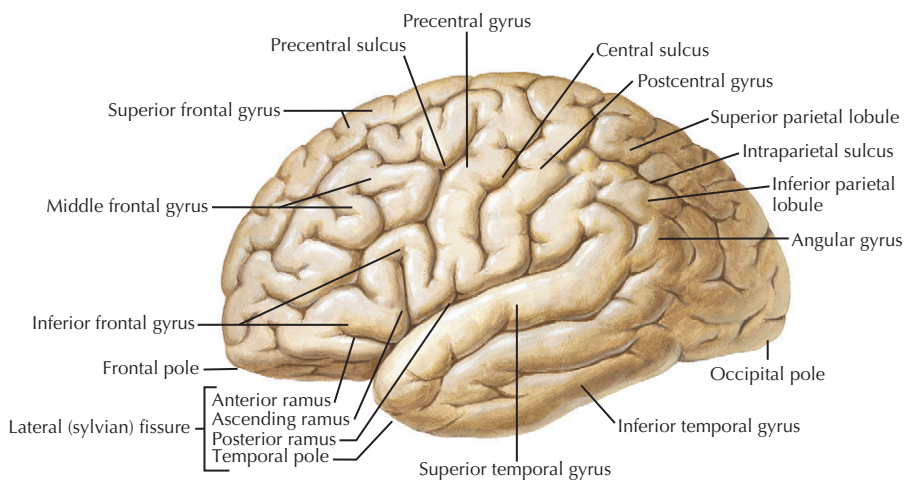


### 3 Central Nervous System

#### GENERAL INFORMATION

The *central nervous system* is composed of the:

- Brain
- Spinal cord



# Central Nervous System

## BRAIN

### CEREBRUM

The surface of the cerebral cortex of the brain is divided by:

- Gyri (singular gyrus)—the elevations of brain tissue on the surface
- Sulci (singular sulcus)—the grooves or fissures located between the gyri

There are 3 large sulci that help divide the cerebral hemispheres into 4 of its lobes:

- Central sulcus (of Rolando)—divides frontal lobe from parietal lobe
- Lateral sulcus (of Sylvius)—divides the frontal and parietal lobes from the temporal lobe
- Parieto-occipital sulcus—divides the parietal lobe from the occipital lobe

The brain is divided into 5 lobes:

- Frontal—motor movement, motor aspect of speech (Broca's area), reasoning, emotions, personality, and problem solving
- Parietal—sensory perceptions related to pain, temperature, touch and pressure, spatial orientation and perception, sensory aspect of language (Wernicke's area)
- Temporal—auditory perceptions, learning, and memory
- Occipital—vision
- Insula—associated with visceral functions including taste

### DIENCEPHALON

Composed of 4 parts:

- Thalamus—major relay center of the somatosensory system and parts of the motor system
- Hypothalamus—controls the autonomic nervous system and endocrine system
- Epithalamus—major structures include the pineal gland (which controls circadian rhythms) and the habenula
- Subthalamus—an extrapyramidal nucleus of the motor system; if lesioned, will result in a contralateral hemiballismus

### BRAINSTEM

Composed of 3 parts:

- Midbrain
- Pons
- Medulla

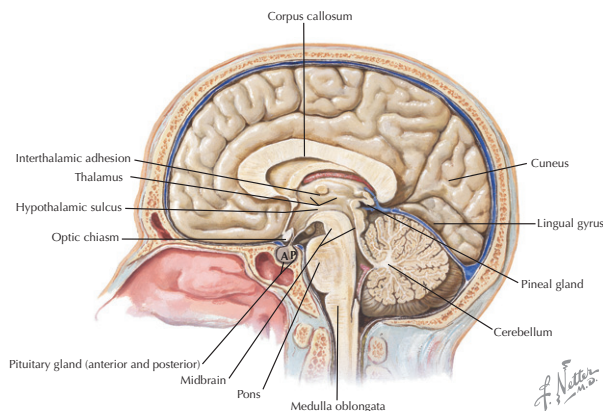
### CEREBELLUM

Part of the motor system

Receives sensory input of all forms that use the deep cerebellar nuclei

Associated with:

- Equilibrium
- Posture
- Tone of axial muscles
- Gait



## 3 Central Nervous System

### SPINAL CORD

The caudal continuation of the central nervous system

Begins at the caudal end of the medulla and ends at vertebral level L1–2, tapering into the conus medullaris

Has 2 enlargements associated with the limbs:

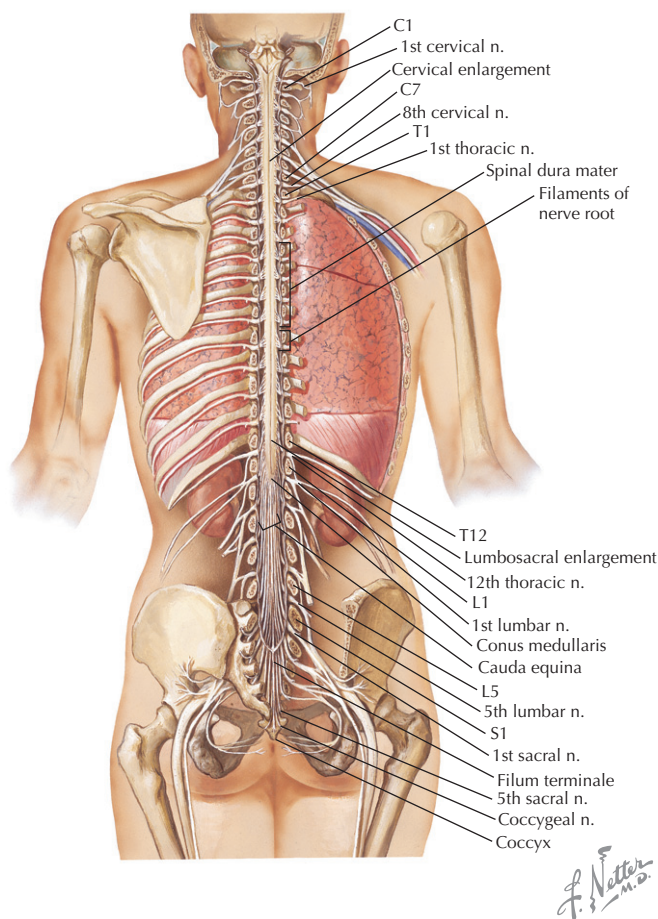
- Cervical—associated with the upper limb and found between the spinal cord at levels C4 to T1
- Lumbosacral—associated with the lower limb and found between the spinal cord at levels L1 to S2

Composed of:

- Gray matter—location of nerve cell bodies and neuroglial cells
- White matter—location of the axons and neuroglial cells

Has 5 levels:

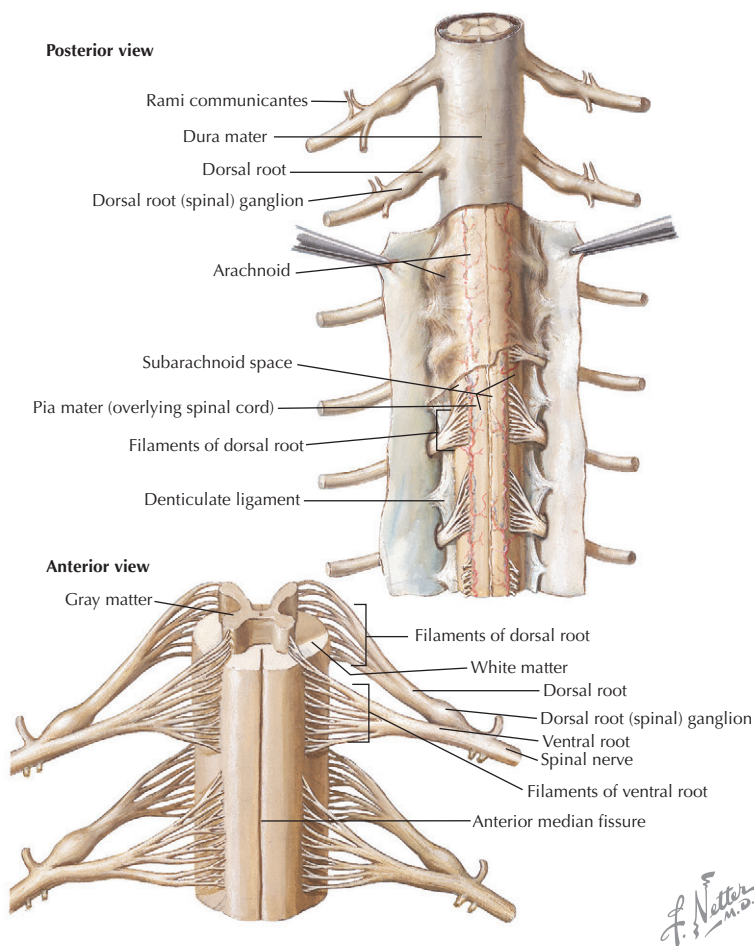
- Cervical—8 spinal nerves
- Thoracic—12 spinal nerves
- Lumbar—5 spinal nerves
- Sacral—5 spinal nerves
- Coccygeal—1 spinal nerve



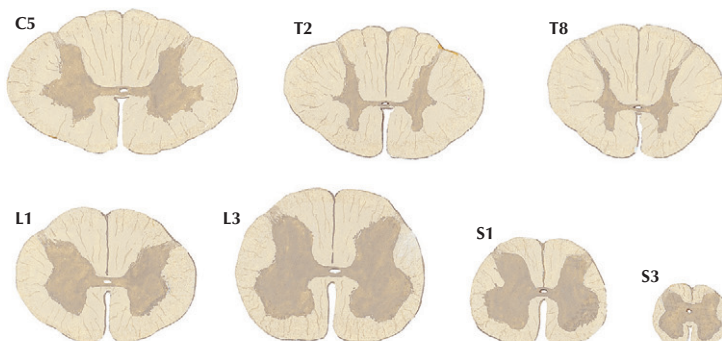
# Central Nervous System

## SPINAL CORD CONTINUED

3



Sections through spinal cord at various levels



## 3 Peripheral Nervous System

### GENERAL INFORMATION

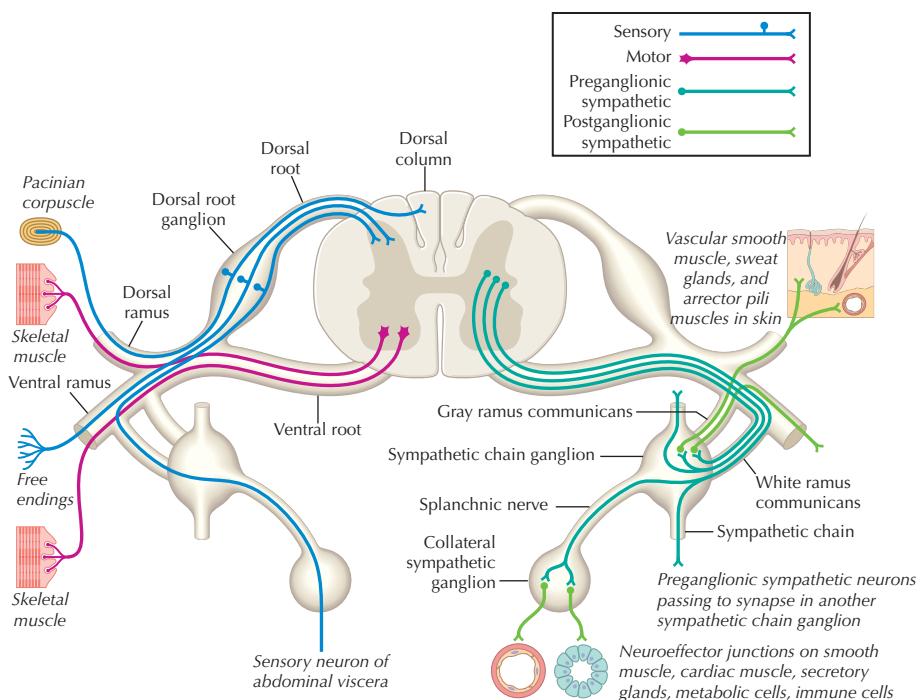
*Peripheral nervous system* is that portion of the nervous system located external to the central nervous system

Consists of:

- Cranial nerves—12 pairs
- Spinal nerves—31 pairs

Can be subdivided into:

- Somatic nervous system—voluntary system associated with afferent (sensory) and efferent (motor) fibers
- Autonomic nervous system—involuntary system associated with homeostasis of the body



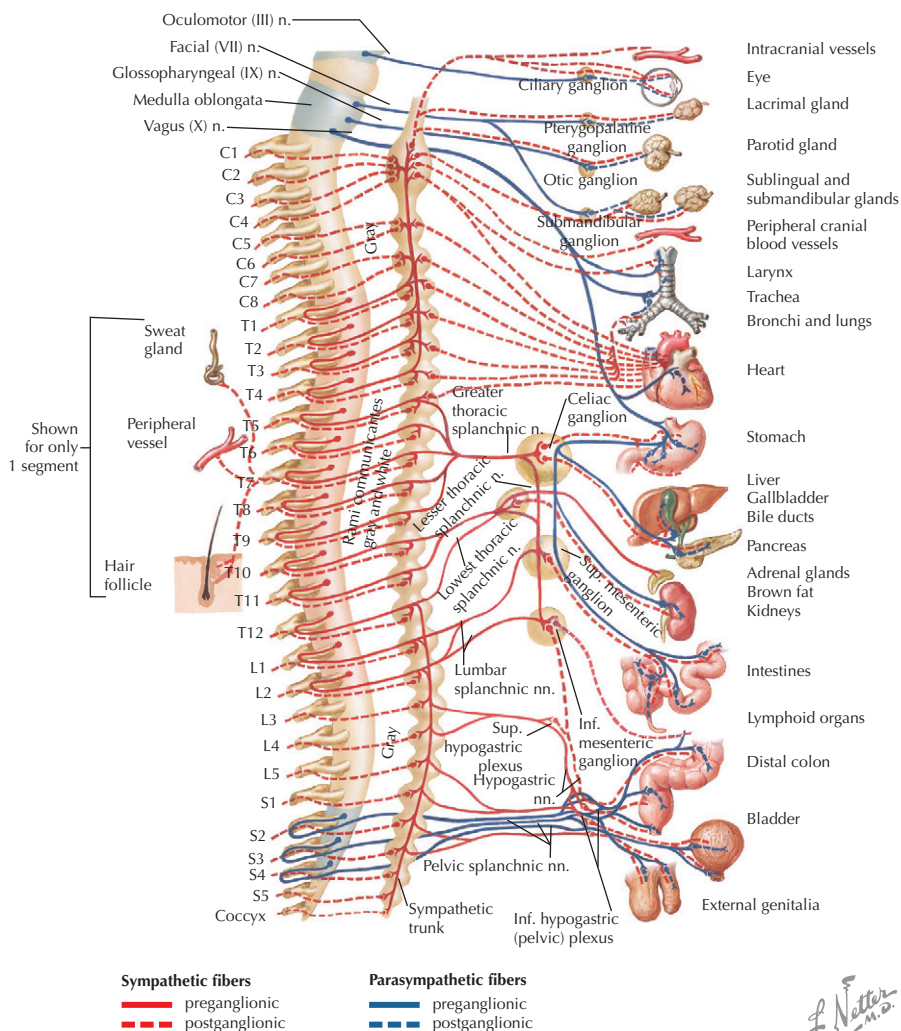
J. Perkins  
MS, MFA



# Peripheral Nervous System

## SPINAL NERVES AND CRANIAL NERVES

3



## 3 Cranial Nerves

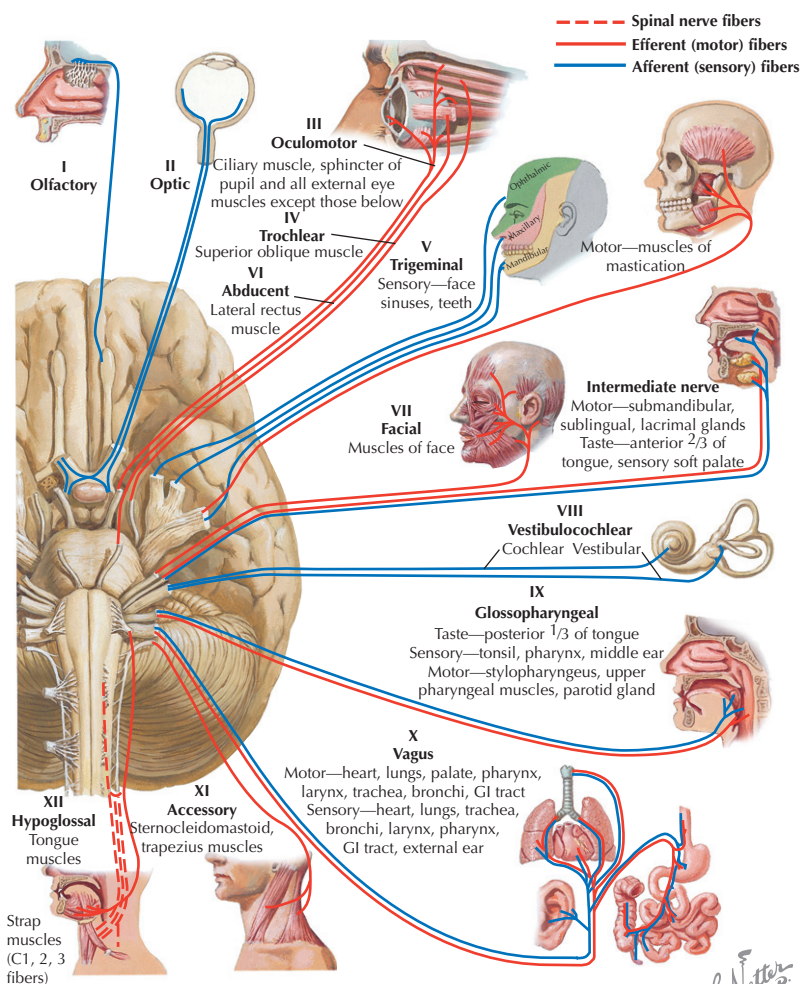
### GENERAL INFORMATION

*Cranial nerves or cerebral nerves* are those peripheral nerves that leave the brain or brainstem

The cranial nerves customarily are subdivided into 12 pairs:

- |                       |                               |
|-----------------------|-------------------------------|
| I: Olfactory nerve    | VII: Facial nerve             |
| II: Optic nerve       | VIII: Vestibulocochlear nerve |
| III: Oculomotor nerve | IX: Glossopharyngeal nerve    |
| IV: Trochlear nerve   | X: Vagus nerve                |
| V: Trigeminal nerve   | XI: Spinal accessory nerve    |
| VI: Abducens nerve    | XII: Hypoglossal nerve        |

Because of the high degree of differentiation in the brain of humans, cranial nerves are more complex in structure and function than spinal nerves





# Cranial Nerves

## FUNCTIONAL COLUMNS

7 functional components (or functional columns) of the cranial nerves are recognized

- Concept of *functional columns* comes from studies of spinal nerves—functions associated with different neurologic pathways along spinal column are assigned corresponding “columns”

A given cranial nerve may have 1 to 5 functional columns

The functional columns are classified as *general* or *special*:

- General—these functional columns have the same functions as those for spinal nerves
- Special—these functional columns are specific only to cranial nerves

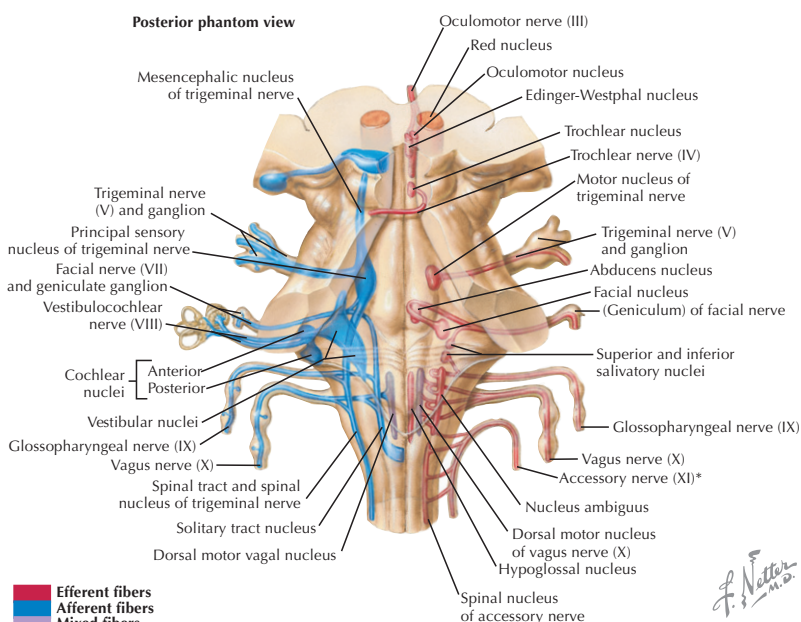
General and special functional columns each are subdivided into 2 additional categories:

- *Afferent* (sensory) and *efferent* (motor)
- *Somatic* (body-related) and *visceral* (organ-related)

## SUMMARY OF FUNCTIONS

GSA	Exteroceptors and proprioceptors (e.g., for pain, touch, and temperature, or within tendons and joints) These are the same as in spinal nerves
SSA	Special senses in eye and ear (vision; hearing and equilibrium)
GVA	Sensory from viscera (e.g., gut) These are the same as in spinal nerves
SVA	Olfaction and taste
GVE	Autonomic nervous system (innervates cardiac muscle, smooth muscle, and glands) These are the same as in spinal nerves
GSE	Skeletal (somatic) muscle These are the same as in spinal nerves
SVE	Skeletal muscle which develops from the pharyngeal (branchial) arches (homologous to GSE)

*\*Within each designation: G or S, general or special; S or V, somatic or visceral; A or E, afferent or efferent.*

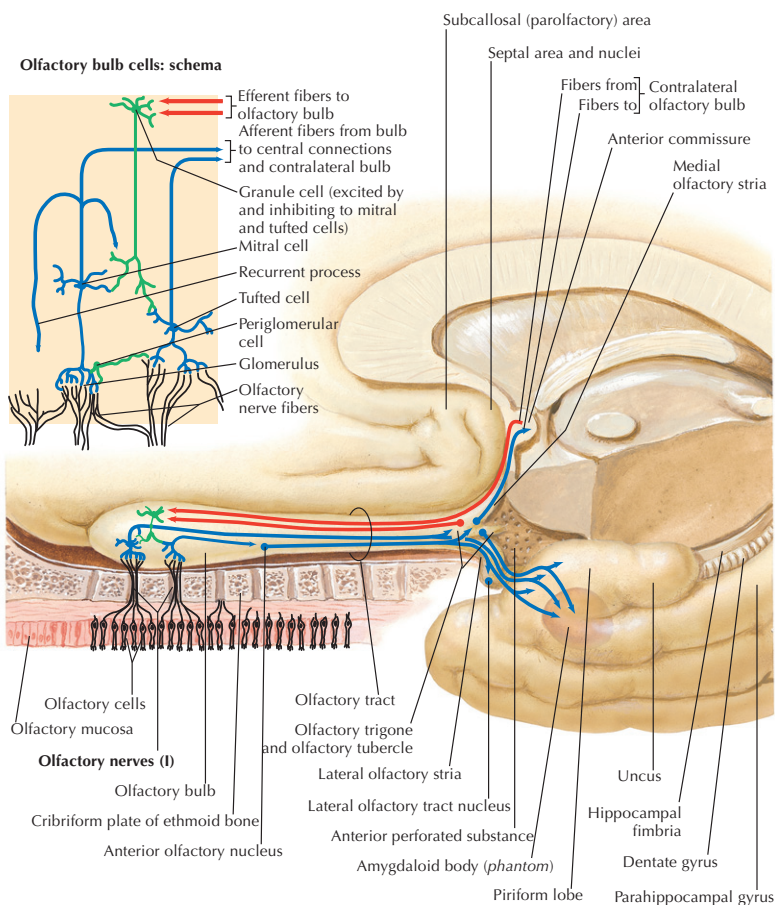


\*Recent evidence suggests that the accessory nerve lacks a cranial root and has no connection to the vagus nerve. Verification of this finding awaits further investigation

### 3 Cranial Nerves

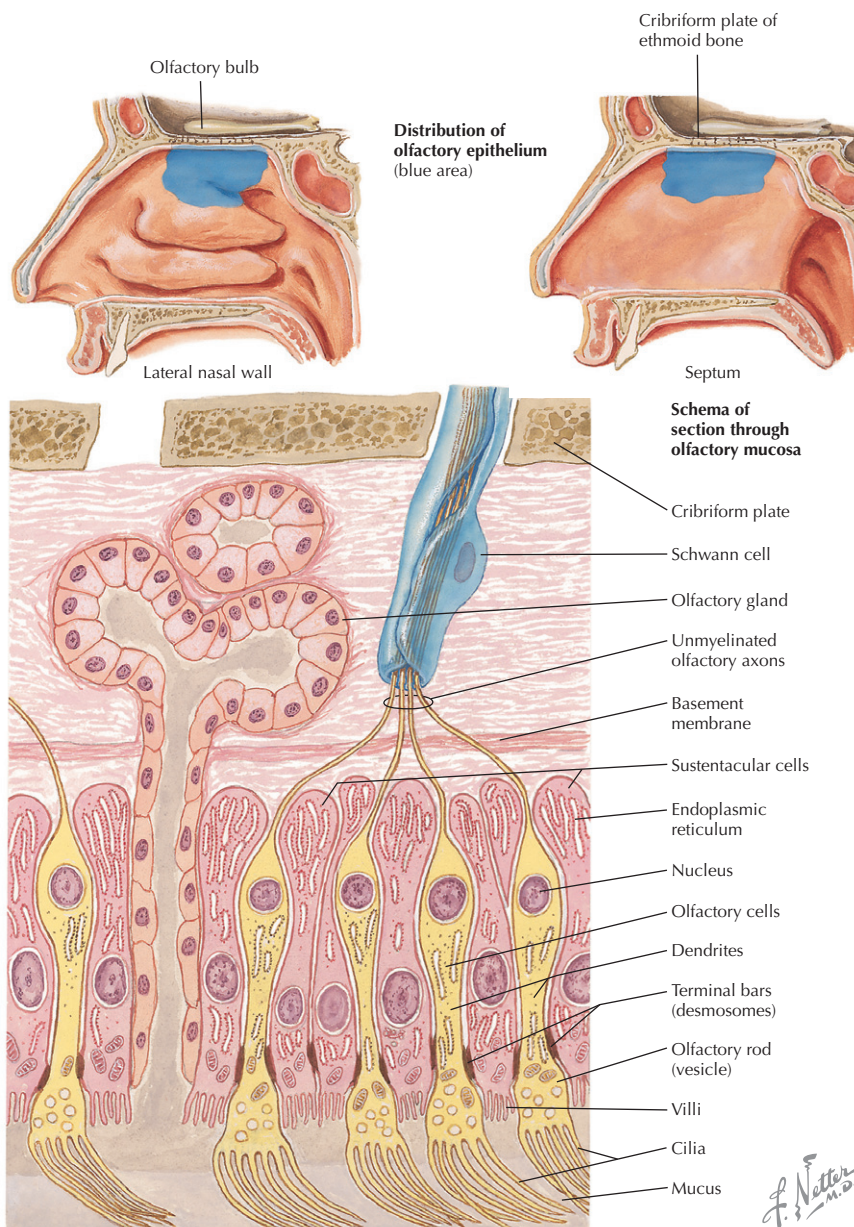
#### CRANIAL NERVE I: OLFACTORY NERVE

Functional Column	Origin of Fibers	Termination of Fibers	Summary	Comment
SVA	Fibers originate in the neurosensory cells of the olfactory epithelium The primary fibers travel through the cribriform plate to synapse on the secondary fibers within the olfactory bulb These fibers continue posteriorly as the olfactory tract that carries the fibers to the olfactory areas	The secondary fibers continue to synapse in the olfactory areas: <ul style="list-style-type: none"> <li>• Lateral olfactory area</li> <li>• Anterior olfactory nucleus</li> <li>• Intermediate olfactory area</li> <li>• Medial olfactory area</li> </ul>	The SVA fibers are responsible for the sense of smell	Tumors of the olfactory lobe can affect the olfactory system



# Cranial Nerves

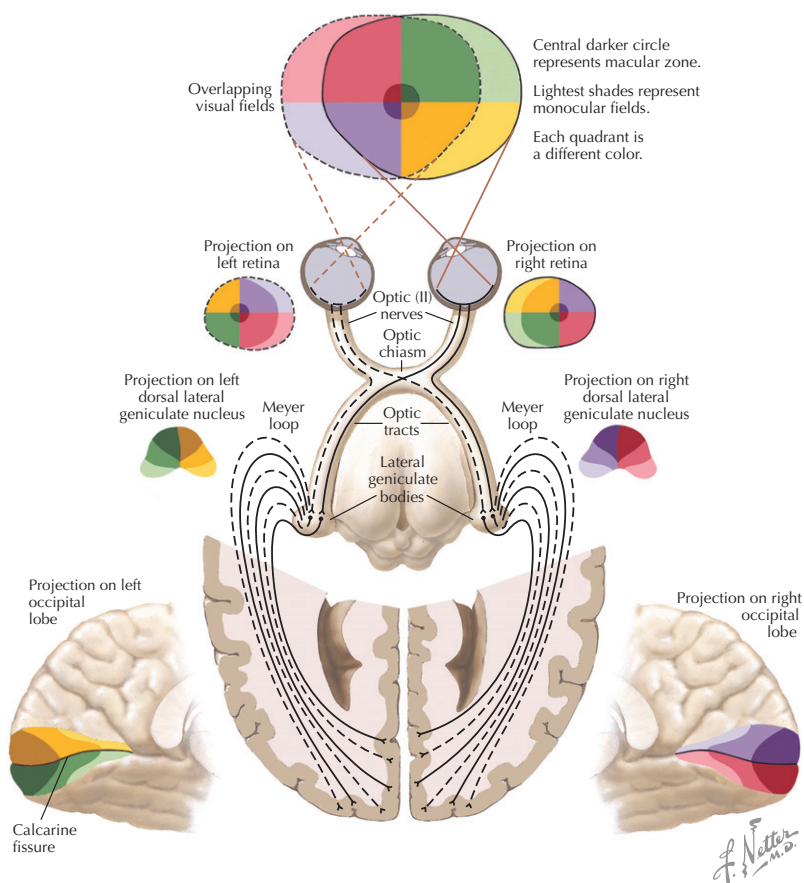
## CRANIAL NERVE I: OLFACTORY NERVE *CONTINUED*



### 3 Cranial Nerves

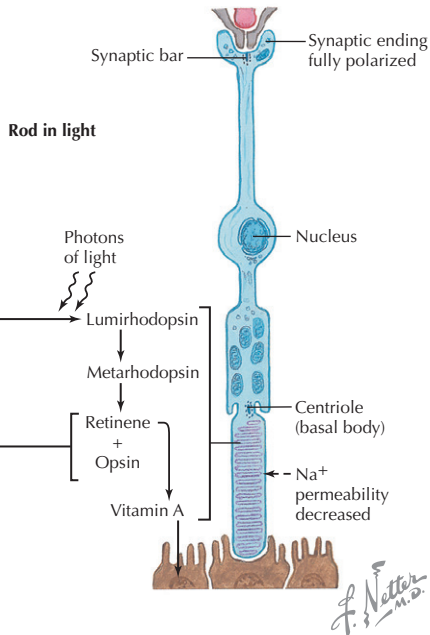
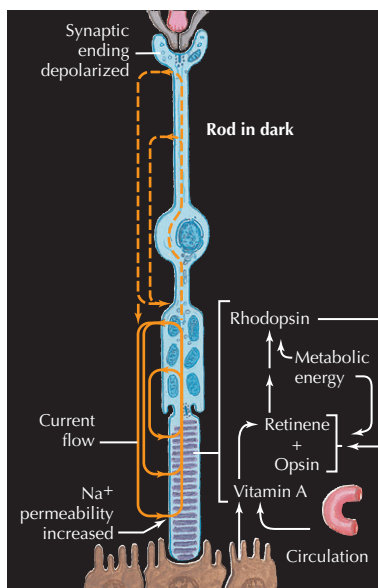
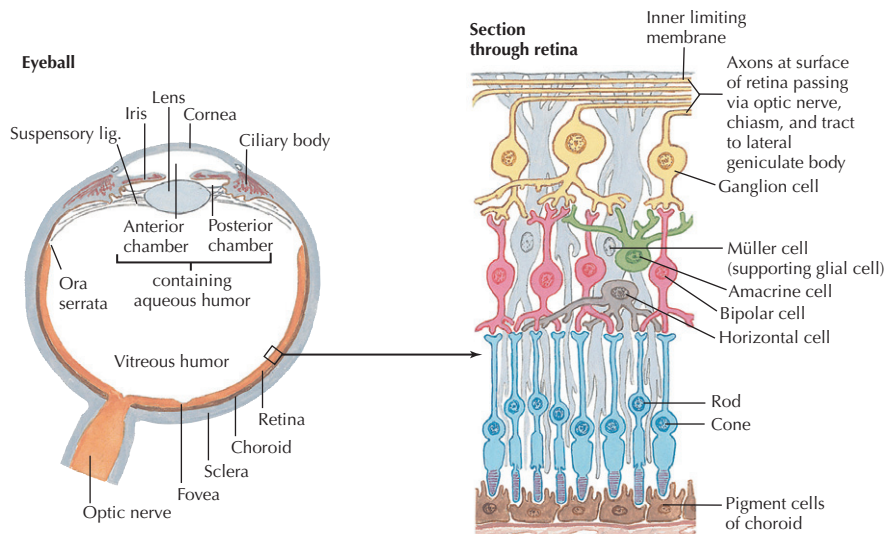
#### CRANIAL NERVE II: OPTIC NERVE

Functional Column	Origin of Fibers	Termination of Fibers	Summary	Comment
SSA	Begins in the retina with the receptors of rods and cones that synapse on bipolar cells which synapse with ganglion cells	<p>Ganglionic axons form the optic nerve that meets in an incomplete crossing at the optic chiasm where:</p> <ul style="list-style-type: none"> <li>• Nasal retinal fibers decussate to the opposite side</li> <li>• Temporal retinal fibers remain on the ipsilateral side</li> </ul> <p>These form an optic tract that terminates on the lateral geniculate nucleus</p> <p>Fibers from the lateral geniculate travel to synapse in the occipital lobe</p>	The SSA fibers are responsible for vision	<p>Lesions of the optic nerve lead to blindness</p> <p>Lesions of the optic chiasm lead to bitemporal hemianopsia</p> <p>Lesions of the optic tract lead to homonymous hemianopsia</p>



# Cranial Nerves

## CRANIAL NERVE II: OPTIC NERVE CONTINUED

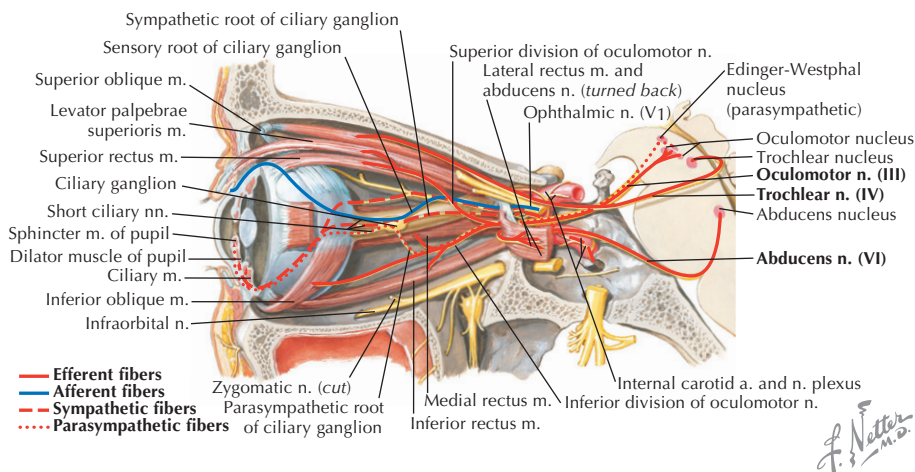




### 3 Cranial Nerves

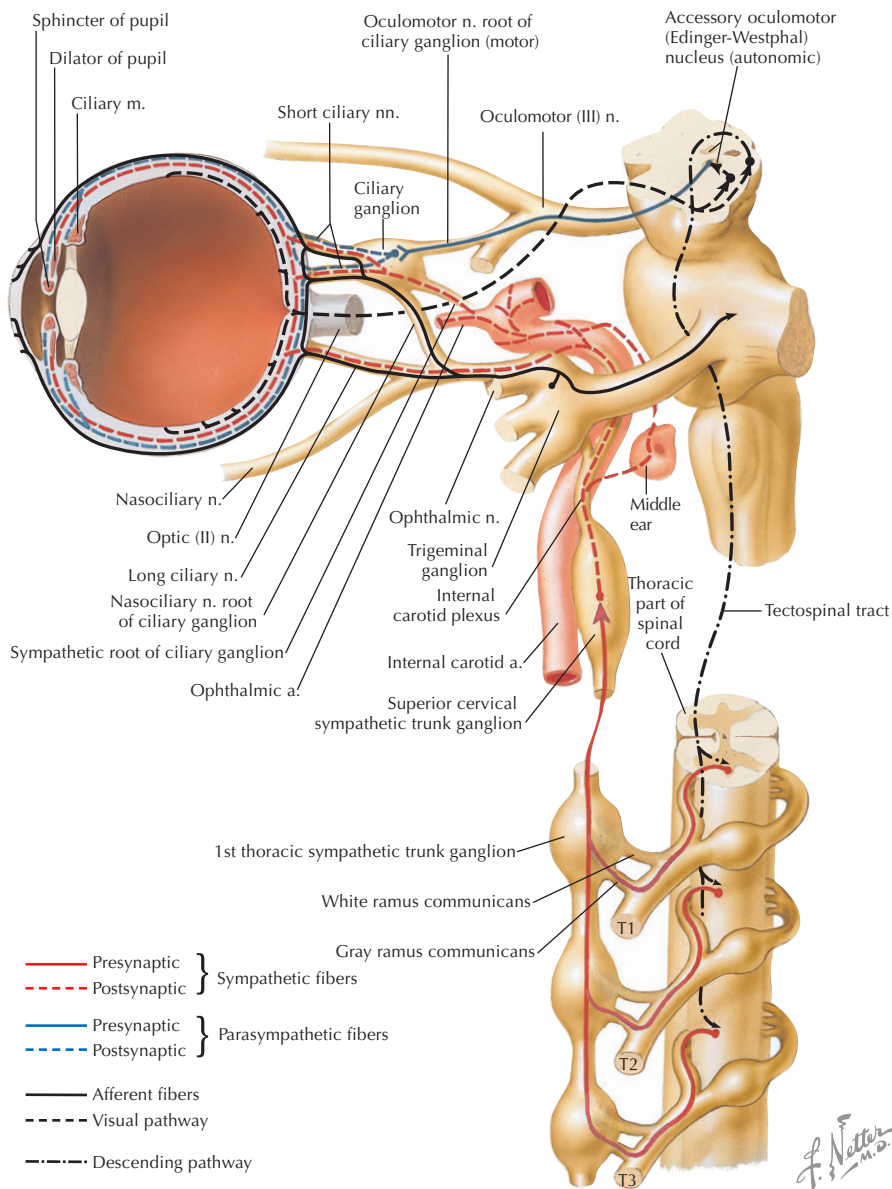
#### CRANIAL NERVES III, IV, AND VI: OCULOMOTOR, AND TROCHLEAR, ABDUCENS NERVES

OCULOMOTOR NERVE				
Functional Column	Origin of Fibers	Termination of Fibers	Summary	Comment
GSE	Begins in the oculomotor nucleus	Innervates the superior rectus, inferior rectus, medial rectus, inferior oblique, and levator palpebrae superioris mm.	GSE fibers are responsible for innervating the majority of the extraocular eye muscles	Lesions of the oculomotor nerve result in diplopia, lateral strabismus, ptosis, and mydriasis
GVE	Preganglionic parasympathetic fibers begin in the Edinger-Westphal nucleus	Innervates the sphincter pupillae and ciliary mm.	GVE fibers are responsible for providing the parasympathetic innervation to the intrinsic eye muscles	GVE fibers utilize 1 ganglion: • Ciliary
TROCHLEAR NERVE				
Functional Column	Origin of Fibers	Termination of Fibers	Summary	Comment
GSE	Begins in the trochlear nucleus	Innervates the superior oblique m.	GSE fibers are responsible for innervating 1 extraocular muscle of the eye: the superior oblique	The trochlear nerve exits the brainstem dorsally Lesions of the trochlear n. result in diplopia In trochlear n. lesions, the eye is adducted and elevated
ABDUCENS NERVE				
Functional Column	Origin of Fibers	Termination of Fibers	Summary	Comment
GSE	Begins in the abducens nucleus	Innervates the lateral rectus m.	GSE fibers are responsible for innervating 1 extraocular muscle of the eye: the lateral rectus	Lesions of the abducens nerve result in diplopia and medial strabismus



# Cranial Nerves

## CRANIAL NERVES III, IV, AND VI: OCULOMOTOR, AND TROCHLEAR, ABDUCENS NERVES *CONTINUED*

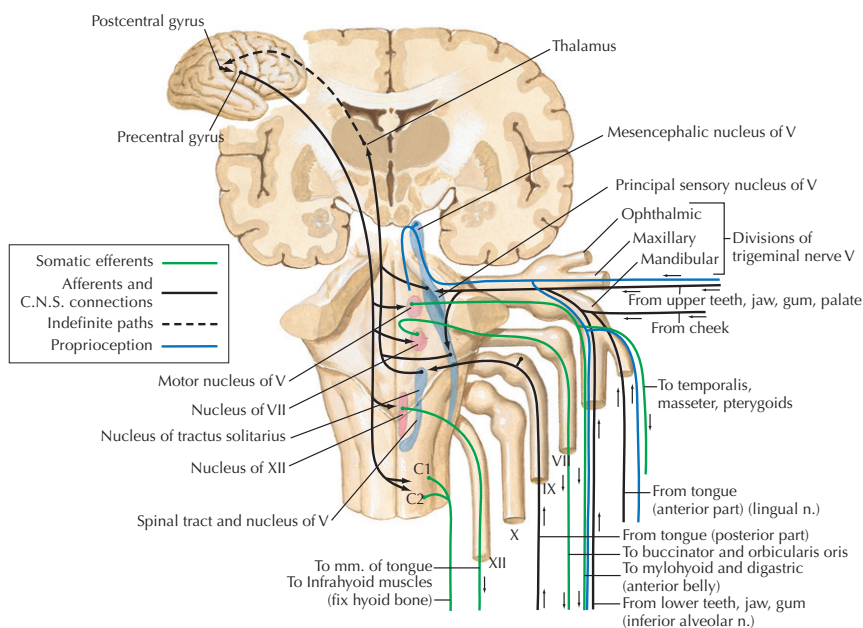




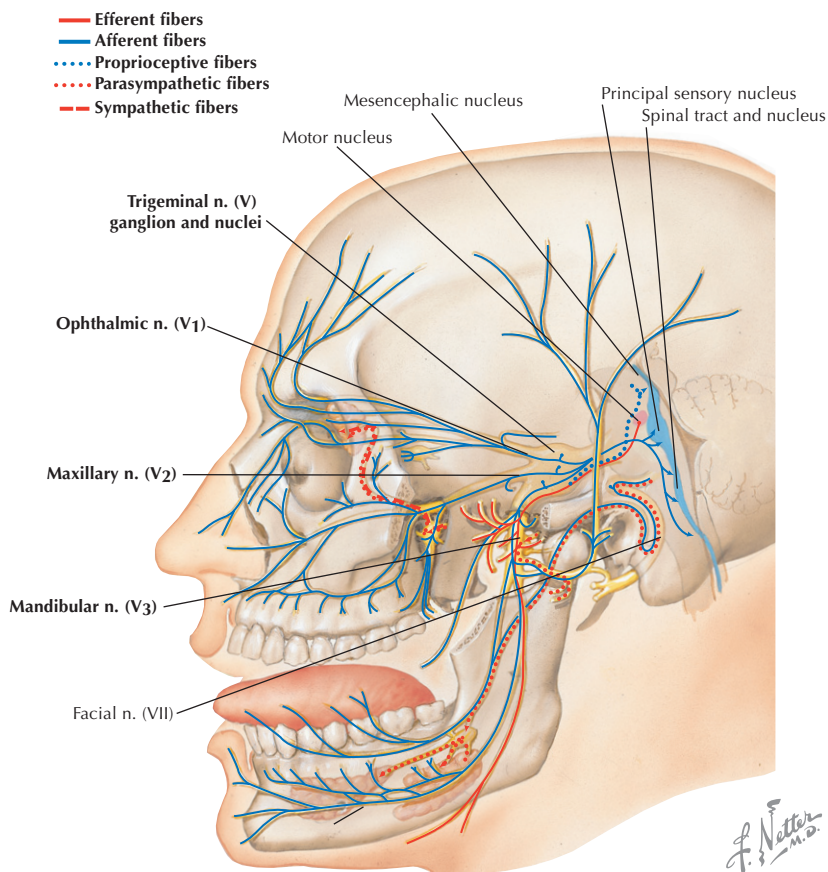
### 3 Cranial Nerves

#### CRANIAL NERVE V: TRIGEMINAL NERVE

Functional Column	Origin of Fibers	Termination of Fibers	Summary	Comment
GSA	Afferent fibers begin in the various receptors (nociceptors, mechanoreceptors, proprioceptors) of the skin and deep tissues of the head	Pain and temperature, and light touch fibers terminate in the spinal nucleus of V Discriminative touch fibers terminate in the main sensory nucleus of V Proprioception fibers have their cell bodies in the mesencephalic nucleus of V	GSA fibers are responsible for providing sensory innervation to the major part of the head GSA fibers utilize the trigeminothalamic lemniscus to carry their sensory impulses to consciousness	Provides sensory innervation through 3 main divisions: • Ophthalmic • Maxillary • Mandibular The nerve cell bodies for the primary fibers are located in the trigeminal ganglion
SVE	Begins in the motor nucleus of the trigeminal	Innervates the muscles of mastication: • Masseter • Temporalis • Medial pterygoid • Lateral pterygoid Also innervates: • Mylohyoid • Anterior digastric • Tensor tympani • Tensor veli palatini	The SVE fibers are responsible for innervating the muscles of the 1st pharyngeal arch	



*F. Netter M.D.*



### OPHTHALMIC DIVISION OF THE TRIGEMINAL NERVE

The ophthalmic division ( $V_1$ ), being a branch of the trigeminal n., is sensory in function  
 Arises from the main nerve in the middle cranial fossa  
 Passes anterior on the lateral wall of the cavernous sinus immediately inferior to the oculomotor and trochlear nn., but superior to the maxillary division of the trigeminal n.  
 Immediately before entering the orbit, through the superior orbital fissure, it divides into 3 major branches:

- Lacrimal
- Frontal
- Nasociliary

Nerve	Source	Course
Lacrimal	1 of the 3 major branches of the ophthalmic division of the trigeminal n.	<p>Smallest branch of the ophthalmic division of the trigeminal n. Passes anteriorly to enter the orbit through the superior orbital fissure</p> <p>In the orbit it travels on the superior border of the lateral rectus with the lacrimal a.</p> <p>Before reaching the lacrimal gland, it communicates with the zygomatic branch of the maxillary division of the trigeminal n. to receive autonomic nervous fibers</p> <p>Enters the lacrimal gland and supplies it and the conjunctiva before piercing the orbital septum to supply the skin of the upper eyelid</p>

### 3 Cranial Nerves

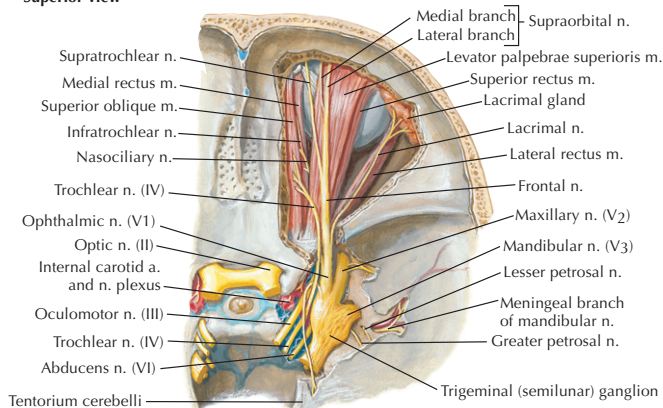
#### CRANIAL NERVE V: TRIGEMINAL NERVE *CONTINUED*

Nerve	Source	Course
Frontal	1 of the 3 major branches of the ophthalmic division of the trigeminal n.	Largest branch of the ophthalmic division of the trigeminal n. Passes anteriorly to enter the orbit through the superior orbital fissure In the orbit it passes anteriorly between the periosteum of the orbit and the levator palpebrae superioris m. About halfway in the orbit, it divides into its 2 terminal nerves, the supraorbital and supratrochlear nn.
<i>Supraorbital</i>	Frontal n.	1 of the 2 terminal branches of the frontal n. in the orbit Passes between the levator palpebrae superioris m. and periosteum of the orbit Continues anteriorly to the supraorbital foramen (notch) At the level of the supraorbital margin, it sends nerve supply to the frontal sinus and ascends superiorly along the scalp Divides into medial and lateral branches, which travel up to the vertex of the scalp
<i>Supratrochlear</i>		1 of the 2 terminal branches of the frontal n. in the orbit Once the supratrochlear a. joins it within the orbit, it continues to pass anteriorly toward the trochlear n. In the trochlear region, it often supplies the frontal sinus before exiting the orbit Ascends along the scalp, at first deep to the musculature in the region, before piercing these muscles to reach the cutaneous innervation along the scalp
Nasociliary	1 of the 3 major branches of the ophthalmic division of the trigeminal n.	Passes anteriorly to enter the orbit through the superior orbital fissure Enters the orbit lateral to the optic n. Travels across the optic n. anteriorly and medially to lie between the medial rectus m. and the superior oblique m. along the medial wall of the orbit All along its path, it gives rise to other nerves, including the sensory root of the ciliary ganglion and the long ciliary and posterior ethmoid nn., until terminating into the anterior ethmoid and infratrochlear nn. near the anterior ethmoid foramen
<i>Sensory root of the ciliary ganglion</i>	Nasociliary n.	Travels anteriorly on the lateral side of the optic n. to enter the ciliary ganglion Carries general sensory fibers, which are distributed by the short ciliary nn.
<i>Short ciliary</i>	Ciliary ganglion	Arises from the ciliary ganglion to travel to the posterior surface of the eye Supplies the sensory fibers to the eye and helps carry the postganglionic parasympathetic fibers to the sphincter pupillae and the ciliary muscle
<i>Long ciliary</i>	Nasociliary n.	Has 2 to 4 branches that travel anteriorly to enter the posterior part of the sclera of the eye
<i>Posterior ethmoid</i>		Travels deep to the superior oblique m. to pass through the posterior ethmoid foramen Supplies the sphenoid sinus and the posterior ethmoid sinus
<i>Anterior ethmoid</i>		Arises on the medial wall of the orbit Enters the anterior ethmoid foramen and travels through the canal to enter the anterior cranial fossa Supplies the anterior and middle ethmoid sinus before entering and supplying the nasal cavity Terminates as the external nasal n. on the face
<i>External nasal</i>	A terminal branch of the anterior ethmoid n.	Exits between the lateral nasal cartilage and the inferior border of the nasal bone Supplies the skin of the ala and apex of the nose around the nares
<i>Internal nasal</i>		Supplies the skin on the internal surface of the vestibule
<i>Infratrochlear</i>	Nasociliary n.	1 of the terminal branches of the nasociliary branch of the ophthalmic division of the trigeminal n. Passes anteriorly on the superior border of the medial rectus m. Passes inferior to the trochlea toward the medial angle of the eye Supplies the skin of the eyelids and bridge of the nose, the conjunctiva, and all of the lacrimal structures

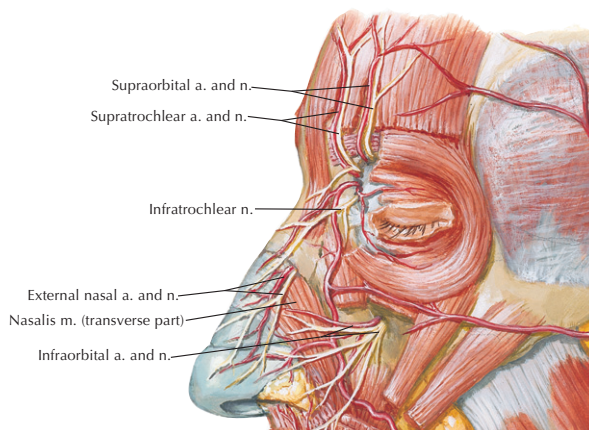
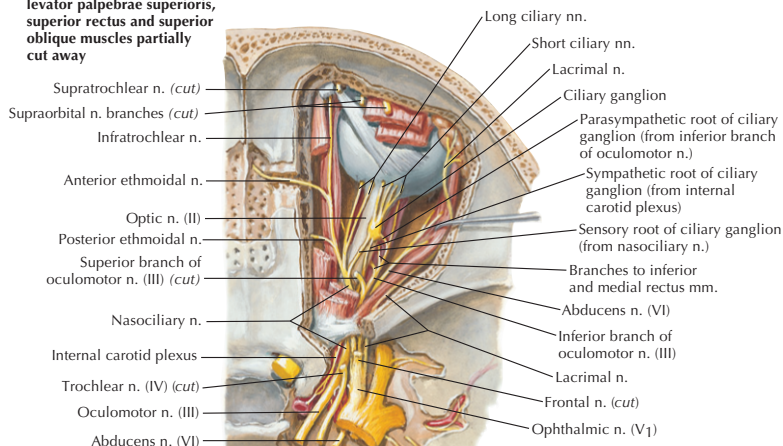
# Cranial Nerves

## CRANIAL NERVE V: TRIGEMINAL NERVE *CONTINUED*

### Superior view



### Superior view: levator palpebrae superioris, superior rectus and superior oblique muscles partially cut away



*F. Netter M.D.*

### 3 Cranial Nerves

#### CRANIAL NERVE V: TRIGEMINAL NERVE *CONTINUED*

MAXILLARY DIVISION OF THE TRIGEMINAL NERVE	
<p>The maxillary division (<math>V_2</math>), being a branch of the trigeminal n., is sensory in function</p> <p>Branches from the trigeminal n. and travels along the lateral wall of the cavernous sinus</p> <p>Passes from the middle cranial fossa into the pterygopalatine fossa via the foramen rotundum</p> <p>Within the pterygopalatine fossa, it gives rise to 4 branches</p> <p>1 of those nerves, the infraorbital n., is considered the continuation of the maxillary division of the trigeminal n.</p>	
BRANCHES WITHIN THE MIDDLE CRANIAL FOSSA	
Nerve	Course
Meningeal	A small meningeal branch is given off within the middle cranial fossa The nerve supplies the meninges
BRANCHES WITHIN THE PTERYGOPALATINE FOSSA	
Nerve	Course
Posterior superior alveolar	<p>Passes through the pterygomaxillary fissure to enter the infratemporal fossa</p> <p>In the infratemporal fossa, it passes on the posterior surface of the maxilla along the region of the maxillary tuberosity</p> <p>Gives rise to a gingival branch that innervates the buccal gingiva alongside the maxillary molars</p> <p>Enters the posterior surface of the maxilla and supplies the maxillary sinus and the maxillary molars, with the possible exception of the mesiobuccal root of the 1st maxillary molar, and the gingiva and mucosa alongside the same teeth</p>
Zygomatic	<p>Passes through the inferior orbital fissure to enter the orbit</p> <p>Passes on the lateral wall of the orbit and branches into the zygomaticotemporal and zygomaticofacial branches</p> <p>A communicating branch from it joins the lacrimal n. from the ophthalmic division of the trigeminal n. to carry autonomic to the lacrimal gland</p>
Ganglionic branches	<p>Usually 1 or 2 ganglionic branches that connect the maxillary division of the trigeminal n. to the pterygopalatine ganglion</p> <p>Contain sensory fibers that pass through the pterygopalatine ganglion (without synapsing) to be distributed with the nerves that arise from the pterygopalatine ganglion</p> <p>Also contain postganglionic autonomic fibers to the lacrimal gland that pass through the pterygopalatine ganglion (parasympathetic fibers form a synapse here between the preganglionic fibers from the vidian n. and the postganglionic fibers)</p>
Infraorbital	<p>Considered the continuation of the maxillary division of the trigeminal n.</p> <p>Passes through the inferior orbital fissure to enter the orbit</p> <p>Passes anteriorly through the infraorbital groove and infraorbital canal and exits onto the face via the infraorbital foramen</p>
BRANCHES ASSOCIATED WITH THE PTERYGOPALATINE GANGLION	
Nerve	Course
Pharyngeal	Passes through the pharyngeal canal to enter and supply the nasopharynx
Posterior superior nasal	<p>A branch of the maxillary division of the trigeminal n.</p> <p>Arises from the pterygopalatine ganglion in the pterygopalatine fossa</p> <p>Passes through the sphenopalatine foramen to enter the nasal cavity and branches into the:</p> <ul style="list-style-type: none"> <li>• Posterior medial superior nasal n.</li> <li>• Posterior lateral superior nasal n.</li> </ul>
Posterior lateral superior nasal	A branch of the posterior superior nasal n. that supplies the posterosuperior portion of the lateral wall of the nasal cavity in the region of the superior and middle concha
Posterior medial superior nasal	<p>Arises from the posterior superior nasal n. from the maxillary division of the trigeminal n.</p> <p>This nerve supplies the posterior portion of the nasal septum</p>
Greater palatine	<p>Passes through the palatine canal to enter the hard palate via the greater palatine foramen</p> <p>Supplies the palatal gingiva and mucosa from the area in the premolar region to the posterior border of the hard palate to the midline</p>

# Cranial Nerves

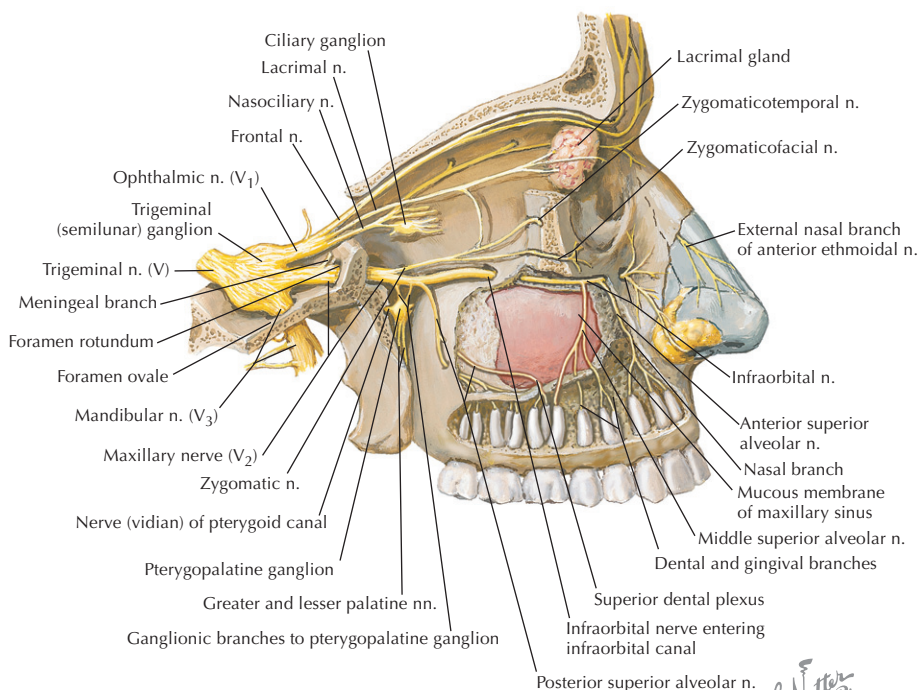
## CRANIAL NERVE V: TRIGEMINAL NERVE *CONTINUED*

BRANCHES ASSOCIATED WITH THE PTERYGOPALATINE GANGLION <i>CONTINUED</i>	
Nerve	Course
Posterior inferior nasal branch of the greater palatine	While descending in the palatine canal, the greater palatine n. gives rise to a posterior inferior nasal branch Supplies the posterior part of the lateral wall of the nasal cavity in the region of the middle meatus
Lesser palatine	Passes through the palatine canal to enter and supply the soft palate via the lesser palatine foramen
Nasopalatine	Branches from the pterygopalatine ganglion in the pterygopalatine fossa Passes through the sphenopalatine foramen to enter the nasal cavity Passes along the superior portion of the nasal cavity to the nasal septum, where it travels anteroinferiorly to the incisive canal, supplying the septum Passes through the incisive canal to supply the gingiva and mucosa of the hard palate from central incisor to canine
BRANCHES WITHIN THE INFRAORBITAL CANAL	
Nerve	Course
Middle superior alveolar	A variable nerve When present, it branches off the infraorbital n. as it travels in the infraorbital canal As the nerve descends to form the superior dental plexus, it innervates part of the maxillary sinus; the premolars and possibly the mesiobuccal root of the 1st molar; and the gingiva and mucosa alongside the same teeth
Anterior superior alveolar	While in the infraorbital canal, it gives rise to the anterior superior alveolar n., which has a small branch that supplies the nasal cavity in the region of the inferior meatus and inferior corresponding portion of the nasal septum, the maxillary sinus As the nerve descends to form the superior dental plexus, it innervates part of the maxillary sinus; maxillary central incisor, lateral incisor, and canine teeth; and the gingiva and mucosa alongside the same teeth
BRANCHES AFTER INFRAORBITAL NERVE EMERGES FROM THE INFRAORBITAL FORAMEN	
Nerve	Course
Superior labial branch of the infraorbital	Supplies the skin of the upper lip
Nasal branch of the infraorbital	Supplies the ala of the nose
Inferior palpebral branch of the infraorbital	Supplies the skin of the lower eyelid

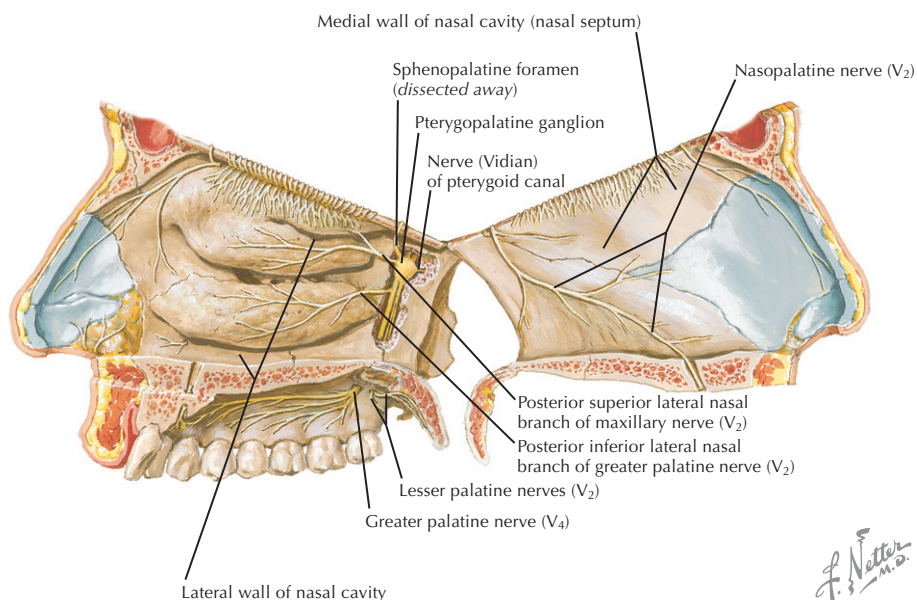


# 3 Cranial Nerves

## CRANIAL NERVE V: TRIGEMINAL NERVE CONTINUED



*F. Netter M.D.*  
K. Carter



*F. Netter M.D.*

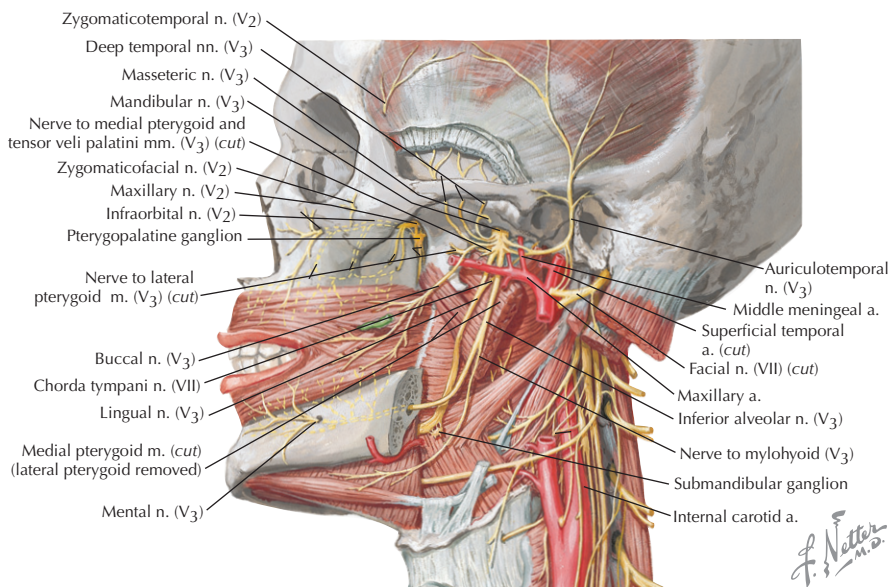
# Cranial Nerves

## CRANIAL NERVE V: TRIGEMINAL NERVE *CONTINUED*

MANDIBULAR DIVISION OF THE TRIGEMINAL NERVE				
Description	Source	Course	Divisions	
			Anterior	Posterior
Mandibular division (V <sub>3</sub> ) is the largest of the 3 divisions of the trigeminal n. Has motor and sensory functions	Created by a large sensory root and a small motor root that unite just after passing through the foramen ovale to enter the infratemporal fossa	Immediately gives rise to a meningeal branch and then divides into anterior and posterior divisions	Smaller; mainly motor, with 1 sensory branch (buccal): <ul style="list-style-type: none"><li>• Masseteric</li><li>• Anterior and posterior deep temporal</li><li>• Medial pterygoid</li><li>• Lateral pterygoid</li><li>• Buccal</li></ul>	Larger; mainly sensory, with 1 motor branch (nerve to the mylohyoid): <ul style="list-style-type: none"><li>• Auriculotemporal</li><li>• Lingual</li><li>• Inferior alveolar</li><li>• Mylohyoid nerve</li></ul>
ANTERIOR DIVISION OF THE MANDIBULAR NERVE				
Branch	Course			
Masseteric	Passes laterally superior to the lateral pterygoid m. Lies anterior to the temporomandibular joint and posterior to the tendon of the temporalis m. Crosses the mandibular notch with the masseteric a. to innervate the masseter m. Also provides a small branch to the temporomandibular joint			
Anterior and posterior deep temporal	Pass superior to the lateral pterygoid m. between the skull and the temporalis m. while passing deep to the muscle to innervate it			
Medial pterygoid	Enters the deep surface of the muscle			
Lateral pterygoid	Passes into the deep surface of the muscle Often arises from the buccal n.			
Buccal	Passes anteriorly between the 2 heads of the lateral pterygoid m. Descends inferiorly along the lower part of the temporalis m. to appear from deep to the anterior border of the masseter m. Supplies the skin over the buccinator m. before passing through it to supply the mucous membrane lining its inner surface and the gingiva along the mandibular molars			
POSTERIOR DIVISION OF THE MANDIBULAR NERVE				
Branch	Course			
Auriculotemporal	Normally arises by 2 roots, between which the middle meningeal a. passes Runs posteriorly just inferior to the lateral pterygoid and continues to the medial side of the neck of the mandible Then it turns superiorly with the superficial temporal vessels between the auricle and condyle of the mandible deep to the parotid gland On exiting the parotid gland, it ascends over the zygomatic arch and divides into superficial temporal branches			
Lingual	Lies inferior to the lateral pterygoid and medial and anterior to the inferior alveolar n. The chorda tympani n. also joins the posterior part The lingual n. passes between the medial pterygoid and the ramus of the mandible to pass obliquely to enter the oral cavity bounded by the superior pharyngeal constrictor m., medial pterygoid, and the mandible Supplies the mucous membrane of the anterior 2/3 of the tongue and gingiva on the lingual side of the mandibular teeth			
Inferior alveolar	The largest branch of the mandibular division Descends following the inferior alveolar a. inferior to the lateral pterygoid and finally between the sphenomandibular lig. and the ramus of the mandible until it enters the mandibular foramen Innervates all mandibular teeth and the gingiva from the premolars anteriorly to the midline via the mental branch			
Mylohyoid	Branches from the inferior alveolar n. immediately before it enters the mandibular foramen Descends in a groove on the deep side of the ramus of the mandible until it reaches the superficial surface of the mylohyoid Supplies the mylohyoid and the anterior belly of the digastric m.			

# 3 Cranial Nerves

## CRANIAL NERVE V: TRIGEMINAL NERVE CONTINUED



### TRIGEMINAL NERVE PATHWAYS

Responsible for carrying to conscious level:

- Pain and temperature
- Light touch
- Discriminative touch
- Pressure

Utilizes a 3-neuron sensory system:

- Primary neuron
- Secondary neuron
- Tertiary neuron

Utilizes the contralateral ventral trigeminothalamic tract

Some discriminative touch and pressure fibers utilize the ipsilateral dorsal trigeminothalamic tract, but this contribution is very minor

Proprioception fibers are unique in that the cell body for the sensory nerve fiber is located in the central nervous system (mesencephalic nucleus)

Types of Fibers	Trigeminal Sensory Nucleus	Ascending Pathway
Pain and temperature Light touch	Spinal (descending) nucleus	Ventral trigeminothalamic tract
Discriminative touch Pressure	Principal (main) sensory nucleus	Ventral trigeminothalamic tract (Dorsal trigeminothalamic tract subserves discriminative touch and pressure)
Proprioception	Mesencephalic nucleus	Projects to motor nucleus of V to control the jaw jerk reflex and force of bite

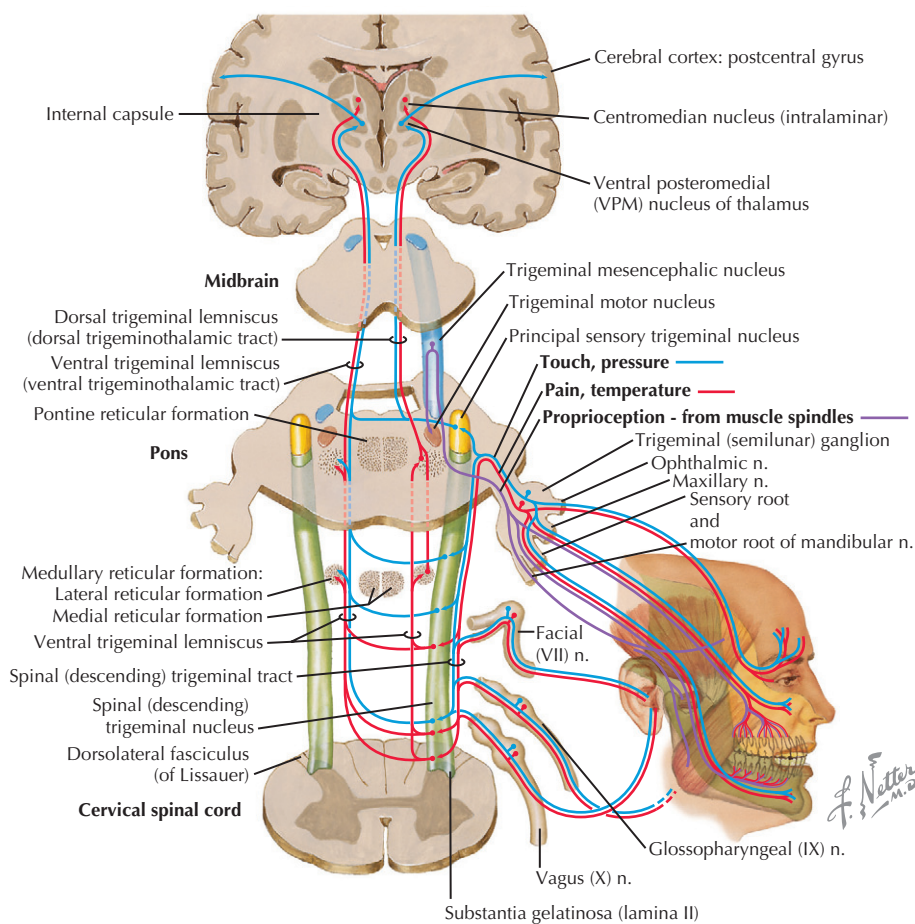
# Cranial Nerves

## CRANIAL NERVE V: TRIGEMINAL NERVE *CONTINUED*

MAJOR ASCENDING PATHWAYS OF THE TRIGEMINAL NERVE			
Types of Neurons	Path of Pain and Temperature	Path of Light Touch	Path of Discriminative Touch and Pressure
Primary neuron	<p>Fibers (A<math>\delta</math> or C) travel from the receptor from the ophthalmic, maxillary, and mandibular divisions of the trigeminal n.</p> <p>The nerve cell body of the primary neuron is located in the trigeminal ganglion</p> <p>Fibers enter the pons</p> <p>Fibers descend in the spinal (descending) tract located from the pons to the upper cervical spinal cord</p> <p>Fibers synapse on the nerve cell body of the secondary neuron</p>	<p>Fibers (A<math>\beta</math>) travel from the receptor from the ophthalmic, maxillary, and mandibular divisions of the trigeminal n.</p> <p>The nerve cell body of the primary neuron is located in the trigeminal ganglion</p> <p>Fibers enter the pons</p> <p>Fibers may have either of 2 courses:</p> <ul style="list-style-type: none"> <li>• May descend in the spinal (descending) tract located from the pons to the upper cervical spinal cord</li> <li>• May ascend to synapse on the nerve cell body of the secondary neuron</li> </ul> <p>Fibers synapse on the nerve cell body of the secondary neuron</p>	<p>Fibers (A<math>\beta</math>) travel from the receptor from the ophthalmic, maxillary, and mandibular divisions of the trigeminal n.</p> <p>The nerve cell body of the primary neuron is located in the trigeminal ganglion</p> <p>Fibers enter the pons</p> <p>Fibers ascend to synapse on the nerve cell body of the secondary neuron</p>
Secondary neuron	<p>Secondary nerve cell bodies begin in the spinal (descending) nucleus located from the pons to the upper cervical spinal cord (pars caudalis)</p> <p>Fibers decussate and ascend in the ventral trigeminothalamic tract (lemniscus) to the thalamus</p> <p>Fibers synapse on the nerve cell body of the tertiary neuron</p>	<p>Secondary nerve cell bodies may reach the thalamus along either of 2 courses:</p> <ul style="list-style-type: none"> <li>• May begin in the spinal (descending) nucleus (pars interpolaris and pars oralis) and decussate and ascend in the ventral trigeminothalamic tract (lemniscus) to the thalamus</li> <li>• May begin in the principal (main) sensory nucleus and decussate and ascend in the ventral trigeminothalamic tract (lemniscus) to the thalamus (NOTE: some fibers ascend in the ipsilateral dorsal trigeminothalamic tract)</li> </ul> <p>Fibers synapse on the nerve cell body of the tertiary neuron</p>	<p>Secondary nerve cell bodies begin in the principal (main) sensory nucleus located in the pons</p> <p>Fibers decussate and ascend in the ventral trigeminothalamic tract (lemniscus) to the thalamus (NOTE: some fibers ascend in the ipsilateral dorsal trigeminothalamic tract)</p> <p>Fibers synapse on the nerve cell body of the tertiary neuron</p>
Tertiary neuron	<p>Tertiary nerve cell bodies begin in the ventral posteromedial nucleus of the thalamus (VPM)</p> <p>Fibers ascend through the posterior limb of the internal capsule to terminate in the postcentral gyrus</p>	<p>Tertiary nerve cell bodies begin in the VPM</p> <p>Fibers ascend through the posterior limb of the internal capsule to terminate in the postcentral gyrus</p>	<p>Tertiary nerve cell bodies begin in the VPM</p> <p>Fibers ascend through the posterior limb of the internal capsule to terminate in the postcentral gyrus</p>
PROPRIOCEPTION OF THE TRIGEMINAL NERVE			
<p>Sensory fibers carry input from the neuromuscular spindles along the mandibular division of the trigeminal n.</p> <p>The nerve cell bodies of these sensory neurons are located in the mesencephalic nucleus of the midbrain</p> <p>These fibers project to the motor nucleus of the trigeminal n. and innervate the muscles of mastication, to control the jaw jerk reflex and force of bite</p>			

### 3 Cranial Nerves

#### CRANIAL NERVE V: TRIGEMINAL NERVE *CONTINUED*



# Cranial Nerves

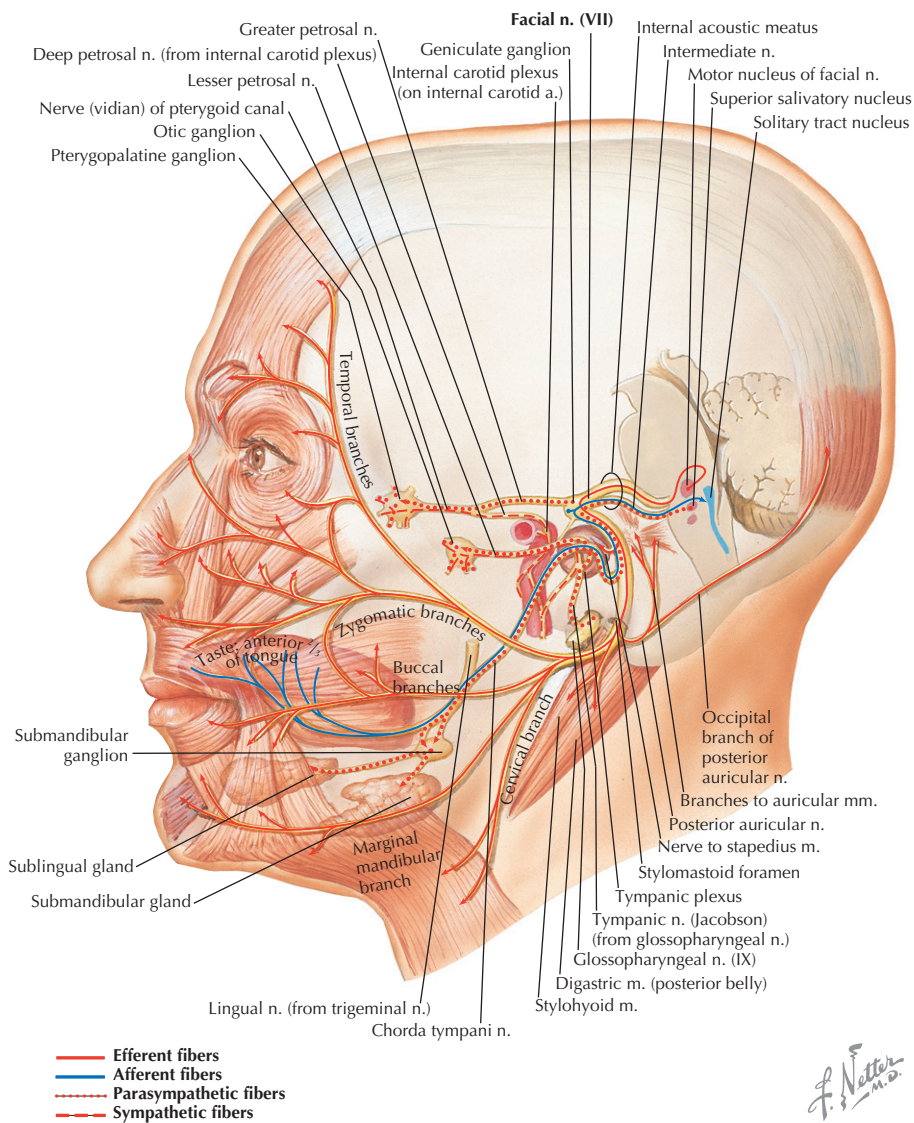
## CRANIAL NERVE VII: FACIAL NERVE

Functional Column	Origin of Fibers	Termination of Fibers	Summary	Comment
GSA	Afferent fibers begin in the various receptors (nociceptors, mechanoreceptors, proprioceptors) of the skin of the external ear and tympanic membrane	Pain and temperature fibers terminate in the spinal nucleus of V	GSA fibers are carried in the nervus intermedius portion of the facial n. GSA fibers are responsible for providing sensory innervation to a portion of the external ear and tympanic membrane GSA fibers of the facial n. utilize the trigeminothalamic lemniscus to carry their sensory impulses to consciousness	Facial nerve provides a very small area of GSA distribution Nerve cell bodies for the primary fibers are located in the geniculate ganglion
SVA	Afferent fibers begin in the taste receptors of the anterior 2/3 of the tongue	Primary afferent fibers travel in the tractus solitarius and terminate in the nucleus solitarius	SVA fibers are carried in the nervus intermedius portion of the facial n. SVA fibers are responsible for carrying the taste fibers from the taste buds on the anterior 2/3 of the tongue	Nerve cell bodies for the primary fibers are located in the geniculate ganglion
GVA	Afferent fibers begin in the various receptors (such as nociceptors) of the mucous membranes of the nasopharynx	Primary afferent fibers travel in the tractus solitarius and terminate in the nucleus solitarius	GVA fibers are carried in the nervus intermedius portion of the facial n. GVA fibers utilize the same pathway as for the SVA fibers	Nerve cell bodies for the primary fibers are located in the geniculate ganglion
GVE	Preganglionic parasympathetic fibers begin in the superior salivatory nucleus	Postganglionic parasympathetic fibers innervate the lacrimal, nasal, submandibular, and sublingual glands	GVE fibers are carried in the nervus intermedius portion of the facial n.	GVE fibers utilize 2 ganglia: ● Pterygopalatine ● Submandibular
SVE	Begins in the motor nucleus of the facial n.	Innervates the muscles of facial expression, stylohyoid, posterior digastric, and stapedius mm.	SVE fibers are carried in the motor root of the facial n. SVE fibers are responsible for innervating the muscles of the 2nd pharyngeal arch	In Bell's palsy, the easiest symptom to observe is that the muscles innervated by the SVE fibers are paralyzed



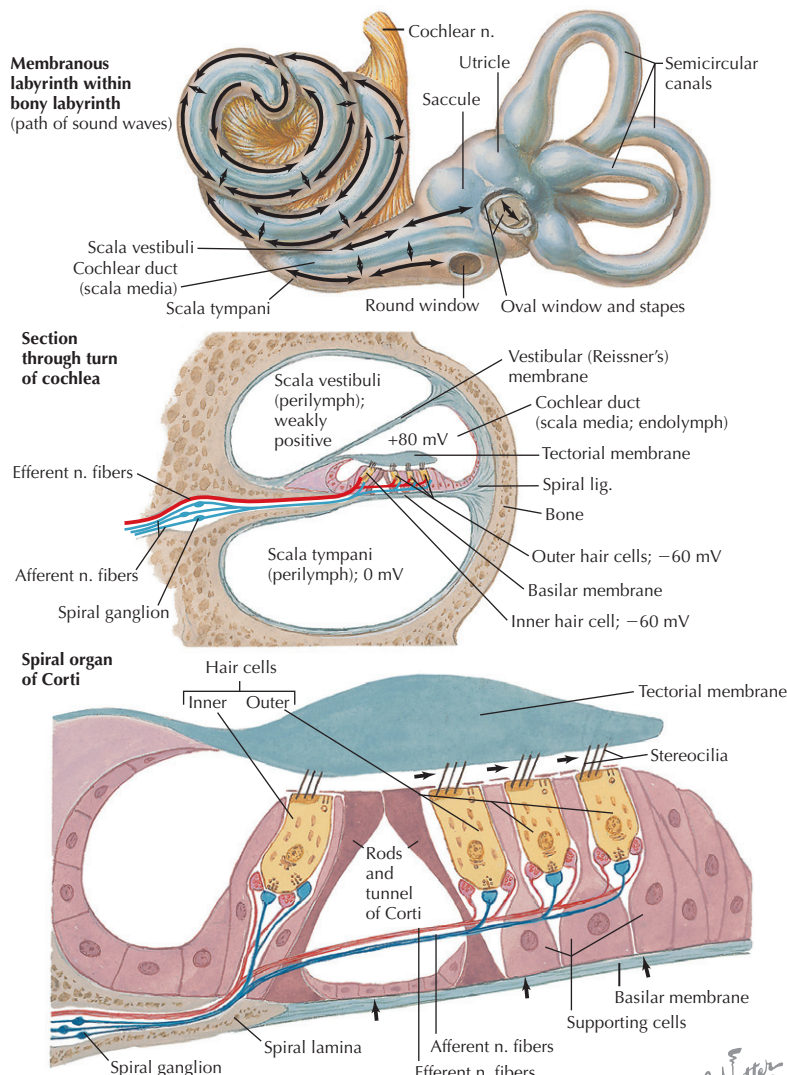
# 3 Cranial Nerves

## CRANIAL NERVE VII: FACIAL NERVE CONTINUED



## CRANIAL NERVE VIII: VESTIBULOCOCHLEAR NERVE

Functional Column	Origin of Fibers	Termination of Fibers	Summary	Comment
SSA	Organ of Corti Cristae of semicircular canals Maculae of utricle and saccule	Cochlear and vestibular nuclei	SSA fibers travel from the various vestibulocochlear receptors to their respective nuclei in the brainstem	Vestibulocochlear and facial nn. both enter the internal acoustic meatus and can be affected by tumors in the region

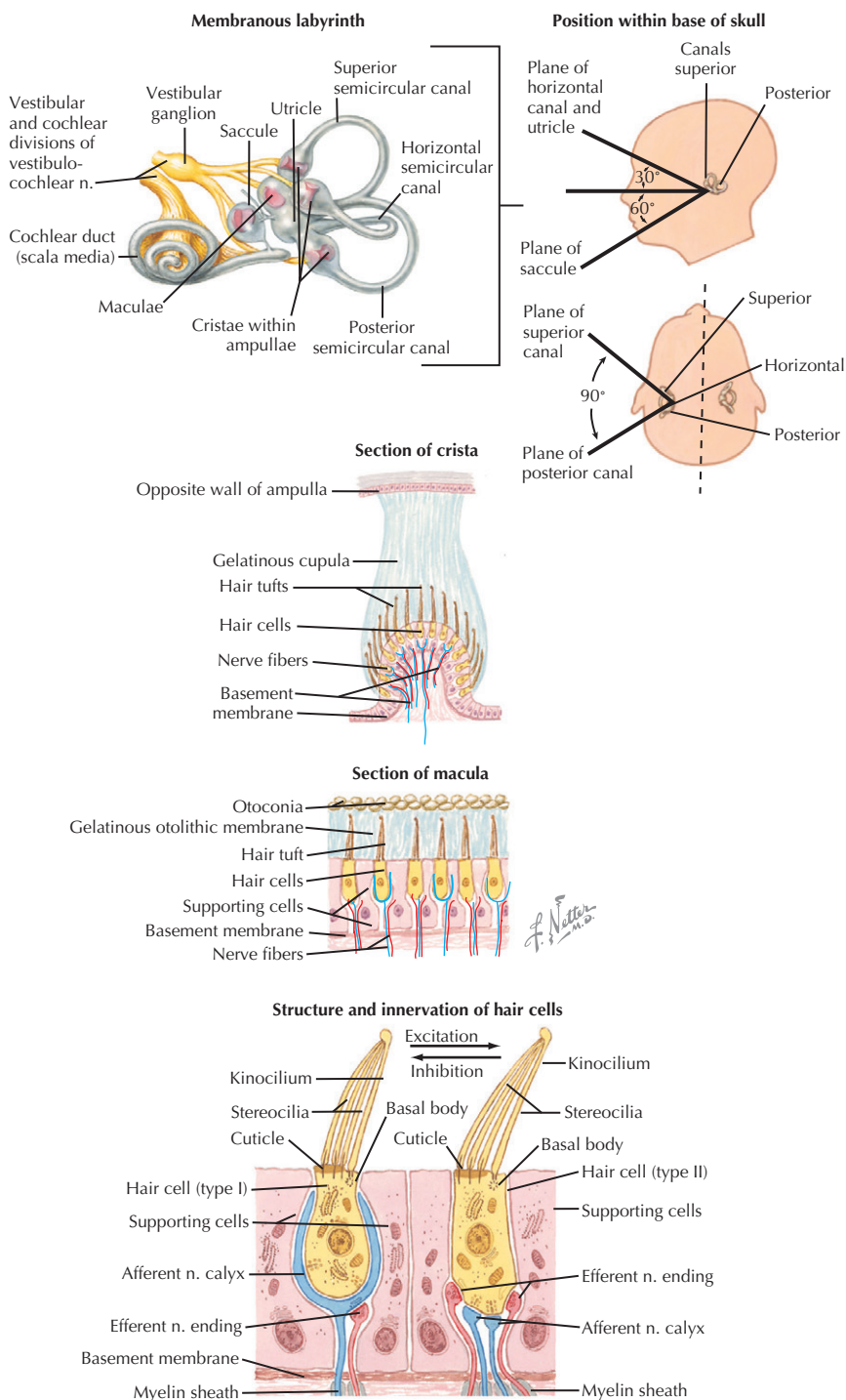


As basilar membrane moves up, hairs are deflected outward, causing depolarization of hair cells and increased firing of afferent nerve fibers

*F. Netter M.D.*

# 3 Cranial Nerves

## CRANIAL NERVE VIII: VESTIBULOCOCHLEAR NERVE *CONTINUED*



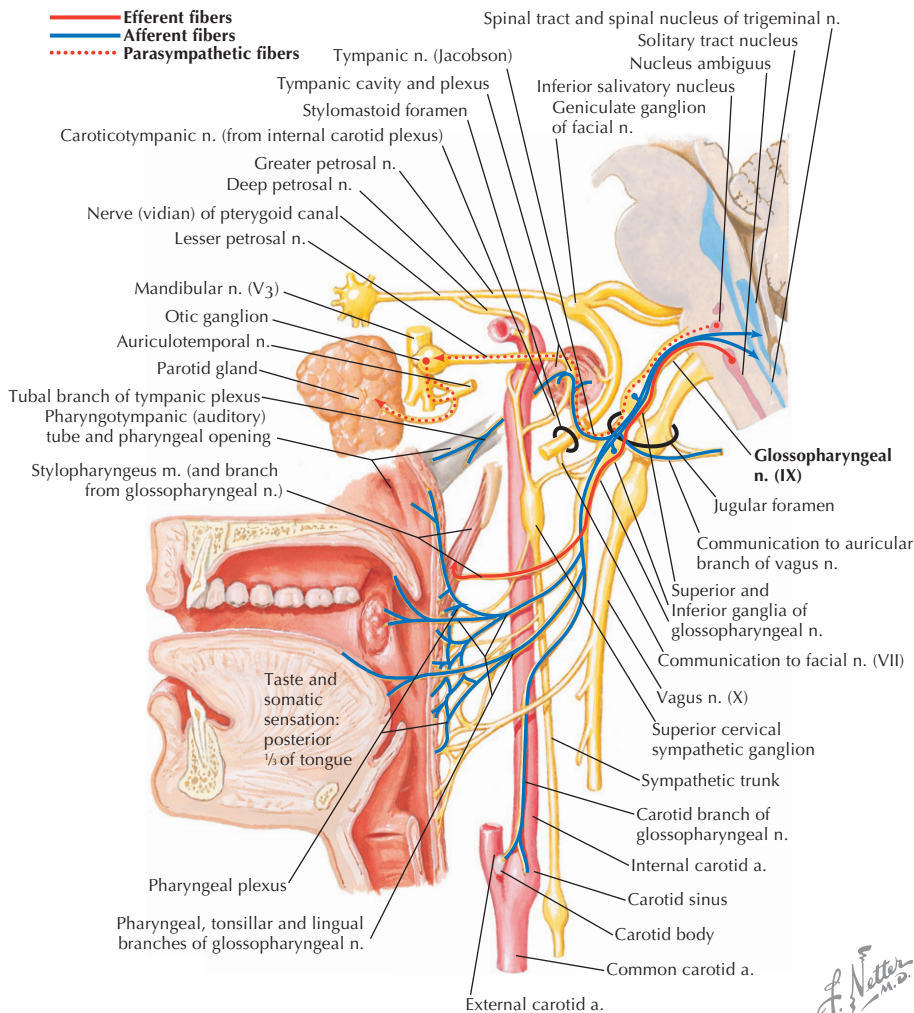
# Cranial Nerves

## CRANIAL NERVE IX: GLOSSOPHARYNGEAL NERVE

Functional Column	Origin of Fibers	Termination of Fibers	Summary	Comment
GSA	Afferent fibers begin in the various receptors of the skin of the external ear and the posterior 1/3 of the tongue	Pain and temperature fibers terminate in the spinal nucleus of V	GSA fibers are responsible for providing sensory innervation to a small portion of the external ear and posterior 1/3 of the tongue GSA fibers of the glossopharyngeal n. utilize the trigeminothalamic lemniscus to carry their sensory impulses to consciousness	Nerve cell bodies for the primary fibers are located in the superior ganglion of IX
SVA	Afferent fibers begin in the taste receptors of the posterior 1/3 of the tongue	Primary afferent fibers travel in the tractus solitarius and terminate in the nucleus solitarius	SVA fibers are responsible for carrying the taste fibers from the circumvallate papillae and the taste buds on the posterior 1/3 of the tongue	Nerve cell bodies for the primary fibers are located in the inferior ganglion of IX
GVA	Afferent fibers begin in the various receptors of the mucous membranes of the nasopharynx, oropharynx, middle ear, carotid body, and carotid sinus	Primary afferent fibers travel in the tractus solitarius and terminate in the nucleus solitarius	GVA fibers utilize the same pathway as for the SVA fibers	The nerve cell bodies for the primary fibers are located in the inferior ganglion of IX GVA fibers are predominantly the sensory portion of the pharyngeal plexus
GVE	Preganglionic parasympathetic fibers begin in the inferior salivatory nucleus	Postganglionic parasympathetic fibers innervate parotid gland	The GVE fibers are responsible for providing the parasympathetic innervation to the parotid gland	GVE fibers utilize 1 ganglion: • Otic
SVE	Begins in the nucleus ambiguus	Innervates the stylopharyngeus m.	SVE fibers are responsible for innervating the muscles of the 3rd pharyngeal arch	Stylopharyngeus is the only muscle innervated by the glossopharyngeal n.

# 3 Cranial Nerves

## CRANIAL NERVE IX: GLOSSOPHARYNGEAL NERVE *CONTINUED*



*F. Netter M.D.*



# Cranial Nerves

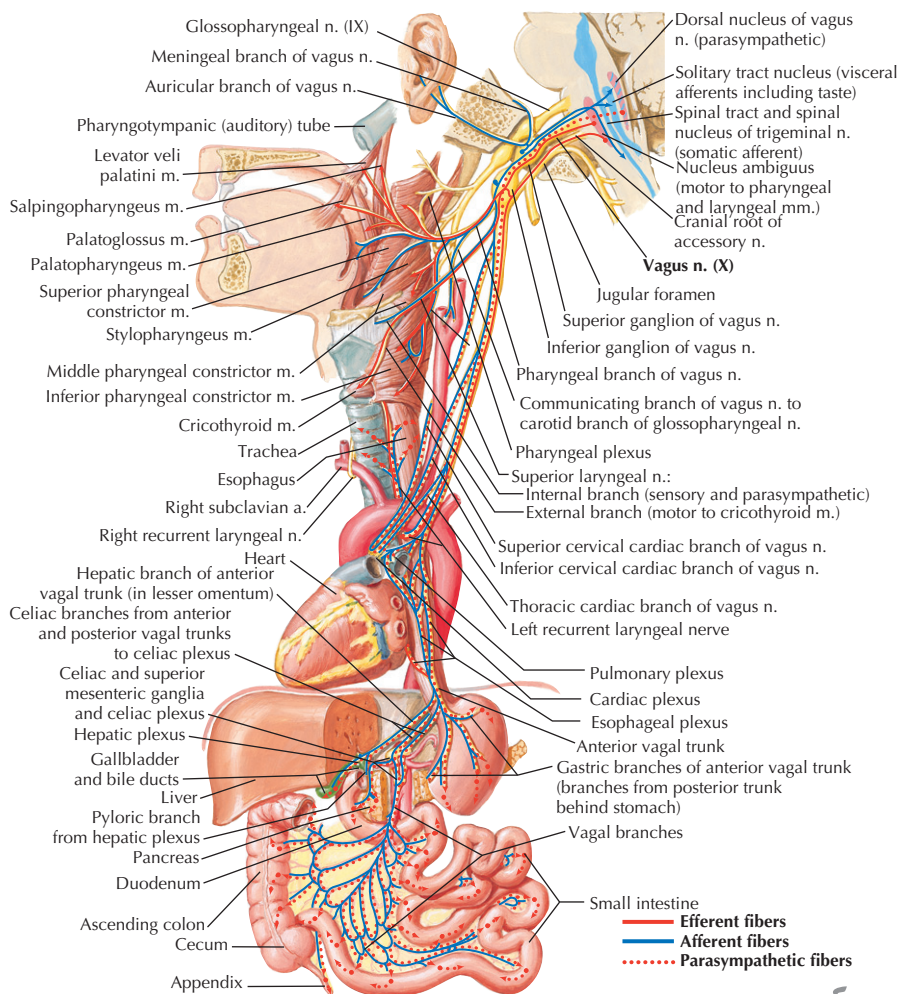
## CRANIAL NERVE X: VAGUS NERVE

Functional Column	Origin of Fibers	Termination of Fibers	Summary	Comment
GSA	Afferent fibers begin in the various receptors on a small part of the skin of the external ear	Pain and temperature fibers terminate in the spinal nucleus of V	The GSA fibers are responsible for providing sensory innervation to a very small portion of the external ear The GSA fibers of the glossopharyngeal n. utilize the trigeminothalamic lemniscus to carry their sensory impulses to consciousness	The nerve cell bodies for the primary fibers are located in the superior ganglion of X
SVA	Afferent fibers begin in the taste receptors of the epiglottic region and are scattered on the palate	Primary afferent fibers travel in the tractus solitarius and terminate in the nucleus solitarius	The SVA fibers are responsible for carrying the taste fibers from the epiglottic region and are scattered on the palate	The nerve cell bodies for the primary fibers are located in the inferior ganglion of X
GVA	Afferent fibers begin in the various receptors of the mucous membranes of the laryngopharynx, larynx, thorax, and abdomen	Primary afferent fibers travel in the tractus solitarius and terminate in the nucleus solitarius	The GVA fibers utilize the same pathway as for the SVA fibers	The nerve cell bodies for the primary fibers are located in the inferior ganglion of X
GVE	Preganglionic parasympathetic fibers begin in the dorsal motor nucleus of the vagus n.	Postganglionic parasympathetic fibers innervate thoracic and abdominal viscera	The GVE fibers are responsible for providing the parasympathetic innervation to the thoracic and abdominal viscera	The GVE fibers utilize: • Intramural ganglia
SVE	Begins in the nucleus ambiguus	Innervates the muscles of the pharynx (via the pharyngeal plexus) and the larynx	The SVE fibers are responsible for innervating the muscles of the 4th pharyngeal arch	The SVE fibers are the motor component to the pharyngeal plexus (muscles of pharynx) Lesions of the vagus paralyze the muscles of the larynx on the affected side



# 3 Cranial Nerves

## CRANIAL NERVE X: VAGUS NERVE *CONTINUED*

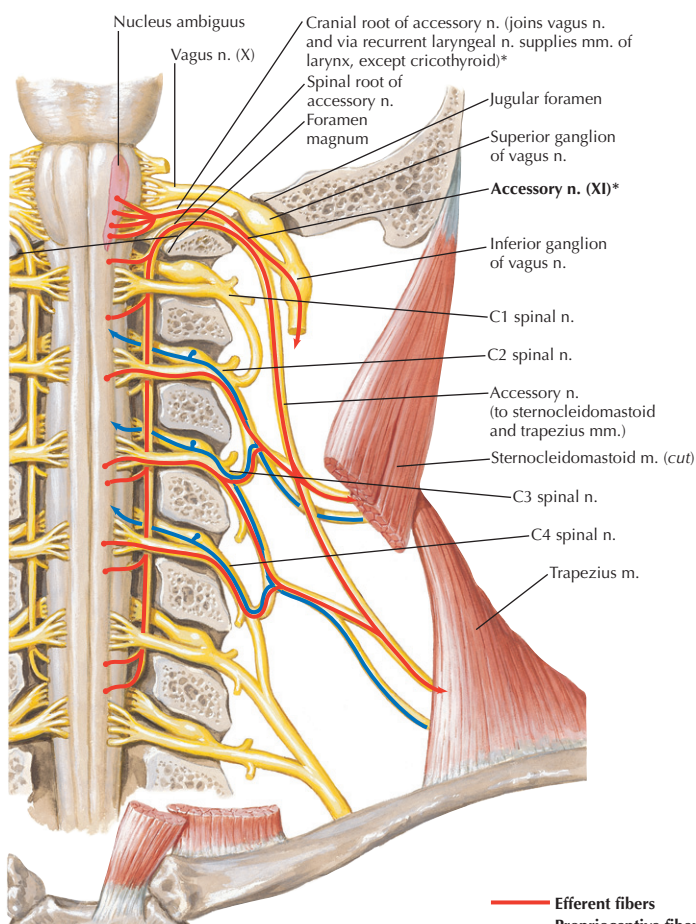


*F. Netter M.D.*

# Cranial Nerves

## CRANIAL NERVE XI: SPINAL ACCESSORY NERVE

Functional Column	Origin of Fibers	Termination of Fibers	Summary	Comment
SVE	Cranial part: Begins in the nucleus ambiguus Spinal part: Begins in the upper cervical levels of the spinal cord	Cranial part: Innervates the muscles of the pharynx (via the pharyngeal plexus) Spinal part: Innervates the trapezius and sternocleidomastoid mm.	These SVE fibers of the cranial part travel with the vagus n. and arise from the same nucleus (nucleus ambiguus) and often are considered to be the same	The cranial and spinal parts separate so the cranial part can join the pharyngeal plexus and the spinal part can innervate the sternocleidomastoid m. and pass through the posterior triangle until reaching the trapezius m.



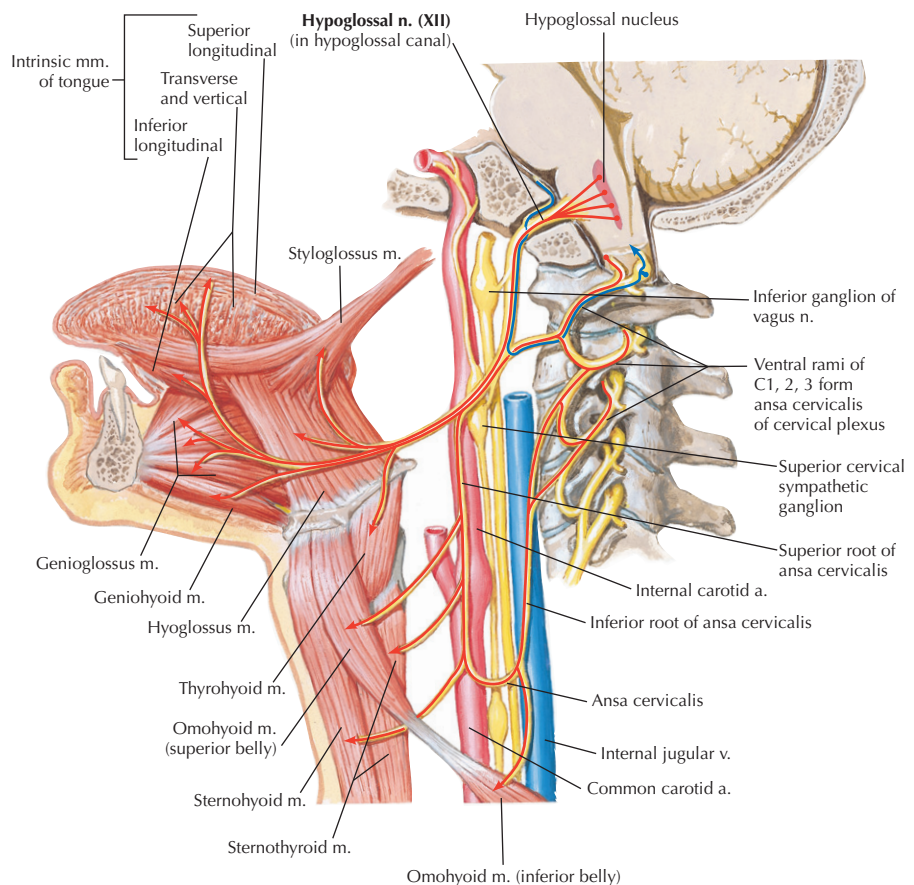
\*Recent evidence suggests that the accessory nerve lacks a cranial root and has no connection to the vagus nerve. Verification of this finding awaits further investigation.

*F. Netter M.D.*

### 3 Cranial Nerves

#### CRANIAL NERVE XII: HYPOGLOSSAL NERVE

Functional Column	Origin of Fibers	Termination of Fibers	Summary	Comment
GSE	Begins in the hypoglossal nucleus	Innervates the genioglossus, hyoglossus, and styloglossus mm. and the intrinsic mm. of the tongue	The GSE fibers are responsible for innervating the major portion of the tongue musculature	Lesions of the hypoglossal n. cause the tongue to deviate to the side of the lesion on protrusion



— Efferent fibers  
— Afferent fibers

*F. Netter M.D.*

## Clinical Correlate

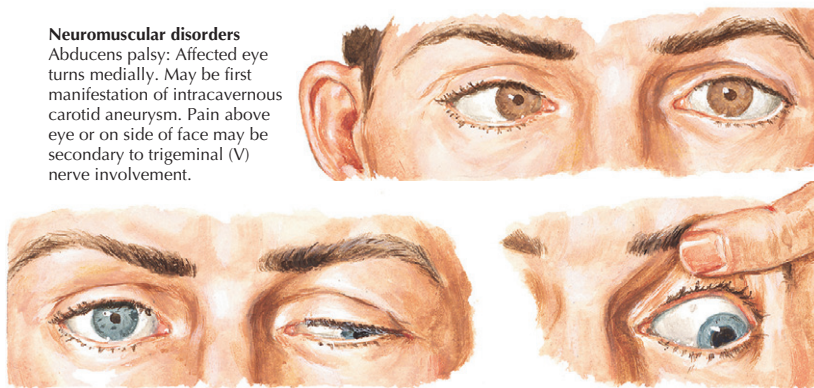
### CEREBRAL ANEURYSMS CAUSING OPHTHALMOPLEGIA

Because of the close proximity of the oculomotor, trochlear, and abducens nerves to blood vessels supplying the brain, aneurysms along these vessels may lead to a paralysis of the muscles that they innervate

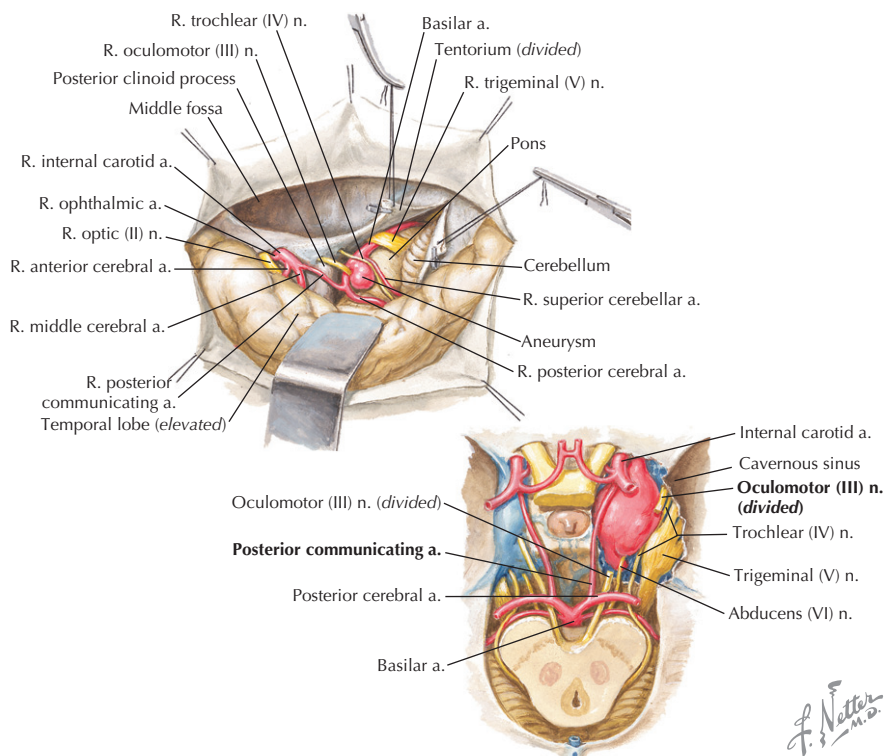
Commonly affected vessels include the basilar, posterior cerebral, and posterior communicating arteries

#### Neuromuscular disorders

**Abducens palsy:** Affected eye turns medially. May be first manifestation of intracavernous carotid aneurysm. Pain above eye or on side of face may be secondary to trigeminal (V) nerve involvement.



**Oculomotor palsy:** Ptosis, eye turns laterally and inferiorly, pupil dilated; common finding with cerebral aneurysms, especially carotid-posterior communicating aneurysms





### 3 Clinical Correlate

#### LESIONS AFFECTING THE VOICE

The vagus nerve provides all of the motor and sensory innervation to the larynx

The superior laryngeal nerve divides into the internal laryngeal (sensory) and external laryngeal (motor to the cricothyroid)

The recurrent laryngeal provides sensory and motor innervation to the remainder of the muscles of the larynx

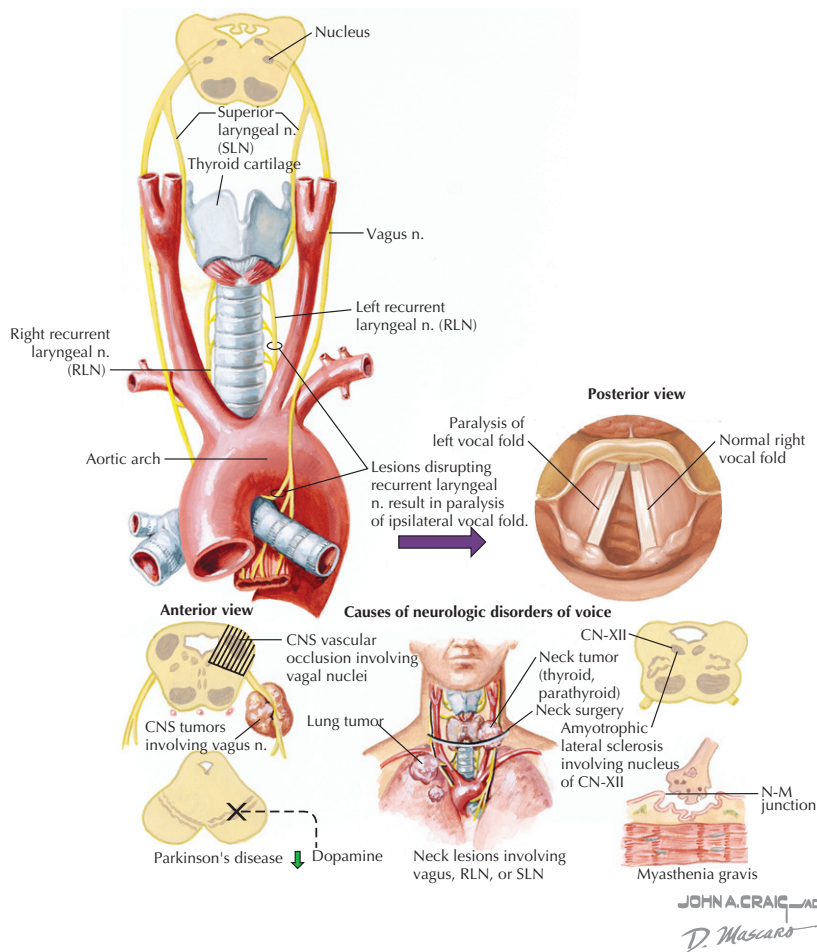
Lesions of the recurrent laryngeal nerve result in a paralysis of the ipsilateral vocal fold

This problem usually manifests clinically as hoarseness with an ineffective cough

Common causes include:

- Thyroid tumors
- Neck tumors
- Cerebrovascular accidents
- Lung tumors
- Surgery
- Thyroiditis

The voice also may be affected in Parkinson's disease and myasthenia gravis



## Clinical Correlate

### LESIONS AFFECTING THE SPINAL ACCESSORY NERVE

The spinal accessory nerve provides motor innervation to the sternocleidomastoid and trapezius muscles

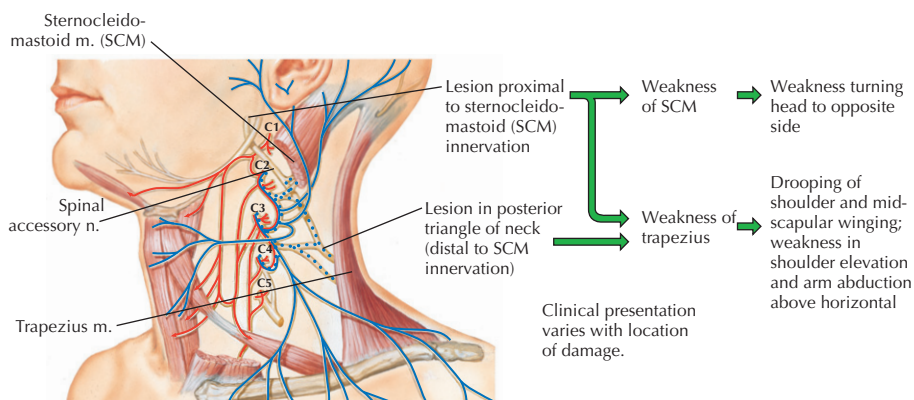
The spinal accessory nerve courses close to the superficial cervical lymph nodes

- This course makes it vulnerable to damage during biopsy or radical neck dissection in the posterior triangle

- Damage to the spinal accessory nerve also may result from a carotid endarterectomy

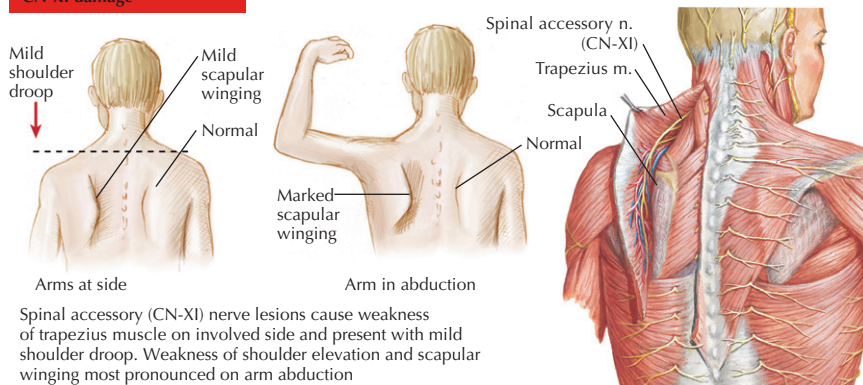
In lesions located in the posterior triangle, the sternocleidomastoid muscle is unaffected, but the trapezius muscle is deinnervated

- The shoulder droops, with mild winging of the scapula
- Abduction of the arm also is affected when patient attempts to raise it above the horizontal plane



### Comparison of clinical findings in CN-XI and long thoracic nerve damage

#### CN-XI damage



*F. Netter M.D.*  
with  
*Savaman*  
CMI



### 3 Clinical Correlate

#### LESIONS AFFECTING THE HYPOGLOSSAL NERVE

The hypoglossal nerve provides motor innervation to a majority of the muscles of the tongue, including:

- Genioglossus
- Hyoglossus
- Styloglossus

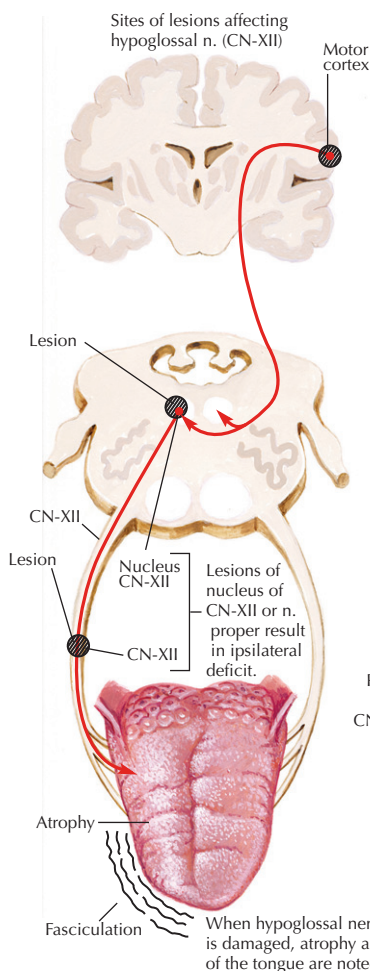
Protrusion of the tongue is accomplished by the bilateral actions of the genioglossus muscles

Paralysis of a genioglossus muscle causes the protruded tongue to deviate to the paralyzed side

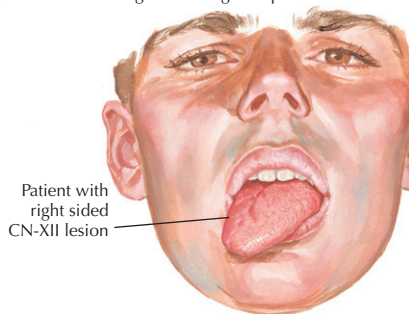
Paralysis of the hypoglossal nerve can be caused by:

- Tumors
- Neck trauma
- Radiation therapy

A similar paralysis can be caused by a stroke affecting the upper motor neurons on the side contralateral to the paralyzed muscles, owing to the crossing fibers of the upper motor neurons



Subtle weakness of tongue may be tested by asking patient to press tongue against cheek (shown) or against a tongue depressor.



Patient with right sided CN-XII lesion

If hypoglossal nerve is affected on one side, the tongue often deviates toward the side of the lesion on protrusion (due to imbalance of genioglossus contraction).

*J. Netter M.D.*  
JOHN A. CRAIG, MD  
with E. Hatton

## CHAPTER 4

# THE NECK

Overview and Topographic Anatomy	108
Triangles of the Neck	111
Anterior Triangle	113
Posterior Triangle	120
Suboccipital Triangle	122
Visceral Contents	123
Root of the Neck	125
Muscles	127
Vascular Supply of the Neck	132
Nerve Supply of the Neck	139
Clinical Correlates	149

## 4 Overview and Topographic Anatomy

### GENERAL INFORMATION

The *neck* is the area between the base of the skull and inferior border of the mandible and the superior thoracic aperture

The anterior portion of the neck contains the major visceral structures between the head and the thorax:

- Pharynx
- Larynx
- Trachea
- Esophagus
- Thyroid and parathyroid glands

For descriptive purposes, the neck is divided into 2 triangles:

- Anterior triangle
- Posterior triangle

Skin is the most superficial structure covering the neck

### FASCIA

The neck is surrounded by 2 main layers of cervical fascia that can be further subdivided:

- Superficial fascia
- Deep fascia
- Superficial layer of deep cervical fascia (investing)
- Middle layer of deep fascia (includes muscular and visceral parts such as the pretracheal)
- Deep layer of deep fascia (includes prevertebral and alar)
- Carotid sheath

Superficial fascia is deep to the skin and surrounds the platysma muscle

Sensory branches to the neck are located in the superficial fascia

Deep to the superficial fascia is the investing layer of deep cervical fascia

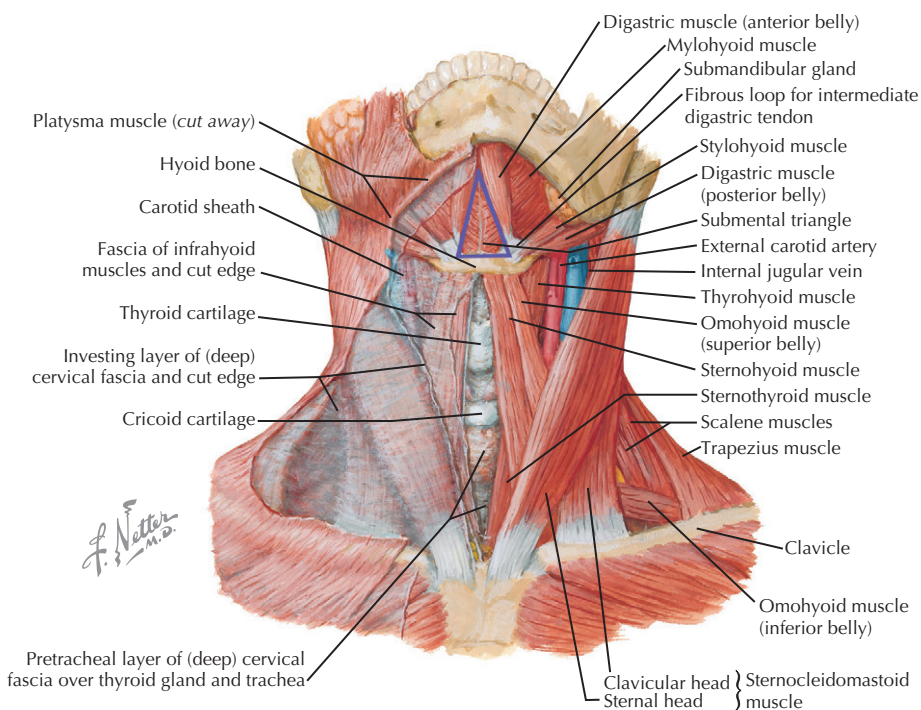
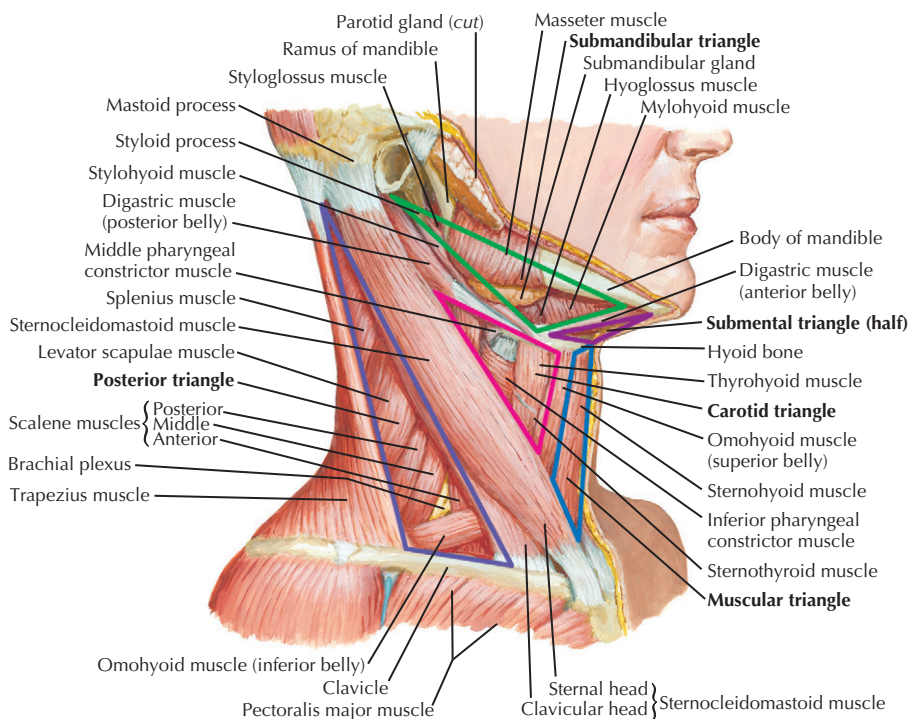
The superficial (or investing) layer of deep cervical fascia attaches posteriorly along the midline and passes anteriorly to surround the entire neck

The superficial (or investing) layer of deep cervical fascia surrounds these muscles:

- Trapezius
- Sternocleidomastoid

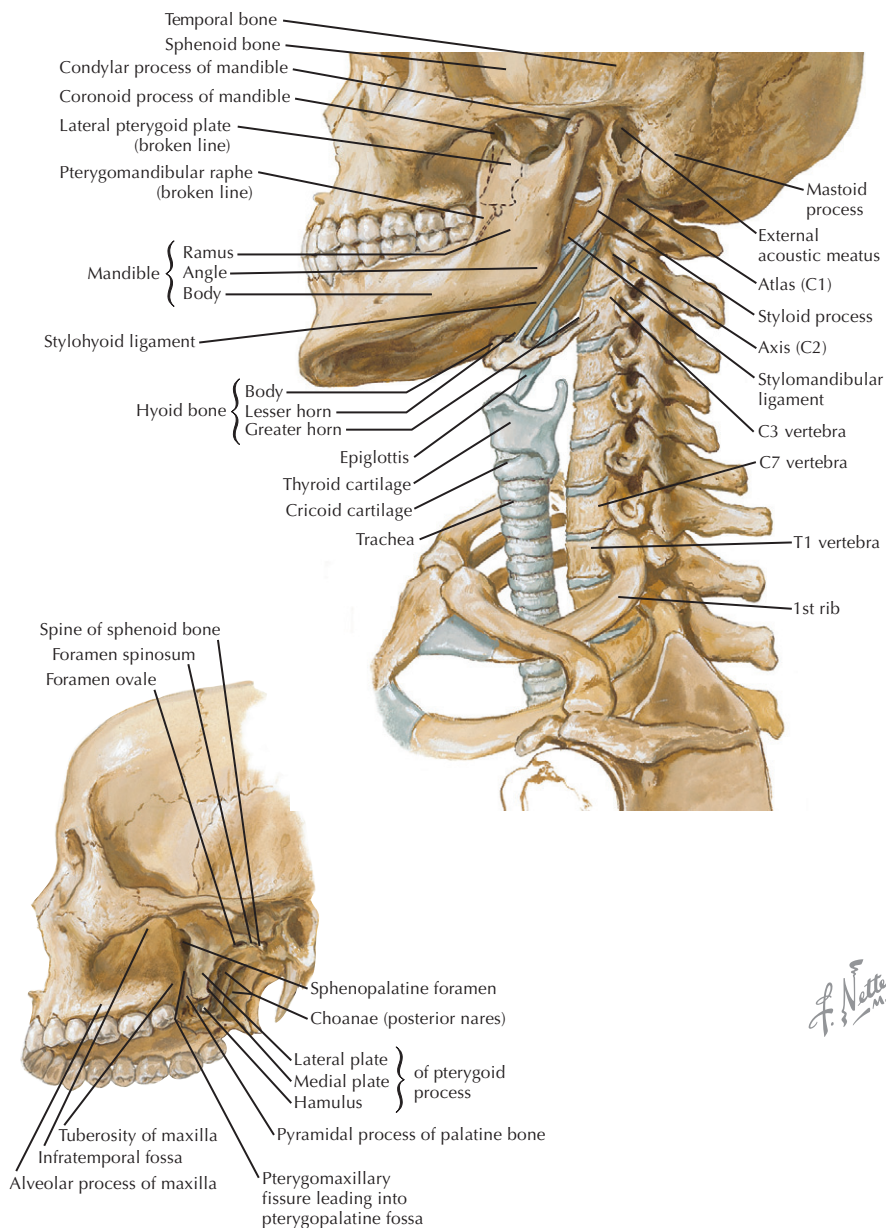
# Overview and Topographic Anatomy

## GENERAL INFORMATION CONTINUED



## 4 Overview and Topographic Anatomy

### GENERAL INFORMATION *CONTINUED*



*F. Netter M.D.*

# Triangles of the Neck

## ANTERIOR TRIANGLE

Borders of the anterior triangle:

- Anterior border of the sternocleidomastoid
- Inferior border of the mandible
- Midline of the neck

Using the hyoid as a keystone, the omohyoid and digastric muscles subdivide the anterior triangle into:

- Submandibular triangle
- Carotid triangle
- Muscular triangle
- Submental triangle

All of the triangles within the anterior triangle are paired except for the submental triangle, which spans the right and the left sides of the neck

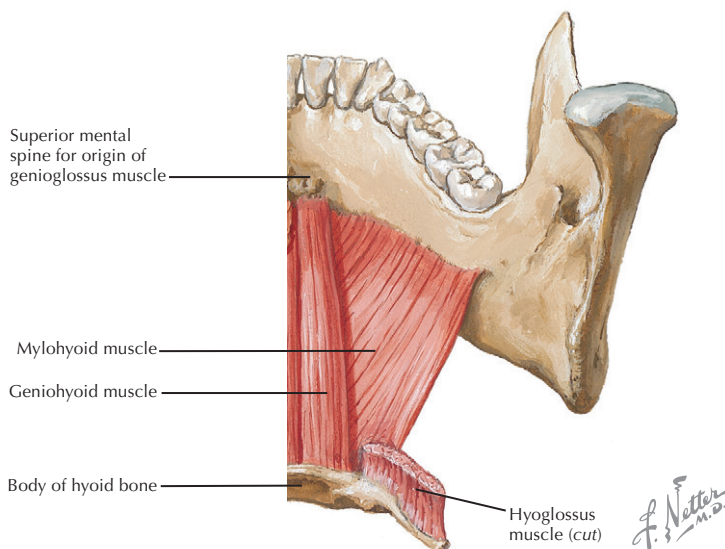
Hyoid bone divides the anterior triangle into 2 areas: suprahyoid and infrahyoid regions

The suprahyoid region contains 4 muscles:

- Mylohyoid
- Digastric
- Stylohyoid
- Geniohyoid

The infrahyoid region contains 4 muscles commonly called strap muscles:

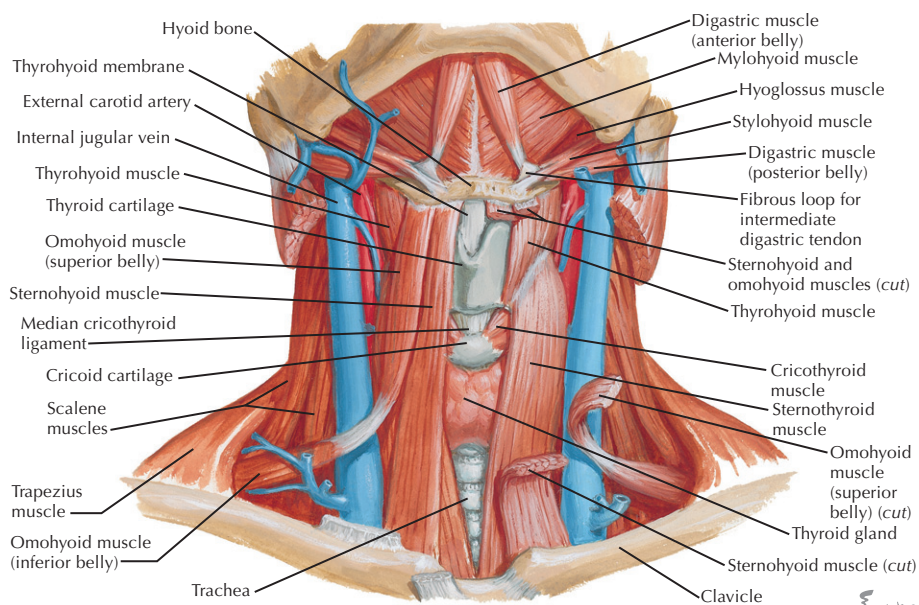
- Omohyoid
- Sternohyoid
- Sternothyroid
- Thyrohyoid





## 4 Triangles of the Neck

### ANTERIOR TRIANGLE CONTINUED



# Anterior Triangle

## SUBMANDIBULAR TRIANGLE

Often called the digastric triangle

Borders of the submandibular triangle:

- Inferior border of the mandible
- Posterior digastric
- Anterior digastric

Floor of the triangle is composed of the:

- Hyoglossus
- Mylohyoid
- Middle constrictor

Roof is made of the:

- Skin
- Superficial fascia with platysma
- Deep cervical fascia

Submandibular triangle is paired

Lesser's triangle is a small subdivision of the submandibular triangle, which aids in identifying the lingual artery (especially for ligation)

Boundaries of Lesser's triangle:

- Hypoglossal nerve
- Anterior digastric
- Posterior digastric

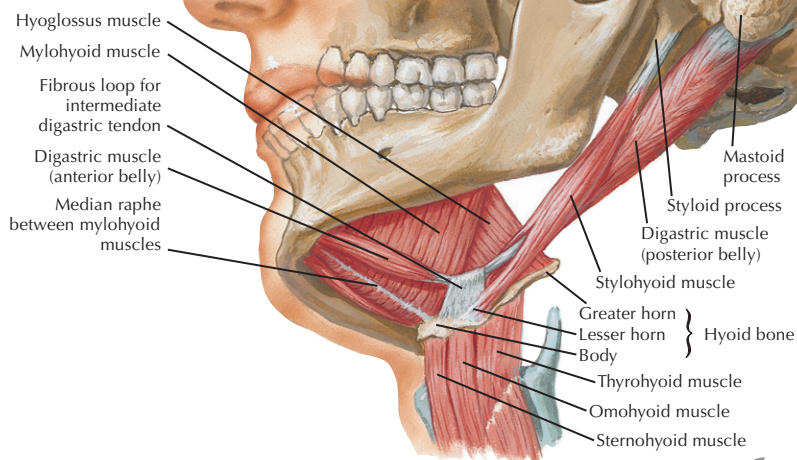
CONTENTS OF THE SUBMANDIBULAR TRIANGLE

Arteries	Veins	Nerves	Structures
Facial Submental Lingual (small portion)	Facial Submental Lingual (small portion)	Mylohyoid Hypoglossal	Submandibular gland Submandibular lymph nodes Inferior portion of the parotid gland

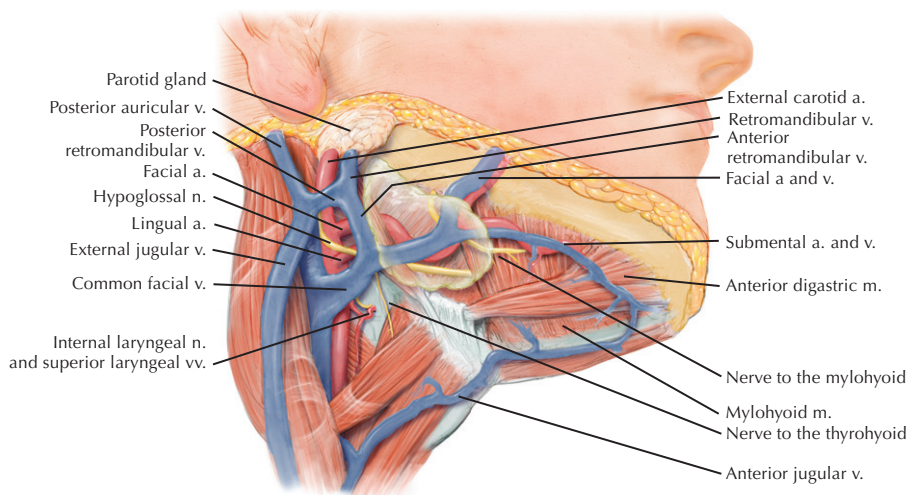
# 4 Anterior Triangle

## SUBMANDIBULAR TRIANGLE CONTINUED

Lateral, slightly inferior view



*J. Netter M.D.*



*SWIFT*

# Anterior Triangle

## CAROTID TRIANGLE

Named because parts of all three carotid arteries are located within it

Borders of the carotid triangle:

- Anterior border of the sternocleidomastoid
- Posterior digastric
- Superior omohyoid

Floor of the triangle is composed of the:

- Hyoglossus
- Thyrohyoid
- Middle constrictor
- Inferior constrictor

Roof is made of the:

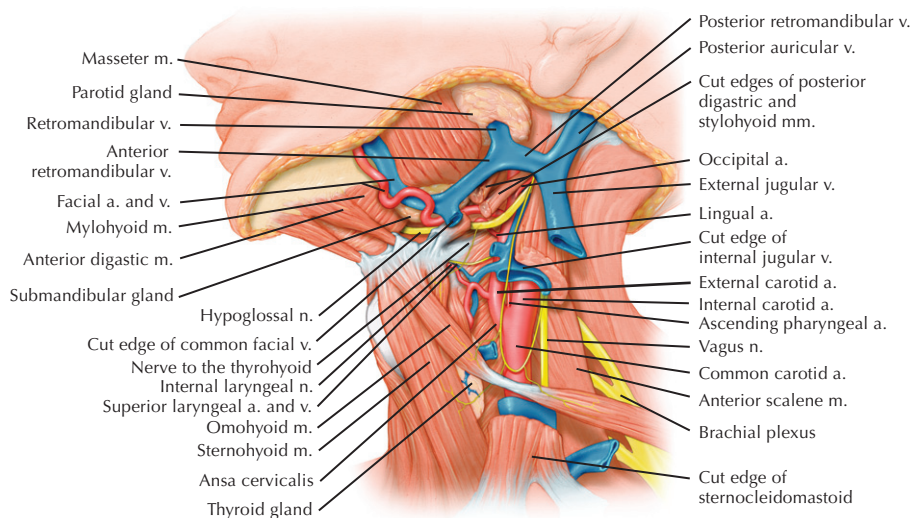
- Skin
- Superficial fascia with platysma
- Deep cervical fascia

Carotid triangle is paired

CONTENTS OF THE CAROTID TRIANGLE			
Arteries	Veins	Nerves	Structures
Common carotid (with carotid body) • Internal carotid (with carotid sinus) • External carotid <ul style="list-style-type: none"> <li>• Superior thyroid (with superior laryngeal branch)</li> <li>• Lingual</li> <li>• Facial</li> <li>• Ascending pharyngeal</li> <li>• Occipital</li> </ul>	Internal jugular Common facial Lingual Superior thyroid Middle thyroid	Vagus <ul style="list-style-type: none"> <li>• External laryngeal</li> <li>• Internal laryngeal</li> </ul> Spinal accessory (small portion) Hypoglossal Ansa cervicalis (superior limb) Sympathetic trunk	Larynx (small portion) Thyroid (small portion)

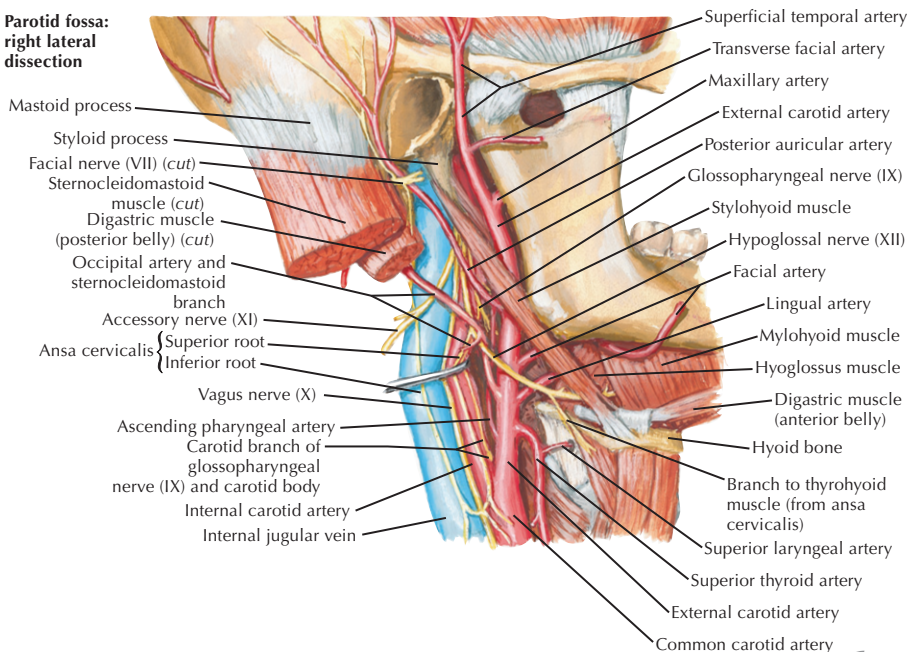
# 4 Anterior Triangle

## CAROTID TRIANGLE CONTINUED



SWIFT

### Parotid fossa: right lateral dissection



f. Netter M.D.

# Anterior Triangle

## MUSCULAR TRIANGLE

Borders of the muscular triangle:

- Anterior border of the sternocleidomastoid
- Superior omohyoid
- Midline

Floor of the triangle is composed of the:

- Sternohyoid
- Sternothyroid

Roof is made of the:

- Skin
- Superficial fascia with platysma
- Deep cervical fascia

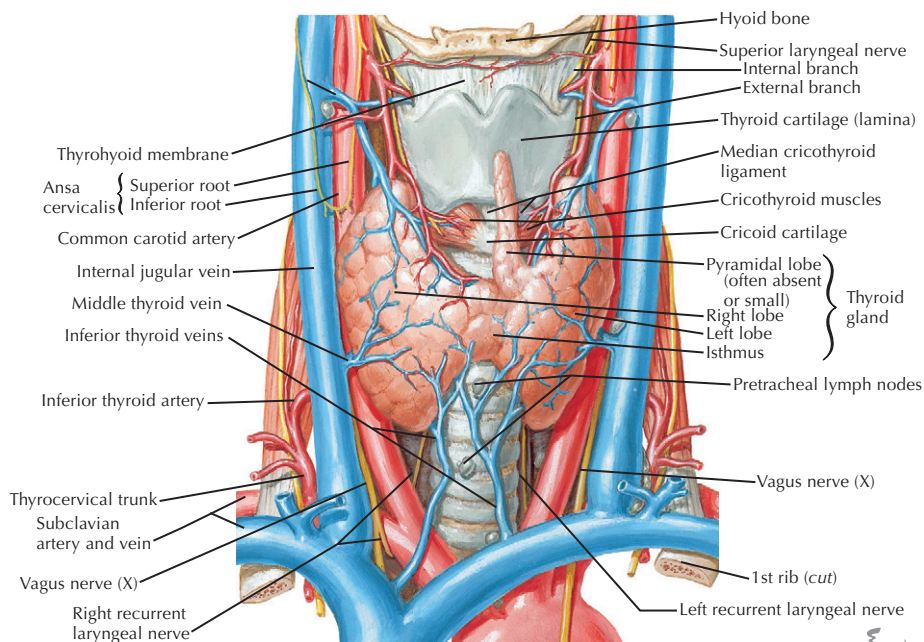
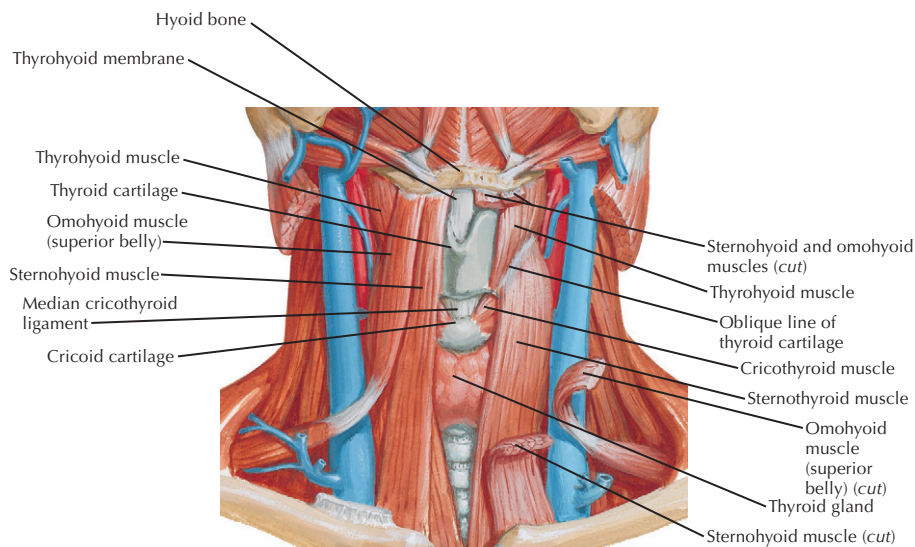
Muscular triangle is paired

CONTENTS OF THE MUSCULAR TRIANGLE			
Artery	Veins	Nerve	Structures
Superior thyroid	Inferior thyroid Anterior jugular	Ansa cervicalis	Strap muscles: <ul style="list-style-type: none"> <li>• Sternohyoid</li> <li>• Sternothyroid</li> <li>• Thyrohyoid</li> </ul> Thyroid gland Parathyroid gland Larynx Trachea Esophagus



## 4 Anterior Triangle

### MUSCULAR TRIANGLE CONTINUED



*J. Netter M.D.*

# Anterior Triangle

## SUBMENTAL TRIANGLE

Borders of the submental triangle:

- Body of hyoid
- Anterior digastric on right
- Anterior digastric on left

Floor of the triangle is composed of the:

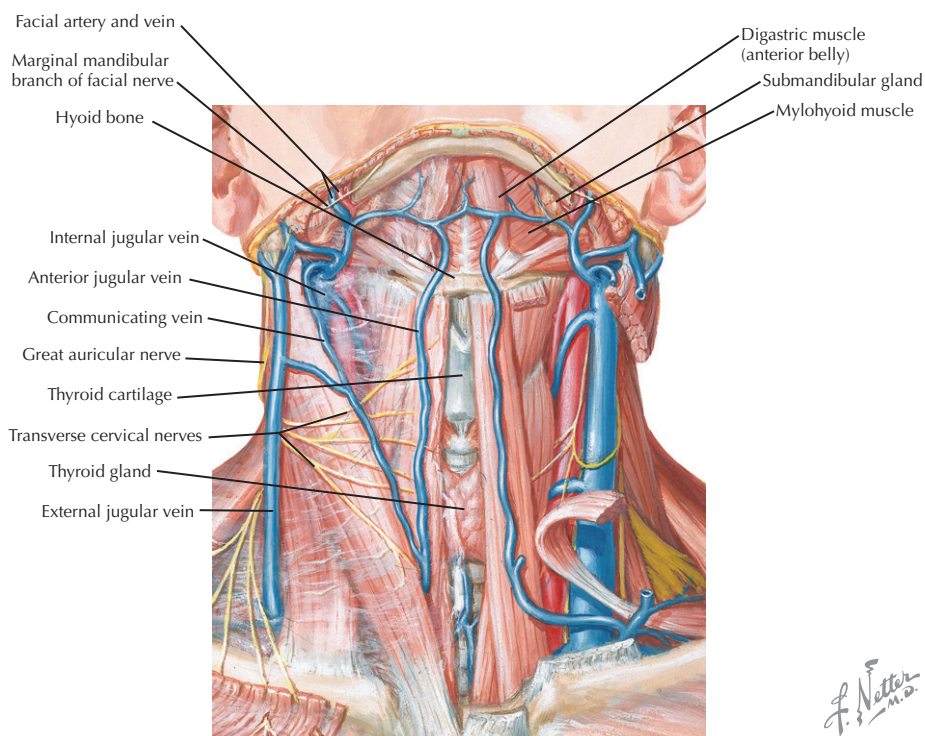
- Mylohyoid

Roof is made of the:

- Skin
- Superficial fascia with platysma
- Deep cervical fascia

Submental triangle is unpaired

CONTENTS OF THE SUBMENTAL TRIANGLE			
Artery	Vein	Nerve	Structures
	Anterior jugular		Submental lymph nodes



## 4 Posterior Triangle

### GENERAL INFORMATION

Borders of the posterior triangle:

- Posterior border of the sternocleidomastoid
- Middle third of the clavicle
- Anterior border of the trapezius

Located on the lateral side of the neck and spirals around the neck

Is subdivided into 2 triangles by the omohyoid:

- Omoclavicular (also called the supraclavicular triangle)
- Occipital

Roof of the posterior triangle includes:

- Skin
- Superficial fascia with platysma
- Superficial (investing) layer of deep cervical fascia

Floor of the posterior triangle includes\*:

- Semispinalis capitis
- Splenius capitis
- Levator scapulae
- Posterior scalene
- Middle scalene
- Anterior scalene

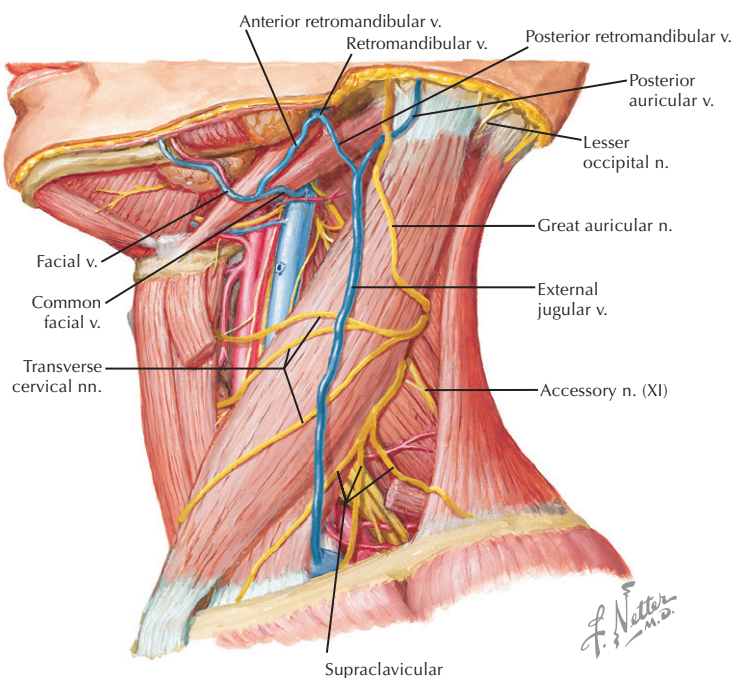
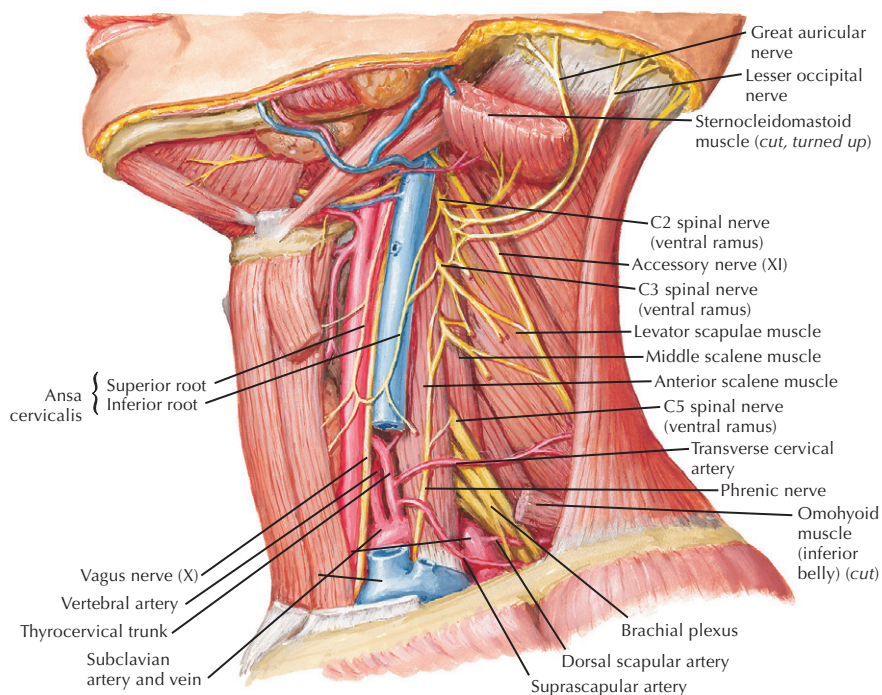
Posterior triangle is paired

CONTENTS OF THE POSTERIOR TRIANGLE		
Arteries	Veins	Nerves
3rd part of the subclavian Occipital Suprascapular Transverse cervical Dorsal scapular (usually)	External jugular (and branches) Occipital Suprascapular Transverse cervical	Cervical plexus (sensory branches): <ul style="list-style-type: none"> <li>• Lesser occipital</li> <li>• Transverse cervical</li> <li>• Great auricular</li> <li>• Supraclavicular</li> </ul> Spinal accessory Dorsal scapular Long thoracic Suprascapular Rami and trunks of brachial plexus <ul style="list-style-type: none"> <li>• Dorsal scapular</li> <li>• Long thoracic</li> <li>• Suprascapular</li> </ul> Phrenic

\*These muscles are covered by the prevertebral layer of deep cervical fascia.

# Posterior Triangle

## GENERAL INFORMATION CONTINUED





## 4 Suboccipital Triangle

### GENERAL INFORMATION

Borders of the suboccipital triangle:

- Obliquus capitis superior
- Obliquus capitis inferior
- Rectus capitis posterior major

Roof of the suboccipital triangle includes:

- Dense connective tissue

Floor of the suboccipital triangle includes:

- Posterior atlanto-occipital membrane
- Posterior arch of the atlas

Suboccipital triangle is paired

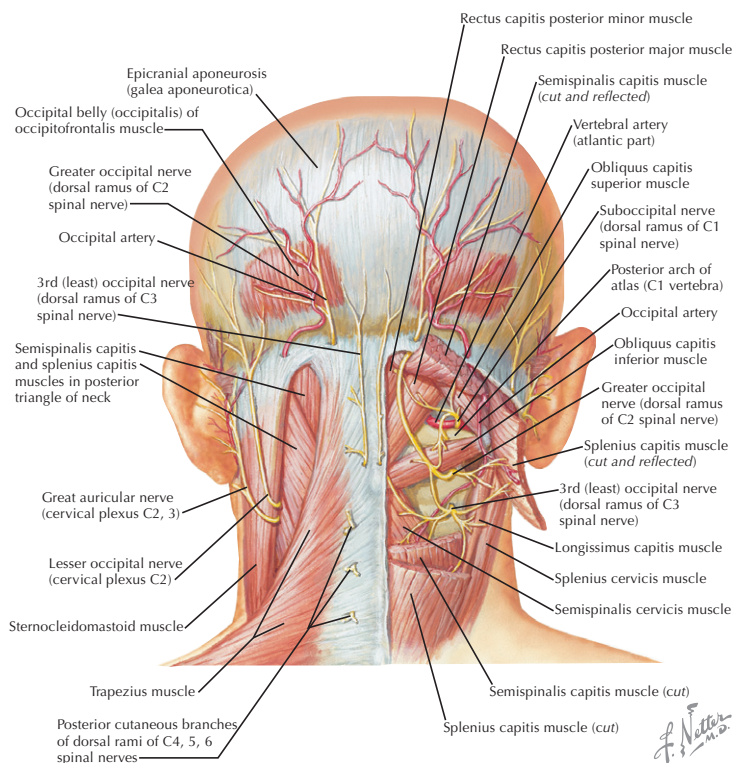
### VERTEBRAL ARTERIES

These vessels enter the foramen transversarium of the 6th cervical vertebra, emerging above the 1st cervical vertebra to enter the suboccipital triangle

They curve medially to lie in a groove on the posterior arch of the atlas

Pass through the posterior atlanto-occipital membrane to enter the vertebral canal

CONTENTS OF THE SUBOCCIPITAL TRIANGLE			
Artery	Vein	Nerves	Structures
Vertebral	Vertebral	Greater occipital Suboccipital	<b>Muscles:</b> <ul style="list-style-type: none"> <li>• Rectus capitis posterior major</li> <li>• Rectus capitis posterior minor</li> <li>• Obliquus capitis superior</li> <li>• Obliquus capitis inferior</li> </ul>



## Visceral Contents

### THYROID GLAND

Highly vascular organ located on the anterior and lateral surfaces of the neck

Formed by a right and a left lobe connected in the midline by an isthmus

Lies roughly at a level between the 5th cervical and the 1st thoracic vertebrae

The isthmus crosses at the 2nd and 3rd tracheal rings

A pyramidal lobe often arises from the isthmus and extends superiorly

Arterial supply arises from the superior and inferior thyroid arteries, with the major portion from the inferior thyroid artery

A thyroidea ima vessel may supply the thyroid gland and arises from the brachiocephalic artery or as a direct branch from the aorta

Venous drainage forms from a plexus on the surface of the thyroid gland that drains into the superior, middle, and inferior thyroid veins

Microscopically, the thyroid is made of thyroid epithelial cells, which secrete thyroid hormones (thyroxine and triiodothyronine), and parafollicular (C cells), which secrete calcitonin

### PARATHYROID GLANDS

Parathyroid glands normally are 4 glands located on the posterior surface of the thyroid lobes

The superior parathyroids are supplied by the superior thyroid artery and the inferior parathyroids are supplied by the inferior thyroid artery

Microscopically, their cells are organized in cords and secrete parathyroid hormone

### LARYNX

Connection between the pharynx and the trachea

Prevents foreign bodies from entering the airways

Designed for the production of sound (phonation)

Shorter in women and children

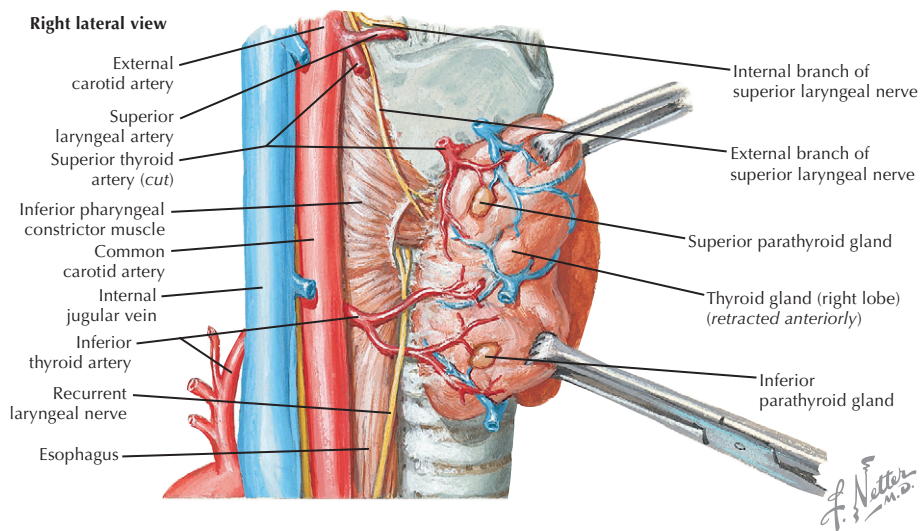
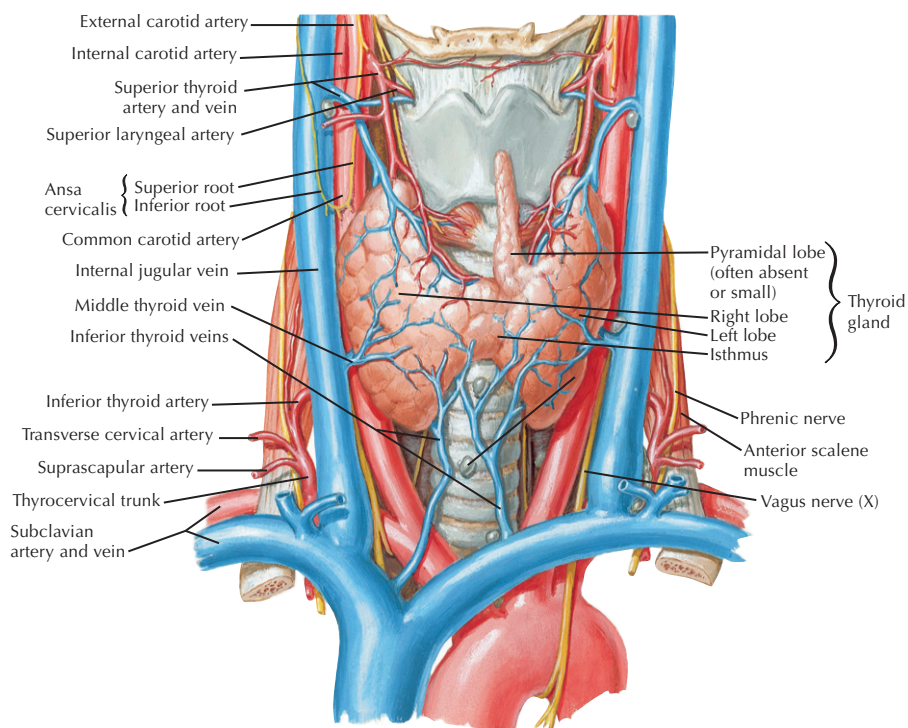
Formed by 9 cartilages: 3 paired and 3 unpaired

Located in the midline opposite the 3rd to 6th cervical vertebrae



## 4 Visceral Contents

### THYROID GLAND, PARATHYROID GLANDS, LARYNX *CONTINUED*



## Root of the Neck

### GENERAL INFORMATION

Root of the neck connects the structures of the neck with the thoracic cavity

The superior thoracic aperture is bounded by:

- Manubrium
- 1st rib and cartilage
- 1st thoracic vertebra

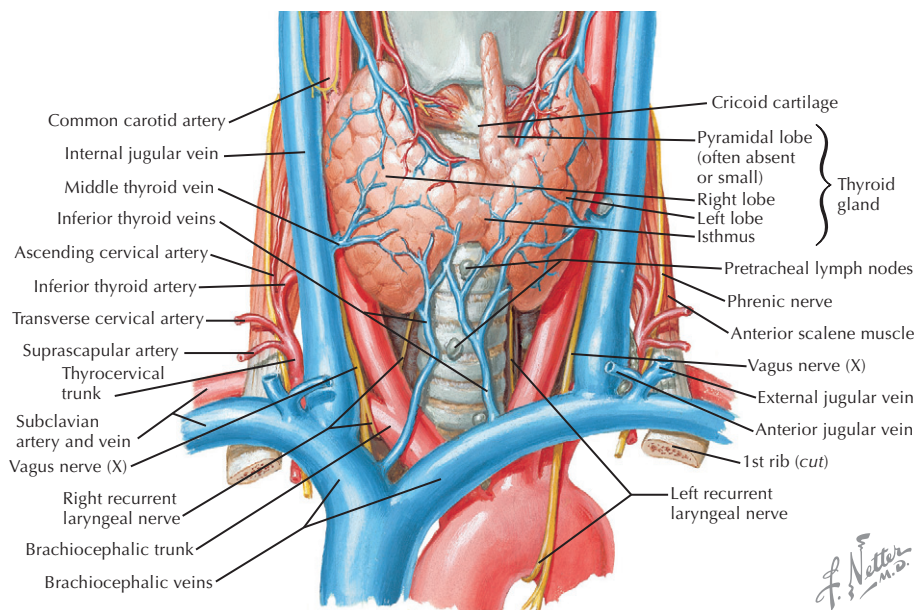
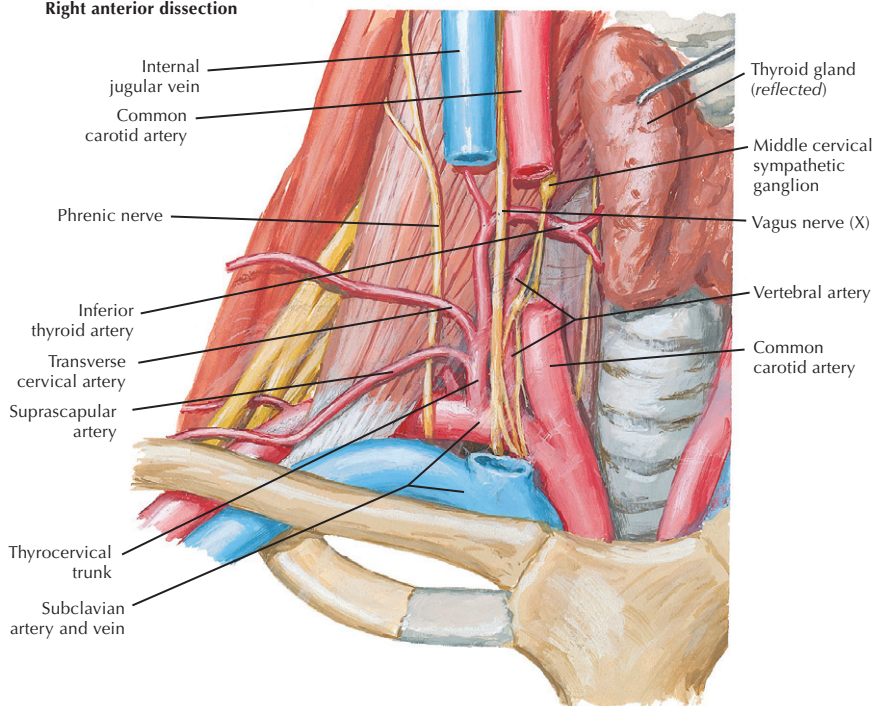
The apex of each lung extends into the root of the neck on the lateral side of the superior thoracic aperture

CONTENTS OF THE ROOT OF THE NECK			
Arteries	Veins	Nerves	Structures
Common carotid Subclavian Vertebral Transverse cervical	Internal jugular Subclavian Brachiocephalic Inferior thyroid Vertebral	Vagus Recurrent laryngeal Phrenic Sympathetic trunk Brachial plexus	Trachea Esophagus Thoracic duct Right lymphatic duct

## 4 Root of the Neck

### GENERAL INFORMATION CONTINUED

**Right anterior dissection**



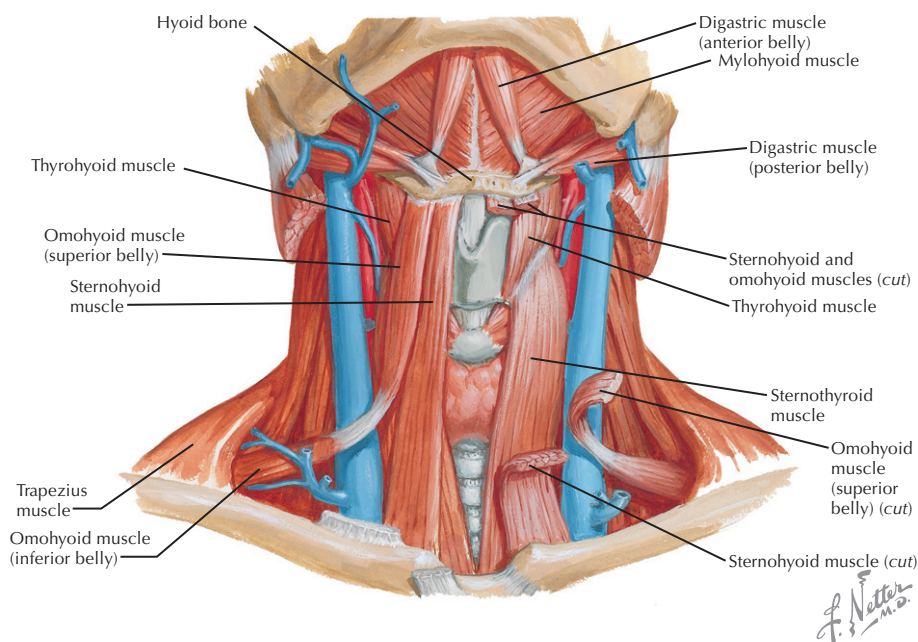
# Muscles

## MAJOR BORDERS OF THE TRIANGLES

Muscle	Origin	Insertion	Actions	Nerve Supply
Trapezius	External occipital protuberance Superior nuchal line Ligamentum nuchae Spinous process of C7 Spinous processes of T1 to T12	Spine of the scapula Acromion Lateral 1/3 of the clavicle	Elevate the scapula Retract the scapula Depress the scapula	Spinal accessory n. also receives some branches from C3 and C4, thought to be proprioceptive
Sternocleidomastoid	Manubrium Medial 1/3 of the clavicle	Mastoid process of the temporal bone Superior nuchal line	Unilaterally: • Face turns to contralateral side • Head tilts to ipsilateral side Bilaterally: • Head is flexed	Spinal accessory n.

## MUSCLES THAT SUBDIVIDE THE TRIANGLES

Muscle	Origin	Insertion	Actions	Nerve Supply
Digastric (posterior and anterior bellies connected by a tendon attached to the hyoid)	Mastoid process	Digastric fossa of the mandible	Elevates hyoid Helps depress and retract the mandible	Facial n. (posterior belly) Trigeminal n. (anterior belly)
Omohyoid (superior and inferior bellies connected by a tendon)	Superior border of the scapula	Body of the hyoid	Depresses the hyoid Helps depress the larynx	Ansa cervicalis



## 4 Muscles

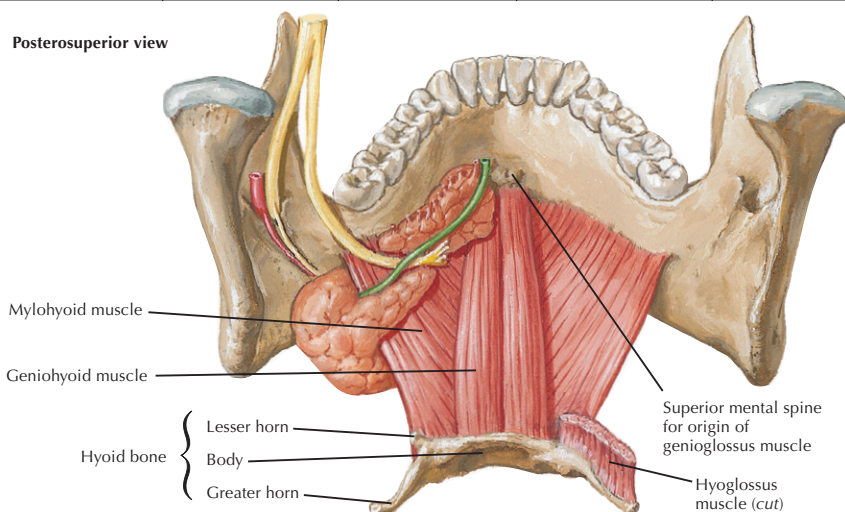
### SUPRAHYOID MUSCLES

Muscle	Origin	Insertion	Actions	Nerve Supply
Stylohyoid	Styloid process	Body of the hyoid	Elevates the hyoid Retracts the hyoid	Facial n.
Mylohyoid	Mylohyoid line of the mandible	Mylohyoid of opposite side at the raphe Body of the hyoid	Elevates the hyoid Elevates the floor of the oral cavity	Trigeminal n. (mandibular division)
Digastric (posterior and anterior bellies connected by a tendon attached to the hyoid)	Mastoid process	Digastric fossa of the mandible	Elevates hyoid Helps depress and retract the mandible	Facial n. (posterior belly) Trigeminal n. (anterior belly—mandibular division)
Geniohyoid	Inferior genial tubercle	Body of the hyoid	Helps move the hyoid and tongue anteriorly	C1 (ventral ramus, which follows the hypoglossal n.)

### INFRAHYOID MUSCLES

Muscle	Origin	Insertion	Actions	Nerve Supply
Omoxyoid (superior and inferior bellies connected by a tendon)	Superior border of the scapula	Body of the hyoid	Depresses the hyoid	Ansa cervicalis
Sternohyoid	Manubrium	Body of the hyoid	Depresses the hyoid	Ansa cervicalis
Sternothyroid	Manubrium	Oblique line of the thyroid cartilage	Depresses the larynx	Ansa cervicalis
Thyrohyoid	Oblique line of the thyroid cartilage	Greater cornu (horn) of the hyoid	Depresses the hyoid	C1 (ventral ramus, which follows the hypoglossal n.)

Posterosuperior view





# Muscles

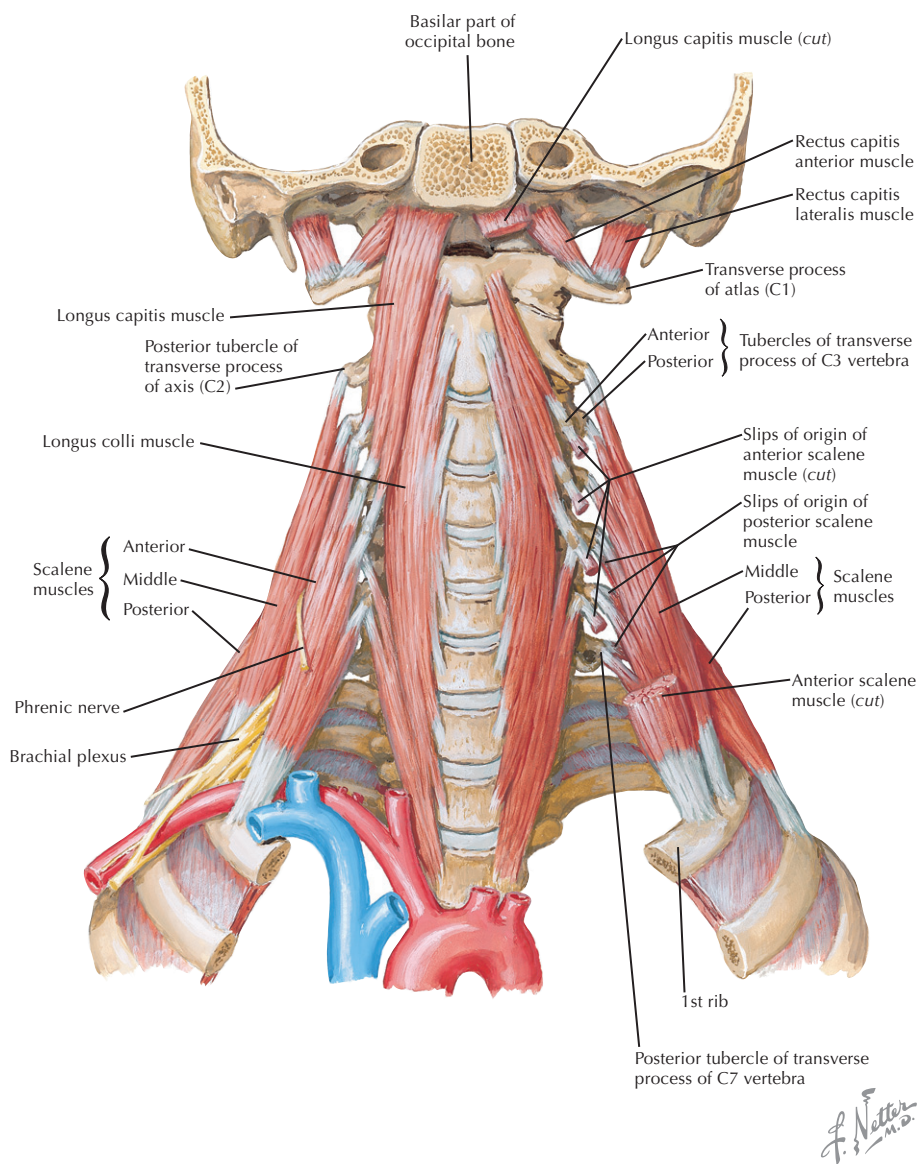
## PREVERTEBRAL MUSCLES

Muscle	Origin	Insertion	Actions	Nerve Supply
Longus colli			Flexion of the neck Helps rotate the neck	Ventral rami of C2 to C8
<i>Superior oblique</i>	Transverse processes of C3 to C5	Anterior arch of atlas		
<i>Inferior oblique</i>	Vertebral bodies of T1 to T3	Transverse process of C5 to C6		
<i>Vertical</i>	Vertebral bodies of C5 to C7 and T1 to T3	Vertebral bodies of C2 to C4		
Longus capitis	Transverse processes of C3 to C6	Basilar portion of the occipital bone	Flexion of the head	Ventral rami of C1 to C3
Rectus capitis anterior	Transverse process of the atlas			Ventral rami of C1 and C2
Rectus capitis lateralis			Jugular portion of the occipital bone	Lateral flexion of the head
Anterior scalene	Transverse processes of C3 to C6	Scalene tubercle on the 1st rib	Elevates 1st rib Lateral flexion of the neck	Ventral rami of C4 to C6
Middle scalene	Transverse processes of C2 to C7	1st rib	Lateral flexion of the neck	Ventral rami of C5 to C8
Posterior scalene	Transverse processes of C5 to C7	2nd rib		Ventral rami of C6 to C8



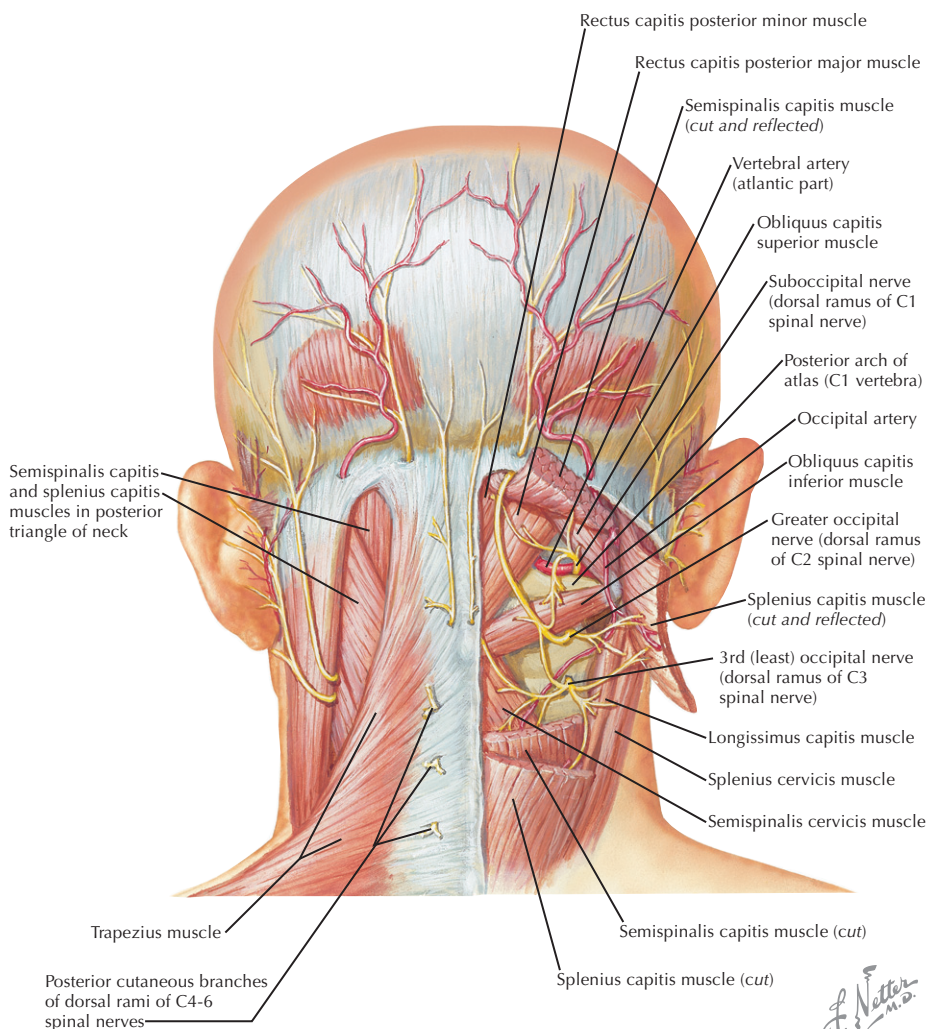
## 4 Muscles

### PREVERTEBRAL MUSCLES *CONTINUED*



## SUBOCCIPITAL TRIANGLE MUSCLES

Muscle	Origin	Insertion	Actions	Nerve Supply
Obliquus capitis superior	Transverse process of the atlas	Occipital bone	Extends head Lateral flexion of head	Suboccipital n. (dorsal rami of C1)
Obliquus capitis inferior	Spinous process of the axis	Transverse process of the atlas	Rotates head to ipsilateral side	Suboccipital n. (dorsal rami of C1)
Rectus capitis posterior major		Inferior nuchal line (lateral portion) of the occipital bone	Extends head Rotates head to ipsilateral side	Suboccipital n. (dorsal rami of C1)
Rectus capitis posterior minor	Posterior arch of the atlas	Inferior nuchal line (medial portion) of the occipital bone	Extends head	Suboccipital n. (dorsal rami of C1)



*F. Netter M.D.*

## 4 Vascular Supply of the Neck

### ARTERIAL SUPPLY

The major arteries of the neck are the common carotid and the subclavian arteries

#### SUBCLAVIAN

- Thyrocervical
- Costocervical
- Vertebral
- Dorsal scapular (usually)

(Internal thoracic artery is located in the thorax)

#### COMMON CAROTID

- Internal carotid
- External carotid
  - Superior thyroid
  - Lingual
  - Facial
  - Ascending pharyngeal
  - Occipital

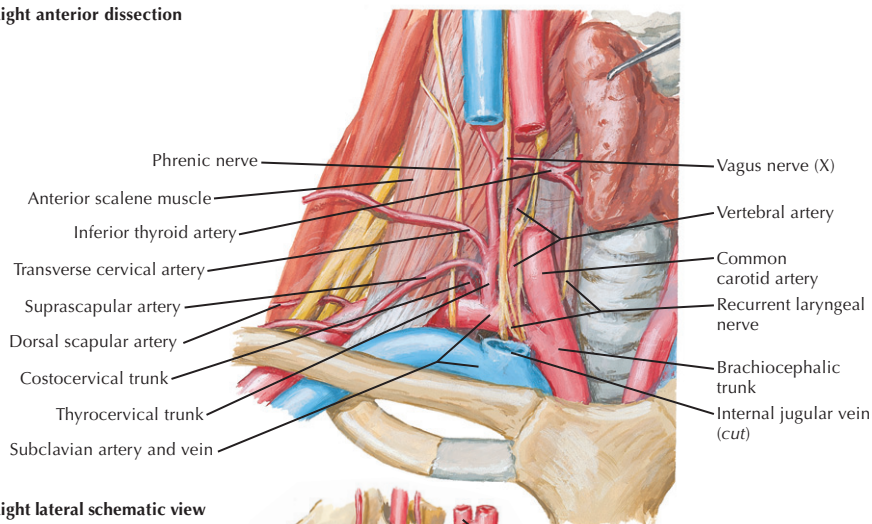
(Posterior auricular, maxillary, and superficial temporal arteries are located in the head)

SUBCLAVIAN VASCULAR SUPPLY OF THE NECK		
Artery	Source	Comments
Subclavian	Right subclavian a. is a branch of the brachiocephalic a.; left subclavian a. is a direct branch of the aorta	Both subclavian aa. travel lateral to the trachea into the root of the neck, passing between the anterior and middle scalene aa. Divided into 3 parts based on its relationship to the anterior scalene m.: <ul style="list-style-type: none"> <li>• 1st part—extends from the beginning of the subclavian to the medial border of the anterior scalene, and all of the branches of the subclavian a. arise from the 1st part, except the left costocervical trunk, which often is a branch of the 2nd part</li> <li>• 2nd part—located posterior to the anterior scalene</li> <li>• 3rd part—located from the lateral margin of the anterior scalene to the lateral border of the 1st rib, where it becomes the axillary a.</li> </ul>
Thyrocervical	A branch of the 1st part of the right subclavian along the medial aspect of the anterior scalene m.	Immediately divides into 3 branches: <ul style="list-style-type: none"> <li>• Inferior thyroid—travels along the medial border of the anterior scalene posterior to the carotid sheath and anterior to the vertebral a. to the thyroid gland while accompanied by the recurrent laryngeal n.; it gives rise to the inferior laryngeal a. to the larynx and the ascending cervical, which helps supply the muscles in the area and sends branches to the vertebral a.</li> <li>• Suprascapular—travels inferior to and laterally across the anterior scalene m. and phrenic n. deep to the sternocleidomastoid m. and crosses the posterior triangle of the neck to reach the scapula, where it passes superior to the transverse lig. of the scapula</li> <li>• Transverse cervical—travels across the posterior triangle of the neck to reach the anterior border of the trapezius m.</li> </ul>
Costocervical	A branch of the 1st part of the right subclavian a. and the 2nd part of the left subclavian a.	Divides into 2 branches: <ul style="list-style-type: none"> <li>• Deep cervical—travels superiorly along the posterior part of the neck mainly to help supply the muscles</li> <li>• Supreme intercostal—travels to supply the 1st and 2nd intercostal spaces</li> </ul>
Vertebral	1st part of the subclavian a.	Ascends to enter the foramen transversarium of C6. Passes around the atlas and then through the foramen magnum to enter the skull, where it unites with the opposite vertebral to form the basilar a. along the ventral surface of the pons
Dorsal scapular	2nd or 3rd part of the subclavian a.	Arises from the subclavian a. in about 70% to 75% of people and the transverse cervical a. in the other 25% to 30%. When arising from the subclavian a., it passes posteriorly between the trunks of the brachial plexus to travel across the posterior triangle of the neck to reach the anterior border of the trapezius m.

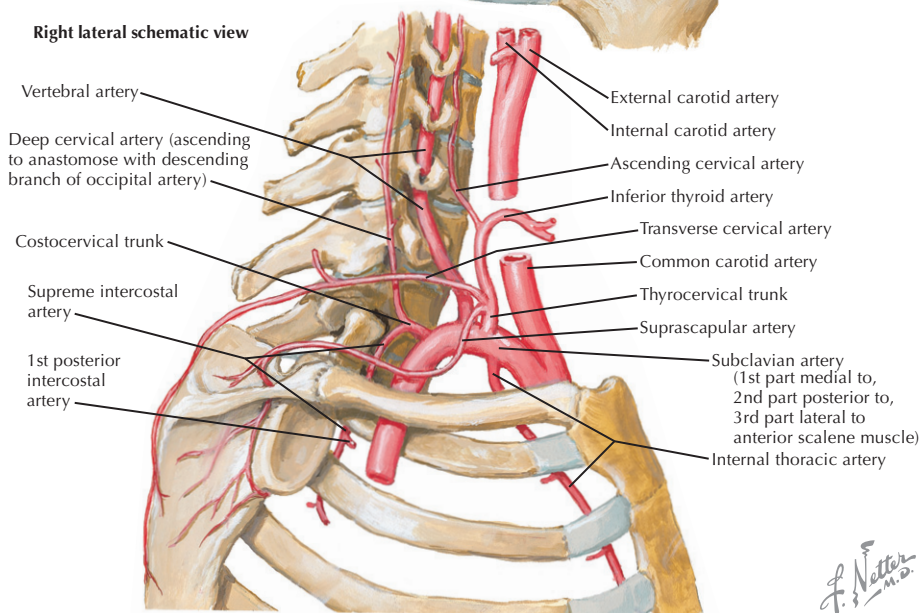
# Vascular Supply of the Neck

## ARTERIAL SUPPLY *CONTINUED*

### Right anterior dissection



### Right lateral schematic view



*F. Netter M.D.*

## 4 Vascular Supply of the Neck

### ARTERIAL SUPPLY *CONTINUED*

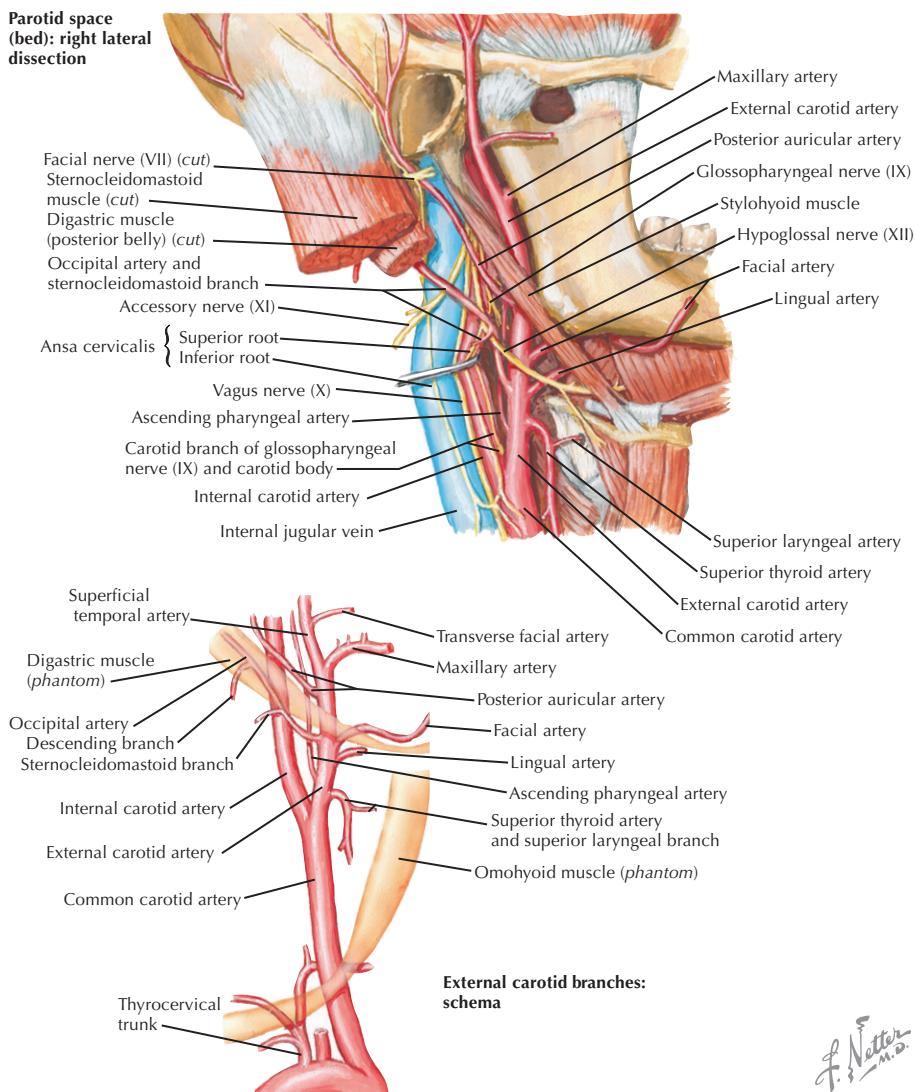
CAROTID VASCULAR SUPPLY OF THE NECK		
Artery	Source	Comments
Common carotid	Right common carotid a. is a branch of the brachiocephalic a.; left common carotid a. is a direct branch of the aorta	Both common carotids ascend posterior to the sternoclavicular joint into the neck and bifurcate at the superior border of the thyroid cartilage at C3 into the: <ul style="list-style-type: none"> <li>• External carotid a.</li> <li>• Internal carotid a.</li> </ul> There are no branches of the common carotid a. in the neck Carotid body: A chemoreceptor located along the common carotid a. Usually receives its sensory innervation from the carotid branch of the glossopharyngeal n.
Internal carotid	The 2 branches of the common carotid a.; arise at the superior border of the thyroid cartilage at C3	There are no branches of the internal carotid a. in the neck Passes superiorly in the neck within the carotid sheath along with the internal jugular v. and the vagus n. anterior to the transverse processes of the upper cervical vertebrae Carotid sinus: A baroreceptor located as a dilation at the beginning of the internal carotid a. Usually receives its sensory innervation from the carotid branch of the glossopharyngeal n.
External carotid		Gives rise to a majority of the branches to the neck Located external to the carotid sheath and travels anteriorly and superiorly in the neck posterior to the mandible and deep to the posterior belly of the digastric and stylohyoid mm. to enter the parotid gland
Superior thyroid	The first branch of the external carotid a.; arises in the carotid triangle	Passes inferiorly along the inferior constrictor m. on its path to the thyroid gland The superior laryngeal a. arises from the superior thyroid a. and passes through the thyrohyoid membrane to supply the larynx
Lingual	External carotid a.; arises within the carotid triangle	Passes superiorly and medially toward the greater cornu of the hyoid bone in an oblique fashion and makes a loop by passing anteriorly and inferiorly while traveling superficial to the middle constrictor m. While forming a loop, the artery is crossed superficially by the hypoglossal n. The lingual a. passes deep to the posterior belly of the digastric and stylohyoid mm. as it travels anteriorly At this region, it gives rise to a hyoid branch that travels on the superior surface of the hyoid bone supplying the muscles in the area Passes deep to the hyoglossus m. and travels anteriorly between the hyoglossus and genioglossus mm. to supply the tongue
Facial	External carotid a. in the carotid triangle of the neck	Passes superiorly immediately deep to the posterior belly of the digastric and stylohyoid mm. Passes along the submandibular gland giving rise to the submental a., which helps supply the gland Passes superiorly over the body of the mandible at the masseter m. in a tortuous pattern to supply the face
Ascending pharyngeal	Posterior portion of the external carotid a. near the bifurcation of the common carotid a.	The smallest branch of the external carotid Ascends superiorly between the lateral side of the pharynx and the internal carotid a. Has a series of branches: 3 to 4 pharyngeal branches supply the superior and middle constrictor mm. The most superior branch passes through the gap superior to the superior constrictor m. Gives rise to an inferior tympanic branch, which supplies the middle ear cavity Gives rise to a posterior meningeal branch, which supplies the bones of the posterior cranial fossa and dura mater
Occipital	External carotid a. in the carotid triangle of the neck	Branches along the inferior margin of the posterior belly of the digastric and stylohyoid mm. The hypoglossal n. wraps around the occipital a. from the posterior part of the vessel, traveling anteriorly Passes posteriorly along the mastoid process, making a groove on the bone Pierces the fascia that connects the attachment of the trapezius with the sternocleidomastoid m. Ascends in the connective tissue layer of the scalp, dividing into many branches Anastomoses with the posterior auricular and superficial temporal aa. The terminal part of the artery is accompanied by the greater occipital n.



# Vascular Supply of the Neck

## ARTERIAL SUPPLY *CONTINUED*

### Parotid space (bed): right lateral dissection



*F. Netter M.D.*



## 4 Vascular Supply of the Neck

### VENOUS DRAINAGE

Highly variable with inconsistent drainage

#### VEINS OF THE NECK

Internal jugular

- Occipital
- Facial
- Lingual
- Pharyngeal

- Superior thyroid
- Middle thyroid

External jugular

Anterior jugular

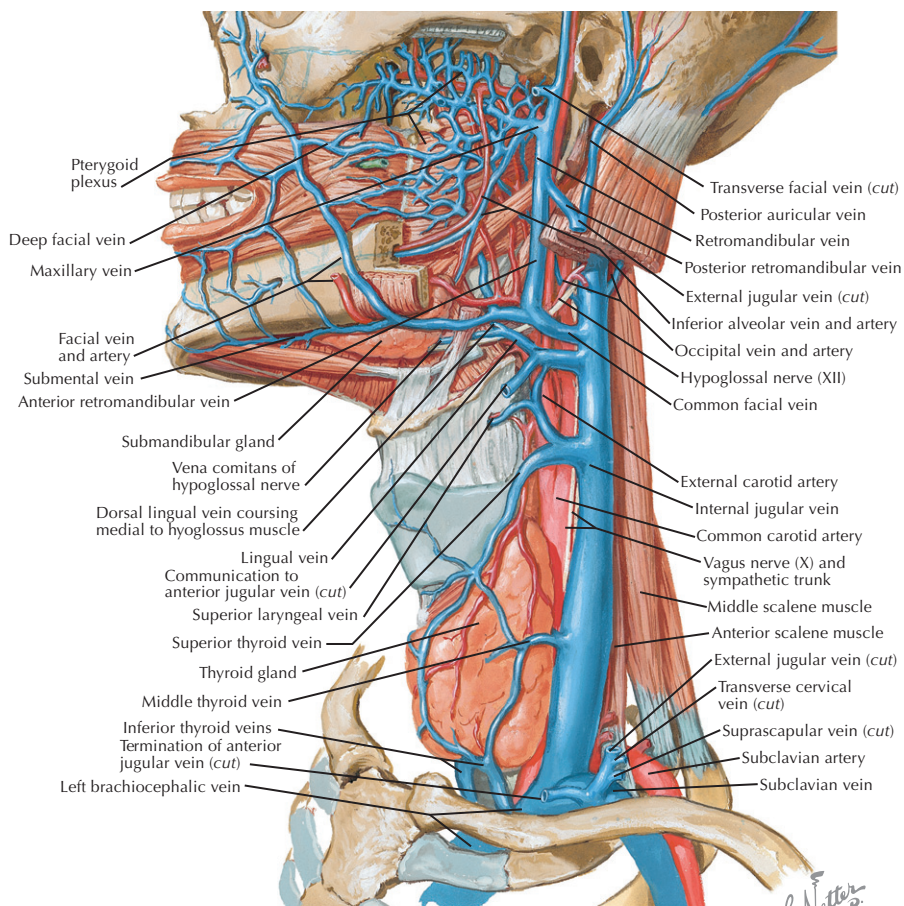
Subclavian

- Vertebral

JUGULAR VASCULAR SUPPLY OF THE NECK	
Vein	Comments
Internal jugular	Continuous with the sigmoid sinus within the cranial cavity Begins at the base of the skull at a dilation called the superior bulb Lies posterior to the internal carotid a. and the glossopharyngeal, vagus, and spinal accessory nn. as it initially descends Travels lateral to the internal carotid a. within the carotid sheath with the vagus n. posterior to the vessels Unites with the subclavian v. to form the brachiocephalic v. at the root of the neck Receives a series of branches
<i>Occipital</i>	Begins on the posterior portion of the scalp at the vertex Passes from superficial to deep by passing through the attachment of the sternocleidomastoid m. Has a mastoid emissary v. that connects it to the transverse sinus The vein's termination is variable, but it usually passes inferiorly to join the internal jugular v.
<i>Facial</i>	Has no valves to allow blood to backflow Begins as the angular v. Passes inferiorly along the side of the nose, receiving the lateral nasal v. Continues in a posterior and inferior path across the angle of the mouth to the cheek, receiving the superior and inferior labial vv. While passing toward the mandible, the deep facial v. connects the facial v. to the pterygoid plexus In the submandibular triangle, the facial v. joins the anterior branch of the retromandibular to form the common facial v. Common facial v. drains into the internal jugular v.
<i>Lingual</i>	Passes with the lingual a., deep to the hyoglossus m., and ends in the internal jugular v. The vena comitans nervi hypoglossi, or accompanying v. of the hypoglossal n., begins at the apex of the tongue and either joins the lingual v. or accompanies the hypoglossal n. and enters the common facial v., draining into the internal jugular v.
<i>Pharyngeal</i>	Pharyngeal vv. pass from the pharyngeal plexus of vv. along the posterior portion of the pharynx Drain into the internal jugular v.
<i>Superior thyroid</i>	Forms a venous plexus on the thyroid gland with the middle and inferior thyroid vv. before draining into the internal jugular v.
<i>Middle thyroid</i>	Forms a venous plexus on the thyroid gland with the superior and inferior thyroid vv. before draining into the internal jugular v.
External jugular	Formed by the combination of the posterior branch of the retromandibular and posterior auricular vv. in the parotid gland Lies deep to the platysma m. but superficial to the sternocleidomastoid m. as it descends vertically Passes into the posterior triangle of the neck, where it drains into the subclavian v. immediately lateral to the anterior scalene m.
<i>Transverse cervical</i>	Passes from the anterior border of the trapezius m. through the posterior triangle to drain into the external jugular v.
<i>Suprascapular</i>	Arises from the scapula above the transverse scapular lig. to pass through the posterior triangle of the neck to drain into the external jugular v.
<i>Anterior jugular</i>	Arises by the joining of a series of superficial veins in the submental region Descends anterior to the sternocleidomastoid m. and passes deep to the muscle before draining into the external jugular or the subclavian
Subclavian	The continuation of the axillary v. Located along the lateral border of the 1st rib until it unites with the internal jugular v. Passes anterior to the anterior scalene m.
<i>Vertebral</i>	Begins as a plexus in the suboccipital triangle and descends through the foramen transversarium of all of the cervical vertebrae before draining into the subclavian or, more commonly, the brachiocephalic v.

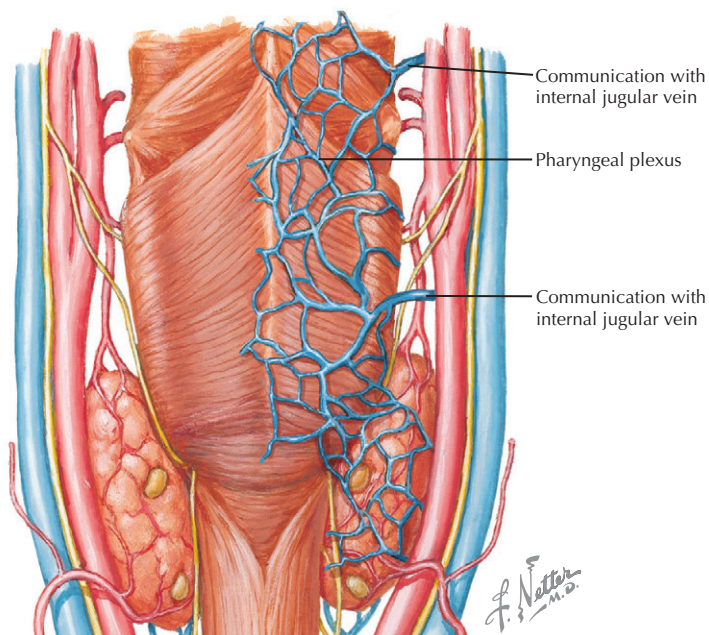
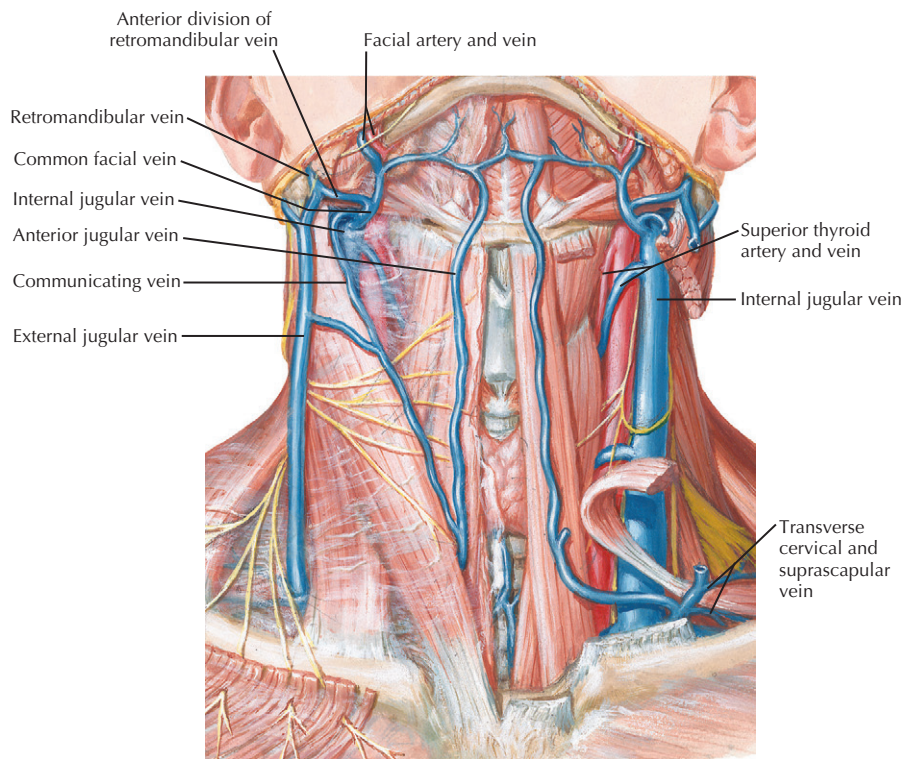
# Vascular Supply of the Neck

## VENOUS DRAINAGE *CONTINUED*



## 4 Vascular Supply of the Neck

### VENOUS DRAINAGE *CONTINUED*



# Nerve Supply of the Neck

## GENERAL INFORMATION

The nerve supply to the neck is extensive; it is made up of:

- Cranial nerves
  - Glossopharyngeal
  - Vagus
  - Spinal accessory
  - Hypoglossal
- Cervical plexus
- Brachial plexus
  - Dorsal scapular
  - Long thoracic
  - Suprascapular
- Phrenic
- Other cervical ventral rami

## CRANIAL NERVES OF THE NECK

GLOSSOPHARYNGEAL NERVE
<p>Also known as cranial nerve IX</p> <p>Branches from the medulla oblongata and passes through the jugular foramen with the vagus and spinal accessory nn.</p> <p>Immediately after passing through the jugular foramen, it gives off the tympanic branch</p> <p>As the glossopharyngeal passes through the foramen, it passes between the internal carotid a. and internal jugular v. in an inferior direction</p> <p>Gives rise to the carotid branch that passes between the internal and external carotid aa. to the carotid body and carotid sinus</p> <p>The main glossopharyngeal n. continues to pass inferiorly, giving rise to the pharyngeal branch, which is the sensory nerve to the pharyngeal plexus that perforates the muscles of the pharynx and supplies the mucous membranes (mainly oropharynx region)</p> <p>Continues to pass inferiorly; travels posterior to the stylopharyngeus m. and innervates it</p> <p>Passes anteriorly with the stylopharyngeus and travels between the superior and middle constrictor mm. to be located by the palatine tonsils</p> <p>Small lingual branches arise from it and distribute general somatic afferent (GSA) fibers to the mucous membrane of the posterior 1/3 of the tongue, in addition to the fauces, and special visceral afferent (SVA) fibers to the taste buds</p>
VAGUS NERVE
<p>Also known as cranial nerve X</p> <p>Branches from the medulla oblongata and passes through the jugular foramen with the glossopharyngeal and spinal accessory nn.</p> <p>As the vagus n. passes through the foramen, it passes between the internal carotid a. and internal jugular v.</p> <p>A series of nerves branch from the vagus n. as it passes from the base of the skull through the neck: auricular, pharyngeal, superior laryngeal, recurrent laryngeal, and cardiac vagal branches</p>
Auricular Branch
<p>Arises from the superior ganglion, travels posterior to the internal jugular v., and passes along the temporal bone to enter the mastoid canaliculus and give branches that innervate the skin of the back of the auricle and the posterior portion of the external acoustic meatus</p>
Pharyngeal Branch
<p>Arises from the upper part of the inferior ganglion of the vagus n., contains filaments from the cranial portion of the spinal accessory n., and serves as the motor component to the pharyngeal plexus</p>
Superior Laryngeal n.
<p>Travels inferiorly posterior to the internal carotid and on the side of the pharynx, and divides into the:</p> <ul style="list-style-type: none"> <li>• Internal laryngeal n.—passes inferiorly to the larynx through the thyrohyoid membrane along with the superior laryngeal vessels to distribute the GSA fibers to the base of the tongue at the epiglottic region, and to the mucous membranes of the larynx as far inferiorly as the false vocal folds; and SVA fibers to the taste buds in the area</li> <li>• External laryngeal n.—travels inferiorly along the inferior constrictor to supply the cricothyroid muscle and the inferior portion of the inferior constrictor</li> </ul>

## 4 Nerve Supply of the Neck

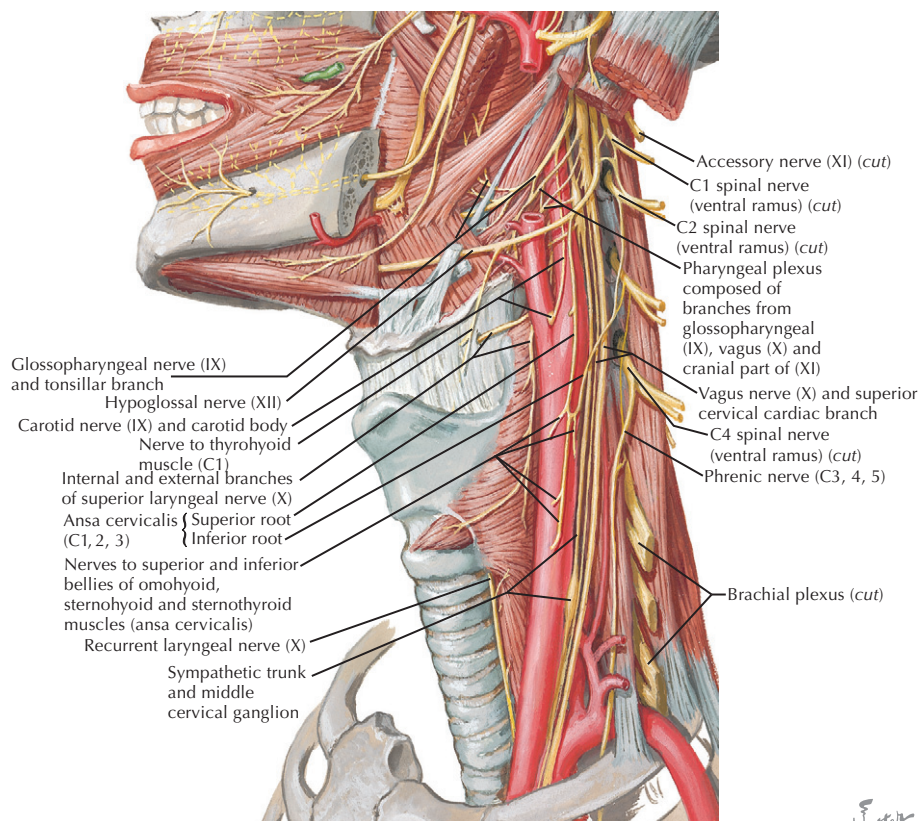
### CRANIAL NERVES OF THE NECK *CONTINUED*

Recurrent Laryngeal n.
<p>Arises from the vagus n. differently, depending on the side of the body</p> <p>The right recurrent laryngeal n. loops under the right subclavian, whereas the left recurrent laryngeal n. loops under the ligamentum arteriosum posterior to the aorta</p> <p>Ascends on the lateral side of the trachea until reaching the pharynx where it passes deep to the inferior constrictor m. to reach the larynx, innervating the mucous membranes below the false vocal folds and all of the intrinsic muscles of the larynx except the cricothyroid</p>
Cardiac Vagal Branches
<p>Descend to form the parasympathetic portion of the cardiac plexus</p>
SPINAL ACCESSORY NERVE
<p>Also known as cranial nerve XI</p> <p>Described as being formed from 2 parts: cranial and spinal</p>
Cranial Part
<p>Begins in the nucleus ambiguus from the medulla as 4 to 5 branches just inferior to the roots of the vagus n. and passes laterally to the jugular foramen, where it merges with the fibers of the spinal part of the spinal accessory n.</p> <p>While united for a short distance, it also is connected by 1 or 2 branches with the inferior ganglion of the vagus n.</p> <p>Exits through the jugular foramen, separates from the spinal part, and continues over the surface of the inferior ganglion of the vagus n. to be distributed mainly to the pharyngeal branches of the vagus to form the motor portion of the pharyngeal plexus, which innervates the muscles in the pharynx, soft palate, and 1 tongue muscle</p>
Spinal Part
<p>Begins in the upper cervical levels of the spinal cord and after separating from the cranial part provides innervation to the sternocleidomastoid m. and passes obliquely through the posterior triangle of the neck to innervate the trapezius m.</p>
HYPOGLOSSAL NERVE
<p>Also known as cranial nerve XII</p> <p>Arises as a series of rootlets from the medulla oblongata and passes through the hypoglossal canal</p> <p>Travels inferiorly, located between the internal carotid a. and the internal jugular v.</p> <p>Passes anteriorly as it wraps around the occipital a. inferior to the posterior belly of the digastric m.</p> <p>Passes superficial to the external carotid a. and the loop of the lingual a. in its anterior path</p> <p>Passes deep to the posterior belly of the digastric and stylohyoid mm. and lies superficial to the hyoglossus m. with the accompanying v. of the hypoglossal n.</p> <p>It passes deep to the mylohyoid m. and continues anterior in the genioglossus m.</p> <p>Gives rise to muscular branches that supply all the intrinsic tongue muscles and the hyoglossus, genioglossus, and styloglossus mm.</p>



# Nerve Supply of the Neck

## CRANIAL NERVES OF THE NECK *CONTINUED*

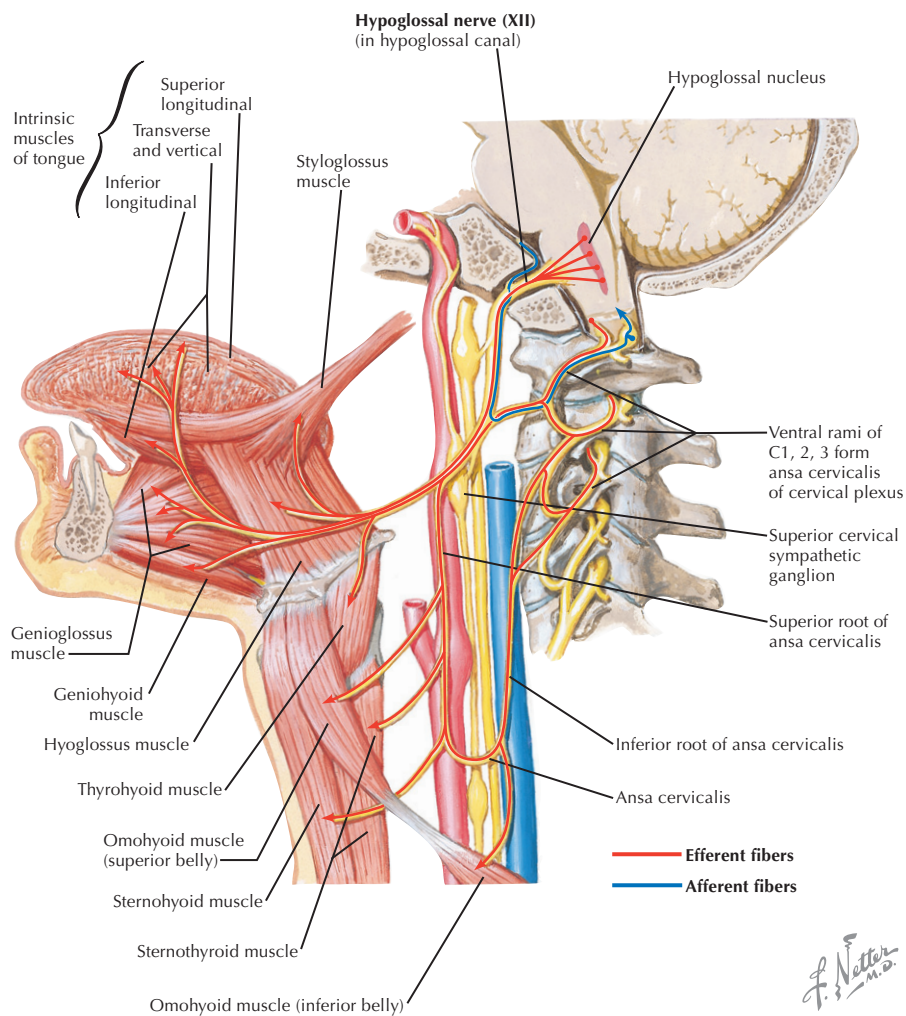


*F. Netter M.D.*



## 4 Nerve Supply of the Neck

### CRANIAL NERVES OF THE NECK *CONTINUED*



# Nerve Supply of the Neck

## SENSORY INNERVATION OF THE NECK

Skin of the neck receives sensory innervation from both dorsal and ventral rami  
Dorsal ramus of C1 lacks sensory fibers and does not contribute to the sensory distribution to the neck

Dorsal rami of C6 to C8 lack sensory fibers and do not contribute to the sensory distribution to the neck

Ventral rami provide most of the sensory innervation to the neck through the sensory branches of the cervical plexus

### CERVICAL PLEXUS

Formed by C1 to C4 ventral rami

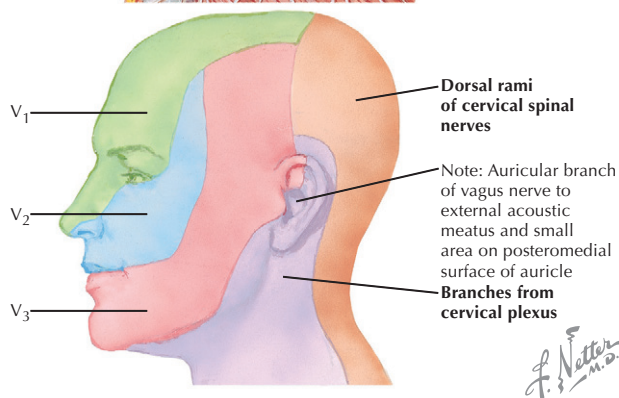
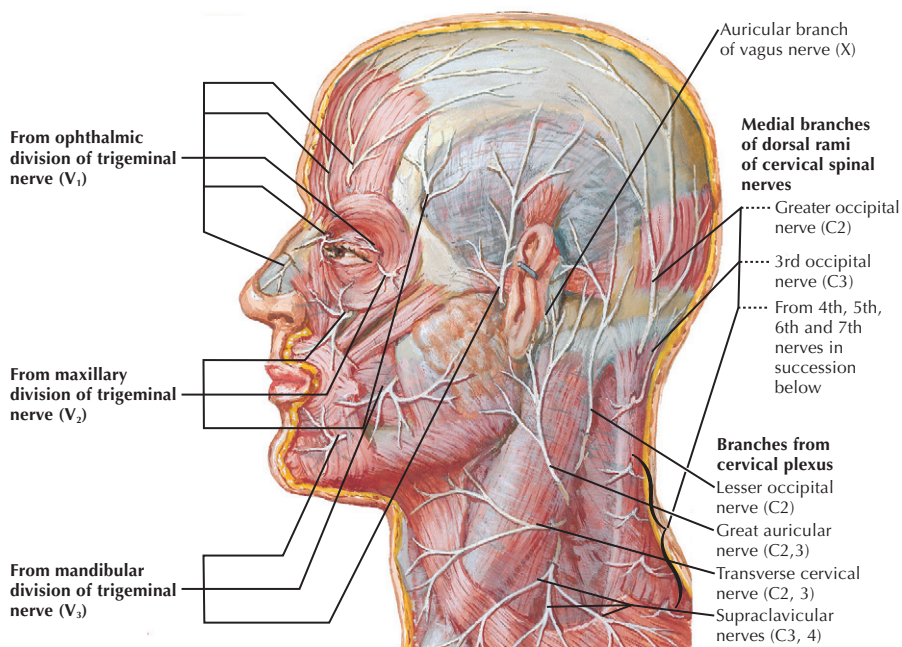
Originates deep to the sternocleidomastoid

Sensory branches pass along the posterior border of the muscle at Erb's point to travel to their destinations

VENTRAL RAMI		
Nerve	Source	Comments
Lesser occipital	Cervical plexus by contributions from the ventral ramus of C2	Passes posterior to the sternocleidomastoid m. at Erb's point Ascends posterior to the sternocleidomastoid along the posterior portion of the head Continues on the head posterior to the auricle supplying the skin in the region
Great auricular	Cervical plexus formed by contributions of ventral rami C2 and C3	Passes posterior to the sternocleidomastoid m. at Erb's point Ascends along the sternocleidomastoid, dividing into anterior and posterior branches: Anterior branch innervates the skin of the face over the parotid gland Posterior branch innervates the skin over the mastoid process, the posterior portion of the auricle, and the concha and lobule
Transverse cervical		Passes posterior to the sternocleidomastoid m. at Erb's point Crosses anteriorly along the sternocleidomastoid, dividing into ascending and descending branches Ascending and descending branches pass through the platysma m. to supply the skin of the neck from the region between the mandible and the manubrium
Supraclavicular	Cervical plexus formed by contributions of ventral rami C3 and C4	Passes posterior to the sternocleidomastoid m. at Erb's point Travels inferiorly in an oblique direction through the posterior triangle of the neck <i>Divides into 3 major branches:</i> <ul style="list-style-type: none"> <li>• Medial supraclavicular—supplies the skin up to the midline</li> <li>• Middle supraclavicular—supplies the skin over the pectoralis major and deltoid m. region</li> <li>• Lateral supraclavicular—supplies the skin along the deltoid and anterior trapezius mm.</li> </ul>
DORSAL RAMI		
Nerve	Source	Comments
Greater occipital	Dorsal ramus of C2	Ascends after emerging from the suboccipital triangle obliquely between the inferior oblique and semispinalis capitis mm. Passes through the trapezius m. and ascends to innervate the skin along the posterior part of the scalp to the vertex
3rd occipital	Branch of the dorsal ramus of C3 deep to the trapezius m.	Passes through the trapezius m. and ascends along in the skin of the inferior portion of the posterior surface of the head near the midline
Dorsal ramus of C4	Dorsal ramus of C4 deep to the trapezius m.	Passes through the trapezius m. and ascends along in the skin of the inferior portion of the posterior surface of the head near the midline
Dorsal ramus of C5	Dorsal ramus of C5 deep to the trapezius m.	Passes through the trapezius m. and ascends along in the skin of the inferior portion of the posterior surface of the head near the midline

## 4 Nerve Supply of the Neck

### SENSORY INNERVATION OF THE NECK *CONTINUED*



# Nerve Supply of the Neck

## CERVICAL PLEXUS OF THE NECK

Arises from the ventral rami of C1 to C4

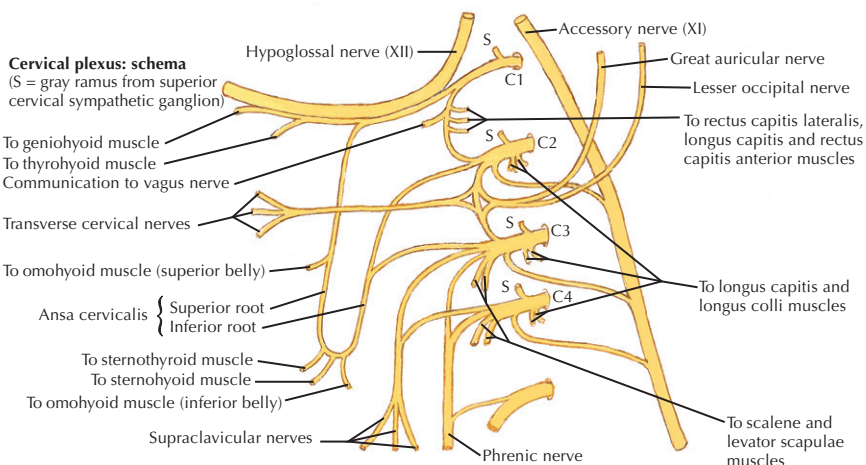
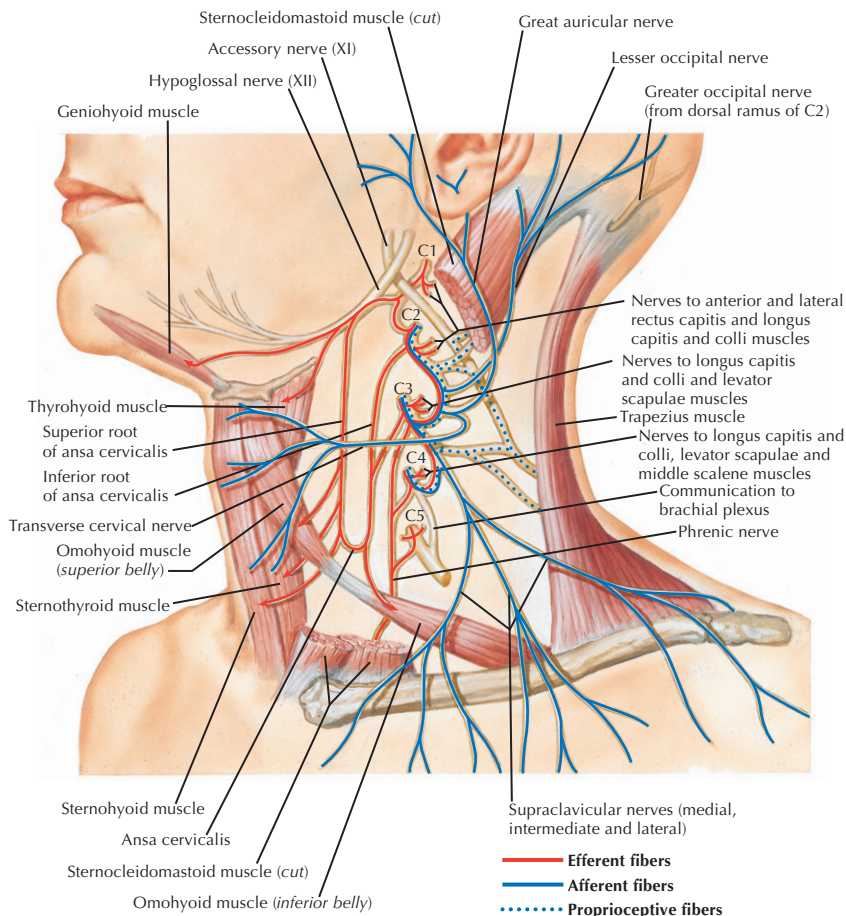
Divided into 2 parts:

- Ansa cervicalis (motor component)
- Cutaneous branches (sensory component):
  - Lesser occipital
  - Transverse cervical
  - Great auricular
  - Supraclavicular

ANSA CERVICALIS		
Source	Comments	
Ventral rami of C1 to C3	<p>The motor component of the cervical plexus Innervates the:</p> <ul style="list-style-type: none"><li>• Omohyoid</li><li>• Sternohyoid</li><li>• Sternothyroid</li></ul> <p><b>Divisions:</b> Superior root (descendens hypoglossi) Arises from the ventral ramus of C1, which passes anteriorly and joins the hypoglossal n., and the fibers travel together without mixing As the hypoglossal n. passes anteriorly toward the tongue, some of the fibers of C1 branch inferiorly to form the superior root of the ansa cervicalis Superior root joins the inferior root along the lateral border of the carotid sheath Some of the fibers from C1 continue to follow the hypoglossal n. to innervate the geniohyoid and thyrohyoid mm. Inferior root (descendens cervicalis) Arises from the ventral rami of C2 and C3 These branches unite to form the inferior root that unites with the superior root along the lateral border of the carotid sheath</p>	
CUTANEOUS BRANCHES		
Nerve	Source	Comments
Lesser occipital	Cervical plexus by contributions from the ventral ramus of C2	Passes posterior to the sternocleidomastoid m. at Erb's point Ascends posterior to the sternocleidomastoid along the posterior portion of the head Continues on the head posterior to the auricle supplying the skin in the region
Great auricular	Cervical plexus formed by contributions of ventral rami C2 and C3	Passes posterior to the sternocleidomastoid m. at Erb's point Ascends along the sternocleidomastoid dividing into anterior and posterior branches: Anterior branch innervates the skin of the face over the parotid gland Posterior branch innervates the skin over the mastoid process, the posterior portion of the auricle, and the concha and lobule
Transverse cervical		Passes posterior to the sternocleidomastoid m. at Erb's point Crosses anteriorly along the sternocleidomastoid dividing into ascending and descending branches Ascending and descending branches pass through the platysma to supply the skin of the neck from the region between the mandible and the manubrium
Supraclavicular	Cervical plexus formed by contributions of ventral rami C3 and C4	Passes posterior to the sternocleidomastoid m. at Erb's point Travels inferiorly in an oblique direction through the posterior triangle of the neck <i>Divides into 3 major branches:</i> <ul style="list-style-type: none"><li>• Medial supraclavicular—supplies the skin up to the midline</li><li>• Middle supraclavicular—supplies the skin over the pectoralis major and deltoid m. region</li><li>• Lateral supraclavicular—supplies the skin along the deltoid and anterior trapezius mm.</li></ul>

## 4 Nerve Supply of the Neck

### CERVICAL PLEXUS OF THE NECK *CONTINUED*



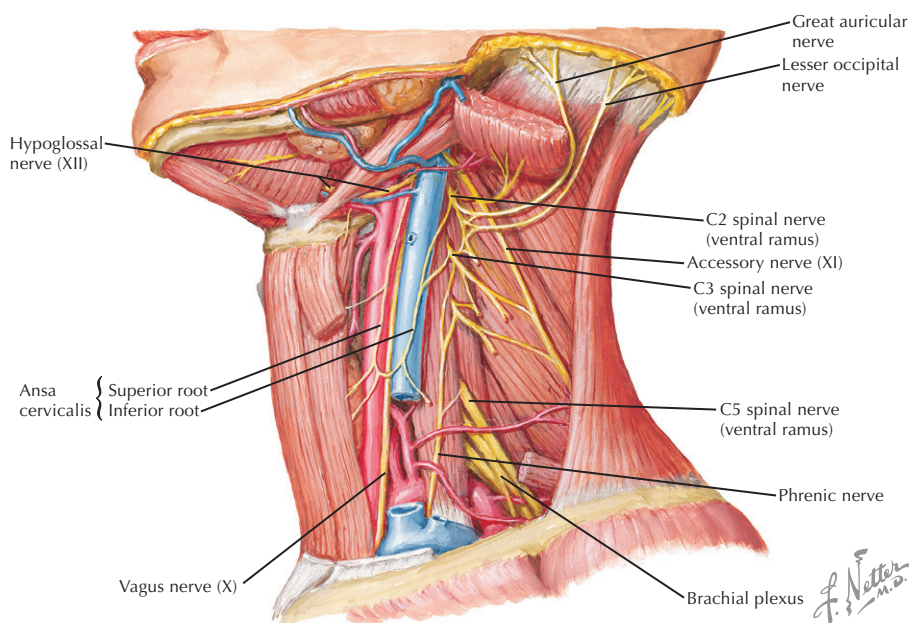
*F. Netter M.D.*



# Nerve Supply of the Neck

## VENTRAL RAMI NERVES OF THE NECK

Nerve	Source	Comments
Phrenic	Arises from the ventral rami of C3 to C5	Passes inferiorly along the anterior surface of the anterior scalene m. Eventually passes through the thorax to innervate the diaphragm
Brachial plexus	Ventral rami of C5 to C8 and T1 form the brachial plexus, which provides motor and sensory function to the upper limb	These rami pass between the anterior and the middle scalene mm. Ventral rami of C5 and C6 unite to form the upper trunk Ventral ramus of C7 continues as the middle trunk Ventral ramus of C8 to T1 form the inferior trunk These trunks continue to form the divisions of the brachial plexus that enter the axilla 3 branches of the brachial plexus are contained in the posterior triangle of the neck: <ul style="list-style-type: none"> <li>• Dorsal scapular—arises from C5 and passes through the middle scalene before passing obliquely to the levator scapulae, which it innervates (along with the rhomboid major and minor mm.)</li> <li>• Long thoracic—arises from the ventral rami C5 to C7 to pass through the middle scalene before passing inferiorly to the serratus anterior, which it innervates</li> <li>• Suprascapular—arises from the upper trunk to pass through the posterior triangle of the neck to reach the supraspinatus and infraspinatus mm. by passing below the transverse scapular lig.</li> </ul>





## 4 Nerve Supply of the Neck

### SYMPATHETICS IN THE NECK

Sympathetic trunk extends into the neck from the thorax

In the neck, the sympathetic trunk typically has 3 ganglia:

- Superior cervical ganglion—located at the base of the skull
- Middle cervical ganglion—located at C6
- Inferior cervical ganglion—located immediately posterior to the vertebral artery near the vessel's origin

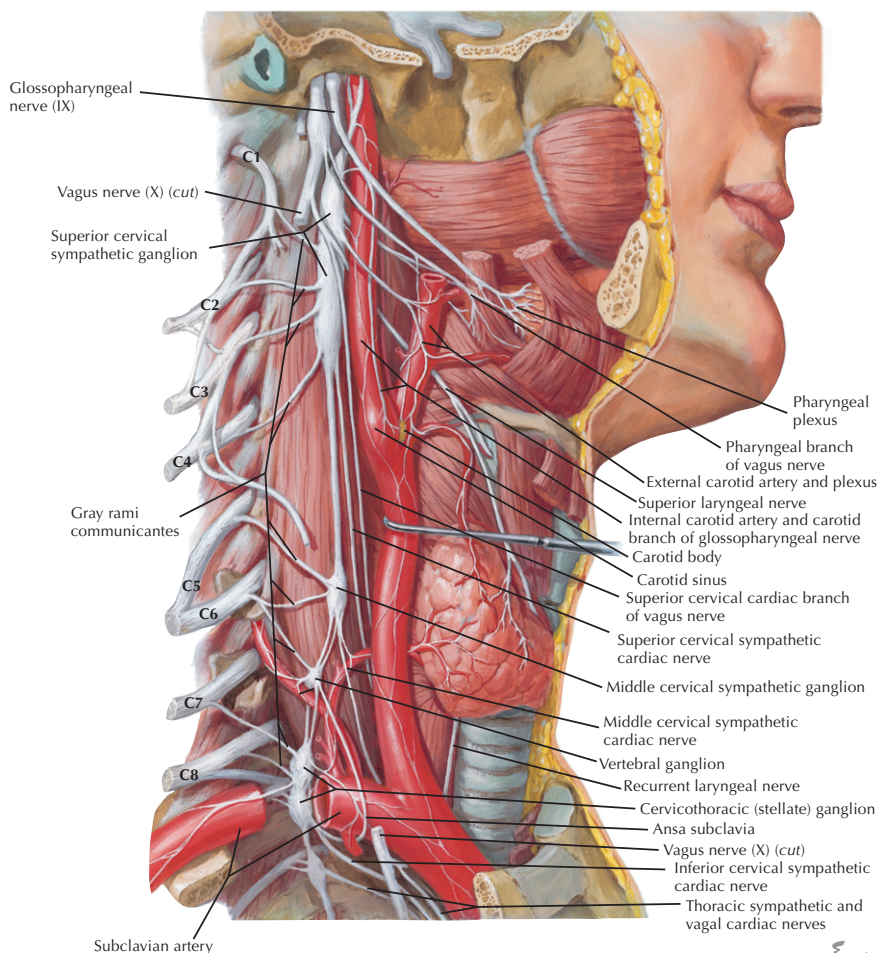
Often the inferior cervical ganglion unites with the 1st thoracic ganglion to create the stellate ganglion

Sympathetics for the head and neck arise in the intermediolateral horn column of the spinal cord from T1 to T4

These preganglionic fibers ascend through the sympathetic trunk to reach the cervical ganglia and synapse with the postganglionic neurons

Postganglionic neurons follow either of 2 paths:

- May travel to the spinal nerves via the gray ramus
- May follow the arterial supply to the effector organs of the head



*F. Netter M.D.*

## Clinical Correlate

### TORTICOLLIS

Torticollis, also known as “wryneck,” is a disorder in which the muscles of the neck are flexed, extended, or twisted in an abnormal position

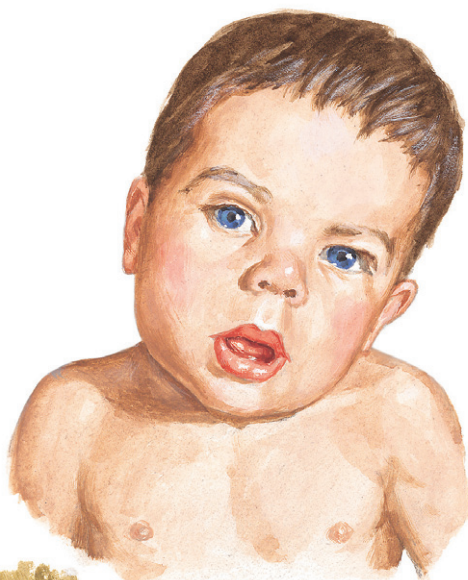The sternocleidomastoid is the most commonly affected muscle

The neck typically twists to one side, leading to abnormal movements and postures of the head

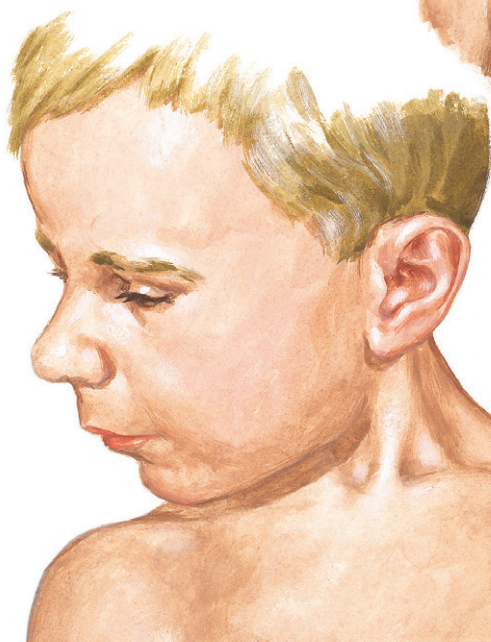In congenital muscular torticollis, the bent neck is caused by a tight sternocleidomastoid on one side of the body

Early treatment is important in preventing permanent deformities

Certain drugs, such as neuroleptic agents, can cause *dystonia*, a condition in which involuntary muscle contraction occurs in the neck, back, and trunk



Child with muscular torticollis. Head tilted to left with chin turned slightly to right because of contracture of left sternocleidomastoid muscle. Note facial asymmetry (flattening of left side of face)



Untreated torticollis in 5-year-old boy. Thick, fibrotic, tendonlike bands have replaced sternocleidomastoid muscle, making head appear tethered to clavicle. Two heads of left sternocleidomastoid muscle prominent

*F. Netter M.D.*

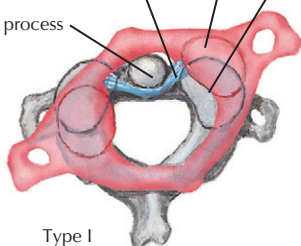
## 4 Clinical Correlate

### TORTICOLLIS *CONTINUED*

#### Nonmuscular Causes of Torticollis

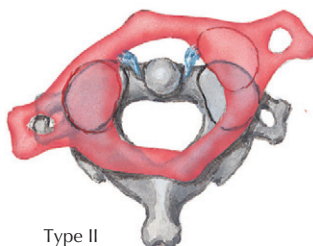
##### Atlantoaxial rotatory subluxation and fixation (after Fielding and Hawkins)

Transverse ligament of atlas  
Inferior articular facet of atlas  
Superior articular facet of axis  
Odontoid process



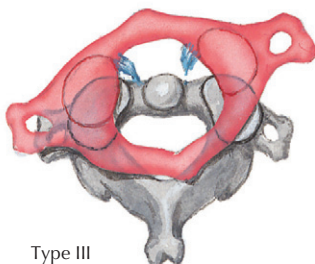
Type I

Rotatory subluxation of atlas about dens but transverse ligament intact. No anterior displacement



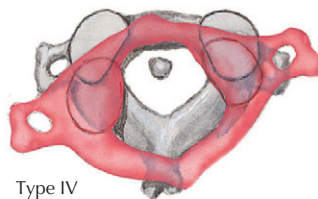
Type II

One articular facet subluxated, other acts as pivot; transverse ligament defective. Anterior displacement of 3-5 mm



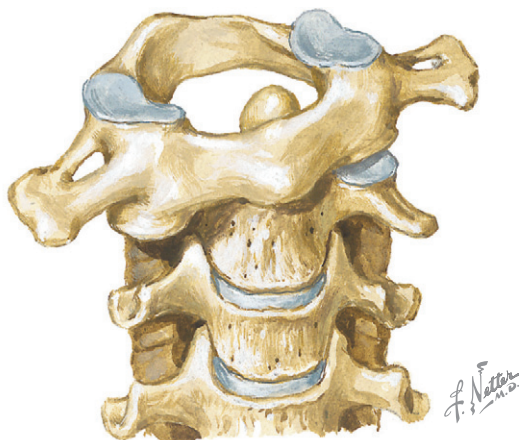
Type III

Both articular facets subluxated, transverse ligament defective. Anterior displacement of >5 mm



Type IV

Posterior rotatory subluxation (rare). Os odontoideum or absent or defective dens



Type I rotatory subluxation

## Clinical Correlate

### HYPOTHYROIDISM

*Hypothyroidism:* a condition in which the thyroid gland does not produce enough thyroid hormones

The pituitary gland regulates the thyroid's normal production of the hormones thyroxine and triiodothyronine

The lack of hormones leads to an overall slowing of mental and physical activities

Congenital hypothyroidism is known as cretinism

#### CAUSES

- Hashimoto's thyroiditis—immune system of the body attacks the gland
- Irradiation of the gland

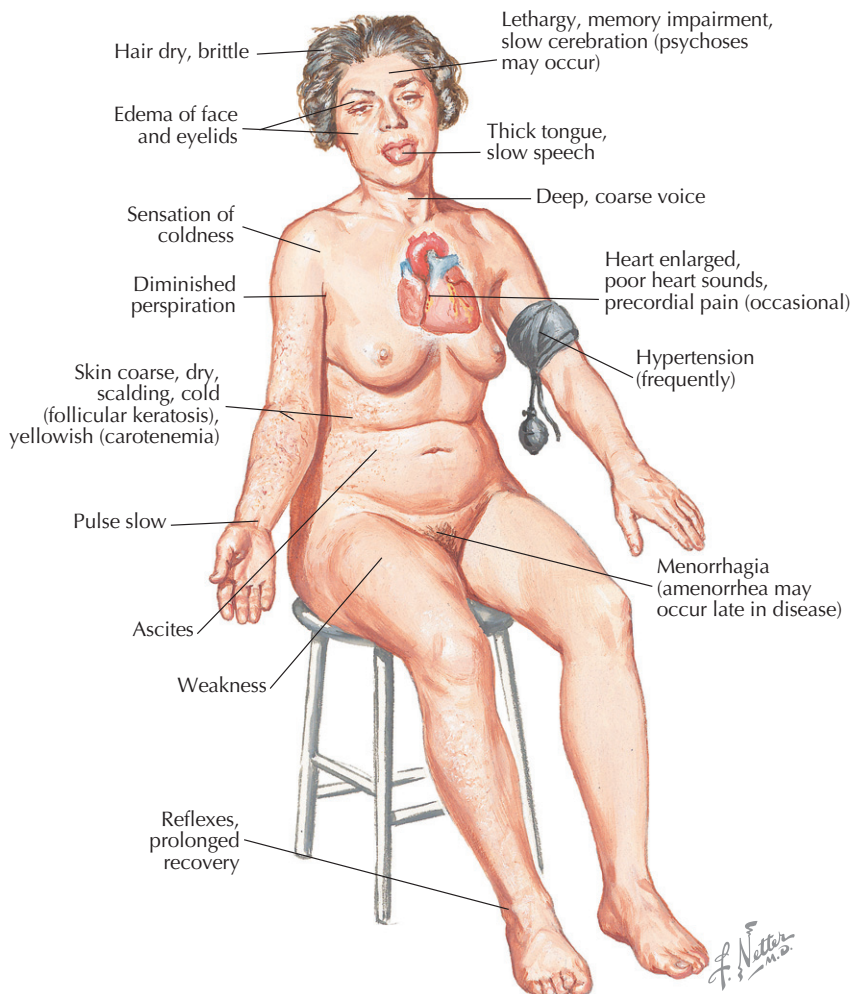
- Surgical removal of the gland
- Congenital defects

#### RISK FACTORS

- Obesity
- Age older than 50 years
- Female gender

#### CLINICAL MANIFESTATIONS

- Fatigue
- Weakness
- Slow pulse
- Edema of face
- Cold sensations
- Dry and coarse skin
- Coarse voice





## 4 Clinical Correlate

### HYPERTHYROIDISM

**Hyperthyroidism:** a condition characterized by hypermetabolism and elevated levels of thyroid hormones

Can lead to *thyrotoxicosis*, a toxic condition caused by excess thyroid hormones regardless of the cause

#### CAUSES

- Graves' disease—most common cause (in greater than 80% of all cases of hyperthyroidism), in which the body produces antibodies that stimulate the thyroid to synthesize excess thyroid hormones
- Benign growths of the thyroid or pituitary gland
- Thyroiditis

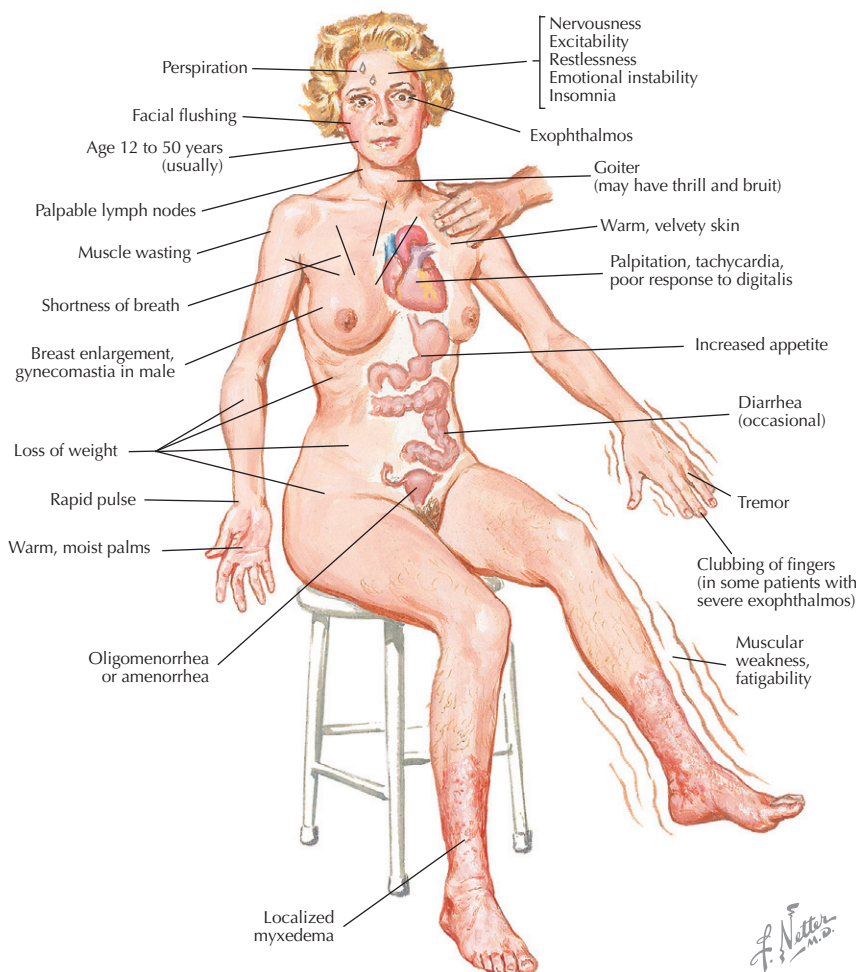
- Ingestion of excess thyroid hormones or iodine
- Gonadal tumors

#### CLINICAL MANIFESTATIONS

- Loss of weight
- Restlessness
- Nervousness
- Increased appetite
- Fatigue
- Goiter

#### TREATMENT

- Radioactive iodine—but too much can lead to hypothyroidism
- Surgery
- Antithyroid agents



## CHAPTER 5

# SCALP AND MUSCLES OF FACIAL EXPRESSION

Overview and Topographic Anatomy	154
Overview of the Scalp	156
Vascular Supply of the Scalp	157
Nerve Supply of the Scalp	159
Overview of Muscles of Facial Expression	161
Vascular Supply of the Face	168
Nerve Supply of the Face	175
Clinical Correlates	182



## 5 Overview and Topographic Anatomy

### GENERAL INFORMATION

#### SCALP

The area bordered by the forehead, superior part of the cranium, and occipital area immediately superior to the superior nuchal line

The lateral portion of the scalp blends with the temporal area because it extends inferiorly to the zygomatic arch

Anatomy of the scalp is important because of frequent trauma in this region

#### FACE

The area bordered within the hairline, anterior border of the auricles, and the chin

Major contents: eyes, nose, mouth, muscles of facial expression, muscles of mastication, parotid gland, trigeminal nerve, and facial nerve

#### BONES

Bones of the facial skeleton:

- Frontal bone
- Zygomatic bone (zygoma)
- Maxilla
- Palatine bone
- Nasal bone
- Mandible

Besides the nasal bone, the most commonly fractured bone of the facial skeleton is the zygomatic bone

#### MUSCLES OF FACIAL EXPRESSION

Innervated by the facial nerve

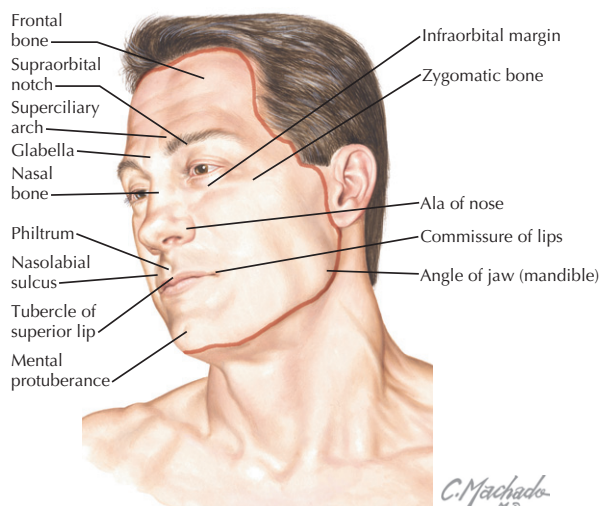
Derivatives of the 2nd pharyngeal arch

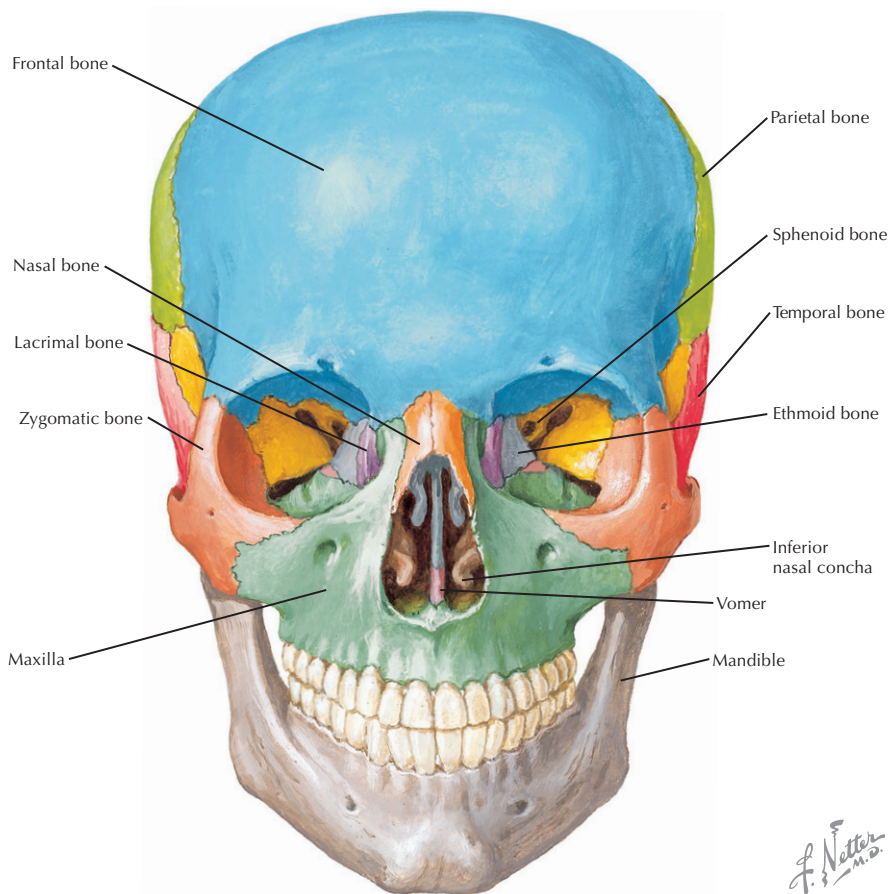
Originate from either bone or fascia and insert on the skin

The Superficial Muscular Aponeurotic System (SMAS) is a term used to describe the relationship of the muscles of facial expression located within the superficial fascia

The SMAS is maneuvered in a rhytidectomy (facelift)

There is no deep fascia along the face

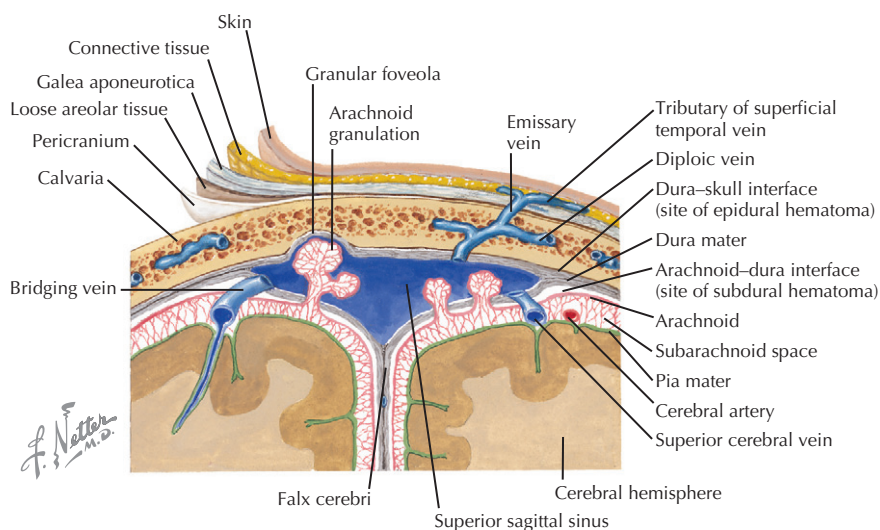




## 5 Overview of the Scalp

### GENERAL INFORMATION

Layer	Description
Skin	Thickest layer of the scalp Contains the hair follicles
Connective tissue	Heavily vascularized Arteries, veins, and nerves of the scalp are located here Emissary veins connect this layer to the dural venous sinuses, providing channel for infections to spread Head wounds that pierce the skin and connective tissue layers bleed profusely
Aponeurosis	Also called galea aponeurosis Continuous with the occipitofrontalis m.: anteriorly with the frontalis, posteriorly with the occipitalis Blends laterally with the temporal fascia Its surgical manipulation is important in cosmetic surgery Head wounds that pierce the skin, connective tissue, and aponeurosis layers bleed and gape open from the pull of the 2 bellies of the occipitofrontalis Skin, connective tissue, and aponeurosis layers are adherent and often called "scalp proper"
Loose areolar connective tissue	Thin and mobile Helps form a subaponeurotic layer that extends from the eyebrows to the superior nuchal line and external occipital protuberance Allows substances such as bacteria and blood to pass freely Separates with scalp avulsion
Pericranium	Covers the outer surface of the cranium



# Vascular Supply of the Scalp

## GENERAL INFORMATION

Highly vascularized; the vessels anastomose freely on the scalp

Arteries are derived from the external and the internal carotid arteries

The neurovascular supply arises from the anterior, lateral, and posterior scalp regions

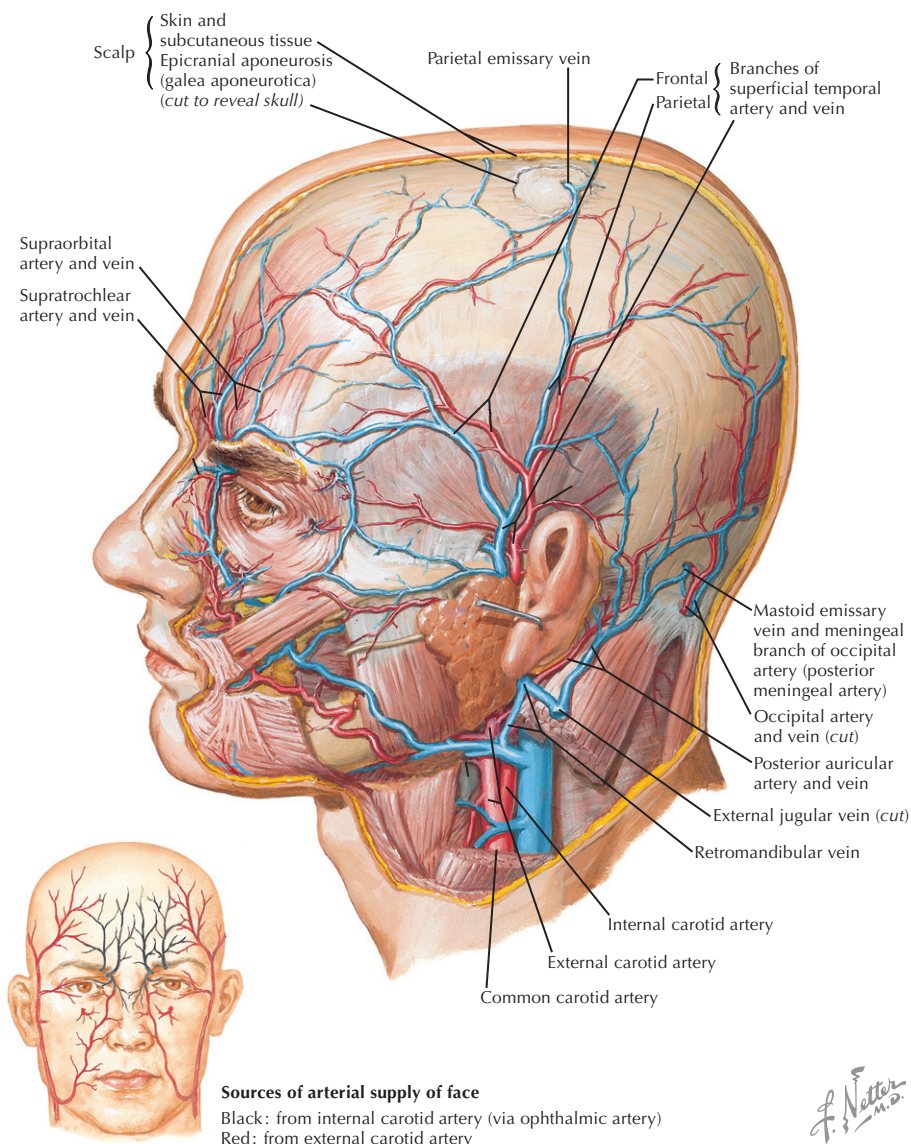
ARTERIAL SUPPLY		
Artery	Source	Course
Supratrochlear	Ophthalmic a. from the internal carotid a.	Exits the orbit at the medial angle accompanied by supratrochlear n. Ascends on the scalp Anastomoses with the contralateral supraorbital and supratrochlear aa.
Supraorbital		Branches from the ophthalmic a. as the artery passes the optic n. Passes medially to the levator palpebrae superioris and superior rectus mm. to join the supraorbital n. Passes through the supraorbital foramen (notch) and ascends superiorly along the scalp Anastomoses with the supratrochlear and superficial temporal aa.
Superficial temporal	1 of 2 external carotid a. terminal branches	Begins posterior to the neck of the mandible and travels superiorly as a continuation of the external carotid a. Joined by the auriculotemporal n. Anastomoses with a majority of other branches supplying the scalp
Posterior auricular	External carotid a.	Arises within the parotid gland Passes superiorly between the mastoid process and the cartilage of the ear Anastomoses with the superficial temporal and occipital aa.
Occipital		Branches along the inferior margin of the posterior belly of the digastric and stylohyoid mm. Hypoglossal n. wraps around it from the posterior part of the vessel, traveling anteriorly Passes posteriorly along the mastoid process, making a groove on the bone Pierces the fascia that connects the attachment of the trapezius with the sternocleidomastoid m. Ascends in the connective tissue layer of the scalp, dividing into many branches The terminal part is accompanied by the greater occipital n. Anastomoses with the posterior auricular and superficial temporal aa.

## VENOUS DRAINAGE

Vein	Course
Supratrochlear	Begins on the forehead, where it communicates with the superficial temporal v. Passes inferiorly along the forehead parallel with the vein of the opposite side At the medial angle of the orbit, it joins the supraorbital and the angular v.
Supraorbital	Begins on the forehead, where it communicates with the superficial temporal v. Passes inferiorly superficial to the frontalis m. and joins the supratrochlear v. at the medial angle of the orbit and the angular v.
Superficial temporal	Descends posterior to the zygomatic root of the temporal bone alongside the auriculotemporal n. to enter the substance of the parotid gland Unites with the maxillary v. to form the retromandibular v.
Posterior auricular	Begins on the side of the scalp, posterior to the auricle Passes inferiorly and joins the posterior division of the retromandibular v. to form the external jugular v.
Occipital	Begins on the posterior portion of the scalp at the vertex Passes from superficial to deep by passing through the attachment of the sternocleidomastoid m. to the skull Has a mastoid emissary v. that connects it to the transverse sinus The vein's termination is variable, but it usually passes inferiorly to join the internal jugular v.

## 5 Vascular Supply of the Scalp

### VENOUS DRAINAGE *CONTINUED*



# Nerve Supply of the Scalp

## SENSORY DISTRIBUTION

Sensory supply is derived from all 3 divisions of the trigeminal nerve, branches of the cervical plexus, and upper cervical dorsal rami

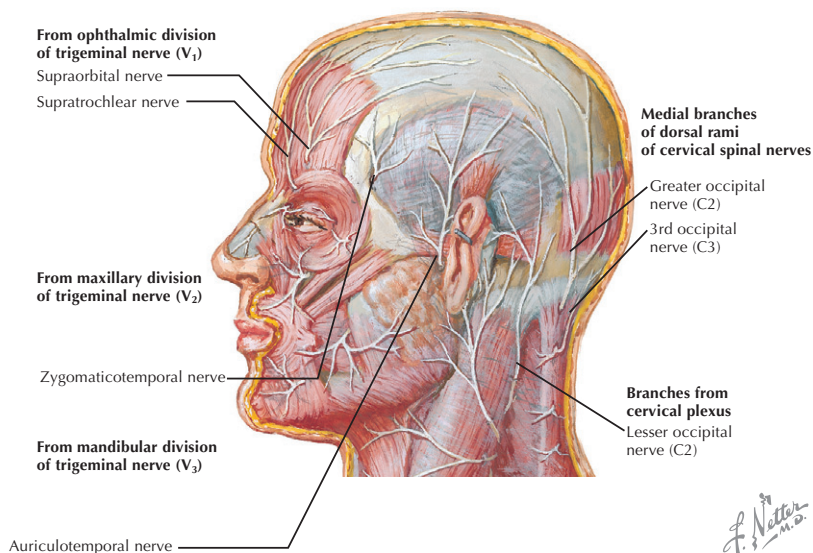
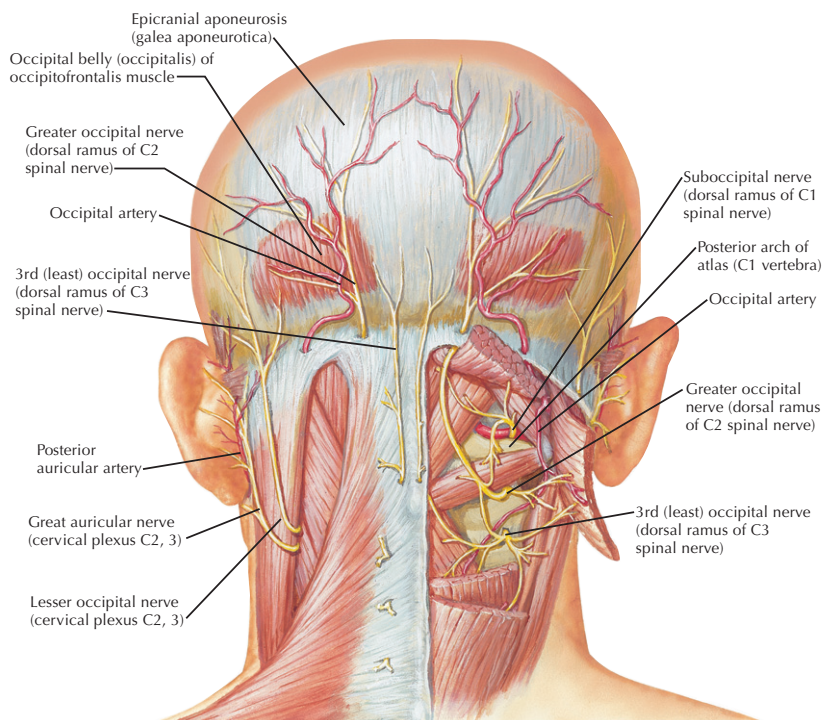
These nerves travel in the scalp's connective tissue layer

SENSORY NERVES OF THE SCALP		
Nerve	Source	Course
Supratrochlear	Arises from the ophthalmic division of the trigeminal n.; 1 of the 2 terminal branches of the frontal n. in the orbit	Continues to pass anteriorly toward the trochlea once the supratrochlear a. joins it within the orbit In the trochlear region, it often supplies the frontal sinus before exiting the orbit Ascends along the scalp, at first deep to the musculature in the region, before piercing them to reach the cutaneous innervation along the scalp
Supraorbital		Passes between the levator palpebrae superioris m. and periosteum of the orbit Continues anteriorly to the supraorbital foramen (notch) At the level of the supraorbital margin, the supraorbital n. supplies the frontal sinus and ascends superiorly along the scalp Divides into medial and lateral branches that travel to the vertex of the scalp
Zygomaticotemporal	Maxillary division of the trigeminal n.	Arises from the zygomatic n. in the pterygopalatine fossa, and passes through the inferior orbital fissure to enter the lateral wall of the orbit and branches into the zygomaticotemporal and zygomaticofacial branches Passes on the lateral wall of the orbit in a groove in the zygomatic bone, then through a foramen in the zygomatic bone to enter the temporal fossa region Within the temporal fossa, it passes superiorly between the bone and the temporalis m. to pierce the temporal fascia superior to the zygomatic arch Passes along the skin of the side of the scalp
Auriculotemporal	Mandibular division of the trigeminal n.	Normally arises as 2 roots, between which the middle meningeal a. passes Runs posteriorly just inferior to the lateral pterygoid and continues to the medial aspect of the neck of the mandible Turns superiorly with the superficial temporal vessels between the auricle and the condyle of the mandible deep to the parotid gland On exiting the parotid gland, ascends over the zygomatic arch and divides into branches along the scalp
Lesser occipital	Arises from the cervical plexus from the ventral ramus of C2	Wraps around and travels superiorly along the posterior border of the sternocleidomastoid At the skull, it passes through the investing layer of deep cervical fascia and continues superiorly posterior to the auricle to supply the skin in the area
Greater occipital	Dorsal ramus of C2	Ascends between the obliquus capitis inferior and semispinalis capitis mm. in the suboccipital triangle Passes through the semispinalis capitis and trapezius mm. near their bony attachments Ascends on the back of the head with the occipital a. to supply the skin as far anterior as the vertex
3rd occipital	Dorsal ramus of C3	Arises deep to the trapezius m., passes through it, and ascends in the skin of the inferior portion of the posterior surface of the head near the midline



# 5 Nerve Supply of the Scalp

## SENSORY DISTRIBUTION *CONTINUED*



*F. Netter M.D.*

# Overview of Muscles of Facial Expression

## GENERAL INFORMATION

Innervated by the facial nerve

Derivatives of the 2nd pharyngeal arch

Insert into the skin to provide movement

Most muscles of facial expression are localized around the facial orifices

There is no deep fascia along the face

## ORAL GROUP

Muscle	Origin	Insertion	Actions	Nerve	Comments
Orbicularis oris	<i>Bone:</i> anterior midline of the maxilla and mandible <i>Muscular:</i> angle of the mouth where fibers blend with levator anguli oris, depressor anguli oris, zygomaticus major, and risorius mm.	Skin along the mouth	Closes mouth Protrusion of lips Pursing of lips	Facial (buccal and mandibular branches)	Sphincter of the mouth Muscle fibers encircle the mouth
Depressor anguli oris	Mandible along area near the external oblique line	Angle of the mouth Some fibers blend and provide origin for the orbicularis oris m. Fibers overlap those of the depressor labii inferioris m.	Depresses the corners of the mouth Antagonizes the levator anguli oris m.	Facial (mandibular branches)	Antagonizes levator anguli oris m.
Levator anguli oris	Canine fossa of the maxilla (inferior to the infraorbital foramen)	Angle of the mouth Some fibers blend and provide origin for the orbicularis oris m.	Elevates the angle of the mouth	Facial (zygomatic and buccal branches)	In an infraorbital injection, the needle lies between the levator anguli oris and levator labii superioris mm.
Zygomaticus major	Zygomatic bone (anterior to the zygomaticotemporal suture)		Moves the angle of the mouth superiorly and laterally		Commonly called the "laughing muscle" owing to its action
Zygomaticus minor	Zygomatic bone (anterior to the zygomaticus major)		Helps elevate the upper lip		Inserts between the levator labii superioris and zygomaticus major mm.

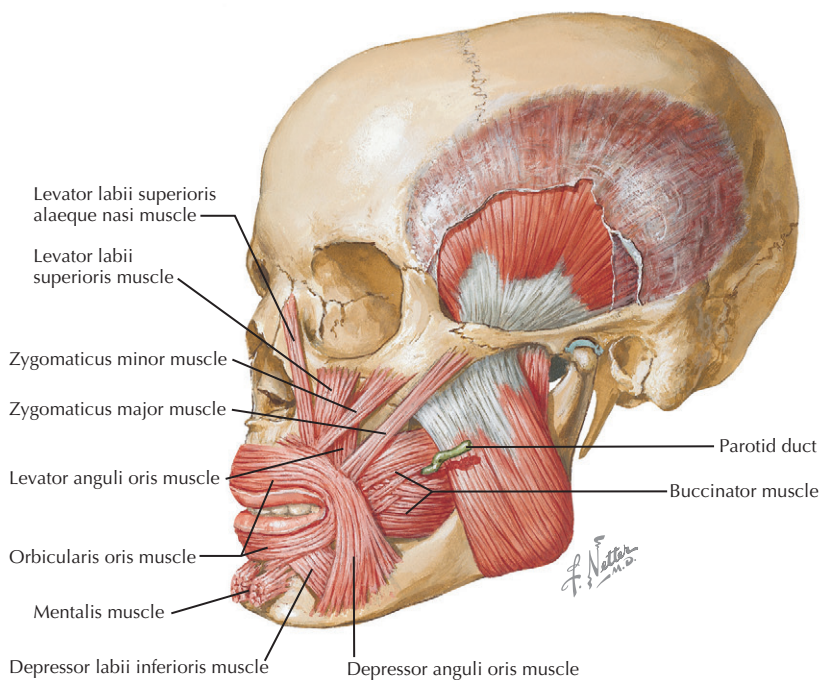
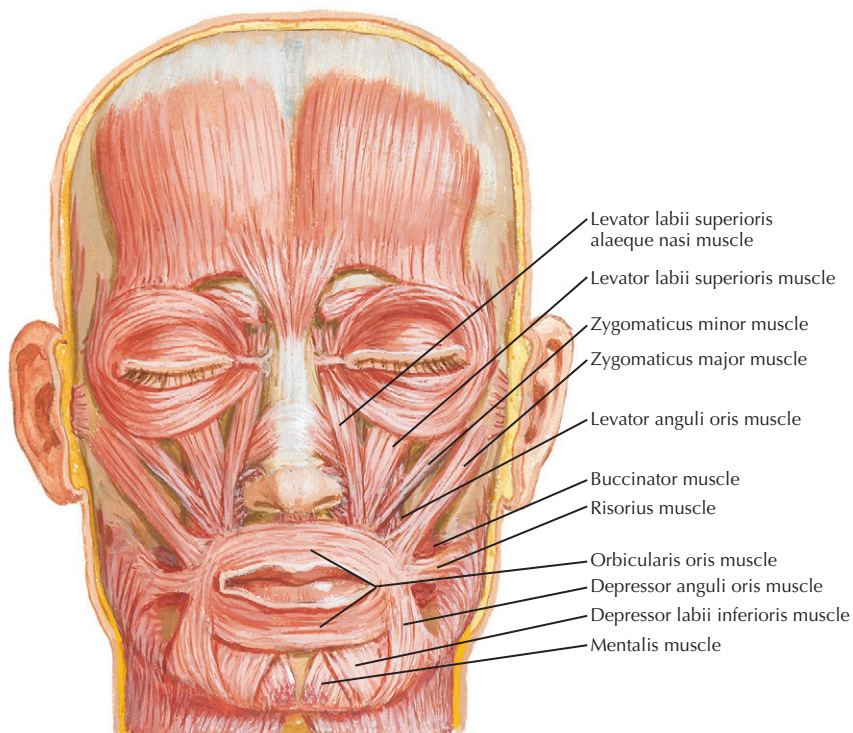
## 5 Overview of Muscles of Facial Expression

### ORAL GROUP *CONTINUED*

Muscle	Origin	Insertion	Actions	Nerve	Comments
Levator labii superioris	Maxilla (superior to the infraorbital foramen along the inferior margin of the orbit)	Lateral upper lip Some fibers blend and provide origin for the orbicularis oris m.	Elevates the upper lip	Facial (zygomatic and buccal branches)	In an infraorbital injection, the needle lies between the levator anguli oris and levator labii superioris mm.
Levator labii superioris alaeque nasi	Maxilla (near the bridge of the nose)	Cartilage of the nose Lateral upper lip	Elevates the upper lip Dilates the nostril		Also called the angular part of the levator labii superioris m.
Risorius	Fascia overlying the parotid gland	Angle of the mouth	Moves the angle of the mouth laterally	Facial (buccal branch)	Commonly called the "grinning muscle"
Depressor labii inferioris	Mandible (inferior to the mental foramen)	Fibers blend and provide origin for the orbicularis oris m.	Depresses the lower lip	Facial (mandibular branch)	Fibers of the depressor anguli oris m. overlap the fibers of the depressor labii inferioris m.
Mentalis	Incisive fossa of the mandible	Skin of the lower lip	Protrudes the lower lip		Used in "pouting"
Buccinator	Pterygomandibular raphe Alveolar margins of the maxilla and mandible	Some fibers blend and provide origin for the orbicularis oris Some fibers blend into the upper and lower lips	Aids in mastication keeping the bolus between cheek and teeth Helps forcibly expel air or create a sucking action	Facial (buccal branch)	Creates the framework of the cheek

# Overview of Muscles of Facial Expression

## ORAL GROUP CONTINUED



## 5 Overview of Muscles of Facial Expression

### NASAL GROUP

Muscle		Origin	Insertion	Actions	Nerve	Comment
Nasalis	Compressor naris	Maxilla	Compressor naris m. of opposite side	Compresses the nostril	Facial n.: buccal branch	Variable and occasionally absent
	Dilator naris		Nasal cartilage	Dilates the nostril		
Depressor septi			Nasal septum	Draws nasal septum anteriorly to constrict the nostril		
Procerus		Nasal bone Lateral nasal cartilage	Skin of the bridge of the nose	Brings skin together producing transverse wrinkles on the bridge of the nose	Facial n.: temporal and zygomatic branches	Partially excised in some facelift procedures (rhytidectomy)

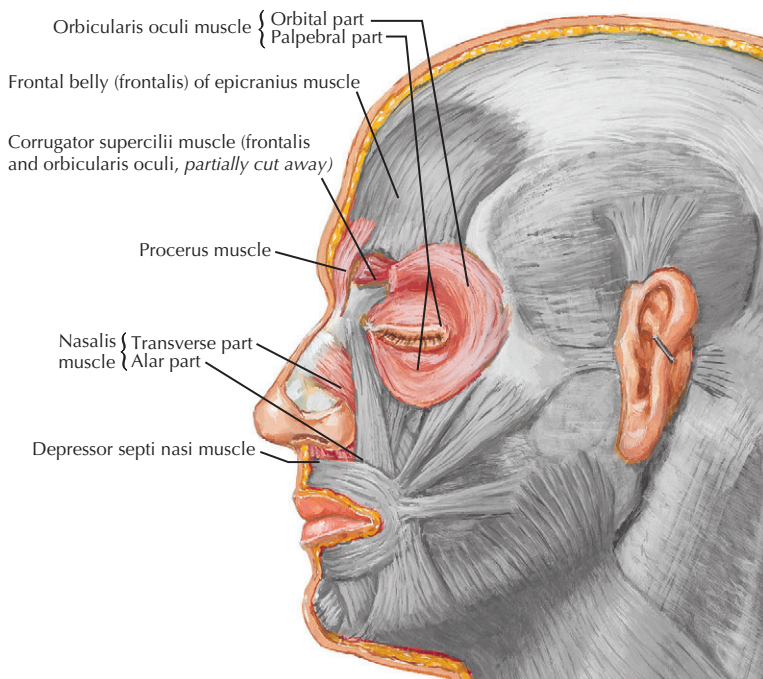
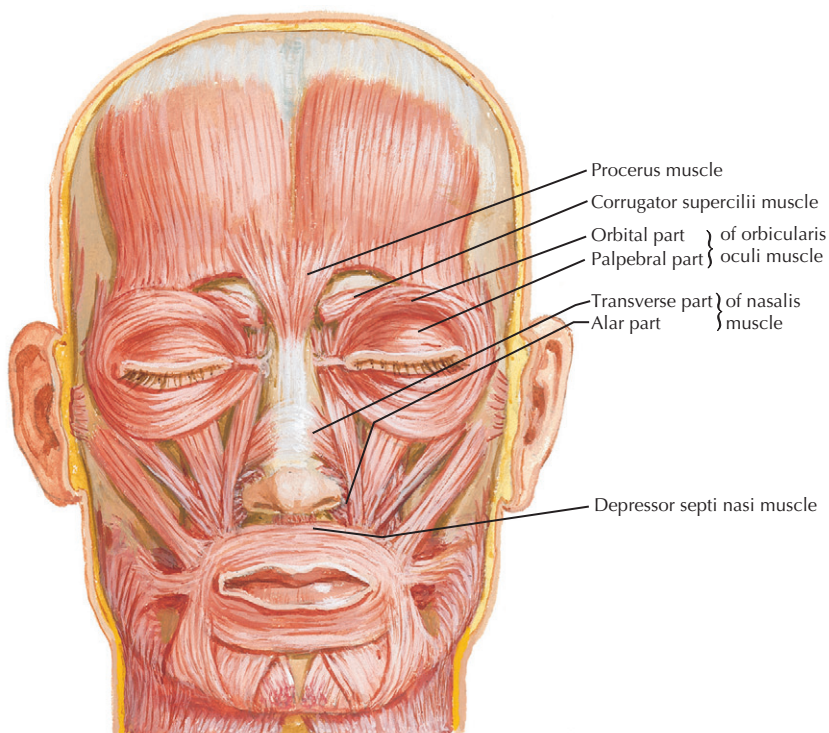
### ORBITAL GROUP

Muscle		Origin	Insertion	Actions	Nerve	Comment
Orbicularis oculi	Orbital	Frontal process of maxilla Nasal portion of frontal bone Medial palpebral ligament	Around the orbit	Forcible closure of the eye	Facial n.: temporal and zygomatic branches	Fat that accumulates around the eye from aging may be removed surgically (blepharoplasty)
	Lacrimal	Lacrimal bone	Lacrimal fascia around the lacrimal canaliculi	Aids the flow of tears		Because the orbicularis oculi m. moves the skin around the eye, its attachment is extremely important
	Palpebral	Medial palpebral ligament	Lateral palpebral raphe	Closure of eyelids gently (blinking)		
Corrugator supercilii		Frontal bone (supraorbital ridge)	Middle of the eyebrow	Draws the eyebrows medially and inferiorly	Facial n.: temporal branch	Fibers lie deep to the orbicularis oculi m.



# Overview of Muscles of Facial Expression

## NASAL GROUP CONTINUED



*F. Netter M.D.*



## 5 Overview of Muscles of Facial Expression

### AURICULAR GROUP

Muscle		Origin	Insertion	Actions	Nerve	Comment
Auricular	Anterior	Galea aponeurosis	Helix	Draws auricle anteriorly	Facial n.: temporal branch	These muscles usually provide little movement and tend to not always be voluntary
	Superior		Superior part of the auricle	Draws auricle superiorly		
	Posterior	Mastoid process	Posterior part of the auricle	Draws auricle posteriorly	Facial n.: posterior auricular branch	

### SCALP GROUP (OCCIPITOFRONTALIS)

Muscle	Origin	Insertion	Actions	Nerve	Comment
Frontalis	Galea aponeurosis	Galea aponeurosis	Elevates eyebrows Wrinkles forehead Wrinkles the back of the head	Facial n.: temporal branch	Has no bony attachment Surgical management important in cosmetic surgery
Occipitalis	Superior nuchal line Mastoid process			Facial n.: posterior auricular branch	

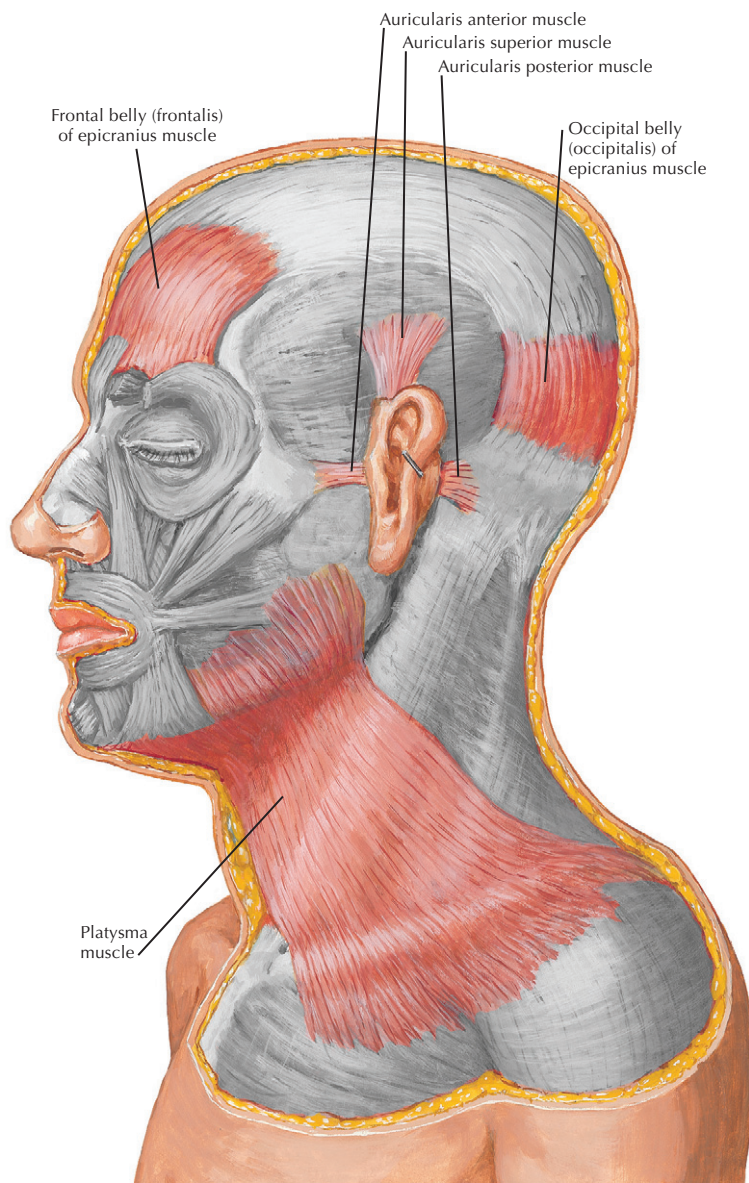
### NECK GROUP

Muscle	Origin	Insertion	Actions	Nerve	Comment
Platysma	Fascia of upper part of the pectoralis major m. and deltoid	Inferior border of the mandible Some fibers blend with the skin of the neck and lower face	Wrinkles the skin of the neck	Facial n.: cervical branch	The external jugular lies deep to the platysma m.

# Overview of Muscles of Facial Expression

## AURICULAR GROUP *CONTINUED*

5



## 5 Vascular Supply of the Face

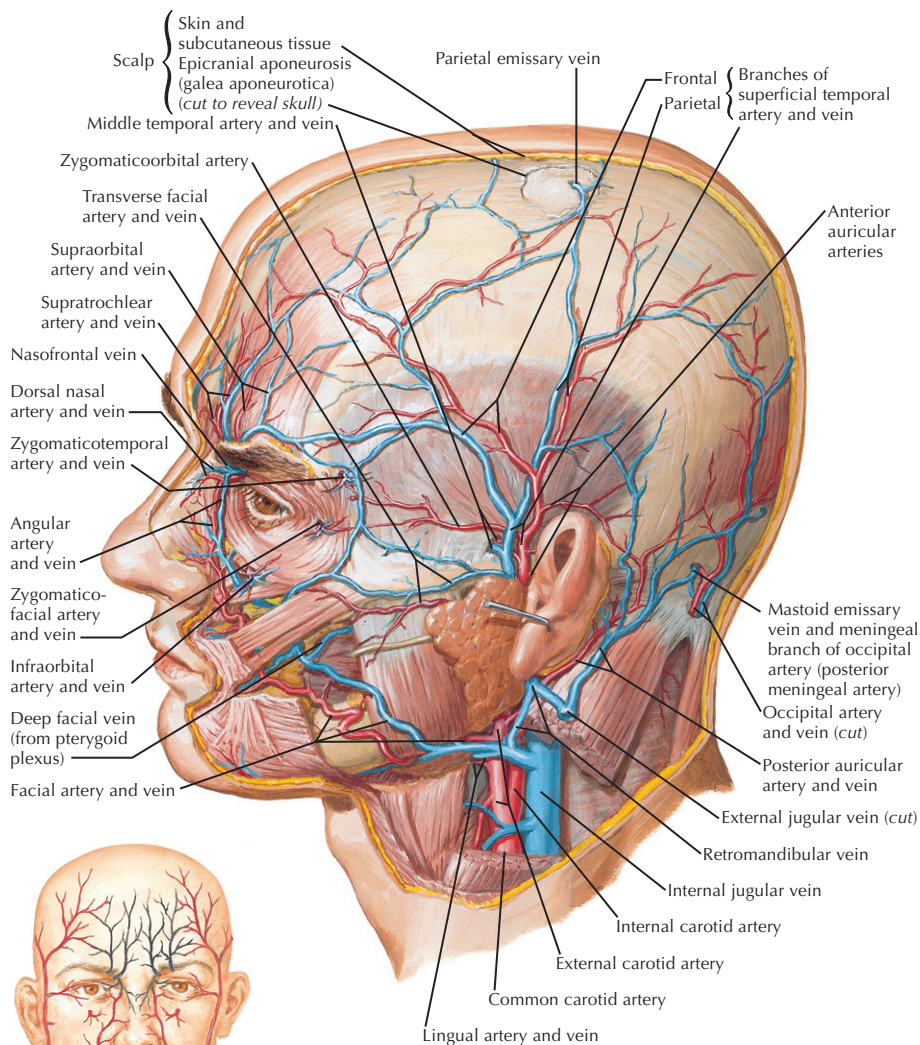
### GENERAL INFORMATION

Most of the arterial supply to the face arises from the superficial temporal artery and facial branches of the external carotid artery

The maxillary branch of the external carotid supplies most areas that the superficial temporal and facial branches do not supply

The internal carotid artery supplies the anterior portion of the forehead and dorsal surface of the nose via ophthalmic artery branches

The arteries of the face anastomose freely



*F. Netter M.D.*

# Vascular Supply of the Face

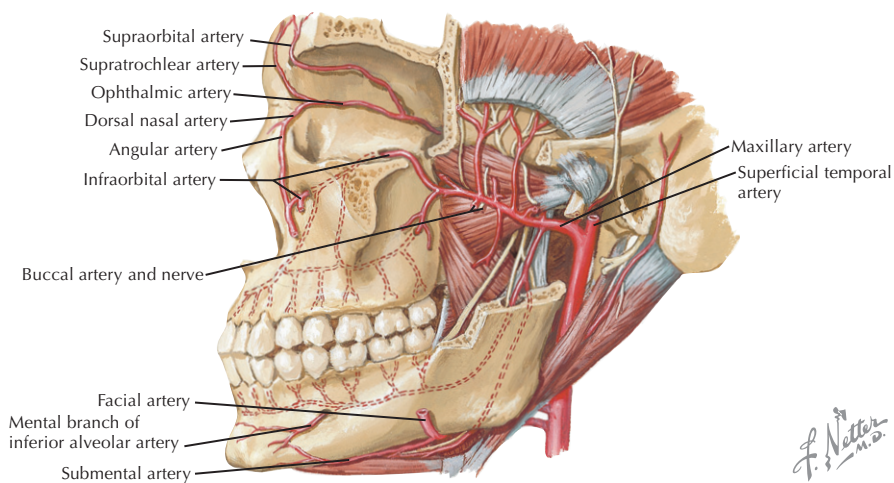
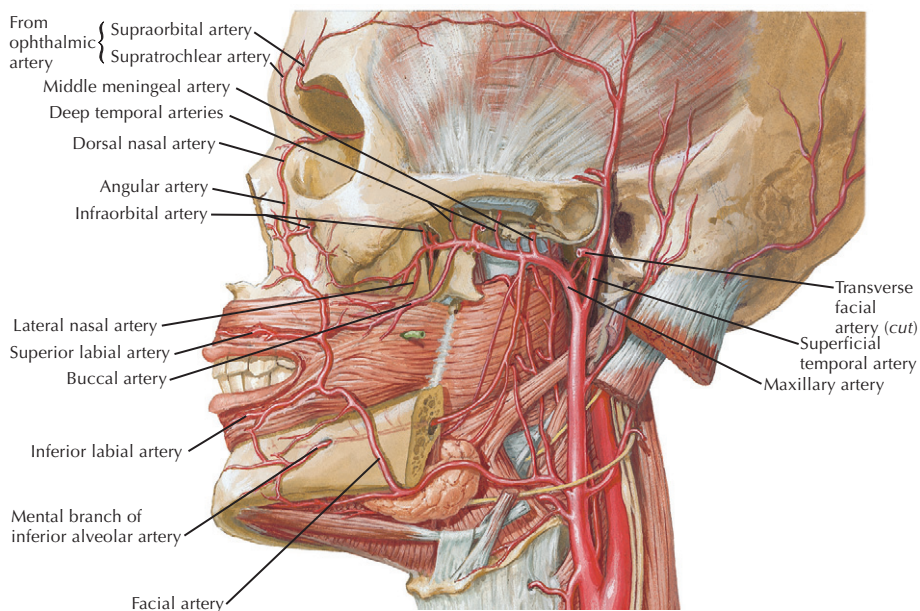
## ARTERIAL SUPPLY

EXTERNAL CAROTID ARTERY AND ITS BRANCHES IN THE FACE		
Artery	Source	Course
Facial	External carotid a.	<p>Arises in the carotid triangle of the neck</p> <p>Passes superiorly immediately deep to the posterior belly of the digastric m. and the stylohyoid mm.</p> <p>Passes along the submandibular gland, giving rise to the submental a. that helps supply the gland</p> <p>Passes superiorly over the body of the mandible at the masseter m.</p> <p>Continues anterosuperiorly across the cheek to the angle of the mouth, giving rise to the <i>superior and inferior labial aa.</i></p> <p>Passes superiorly along the side of the nose, giving rise to the <i>lateral nasal a.</i></p> <p>Continues on the side of the nose as the <i>angular a.</i> to terminate along the medial aspect of the eye</p> <p>Tortuous</p>
<i>Superior labial</i>	Facial a.	Supplies the upper lip Gives rise to the septal branch that travels to the nasal septum
<i>Inferior labial</i>		Supplies the lower lip
<i>Lateral nasal</i>		Supplies the ala and nose
<i>Angular</i>		The facial a.'s terminal branch Passes superiorly to terminate at the medial angle of the orbit
Superficial temporal	External carotid a.	1 of the 2 terminal branches of the external carotid Arises posterior to the neck of the mandible and travels superiorly as a continuation of the external carotid a. Joined by the auriculotemporal n.
<i>Transverse facial</i>	Superficial temporal a.	Passes transversely before it exits the parotid gland Passes immediately superior to the parotid duct across the masseter m. and face
Maxillary	External carotid a.	1 of the 2 terminal branches of the external carotid a. Gives rise to a series of branches; only 3 provide blood supply to the face: the infraorbital, buccal, and mental
<i>Infraorbital</i>	Maxillary a.	<p>The continuation of the 3rd part of the maxillary a.</p> <p>Accompanied by the infraorbital n. and v.</p> <p>Passes forward in the infraorbital groove and infraorbital canal and exits the infraorbital foramen</p> <p>On exiting the infraorbital foramen, it lies between the levator labii superioris and levator anguli oris mm. and follows the branching pattern of the nerve:</p> <p>Inferior palpebral (supplies the lower eyelid)</p> <p>Nasal (supplies the lateral side of the nose)</p> <p>Superior labial (supplies the upper lip)</p>
<i>Buccal</i>		<p>A branch of the 2nd part of the maxillary</p> <p>A small artery that runs obliquely in an anterior direction between the medial pterygoid m. and the insertion of the temporalis m. until it reaches the outer surface of the buccinator m. to supply it and the face</p>
<i>Mental</i>		<p>A terminal branch of the inferior alveolar a., which arises from the 1st part of the maxillary a.</p> <p>Emerges from the mental foramen to supply the chin region</p>



# 5 Vascular Supply of the Face

## ARTERIAL SUPPLY *CONTINUED*



# Vascular Supply of the Face

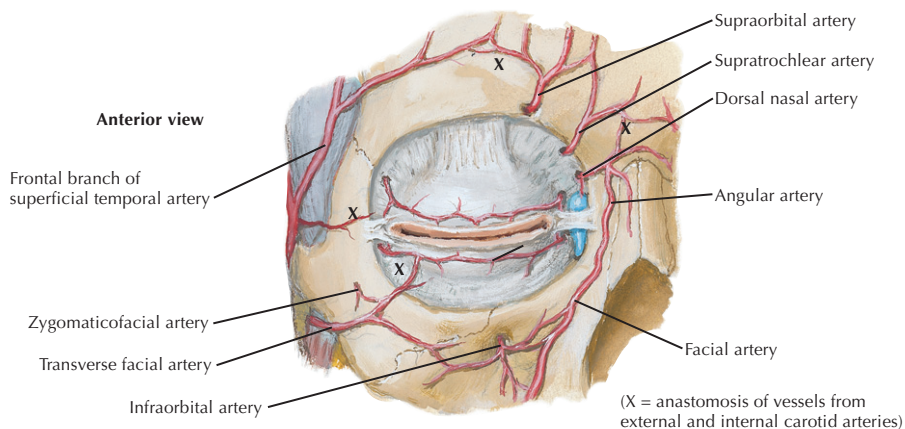
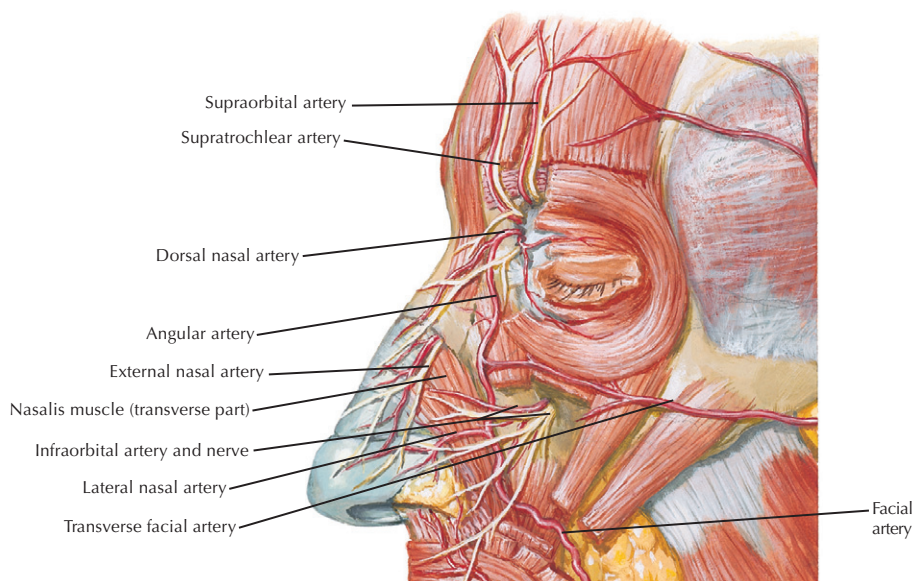
## ARTERIAL SUPPLY

OPHTHALMIC ARTERY AND ITS BRANCHES	
Artery	Course
Ophthalmic	<p>A branch of the internal carotid Enters the orbit through the optic foramen immediately inferior and lateral to the optic n. Crosses the optic n. to reach the medial part of the orbit <i>Within the orbit, besides the orbital branches, it gives rise to 5 major branches that supply the face:</i></p> <ul style="list-style-type: none"> <li>• Supratrochlear</li> <li>• Supraorbital</li> <li>• Lacrimal</li> <li>• Anterior ethmoid</li> <li>• Dorsal nasal</li> </ul>
<i>Supratrochlear</i>	<p>Exits the orbit at the medial angle accompanied by supratrochlear n. Ascends on the scalp, anastomosing with the supraorbital and supratrochlear aa. from the opposite side</p>
<i>Supraorbital</i>	<p>Arises as the ophthalmic passes the optic n. Passes on the medial side of the levator palpebrae superioris and superior rectus mm. to join the supraorbital n. Passes through the supraorbital foramen (notch) and ascends superiorly along the scalp Anastomoses with the supratrochlear and superficial temporal aa.</p>
<i>Lacrimal</i>	<p>Arises near the optic foramen One of the largest branches of the ophthalmic a. Follows the lacrimal n. along the superior border of the lateral rectus m. of the eye to reach and supply the lacrimal gland Gives rise to a series of terminal branches that pass to the eyelids and conjunctivae Gives rise to a zygomatic branch that divides into the zygomaticotemporal and zygomaticofacial aa., to supply those facial regions</p>
<i>External nasal</i>	<p>A terminal branch of the anterior ethmoid a. Supplies the area along the external nose at the junction of the nasal bone and the lateral nasal cartilage</p>
<i>Dorsal nasal</i>	<p>One of the terminal branches of the ophthalmic a. Exits the orbit along the superomedial border along with the infratrochlear n. Supplies the area along the bridge of the nose</p>



# 5 Vascular Supply of the Face

## ARTERIAL SUPPLY *CONTINUED*



*J. Netter M.D.*

# Vascular Supply of the Face

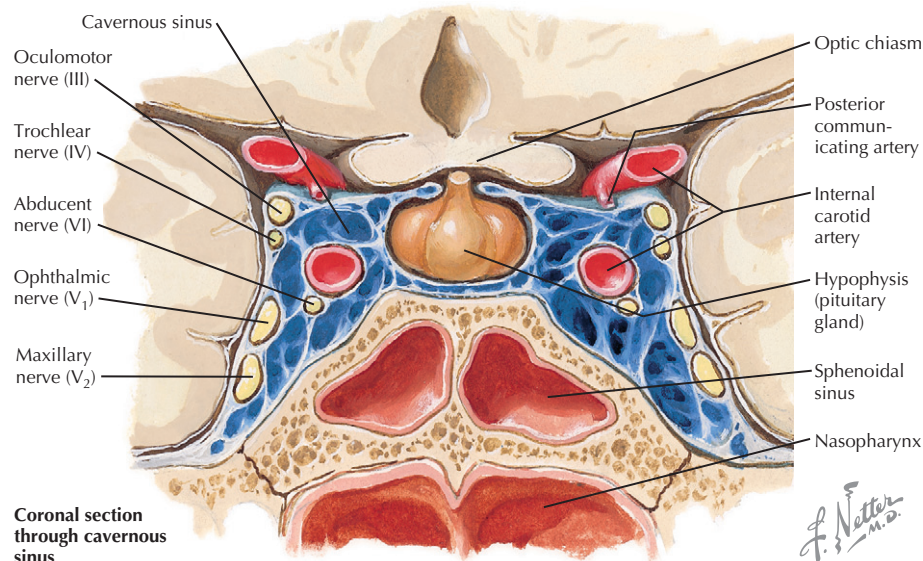
## VENOUS DRAINAGE

Facial veins have similar distribution pattern to that for the arteries

Highly variable

Connect to the deeper vessels such as the pterygoid plexus and cavernous sinus

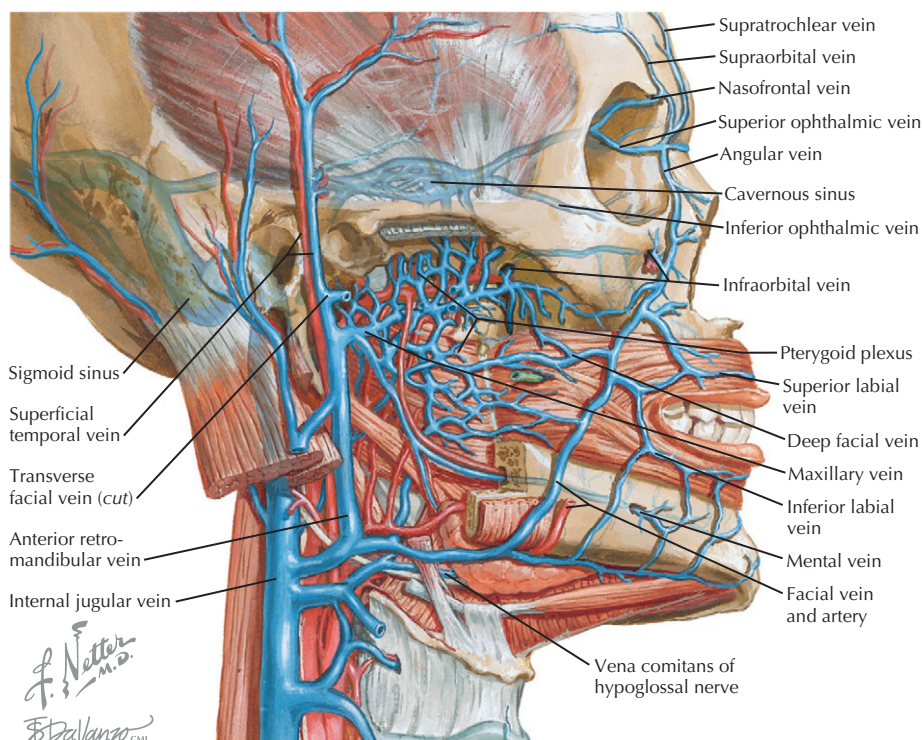
SUPERFICIAL VEINS	
Vein	Course
Facial	Begins as the angular v. Passes inferiorly along the side of the nose, receiving the lateral nasal v. Continues posteroinferiorly across the angle of the mouth to the cheek, receiving the superior and inferior labial vv. While passing toward the mandible, the deep facial v. connects it to the pterygoid plexus In the submandibular triangle, it joins the anterior branch of the retromandibular v. to form the common facial v. Has no valves that can allow blood to backflow
<i>Superior labial</i>	Drains the upper lip and joins the facial v.
<i>Inferior labial</i>	Drains the lower lip and joins the facial v.
<i>Lateral nasal</i>	Drains the ala and nose and joins the facial v.
<i>Angular</i>	Forms from the confluence of the supraorbital and supratrochlear vv. along the medial part of the eye Travels along the lateral aspect of the nose to become the facial v.
Supraorbital	Begins on the forehead, where it communicates with the superficial temporal v. Passes inferiorly superficial to the frontalis m. and joins the supratrochlear v. at the medial angle of the orbit to form the angular v.
Supratrochlear	Begins on the forehead, where it communicates with the superficial temporal v. Passes inferiorly along the forehead parallel with the vein of the opposite side At the medial angle of the orbit, it joins the supraorbital v. to form the angular v.
Superficial temporal	Descends posterior to the zygomatic root of the temporal bone alongside the auriculotemporal n. to enter the substance of the parotid gland Unites with the maxillary v. to form the retromandibular v.
<i>Transverse facial</i>	Travels posteriorly to enter the parotid gland and join the superficial temporal v.
Buccal	Drains the cheek and joins the pterygoid plexus
Mental	Drains the chin and joins the pterygoid plexus



## 5 Vascular Supply of the Face

### VENOUS DRAINAGE *CONTINUED*

COMMUNICATING VEINS	
Vein	Course
Superior ophthalmic	Receives blood from the roof of the orbit and the scalp Travels posteriorly to communicate with the pterygoid plexus and cavernous sinus
Inferior ophthalmic	Receives blood from the floor of the orbit Travels posteriorly with the infraorbital v., which passes through the inferior orbital fissure to communicate with the pterygoid plexus and the cavernous sinus
Infraorbital	Receives blood from the midface via the lower eyelid, lateral aspect of the nose, and the upper lip Eventually communicates with the pterygoid plexus
Deep facial	Connects the facial v. with the pterygoid plexus
DEEP VEINS	
Vein	Course
Cavernous sinus	A reticulated venous structure on the lateral body of the sphenoid bone Drains posteriorly into the superior and inferior petrosal sinuses Receives blood from the superior and inferior ophthalmic vv. The oculomotor and trochlear nn. and ophthalmic and maxillary divisions of the trigeminal n. lie along the lateral wall of the sinus Abducens n. and internal carotid artery lie in the sinus
Pterygoid plexus	An extensive network of veins that parallels the 2nd and 3rd parts of the maxillary a. Receives branches that correspond to the maxillary a.'s branches Tributaries of the pterygoid plexus eventually converge to form a short maxillary v. Communicates with the cavernous sinus, pharyngeal venous plexus, facial v. via the deep facial v., and ophthalmic vv.



# Nerve Supply of the Face

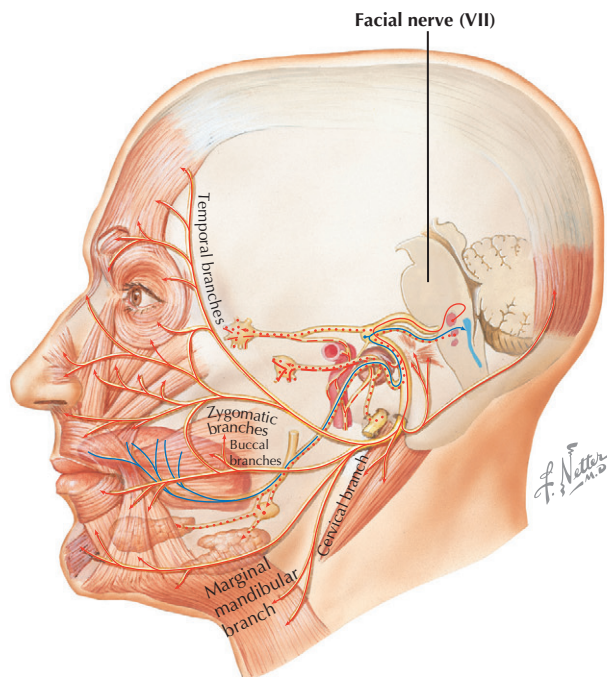
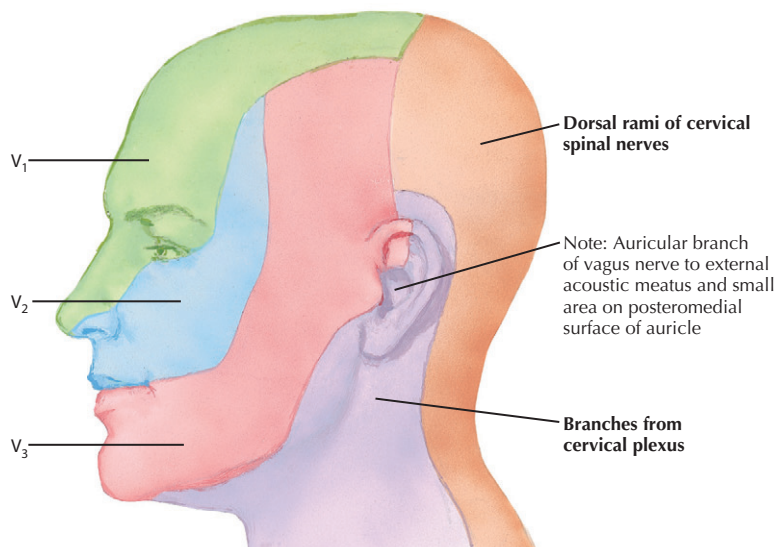
## GENERAL INFORMATION

Many motor and sensory nerves supply the face

All motor nerves are from the facial nerve and supply the muscles of facial expression

Sensory nerves of the face are derived mainly from the 3 divisions of the trigeminal nerve ( $V_1$ ,  $V_2$ ,  $V_3$ )

Some sensory branches are from the cervical plexus





## 5 Nerve Supply of the Face

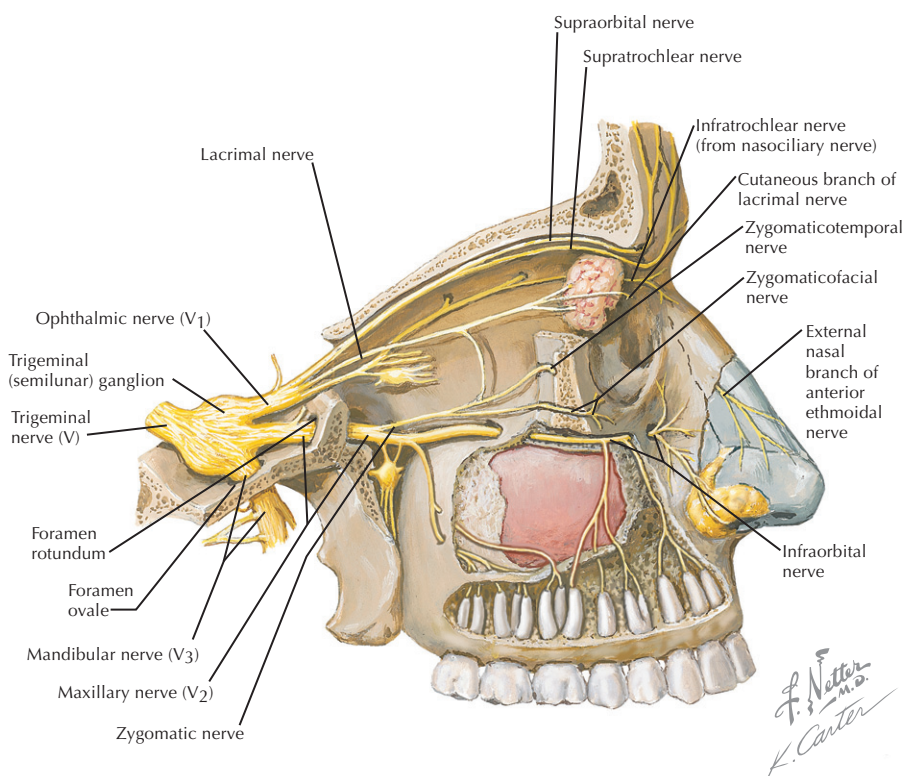
### SENSORY INNERVATION

TRIGEMINAL NERVE: OPHTHALMIC DIVISION		
Nerve	Source	Course
Ophthalmic division	Trigeminal n. in the middle cranial fossa	Passes anteriorly on the lateral wall of the cavernous sinus immediately inferior to the oculomotor and trochlear nn., but superior to the maxillary division of the trigeminal n. Immediately before entering the orbit, through the superior orbital fissure, it divides into 3 major branches: <i>lacrimal</i> , <i>frontal</i> , and <i>nasociliary</i>
<i>Supratrochlear</i>	From the ophthalmic division; the 2 terminal branches of the frontal n. in the orbit	Continues to pass anteriorly toward the trochlea, once the supratrochlear a. joins it within the orbit In the trochlear region, it often supplies the frontal sinus before exiting the orbit Ascends along the scalp, at first deep to the musculature in the region, before piercing it to reach the cutaneous innervation along the scalp
<i>Supraorbital</i>		Passes between the levator palpebrae superioris m. and orbital periosteum Continues anteriorly to the supraorbital foramen (notch) At the level of the supraorbital margin, it sends nerve supply to the frontal sinus and ascends superiorly along the scalp Divides into medial and lateral branches that travel up to the vertex of the scalp
<i>Lacrimal</i>	The smallest branch of the ophthalmic division	Passes anteriorly to enter the orbit through the superior orbital fissure Travels in the orbit on the superior border of the lateral rectus with the lacrimal a. Before reaching the lacrimal gland, it communicates with the zygomatic branch of the maxillary division of the trigeminal n. to receive autonomic nervous fibers Enters the lacrimal gland and supplies it and the conjunctivae before piercing the orbital septum to supply the skin of the upper eyelid
<i>Infratrochlear</i>	One of the terminal branches of the nasociliary	Passes anteriorly on the superior border of the medial rectus m. Passes inferior to the trochlea toward the medial angle of the eye Supplies the skin of the eyelids and bridge of the nose, the conjunctivae, and all of the lacrimal structures
<i>External nasal</i>	Arises from the anterior ethmoid n. (from the nasociliary n.)	Terminal branch of the anterior ethmoid n. Exits between the lateral nasal cartilage and the inferior border of the nasal bone Supplies the skin of the ala and apex of the nose around the nares
TRIGEMINAL NERVE: MAXILLARY DIVISION		
Nerve	Source	Course
Maxillary division	Trigeminal n. in the middle cranial fossa	Travels along the lateral wall of the cavernous sinus Before exiting the middle cranial fossa, it gives off a meningeal branch that innervates the dura mater Passes from the middle cranial fossa into the pterygopalatine fossa via the foramen rotundum Within the pterygopalatine fossa, it gives rise to 4 branches: <i>posterior superior alveolar n.</i> , <i>zygomatic n.</i> , <i>ganglionic branches</i> , and <i>infraorbital n.</i>
<i>Zygomaticotemporal</i>	Zygomatic branch of the maxillary division	Arises from the zygomatic n. in the pterygopalatine fossa, which passes through the inferior orbital fissure to enter the orbit, dividing into the zygomaticotemporal and zygomaticofacial Passes on the lateral wall of the orbit in a groove in the zygomatic bone, then through a foramen in the zygomatic bone to enter the temporal fossa region Within the temporal fossa, it passes superiorly between the bone and the temporalis m. to pierce the temporal fascia superior to the zygomatic arch Continues along the skin of the side of the scalp

# Nerve Supply of the Face

## SENSORY INNERVATION *CONTINUED*

TRIGEMINAL NERVE: MAXILLARY DIVISION <i>CONTINUED</i>		
Nerve	Source	Course
<i>Zygomaticofacial</i>	Zygomatic branch of the maxillary division	Passes on the lateral wall of the orbit before emerging on the face through the zygomaticofacial foramen in the zygomatic bone Supplies the skin on the prominence of the cheek
<i>Infraorbital</i>	The continuation of the maxillary division of the trigeminal n.	Passes through the inferior orbital fissure to enter the orbit, then anteriorly through the infraorbital groove, infraorbital canal, and exits onto the face via the infraorbital foramen Within the infraorbital canal, it gives rise to the anterior superior alveolar and middle superior alveolar nn. It exits onto the face and divides into 3 terminal branches: <ul style="list-style-type: none"> <li>• Inferior palpebral (supplies the skin of the lower eyelid)</li> <li>• Nasal (supplies the ala of the nose)</li> <li>• Superior labial (supplies the skin of the upper lip)</li> </ul>

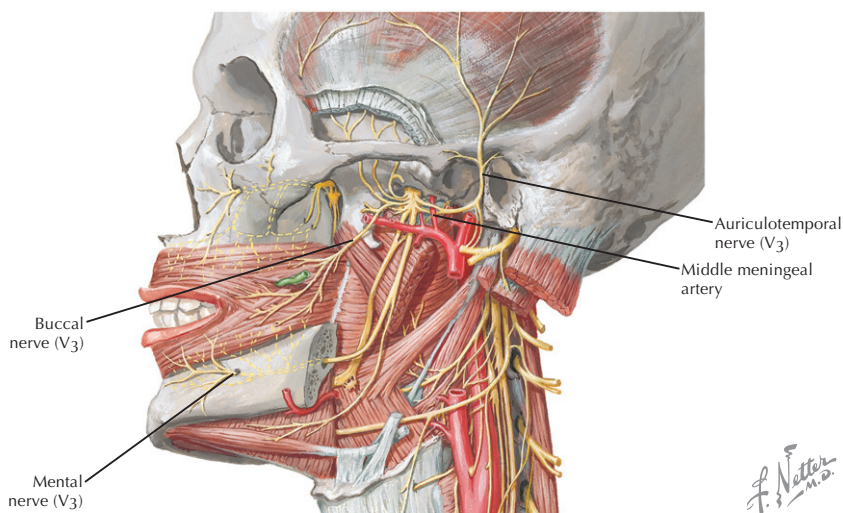




## 5 Nerve Supply of the Face

### SENSORY INNERVATION *CONTINUED*

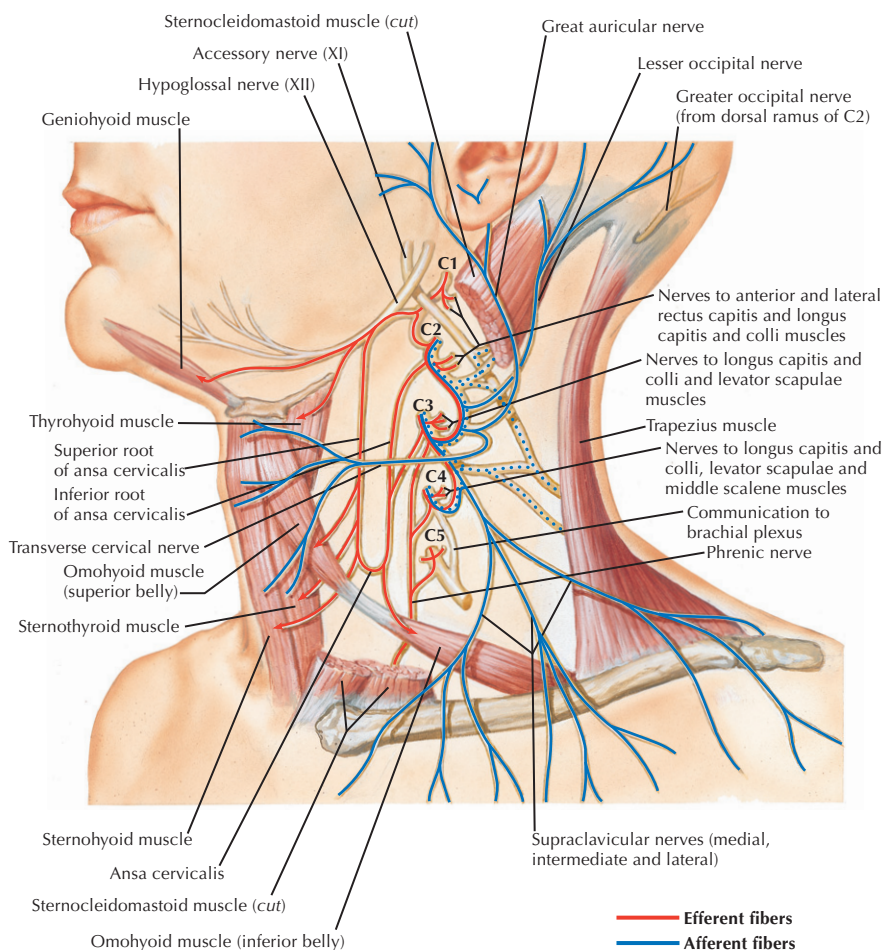
TRIGEMINAL NERVE: MANDIBULAR DIVISION		
Nerve	Source	Course
Mandibular division	Trigeminal n. in the middle cranial fossa	<p>The largest of the trigeminal n.'s 3 divisions Created by a large sensory and a small motor root that unite just after passing through the foramen ovale to enter the infratemporal fossa It immediately gives rise to 4 branches—<i>meningeal</i>, <i>medial pterygoid</i>, <i>tensor tympani</i>, and <i>tensor veli palatini</i>—before it divides into an anterior and a posterior division</p> <ul style="list-style-type: none"> <li>• Anterior division—smaller and mainly motor, with 1 sensory branch (buccal n.)</li> <li>• Posterior division—larger and mainly sensory, with 1 motor branch (mylohyoid n.)</li> </ul>
<i>Auriculo-temporal</i>	Posterior part of mandibular division	<p>Normally arises by 2 roots, between which the middle meningeal a. passes Runs posteriorly just inferior to the lateral pterygoid and continues to the medial aspect of the neck of the mandible Turns superiorly with the superficial temporal vessels between the auricle and the condyle of the mandible deep to the parotid gland On exiting the substance of the parotid gland, it ascends over the zygomatic arch and divides into superficial temporal branches</p>
<i>Buccal</i>	Anterior part of the mandibular division	<p>Passes anterior between the 2 heads of the lateral pterygoid m. Descends inferiorly along the lower part of the temporalis to emerge deep to the anterior border of the masseter m. Supplies the skin over the buccinator m. before passing through it to supply the mucous membrane lining its inner surface and the gingiva along the mandibular molars</p>
<i>Mental</i>	1 of the 2 terminal branches of the inferior alveolar n.	<p>Emerges through the mental foramen of the mandible in the region of the 2nd mandibular premolar Supplies the skin of the lower lip, chin, and facial gingiva as far posteriorly as the 2nd mandibular premolar</p>



# Nerve Supply of the Face

## SENSORY INNERVATION *CONTINUED*

CERVICAL PLEXUS		
Nerve	Source	Course
Great auricular	Arises from the cervical plexus formed by contributions of C2 and C3 ventral rami	After passing posterior to the sternocleidomastoid at Erb's point, it ascends along the sternocleidomastoid dividing into anterior and posterior branches Anterior branch continues along the superficial aspect of the parotid gland's inferior part Innervates the superficial and inferior portions of the parotid gland
Transverse cervical		After passing posterior to the sternocleidomastoid at Erb's point, it crosses the sternocleidomastoid to pass anteriorly toward the neck Perforates the investing layer of deep cervical fascia, dividing deep to the platysma m. into ascending and descending branches Innervates the skin to the anterolateral region of the neck and lower face around the mandible



*F. Netter M.D.*

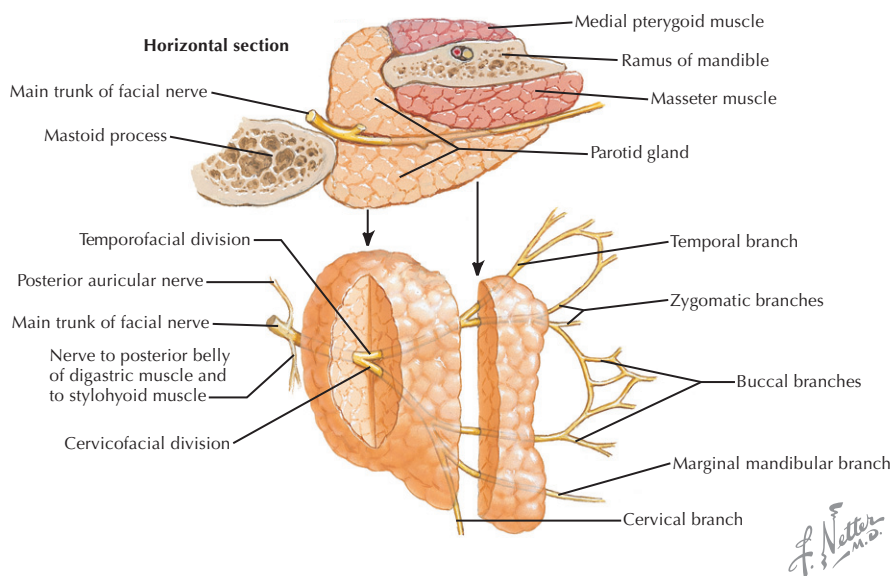
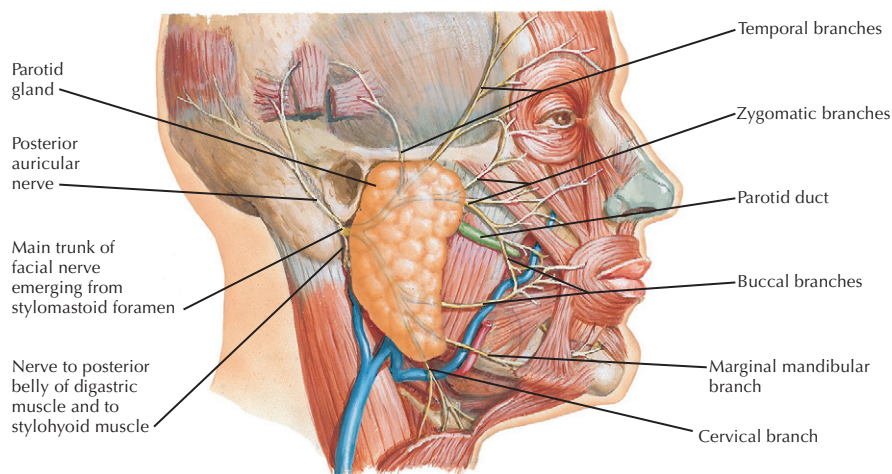
## 5 Nerve Supply of the Face

### MOTOR INNERVATION

Nerve	Course
Facial	<p>Exits the stylomastoid foramen and gives rise to the posterior auricular n.</p> <p>Enters the parotid fossa by passing between the stylohyoid m. and posterior belly of the digastric m.</p> <p>Small muscular branches innervate the stylohyoid m., the posterior belly of the digastric m., and the auricularis mm.</p> <p>Once in the fossa, it splits the parotid gland into a superficial lobe and a deep lobe that are connected by an isthmus</p> <p>Within the gland, it divides into temporofacial and cervicofacial trunks</p> <p>The trunks form a loop anterior to the gland superficial to the parotid duct and give rise to 5 major branches before emerging from the gland: <i>temporal, zygomatic, buccal, mandibular, and cervical</i></p>
<i>Temporal</i>	<p>Exits the superior portion of the parotid gland from the temporofacial trunk</p> <p>Crosses the zygomatic arch along the temporal fossa to innervate the forehead</p>
<i>Zygomatic</i>	<p>The zygomatic branches from the temporofacial trunk pass across the zygomatic bone to the lateral angle of the orbit</p> <p>Innervates muscles in the region</p>
<i>Buccal</i>	<p>Branches arise from both the temporofacial and the cervicofacial trunks</p> <p>Innervates muscles of the cheek</p>
<i>Mandibular</i>	<p>Branches arise from the cervicofacial trunk and pass anteriorly</p> <p>Innervates muscles of the lower lip and chin</p>
<i>Cervical</i>	<p>Branches arise from the cervicofacial trunk and pass anteriorly and inferiorly to innervate the platysma m.</p>

# Nerve Supply of the Face

## MOTOR INNERVATION CONTINUED



## 5 Clinical Correlate

### TRIGEMINAL NEURALGIA

Also called tic douloureux

Usually affects the maxillary ( $V_2$ ) or mandibular ( $V_3$ ) division of the trigeminal nerve; rarely affects the ophthalmic division ( $V_1$ )

Bilateral involvement suggests other factors such as multiple sclerosis

More common in the 5th and 6th decades of life

Cause is unknown—theories involve nerve irritation from abnormal vascularity or tumor compression, or a nerve injury

#### CLINICAL MANIFESTATIONS

Periods of intense (lasting 1 to 2 minutes), paroxysmal pain along one of the divisions of the trigeminal nerve

Usually unilateral

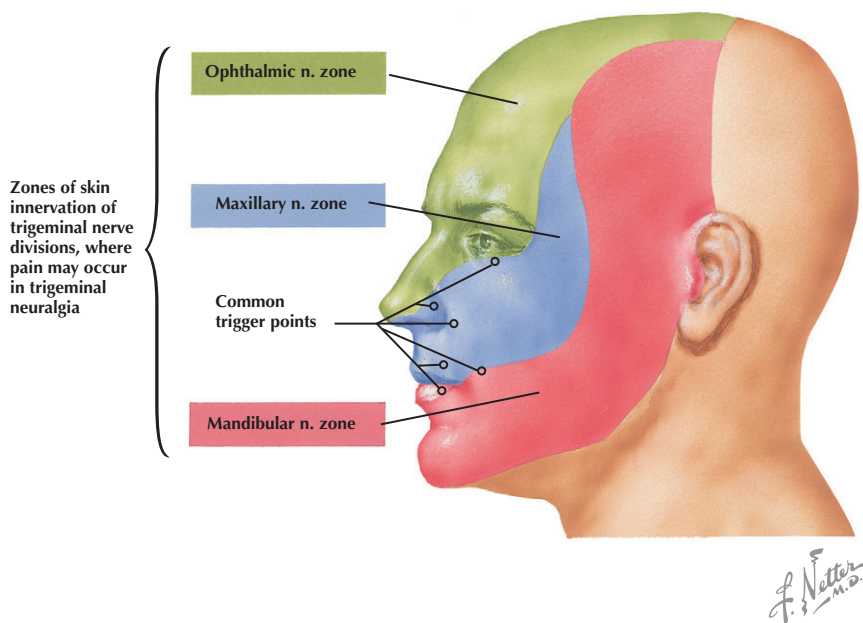
Pain normally is initiated by a particular sensory stimulus, such as light touch (putting on makeup, washing the face, shaving, a light breeze), mastication, or brushing teeth

#### TREATMENT

Commonly, trigeminal neuralgia is treated pharmacologically with anticonvulsants, such as carbamazepine (Tegretol)

If drug therapy is unsuccessful, neurosurgery may be required, such as percutaneous radiofrequency rhizotomy of the nerve, glycerol injection of the trigeminal ganglion, or nerve decompression

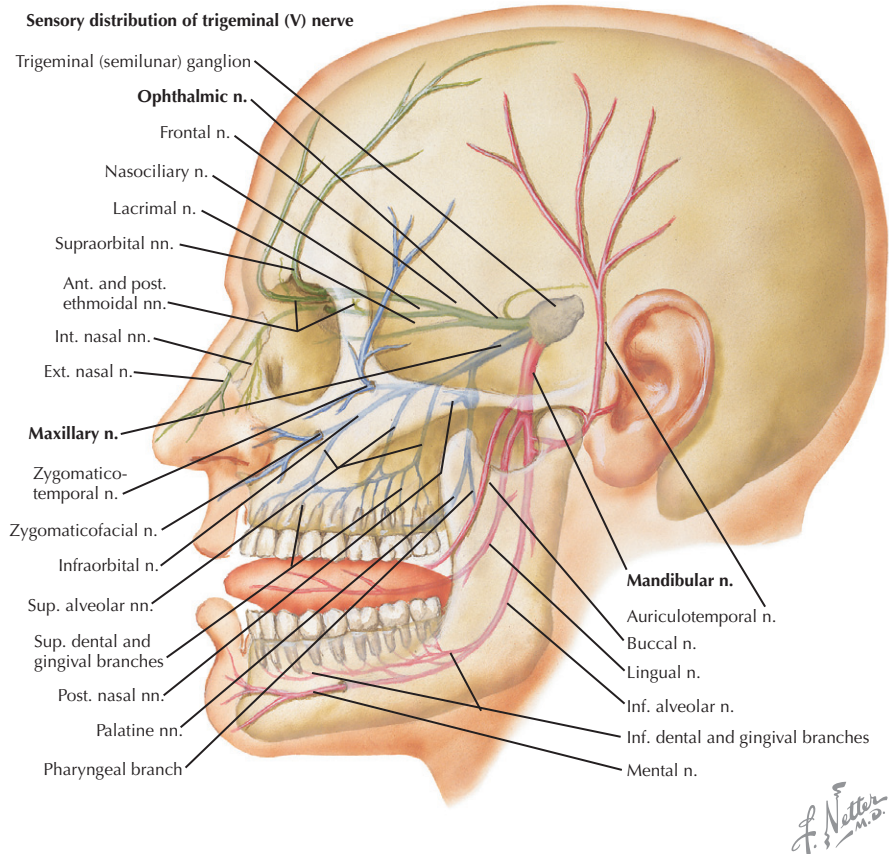
Alternative and complementary medicine treatments have included acupuncture and meditation





# Clinical Correlate

## TRIGEMINAL NEURALGIA *CONTINUED*



## CAVERNOUS SINUS SYNDROME

Pathologic condition involving the cavernous sinus that is often caused by a thrombosis, tumor, aneurysm, fistula, or trauma

When caused by a thrombosis, the syndrome usually occurs as a sepsis from the central portion of the face or paranasal sinuses from their connection to the cavernous sinus

Before the advent of antibiotics, death was the normal outcome from the sepsis

It affects the contents of the cavernous sinus, including:

- Internal carotid artery with sympathetics
- Cranial nerve III
- Cranial nerve IV
- Cranial nerve V<sub>1</sub>
- Cranial nerve V<sub>2</sub>
- Cranial nerve VI

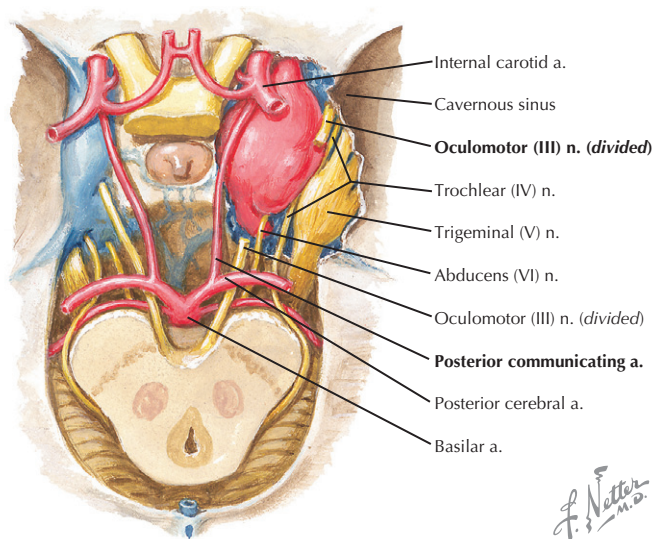
Common clinical manifestations include:

- Ophthalmoplegia with diminished pupillary light reflexes
- Venous congestion leading to periorbital edema
- Exophthalmos



# 5 Clinical Correlate

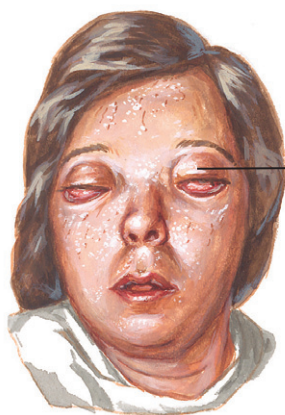## CAVERNOUS SINUS SYNDROME CONTINUED



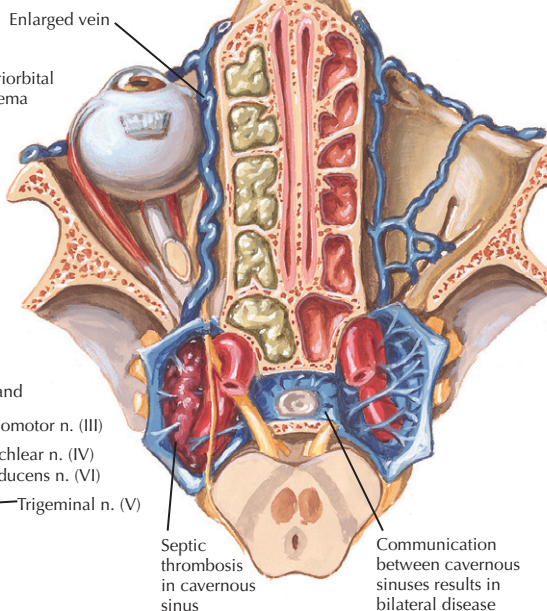
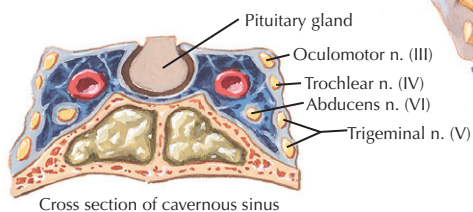
### Cavernous sinus thrombosis

Involvement of cranial nerves (III, IV, V, and VI) results in ophthalmoplegia and facial analgesia

Network of valveless veins allows migration of septic thrombi from sinus or orbit sites to cavernous sinus



Periorbital edema and ophthalmoplegia



JOHN A. CRAIG MD

## CHAPTER 6

# PAROTID BED AND GLAND

Overview and Topographic Anatomy	186
Recess of the Parotid Bed	187
Contents of the Parotid Bed	188
Clinical Correlates	196

## 6 Overview and Topographic Anatomy

### GENERAL INFORMATION

The largest of all the major salivary glands

Entirely serous in secretion

Pyramidal in shape, with up to 5 processes (or extensions)

The gland's capsule is from the deep cervical fascia

### ANATOMIC LANDMARKS

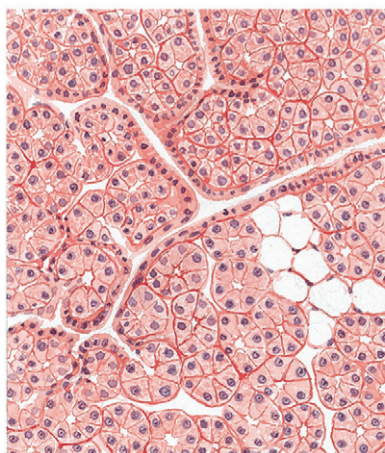
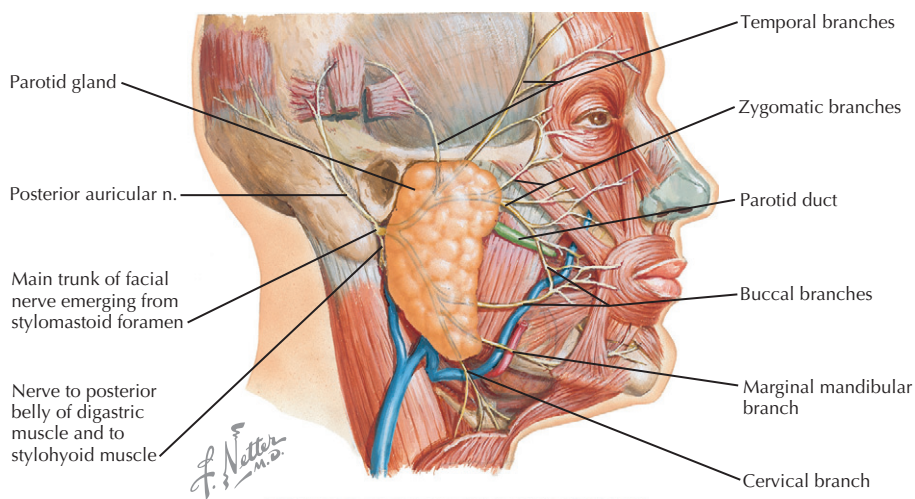
Approximately 75% or more of the parotid gland overlies the masseter muscle; the rest is retromandibular

Facial nerve enters the parotid fossa by passing between the stylohyoid muscle and the posterior belly of the digastric muscle, then splits the gland into a superficial lobe and a deep lobe that are connected by an isthmus

Deep lobe lies adjacent to the lateral pharyngeal space

Transverse facial artery parallels the parotid duct slightly superior to the duct

Buccal and zygomatic branches of the facial nerve form an anastomosing loop superficial to the parotid duct

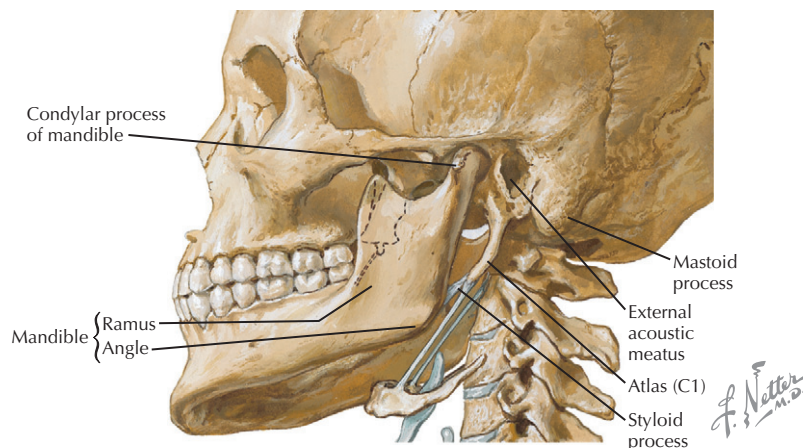


Parotid gland: totally serous

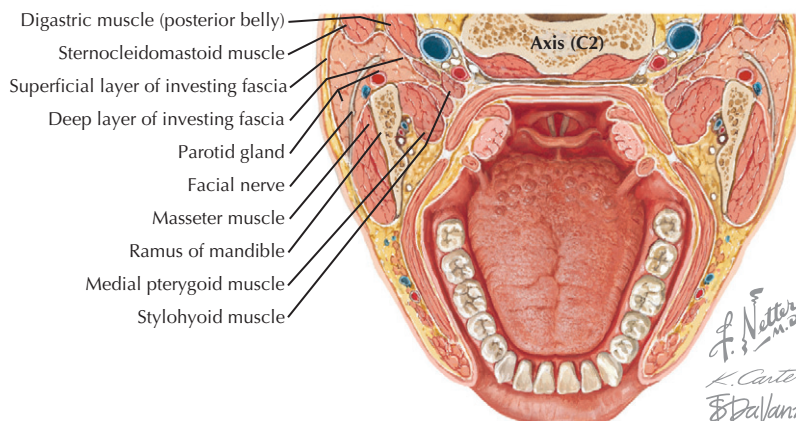
# Recess of the Parotid Bed

## BORDERS AND STRUCTURES

Borders	Structures
Anterior	Masseter m. Ramus of mandible
Anteromedial	Medial pterygoid m. Stylomandibular fascia
Medial	Styloid process superomedially Transverse process of the atlas inferomedially
Posteromedial	Stylohyoid m. Posterior belly of the digastric m.
Posterior	Mastoid process of the temporal bone Sternocleidomastoid m.
Lateral	Investing layer of deep cervical fascia helping form the capsule
Superior	External acoustic meatus Condylar head of the mandible articulating in the glenoid fossa
Inferior	Angular tract of Eisler between the angle of the mandible and the sternocleidomastoid m.



**Horizontal section below lingula of mandible (superior view) demonstrating bed of parotid gland**



## 6 Contents of the Parotid Bed

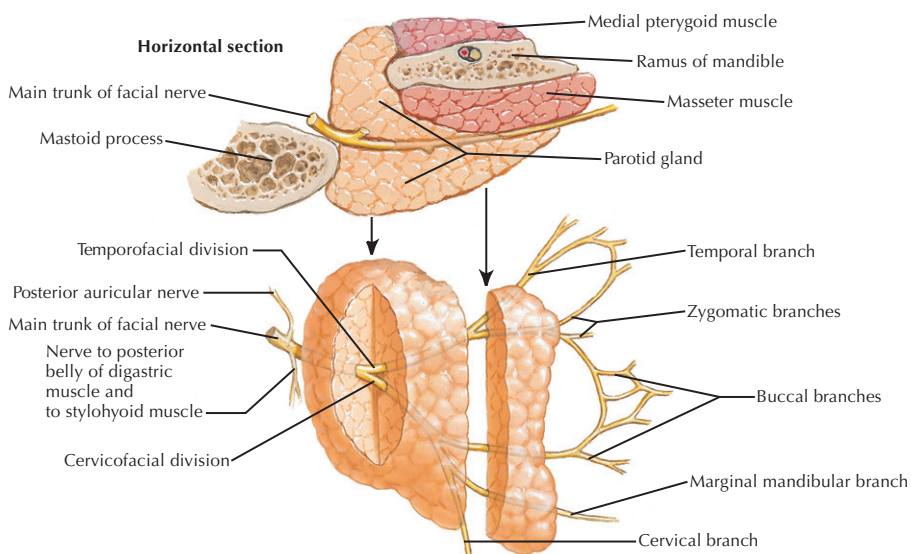
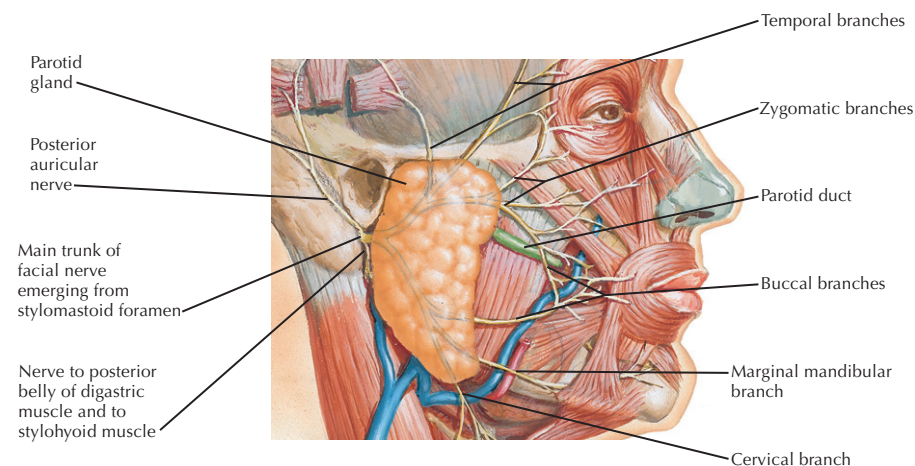
### MAJOR STRUCTURES

Structure	Features
Parotid gland	<p>The largest of all of the major salivary glands, entirely serous in secretion</p> <p>Pyramidal in shape, with up to 5 processes (or extensions)</p> <p>The gland's capsule is from the deep cervical fascia</p> <p>About 75% or more of the parotid gland overlies the masseter m.; the rest is retromandibular</p>
Facial nerve	<p>Facial n. exits the stylomastoid foramen and gives rise to the posterior auricular n.</p> <p>Enters the parotid fossa by passing between the stylohyoid m. and the posterior belly of the digastric m.</p> <p>Small muscular branches innervate the stylohyoid m., the posterior belly of the digastric m., and the auricularis mm.</p> <p>Once in the fossa, it splits the parotid gland into a superficial lobe and a deep lobe that are connected by an isthmus</p> <p>Parotid gland's deep lobe lies adjacent to the lateral pharyngeal space</p> <p>Within the gland, the facial n. divides into temporofacial and cervicofacial trunks</p> <p>The trunks form a loop anterior to the gland superficial to the parotid duct and give rise to 5 major branches before emerging from the gland: temporal, zygomatic, buccal, mandibular, and cervical</p> <p>Although it passes through the parotid gland, the facial n. does not provide any innervation to it</p> <p>Buccal and zygomatic branches of the facial n. form an anastomosing loop superficial to the parotid duct</p>
Parotid duct	<p>Also known as Stensen's duct</p> <p>Forms within the deep lobe and passes from the anterior border of the gland across the masseter superficially, through the buccinator into the oral cavity opposite the 2nd maxillary molar</p> <p>Accessory parotid tissue often follows the parotid duct</p>



# Contents of the Parotid Bed

## MAJOR STRUCTURES *CONTINUED*



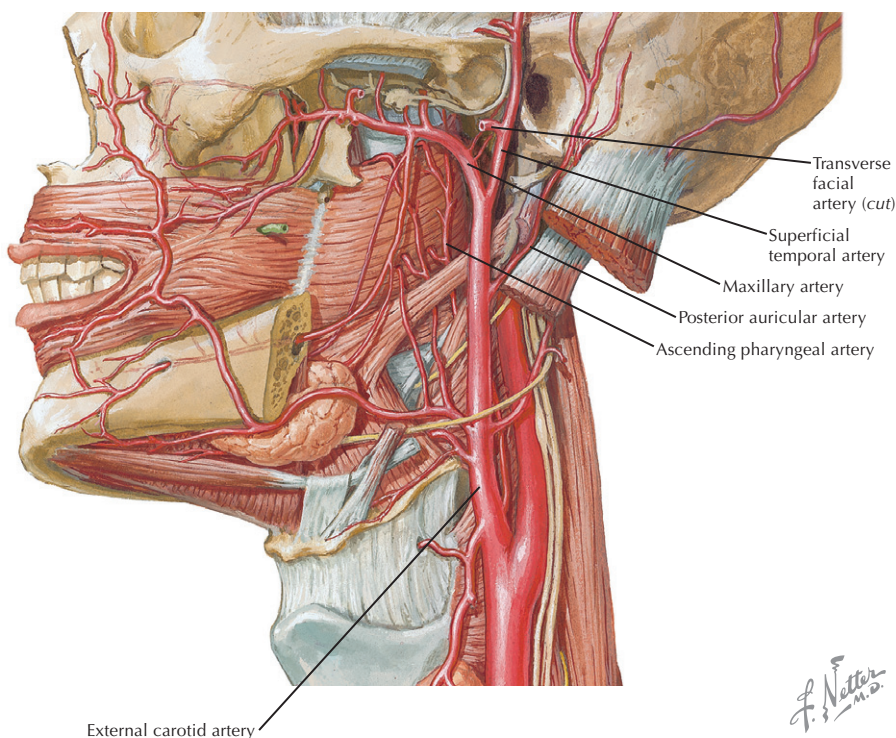
*F. Netter M.D.*



## 6 Contents of the Parotid Bed

### VASCULAR SUPPLY

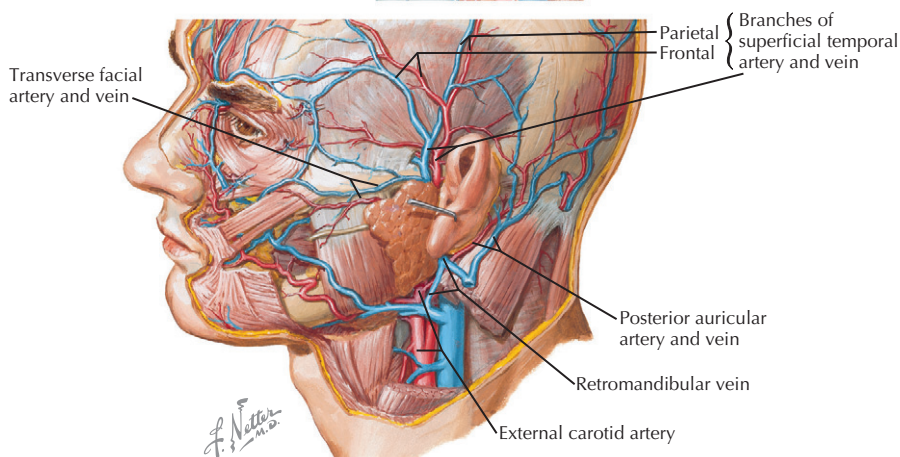
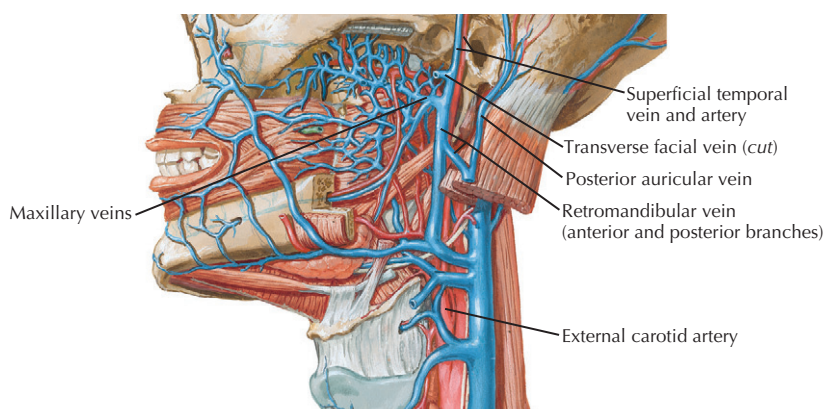
ARTERIAL SUPPLY		
Artery	Source	Course
External carotid	The bifurcation of the common carotid a. at vertebral level C3	Ascends superiorly posterior to the mandible and deep to the posterior belly of the digastric m. and the stylohyoid m. to enter the parotid gland Within the parotid gland, it gives branches to the gland and the posterior auricular a. Then branches into the superficial temporal and maxillary aa. within the gland The transverse facial a. arises from the superficial temporal a. within the gland
Posterior auricular	External carotid a. within the parotid gland	Passes superiorly between the mastoid process and cartilage of the ear
Maxillary	The 2 terminal branches of the external carotid a.	Begins posterior to the neck of the mandible and travels anteromedially between the sphenomandibular lig. and the ramus of the mandible On exiting the parotid gland, passes either superficial or deep to the lateral pterygoid muscle
Superficial temporal		Begins posterior to the neck of the mandible and travels superiorly as a continuation of the external carotid Joined by the auriculotemporal n.
Transverse facial	Superficial temporal a. before it exits the parotid gland	Passes transversely to exit the gland Passes immediately superior to the parotid duct across the masseter m. and face



# Contents of the Parotid Bed

## VASCULAR SUPPLY CONTINUED

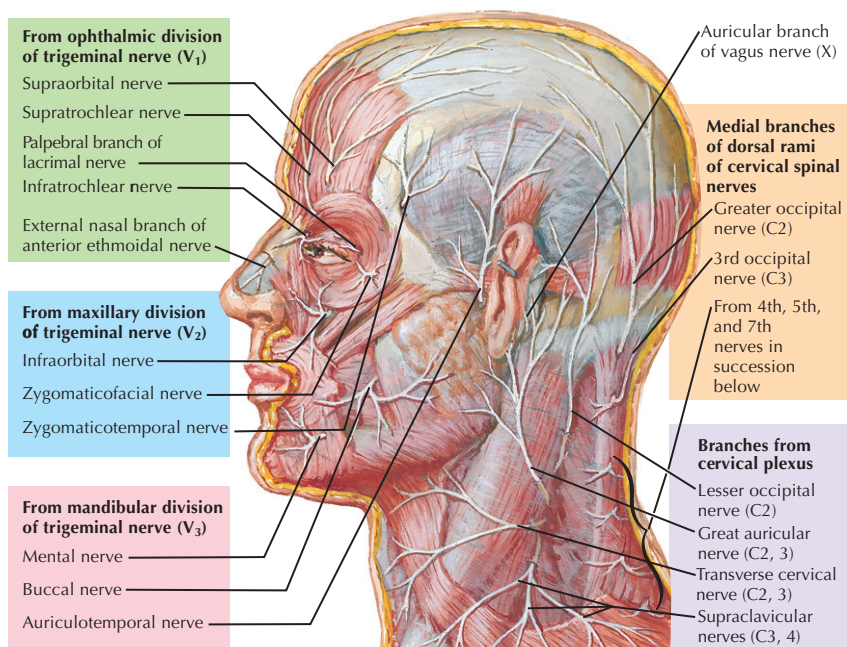
VENOUS DRAINAGE	
Vein	Course
Superficial temporal	Descends posterior to the zygomatic root of the temporal bone alongside the auriculotemporal n. to enter the parotid gland Unites with the maxillary v. to form the retromandibular v.
Transverse facial	Travels posteriorly to enter the parotid gland and join the superficial temporal v.
Maxillary	A short, sometimes paired vein, formed by the convergence of the tributaries of the pterygoid plexus Enters the parotid gland traveling posteriorly between the sphenomandibular lig. and the neck of the mandible Unites with the superficial temporal v. to form the retromandibular v.
Retromandibular	Arises from the joining of the superficial temporal and maxillary vv. within the parotid gland Descends superficial to the external carotid a. in the gland, where it branches into the anterior and posterior divisions of the retromandibular vv.
Posterior auricular	Arises from a plexus of veins created by the occipital and superficial temporal vv. Descends posterior to the auricle to unite with the posterior division of the retromandibular v. to form the external jugular v.



## 6 Contents of the Parotid Bed

### NERVE SUPPLY

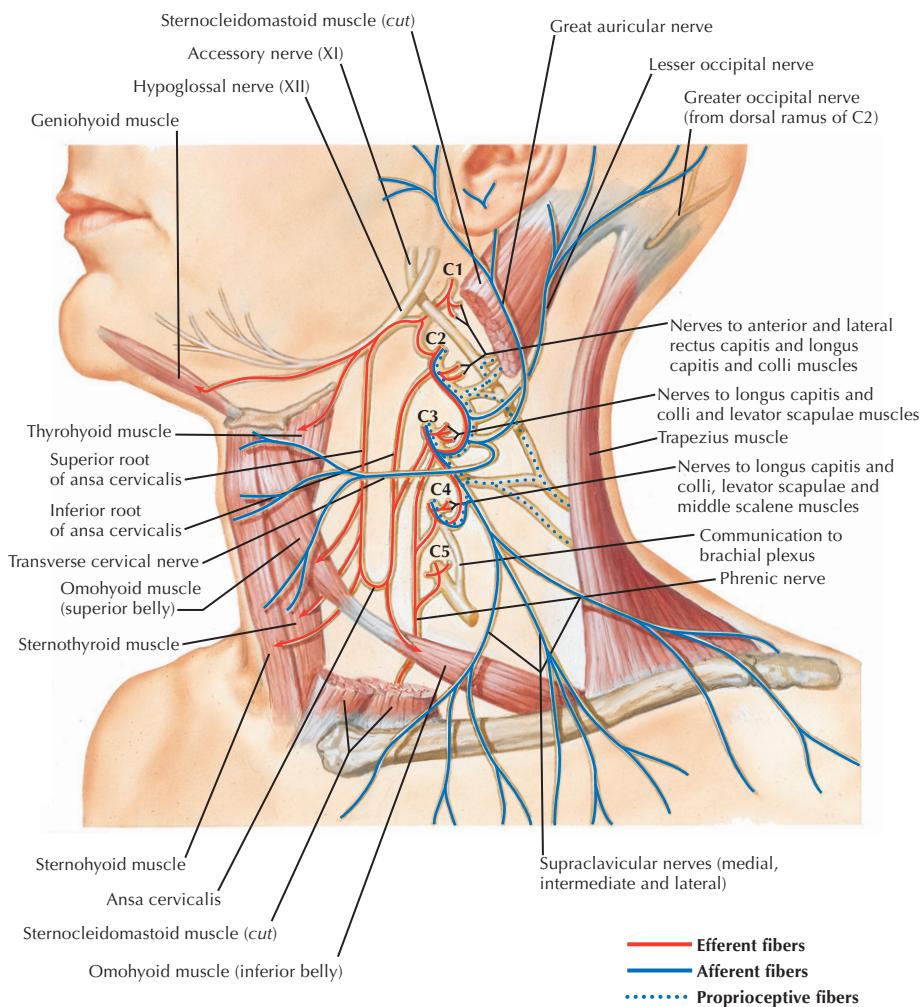
SENSORY NERVES OF THE PAROTID		
Nerve	Source	Course
Auriculotemporal	Mandibular division of the trigeminal n.	Often arises as 2 roots surrounding the middle meningeal a. that unite Passes inferior to the lateral pterygoid toward the neck of the mandible Passes posterior to the neck of the mandible to ascend with the superficial temporal a. Supplies the parotid gland's deep and superior portions
Great auricular	The cervical plexus formed by contributions of C2 and C3 ventral rami	After passing posterior to the sternocleidomastoid at Erb's point, it ascends along the sternocleidomastoid m., dividing into anterior and posterior branches The anterior branch continues along the superficial aspect of the inferior part of the parotid gland Supplies the parotid gland's superficial and inferior portions



*f. Netter M.D.*

# Contents of the Parotid Bed

## NERVE SUPPLY *CONTINUED*



*F. Netter M.D.*



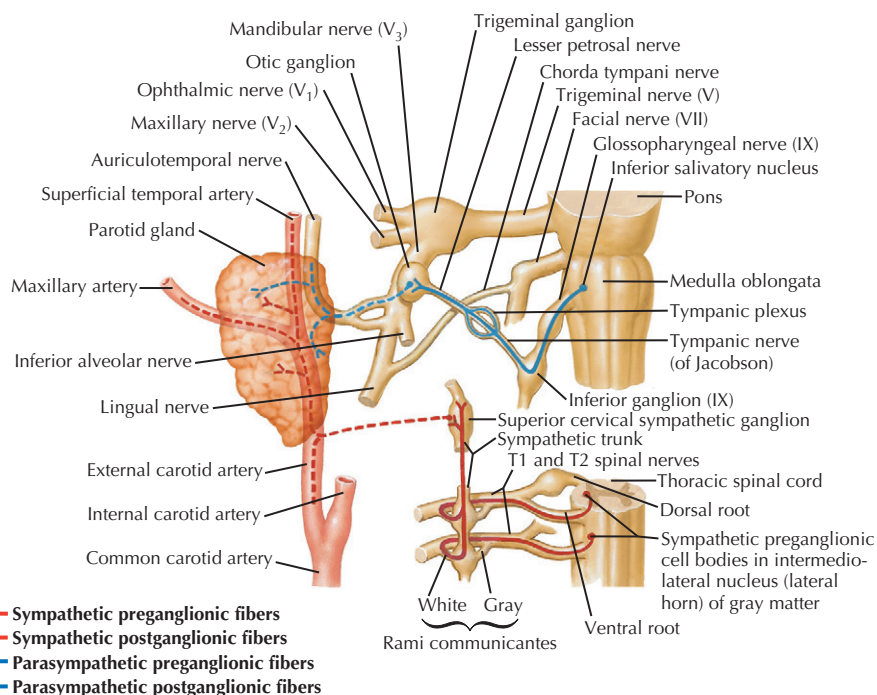
## 6 Contents of the Parotid Bed

### NERVE SUPPLY *CONTINUED*

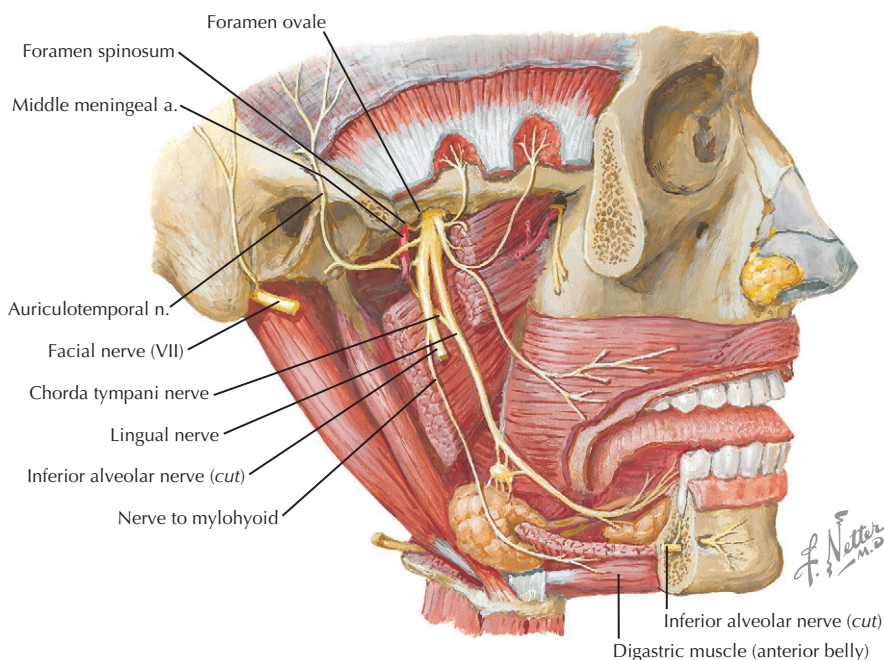
ANATOMIC PATHWAY FOR PARASYMPATHETICS OF THE PAROTID GLAND			
Type of Neuron	Name of Cell Body	Characteristics of the Cell Body	Course of the Neuron
Preganglionic neuron	Inferior salivatory nucleus	A collection of nerve cell bodies located in the medulla	Preganglionic parasympathetic fibers arise from the inferior salivatory nucleus in the medulla These fibers travel through the glossopharyngeal n. and exit the jugular foramen Gives rise to the tympanic branch of IX, which reenters the skull via the tympanic canaliculus Tympanic branch of IX forms the tympanic plexus along the promontory of the ear The plexus re-forms as the lesser petrosal n., typically exiting the foramen ovale to enter the infratemporal fossa Lesser petrosal n. joins the otic ganglion
Postganglionic neuron	Otic ganglion	A collection of nerve cell bodies located inferior to the foramen ovale medial to the mandibular division of the trigeminal n.	Postganglionic parasympathetic fibers arise in the otic ganglion These fibers travel to the auriculotemporal branch of the trigeminal n. Auriculotemporal n. travels to the parotid gland Postganglionic parasympathetic fibers innervate the parotid gland
ANATOMIC PATHWAY FOR SYMPATHETICS OF THE PAROTID GLAND			
Type of Neuron	Name of Cell Body	Characteristics of the Cell Body	Course of the Neuron
Preganglionic neuron	Intermediolateral horn nucleus	Collection of nerve cell bodies located in the lateral horn nucleus of the spinal cord between spinal segments T1 and T3 (and possibly T4)	Arise from the intermediolateral horn nuclei from T1 and T3(4) Travel through the ventral root of the spinal cord to the spinal nerve Enter the sympathetic chain via white rami communicantes Once in the sympathetic chain, the preganglionic fibers for the eye will ascend and synapse with postganglionic fibers in the superior cervical ganglion
Postganglionic neuron	Superior cervical ganglion	Collection of nerve cell bodies located in the superior cervical ganglion, which is located at the base of the skull	Arise in the superior cervical ganglion Postganglionic fibers will follow the external carotid a. Branches from the external carotid follow the arteries that supply the parotid gland

# Contents of the Parotid Bed

## NERVE SUPPLY *CONTINUED*



### Lateral view





## 6 Clinical Correlate

### BELL'S PALSY

Unilateral facial paralysis from facial nerve (cranial nerve VII) damage

#### CAUSES

Approximately 80% of cases have unclear etiology

Evidence suggests herpes simplex virus (HSV-1) infection is a cause

- *Proposed mechanism:* When the virus becomes active at the facial nerve, if the inflammation is in the bony facial canal, limited room for expansion results in nerve compression

Bacterial infections also have been implicated

- In some cases of otitis media, bacteria may enter the facial canal, and any resulting inflammatory response could compress the facial nerve

Temporary Bell's palsy can result from dental procedures if inferior alveolar nerve block anesthetic is improperly administered in the parotid fossa; signs and symptoms disappear when the anesthetic effects wear off

#### PROGNOSIS

Mild cases produce a facial nerve neurapraxia; the prognosis for complete recovery is very good, usually within 2 to 3 weeks

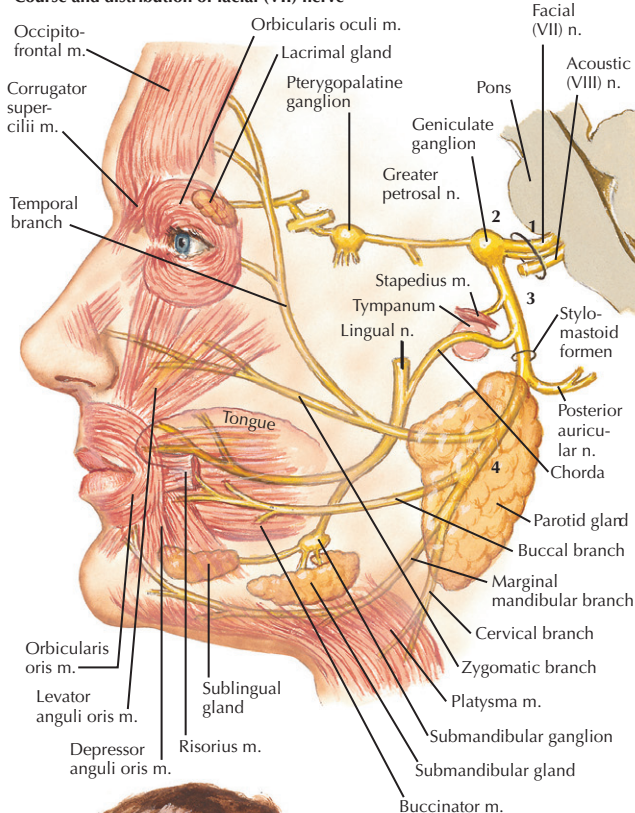
In more moderate cases, an axonotmesis may occur, producing wallerian degeneration; full recovery may take 2 to 3 months

In a small percentage of cases, function is never completely recovered

# Clinical Correlate

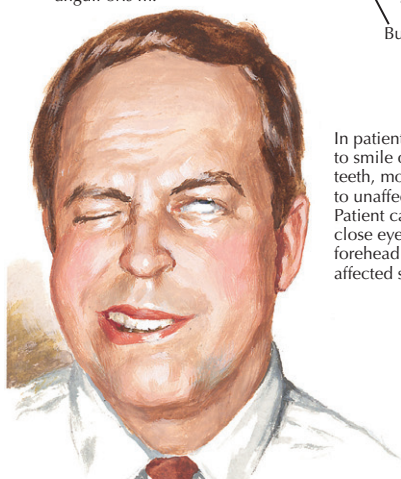
## BELL'S PALSY CONTINUED

### Course and distribution of facial (VII) nerve



### Sites of lesions and their manifestations

- 1. Intracranial and/or internal auditory meatus.**  
All symptoms of 2, 3, and 4, plus deafness due to involvement of eighth cranial nerve.
- 2. Geniculate ganglion.**  
All symptoms of 3 and 4, plus pain behind ear. Herpes of tympanum and of external auditory meatus may occur.
- 3. Facial canal.**  
All symptoms of 4, plus loss of taste in anterior tongue and decreased salivation on affected side due to chorda tympani involvement. Hyperacusis due to effect on nerve branch to stapedius muscle.
- 4. Below stylomastoid foramen (parotid gland tumor, trauma)**  
Facial paralysis (mouth draws to opposite side; on affected side, patient unable to close eye or wrinkle forehead; food collects between teeth and cheek due to paralysis of buccinator muscle).



In patient's attempts to smile or bare teeth, mouth draws to unaffected side. Patient cannot wink, close eye, or wrinkle forehead on affected side.

*F. Netter M.D.*



Hyperacusis: patient holds phone away from ear because of painful sensitivity to sound

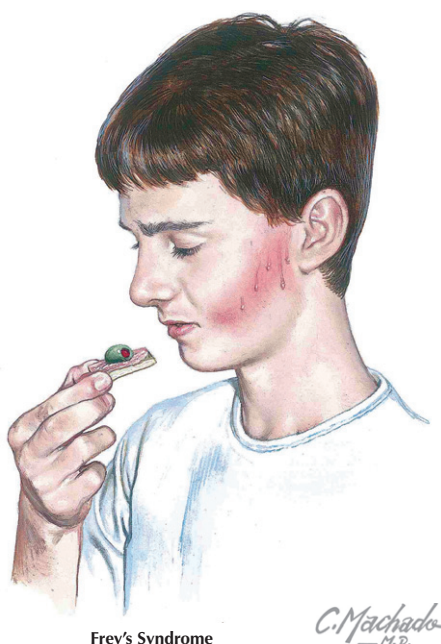## 6 Clinical Correlate

### FREY'S SYNDROME

Caused by regeneration of the auriculotemporal autonomic fibers in an abnormal fashion, innervating the sweat glands near the parotid gland after a parotidectomy. Symptoms include sweating and redness in the distribution of the auriculotemporal nerve during eating.

Diagnosis is via Minor's starch iodine test—creates a dark spot over the gustatory sweating area.

Treatments include tympanic neurectomy (severing the parasympathetic component) and the topical anticholinergic glycopyrrolate (Robinul).



Frey's Syndrome

## Clinical Correlate

### TUMORS OF THE PAROTID GLAND

80% of parotid tumors are benign

The most common benign tumor is a pleomorphic adenoma, which, if present for many years, can convert to a highly malignant carcinoma

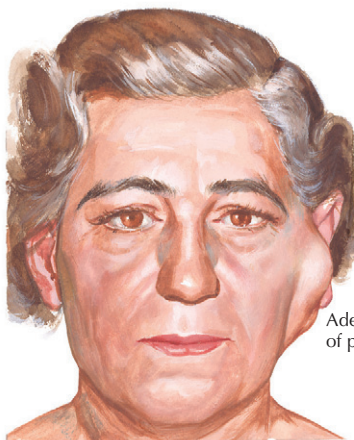
When pleomorphic adenomas extend through the capsule, they must be removed to reduce recurrence

Because of the proximity, these tumors can extend into the lateral pharyngeal space

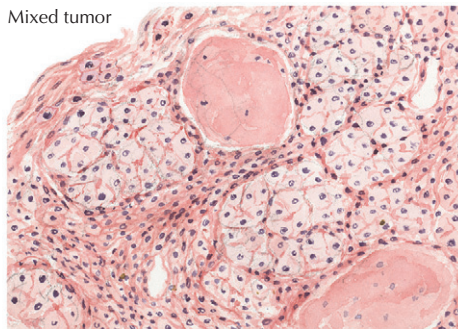
Removal of the tumor with its surrounding capsule and tissue is important to obtain a low recurrence rate

- Histologically, pleomorphic adenomas have extensions through the tumor capsule into adjacent tissue, so simple enucleation would allow recurrence from tumor cells left behind

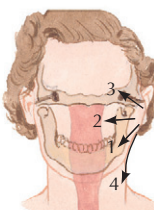
Lymphosarcoma



Mixed tumor

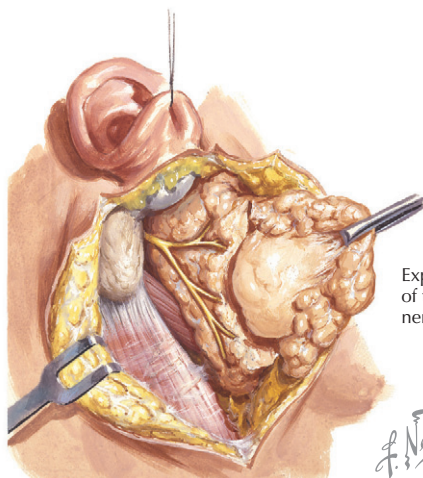


Adenocarcinoma of parotid gland



Local spread of carcinoma of parotid

1. Mandible
2. Pharynx
3. Base of skull and middle ear
4. Cervical lymph nodes



Exposure and resection of tumor sparing facial nerve branches

## 6 Clinical Correlate

### PAROTITIS/MUMPS

An inflammation of the parotid glands that typically is caused by a bacterial or viral infection

Can also be caused by other diseases, such as Sjögren's syndrome, tuberculosis, and human immunodeficiency virus (HIV) infection

Pain through mandibular movement is the result of the compression of the deep lobe of the gland by the mandibular ramus

#### BACTERIAL PAROTITIS

Less common since the introduction of antibiotics, proper hydration, and better oral hygiene

Mortality rate in the early 19th century was as high as 70% to 80%

Most cases now seen in patients on anticholinergic medication, especially the elderly, because it inhibits the salivary flow, which makes it easier for the bacteria to be transported in retrograde fashion along the parotid duct into the gland, where they may settle to cause an infection

#### VIRAL PAROTITIS

Known as mumps

Causative virus is a paramyxovirus that infects different body parts, notably the parotid glands

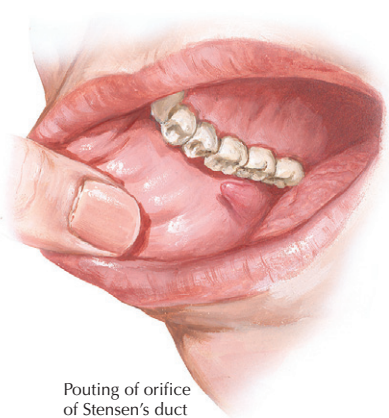
Usually is spread through saliva, coughing, and sneezing

Parotid glands typically swell and become very painful

With the introduction of mumps vaccination in the 1970s, now rare in most developed nations



Parotitis  
(obstruction or  
ascending infection)



Pouting of orifice  
of Stensen's duct

*F. Netter M.D.*



## Clinical Correlate

### XEROSTOMIA

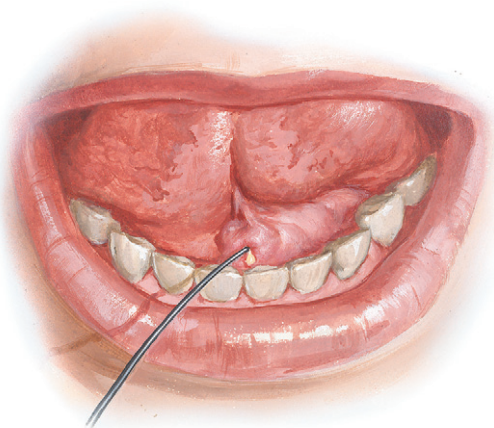
*Xerostomia*: "dry mouth"

Dry mouth is a symptom that increases the affected person's susceptibility to dental caries

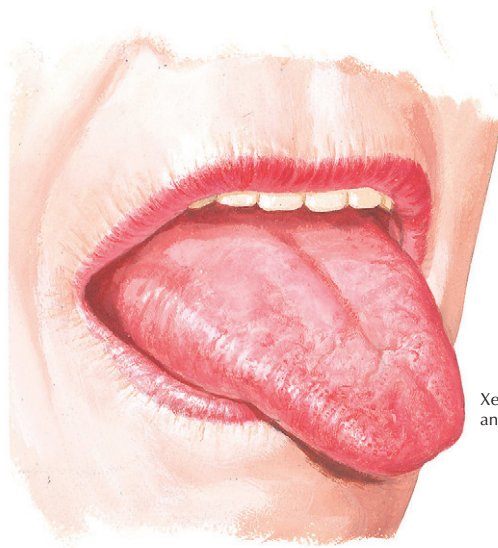
Can be caused by any medication that reduces salivary outflow, commonly: many antihistamines, antidepressants, chemotherapeutic agents (including radiation therapy), antihypertensives, and analgesics

Occurs in disease processes such as depression, stress, endocrine disorders, Sjögren's syndrome, and improper nutrition

Can lead to the formation of sialoliths, calculi that form in the duct or gland, although they are more commonly associated with infections of the submandibular gland than of the parotid gland and duct



Calculus in Wharton's duct  
probe inserted  
and drop of pus  
exuding



Xerostomia  
and glossitis

*F. Netter M.D.*



## 6 Clinical Correlate

### FISTULAS AND SIALOCELES

**Parotid fistula:** a communication between the skin and the parotid gland or duct that may lead to the formation of a *sialocele*, a cyst filled with a collection of mucoid saliva in the tissues surrounding the gland

#### CAUSES

Both parotid fistulas and sialoceles often occur as the result of trauma

May also be caused by:

- Section or injury of the duct or one of its branches during operation for cancer of the cheek or face
- Removal of parotid tumors, especially those of the accessory lobe
- Primary or secondary malignant tumors that ulcerate the skin
- Incision and drainage for acute bacterial parotitis
- Ulceration and infection associated with large salivary calculi
- Fistula may develop after a mastoid or fenestration operation
- Congenital
- Infection (actinomycosis, tuberculosis, syphilis, cancrum oris)

#### TREATMENT

Fistulas that lead directly into the oral cavity need no treatment

Fistulas on the skin may or may not need surgical intervention

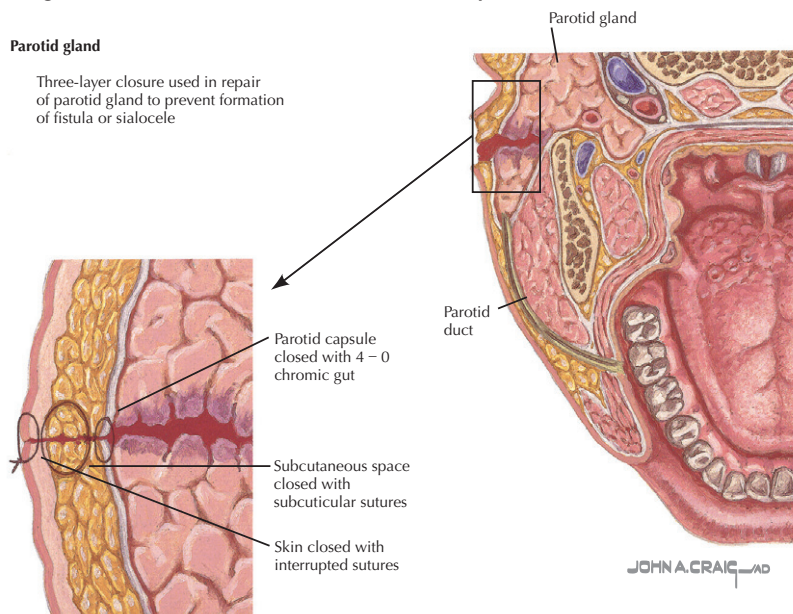
Anticholinergics are useful agents to diminish the salivation during treatment

Sialoceles often resolve with aspiration or compression and normally do not require drain placement

Injury to the parotid gland or duct should be repaired to prevent formation of fistulas and sialoceles

#### 3 COMMON REPAIRS

- Repair of the duct using a stent
- Ligation of the duct
- Creating a fistula from the duct into the oral cavity



## CHAPTER 7

# TEMPORAL AND INFRATEMPORAL FOSSAE

Overview and Topographic Anatomy	204
Borders of the Temporal Fossa	205
Contents of the Temporal Fossa	206
Borders of the Infratemporal Fossa	210
Contents of the Infratemporal Fossa	212

# 7 Overview and Topographic Anatomy

## GENERAL INFORMATION

### TEMPORAL FOSSA

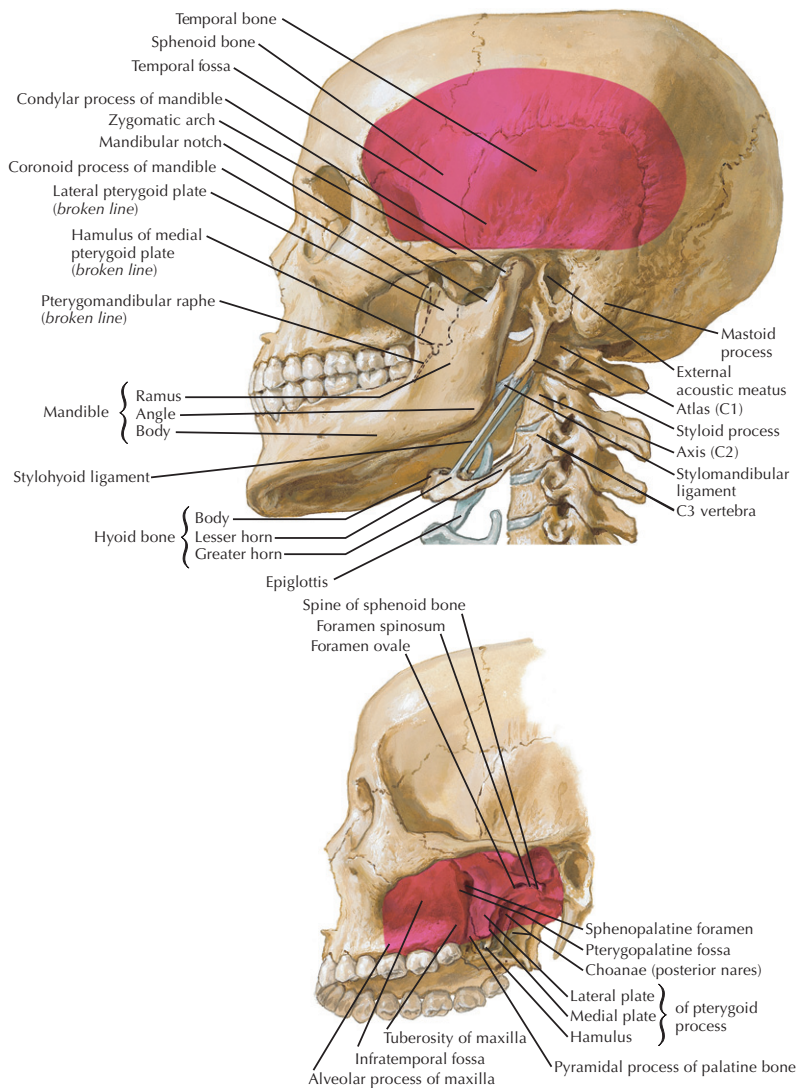
Related to the temple of the head

Communicates with the infratemporal fossa beneath the zygomatic arch

### INFRATEMPORAL FOSSA

An irregularly shaped fossa inferior and medial to the zygomatic arch

Communicates with the pterygopalatine fossa at the pterygomaxillary fissure

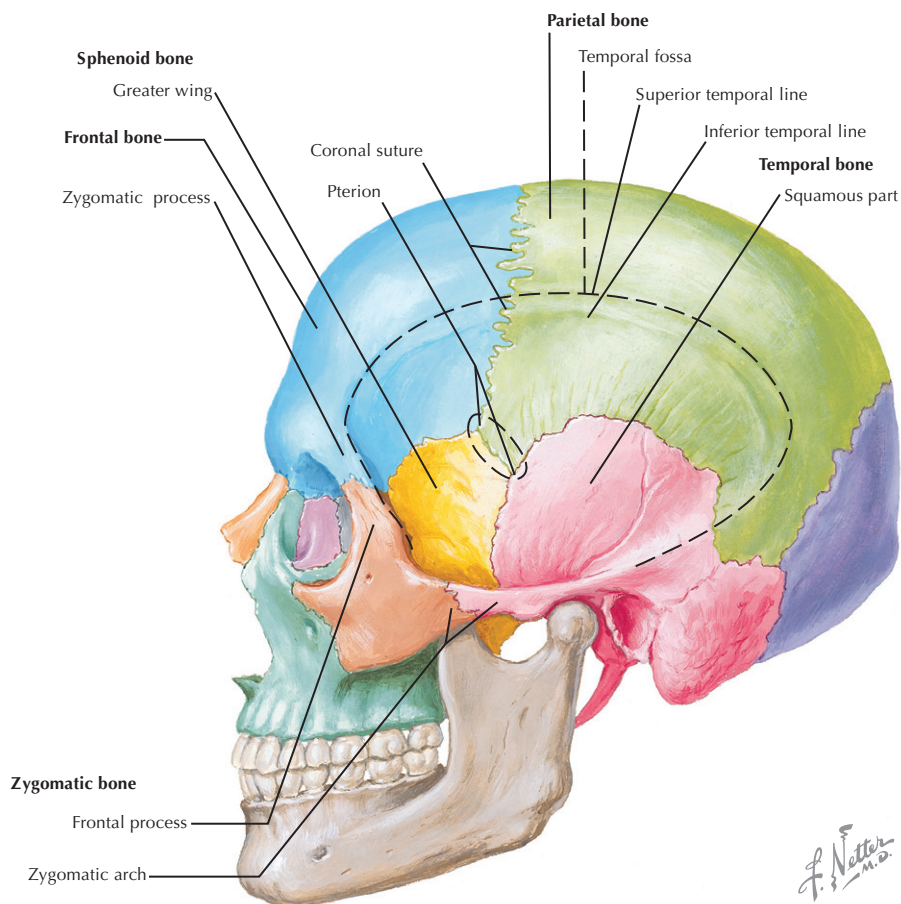


*J. Netter M.D.*

# Borders of the Temporal Fossa

## OVERVIEW

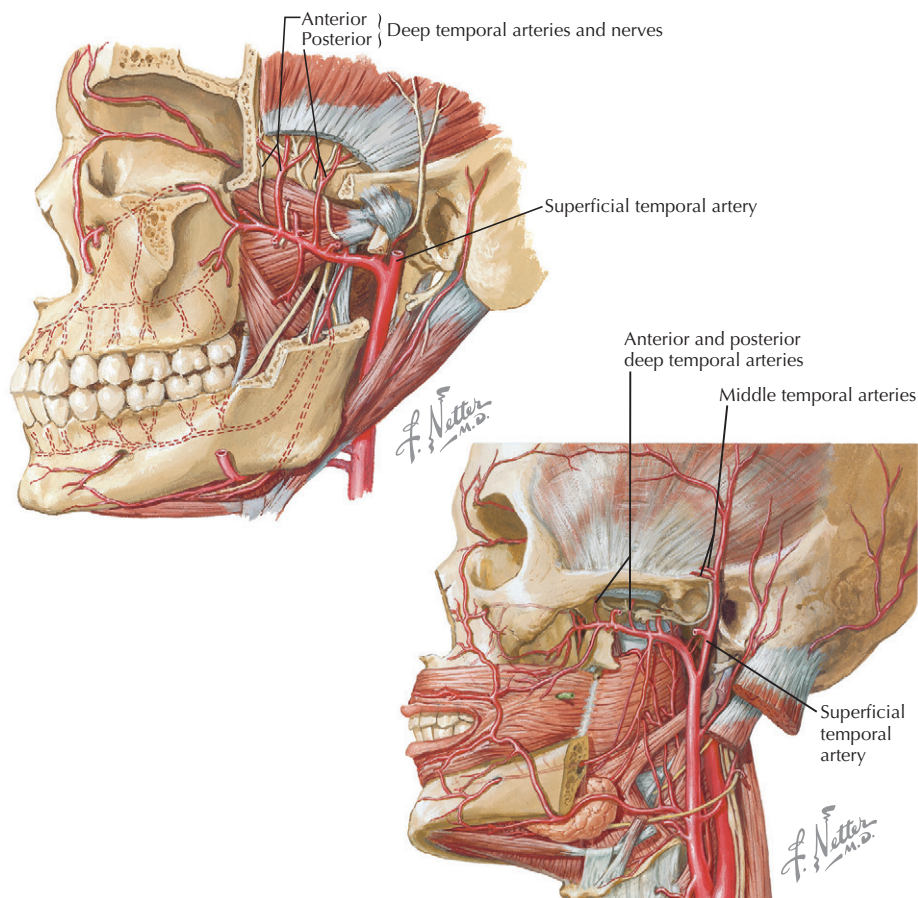
Border	Structures
Superior	Superior temporal line of the skull
Inferior	Zygomatic arch
Anterior	Frontal process of the zygoma Zygomatic process of the frontal bone
Posterior	Superior temporal line of the skull
Floor	Frontal, greater wing of the sphenoid Parietal and squamous part of the temporal bones (including the pterion)



## 7 Contents of the Temporal Fossa

### VASCULAR SUPPLY

ARTERIAL SUPPLY		
Artery	Source	Course
Superficial temporal	A terminal branch of the external carotid a. that arises within the parotid gland	Within the substance of the parotid gland, it gives off a transverse facial a. Emerges from the superior part of the parotid gland immediately posterior to the temporomandibular joint and anterior to the external auditory meatus Passes superficial to the root of the zygomatic arch just anterior to the auriculotemporal n. and the auricle Immediately superior to the root of the zygomatic arch, it gives rise to the middle temporal a. that pierces deep into the temporalis fascia and muscle As it continues to pass superiorly, it divides into anterior and posterior branches
Middle temporal	Superficial temporal a. after it passes superior to the root of the zygomatic arch	Passes deep into the temporalis fascia and temporalis m., where it anastomoses with the anterior and posterior deep temporal vessels
Anterior and posterior deep temporal	Branches of the 2nd part of the maxillary a.	Pass between the skull and the temporalis m. Supply the temporalis throughout their course While ascending, they anastomose with the middle temporal a.

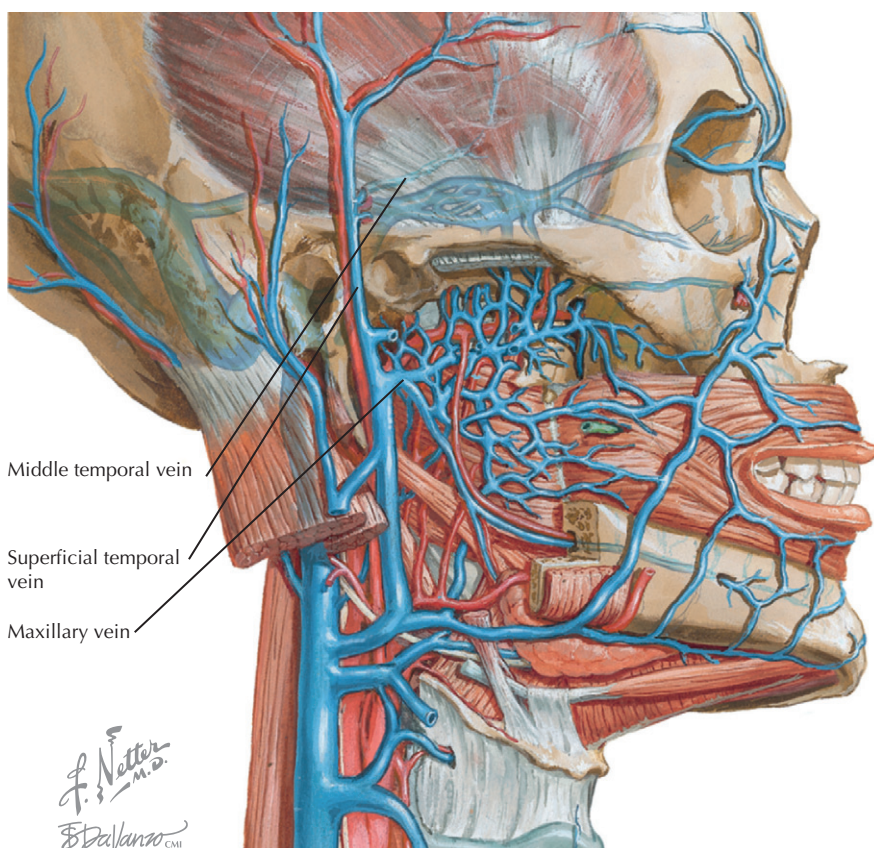




# Contents of the Temporal Fossa

## VASCULAR SUPPLY

VENOUS DRAINAGE	
Vein	Course
Superficial temporal	<p>Begins at the vertex and lateral aspect of the skull</p> <p>Forms a venous plexus along the scalp by communicating with the supraorbital, posterior auricular, occipital vv. and corresponding veins from the opposite side</p> <p>Forms an anterior and a posterior branch of the superficial temporal v. that pass inferiorly immediately anterior to the artery</p> <p>A middle temporal v. joins the superficial temporal before the vessel passes inferior to the root of the zygomatic arch</p> <p>Enters the parotid gland, where it receives the transverse facial v.</p> <p>Joins the maxillary v. to form the retromandibular v.</p>
Middle temporal	<p>Arises deep within the temporalis m. and fascia</p> <p>Within the temporalis m. and fascia, it anastomoses with the anterior and posterior deep temporal vessels</p> <p>Joins the superficial temporal a. immediately before it passes inferior to the root of the zygomatic arch</p>
Anterior and posterior deep temporal	<p>Drain into the pterygoid plexus of veins</p> <p>Also communicate with the middle temporal v.</p>
Maxillary	<p>A short branch formed by a confluence of the pterygoid plexus of veins</p> <p>Joins the superficial temporal v. to form the retromandibular v.</p>

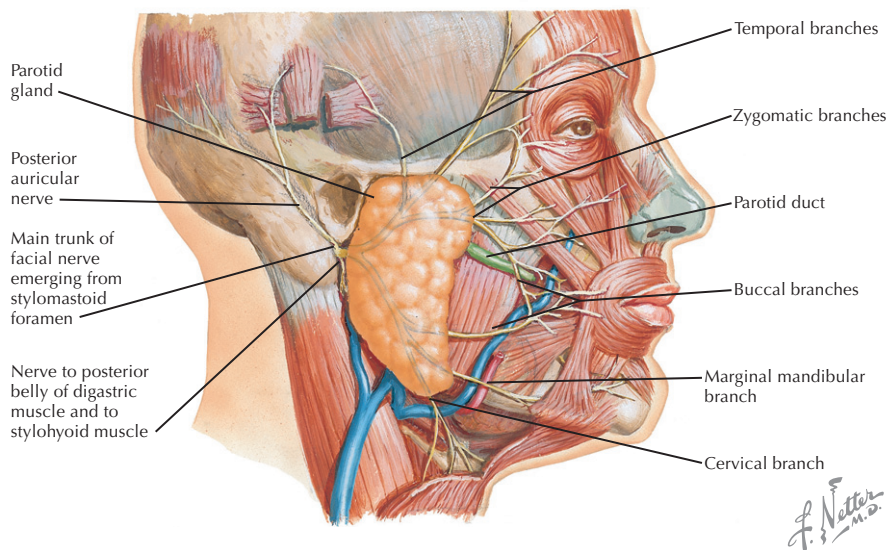




## 7 Contents of the Temporal Fossa

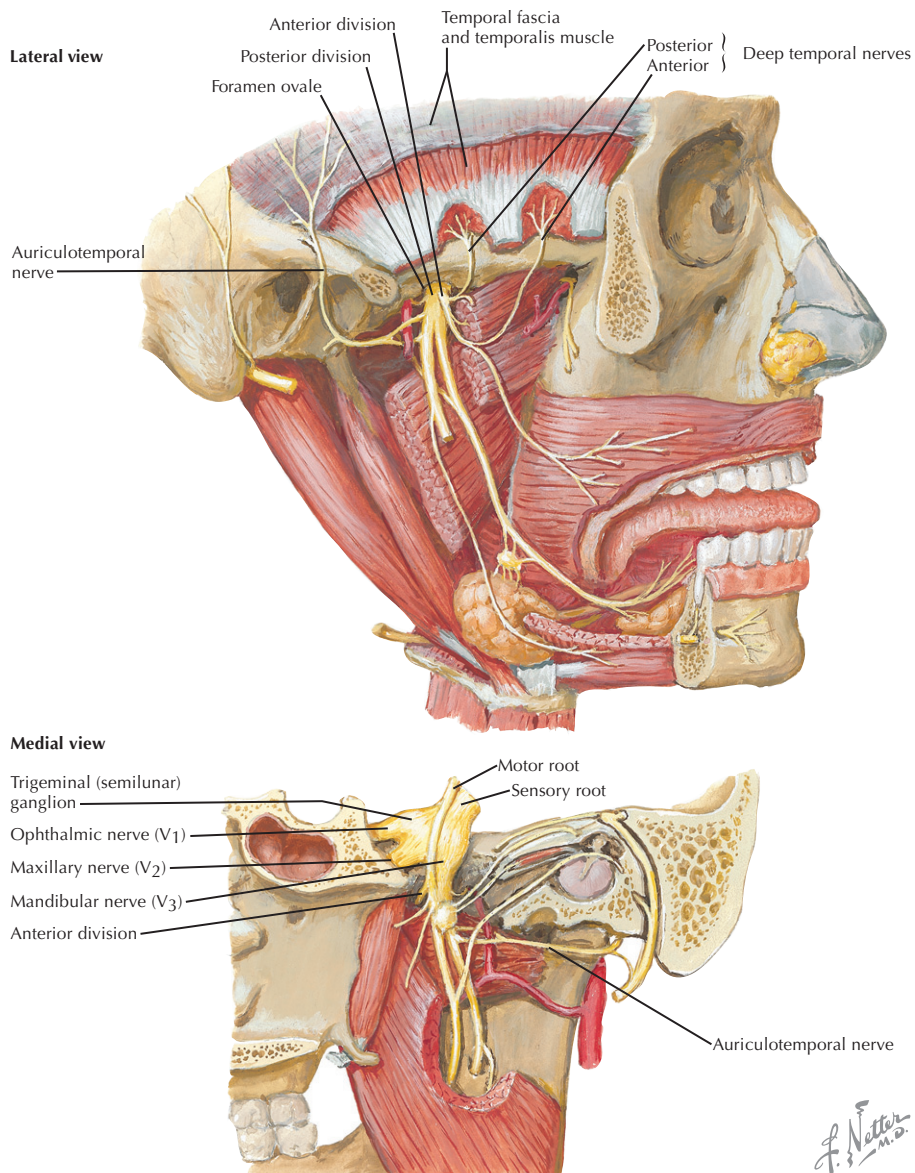
### NERVE SUPPLY

Nerve	Source	Course
Mandibular division of the trigeminal	The largest of the 3 divisions of the trigeminal n. Created by a large sensory and small motor root that unite just after passing through the foramen ovale to enter the infratemporal fossa	Immediately gives rise to a meningeal branch, medial pterygoid branch, tensor tympani branch, and tensor veli palatini branch before it divides into anterior and posterior divisions The anterior division is smaller and mainly motor, with 1 sensory branch (buccal n.) The posterior division is larger and mainly sensory, with 1 motor branch (mylohyoid n.)
<i>Anterior and posterior deep temporal</i>	Arise from the anterior part of the mandibular division of the trigeminal n.	Pass superior to the lateral pterygoid m. between the skull and the temporalis m. while passing deep to the muscle to innervate it
<i>Auriculotemporal</i>	Arises from the posterior part of the mandibular division of the trigeminal n.	Normally arises from 2 roots, between which the middle meningeal a. passes Runs posteriorly just inferior to the lateral pterygoid and continues to the medial side of the neck of the mandible Turns superiorly with the superficial temporal vessels between the auricle and the condyle of the mandible deep to the parotid gland On exiting the substance of the parotid gland, it ascends over the zygomatic arch and divides into superficial temporal branches
Temporal branches of the facial	Motor branches that arise in the substance of the parotid gland	Cross the zygomatic arch to the temporal region Supply the muscles in the area, including the auricularis frontalis, orbicularis oculi, and the corrugator supercilii mm.



# Contents of the Temporal Fossa

## NERVE SUPPLY CONTINUED



## 7 Borders of the Infratemporal Fossa

### OVERVIEW

Borders	Structures
Lateral	Ramus of the mandible and coronoid process of the mandible
Medial	Lateral pterygoid plate of the sphenoid, the superior constrictor m., and the pyramidal process of the palatine bone
Superior	Infratemporal surface of the greater wing of the sphenoid with the foramen ovale and foramen spinosum
Anterior	Posterior portion of the maxilla
Posterior	Styloid process and condylar process of the mandible
Inferior	No anatomic floor as the boundary of the fossa ends where the medial pterygoid attaches to the mandible

### CONTENTS OF THE INFRATEMPORAL FOSSA

#### MUSCLES

- Temporalis
- Lateral pterygoid
- Medial pterygoid

#### ARTERIES

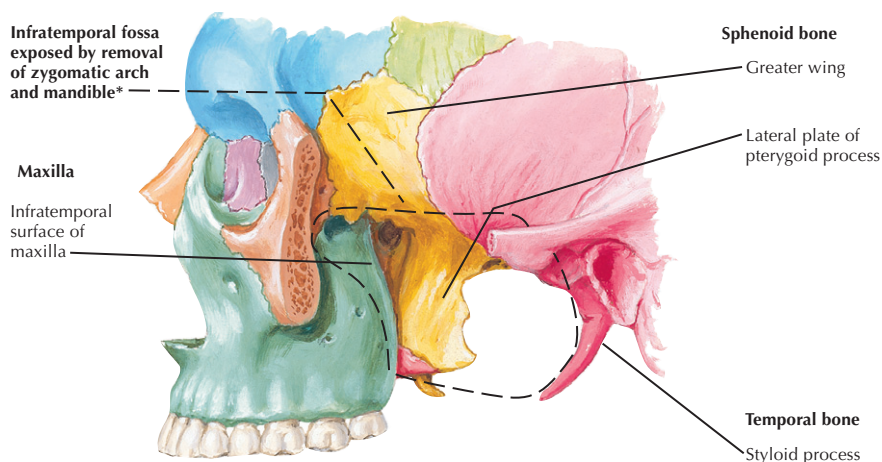
- Maxillary and its branches

#### VEINS

- Pterygoid plexus of veins and tributaries

#### NERVES

- Mandibular division of the trigeminal and branches
- Posterior superior alveolar
- Chorda tympani branch of the facial
- Otic ganglion
- Lesser petrosal

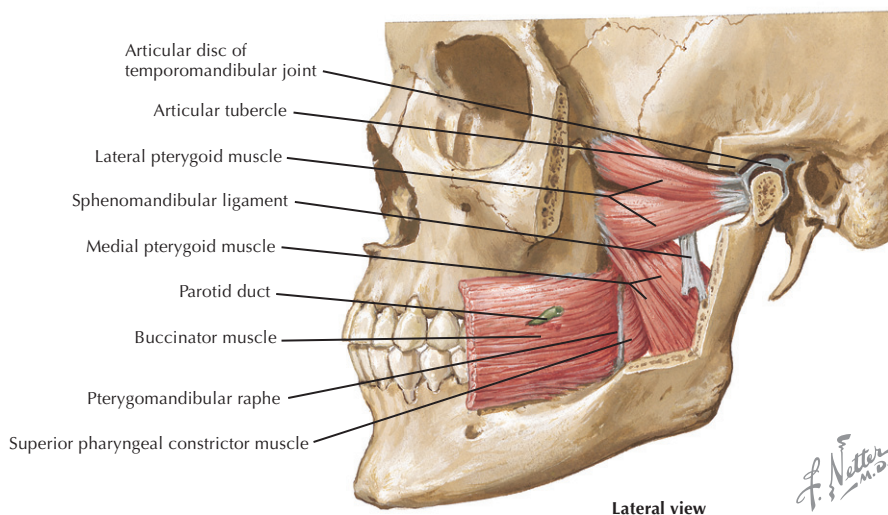
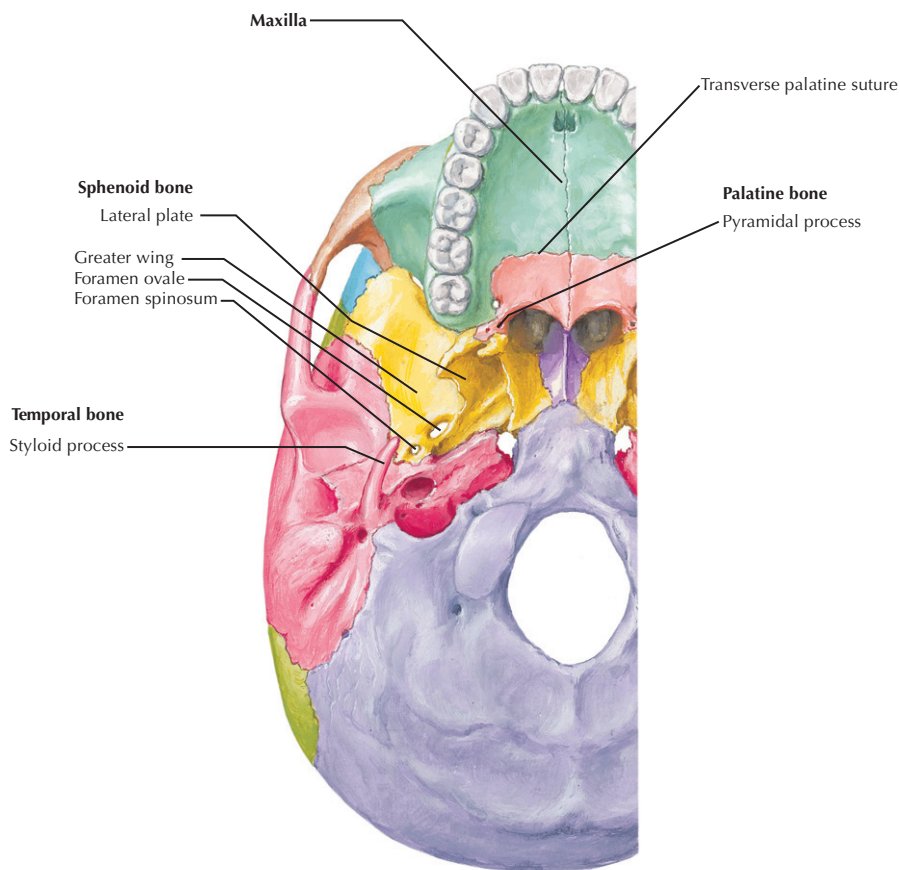


\*Superficially, mastoid process forms posterior boundary

*F. Netter M.D.*

# Borders of the Infratemporal Fossa

## OVERVIEW CONTINUED



## 7 Contents of the Infratemporal Fossa

### VASCULAR SUPPLY

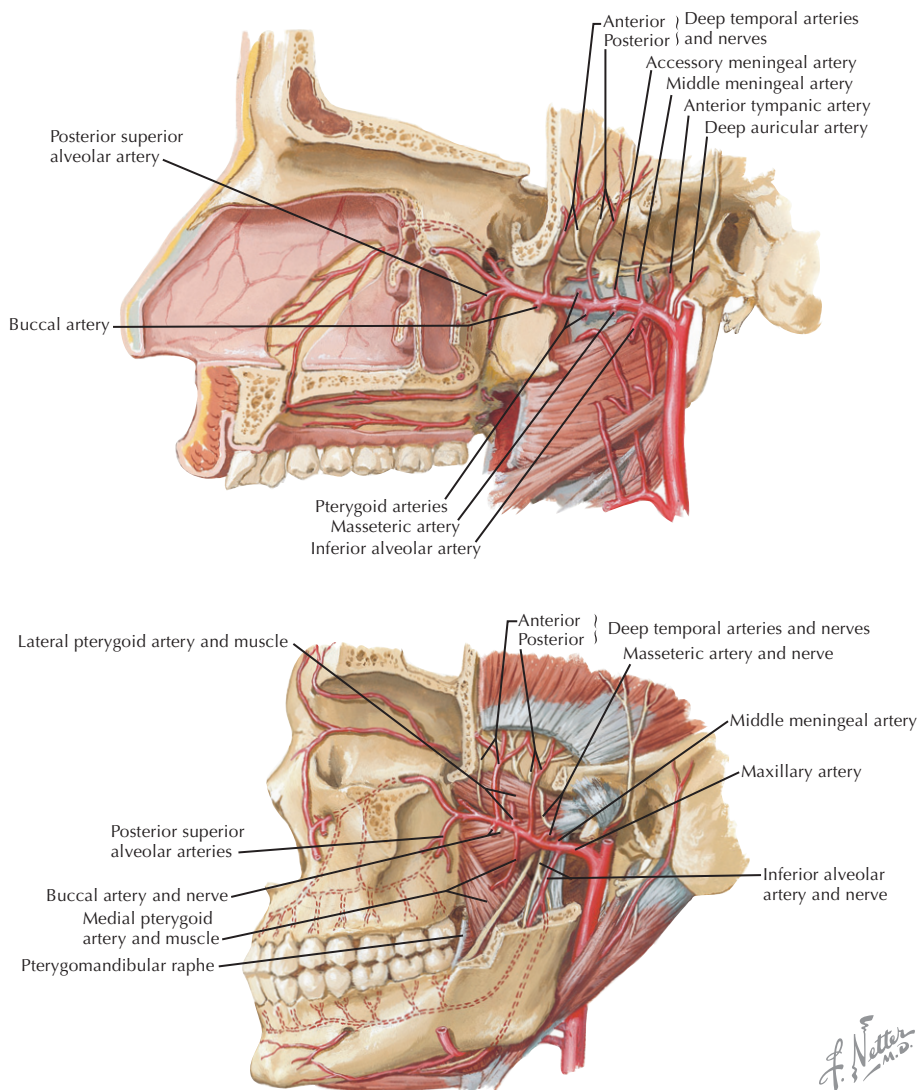
MAXILLARY ARTERY	
<p>The larger of the 2 terminal branches of the external carotid a. (superficial temporal a.)</p> <p>Arises posterior to the condylar neck of the mandible within the parotid gland</p> <p>Exits the parotid gland and passes anteriorly between the ramus of the mandible and the sphenomandibular lig. within the infratemporal fossa</p> <p>Takes a course that is either superficial or deep to the lateral pterygoid until reaching the pterygopalatine fossa via the pterygomaxillary fissure</p> <p>Supplies the deep structures of the face and may be divided into 3 parts as it passes medially through the infratemporal fossa:</p> <ul style="list-style-type: none"> <li>• 1st part—mandibular part</li> <li>• 2nd part—pterygoid part</li> <li>• 3rd part—pterygopalatine part</li> </ul>	
MAXILLARY ARTERY: 1ST PART (MANDIBULAR PART)	
Artery	Course
1st part (mandibular part)	<p>Passes between the ramus of the mandible and the sphenomandibular lig. Lies parallel to and inferior to the auriculotemporal n.</p> <p>Crosses the inferior alveolar n. and passes on the inferior border of the lateral pterygoid</p> <p>Gives rise to 5 branches: anterior tympanic, deep auricular, middle meningeal, accessory meningeal, and the inferior alveolar</p>
Deep auricular	<p>Given off in the same area as the anterior tympanic</p> <p>Lies in the parotid gland, posterior to the temporomandibular joint, where it gives branches to supply the temporomandibular joint</p>
Anterior tympanic	<p>Given off in the same area as for the the deep auricular a.</p> <p>Passes superiorly immediately posterior to the temporomandibular joint, where it gives branches to supply the temporomandibular joint</p> <p>Enters the tympanic cavity through the petrotympanic fissure and aids in supplying the tympanic membrane, along with branches of the posterior auricular a., artery of the pterygoid canal, and caroticotympanic branch from the internal carotid a.</p>
Middle meningeal	<p>Passes superiorly between the sphenomandibular lig. and the lateral pterygoid between the 2 roots of the auriculotemporal n. to the foramen spinosum of the sphenoid bone</p> <p>In the middle cranial fossa, passes anteriorly in a groove on the greater wing of the sphenoid, dividing into an anterior and posterior branch</p>
Accessory meningeal	<p>Arises from the maxillary or middle meningeal</p> <p>Enters the skull through the foramen ovale to supply the trigeminal ganglion and dura mater</p>
Inferior alveolar	<p>Descends inferiorly following the inferior alveolar n. to enter the mandibular foramen</p>
MAXILLARY ARTERY: 2ND PART (PTERYGOID PART)	
Artery	Course
2nd part (pterygoid part)	<p>Passes obliquely and anterosuperiorly between the ramus of the mandible and insertion of the temporalis m.</p> <p>Then passes on the superficial surface of the lateral pterygoid to travel between the muscle's 2 heads</p> <p>Has 5 branches: anterior and posterior deep temporal, masseteric, pterygoid, and buccal</p>
Anterior and posterior deep temporal	<p>Pass between the skull and the temporalis m.</p> <p>Supply the temporalis throughout their course</p> <p>While ascending, these arteries anastomose with the middle temporal a. from the superficial temporal a.</p>
Masseteric	<p>Small; passes laterally through the mandibular notch to supply the deep surface of the masseter m.</p>
Pterygoid	<p>An irregular number of arteries supplying the pterygoid mm.</p>
Buccal	<p>A small artery that runs obliquely in an anterior direction between the medial pterygoid m. and the insertion of the temporalis m. until it reaches the outer surface of the buccinator m. to supply it</p>



# Contents of the Infratemporal Fossa

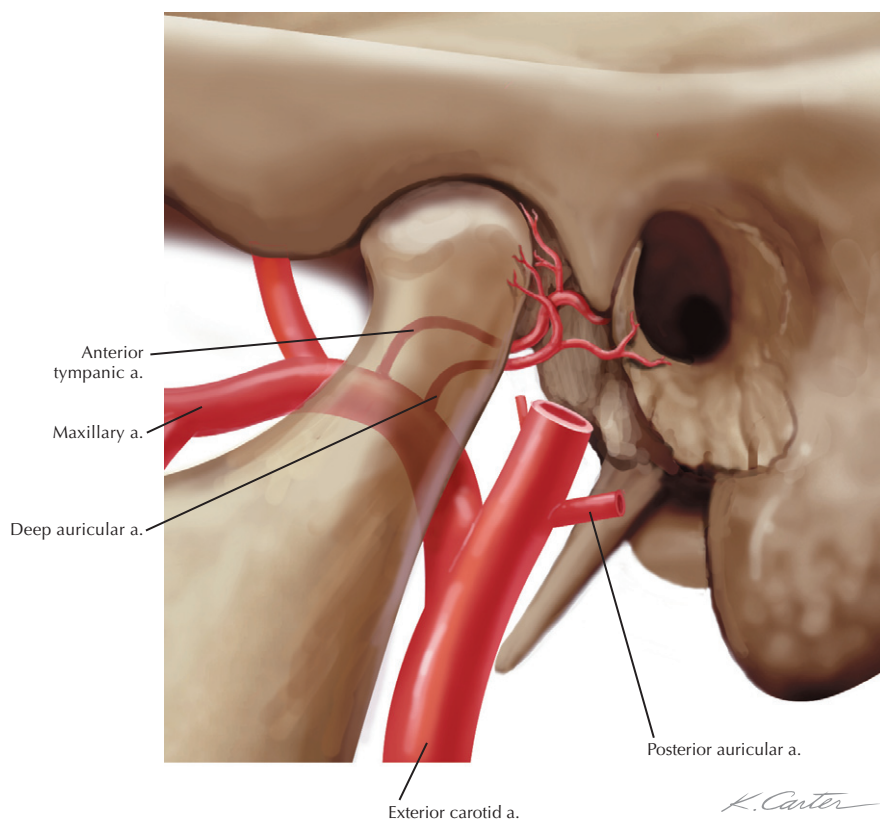
## VASCULAR SUPPLY CONTINUED

MAXILLARY ARTERY: 3RD PART (PTERYGOPALATINE PART)	
Artery	Course
3rd part (pterygopalatine part)	Passes from the infratemporal fossa into the pterygopalatine fossa via the pterygomaxillary fissure Before passing through the pterygomaxillary fissure, it gives off the posterior superior alveolar a. (the only artery off the 3rd part of the maxillary a. that does not normally branch off within the pterygopalatine fossa)
Posterior superior alveolar	Arises in the infratemporal fossa Descends on the maxillary tuberosity to enter the posterior surface of the maxilla to supply the molars and premolars, lining of the maxillary sinus, and the gums



## 7 Contents of the Infratemporal Fossa

### VASCULAR SUPPLY *CONTINUED*

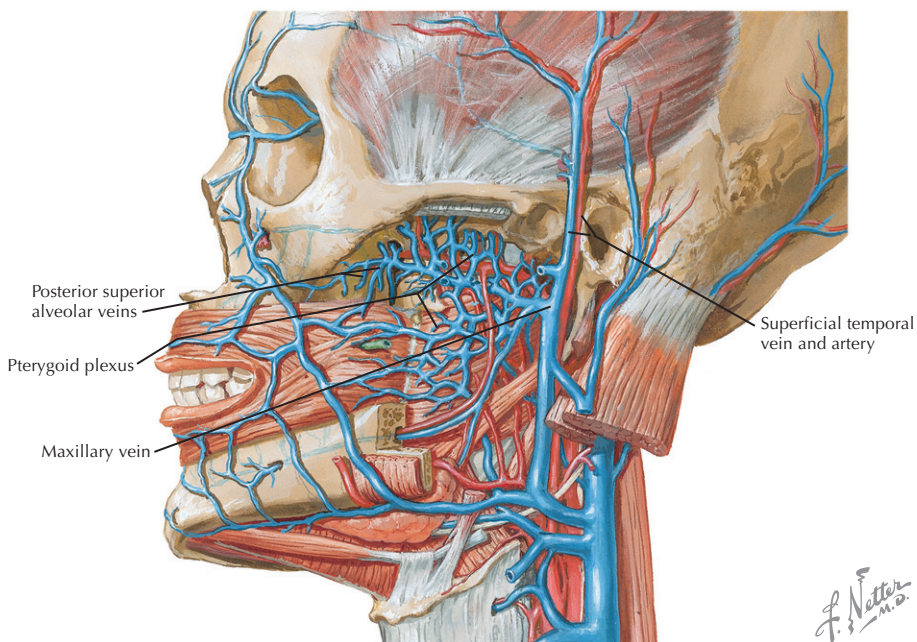
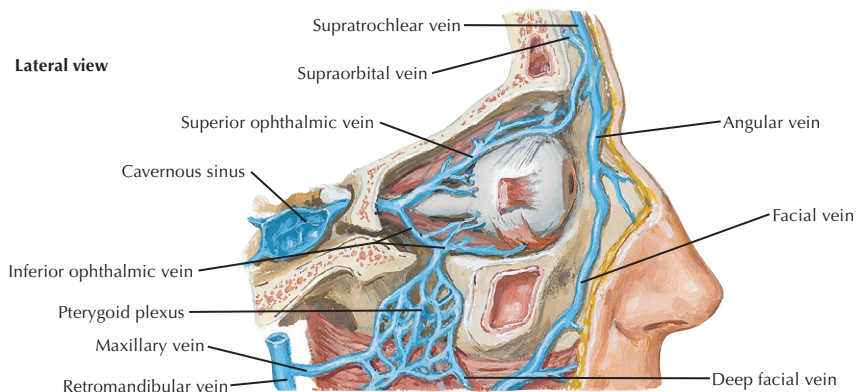


# Contents of the Infratemporal Fossa

## VASCULAR SUPPLY *CONTINUED*

VENOUS DRAINAGE	
Vein	Course
Pterygoid plexus	An extensive network of veins that parallel the 2nd and 3rd parts of the maxillary a. Receives branches that correspond with the same branches of the maxillary a. The tributaries of the pterygoid plexus eventually converge to form a short maxillary v. Communicates with the cavernous sinus, pharyngeal venous plexus, facial v. via the deep facial v., and ophthalmic vv.

### Lateral view



*F. Netter M.D.*

## 7 Contents of the Infratemporal Fossa

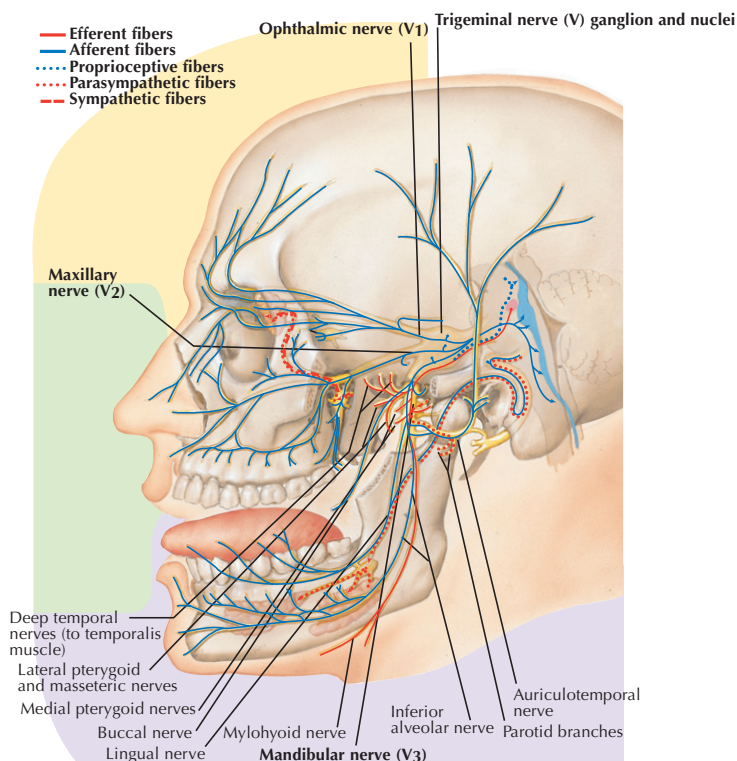
### NERVOUS STRUCTURES

MANDIBULAR NERVE	
<p>The largest of the 3 divisions of the trigeminal n.</p> <p>Has motor <i>and</i> sensory functions</p> <p>Created by a large sensory and a small motor root that unite just after passing through the foramen ovale to enter the infratemporal fossa</p> <p>Immediately gives rise to a meningeal branch and then divides into anterior and posterior divisions</p>	
Anterior Division	
<p>Smaller; mainly motor with 1 sensory branch (buccal):</p> <ul style="list-style-type: none"> <li>• Masseteric</li> <li>• Anterior and posterior deep temporal</li> <li>• Medial pterygoid</li> <li>• Lateral pterygoid</li> <li>• Buccal</li> </ul>	
Posterior Division	
<p>Larger, mainly sensory with 1 motor branch (mylohyoid n.):</p> <ul style="list-style-type: none"> <li>• Auriculotemporal</li> <li>• Lingual</li> <li>• Inferior alveolar</li> <li>• Mylohyoid n.</li> </ul>	
ANTERIOR DIVISION OF THE MANDIBULAR NERVE	
Branch	Course
Masseteric	<p>Passes laterally superior to the lateral pterygoid</p> <p>Lies anterior to the temporomandibular joint and posterior to the tendon of the temporalis m.</p> <p>Crosses the mandibular notch with the masseteric a. to innervate the masseter m.</p> <p>Also provides a small branch to the temporomandibular joint</p>
Anterior and posterior deep temporal	<p>Pass superior to the lateral pterygoid m. between the skull and the temporalis m. while passing deep to the muscle to innervate it</p>
Medial pterygoid	<p>Enters the deep surface of the muscle</p>
Lateral pterygoid	<p>Passes into the deep surface of the muscle</p> <p>Often arises from the buccal n.</p>
Buccal	<p>Passes anteriorly between the 2 heads of the lateral pterygoid m.</p> <p>Descends inferiorly along the lower part of the temporalis m. to appear from deep to the anterior border of the masseter m.</p> <p>Supplies the skin over the buccinator m. before passing through it to supply the mucous membrane lining its inner surface and the gingiva along the mandibular molars</p>
POSTERIOR DIVISION OF THE MANDIBULAR NERVE	
Branch	Course
Auriculotemporal	<p>Normally arises from 2 roots, between which the middle meningeal a. passes</p> <p>Runs posteriorly just inferior to the lateral pterygoid and continues to the medial aspect of the neck of the mandible</p> <p>Then it turns superiorly with the superficial temporal vessels between the auricle and condyle of the mandible deep to the parotid gland</p> <p>On exiting the parotid gland, it ascends over the zygomatic arch and divides into superficial temporal branches</p>
Lingual	<p>Lies inferior to the lateral pterygoid and medial and anterior to the inferior alveolar n.</p> <p>The chorda tympani n. also joins the posterior part</p> <p>The lingual n. passes between the medial pterygoid and the ramus of the mandible to pass obliquely to enter the oral cavity bounded by the superior pharyngeal constrictor m., medial pterygoid m., and the mandible</p> <p>Supplies the mucous membrane of the anterior 2/3 of the tongue and gingiva on the lingual aspect of the mandibular teeth</p>

# Contents of the Infratemporal Fossa

## NERVOUS STRUCTURES *CONTINUED*

POSTERIOR DIVISION OF THE MANDIBULAR NERVE <i>CONTINUED</i>	
Branch	Course
Inferior alveolar	The largest branch of the mandibular division Descends following the inferior alveolar a. inferior to the lateral pterygoid and, finally, between the sphenomandibular lig. and the ramus of the mandible until it enters the mandibular foramen Innervates all mandibular teeth and the gingiva from the premolars anteriorly to the midline
Mylohyoid	Branches from the inferior alveolar n. immediately before it enters the mandibular foramen Descends in a groove on the deep side of the ramus of the mandible until it reaches the superficial surface of the mylohyoid m. Supplies the mylohyoid m. and the anterior belly of the digastric m.
MAXILLARY NERVE	
Branch	Course
Posterior superior alveolar	Passes through the pterygomaxillary fissure to enter the infratemporal fossa In the infratemporal fossa, it passes on the posterior surface of the maxilla along the region of the maxillary tuberosity Gives rise to a gingival branch that innervates the buccal gingiva alongside the maxillary molars Enters the posterior surface of the maxilla and supplies the maxillary sinus and the maxillary molars with the possible exception of the mesiobuccal root of the first maxillary molar

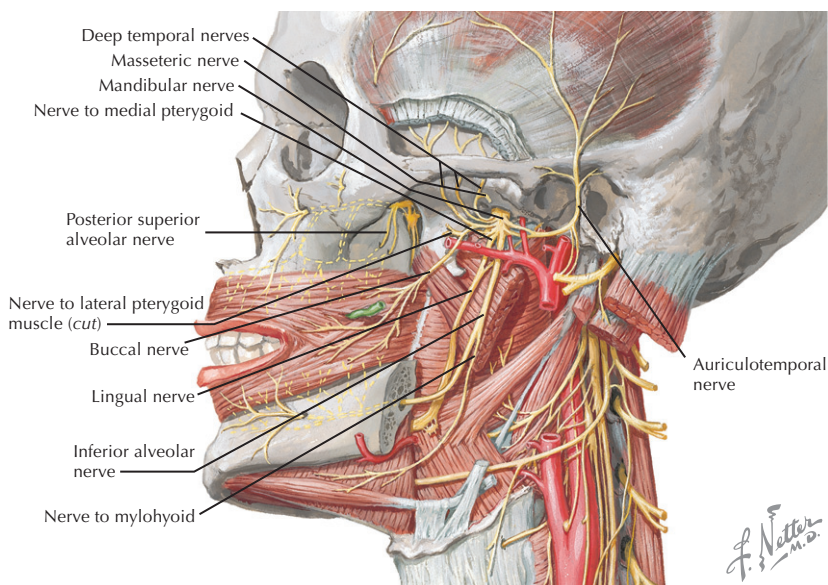
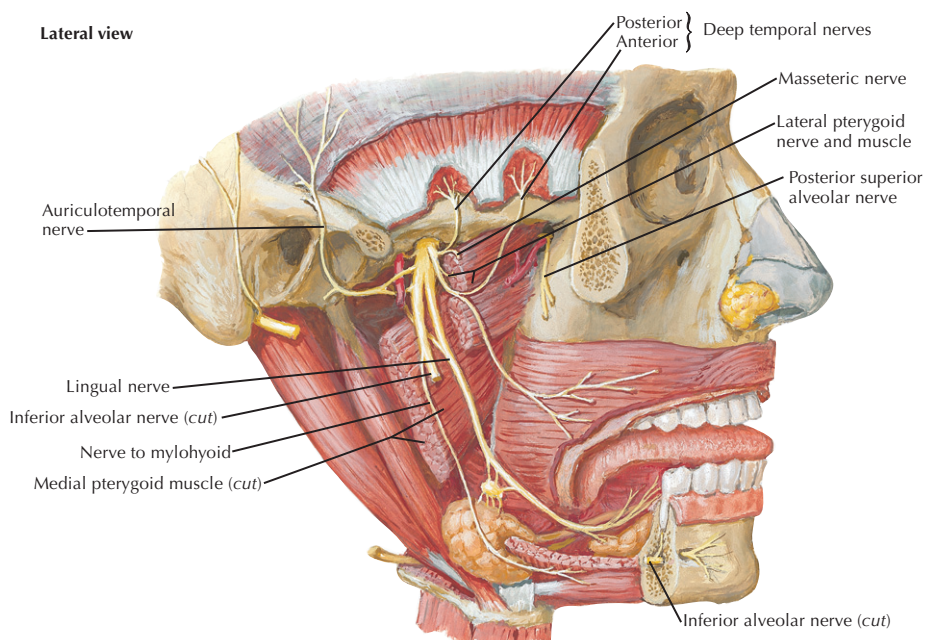


*F. Netter M.D.*



# 7 Contents of the Infratemporal Fossa

## NERVOUS STRUCTURES *CONTINUED*



# Contents of the Infratemporal Fossa

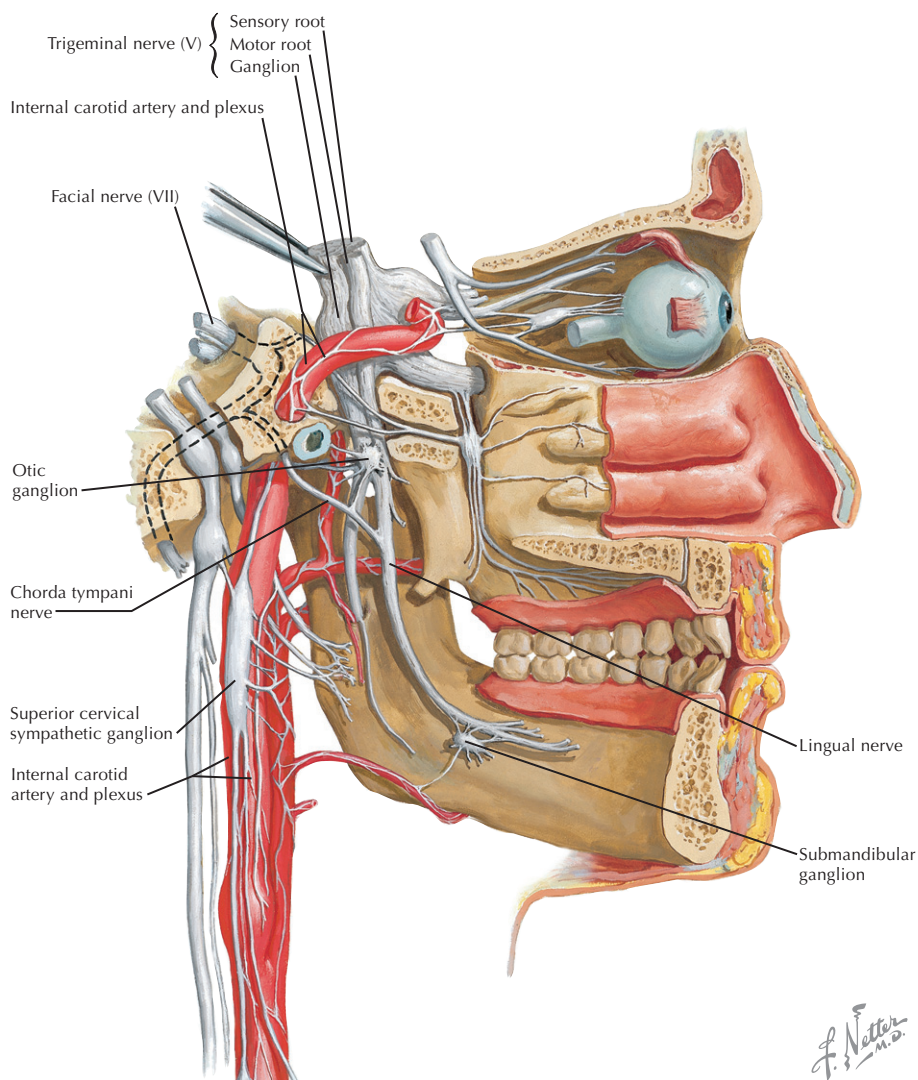
## NERVOUS STRUCTURES *CONTINUED*

CHORDA TYMPANI, LESSER PETROSAL NERVE, AND OTIC GANGLION		
Nerve	Source	Course
Chorda tympani	Branch from the facial n. in the tympanic cavity	<p>Carries the preganglionic parasympathetic fibers to the submandibular ganglion and taste fibers to the anterior 2/3 of the tongue</p> <p>Passes anteriorly to enter the tympanic cavity and lies along the tympanic membrane and malleus until exiting the petrotympanic fissure</p> <p>Once it exits the petrotympanic fissure, it joins the posterior border of the lingual n. in the infratemporal fossa</p> <p>The lingual n. is distributed to the anterior 2/3 of the tongue and the SVA* fibers from the chorda tympani travel to the taste buds in this region</p>
Lesser petrosal	Tympanic plexus along the promontory of the ear re-forms as the lesser petrosal n.	<p>Forms in the middle ear cavity</p> <p>Carries the preganglionic parasympathetic (from the tympanic branch of IX) and postganglionic sympathetic (from the caroticotympanic branch of the internal carotid a. plexus) that are traveling to the parotid gland</p> <p>The nerve passes along the groove for the lesser petrosal n. on the petrous portion of the temporal bone toward the foramen ovale</p> <p>Normally enters the infratemporal fossa by passing through the foramen ovale</p> <p>Joins the otic ganglion</p>
Nerve Cell Body	Characteristics of the Cell Body	Course
Otic ganglion	<p>A collection of nerve cell bodies located in the infratemporal fossa</p> <p>This very small stellate-shaped ganglion is inferior to the foramen ovale and medial to the mandibular division of the trigeminal n.</p>	<p>Postganglionic parasympathetic fibers arise in the otic ganglion and travel to the auriculotemporal branch of the trigeminal n.</p> <p>Auriculotemporal n. travels to the parotid gland</p> <p>These postganglionic parasympathetic fibers innervate the:</p> <ul style="list-style-type: none"> <li>• Parotid gland—secretion of saliva</li> </ul>

\*SVA, special visceral afferent. See Chapter 3 for a discussion of the SVA and other functional columns.

## 7 Contents of the Infratemporal Fossa

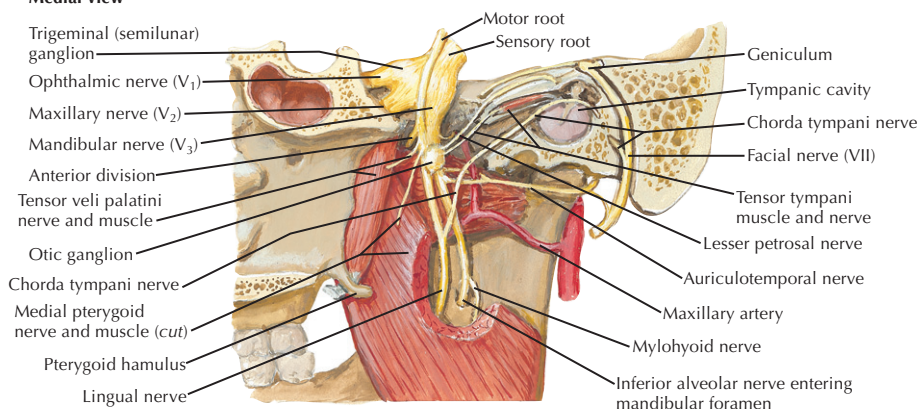
### NERVOUS STRUCTURES *CONTINUED*



# Contents of the Infratemporal Fossa

## NERVOUS STRUCTURES *CONTINUED*

### Medial view

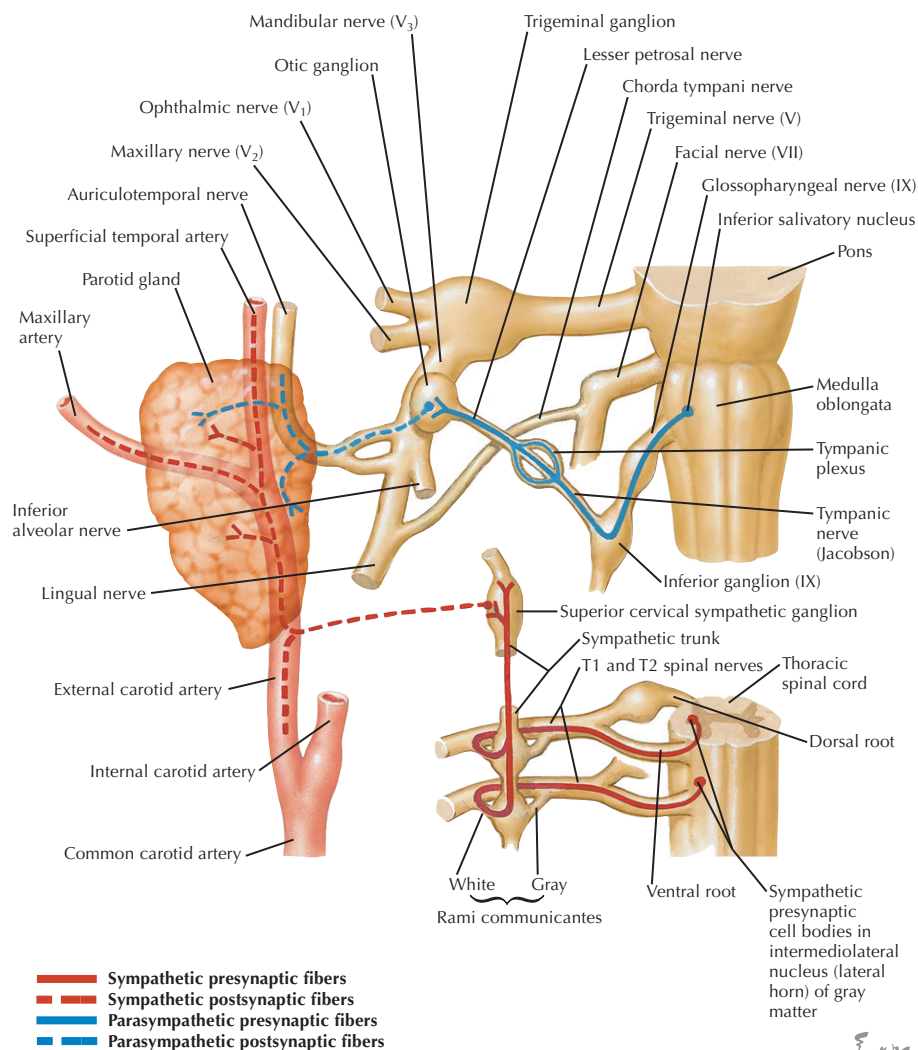


### ANATOMIC PATHWAY FOR PARASYMPATHETICS OF THE PAROTID GLAND

Type of Neuron	Name of Cell Body	Characteristics of the Cell Body	Course of the Neuron
Preganglionic neuron	Inferior salivatory nucleus	A collection of nerve cell bodies located in the medulla	Preganglionic parasympathetic fibers arise from the inferior salivatory nucleus in the medulla Travel through the glossopharyngeal n. and exit the jugular foramen The glossopharyngeal n. gives rise to the tympanic branch of IX, which reenters the skull via the tympanic canaliculus Tympanic branch of IX forms the tympanic plexus along the promontory of the ear The plexus re-forms as the lesser petrosal n., which typically exits the foramen ovale to enter the infratemporal fossa Lesser petrosal n. joins the otic ganglion
Postganglionic neuron	Otic ganglion	A collection of nerve cell bodies This very small stellate-shaped ganglion is located inferior to the foramen ovale, medial to the mandibular division of the trigeminal n.	Postganglionic parasympathetic fibers arise in the otic ganglion These fibers travel to the auriculotemporal branch of the trigeminal n. Auriculotemporal n. travels to the parotid gland These postganglionic parasympathetic fibers innervate the: ● Parotid gland—secretion of saliva

# 7 Contents of the Infratemporal Fossa

## NERVOUS STRUCTURES *CONTINUED*



*F. Netter M.D.*



## CHAPTER 8

# MUSCLES OF MASTICATION

Overview and Topographic Anatomy	224
Muscles of Mastication	225
Vascular Supply	228
Nerve Supply	231
Clinical Correlate	233

## 8 Overview and Topographic Anatomy

### GENERAL INFORMATION

**Mastication** is the process of chewing food in preparation for deglutition (swallowing) and digestion

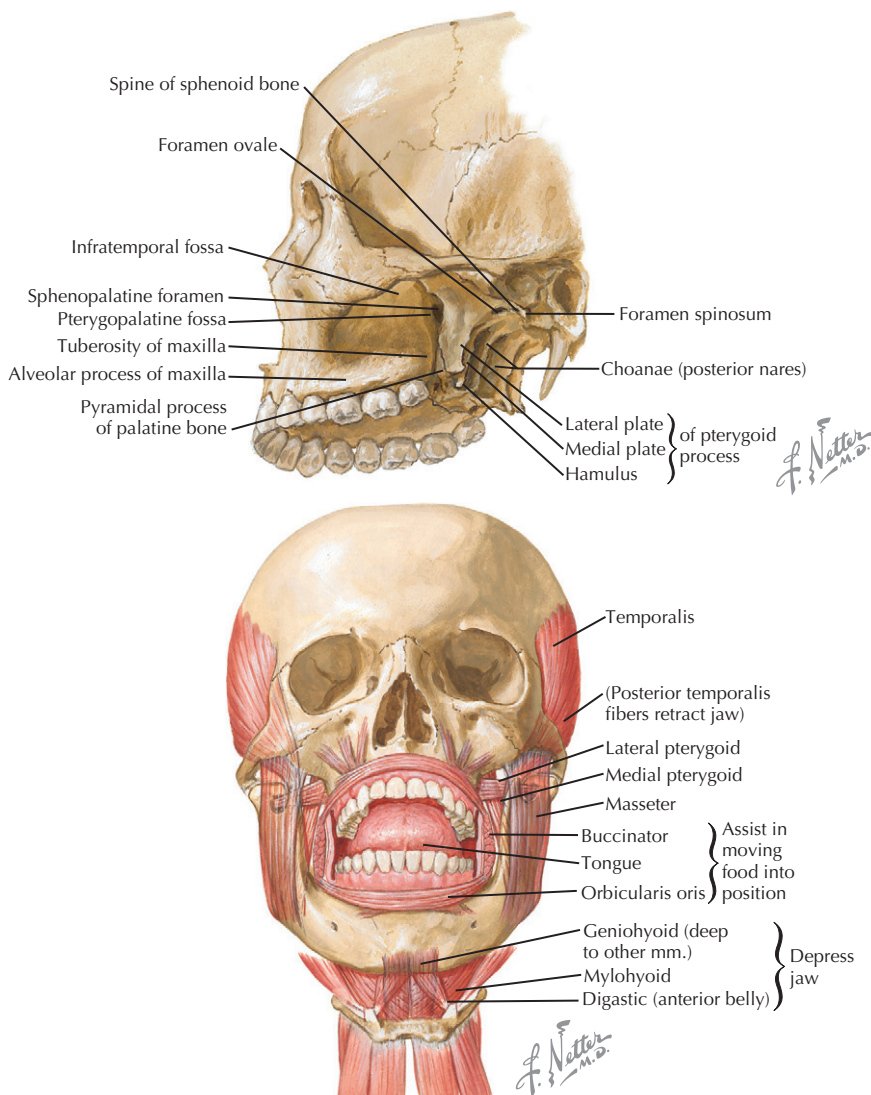
All muscles of mastication originate on the skull and insert on the mandible

All muscles of mastication are innervated by the mandibular division of the trigeminal nerve

All muscles of mastication are derivatives of the 1st pharyngeal arch

Movements of the mandible are classified as:

- Elevation
- Depression
- Protrusion
- Retrusion
- Side-to-side (lateral) excursion



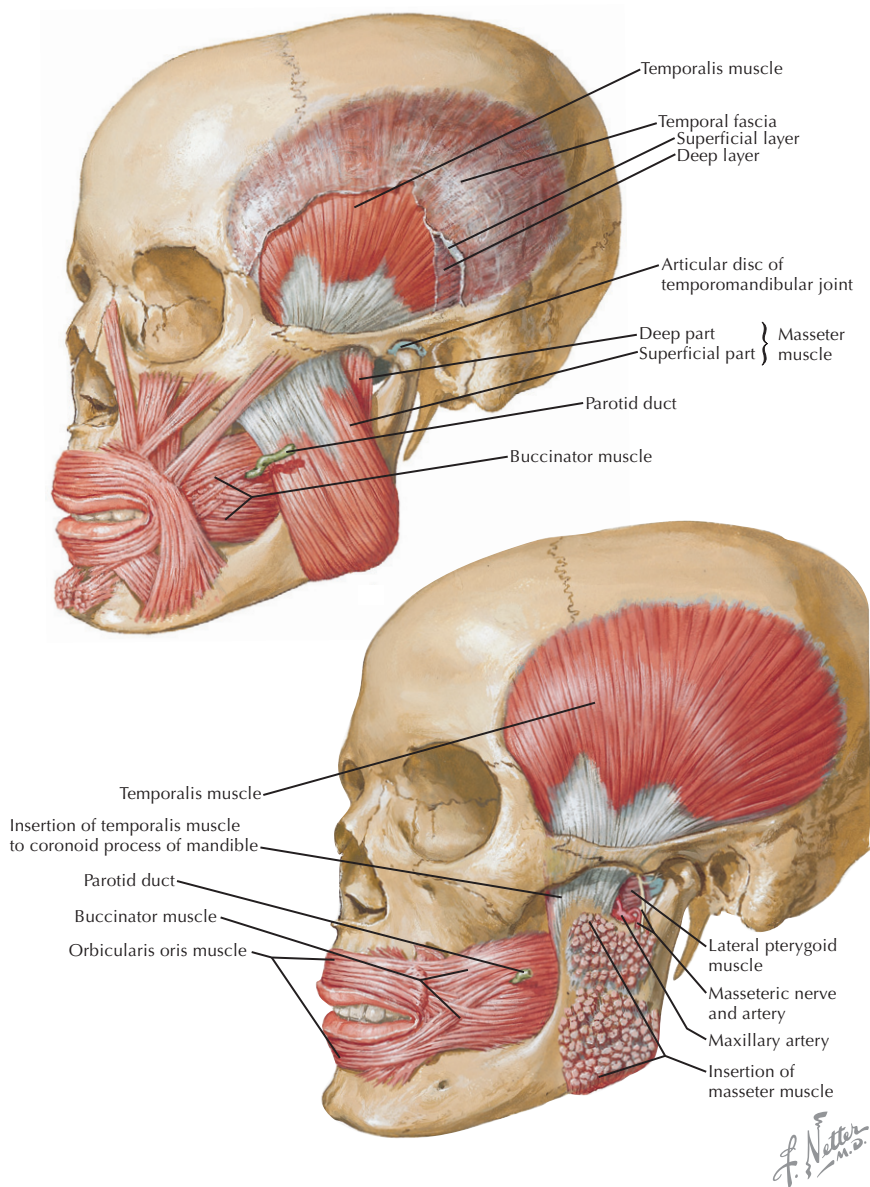
# Muscles of Mastication

## OVERVIEW

Muscle	Origin	Insertion	Main Actions	Nerve Supply	Comments
Masseter: superficial head (larger part)	Inferior border of the anterior 2/3 of the zygomatic arch	Angle of mandible Inferior and lateral parts of the mandibular ramus	Elevates mandible Protrudes mandible (superficial head) Aids in lateral excursion of the mandible	Masseteric branch from the mandibular division of the trigeminal n.	Superficial head's fibers run posteroinferiorly The parotid duct, transverse facial a., and branches of the facial n. pass superficial to the masseter m.
Masseter: deep head (smaller part)	Medial border of the zygomatic arch Inferior border of the posterior 1/3 of the zygomatic arch	Superolateral mandibular ramus Coronoid process			
Temporalis	Entire temporal fossa: along the inferior temporal line including the temporal fascia	Coronoid process: along the apex, anterior and posterior borders, medial surface extending inferiorly on the anterior border of the mandibular ramus (temporal crest) to the 3rd molar tooth	Elevates mandible Retrudes mandible (posterior fibers) Aids in lateral excursion of the mandible	Anterior and posterior deep temporal branches from the mandibular division of the trigeminal n.	The main postural muscle—maintains the mandible in rest position
Medial pterygoid: deep head	Medial surface of lateral pterygoid plate	Medial surface of ramus and angle of the mandible (pterygoid tubercles)	Elevates mandible Protrudes mandible Lateral excursion of the mandible	Medial pterygoid branch from the mandibular division of the trigeminal n.	The deepest muscle of mastication
Medial pterygoid: superficial head	Maxillary tuberosity Pyramidal process of the palatine				
Lateral pterygoid: upper head	Greater wing of the sphenoid Infratemporal crest	Articular disc and capsule of the temporomandibular joint	Depresses mandible Protrudes mandible Lateral excursion of the mandible	Lateral pterygoid branches (for each head) from the mandibular division of the trigeminal n., which exits the foramen ovale, lying medial to the lateral pterygoid	Maxillary a. runs either superficial or deep to it Surrounded by the pterygoid venous plexus Buccal branch of the trigeminal n. passes between the 2 heads
Lateral pterygoid: lower head	Lateral surface of the lateral pterygoid plate	Pterygoid fovea on the neck of the condyle of the mandible			

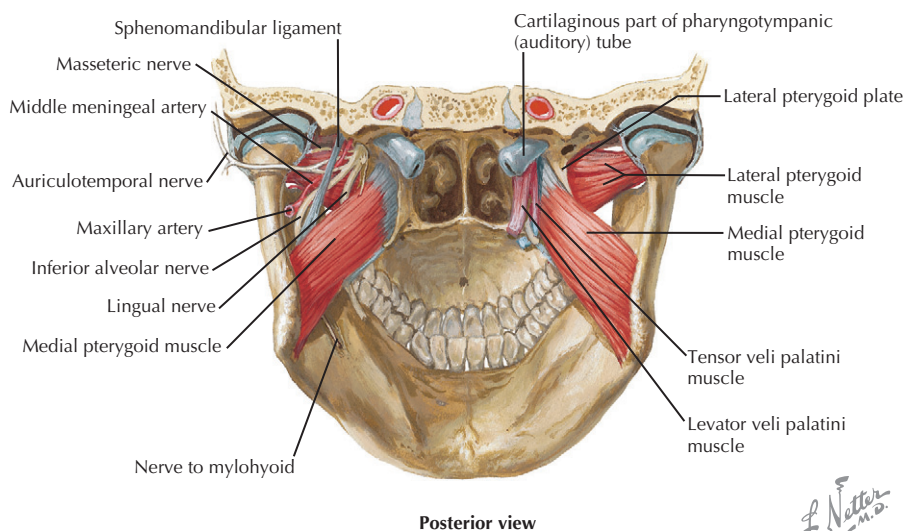
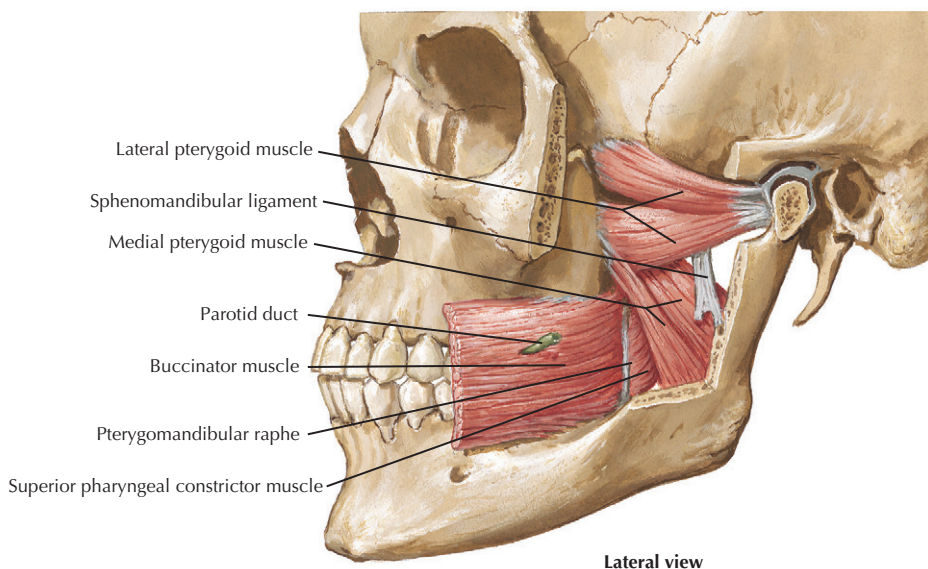
# 8 Muscles of Mastication

## OVERVIEW CONTINUED



# Muscles of Mastication

## OVERVIEW CONTINUED



*F. Netter M.D.*



# 8 Vascular Supply

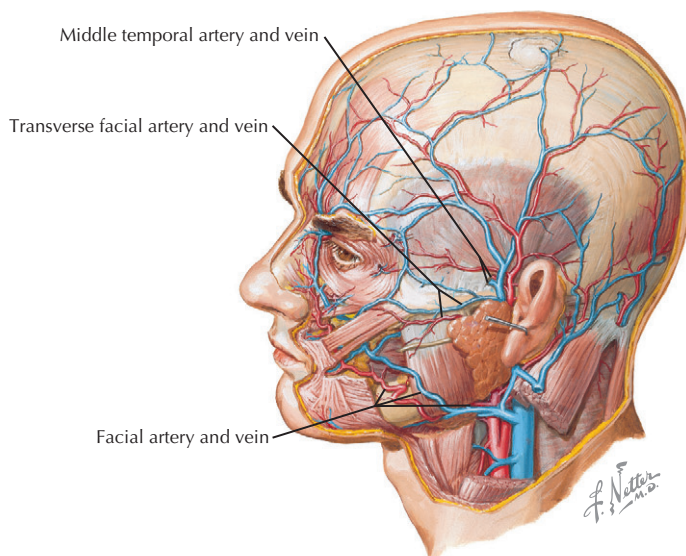
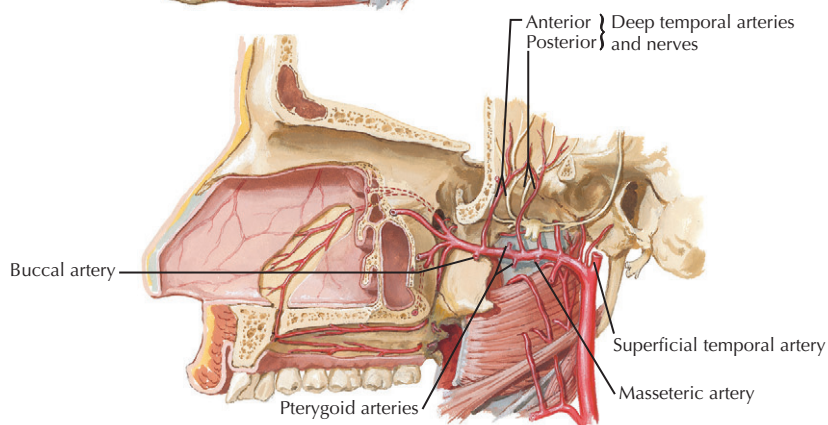
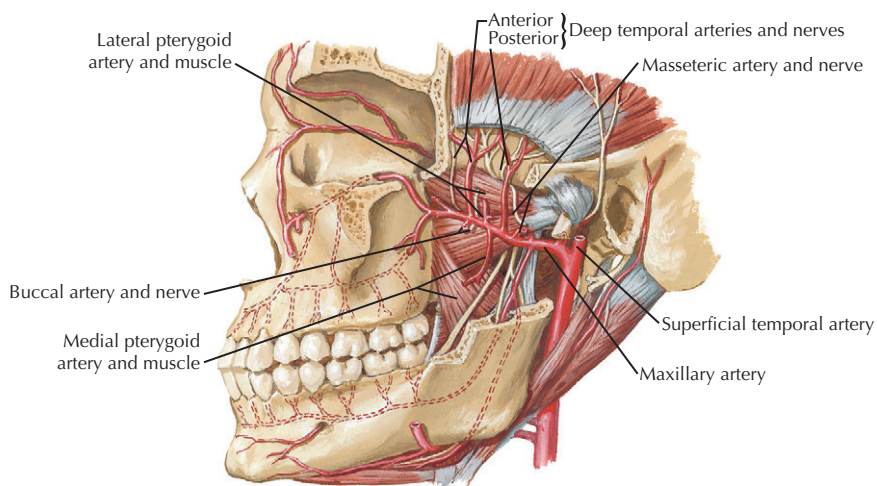
## ARTERIAL SUPPLY

Artery	Source	Course
Maxillary	Larger of the 2 terminal branches of the external carotid a. (superficial temporal a. is the other terminal branch)	<p>Arises posterior to the condylar neck of the mandible within the parotid gland</p> <p>Exits the parotid gland and passes anteriorly between the ramus of the mandible and the sphenomandibular ligament within the infratemporal fossa</p> <p>Takes a course that is either superficial or deep to the lateral pterygoid until reaching the pterygopalatine fossa via the pterygomaxillary fissure</p> <p>Supplies the deep structures of the face and is divided into 3 parts as it passes medially through the infratemporal fossa:</p> <ul style="list-style-type: none"> <li>• 1st part: mandibular</li> <li>• 2nd part: pterygoid</li> <li>• 3rd part: pterygopalatine</li> </ul> <p>1st and 3rd parts do not supply the muscles of mastication</p> <p>2nd part also feeds the buccinator m., which is not a muscle of mastication</p>
2nd part: (pterygoid part)	External carotid a.	<p>Passes obliquely in an anterior and superior direction between the ramus of the mandible and insertion of the temporalis m.</p> <p>Courses on the superficial surface of the lateral pterygoid m. to travel between the 2 heads of the muscle</p> <p>Provides the muscular branches to the muscles of mastication and the buccinator m.</p> <p>Gives rise to 5 branches: anterior and posterior deep temporal, masseteric, pterygoid branches, and buccal</p>
<i>Anterior and posterior deep temporal</i>	Pterygoid (2nd part of the maxillary a.)	<p>Pass between the skull and the temporalis m. Supply the temporalis throughout their course</p> <p>While ascending, they anastomose with the middle temporal a. from the superficial temporal a.</p>
<i>Masseteric</i>		<p>Typically arises between the neck of the mandible and the sphenomandibular lig.</p> <p>Passes laterally through the mandibular notch with the nerve</p> <p>Supplies the deep surface of the masseter</p>
<i>Pterygoid</i>		<p>A branch of the pterygoid a. (2nd part of the maxillary a.)</p> <p>An irregular number of branches supply the medial and lateral pterygoids</p>
<i>Buccal</i>		<p>A branch of the pterygoid a. (2nd part of the maxillary a.)</p> <p>A small artery that runs obliquely in an anterior direction between the medial pterygoid and the insertion of the temporalis m. until it reaches the outer surface of the buccinator, which it supplies</p>
Middle temporal	Superficial temporal a. after it passes superior to the root of the zygomatic arch	<p>Passes deep into the temporalis fascia and temporalis m.</p> <p>Anastomoses with the anterior and posterior deep temporal vessels</p>
Transverse facial	Superficial temporal a. before it exits the parotid gland	<p>Passes transversely to exit the gland</p> <p>Passes immediately superior to the parotid duct across the masseter m. and face, providing vascular supply along the way</p>

# Vascular Supply

## ARTERIAL SUPPLY *CONTINUED*

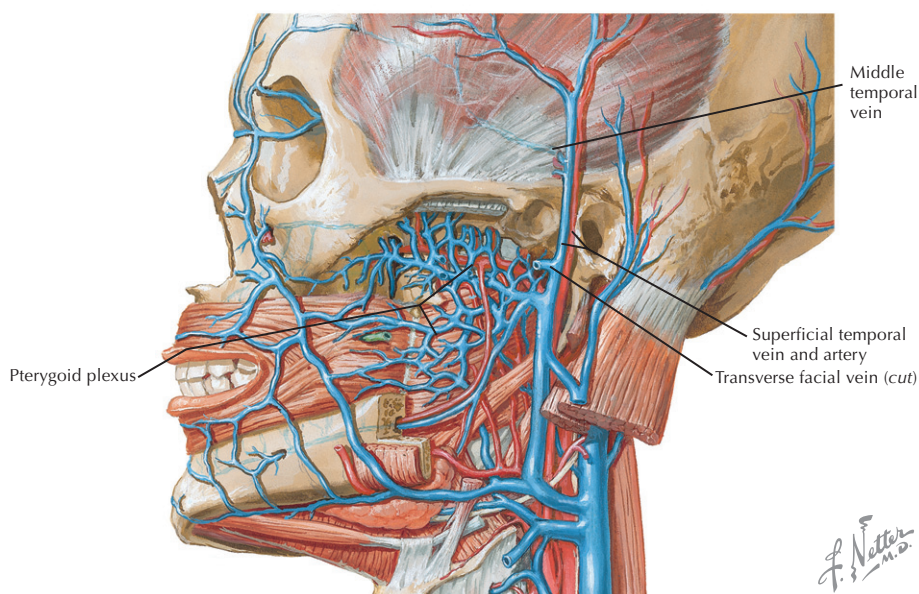
8



## 8 Vascular Supply

### VENOUS DRAINAGE

Vein	Course
Pterygoid plexus	An extensive network of veins that parallel the 2nd and 3rd parts of the maxillary a. Receives branches that correspond with the same branches of the maxillary a. Tributaries of the pterygoid plexus eventually converge to form a short maxillary v. Communicates with the cavernous sinus, pharyngeal venous plexus, facial v. via the deep facial v., and ophthalmic vv.
Middle temporal	Arises from deep within the temporalis m. and fascia, where it anastomoses with the anterior and posterior deep temporal vessels Joins the superficial temporal v. immediately before it passes inferior to the root of the zygomatic arch
Transverse facial	Travels posteriorly to enter the parotid gland and join the superficial temporal v.
Anterior and posterior deep temporal	Join the pterygoid plexus of veins Also communicate with the middle temporal v.
Masseteric	Join the pterygoid plexus of veins
Pterygoid	
Buccal	



# Nerve Supply

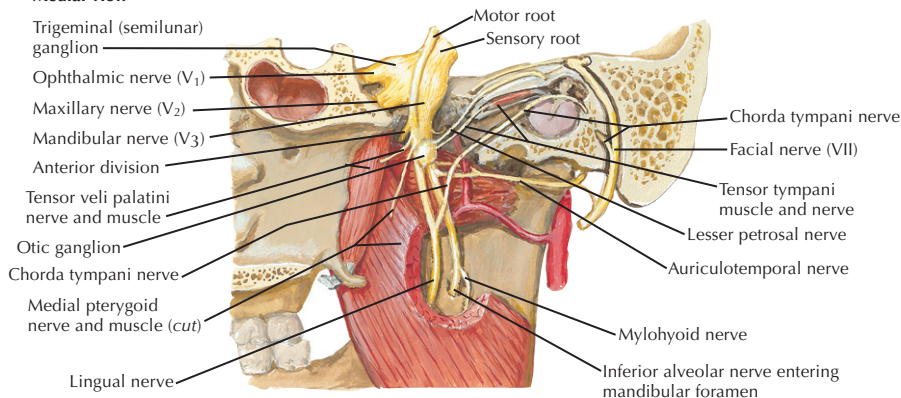
## MOTOR BRANCHES OF THE TRIGEMINAL NERVE

Nerve	Source	Course
Mandibular division of the trigeminal	Largest of the 3 divisions of the trigeminal n. Created by a large sensory and a small motor root that unite just after passing through the foramen ovale to enter the infratemporal fossa	Immediately gives rise to 4 branches: meningeal, medial pterygoid, tensor tympani, and tensor veli palatini Divides into anterior and posterior divisions Anterior division (smaller)—mainly motor with 1 sensory branch (buccal n.) Posterior division (larger)—mainly sensory with 1 motor branch (mylohyoid n.)
Anterior and posterior deep temporal	The anterior part of the mandibular division of the trigeminal n. The anterior deep temporal n. sometimes arises from the buccal n.	Pass superior to the lateral pterygoid m. between the skull and the temporalis m. while passing deep to the temporalis to innervate it Innervates the temporalis
Masseteric	Arises from the anterior part of the mandibular division of the trigeminal n., but occasionally arises from a common branch with the posterior deep temporal n.	Runs superior to the lateral pterygoid m. and continues on the lateral aspect of the muscle as it approaches the mandible Lies anterior to the temporomandibular joint and posterior to the tendon of the temporalis m. Passes through the masseteric notch with the masseteric vessels Enters the masseter m.'s deep surface to innervate it Also provides a small branch to the temporomandibular joint
Medial pterygoid	Arises from the undivided trunk created by the large sensory and the small motor root of the mandibular division of the trigeminal n.	Passes through the otic ganglion to provide motor and proprioceptive innervation to the medial pterygoid m. Passes anteriorly and inferiorly to enter the medial pterygoid Connected to the otic ganglion but does not form a synapse at the ganglion
Lateral pterygoid	Arises from the anterior part of the mandibular division of the trigeminal n., but sometimes arises as a branch from the buccal n.	These branches, 1 for each muscular head, enter the deep surface of the lateral pterygoid m. to innervate it

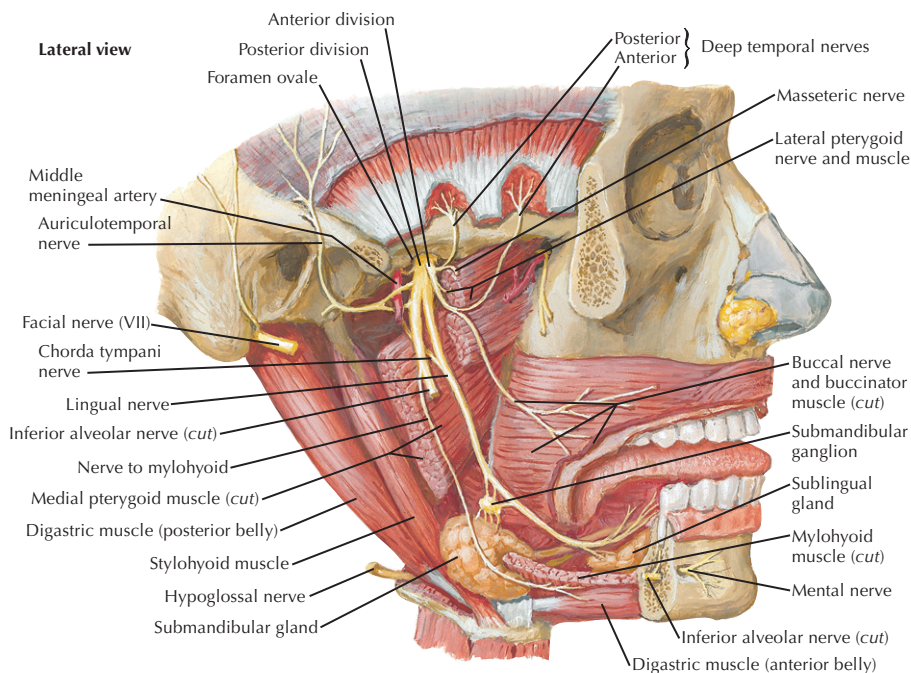
# 8 Nerve Supply

## MOTOR BRANCHES OF THE TRIGEMINAL NERVE *CONTINUED*

### Medial view



### Lateral view



*F. Netter M.D.*



## Clinical Correlate

### MASTICATION

Mastication prepares food by chewing for deglutition and digestion

It is the first step in the breakdown of food by:

- Making smaller pieces from larger pieces (thus increasing the surface area for digestive breakdown)
- Helping soften and lubricate the food with saliva

### BONES INVOLVED

Base of the skull and the mandible

They articulate at the temporomandibular joint (between the squamous portion of the temporal bone [skull] and the condyle of the mandible)

### MUSCLES INVOLVED

4 muscles of mastication:

- Masseter
- Temporalis
- Medial pterygoid
- Lateral pterygoid

All muscles of mastication are innervated by the mandibular division of the trigeminal nerve (nerve of the first pharyngeal arch)

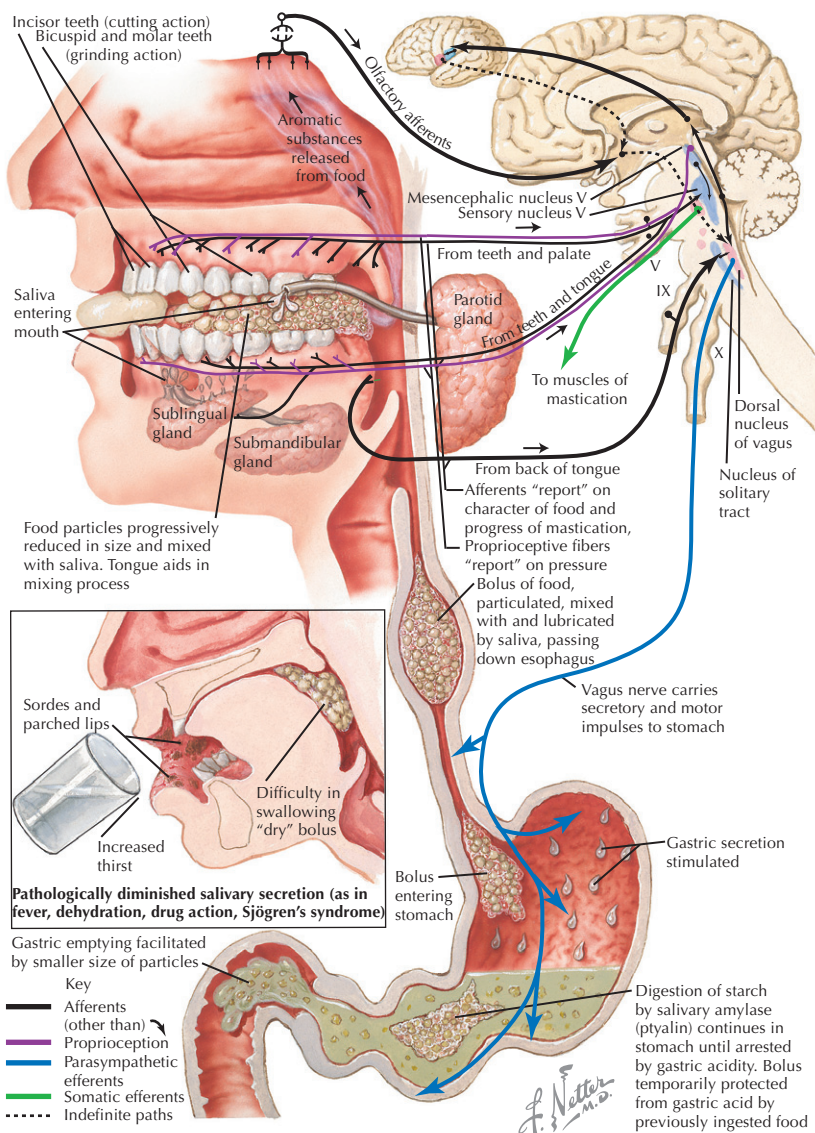
Mastication involves using the muscles of mastication to move the mandible in 1 of 3 planes in an antagonistic fashion:

- Elevation/depression
- Protrusion/retrusion
- Side-to-side excursion

Although the buccinator is not a muscle of mastication, it aids in keeping the bolus of food against the teeth to help in mastication

# 8 Clinical Correlate

## MASTICATION CONTINUED



## CHAPTER 9

# TEMPOROMANDIBULAR JOINT

Overview and Topographic Anatomy	236
Anatomy	237
Vascular Supply	240
Nerve Supply	242
Clinical Correlates	243

## 9 Overview and Topographic Anatomy

### GENERAL INFORMATION

The *temporomandibular joint* (TMJ) is the articulation between the squamous portion of the temporal bone and the condyle of the mandible

#### Structural Components

The TMJ comprises 2 types of synovial joints—*hinge* and *sliding*—and consists of the following:

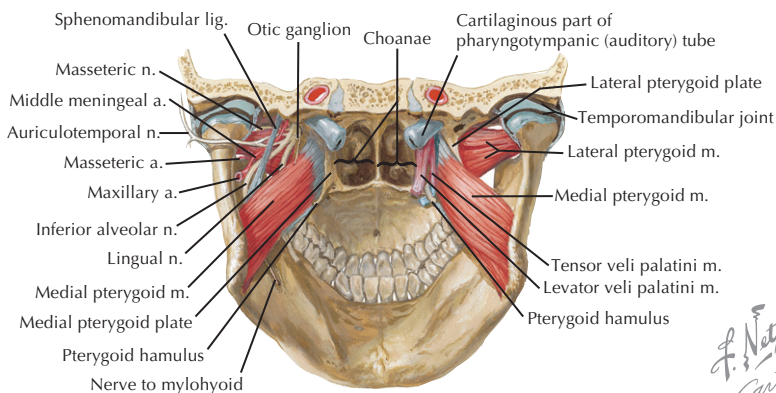
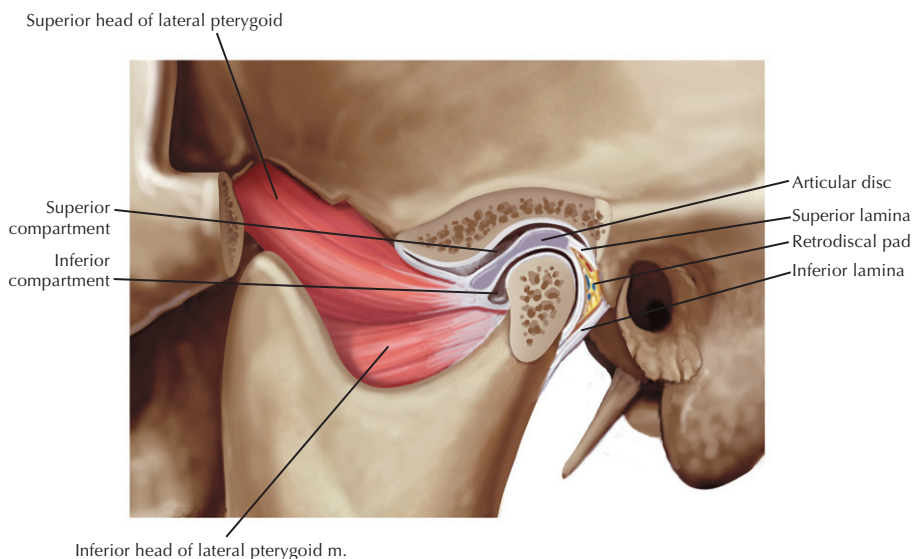
- Squamous portion of the temporal bone
- Articular disc (contained within the TMJ)
- Condyle of the mandible
- Ligaments (serve as boundaries)

#### TMJ Dysfunction

Affects approximately 25% of the population and may be severe in a small subgroup

Causes include arthritis, trauma, infection, bruxism, and disc displacement

More common in females



Posterior view

*F. Netter M.D.  
K. Carter*

# Anatomy

## ANATOMIC FEATURES

Feature	Comments
Squamous portion of the temporal bone	<p>The TMJ articulation is located on the squamous portion of the temporal bone</p> <p>Has an avascular articular surface composed of fibrous connective tissue instead of hyaline cartilage</p> <p>The main load-bearing areas are on the lateral aspect of the squamous portion, condyle, and articular disc</p> <p>The dense fibrous connective tissue is thickest in the load-bearing areas</p> <p>Relations of the squamous portion of the temporal bone:</p> <ul style="list-style-type: none"> <li>• Anterior—articular eminence becoming the articular tubercle</li> <li>• Intermediate—glenoid fossa</li> <li>• Posterior—tympanic plate tapering to the postglenoid tubercle</li> </ul> <p>Articular Eminence</p> <p>The strong bony prominence on the base of the zygomatic process</p> <p>Articular Tubercle</p> <p>Located on the lateral part of the articular eminence</p> <p>Provides attachment for the capsule and lateral temporomandibular ligament</p> <p>Glenoid Fossa</p> <p>The depression into which the condyle is located</p> <p>Superior to this thin plate of bone is the middle cranial fossa</p> <p>Tympanic Plate</p> <p>The vertical plate located anterior to the external auditory meatus</p> <p>Postglenoid Tubercle</p> <p>An inferior extension of the squamous portion of the temporal bone</p> <p>Makes the posterior aspect of the glenoid fossa</p> <p>Provides attachment for the capsule and retrodiscal pad</p>
Mandibular condyles	<p>Articulate with the articular disc</p> <p>Shaped like footballs:</p> <ul style="list-style-type: none"> <li>• Mediolateral—20 mm</li> <li>• Anteroposterior—10 mm</li> </ul> <p>Articular surface is avascular fibrous connective tissue instead of hyaline cartilage</p> <p>The main load-bearing areas are on the lateral aspect</p>
Articular disc	<p>Composed of dense fibrous connective tissue</p> <p>Located between the squamous portion of the temporal bone and the condyle</p> <p>Is avascular and aneural in its central part but is vascular and innervated in the peripheral areas, where load-bearing is minimal</p> <p>The main load-bearing areas are located on the lateral aspect; this is an area of potential perforation</p> <p>Merges around its periphery, attaching to the capsule</p> <p>Divided into 3 bands:</p> <ul style="list-style-type: none"> <li>• Anterior—this thick band lies just anterior to the condyle with the mouth closed</li> <li>• Intermediate—this band, the thinnest part, is located along the articular eminence with the mouth closed</li> <li>• Posterior—this thick band is located superior to the disc with the mouth closed</li> </ul> <p>Additional attachments:</p> <ul style="list-style-type: none"> <li>• Medial/lateral—strong medial and lateral collateral ligaments anchor the disc to the condyle</li> <li>• Anterior—the disc is attached to the capsule and the superior head of the lateral pterygoid, but not the condyle, allowing the disc to rotate over the condyle in an anteroposterior direction</li> <li>• Posterior—the disc is contiguous with the bilaminar zone that blends with the capsule</li> </ul>

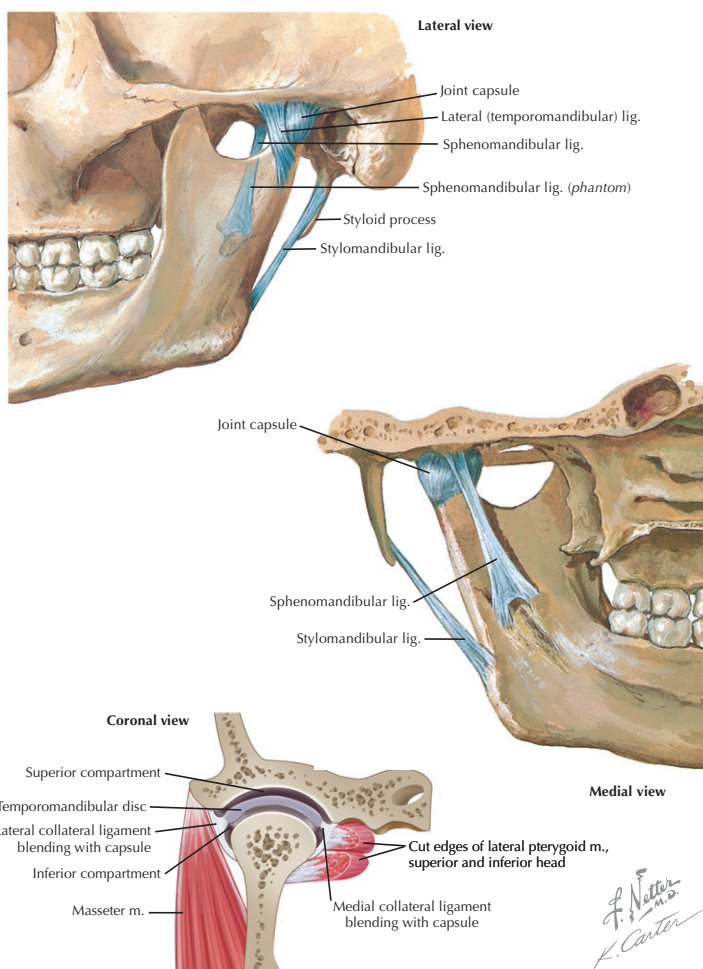


ANATOMIC FEATURES *CONTINUED*

Feature	Comments
Bilaminar zone (posterior attachment complex)	<p>A bilaminar structure located posterior to the articular disc Highly distortable, especially on opening the mouth Composed of:</p> <ul style="list-style-type: none"> <li>• Superior lamina—contains elastic fibers and anchors the superior aspect of the posterior portion of the disc to the capsule and bone at the postglenoid tubercle and tympanic plate</li> <li>• Retrodiscal pad—the highly vascular and neural portion of the TMJ, made of collagen, elastic fibers, fat, nerves, and blood vessels (a large venous plexus fills with blood when the condyle moves anteriorly)</li> <li>• Inferior lamina—contains mainly collagen fibers and anchors the inferior aspect of the posterior portion of the disc to the condyle</li> </ul>
TMJ compartments	<p><b>Overview</b></p> <p>The articular disc divides the TMJ into superior and inferior compartments The internal surface of both compartments contains specialized endothelial cells that form a synovial lining that produces synovial fluid, making the TMJ a synovial joint Synovial fluid acts as:</p> <ul style="list-style-type: none"> <li>• A lubricant</li> <li>• An instrument for providing the metabolic requirements to the articular surfaces of the TMJ</li> </ul> <p><b>Superior Compartment</b></p> <p>Between the squamous portion of the temporal bone and the articular disc Volume = 1.2 mL Provides for the translational movement of the TMJ</p> <p><b>Inferior Compartment</b></p> <p>Between the articular disc and the condyle Volume = 0.9 mL Provides for the rotational movement of the TMJ</p>
Capsule	<p>Completely encloses the articular surface of the temporal bone and the condyle Composed of fibrous connective tissue Toughened along the medial and lateral aspects by ligaments Lined by a highly vascular synovial membrane Has various sensory receptors including nociceptors Attachments:</p> <ul style="list-style-type: none"> <li>• Superior—along the rim of the temporal articular surfaces</li> <li>• Inferior—along the condylar neck</li> <li>• Medial—blends along the medial collateral lig.</li> <li>• Lateral—blends along the lateral collateral lig.</li> <li>• Anterior—blends with the superior head of the lateral pterygoid m.</li> <li>• Posterior—along the retrodiscal pad</li> </ul>
Ligaments	<p><b>Collateral Ligaments</b></p> <ul style="list-style-type: none"> <li>• Composed of 2 ligaments:  <i>Medial collateral ligament</i>—connects the medial aspect of the articular disc to the medial pole of the condyle  <i>Lateral collateral ligament</i>—connects the lateral aspect of the articular disc to the lateral pole of the condyle</li> <li>• Frequently called the discal ligaments</li> <li>• Composed of collagenous connective tissue; thus, they do not stretch</li> </ul> <p><b>Temporomandibular (Lateral) Ligament</b></p> <ul style="list-style-type: none"> <li>• The thickened ligament on the lateral aspect of the capsule</li> <li>• Prevents lateral and posterior displacement of the condyle</li> <li>• Composed of 2 separate bands:  <i>Outer oblique part</i>—largest portion; attached to the articular tubercle; travels posteroinferiorly to attach immediately inferior to the condyle; this limits the opening of the mandible</li> </ul>

## ANATOMIC FEATURES *CONTINUED*

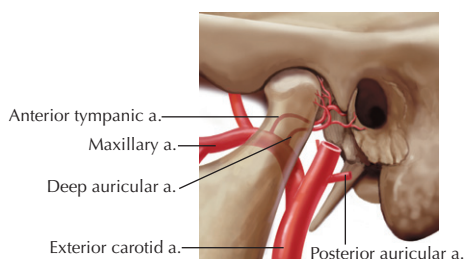
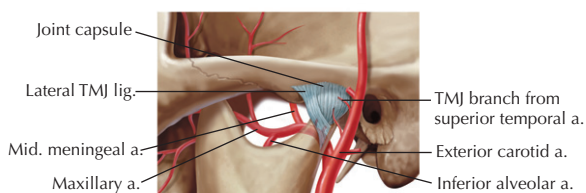
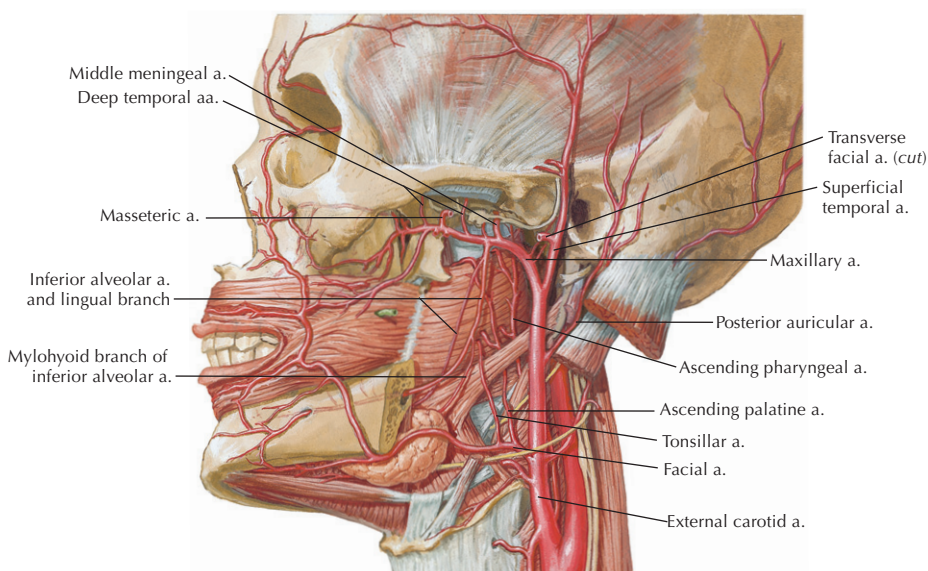
Feature	Comments
Ligaments	<p><i>Inner horizontal part</i>—smaller band attached to the articular tubercle running horizontally to attach to the lateral part of the condyle and disc; this limits posterior movement of the articular disc and the condyle</p> <p><b>Stylomandibular Ligament</b></p> <ul style="list-style-type: none"> <li>• Composed of a thickening of deep cervical fascia</li> <li>• Extends from the styloid process to the posterior margin of the angle and the ramus of the mandible</li> <li>• Helps limit anterior protrusion of the mandible</li> </ul> <p><b>Sphenomandibular Ligament</b></p> <ul style="list-style-type: none"> <li>• Remnant of Meckel's cartilage</li> <li>• Extends from the spine of the sphenoid to the lingula of the mandible</li> <li>• May help act as a pivot on the mandible by maintaining the same amount of tension during both opening and closing of the mouth</li> </ul>



# 9 Vascular Supply

## ARTERIAL SUPPLY

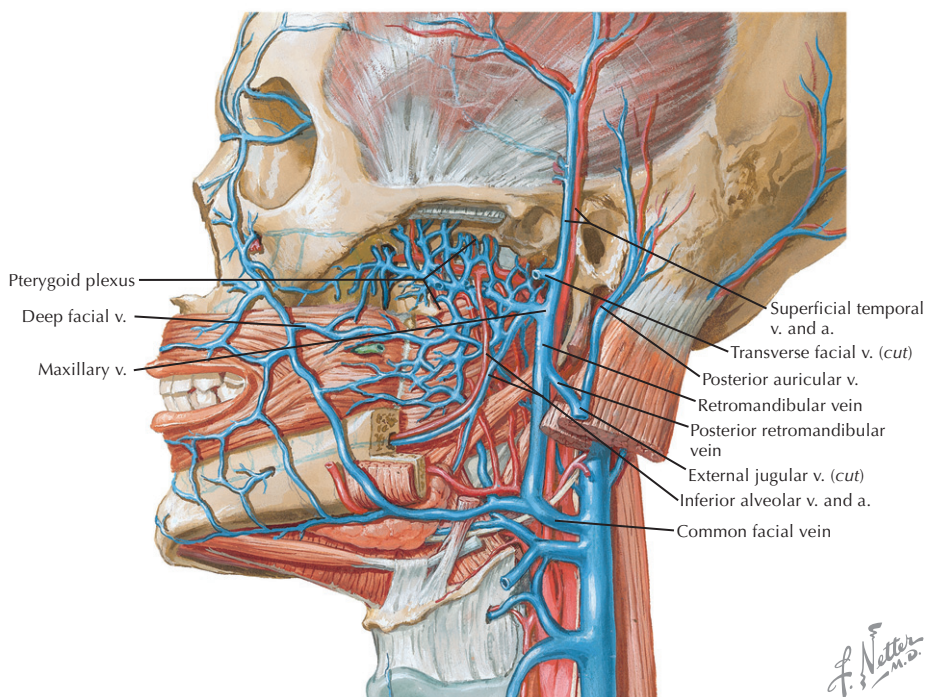
Artery	Source	Course
Superficial temporal	Terminal branch of the external carotid a.	Begins in the parotid gland and initially is located posterior to the mandible, where it provides small branches to the TMJ
Deep auricular	Maxillary a.	Arising in the same area as that of the anterior tympanic a. Lies in the parotid gland, posterior to the TMJ, where it gives branches to the TMJ
Anterior tympanic		Arising in the same area as that of the deep auricular a. Passes superiorly behind the TMJ to enter the tympanic cavity through the petrotympanic fissure, where it gives branches to the TMJ



*F. Netter M.D.*  
*K. Carter*

## VENOUS DRAINAGE

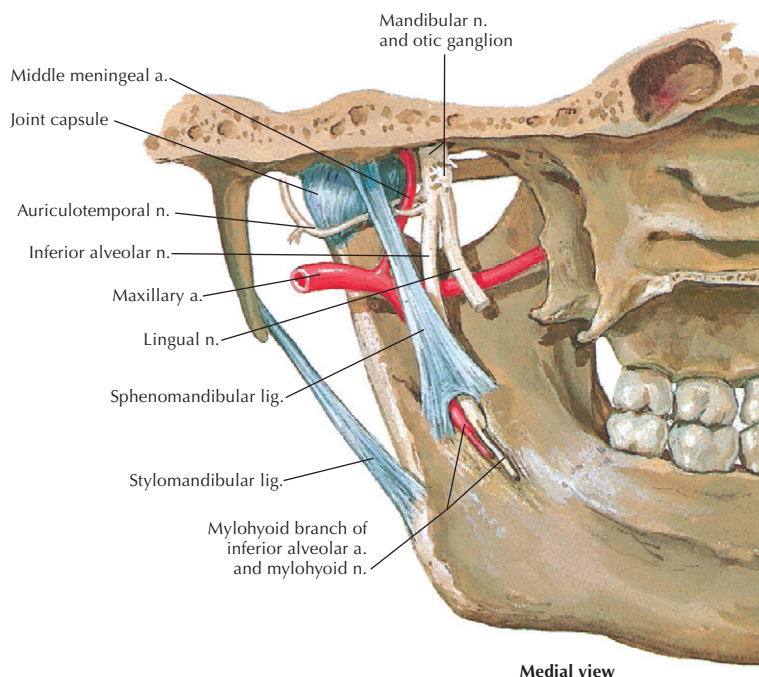
Vein	Course
Superficial temporal	Receives some branches from the TMJ Then joins the maxillary v. to form the retromandibular v.
Maxillary	Receives some branches from the TMJ Joins the superficial temporal v. to form the retromandibular v.



## 9 Nerve Supply

### SENSORY INNERVATION

Nerve	Source	Comment
Auriculotemporal	Mandibular division of the trigeminal n.	From the posterior division of the mandibular division of the trigeminal n. Splits around the middle meningeal a. and passes between the sphenomandibular lig. and the condylar neck Supplies sensory branches all along the capsule Sensory but carries autonomic function to the parotid gland
Masseteric	Anterior division of the mandibular division of the trigeminal n.	Lies anterior to the TMJ and provides branches to the joint before passing over the masseteric notch to reach the masseter m. Sensory branches aid the auriculotemporal n.
Posterior deep temporal		Lies anterior to the TMJ and provides branches to the joint before innervating the temporalis m. Sensory branches aid the auriculotemporal n. in supplying the anterior part of the TMJ Mainly motor, but carries additional sensory function to the TMJ



*F. Netter M.D.*



## Clinical Correlate

### OPENING THE MANDIBLE

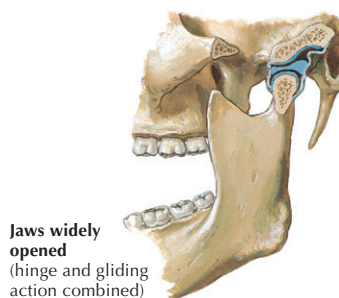
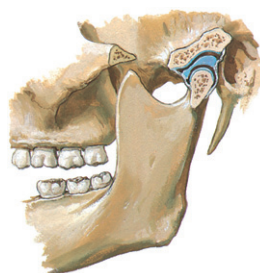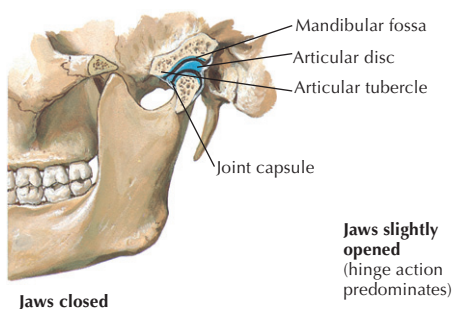
Opening the mandible involves a complex series of movements

Initial movement is *rotational*, which occurs in the lower TMJ compartment:

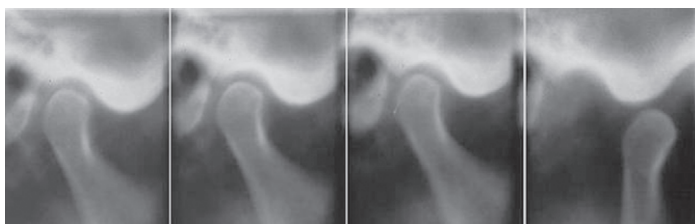
- Lateral pterygoid (inferior head) initiates the opening of the jaw (the superior head of the lateral pterygoid is described as being active during elevation of the mandible in a "power stroke")
- As the mandible is depressed, the medial and collateral ligaments tightly attach the condyle to the articular disc, thereby allowing only for rotational movement
- Once the TMJ becomes taut, no further rotation of the condyle can occur
- Normally, rotational movement continues until the upper and the lower teeth are about 20 mm away from each other

For additional movement of the mandible, *translational* movement must occur:

- A translational movement occurs in the upper TMJ compartment and provides for most of the mandible's ability to open
- In this movement, the articular disc and the condyle complex slide inferiorly on the articular eminences, allowing for maximum depression of the mandible



*F. Netter M.D.*



## 9 Clinical Correlate

### MANDIBULAR DISLOCATION

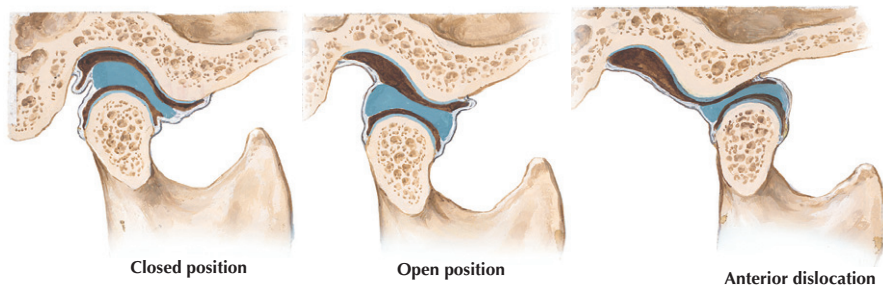
*Mandibular dislocation* (or subluxation of the TMJ) occurs when the condyle moves anterior to the articular eminence

- With dislocation, the mouth appears “wide open”
- Because the condyle is displaced anterior to the articular eminence, a depression can be palpated posterior to the condyle

Spontaneous dislocations can occur from a variety of actions ranging from an extended dental treatment to a simple yawn

Because the mandible is dislocated, the patient has a great deal of difficulty verbalizing his or her predicament

Relocation involves repositioning the condyle posterior to the articular eminence



*F. Netter M.D.*

## Clinical Correlate

### ARTHRITIS AND ANKYLOSIS

#### ARTHRITIS

*Arthritis* is the most common cause of pathologic changes in the TMJ

When rheumatoid arthritis occurs, usually both TMJs are affected, and other joints tend to be affected before the TMJ

Radiologic images in the *initial* disease stages show decreased joint space without osseous changes

Radiologic images in the *late* disease stages show decreased joint space with osseous changes, possibly including ankylosis

In osteoarthritis, causes include normal wear, trauma, and bruxism, and clinical manifestations may range from mild to severe

#### ANKYLOSIS


*Ankylosis* is an obliteration of the TMJ space with abnormal osseous morphologic features, which often occurs as a result of trauma or infection

Classified as either true (intracapsular) or false ankylosis (extracapsular condition usually associated with an abnormally large coronoid process or zygomatic arch)

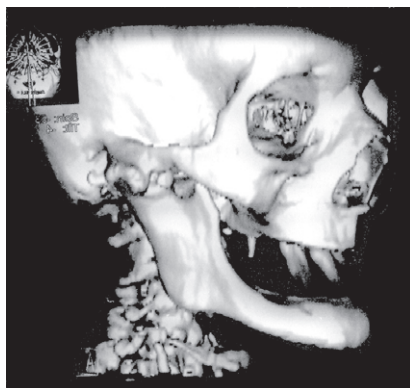
Treatment varies in accordance with the cause but may include a prosthetic replacement or condylectomy

## 9 Clinical Correlate

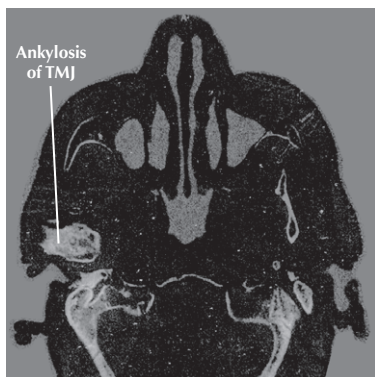
### ARTHRITIS AND ANKYLOSIS *CONTINUED*



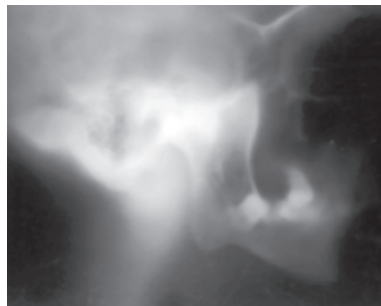
Unilateral ankylosis



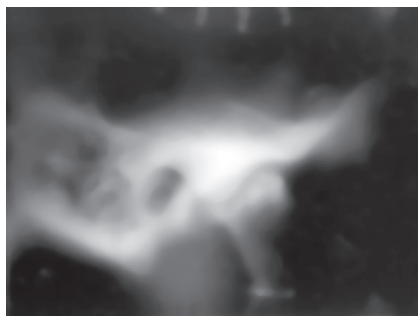
Ankylosis



Ankylosis  
of TMJ



Ankylosis



Osteoarthritis

## CHAPTER 10

# PTERYGOPALATINE FOSSA

Overview and Topographic Anatomy	248
Borders and Openings	249
Contents of the Pterygopalatine Fossa	252
Imaging	263



## 10 Overview and Topographic Anatomy

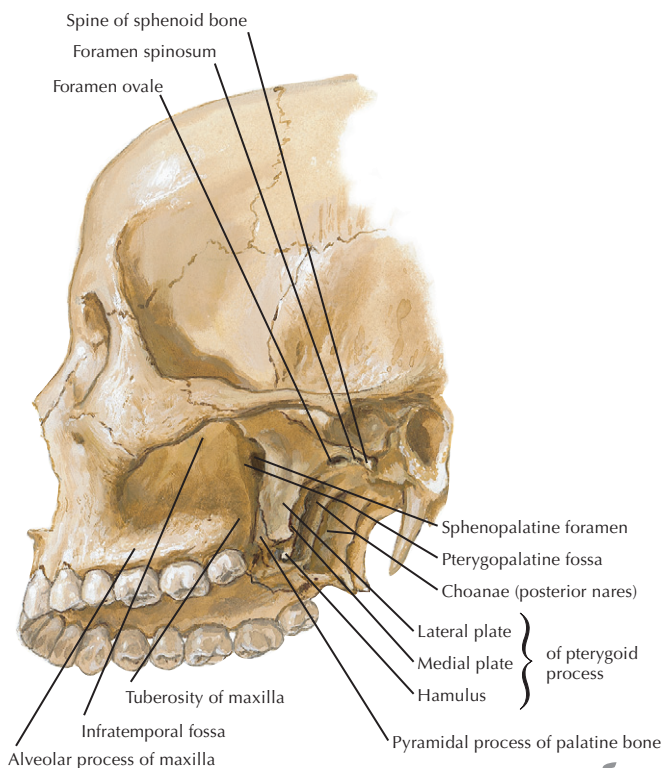
### GENERAL INFORMATION

Pyramid-shaped fossa on the lateral aspect of the skull between the maxilla's infratemporal surface and the pterygoid process of the sphenoid

Contains major nerves and blood vessels that supply the nasal cavity, upper jaw, hard palate, and soft palate: the maxillary division of the trigeminal nerve, pterygopalatine (sphenopalatine, Meckel's) ganglion, and 3rd portion of the maxillary artery

Allows the infratemporal fossa, middle cranial fossa, foramen lacerum, nasopharynx, nasal cavity, orbital cavity, and oral cavity to communicate

7 foramina/fissures allow passage of nerves and vessels



*F. Netter M.D.*

# Borders and Openings

## BORDERS

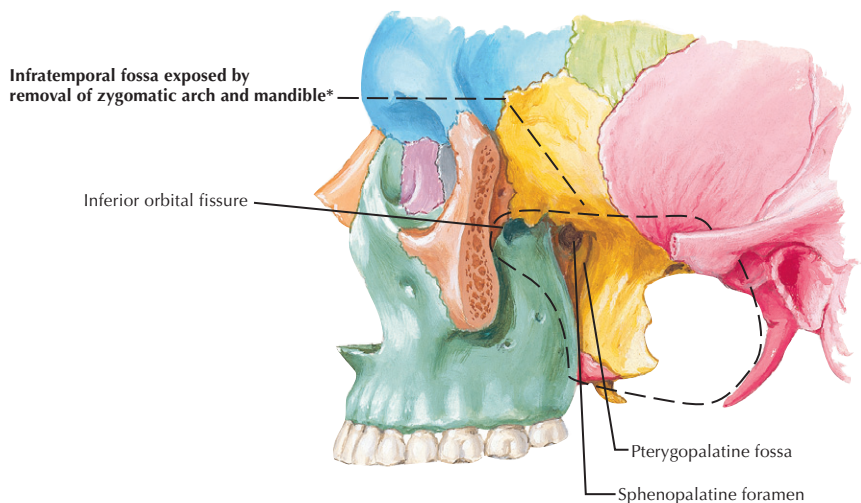
Border	Structures
Anterior wall	Infratemporal surface of the maxilla
Posterior wall	Pterygoid process of the sphenoid
Medial wall	Perpendicular plate of the palatine
Lateral wall	None (open to the pterygomaxillary fissure)
Superior wall	Inferior surface of the sphenoid and the orbital plate of the palatine bone
Inferior wall	Pyramidal process of the palatine

## OPENINGS

Opening	Location	Transmitted Structures
Pterygomaxillary fissure	Lateral part of the pterygopalatine fossa Between the infratemporal fossa and the pterygopalatine fossa	Posterior superior alveolar n. from the pterygopalatine fossa into the infratemporal fossa 3rd part of the maxillary a. from the infratemporal fossa into the pterygopalatine fossa A variable network of veins, such as the sphenopalatine, into the pterygoid plexus of vv.
Sphenopalatine foramen	Medial wall of the pterygopalatine fossa Between the nasal cavity and the pterygopalatine fossa Often located posterior to the middle nasal concha	Nasopalatine n. Posterior superior nasal nn. Sphenopalatine vessels
Inferior orbital fissure	Superior part of the pterygopalatine fossa Between the pterygopalatine fossa and the orbit Continues posteriorly with the superior part of the pterygomaxillary fissure	Infraorbital n. from the maxillary division of the trigeminal n. Zygomatic n. from the maxillary division of the trigeminal Infraorbital vessels Inferior ophthalmic v. that connects with the pterygoid plexus of veins
Palatine canal	Inferior part of the pterygopalatine fossa Between the pterygopalatine fossa and the hard and the soft palate Eventually terminates into the greater and lesser palatine foramina	Greater palatine n. and vessels (through the greater palatine foramen) onto the hard palate Lesser palatine n. and vessels (through the lesser palatine foramen) onto the soft palate
Foramen rotundum	Posterolateral part of the pterygopalatine fossa Between the pterygopalatine fossa and the middle cranial fossa	Maxillary division of the trigeminal n.
Pterygoid canal	Posterior part of the pterygopalatine fossa Between the pterygopalatine fossa and the foramen lacerum Inferior and medial to the foramen rotundum	Nerve of the pterygoid canal (vidian n.) An accompanying artery
Pharyngeal canal	Posteromedial part of the pterygopalatine fossa Between the pterygopalatine fossa and the nasopharynx Medial to the pterygoid canal	Pharyngeal n. Pharyngeal vessels

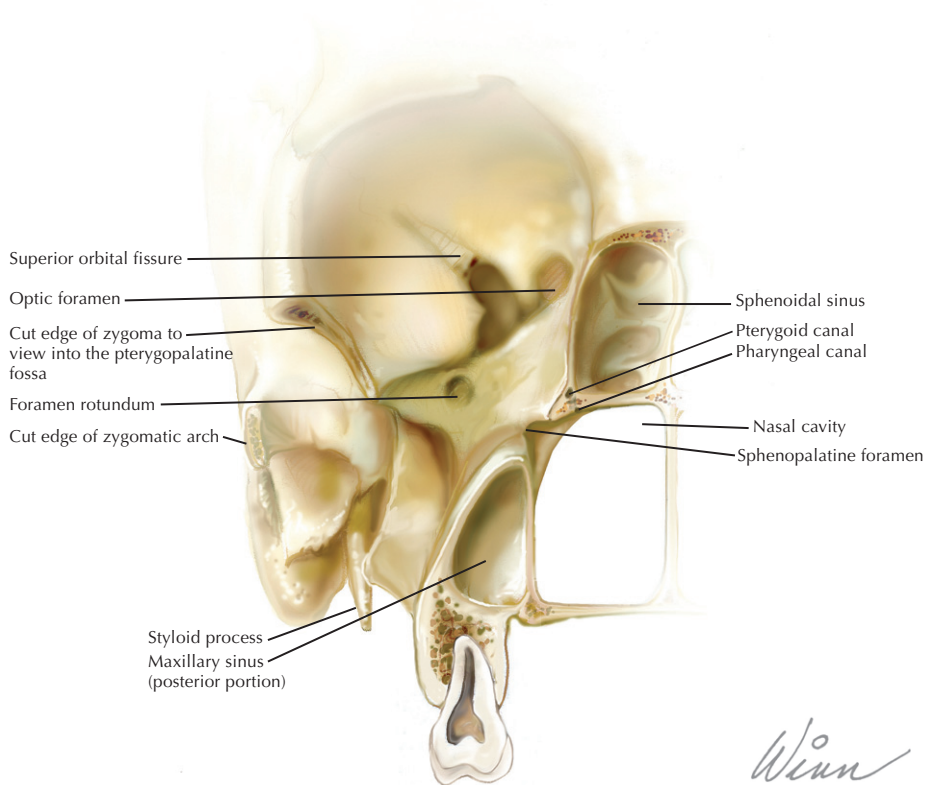
# 10 Borders and Openings

## OPENINGS CONTINUED



\*Superficially, mastoid process forms posterior boundary

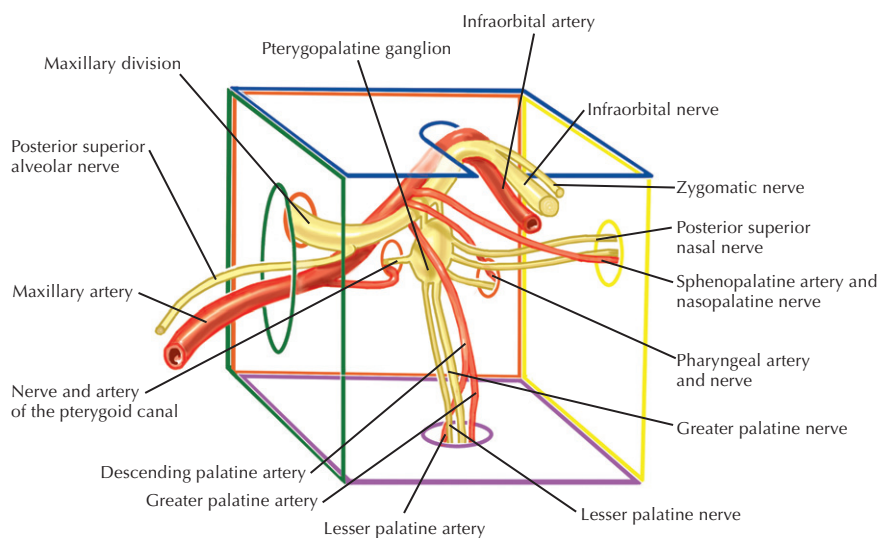
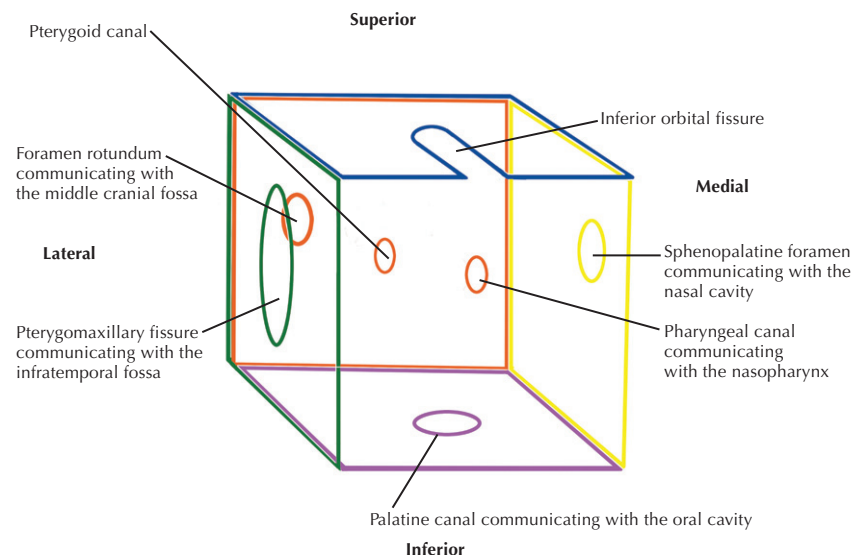
*F. Netter M.D.*



*Winn*

## OPENINGS CONTINUED

Posterior – Red border



Winn

# 10 Contents of the Pterygopalatine Fossa

## VASCULAR SUPPLY

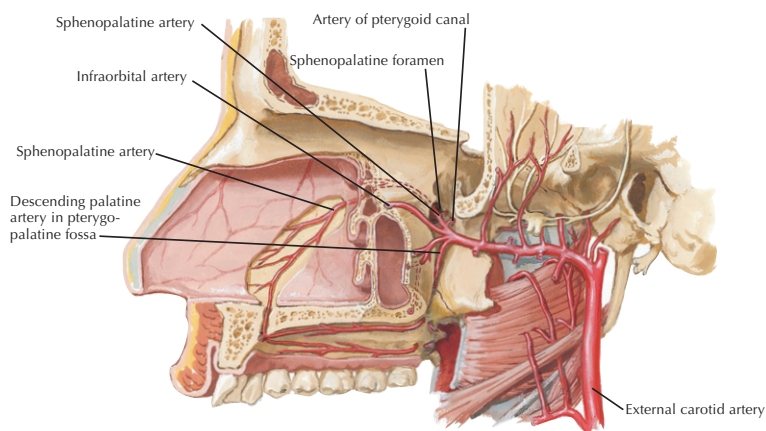
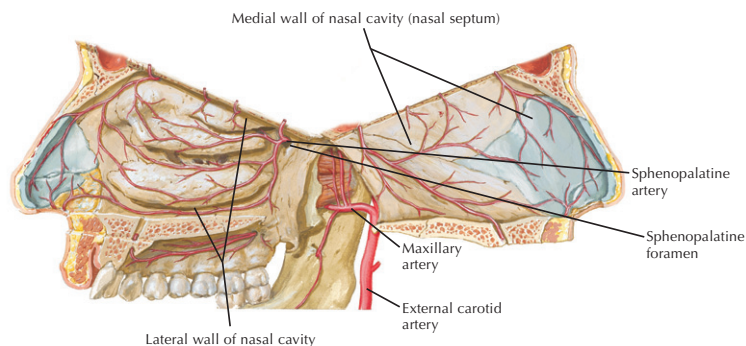
ARTERIAL SUPPLY		
Artery	Source	Course
Maxillary (3rd part)	External carotid a.	Passes from the infratemporal fossa into the pterygopalatine fossa via the pterygomaxillary fissure Prior to passing through the pterygomaxillary fissure, it gives off the posterior superior alveolar a. (the only artery from the 3rd part of the maxillary a. that does not normally branch off within the pterygopalatine fossa)
Infraorbital	The continuation of the 3rd part of the maxillary a.	Accompanied by the infraorbital n. and v. The artery passes forward in the infraorbital groove, infraorbital canal, and exits the infraorbital foramen In the infraorbital canal, it gives rise to various orbital branches that aid in supplying the lacrimal gland and extraocular muscles In the infraorbital canal, it also gives rise to the anterior and middle (if present) superior alveolar aa. that supply the maxillary teeth from the central incisors to the premolars (where they anastomose with the posterior superior alveolar a.) and the mucous membrane of the maxillary sinus On exiting the infraorbital foramen, the artery is located between the levator labii superioris and levator anguli oris mm. and follows the branching pattern of the nerve: <ul style="list-style-type: none"> <li>• Inferior palpebral branch (supplies the lower eyelid)</li> <li>• Nasal branch (supplies the lateral side of the nose)</li> <li>• Superior labial branch (supplies the upper lip)</li> </ul>
Descending palatine	3rd part of the maxillary a.	Descends into the palatine canal Within the canal, the artery splits into the greater and lesser palatine aa. Greater palatine a. exits the greater palatine foramen and passes anteriorly toward the incisive foramen and supplies the hard palate gingiva, mucosa, and palatal glands and anastomoses with the terminal branch of the sphenopalatine a. that exits the incisive foramen Lesser palatine a. supplies the soft palate and palatine tonsil
Artery of the pterygoid canal		Passes posteriorly into the pterygoid canal, accompanying the nerve of the pterygoid canal (vidian n.) Helps supply the auditory tube and sphenoid sinus
Pharyngeal		Passes posteromedially into the pharyngeal canal Helps supply the auditory tube and nasopharynx
Sphenopalatine		Passes medially into the sphenopalatine foramen to enter the nasal cavity It then gives rise to the posterior lateral nasal branches and posterior septal branches, which supply the nasal concha, mucous membranes, and nasal septum The sphenopalatine a. continues along the nasal septum to enter the hard palate via the incisive canal



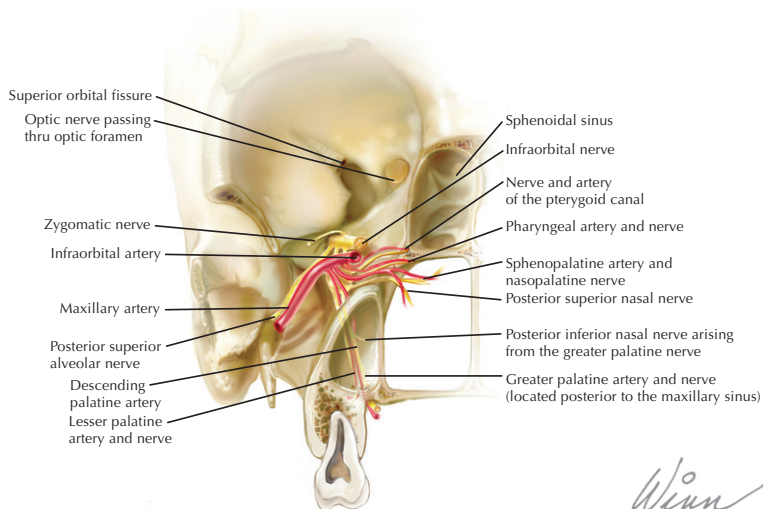
# Contents of the Pterygopalatine Fossa

10

## VASCULAR SUPPLY CONTINUED



*F. Netter M.D.*

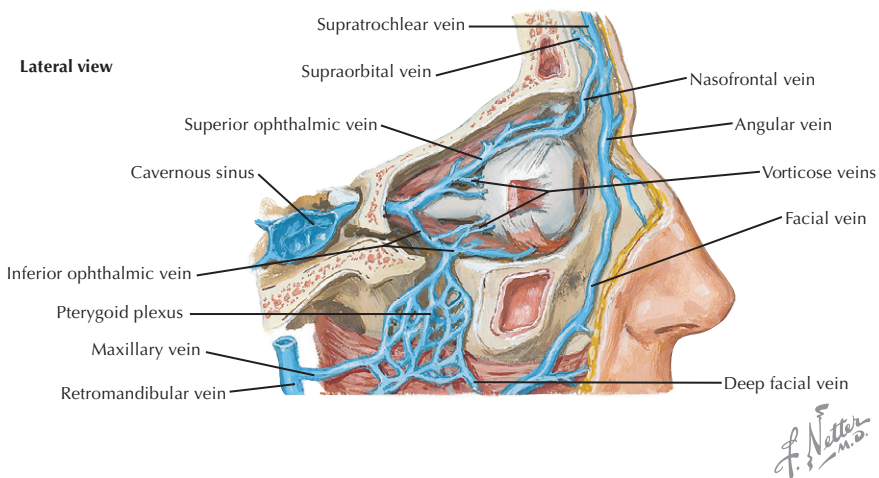


*Winn*

# 10 Contents of the Pterygopalatine Fossa

## VASCULAR SUPPLY *CONTINUED*

VENOUS DRAINAGE		
Vein	Course	
Posterior superior alveolar	Receives blood from the posterior teeth and soft tissue	Eventually communicate with the pterygoid plexus of veins
Pharyngeal	Receives blood from the nasopharynx	
Descending palatine	Receives blood from the hard and soft palate	
Infraorbital	Receives blood from the midface via the lower eyelid, lateral side of the nose, and the upper lip	
Sphenopalatine	Receives blood from the nasal cavity and the nasal septum	
Vein of the pterygoid canal	Receives blood from the foramen lacerum region and the sphenoid sinus	
Inferior ophthalmic	Receives blood from the floor of the orbit Branches into 2 parts The first branch travels posteriorly with the infraorbital v. that passes through the inferior orbital fissure to communicate with the pterygoid plexus and the cavernous sinus The main branch travels posteriorly to communicate with the superior ophthalmic vein in the superior orbital fissure or travels posteriorly in the fissure to join the cavernous sinus	
Pterygoid plexus	An extensive network of veins that parallels the 2nd and 3rd parts of the maxillary a. The tributaries of the pterygoid plexus eventually converge to form a short maxillary v.	

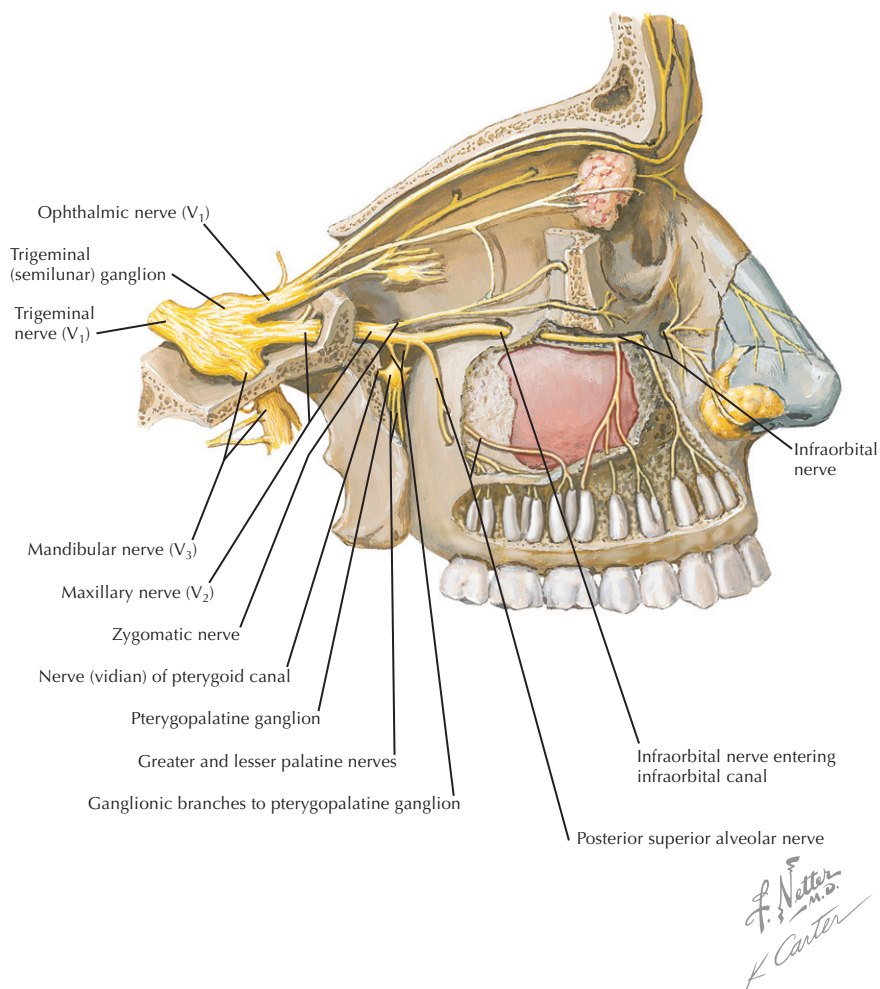


## NERVE SUPPLY

MAXILLARY NERVE		
Nerve	Source	Course
Maxillary division of the trigeminal n.	Trigeminal n.	<p>Sensory in function</p> <p>Travels along the lateral wall of the cavernous sinus</p> <p>Before exiting the middle cranial fossa, it gives off a meningeal branch that innervates the dura mater</p> <p>Passes from the middle cranial fossa into the pterygopalatine fossa via the foramen rotundum</p> <p>Within the pterygopalatine fossa, gives rise to 4 branches:</p> <ul style="list-style-type: none"> <li>• Posterior superior alveolar n.</li> <li>• Zygomatic n.</li> <li>• Ganglionic branches</li> <li>• Infraorbital n.</li> </ul>
Posterior superior alveolar	Maxillary division of the trigeminal n. in pterygopalatine fossa	<p>Passes through the pterygomaxillary fissure to enter the infratemporal fossa</p> <p>In the infratemporal fossa, it passes on the posterior surface of the maxilla along the region of the maxillary tuberosity</p> <p>Gives rise to a gingival branch that innervates the buccal gingiva alongside the maxillary molars</p> <p>Enters the posterior surface of the maxilla and supplies the maxillary sinus and the maxillary molars with the possible exception of the mesiobuccal root of the 1st maxillary molar</p>
Zygomatic		<p>Passes through the inferior orbital fissure to enter the orbit</p> <p>Passes on the lateral wall of the orbit and branches into the zygomaticotemporal and zygomaticofacial branches</p> <p>A communicating branch from it joins the lacrimal n. from the ophthalmic division of the trigeminal to carry autonomics to the lacrimal gland</p>
Ganglionic branches		<p>Usually 1 or 2 ganglionic branches that connect the maxillary division of the trigeminal to the pterygopalatine ganglion</p> <p>Contain sensory fibers that pass through the pterygopalatine ganglion (without synapsing) to be distributed with the nerves that arise from the pterygopalatine ganglion</p> <p>Also contain postganglionic autonomic fibers to the lacrimal gland that pass through the pterygopalatine ganglion (Parasympathetic fibers form a synapse here between the preganglionic fibers from the vidian n. and the postganglionic fibers)</p>
Infraorbital	Considered the continuation of the maxillary division of the trigeminal n.	<p>Passes through the inferior orbital fissure to enter the orbit</p> <p>Passes anteriorly through the infraorbital groove, infraorbital canal, and exits onto the face via the infraorbital foramen</p> <p>Within the infraorbital canal, it gives rise to:</p> <ul style="list-style-type: none"> <li>• Anterior superior alveolar (supplies the maxillary sinus; maxillary central incisor, lateral incisor, and canine; gingiva and mucosa alongside the same teeth)</li> <li>• A small branch of the anterior superior alveolar (supplies the nasal cavity)</li> <li>• Middle superior alveolar (present about 70% of the time; supplies the maxillary sinus, maxillary premolars and often the mesiobuccal root of the 1st maxillary molar, and gingiva and mucosa alongside the same teeth)</li> </ul>

## 10 Contents of the Pterygopalatine Fossa

### NERVE SUPPLY *CONTINUED*



## NERVE SUPPLY *CONTINUED*

### BRANCHES OF THE MAXILLARY DIVISION OF THE TRIGEMINAL NERVE ASSOCIATED WITH THE PTERYGOPALATINE GANGLION

A parasympathetic ganglion named because it is a collection of cell bodies in the peripheral nervous system (postganglionic cell bodies)

The ganglionic branches are of the maxillary division of the trigeminal n. that pass through the pterygopalatine ganglion

The vidian n. connects to the pterygopalatine ganglion

3 sets of nerve fibers travel through the pterygopalatine ganglion:

- General sensory fibers from the trigeminal n. (without synapsing)
- Postganglionic sympathetic fibers (carried to the pterygopalatine ganglion via the vidian n, without synapsing)
- Preganglionic parasympathetic fibers (carried to the pterygopalatine ganglion via the vidian n. and formed by synapsing in the pterygopalatine ganglion with the postganglionic parasympathetic fibers)

All branches arising from the pterygopalatine ganglion carry these 3 sets of fibers to the areas where they terminate

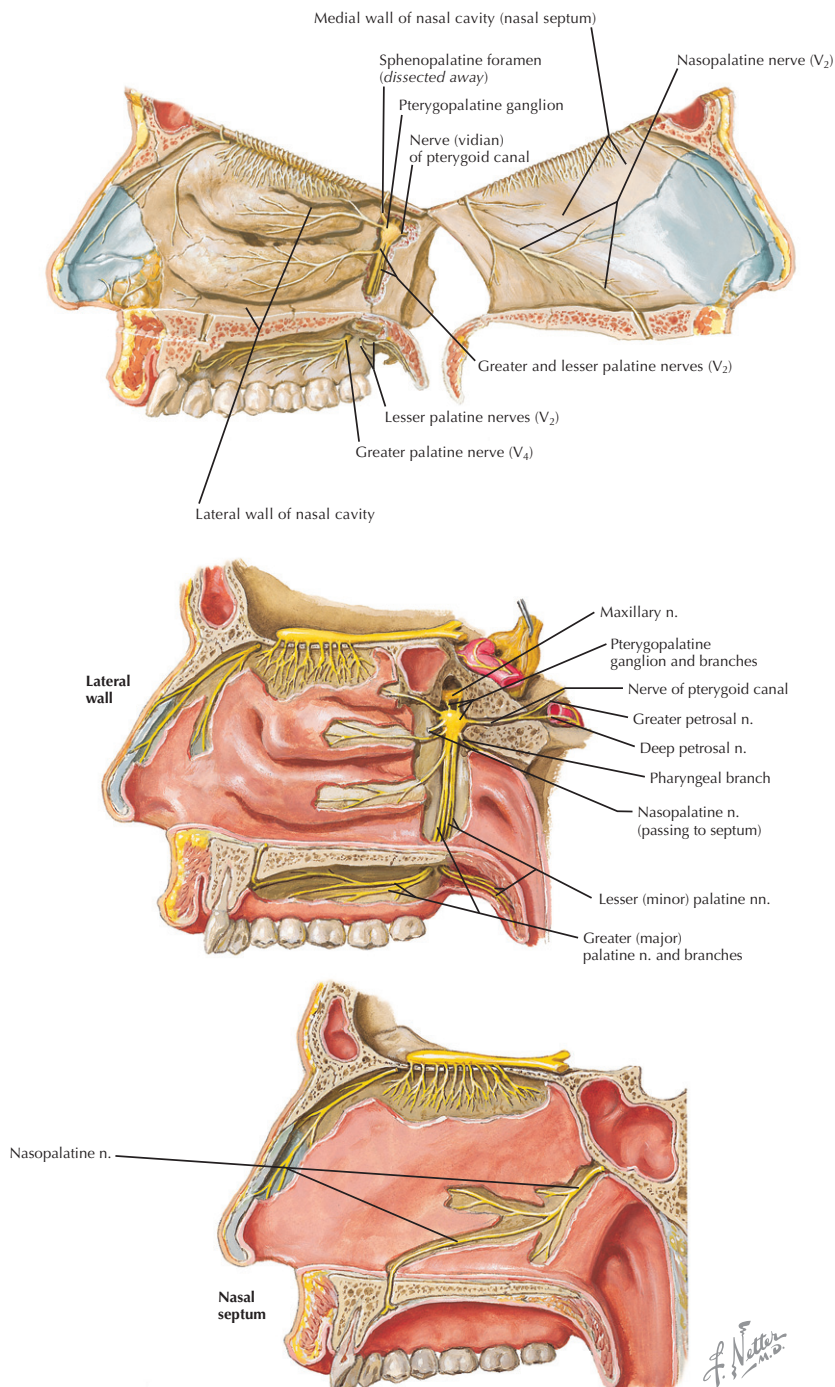
These nerves of the maxillary division travel through the pterygopalatine ganglion:

- Nasopalatine n.
- Posterior superior nasal n.
- Greater palatine n.
- Lesser palatine n.
- Pharyngeal n.

Branch	Source	Course
Vidian (nerve of the pterygoid canal)	Formed by the greater and deep petrosal nn.	An autonomic nerve: <ul style="list-style-type: none"> <li>• Greater petrosal n. carries the preganglionic parasympathetic fibers</li> <li>• Deep petrosal n. carries the postganglionic sympathetic fibers</li> </ul> Communicates with the pterygopalatine ganglion, which allows the autonomics to be distributed along any nerve connected to the ganglion
Nasopalatine	Branches of the pterygopalatine ganglion in the pterygopalatine fossa	Passes through the sphenopalatine foramen to enter the nasal cavity Passes along the superior portion of the nasal cavity to the nasal septum; then travels anteroinferiorly to the incisive canal Exits the incisive foramen on the hard palate and supplies the palatal gingiva and mucosa from the region of the central incisors to the canines
Posterior superior nasal		Passes through the sphenopalatine foramen to enter the nasal cavity, where it divides into 2 nerves: <ul style="list-style-type: none"> <li>• Lateral posterior superior (supplies the lateral wall of the nasal cavity)</li> <li>• Medial posterior superior nasal (supplies the posterosuperior portion of the nasal septum)</li> </ul>
Greater palatine		Passes through the palatine canal to enter the hard palate via the greater palatine foramen Supplies the palatal gingiva and mucosa from the area in the premolar region to the posterior border of the hard palate to the midline
Lesser palatine		Passes through the palatine canal to enter and supply the soft palate via the lesser palatine foramen
Pharyngeal		Passes through the pharyngeal canal to enter and supply the nasopharynx

# 10 Contents of the Pterygopalatine Fossa

## NERVE SUPPLY CONTINUED





# Contents of the Pterygopalatine Fossa

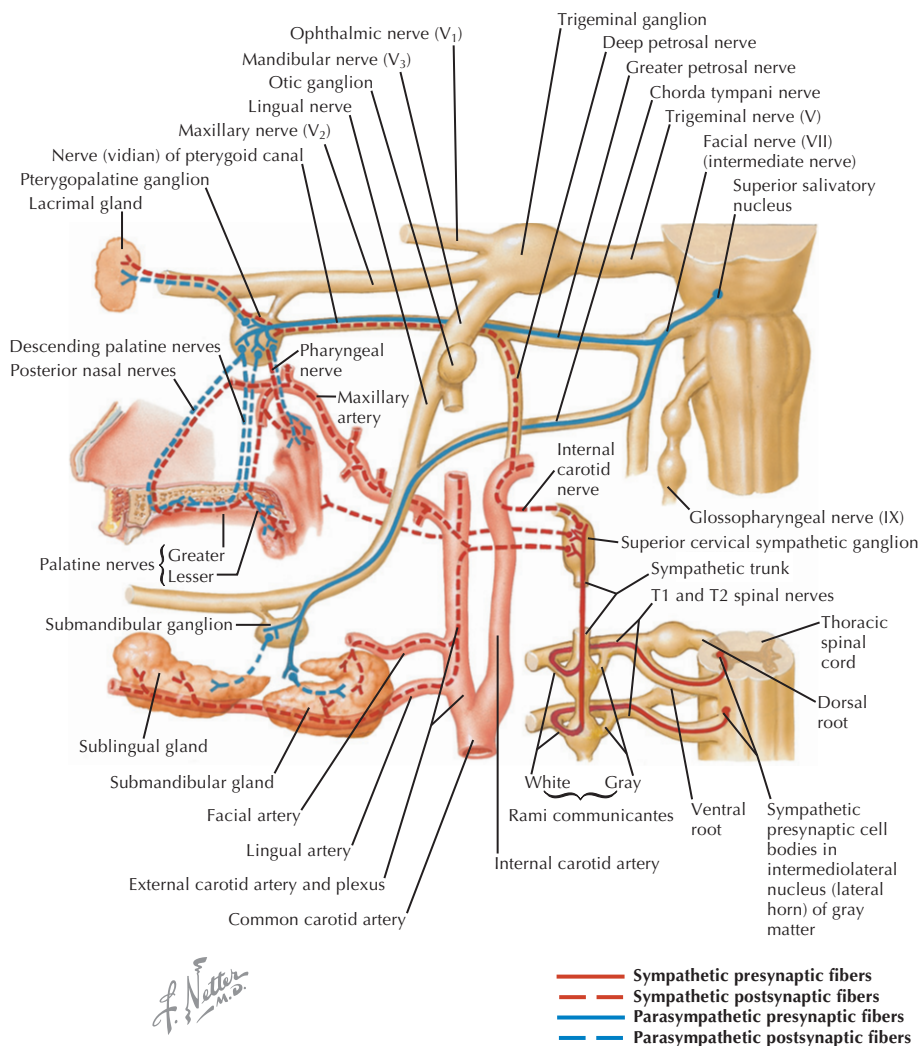
## NERVE SUPPLY *CONTINUED*

10

AUTONOMICS TRAVERSING THE PTERYGOPALATINE FOSSA			
Type of Neuron	Name of Cell Body	Characteristics of the Cell Body	Course of the Neuron
Anatomic Pathway for Parasympathetics Associated with the Maxillary Division of the Trigeminal Nerve			
Preganglionic neuron	Superior salivatory nucleus	<p>A collection of nerve cell bodies located in the pons</p> <p>Travel through the nervus intermedius of the facial n. into the internal acoustic meatus</p> <p>In the facial canal, the facial n. gives rise to 2 parasympathetic branches:</p> <ul style="list-style-type: none"> <li>• Greater petrosal n.</li> <li>• Chorda tympani n.</li> </ul>	<p><b>Greater Petrosal Nerve</b></p> <p>Greater petrosal n. exits along the hiatus for the greater petrosal n. toward the foramen lacerum, where it joins the deep petrosal n. (sympathetics) to form the nerve of the pterygoid canal (vidian n.)</p> <p>Vidian n. passes through the pterygoid canal and enters the pterygopalatine fossa, where it joins with the pterygopalatine ganglion</p>
Postganglionic neuron	Pterygopalatine ganglion	<p>Pterygopalatine ganglion is a collection of nerve cell bodies located in the pterygopalatine fossa</p> <p>Postganglionic parasympathetic fibers that arise in the pterygopalatine ganglion are distributed to the ophthalmic and maxillary divisions of the trigeminal n. to the:</p> <ul style="list-style-type: none"> <li>• Lacrimal gland</li> <li>• Nasal glands</li> <li>• Palatine glands</li> <li>• Pharyngeal glands</li> </ul>	<p><b>Ophthalmic Division Distribution</b></p> <p>Postganglionic fibers travel along the zygomatic branch of the maxillary division for a short distance to enter the orbit</p> <p>A short communicating branch joins the lacrimal n. of the ophthalmic division of the trigeminal n.</p> <p>These fibers innervate the lacrimal gland to cause the secretion of tears</p> <p><b>Maxillary Division Distribution</b></p> <p>Postganglionic fibers travel along the maxillary division of the trigeminal n. to be distributed along its branches that are located in the nasal cavity, oral cavity, and pharynx (e.g., nasopalatine, greater palatine)</p> <p>These fibers innervate:</p> <ul style="list-style-type: none"> <li>• Nasal glands</li> <li>• Palatine glands</li> <li>• Pharyngeal glands</li> </ul>

# 10 Contents of the Pterygopalatine Fossa

## NERVE SUPPLY CONTINUED



# Contents of the Pterygopalatine Fossa

10

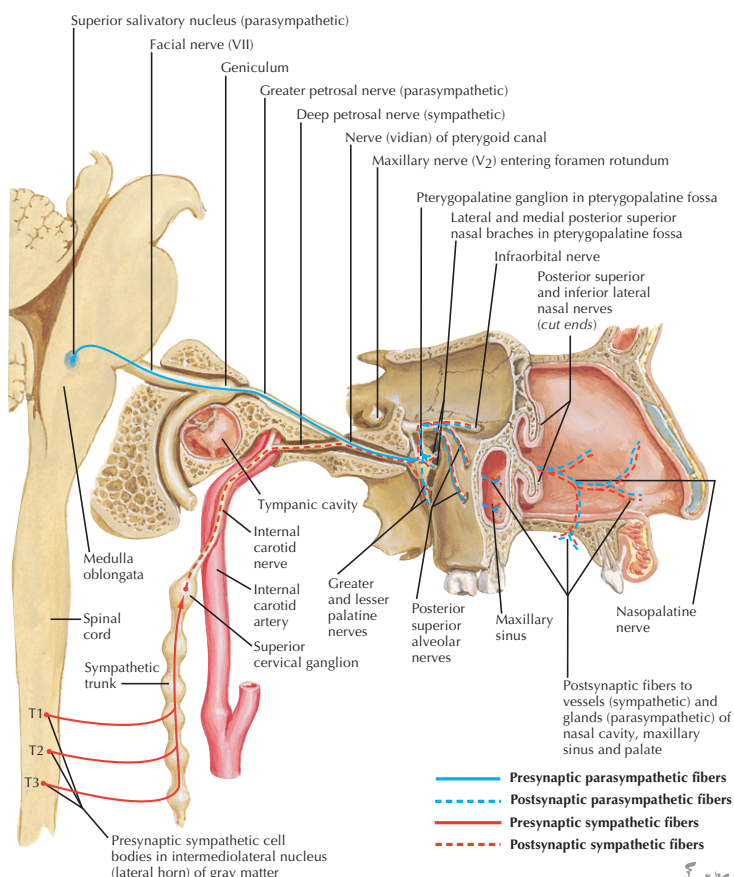
## NERVE SUPPLY *CONTINUED*

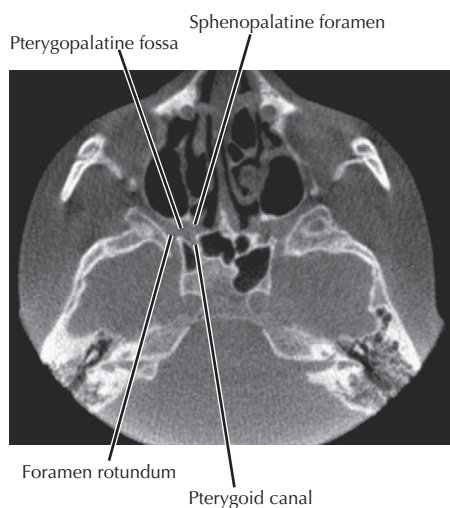
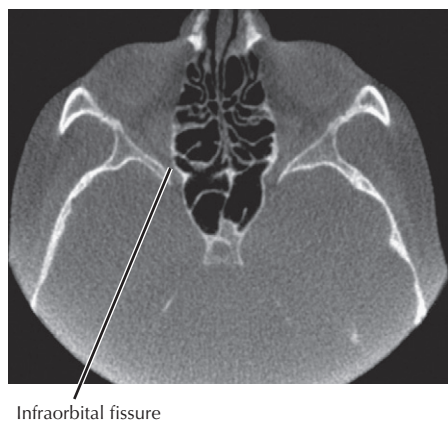
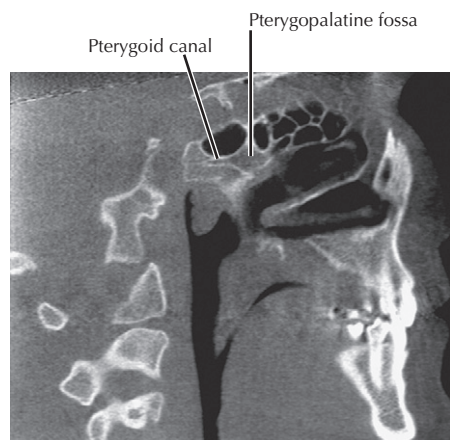
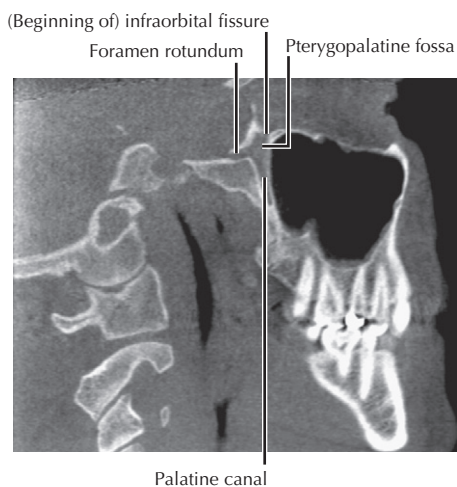
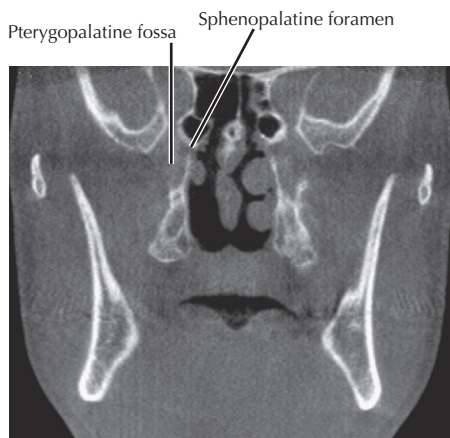
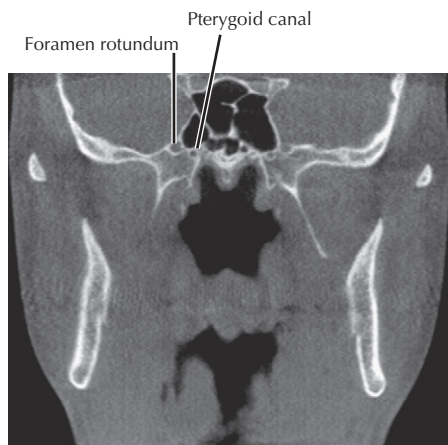
AUTONOMICS TRAVERSING THE PTERYGOPALATINE FOSSA <i>CONTINUED</i>			
Type of Neuron	Name of Cell Body	Characteristics of the Cell Body	Course of the Neuron
Anatomic Pathway for Sympathetics Associated with the Maxillary Division of the Trigeminal Nerve			
Preganglionic neuron	Intermediolateral horn nucleus	Collection of nerve cell bodies located in the lateral horn nucleus of the spinal cord between spinal segments T1 and T3 (and possibly T4)	<p>Arise from the intermediolateral horn nuclei from T1 to T3 (4)</p> <p>Travel through the ventral root of the spinal cord to the spinal n.</p> <p>Enter the sympathetic chain via a white ramus communicantes</p> <p>Once in the sympathetic chain, the preganglionic fibers for the eye will ascend and synapse with postganglionic fibers in the superior cervical ganglion</p>
Postganglionic neuron	Superior cervical ganglion	<p>Collection of nerve cell bodies located in the superior cervical ganglion, which is located at the base of the skull</p> <p>Postganglionic sympathetic fibers follow the internal carotid or external carotid a. to pass near their respective effector organs (e.g., nasal cavity)</p>	<p><b>Nasal Cavity and Palate</b></p> <p>Postganglionic sympathetic fibers follow both the internal and external carotid aa.</p> <p>Postganglionic sympathetic fibers from the internal carotid branch in the region of the foramen lacerum to form the deep petrosal n.</p> <p>The deep petrosal n. joins the greater petrosal n. (parasympathetics) to form the nerve of the pterygoid canal (vidian n.)</p> <p>Postganglionic sympathetic fibers travel along the branches of the maxillary division of the trigeminal n. associated with the pterygopalatine ganglion to be distributed along its branches in the nasal cavity and palate</p> <p>Postganglionic sympathetic fibers from the external carotid branch and follow the maxillary a.</p> <p>These fibers travel along the branches of the maxillary a. to be distributed along the nasal cavity and palate</p> <p><b>Lacrimal Gland</b></p> <p>Postganglionic sympathetic fibers follow the internal carotid a.</p> <p>Postganglionic sympathetic fibers from the internal carotid branch off in the region of the foramen lacerum to form the deep petrosal n.</p>

# 10 Contents of the Pterygopalatine Fossa

## NERVE SUPPLY *CONTINUED*

AUTONOMICS TRAVERSING THE PTERYGOPALATINE FOSSA <i>CONTINUED</i>			
Type of Neuron	Name of Cell Body	Characteristics of the Cell Body	Course of the Neuron
Anatomic Pathway for Sympathetics Associated with the Maxillary Division of the Trigeminal Nerve			
Postganglionic neuron			<p>The deep petrosal n. joins the greater petrosal n. (parasympathetics) to form the nerve of the pterygoid canal (vidian n.)</p> <p>Postganglionic fibers travel along the zygomatic branch of the maxillary division for a short distance to enter the orbit</p> <p>A short communicating branch joins the lacrimal n. of the ophthalmic division of the trigeminal n.</p> <p>These fibers are distributed to the lacrimal gland</p>









# CHAPTER 11

## NOSE AND NASAL CAVITY

Overview and Topographic Anatomy	266
Nose	268
Nasal Cavity	276
Clinical Correlates	294
Imaging	298

**GENERAL INFORMATION****Nose**

The prominent anatomic structure located inferior and medial to the eyes

Helps in breathing and olfaction

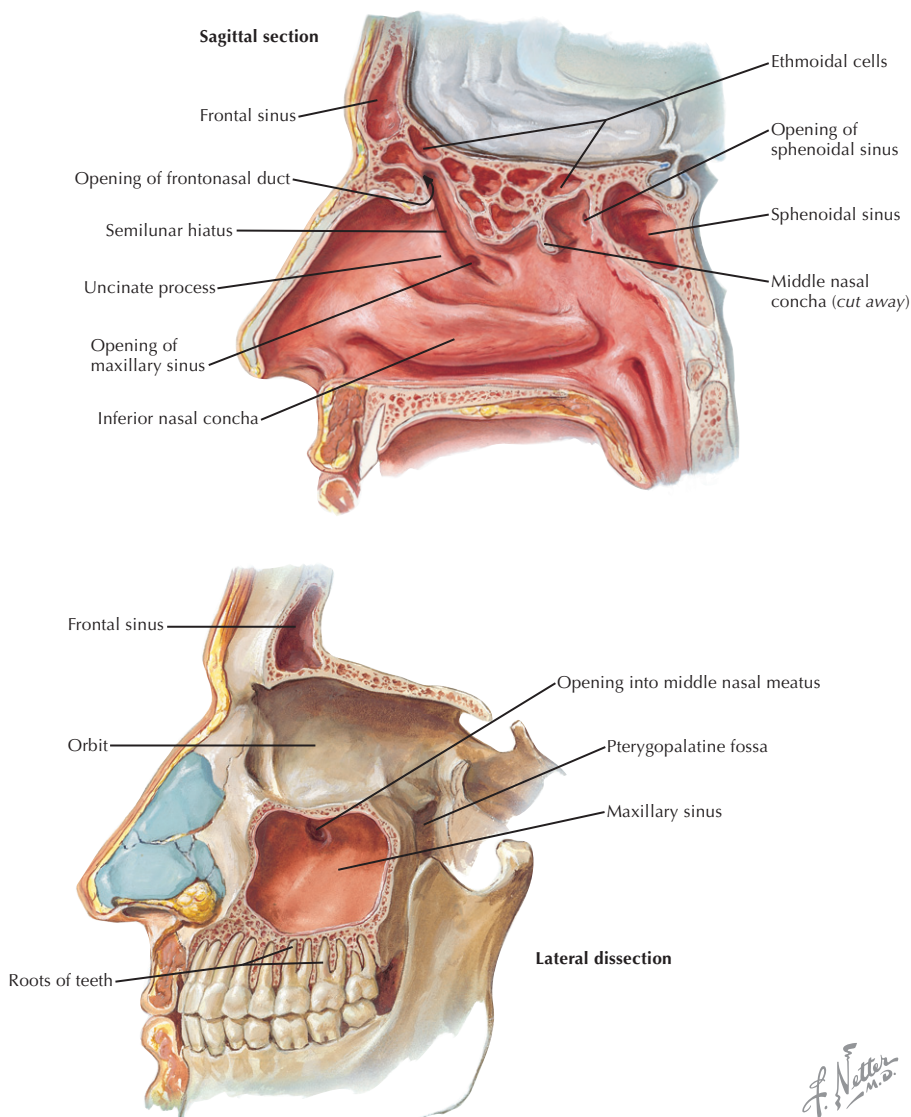
**Nasal Cavity**

The complex chamber located posterior to the vestibule and atrium of the nose

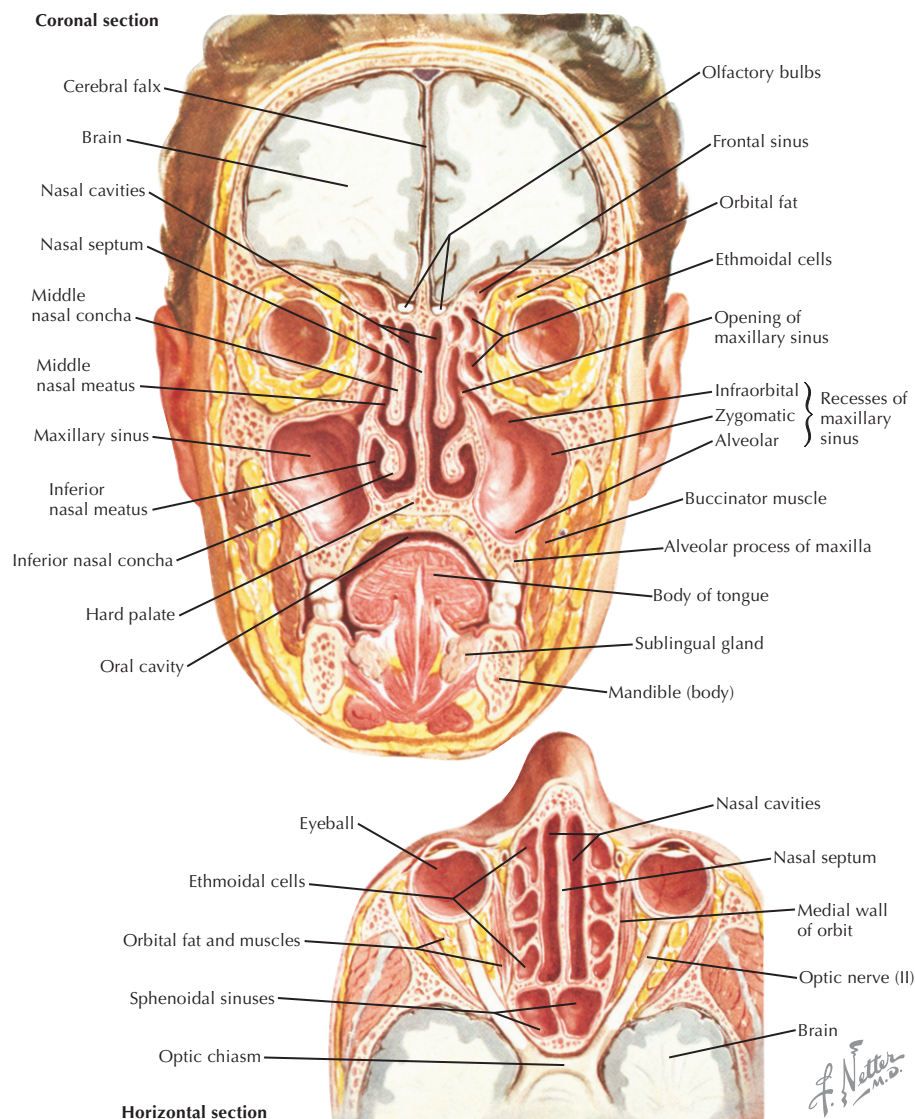
**Respiratory Epithelium**

Highly vascular and easily congested

When this tissue is irritated, its blood vessels reflexively dilate and the glands secrete, normally leading to sneezing



## GENERAL INFORMATION CONTINUED



**ANATOMY OF THE NOSE**

The nose is pyramidal in form

3 pairs of *bones* form the root of the nose:

- Frontal (nasal process)
- Maxilla (frontal process)
- Nasal

Because the root of the nose is made of bone, it is fixed

3 different *cartilages* form the dorsum and apex of the nose:

- Septal
- Lateral nasal
- Alar

Because the dorsum and apex are cartilaginous, the nose is quite mobile

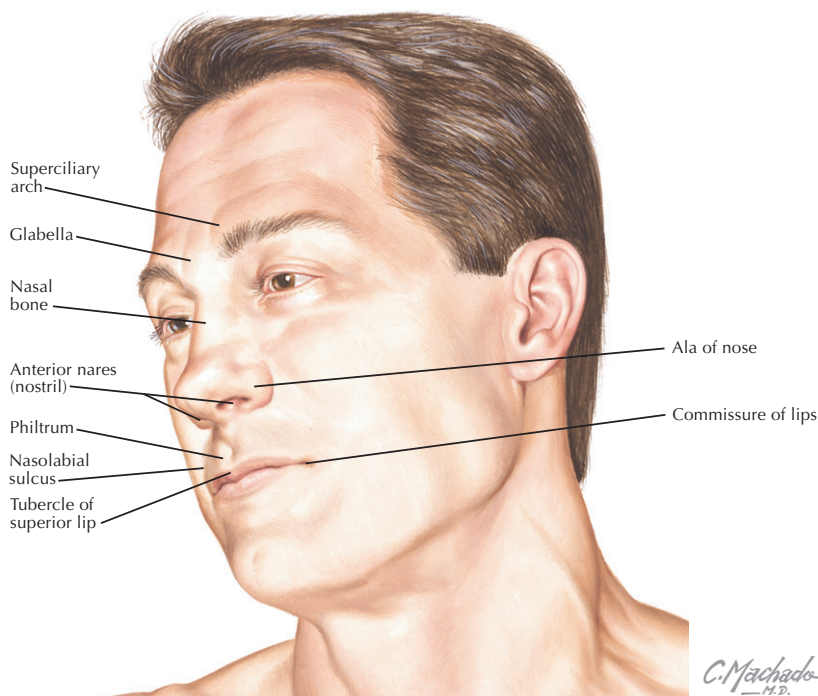
The cavity of the nose opposite the alar cartilage is called the vestibule and is lined by many coarse hairs called vibrissae

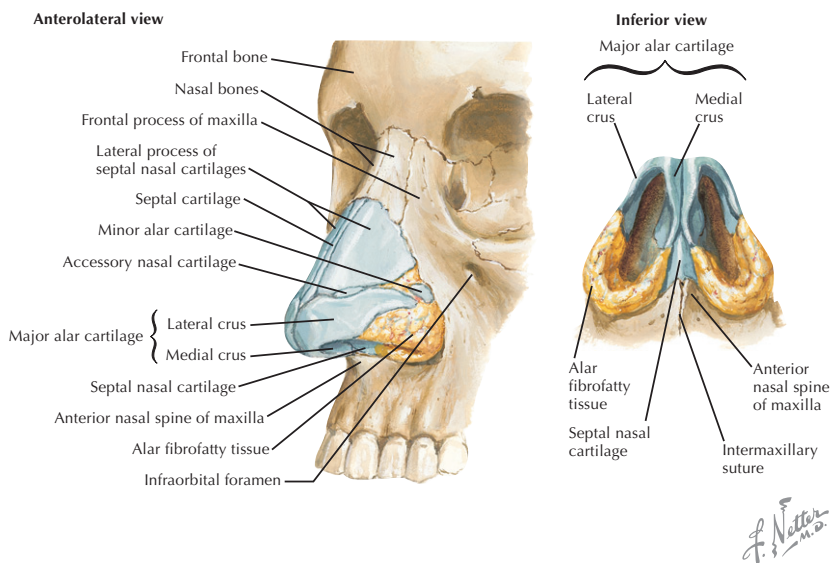
The cavity superior to the vestibule is the atrium

At the apex are found the 2 nostrils, or anterior nares, which are separated by the septum connecting the apex to the philtrum of the upper lip

Fibrous tissue helps connect the cartilages together and posteriorly to the maxilla

The primary lymphatic drainage of the nose is into the submandibular lymph nodes



**ANATOMY OF THE NOSE** *CONTINUED***VASCULAR SUPPLY OF THE NOSE**

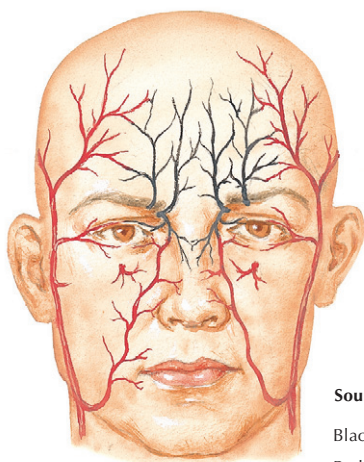
The blood supply to the nose arises from 3 major *arteries*:

- Ophthalmic
- Maxillary
- Facial

These vessels are derived from the external and internal carotid arteries

These arteries anastomose along the nose

Many nosebleeds are due to trauma to the septal branch of the superior labial artery from the facial artery

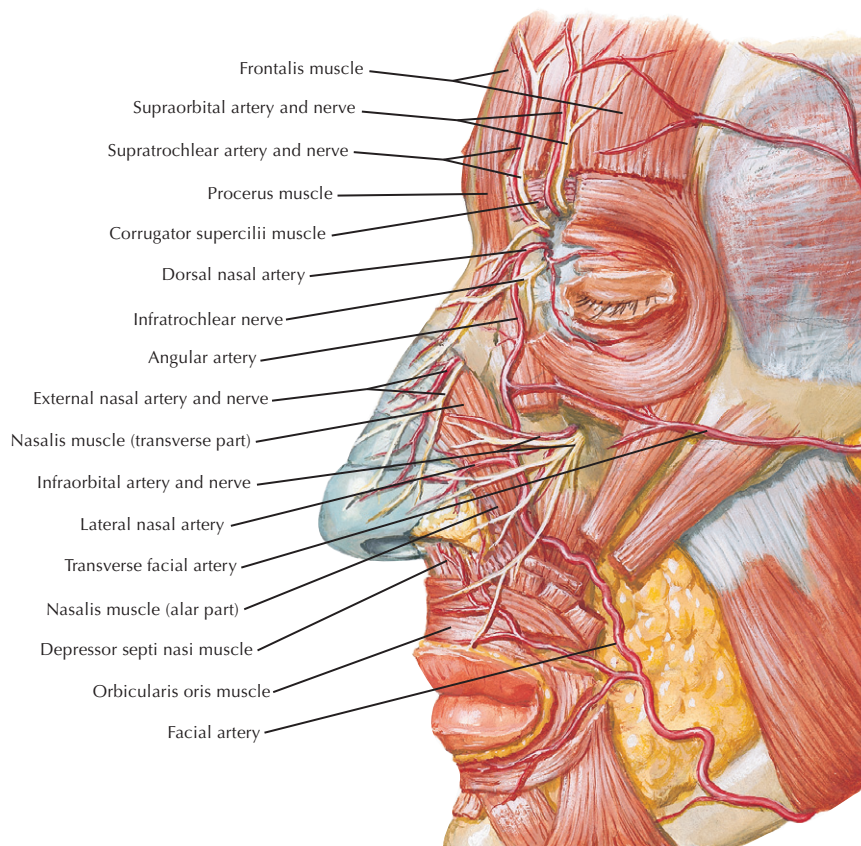
**Sources of arterial supply of face**

Black: from internal carotid artery (via ophthalmic artery)

Red: from external carotid artery

*F. Netter M.D.*



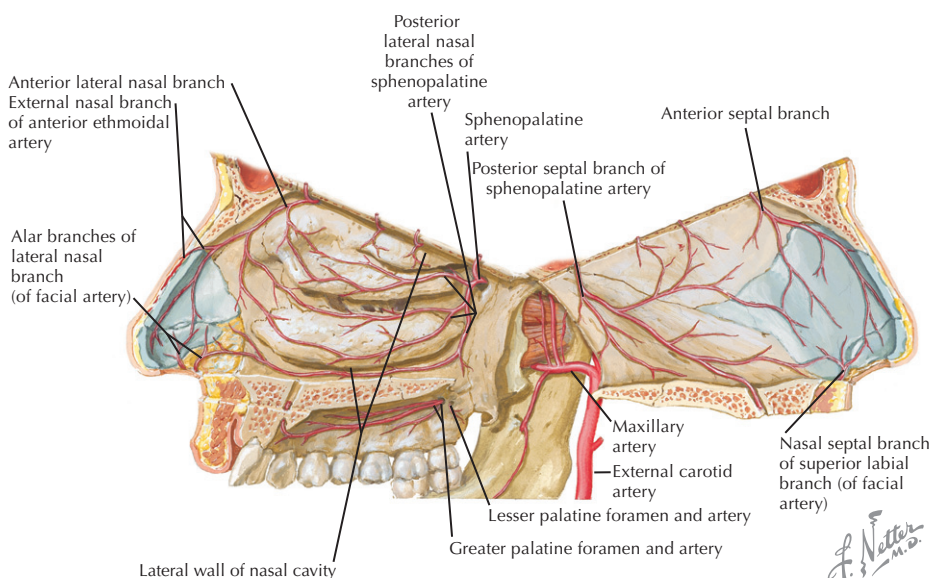
VASCULAR SUPPLY OF THE NOSE *CONTINUED*

ARTERIAL SUPPLY		
Artery	Source	Course
Ophthalmic	Internal carotid a.	Enters the orbit through the optic foramen immediately inferior and lateral to the optic n. Crosses the optic n. to reach the medial part of the orbit While in the orbit, besides other branches including the orbital vessels, it gives rise to 2 major branches that supply the nose: <ul style="list-style-type: none"> <li>• Dorsal nasal</li> <li>• External nasal from the anterior ethmoidal a.</li> </ul>
<i>Dorsal nasal (infratrochlear)</i>	1 of the terminal branches of the ophthalmic a.	Exits the orbit along the superomedial border along with the infratrochlear n. Supplies the area along the bridge of the nose
<i>External nasal</i>	A terminal branch of the anterior ethmoid a.	Supplies the area along the external nose at the junction between the nasal bone and the lateral nasal cartilage



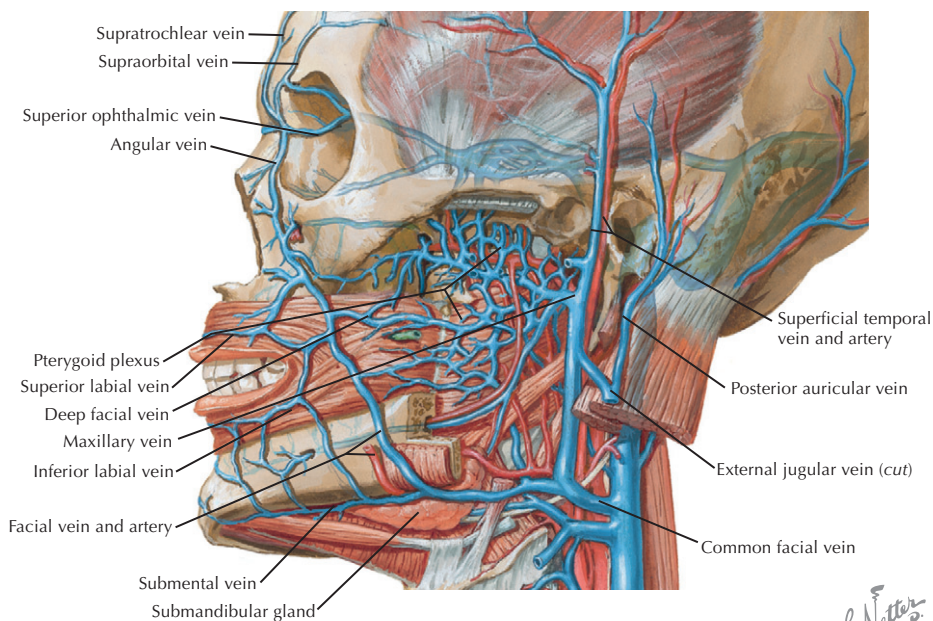
**VASCULAR SUPPLY OF THE NOSE** *CONTINUED*

ARTERIAL SUPPLY <i>CONTINUED</i>		
Artery	Source	Course
Maxillary	1 of 2 terminal branches of the external carotid a.	Gives rise to a series of branches; only 1 provides blood supply to the nose: nasal branch of the infraorbital a.
<i>Nasal branch of the infraorbital</i>	Infraorbital, the continuation of the 3rd part of the maxillary a.	Arises with the inferior palpebral branch and the superior labial branch Supplies the lateral aspect of the nose
Facial	External carotid a. in the carotid triangle of the neck	Passes superiorly immediately deep to the posterior belly of the digastric m. and the stylohyoid m. Passes along the submandibular gland, giving rise to the submental a., which helps supply the gland Passes superiorly over the body of the mandible at the masseter Continues anterosuperiorly across the cheek to the angle of the mouth, giving rise to the superior and inferior labial aa. Passes superiorly along the side of the nose, giving rise to the lateral nasal a. Continues on the side of the nose as the angular a. that terminates along the medial side of the eye Tortuous
<i>Septal</i>	Superior labial a.	Supplies the septum
<i>Alar</i>	Superior labial a. off of the facial a.	Supplies the ala of the nose
<i>Lateral nasal</i>	Facial a.	Supplies the ala and dorsal surface of nose



**VASCULAR SUPPLY OF THE NOSE** *CONTINUED*

VENOUS DRAINAGE	
Vein	Course
Facial	<p>Begins as the angular v.</p> <p>Passes inferiorly along the side of the nose, receiving the lateral nasal v.</p> <p>Continues in a posteroinferior path across the angle of the mouth to the cheek, receiving the superior and inferior labial vv.</p> <p>While passing toward the mandible, the deep facial v. connects the facial vein to the pterygoid plexus</p> <p>In the submandibular triangle, the facial v. joins the anterior branch of the retromandibular to form the common facial v.</p> <p>Has no valves that can allow blood to backflow</p>
Angular	<p>From the confluence of the supraorbital and supratrochlear vv. along the medial part of the eye</p> <p>Travels along the lateral side of the nose to become the facial v.</p>
Superior ophthalmic	<p>Receives blood from the roof of the orbit and the scalp</p> <p>Anastomoses with the angular v.</p> <p>Travels posteriorly to communicate with the pterygoid plexus</p>
Inferior ophthalmic	<p>Receives blood from the floor of the orbit</p> <p>Anastomoses with the angular v.</p> <p>Travels posteriorly with the infraorbital v. that passes through the inferior orbital fissure to communicate with the pterygoid plexus</p>



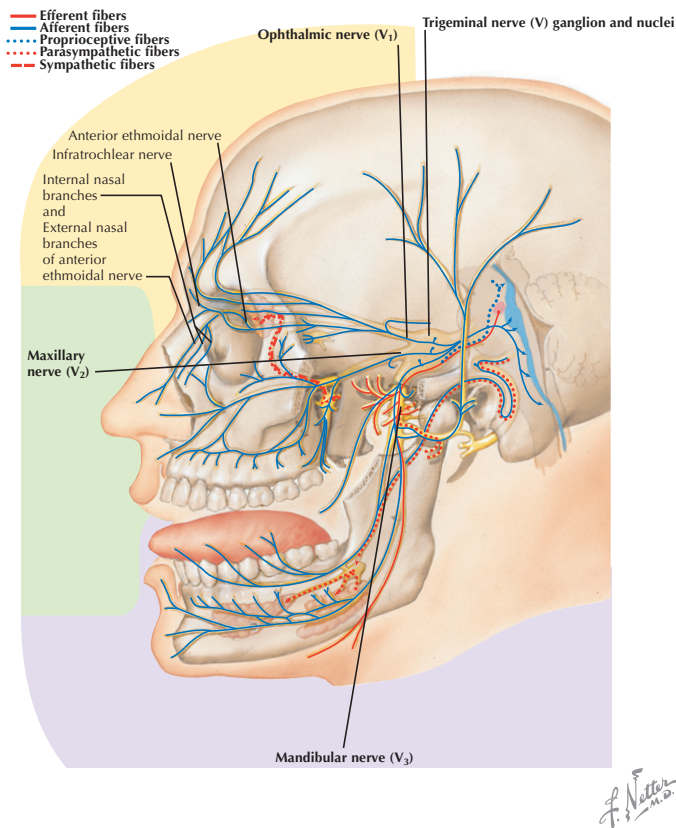
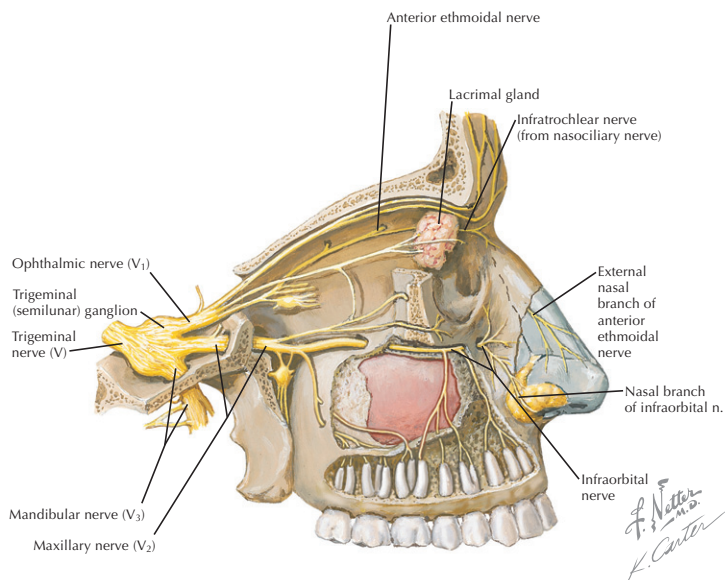
*F. Netter M.D.*

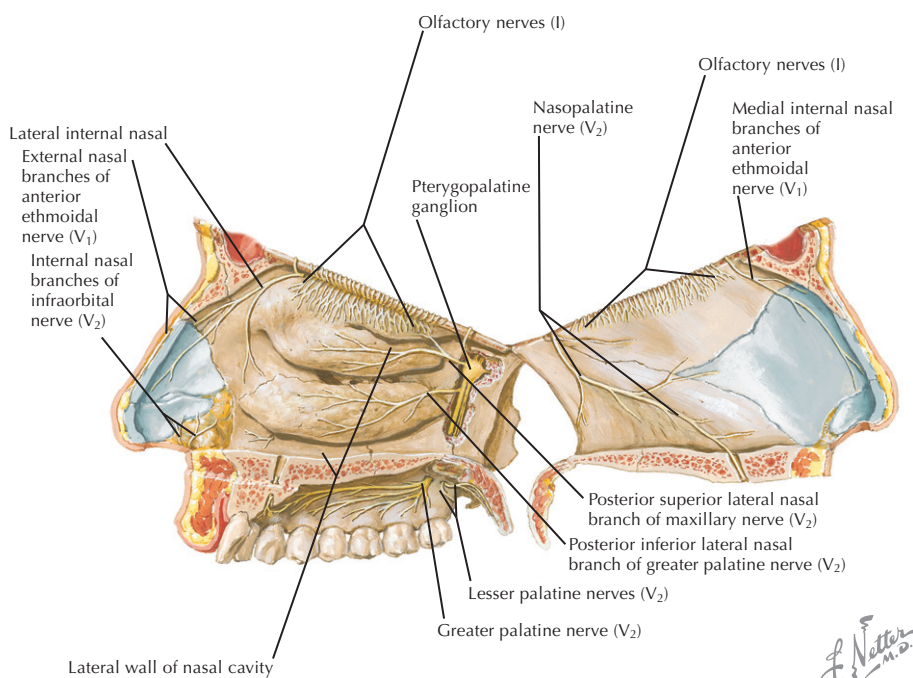
**NERVE SUPPLY OF THE NOSE**

The sensory supply to the nose arises from branches of the ophthalmic and maxillary divisions of the trigeminal nerve

Nerve	Source	Course
Ophthalmic division of the trigeminal	Trigeminal n. Arises from the main nerve in the middle cranial fossa	Passes anterior on the lateral wall of the cavernous sinus immediately inferior to the oculomotor and trochlear nn., but superior to the maxillary division of the trigeminal n. Immediately prior to entering the orbit, through the superior orbital fissure, the ophthalmic division divides into 3 major branches: lacrimal, frontal, and nasociliary
<i>External nasal</i>	Terminal branches of the anterior ethmoid nerve from the ophthalmic division of the trigeminal n.	Exits between the lateral nasal cartilage and the inferior border of the nasal bone Supplies the skin of the ala and apex of the nose around the nares
<i>Internal nasal</i>		Supplies the skin on the internal surface of the vestibule
<i>Infratrochlear</i>	One of the terminal branches of the nasociliary branch of the ophthalmic division of the trigeminal n.	Passes anteriorly on the superior border of the medial rectus m. Passes inferior to the trochlea toward the medial angle of the eye Supplies the skin of the bridge of the nose, in addition to the eyelids, the conjunctiva, and all lacrimal structures
Maxillary division of the trigeminal	Trigeminal n.	Travels along the lateral wall of the cavernous sinus Passes from the middle cranial fossa into the pterygopalatine fossa via the foramen rotundum <b>4 branches:</b> <ul style="list-style-type: none"> <li>• Infraorbital—this is the continuation of the maxillary division</li> <li>• Posterior superior alveolar</li> <li>• Zygomatic</li> <li>• Ganglionic</li> </ul>
<i>Infraorbital</i>	The continuation of the maxillary division of the trigeminal n.	Passes through the inferior orbital fissure to enter the orbit Passes anteriorly through the infraorbital groove and infraorbital canal and exits onto the face via the infraorbital foramen Once it exits onto the face, it divides into <b>3 terminal branches:</b> <ul style="list-style-type: none"> <li>• Nasal (supplies the ala of the nose)</li> <li>• Inferior palpebral (supplies the skin of the lower eyelid)</li> <li>• Superior labial (supplies the skin of the upper lip)</li> </ul>
<i>Nasal branch of the infraorbital</i>	Infraorbital n.	Supplies the ala of the nose

## NERVE SUPPLY OF THE NOSE *CONTINUED*



**NERVE SUPPLY OF THE NOSE** *CONTINUED*

# 11 Nasal Cavity

## ANATOMY

Lined by pseudostratified columnar epithelium with cilia

Inferior portion is larger than superior portion

Olfactory epithelium is located at the superior part of the nasal cavity around the cribriform plate

### *Piriform Aperture*

Anterior opening bounded by the nasal bones and maxilla

### *Nasal Septum*

Frequently deviates to 1 side, giving rise to unequal chambers

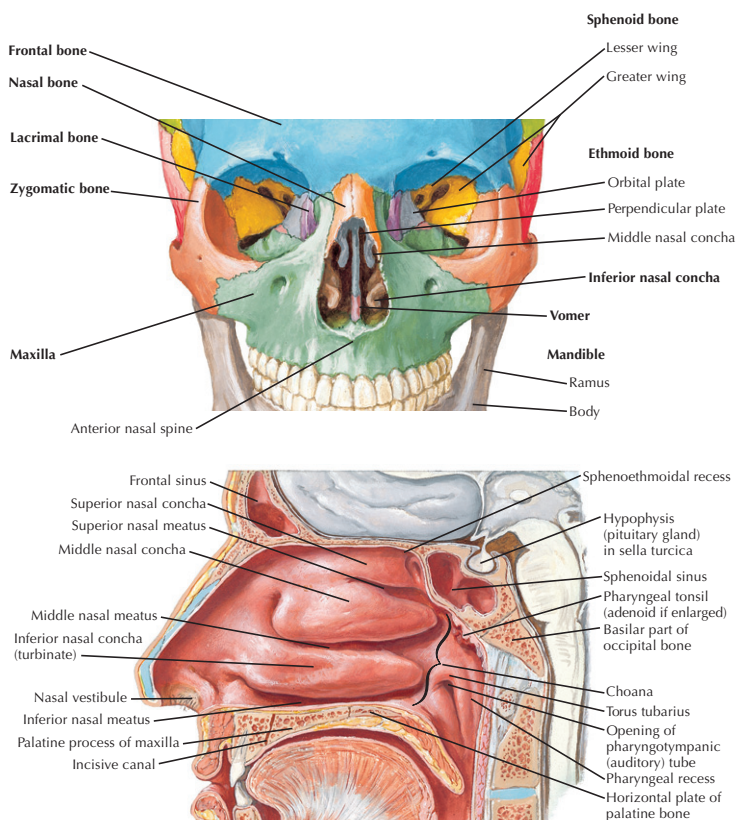
### *Lateral Walls*

Composed of large venous plexuses that have the appearance of erectile tissue

3 large elevations, known as conchae, protrude from the lateral wall

All of the paranasal sinuses and the nasolacrimal duct drain into the lateral walls of the nasal cavity

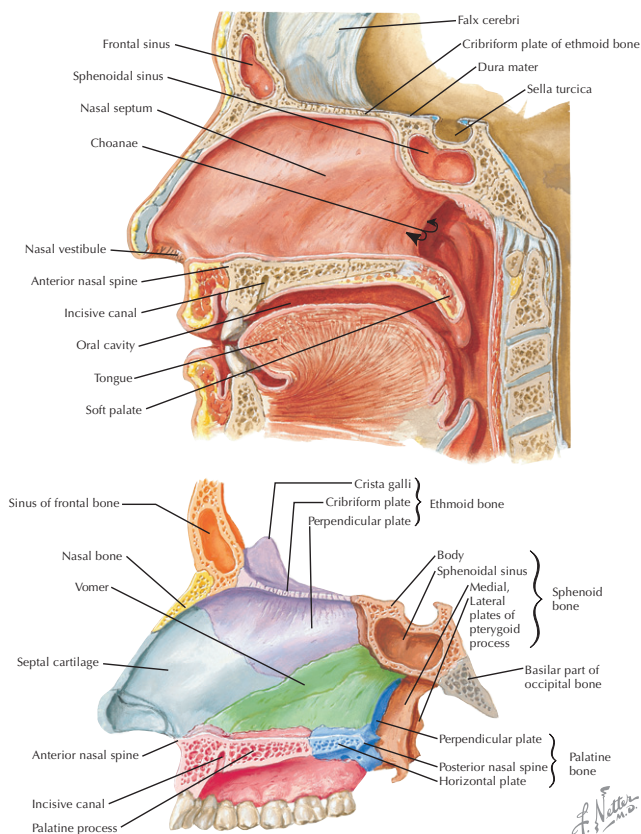
The sphenopalatine foramen, located in the posterior portion of the lateral walls, connects the nasal cavity to the pterygopalatine fossa





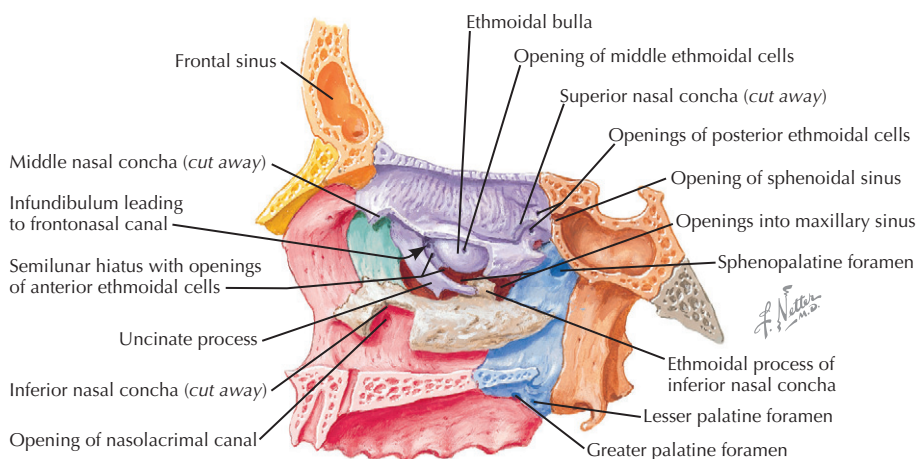
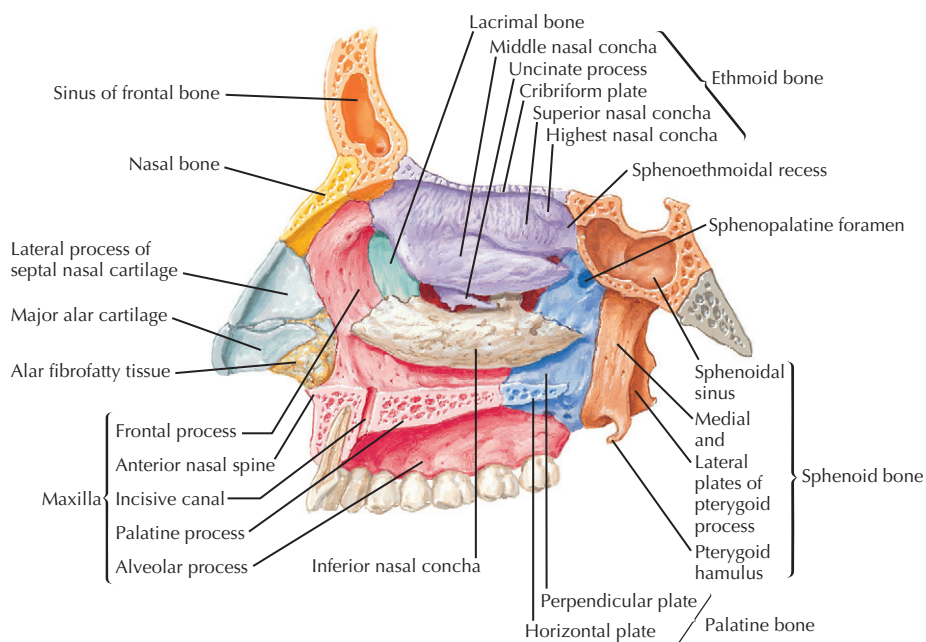
## BOUNDARIES AND RELATIONS OF THE NASAL CAVITY

RELATIONS	
Border	Structures
Superior	Frontal sinus, sphenoid sinus, anterior cranial fossa with frontal lobe of the brain
Inferior	Palate, oral cavity
Medial	Other half of nasal cavity
Lateral	Maxillary sinus, ethmoid sinuses, orbit, and pterygopalatine fossa
BOUNDARIES	
Border	Structures
Superior	Nasal, frontal, cribriform plate of the ethmoid, body of the sphenoid
Inferior	Palatine process of the maxilla, horizontal plate of the palatine
Anterior	External nose
Posterior	Choanae
Septum	Ethmoid (perpendicular plate), vomer, septal cartilage
Lateral	Maxilla, ethmoid, palatine, sphenoid (medial pterygoid plate), and inferior nasal concha, lacrimal



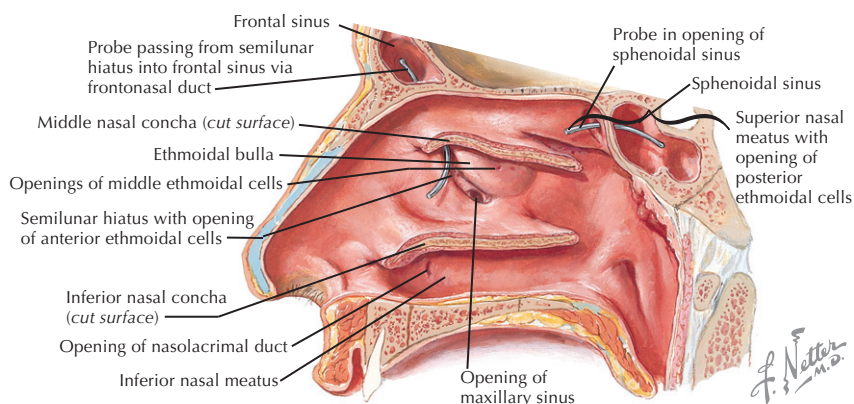
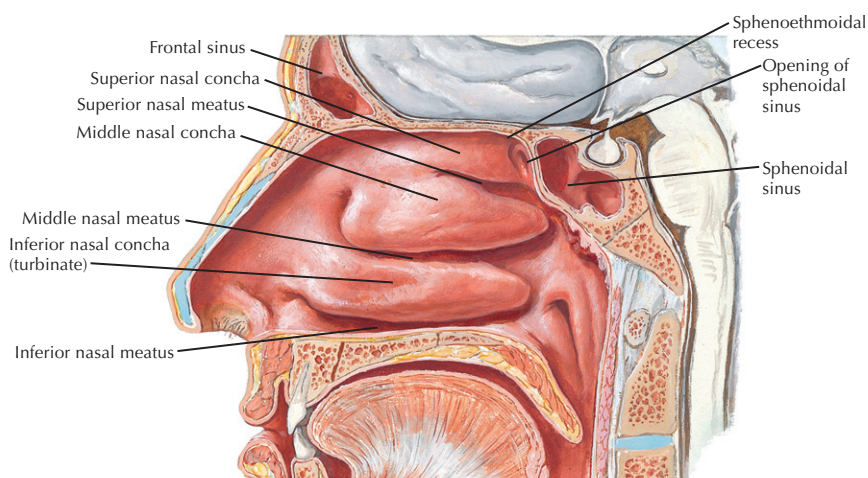
# 11 Nasal Cavity

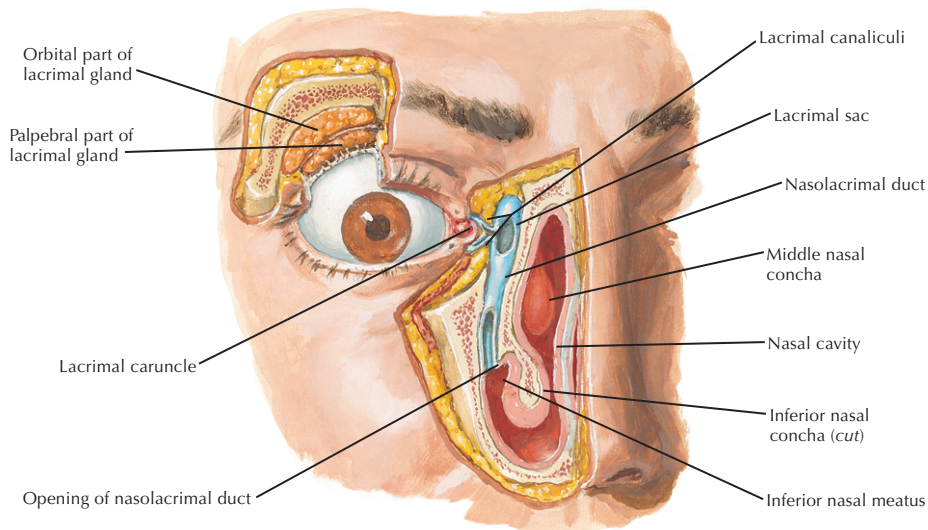
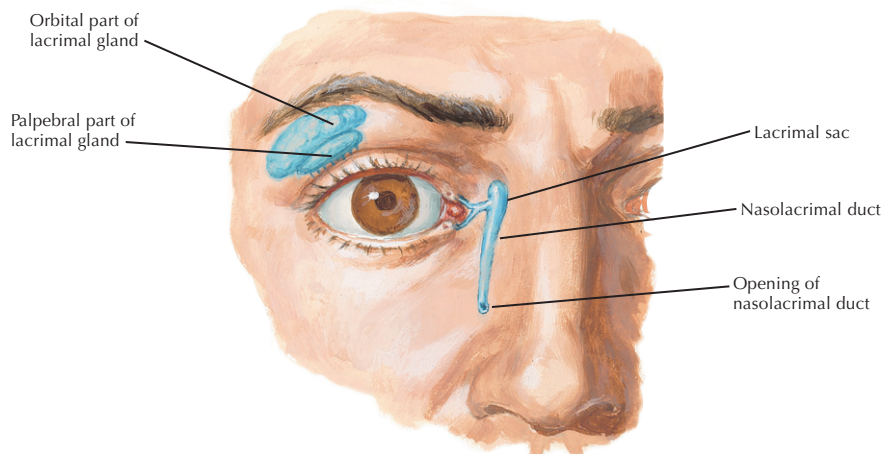
## BOUNDARIES AND RELATIONS OF THE NASAL CAVITY *CONTINUED*



## CONCHAE OF THE NASAL CAVITY

Concha	Regions Drained	Location	Structures Drained
Superior	Sphenoethmoidal recess	Superior to the superior meatus	Sphenoidal sinus
	Superior meatus	Inferior to the superior meatus	Posterior ethmoid sinus
Middle	Middle meatus	Inferior to the middle meatus	Anterior ethmoidal sinus Middle ethmoidal sinus Maxillary sinus Frontal sinus
Inferior	Inferior meatus	Inferior to the inferior meatus	Nasolacrimal duct



**CONCHAE OF THE NASAL CAVITY** *CONTINUED*

*J. Netter M.D.*

# Nasal Cavity

## VASCULAR SUPPLY OF THE NASAL CAVITY

The blood supply to the nasal cavity arises from 3 major *arteries*:

- Ophthalmic
- Maxillary
- Facial

These 3 vessels are derived from the external and internal carotid arteries and generally follow the paths of the nerves

The *veins* generally correspond to the arteries

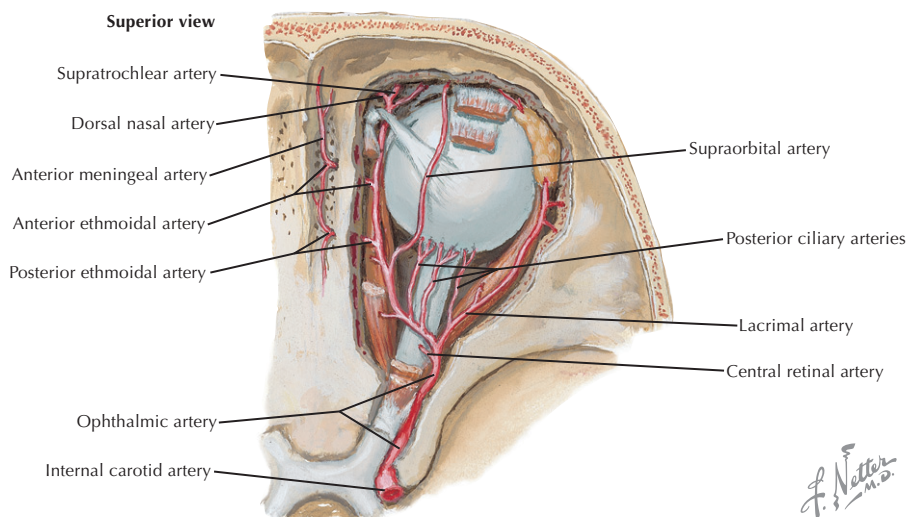
ARTERIAL SUPPLY		
Artery	Source	Course
Ophthalmic	Internal carotid a.	Enters the orbit through the optic foramen immediately inferior and lateral to the optic n. Crosses the optic n. to reach the medial part of the orbit While in the orbit, besides the orbital branches, it gives rise to 2 major branches that supply the nasal cavity: <ul style="list-style-type: none"> <li>• Anterior ethmoid</li> <li>• Posterior ethmoid</li> </ul>
<i>Anterior ethmoid</i>	Ophthalmic a.	Travels with the nasociliary n. through the anterior ethmoidal foramen Enters the anterior cranial fossa, where it gives rise to a meningeal branch and nasal branches that descend into the nasal cavity Supplies branches to the lateral wall and septum of the nose before giving rise to the external nasal a., which supplies the nose
<i>Posterior ethmoid</i>	Ophthalmic a.	Travels through the posterior ethmoidal foramen Enters the anterior cranial fossa, where it gives rise to a meningeal branch and nasal branches that descend into the nasal cavity through the cribriform plate Supplies part of the lateral wall near the superior nasal concha and the posterosuperior portion of the nasal septum
Maxillary	1 of 2 terminal branches of the external carotid a.	Gives rise to a series of branches; 2 provide blood supply to the nasal cavity: <ul style="list-style-type: none"> <li>• Sphenopalatine</li> <li>• Greater palatine</li> </ul>
<i>Sphenopalatine</i>	3rd part of the maxillary a.	After passing through the sphenopalatine foramen, enters the nasal cavity, where it gives rise to the posterior superior nasal branches <ul style="list-style-type: none"> <li>• The posterior superior <i>lateral</i> branch supplies the nasal concha, mucous membranes, and lateral wall</li> <li>• The posterior superior <i>medial</i> branch continues along the nasal septum to enter the hard palate via the incisive canal</li> </ul>
<i>Greater palatine</i>	A branch of the descending palatine, arising from the 3rd part of the maxillary a.	Travels in the palatine canal, where it splits into the lesser palatine a. (supplies the soft palate and palatine tonsil), and greater palatine a., which exits the greater palatine foramen and passes anteriorly toward the incisive foramen (supplies the hard palate gingiva, mucosa, and palatal glands) and anastomoses with the terminal branch of the sphenopalatine a. that exits the incisive foramen Also provides branches that supply the area of the inferior meatus



# 11 Nasal Cavity

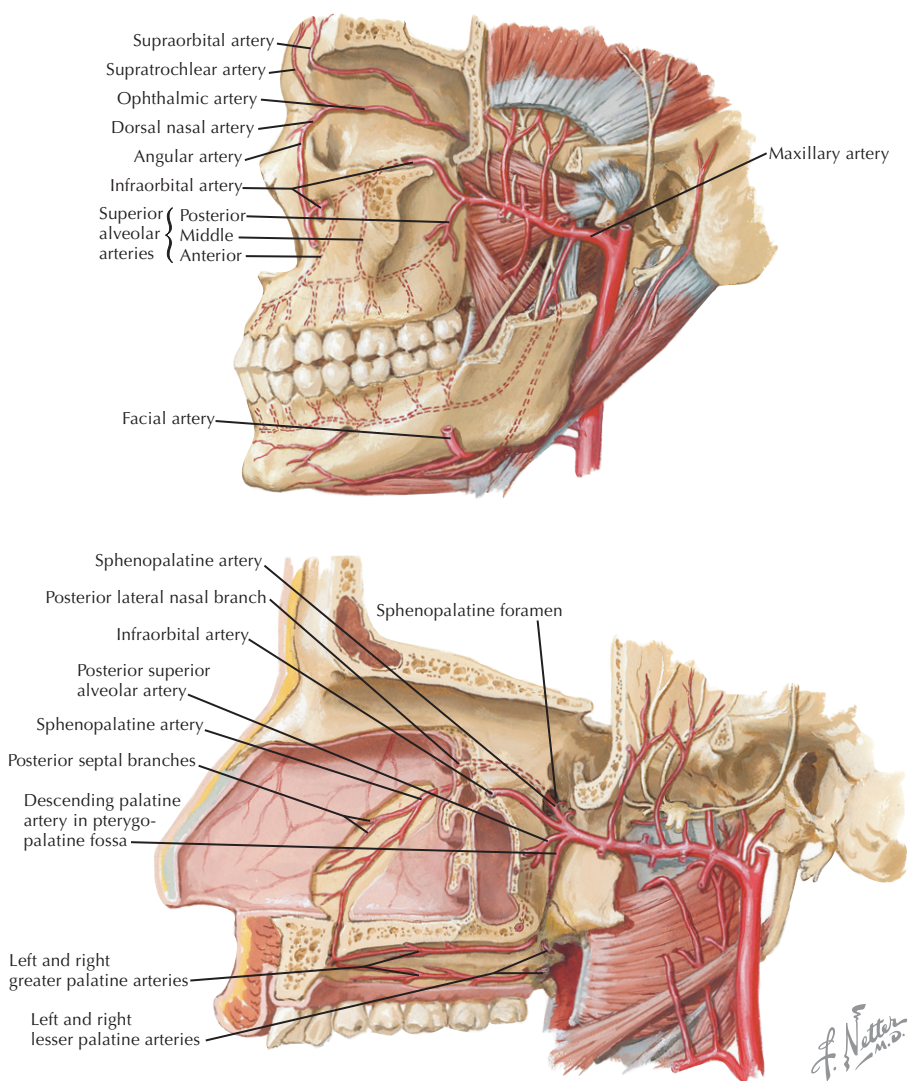
## VASCULAR SUPPLY OF THE NASAL CAVITY *CONTINUED*

ARTERIAL SUPPLY <i>CONTINUED</i>		
Artery	Source	Course
Facial	External carotid a. in the carotid triangle of the neck	<p>Tortuous</p> <p>Passes superiorly immediately deep to the posterior belly of the digastric and the stylohyoid mm.</p> <p>Passes along the submandibular gland giving rise to the submental a. that helps supply the gland</p> <p>Passes superiorly over the body of the mandible at the masseter m.</p> <p>Continues anterosuperiorly across the cheek to the angle of the mouth, giving rise to the superior and inferior labial aa.</p> <p>Passes superiorly along the side of the nose, giving rise to the lateral nasal a.</p> <p>Continues on the side of the nose as the angular a. that terminates along the medial side of the eye</p>
Superior labial	Facial	<p>Supplies the upper lip</p> <p>Gives rise to the septal branch that travels to the nasal septum</p> <p>The major blood supply to the anterior part of the nasal septum</p>



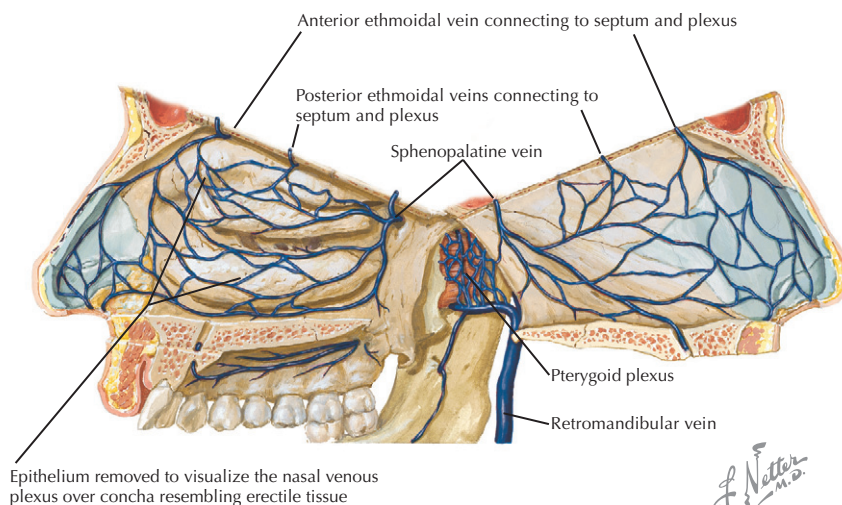


## VASCULAR SUPPLY OF THE NASAL CAVITY *CONTINUED*



**VASCULAR SUPPLY OF THE NASAL CAVITY** *CONTINUED*

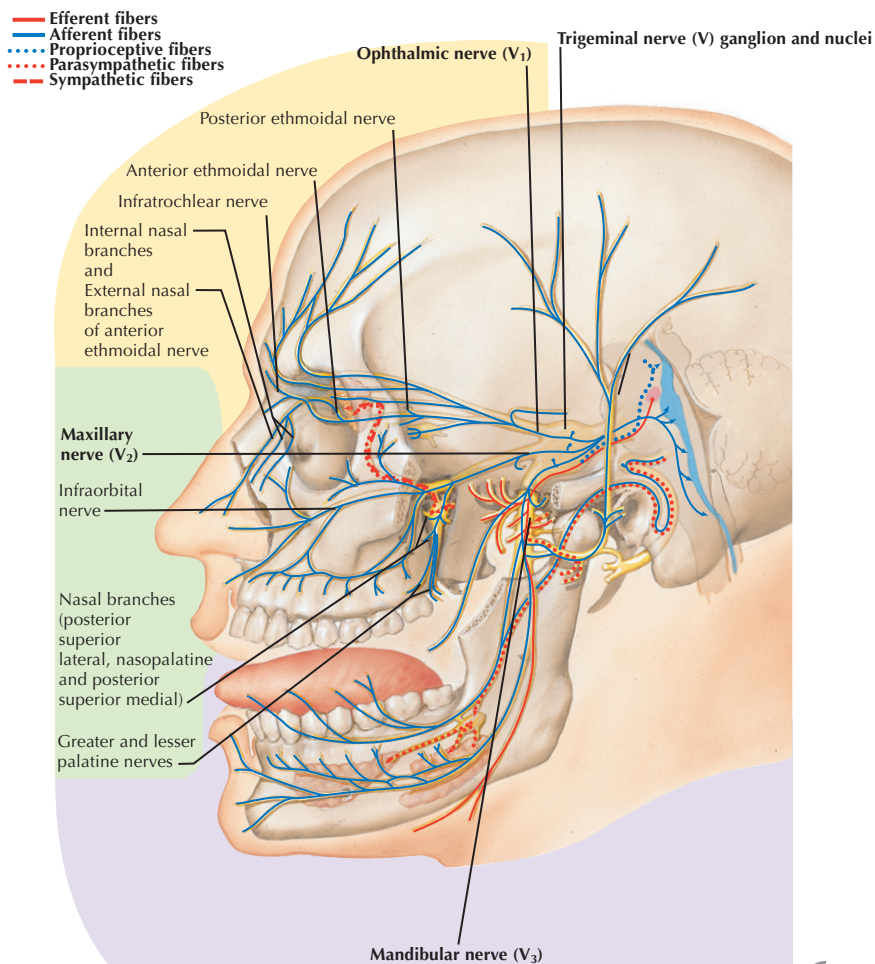
VENOUS DRAINAGE	
Vein	Course
A well-developed cavernous plexus lies deep to the mucous membrane The plexus drains into the following series of veins	
Emissary	Vein from the cavernous plexus in the nasal cavity passes through the foramen cecum to drain into the superior sagittal sinus
Sphenopalatine	Blood from the venous plexus along the posterior portion of the nasal cavity drains to the sphenopalatine v. Travels through the sphenopalatine foramen to enter the pterygoid plexus
Ethmoidal branches	Blood from the venous plexus in the anterior portion of the nasal cavity drains into ethmoid branches, which follow the ethmoid aa. to terminate in the ophthalmic v. and/or facial v.



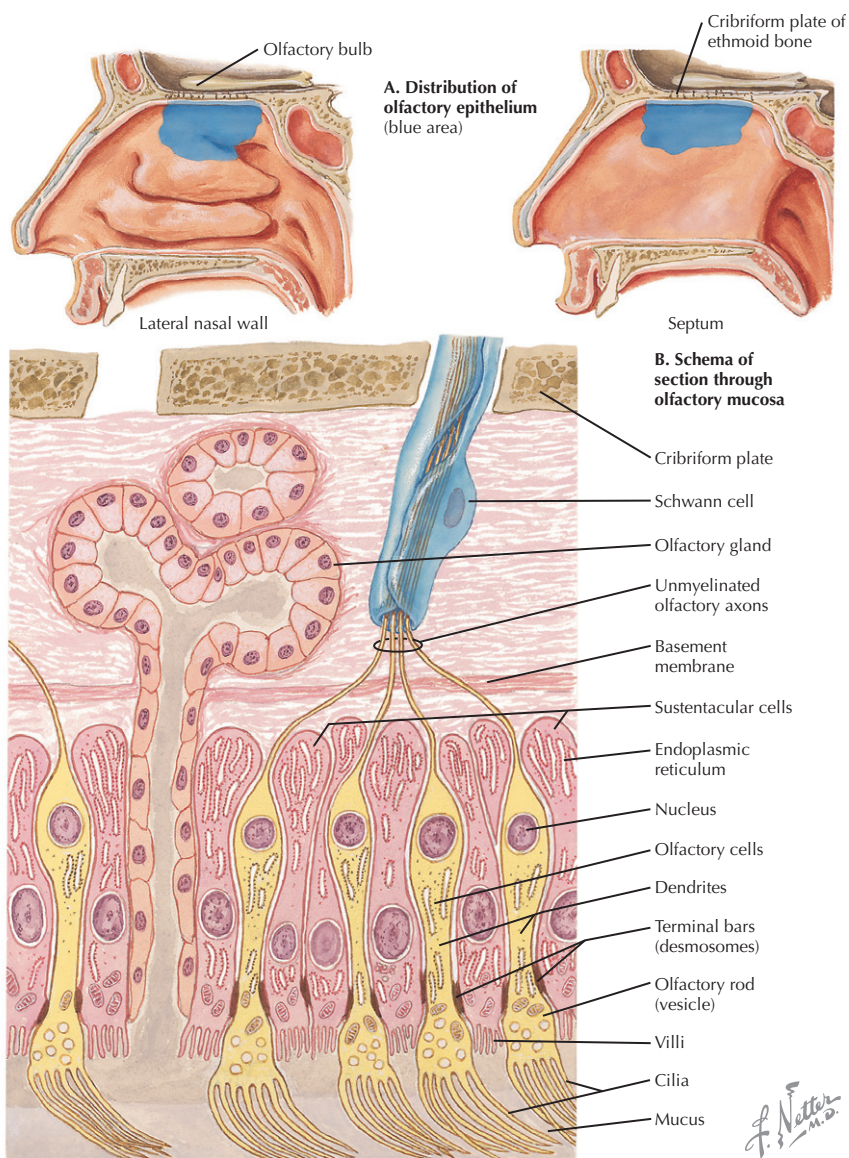
## NERVE SUPPLY OF THE NASAL CAVITY

2 major types of sensory innervation to the nasal cavity:

- Olfaction (special visceral afferent) via the olfactory nerve
- General sensation (general somatic afferent) via ophthalmic and maxillary divisions of the trigeminal nerve



*F. Netter M.D.*

NERVE SUPPLY OF THE NASAL CAVITY *CONTINUED*



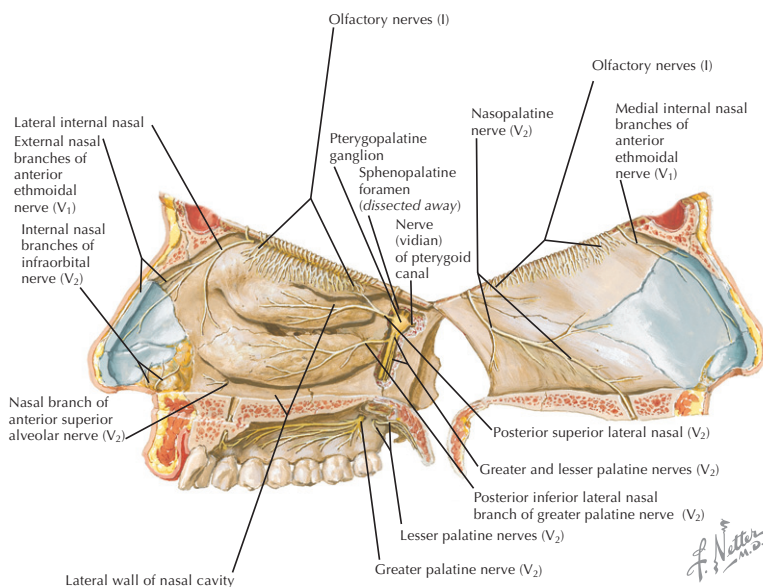
## NERVE SUPPLY OF THE NASAL CAVITY *CONTINUED*

SENSORY INNERVATION		
Olfaction		
<p>The olfactory epithelium is found in the roof of the nasal cavity including the adjacent superior portions of the lateral wall of the nasal cavity and the nasal septum</p> <p>Roughly 20 to 25 small olfactory n. fibers, which collectively form the olfactory nerves per side, travel superiorly through the cribriform plate into the anterior cranial fossa to join the olfactory bulb</p>		
GENERAL SENSATION		
Nerve	Source	Course
Ophthalmic division of the trigeminal	Trigeminal n.	<p>Sensory</p> <p>Arises from the main nerve in the middle cranial fossa</p> <p>Passes anterior on the lateral wall of the cavernous sinus immediately inferior to the oculomotor and trochlear nn., but superior to the maxillary division of the trigeminal n.</p> <p>Immediately before entering the orbit, through the superior orbital fissure, it divides into 3 major branches:</p> <ul style="list-style-type: none"> <li>• Lacrimal</li> <li>• Frontal</li> <li>• Nasociliary</li> </ul>
<i>Anterior ethmoid</i>	Nasociliary n. on the medial wall of the orbit	<p>Enters the anterior ethmoid foramen and travels through the canal to enter the anterior cranial fossa</p> <p>While descending toward the nasal cavity, it provides innervation to the anterior parts of the middle and inferior conchae, as well as the region anterior to the nasal concha</p>
Maxillary division of the trigeminal	Trigeminal n.	<p>Sensory</p> <p>Travels along the lateral wall of the cavernous sinus</p> <p>Passes from the middle cranial fossa into the pterygopalatine fossa via the foramen rotundum</p> <p>Within the pterygopalatine fossa, it gives rise to 4 branches:</p> <ul style="list-style-type: none"> <li>• Infraorbital—this is the continuation of the maxillary</li> <li>• Posterior superior alveolar</li> <li>• Zygomatic</li> <li>• Ganglionic</li> </ul>
<i>Infraorbital</i>	Maxillary division of the trigeminal n.	<p>Passes through the inferior orbital fissure to enter the orbit</p> <p>Passes anteriorly through the infraorbital groove and infraorbital canal and exits onto the face via the infraorbital foramen</p> <p>While in the infraorbital canal, it gives rise to the anterior superior alveolar n., which has a small branch that supplies the nasal cavity in the region of the inferior meatus and inferior corresponding portion of the nasal septum (in addition to supplying the maxillary sinus; the maxillary central incisor, lateral incisor, and canine teeth; and the gingiva and mucosa alongside these teeth)</p>
<i>Nasopalatine</i>	Pterygopalatine ganglion in the pterygopalatine fossa	<p>Passes through the sphenopalatine foramen to enter the nasal cavity</p> <p>Passes along the superior portion of the nasal cavity to the nasal septum, where it travels anteroinferiorly to the incisive canal supplying the septum</p>
<i>Posterior inferior nasal branch of the greater palatine</i>		<p>Passes through the palatine canal to enter the hard palate via the greater palatine foramen</p> <p>While descending in the palatine canal, it gives rise to a posterior inferior nasal branch</p> <p>Supplies the posterior part of the lateral wall of the nasal cavity in the region of the middle meatus</p>

# 11 Nasal Cavity

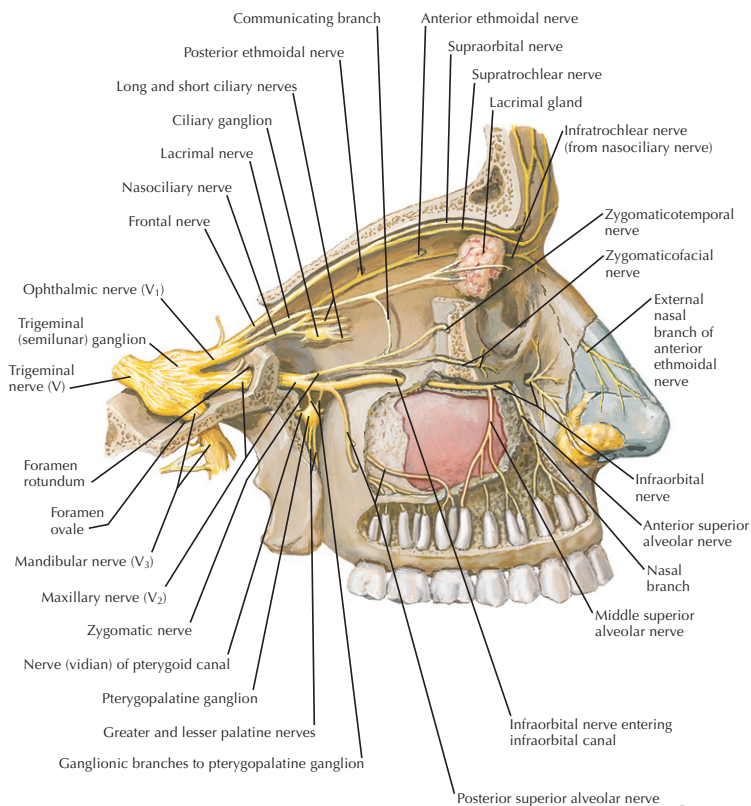
## NERVE SUPPLY OF THE NASAL CAVITY *CONTINUED*

GENERAL SENSATION <i>CONTINUED</i>		
Nerve	Source	Course
<i>Posterior superior nasal</i>	Arises from the pterygopalatine ganglion in the pterygopalatine fossa	Passes through the sphenopalatine foramen to enter the nasal cavity and branches into 2 nerves: <ul style="list-style-type: none"> <li>• Posterior medial superior nasal</li> <li>• Posterior lateral superior nasal</li> </ul>
<i>Posterior lateral superior nasal</i>	Posterior superior nasal n. from the pterygopalatine ganglion	Supplies the posterosuperior portion of the lateral wall of the nasal cavity in the region of the superior and middle concha
<i>Posterior medial superior nasal</i>		Supplies the posterior portion of the nasal septum

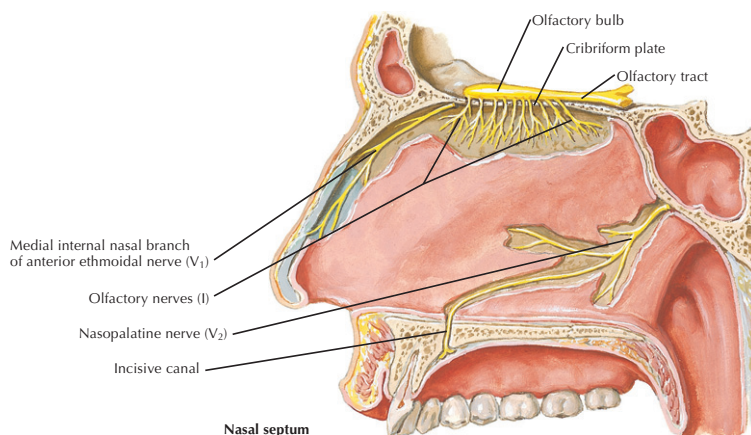




## NERVE SUPPLY OF THE NASAL CAVITY *CONTINUED*



*F. Netter M.D.*  
*K. Carter*



*F. Netter M.D.*

# 11 Nasal Cavity

## NERVE SUPPLY OF THE NASAL CAVITY *CONTINUED*

Autonomic fibers are distributed through the sensory branches of the maxillary division of the trigeminal nerve via the pterygopalatine ganglion (parasympathetics) and the superior cervical ganglion (sympathetics)

Autonomics travel to the glands and blood vessels of the nasal cavity

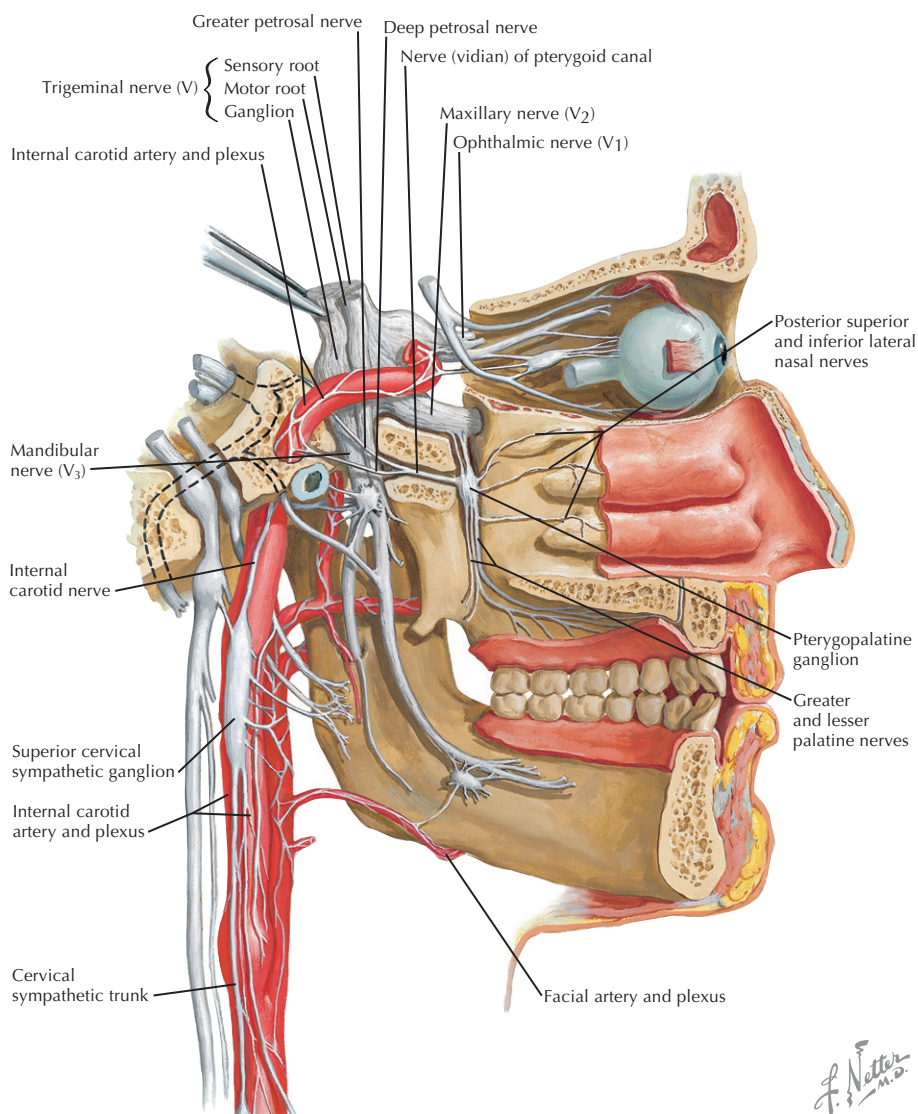
AUTONOMIC INNERVATION			
ANATOMIC PATHWAY FOR PARASYMPATHETICS OF THE NASAL CAVITY			
Type of Neuron	Name of Cell Body	Characteristics of the Cell Body	Course of the Neuron
Preganglionic neuron	Superior salivatory nucleus	<p>A collection of nerve cell bodies located in the pons</p> <p>Travel through the nervus intermedius of the facial nerve into the internal acoustic meatus</p> <p>In the <i>facial canal</i>, the facial nerve gives rise to 2 parasympathetic branches:</p> <ul style="list-style-type: none"> <li>• Greater petrosal n.</li> <li>• Chorda tympani n.</li> </ul>	<p><b>Greater Petrosal Nerve</b></p> <p>Greater petrosal n. exits the hiatus for the greater petrosal n. toward the foramen lacerum, where it joins the deep petrosal n. (sympathetics) to form the nerve of the pterygoid canal (vidian n.)</p> <p>Vidian n. passes through the pterygoid canal and enters the pterygopalatine fossa, where it joins with the pterygopalatine ganglion</p>
Postganglionic neuron	Pterygopalatine ganglion	<p>Pterygopalatine ganglion is a collection of nerve cell bodies located in the pterygopalatine fossa</p> <p>Postganglionic parasympathetic fibers that arise in the pterygopalatine ganglion are distributed to the ophthalmic and maxillary divisions of the trigeminal n. to the:</p> <ul style="list-style-type: none"> <li>• Lacrimal gland</li> <li>• Nasal glands</li> <li>• Palatine glands</li> <li>• Pharyngeal glands</li> </ul>	<p><b>Maxillary Division Distribution</b></p> <p>Postganglionic fibers travel along the maxillary division of the trigeminal n. to be distributed along its branches that are located in the nasal cavity, oral cavity, and pharynx (e.g., nasopalatine, greater palatine)</p> <p>These fibers innervate:</p> <ul style="list-style-type: none"> <li>• Nasal glands</li> <li>• Palatine glands</li> <li>• Pharyngeal glands</li> </ul>
ANATOMIC PATHWAY FOR SYMPATHETICS OF THE NASAL CAVITY			
Type of Neuron	Name of Cell Body	Characteristics of the Cell Body	Course of the Neuron
Preganglionic neuron	Intermediolateral horn nucleus	Collection of nerve cell bodies located in the lateral horn nucleus of the spinal cord between spinal segments T1 and T3 (and possibly T4)	<p>Arise from the intermediolateral horn nuclei from T1 to T3 (4)</p> <p>Travel through the ventral root of the spinal cord to the spinal nerve</p> <p>Enter the sympathetic chain via a white ramus communicantes</p> <p>Once in the sympathetic chain, the preganglionic fibers for the eye ascend and synapse with postganglionic fibers in the superior cervical ganglion</p>

## NERVE SUPPLY OF THE NASAL CAVITY *CONTINUED*

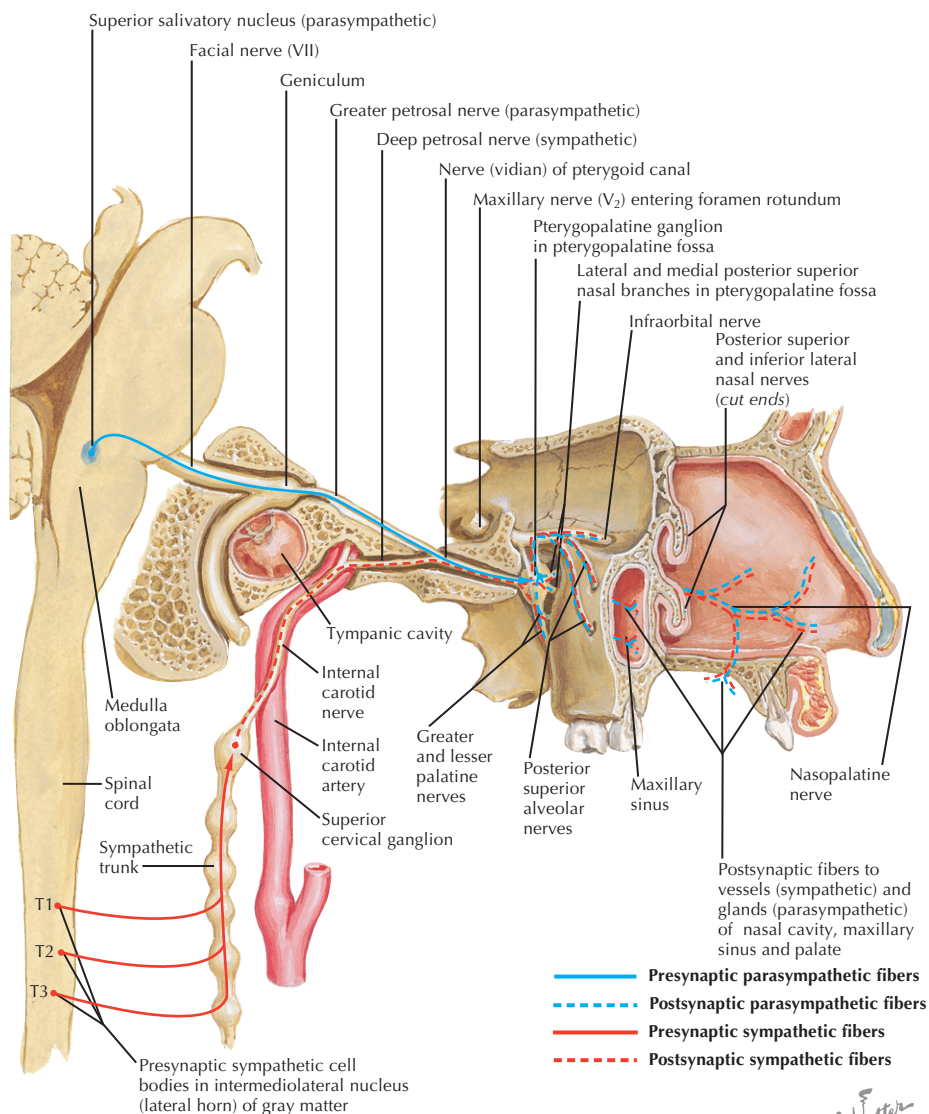
ANATOMIC PATHWAY FOR SYMPATHETICS OF THE NASAL CAVITY			
Type of Neuron	Name of Cell Body	Characteristics of the Cell Body	Course of the Neuron
Postganglionic neuron	Superior cervical ganglion	<p>Collection of nerve cell bodies located in the superior cervical ganglion, which is located at the base of the skull</p> <p>Postganglionic sympathetic fibers follow the internal carotid or external carotid a. to pass near their respective effector organs (e.g., nasal cavity)</p>	<p><b>Nasal Cavity and Palate</b></p> <p>Postganglionic sympathetic fibers follow both the <i>internal</i> and <i>external</i> carotid aa.:</p> <ul style="list-style-type: none"> <li>• Postganglionic sympathetic fibers from the internal carotid branch in the region of the foramen lacerum to form the deep petrosal n. The deep petrosal n. joins the greater petrosal n. (parasympathetics) to form the nerve of the pterygoid canal (vidian n.)</li> <li>• Postganglionic sympathetic fibers travel along the branches of the maxillary division of the trigeminal n., associated with the pterygopalatine ganglion, to be distributed along its branches in the nasal cavity and palate</li> <li>• Postganglionic sympathetic fibers from the external carotid branch and follow the maxillary a. These fibers travel along the branches of the maxillary a., to be distributed along the nasal cavity and palate</li> </ul>

# 11 Nasal Cavity

## NERVE SUPPLY OF THE NASAL CAVITY *CONTINUED*



## NERVE SUPPLY OF THE NASAL CAVITY *CONTINUED*



*F. Netter M.D.*

## EPISTAXIS

*Epistaxis*, or nosebleed, is a hemorrhage from the nasal cavity or nose

Classified by bleeding location:

- Anterior
- Posterior

### Causes

- Trauma (blows to the face, fractures, nose picking)
- Sinus infections
- Rhinitis
- Arid environment
- Hypertension
- Hematologic disorders
- Neoplasms

### Anterior Epistaxis

The most common form (in about 90% of cases)

Usually found along the nasal septum and results from bleeding along Kiesselbach's plexus

Many nosebleeds are due to trauma to the septal branch of the superior labial artery from the facial artery

Typically managed with local pressure

May be controlled with cautery via a silver nitrate stick or anterior nasal packing if bleeding is persistent

With anterior epistaxis, another treatment, although somewhat drastic, is septal dermoplasty

- The thin septal mucosa is replaced by a thicker graft of skin
- Often used to treat nosebleeds caused by hereditary hemorrhagic telangiectasia or septal perforations

### Posterior Epistaxis

Usually found along the posterior part of the nasal cavity

More difficult to treat and may be accomplished with posterior nasal packing or a balloon catheter

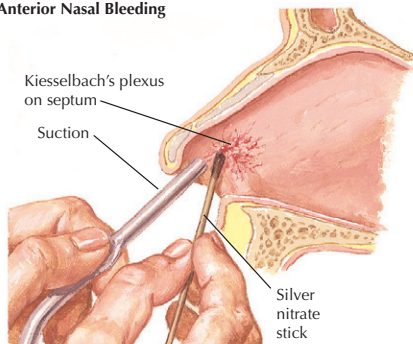
Severe posterior epistaxis may require ligation of the maxillary artery



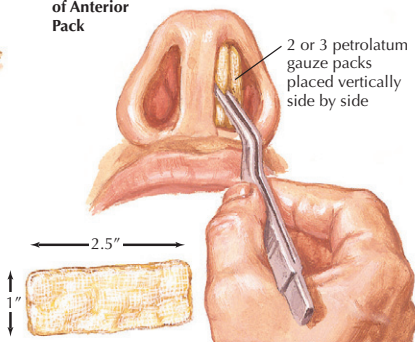
# Clinical Correlate

## EPISTAXIS *CONTINUED*

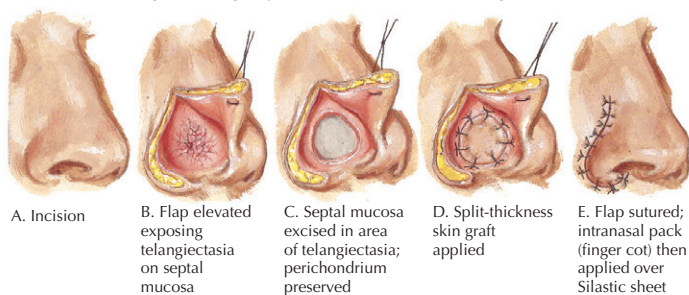
### Cauterization of Anterior Nasal Bleeding



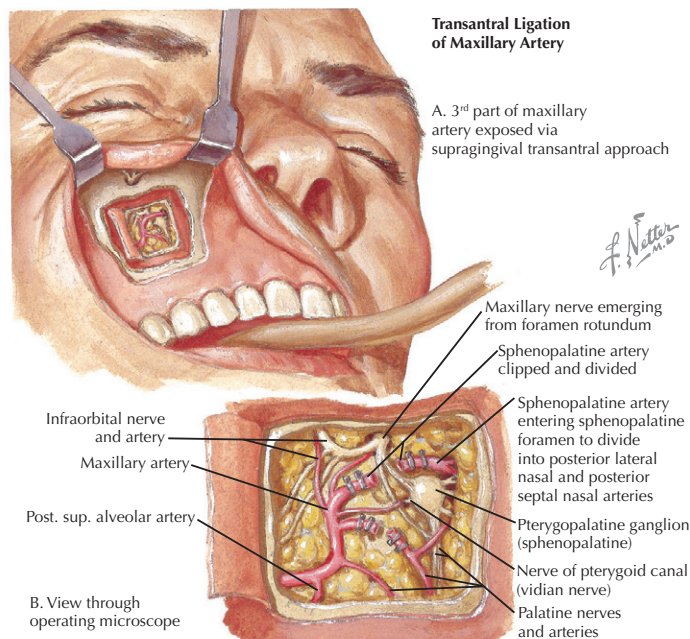
### Placement of Anterior Pack



### Septal Dermoplasty for Recurrent Severe Anterior Epistaxis



### Transanal Ligation of Maxillary Artery



**DEVIATED SEPTUM**

A severe shift of the nasal septum from the midline

**Causes**

- Trauma
- Birth defects

**Results**

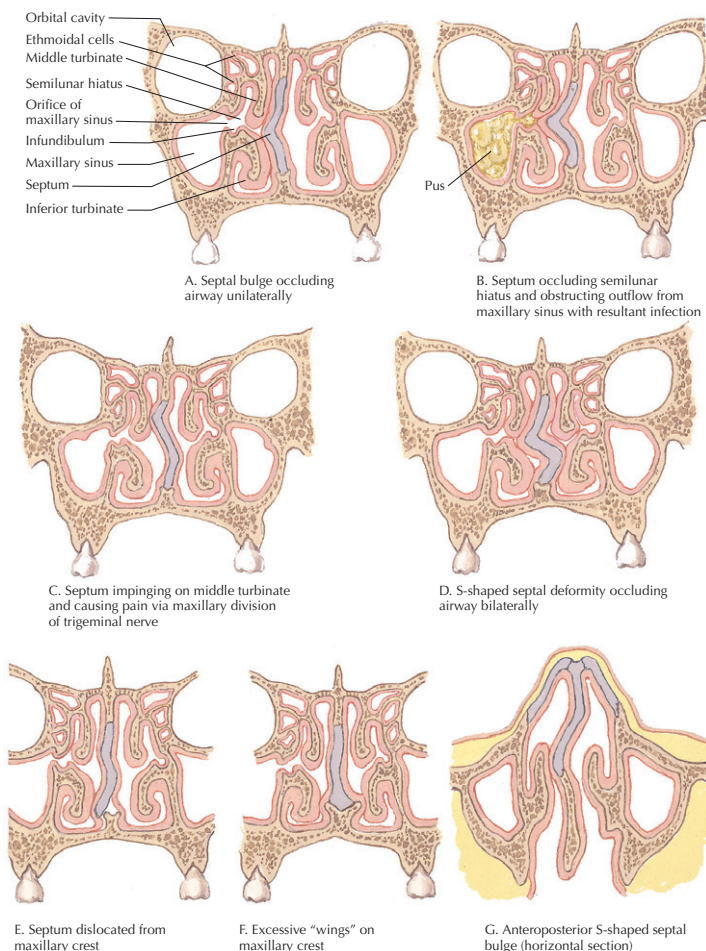
Occlusion of one side, either partial or complete, producing difficulty in breathing or blocked air flow on that side

May also cause:

- Sinusitis
- Epistaxis
- Nasal congestion

**Treatment**

May be treated by septoplasty



*F. Netter M.D.*

# Clinical Correlate

## RHINITIS

An inflammation of the mucosa of the nasal cavity that results in:

- Nasal congestion
- Sneezing
- Rhinorrhea
- Nasal itching

May involve the eyes, ears, sinuses, and throat and cause headaches

Most commonly caused by allergic rhinitis

### Allergic Rhinitis

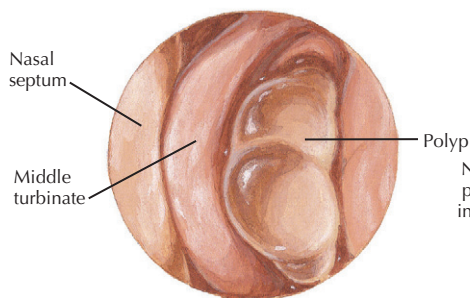
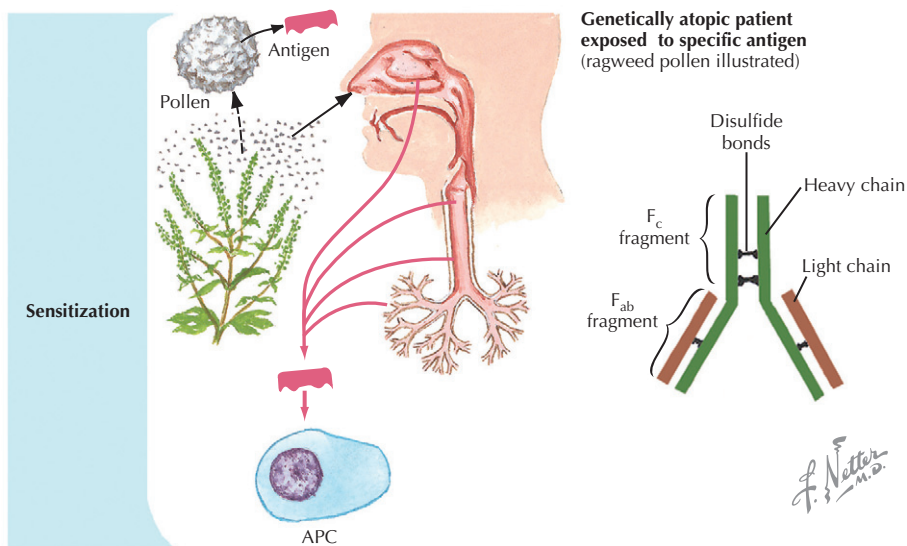
Can be associated with nasal polyps, deviated septum, and asthma

Caused by an allergen inducing an immunoglobulin E (IgE)-mediated response on the mast cells

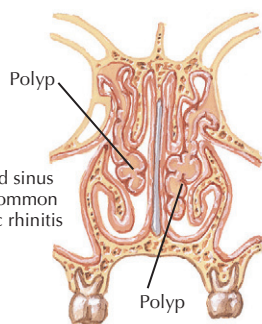
Because mast cells are located on the nasal mucosa, an allergen can bind to the mast cell, resulting in the release of histamines, prostaglandins, cytokines, and leukotrienes

Typically treated with decongestants, antihistamines, and steroids

### Mechanism of Type 1 (Immediate) Hypersensitivity

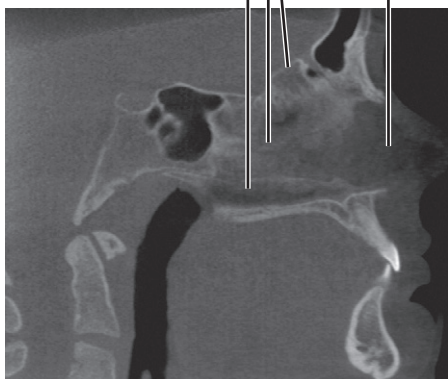

Endoscopic view of nasal polyp protruding from middle meatus

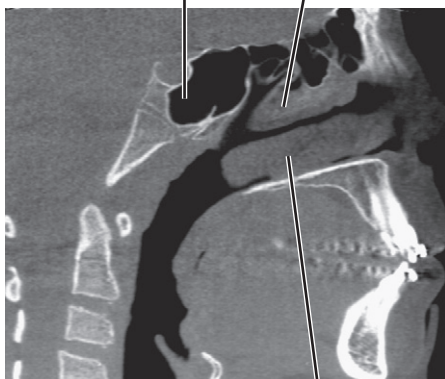

Nasal polyps most often bilateral in allergic sinusitis

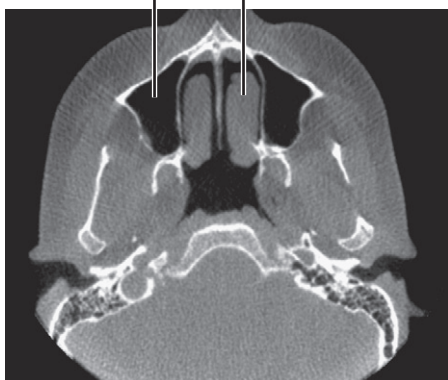Perpendicular plate of the ethmoid  
Crista galli  
Vomer  
Septal cartilage



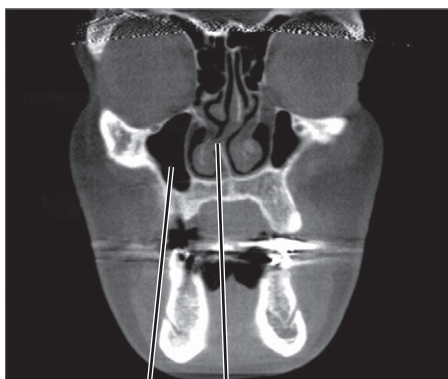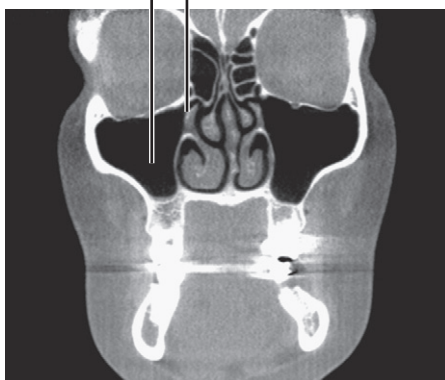
Sphenoid sinus  
middle nasal concha



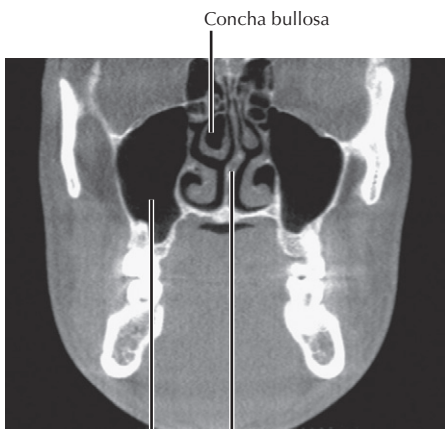
Maxillary sinus  
Inferior nasal concha



Maxillary sinus  
Uncinate process  
Inferior nasal concha



Maxillary sinus  
Deviated septum



Maxillary sinus  
Deviated septum

## CHAPTER 12

# PARANASAL SINUSES

Overview and Topographic Anatomy	300
Frontal Sinus	304
Ethmoid Sinus	307
Maxillary Sinus	311
Sphenoid Sinus	314
Clinical Correlates	317
Imaging	324



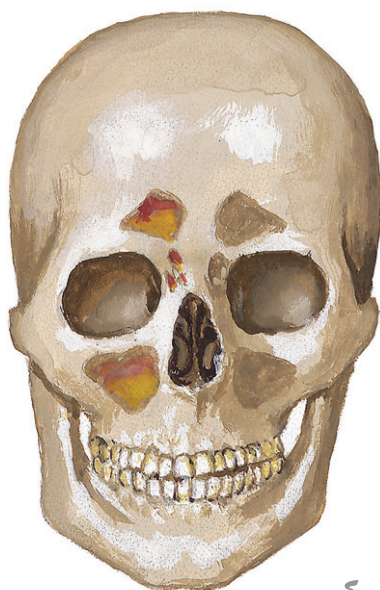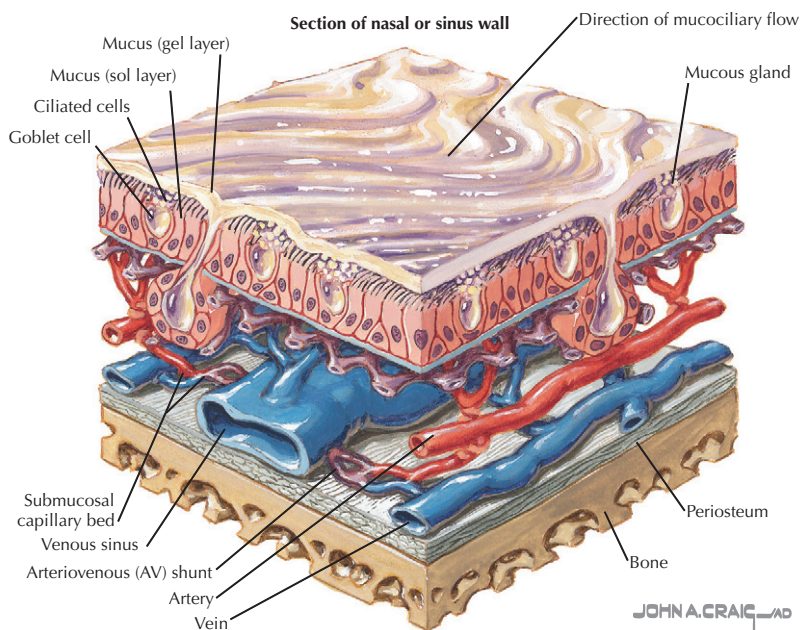
## 12 Overview and Topographic Anatomy

### GENERAL INFORMATION

*Paranasal sinuses:* invaginations from the nasal cavity that drain into spaces associated with the lateral nasal wall

Each is lined by a respiratory epithelium

Morphology of the sinuses is highly variable

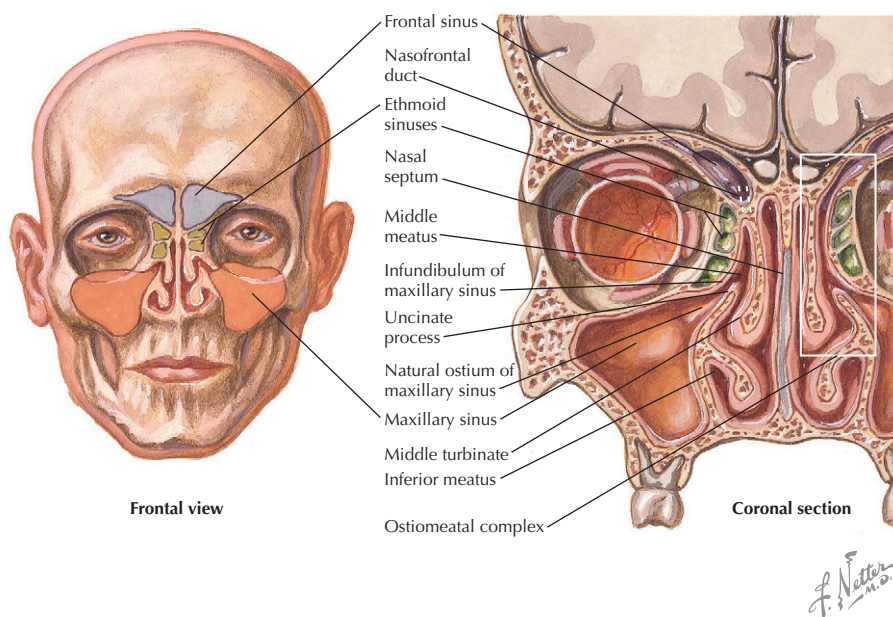


Paranasal sinus infection  
that spreads to skull bones

F. Netter  
M.D.



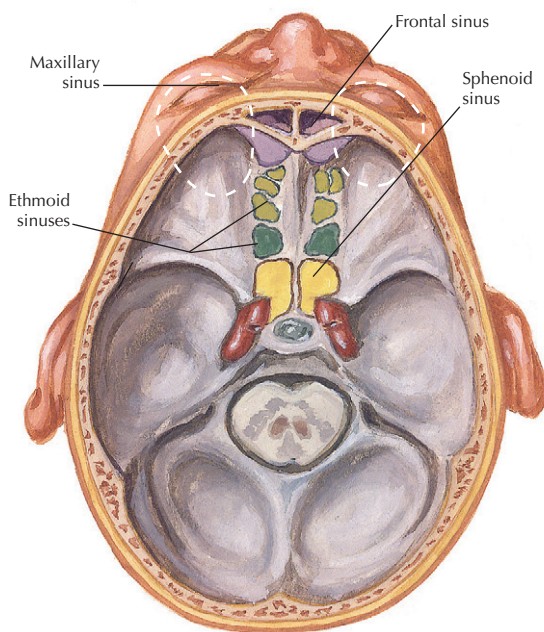
## GENERAL INFORMATION *CONTINUED*



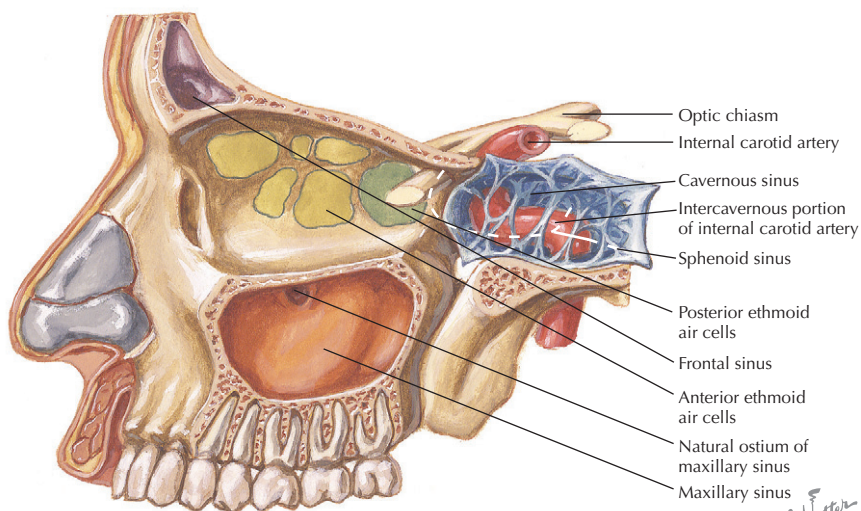
FEATURES OF THE PARANASAL SINUSES				
Sinus	Location	Comment	Artery	Nerve
Frontal	Within frontal bone	Flattened triangular shape	Ophthalmic branches	Ophthalmic division of the trigeminal n.
Maxillary	Within maxillary bone	Pyramidal shape, 1st to develop	Maxillary branches	Maxillary division of the trigeminal n.
Ethmoid	Within ethmoid bone	3 to 18 irregularly shaped cells	Ophthalmic and maxillary branches	Ophthalmic and maxillary divisions of the trigeminal n.
Sphenoid	Within sphenoid bone	Cuboid shape		

## 12 Overview and Topographic Anatomy

### GENERAL INFORMATION *CONTINUED*



Superior view



Lateral view (orbital aspect)

*F. Netter M.D.*

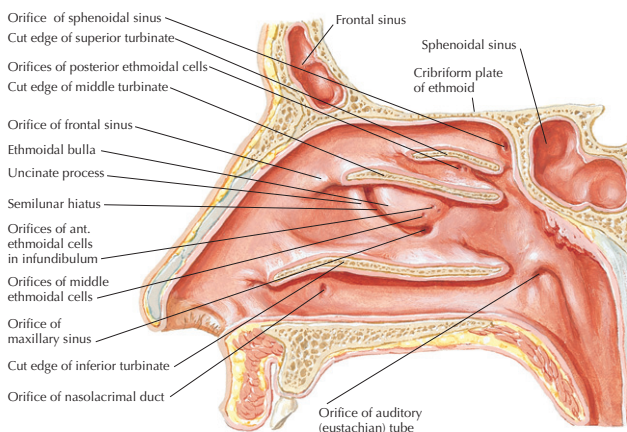
## DRAINAGE OF THE PARANASAL SINUSES AND ASSOCIATED STRUCTURES

All paranasal sinuses drain into the nasal cavity

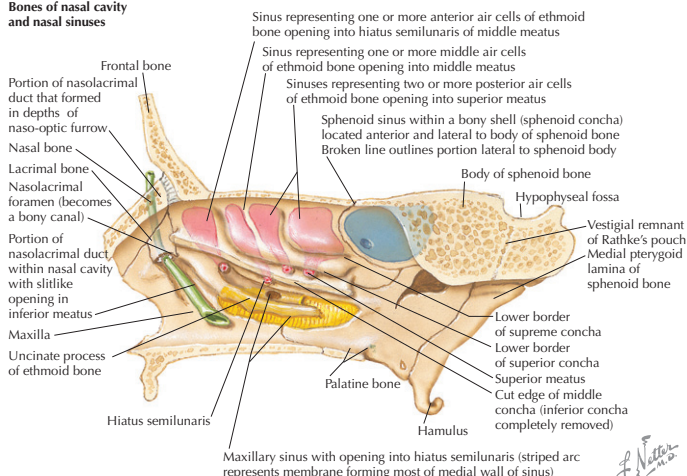
Different sinuses serve as drainage conduits for different regions

SUMMARY OF PARANASAL SINUS DRAINAGE		
Region Drained	Location	Structure(s) Drained
Sphenoethmoidal recess	Superior to the superior concha	Sphenoid sinus
Superior meatus	Inferior to the superior concha	Posterior ethmoid sinus
Middle meatus	Inferior to the middle concha	Anterior ethmoid sinus Middle ethmoid sinus Maxillary sinus Frontal sinus
Inferior meatus	Inferior to the inferior concha	Nasolacrimal duct

### Anatomy of the nose



### Bones of nasal cavity and nasal sinuses



## 12 Frontal Sinus

### GENERAL INFORMATION

The two frontal sinuses typically are asymmetrical

Rudimentary at birth and usually well-developed by the age of 7 or 8 years

Display a prime expansion when the 1st deciduous molars erupt and another when the permanent molars begin to appear at about age 6

Drainage varies; often drain in front of, above, or into the ethmoidal infundibulum

Primary lymphatic drainage is to the submandibular lymph nodes

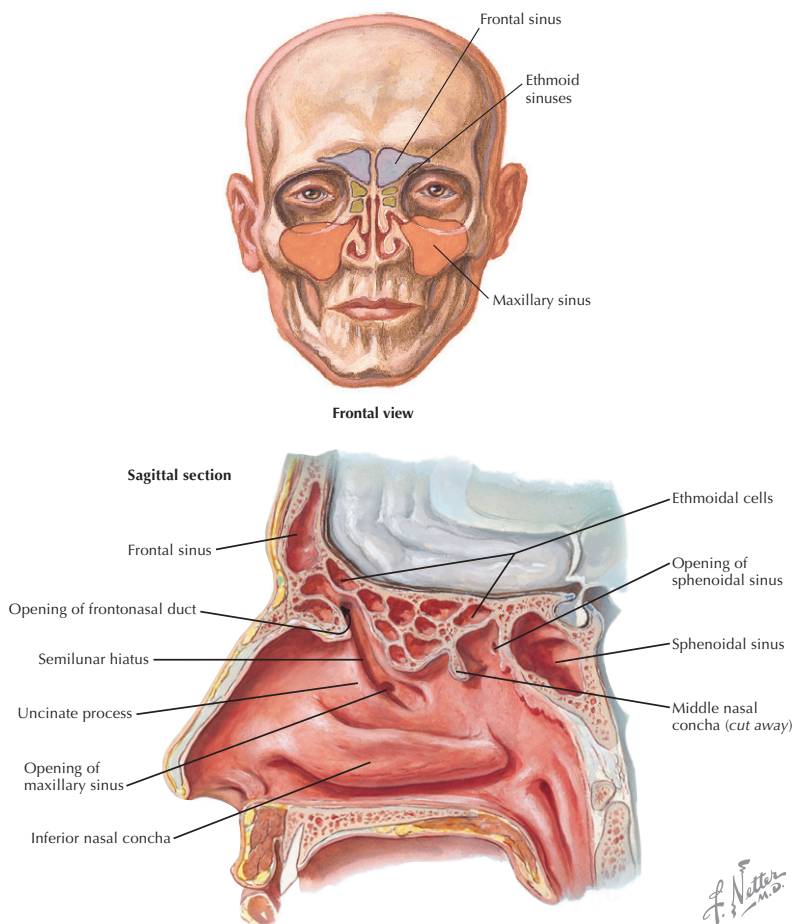
The frontal sinus receives its nerve supply from branches of the ophthalmic division of the trigeminal nerve

#### *Relations of Sinus*

- **Superior:** anterior cranial fossa and contents
- **Inferior:** orbit, anterior ethmoidal sinuses, nasal cavity
- **Anterior:** forehead, superciliary arches
- **Posterior:** anterior cranial fossa and contents
- **Medial:** other frontal sinus

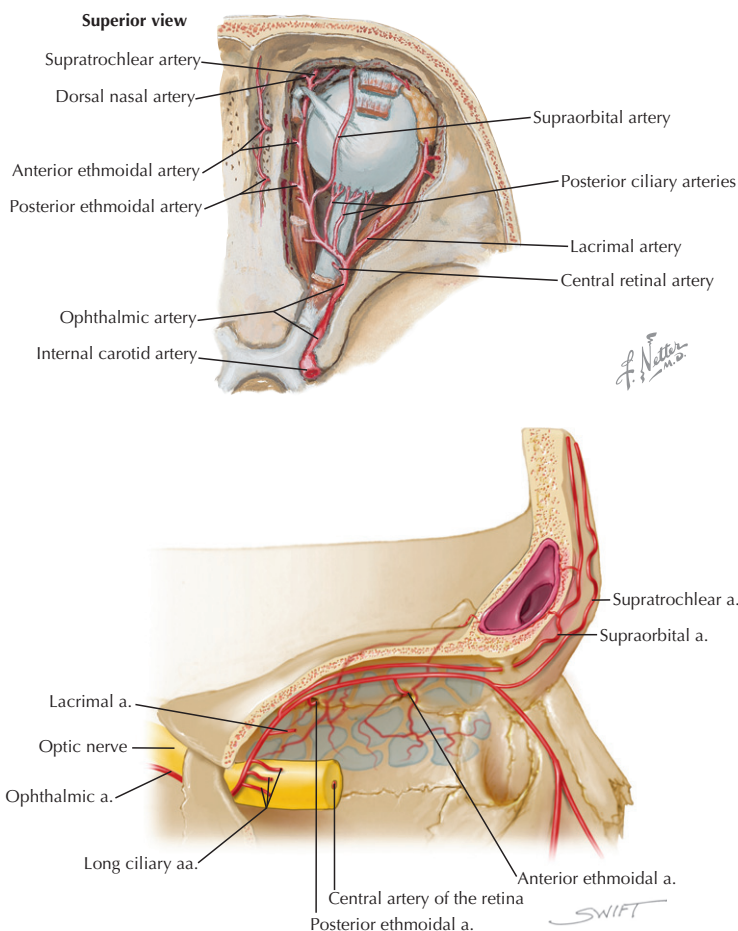
#### *Location of Ostium*

Middle meatus



## ARTERIAL SUPPLY

Artery	Source	Course
Anterior ethmoid	Ophthalmic a. (from the internal carotid a.)	Enters the anterior ethmoid foramen with the nerve to pass through the canal At this location, it supplies the anterior and middle ethmoid air cells and the frontal sinus
Supraorbital		Branches from the ophthalmic a. when crossing the optic n. Ascends medial to both the levator palpebrae superioris and the superior rectus mm. At this location, it runs with the supraorbital n. and is found between the levator palpebrae superioris m. and the periosteum of the orbit Travels to the supraorbital foramen (notch) At the level of the supraorbital margin, it supplies the frontal sinus
Supratrochlear		One of the terminal branches of the ophthalmic a. in the orbit Ascends to meet the supratrochlear n. While passing anteriorly in the orbit toward the trochlea, the supratrochlear a. supplies the frontal sinus



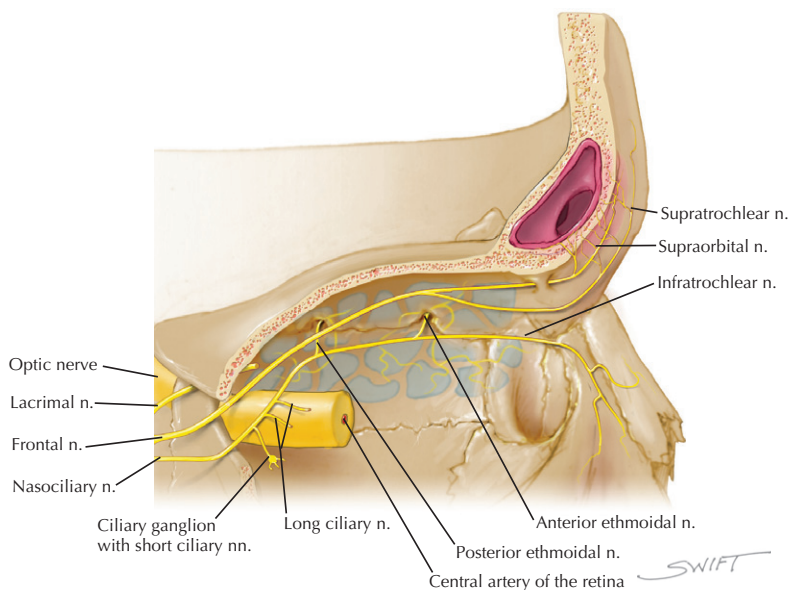
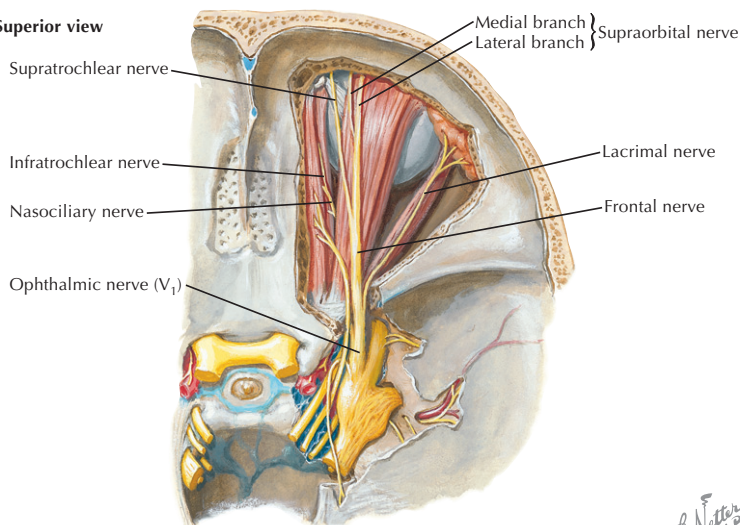


## 12 Frontal Sinus

### NERVE SUPPLY

Nerve	Source	Course
Supraorbital	Ophthalmic division of the trigeminal n.	Passes between the levator palpebrae superioris m. and periosteum of the orbit Continues anteriorly to the supraorbital foramen (notch) At the level of the supraorbital margin, it sends nerve supply to the frontal sinus
Supratrochlear		Once the supratrochlear a. joins it, the nerve continues to pass anteriorly toward the trochlear n. There it often supplies the frontal sinus

#### Superior view



# Ethmoid Sinus

## GENERAL INFORMATION

May find 3 to 18 ethmoid air cells on each side

Ethmoid air cells may invade any of the other 3 sinuses

The middle ethmoid air cells produce the swelling on the lateral wall of the middle meatus called the ethmoid bulla

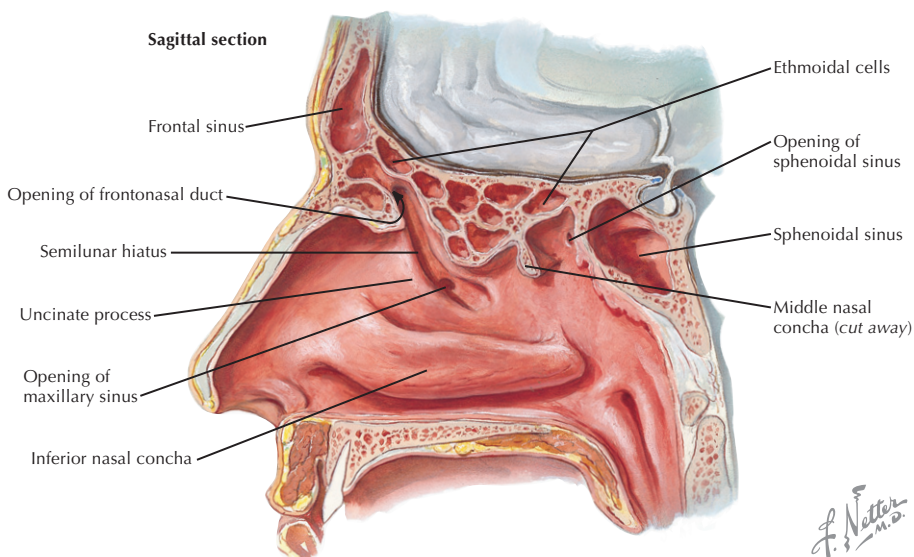
Primary lymphatic drainage is to the submandibular lymph nodes for the anterior and middle ethmoid sinuses; and the retropharyngeal lymph nodes for the posterior ethmoid sinus

### *Relations of Sinus*

- *Superior:* anterior cranial fossa and contents, frontal bone with sinus
- *Medial:* nasal cavity
- *Lateral:* orbit

### *Location of Ostium*

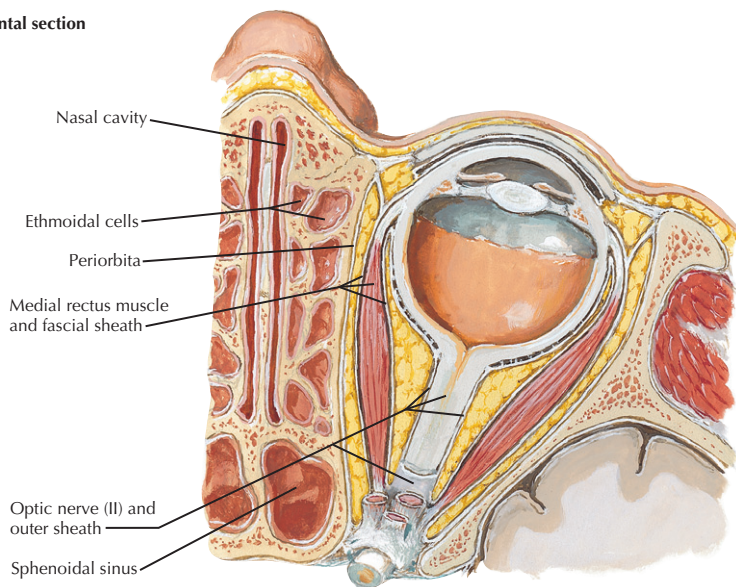
- *Anterior:* middle meatus (frontonasal duct or ethmoidal infundibulum)
- *Middle:* middle meatus (on or above ethmoid bulla)
- *Posterior:* superior meatus



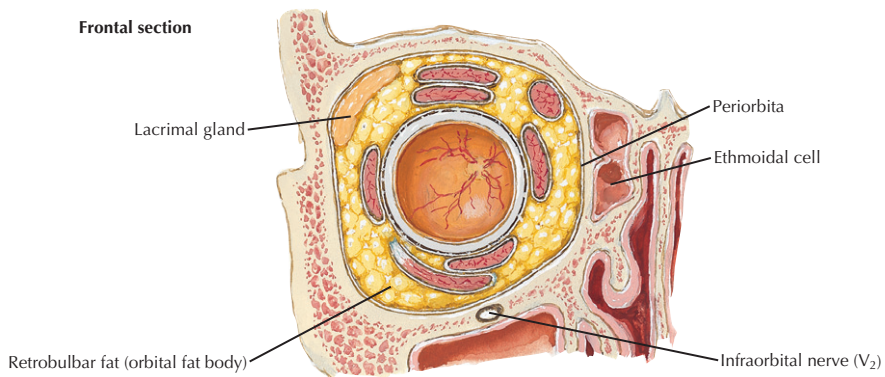
## 12 Ethmoid Sinus

### GENERAL INFORMATION *CONTINUED*

**Horizontal section**



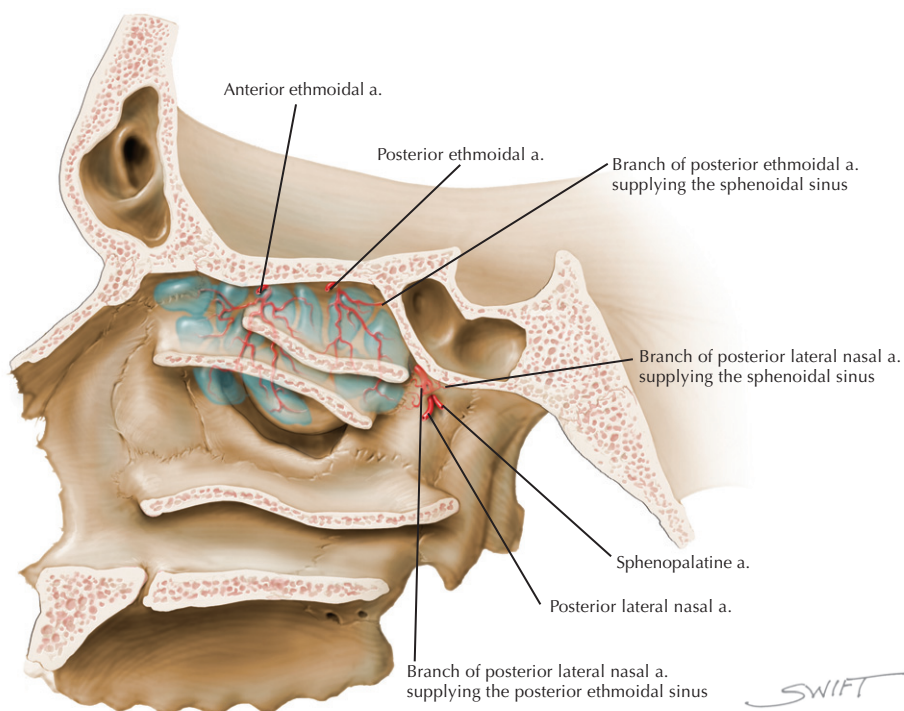
**Frontal section**



*F. Netter M.D.*

## ARTERIAL SUPPLY

Artery	Source	Course
Anterior ethmoid	Ophthalmic a. (from the internal carotid)	Enters the anterior ethmoid foramen with the nerve to pass through the canal There it supplies the anterior and middle ethmoid air cells and sometimes the frontal sinus
Posterior ethmoid		Passes through the posterior ethmoid foramen to enter the canal There it supplies the posterior ethmoid air cells and sphenoid sinus
Posterior lateral nasal branches	Sphenopalatine a. (from the maxillary a. from the external carotid a.)	Anastomose with the ethmoidal arteries to help supply the ethmoid air cells and sphenoid sinus

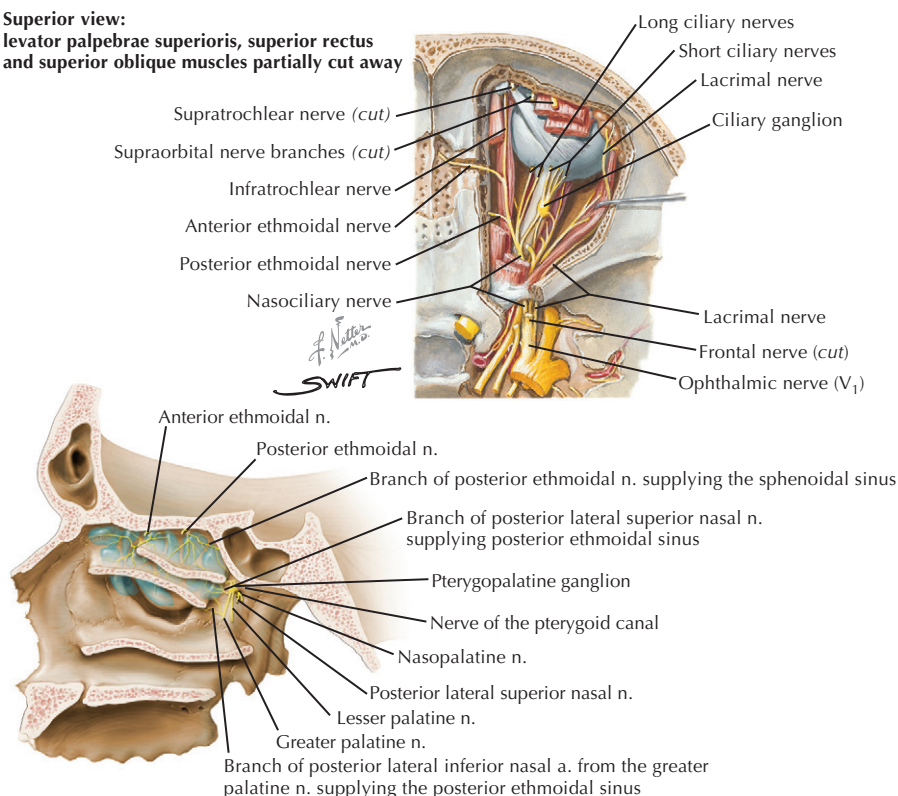


# 12 Ethmoid Sinus

## NERVE SUPPLY

Nerve	Source	Course
Anterior ethmoid	Nasociliary n. on the medial wall of the orbit (from the ophthalmic division of the trigeminal n.)	Enters the anterior ethmoid foramen and travels through the canal to enter the anterior cranial fossa While descending toward the nasal cavity, it provides innervation to the anterior and middle ethmoid air cells
Posterior ethmoid		Enters the posterior ethmoid foramen to supply the posterior ethmoid air cells Also innervates the sphenoid sinus at this location
Posterior lateral superior nasal	Pterygopalatine ganglion in the pterygopalatine fossa (from the maxillary division of the trigeminal n.)	Pass through the sphenopalatine foramen to enter the nasal cavity Branches supply the posterior ethmoid air cells at this location
Posterior lateral inferior nasal	Greater palatine n. as it descends through the palatine canal (from the maxillary division of the trigeminal n.)	May send branches to the ethmoid air cells

**Superior view:**  
levator palpebrae superioris, superior rectus  
and superior oblique muscles partially cut away





# Maxillary Sinus

## GENERAL INFORMATION

Large pyramidal cavity

Thin walls

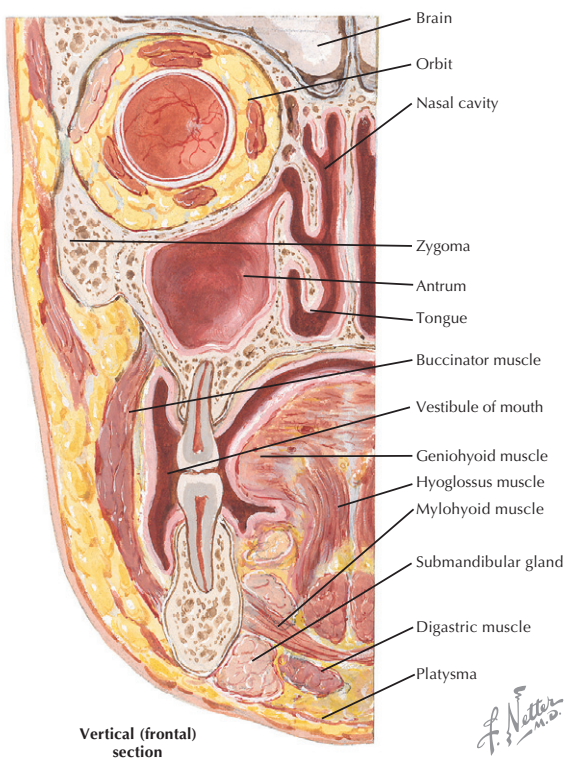
Primary lymphatic drainage is to the submandibular lymph nodes

### Relations of Sinus

- *Superior:* orbit, infraorbital nerve and vessels
- *Inferior:* roots of molars and premolars
- *Medial:* nasal cavity
- *Lateral and anterior:* cheek
- *Posterior:* infratemporal fossa, pterygopalatine fossa and contents

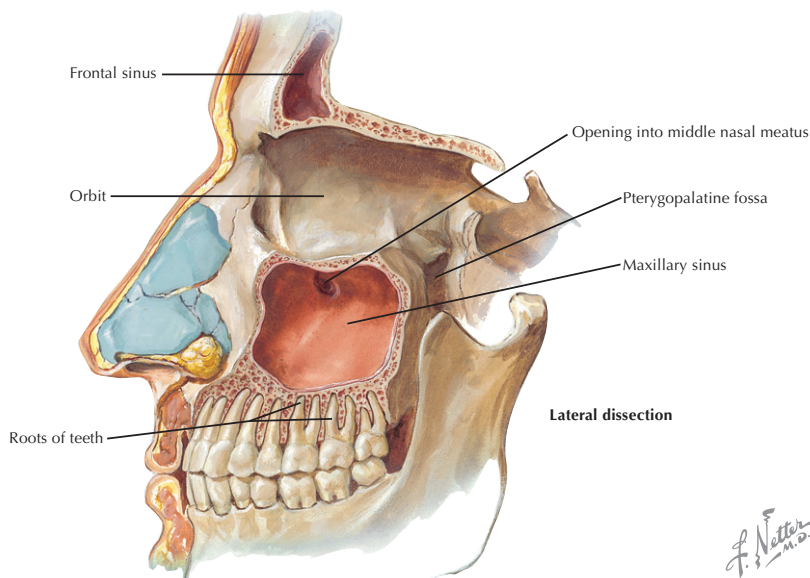
### Location of Ostium

Middle meatus



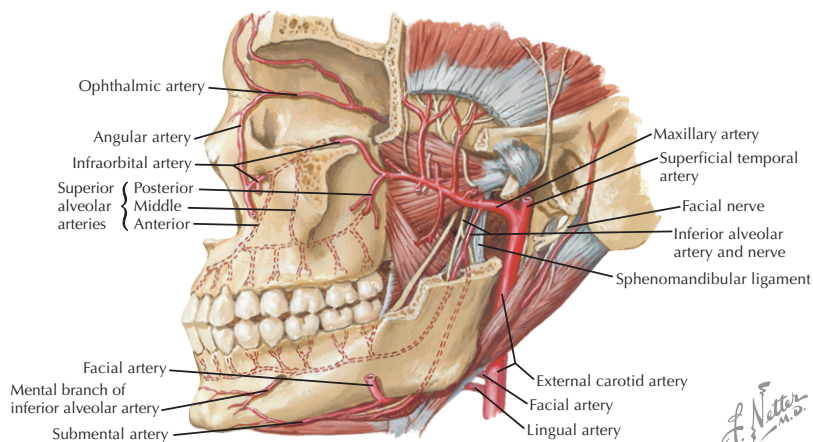
# 12 Maxillary Sinus

## GENERAL INFORMATION CONTINUED



## ARTERIAL SUPPLY

Artery	Source	Course
Anterior superior alveolar	Maxillary a. from the external carotid a.	Arises from the infraorbital a. of the maxillary a. after it passes through the inferior orbital fissure and into the infraorbital canal Descends via the alveolar canals to supply the sinus
Middle superior alveolar		When present, it arises from the infraorbital a. of the maxillary a. after passing through the inferior orbital fissure and into the infraorbital canal Descends via the alveolar canals to supply the sinus
Posterior superior alveolar		Arises from the 3rd part of the maxillary a. before the maxillary a. enters the pterygopalatine fossa Enters the infratemporal surface of the maxilla to supply the sinus

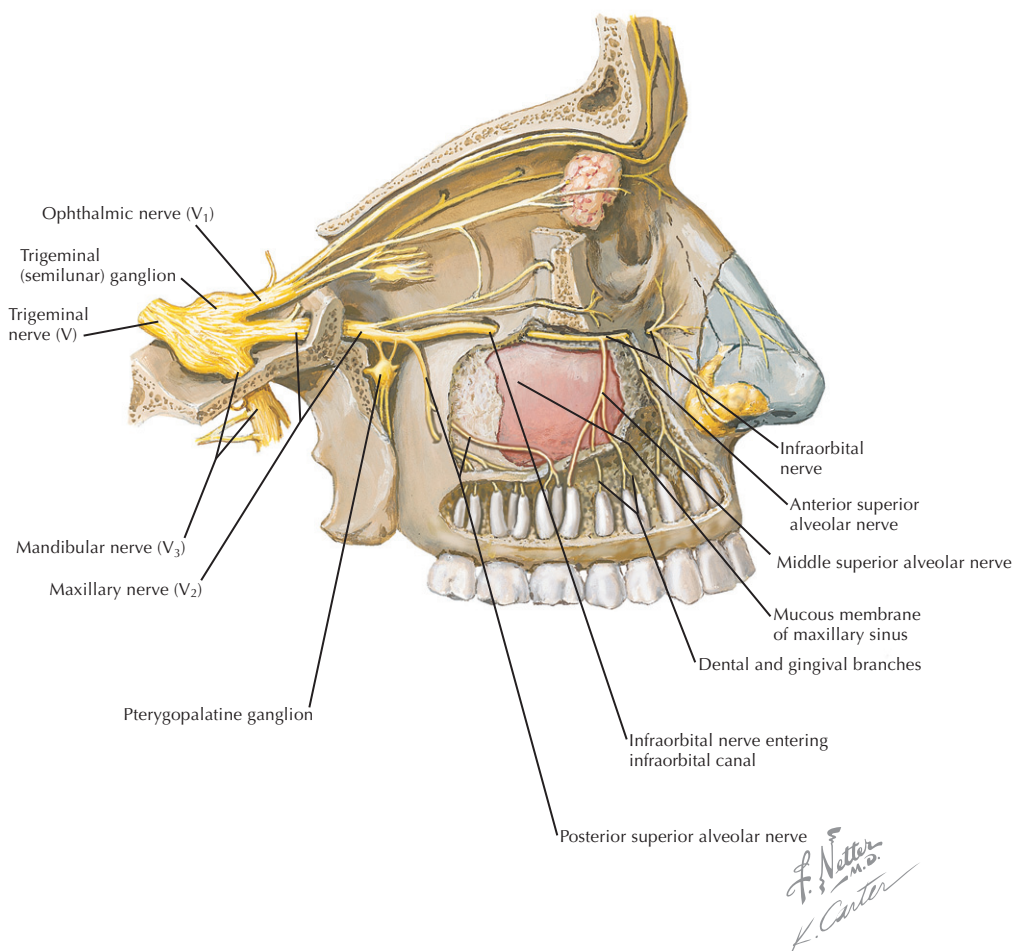


# Maxillary Sinus

12

## NERVE SUPPLY

Nerve	Source	Course
Anterior superior alveolar	Infraorbital n., which is the continuation of the maxillary division of the trigeminal n.	Branches from the infraorbital n. as it travels in the infraorbital canal As it descends to form the superior dental plexus, it innervates part of the maxillary sinus
Middle superior alveolar		When present, it branches from the infraorbital n. as it travels in the infraorbital canal As it descends to form the superior dental plexus, it innervates part of the maxillary sinus
Posterior superior alveolar	Maxillary division of the trigeminal n.	Arises in the pterygopalatine fossa Travels laterally through the pterygomaxillary fissure to enter the infratemporal fossa Enters the infratemporal surface of the maxilla As it descends to form the superior dental plexus, it innervates part of the maxillary sinus



## 12 Sphenoid Sinus

### GENERAL INFORMATION

Two large, irregularly shaped cavities

Separated by an irregular septum

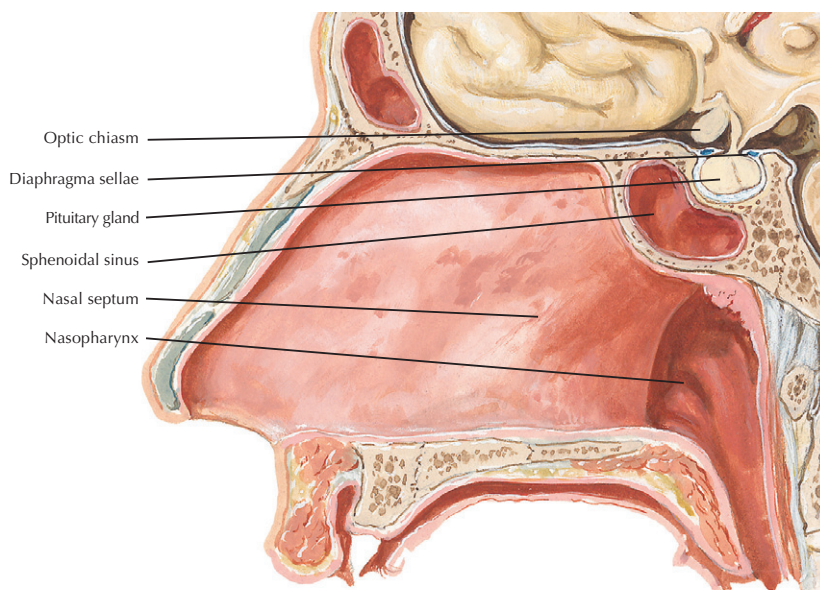
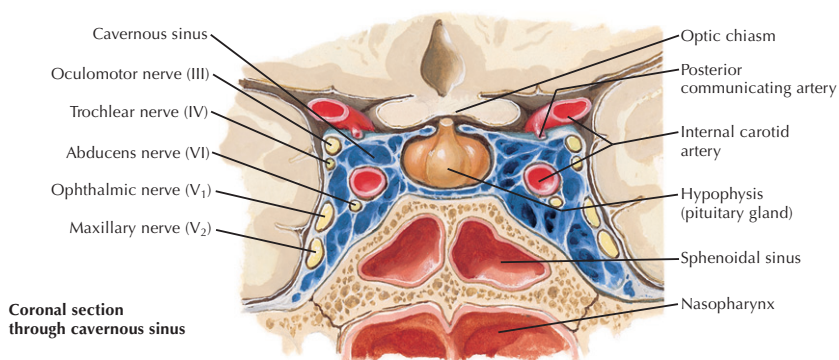
Primary lymphatic drainage is to the retropharyngeal lymph nodes

#### Relations of Sinus

- **Superior:** hypophyseal fossa, pituitary gland, optic chiasm
- **Inferior:** nasopharynx, pterygoid canal
- **Medial:** other sphenoid bone
- **Lateral:** cavernous sinus, internal carotid artery, cranial nerves III, IV, V<sub>1</sub>, V<sub>2</sub>, and VI
- **Anterior:** nasal cavity

#### Location of Ostium

Sphenoethmoidal recess



Anatomy and relations of the pituitary gland

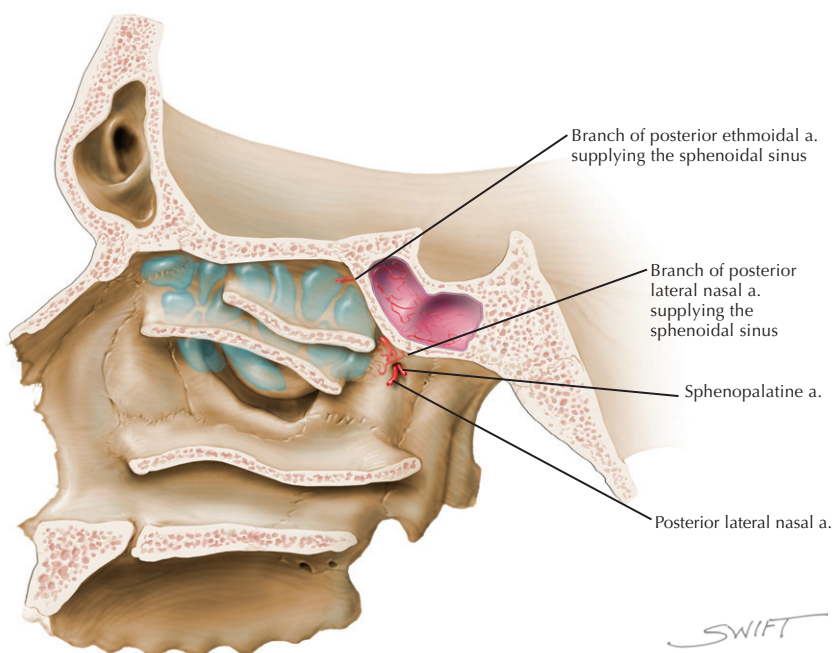
*F. Netter M.D.*

# Sphenoid Sinus

12

## ARTERIAL SUPPLY

Artery	Source	Course
Posterior ethmoid	Ophthalmic a. (from the internal carotid a.)	Passes through the posterior ethmoid foramen to enter the canal There it supplies the sphenoid sinus and the posterior ethmoid air cells
Posterior lateral nasal branches	Sphenopalatine a. from the maxillary a. (from the external carotid a.)	These branches anastomose with the ethmoidal arteries to help supply the sphenoid sinus and the ethmoid air cells

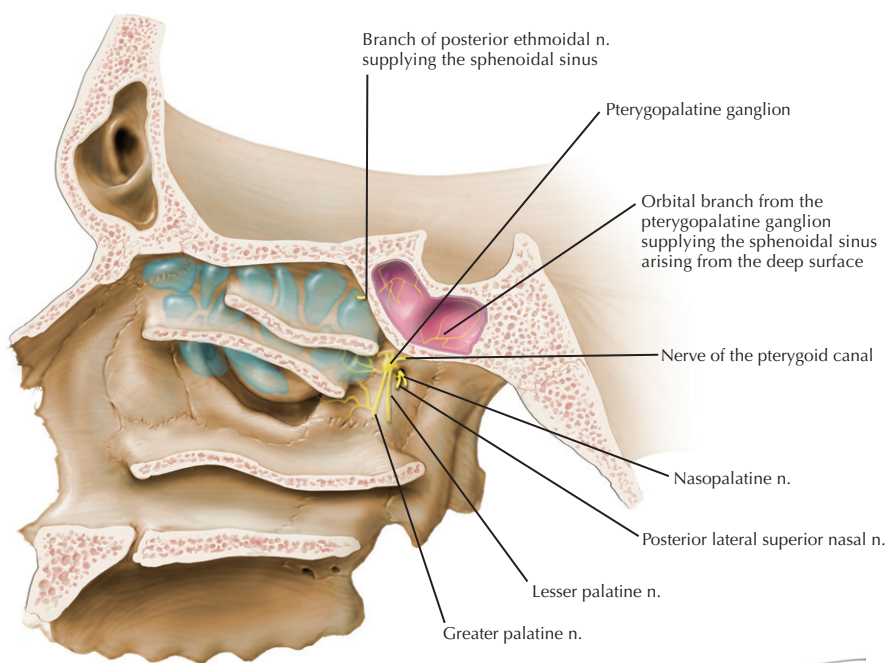




## 12 Sphenoid Sinus

### NERVE SUPPLY

Nerve	Source	Course
Posterior ethmoid	Ophthalmic division of the trigeminal n.	A branch of the nasociliary n. that lies on the medial wall of the orbit Enters the posterior ethmoid foramen to supply the sphenoid sinus Also innervates the posterior ethmoid air cell at this location
Orbital branch from the pterygopalatine ganglion	Maxillary division of the trigeminal n.	Orbital branches arising from the pterygopalatine ganglion enter the orbit through the inferior orbital fissure Some of these branches supply the sphenoid sinus at this location



SWIFT

# Clinical Correlate

## SINUSITIS

An inflammation of the membrane of the sinus cavities caused by infections (by bacteria or viruses) or noninfectious means (such as allergy)

2 types of sinusitis: acute and chronic

Common clinical manifestations include sinus congestion, discharge, pressure, face pain, headaches

### Acute Sinusitis

The most common form of sinusitis

Typically caused by a cold that results in inflammation of the sinus membranes

Normally resolves in 1 to 2 weeks

Sometimes a secondary bacterial infection may settle in the passageways after a cold; bacteria normally located in the area (*Streptococcus pneumoniae* and *Haemophilus influenzae*) may then begin to increase, producing an acute bacterial sinusitis

### Chronic Sinusitis

An infection of the sinuses that is present for longer than 1 month and requires longer-duration medical therapy

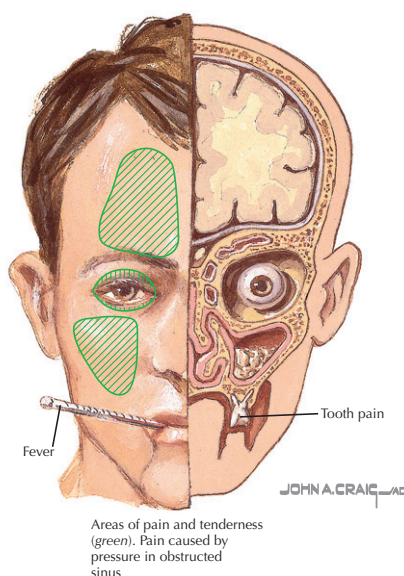
Typically either chronic bacterial sinusitis or chronic noninfectious sinusitis

Chronic bacterial sinusitis is treated with antibiotics

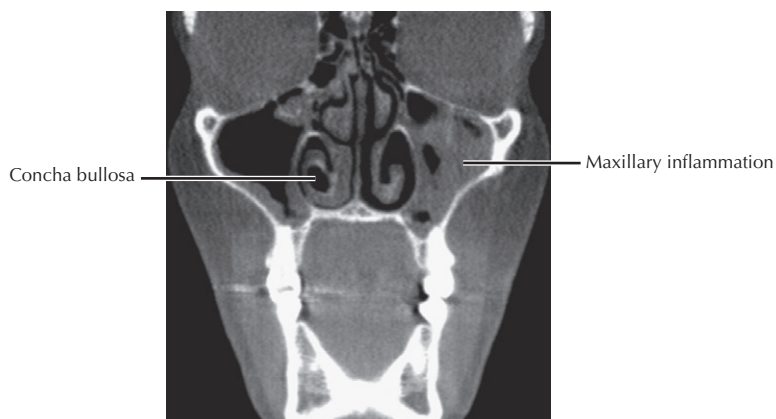
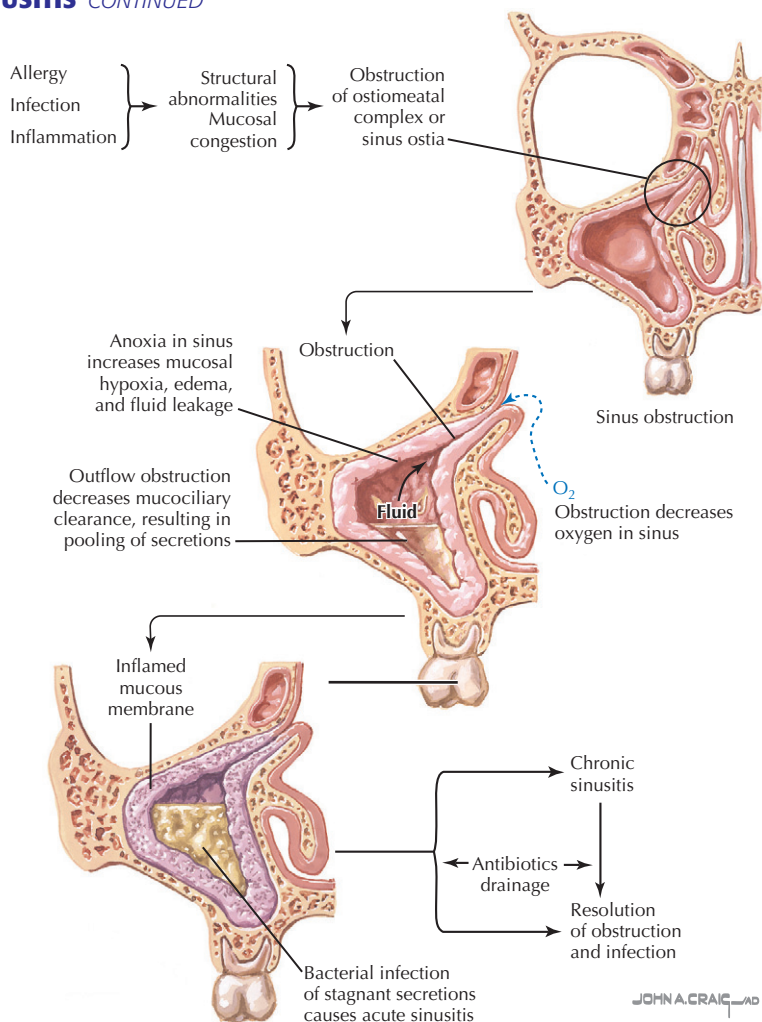
Chronic noninfectious sinusitis often is treated with steroids (topical or oral) and nasal washes

### Locations

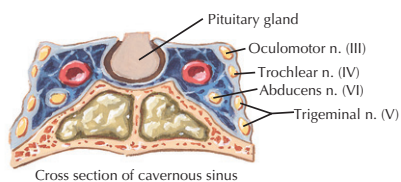
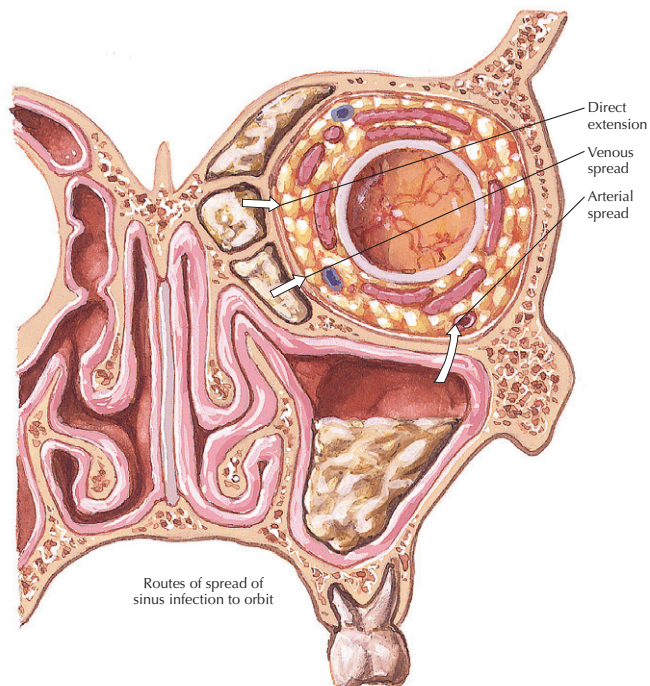
- Maxillary: the most common location for sinusitis; associated with all of the common signs and symptoms but also results in tooth pain, usually in the molar region
- Sphenoid: rare, but in this location can result in problems with the pituitary gland, cavernous sinus syndrome, and meningitis
- Frontal: usually associated with pain over the forehead and possibly fever; rare complications include osteomyelitis
- Ethmoid: potential complications include meningitis and orbital cellulitis



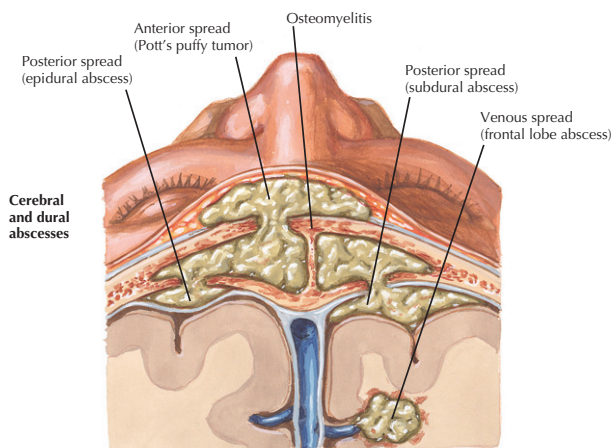
## SINUSITIS CONTINUED



## POTENTIAL SPREAD OF INFECTION VIA THE PARANASAL SINUSES



JOHN A. CRAIG MD



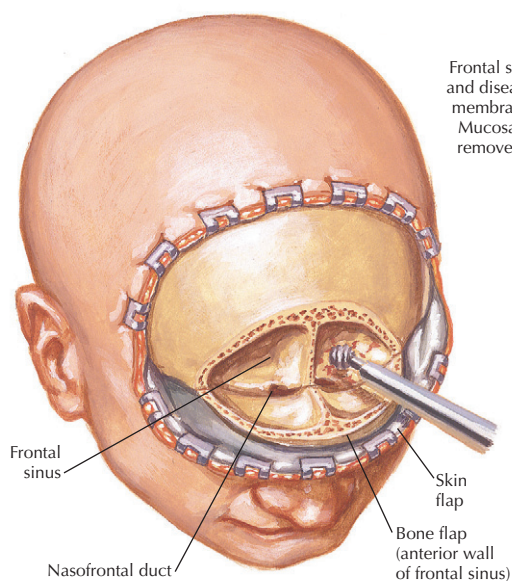
## SURGICAL PROCEDURES

### FRONTAL SINUS OBLITERATION

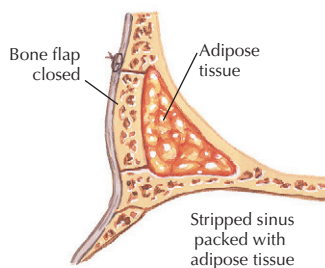
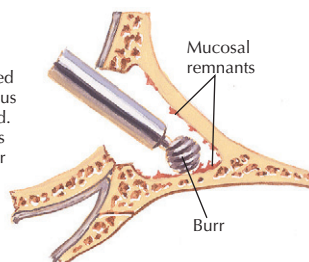
A procedure in which the frontal sinus is completely removed to treat problematic cases of frontal sinus infection, osteomyelitis, and trauma

Once the sinus is opened, all of the sinus membrane is removed with a burr; otherwise, any remaining membrane may form a mucocele

The remaining area often is filled with adipose tissue from the patient because it is thought to impede regrowth of the mucoperiosteum



Frontal sinus opened and diseased mucous membrane stripped. Mucosal remnants removed with burr



JOHN A. CRAIG MD



## Clinical Correlate

### SURGICAL PROCEDURES *CONTINUED*

#### CALDWELL-LUC PROCEDURE

This intraoral procedure allows direct entry into the maxillary sinus

Also provides access to the ethmoid sinus

The maxillary sinus is entered through the canine fossa above the maxillary premolar teeth

The maxillary antrum is opened, the sinus membrane is stripped, and an additional antrostomy is made between the maxillary sinus and the inferior meatus

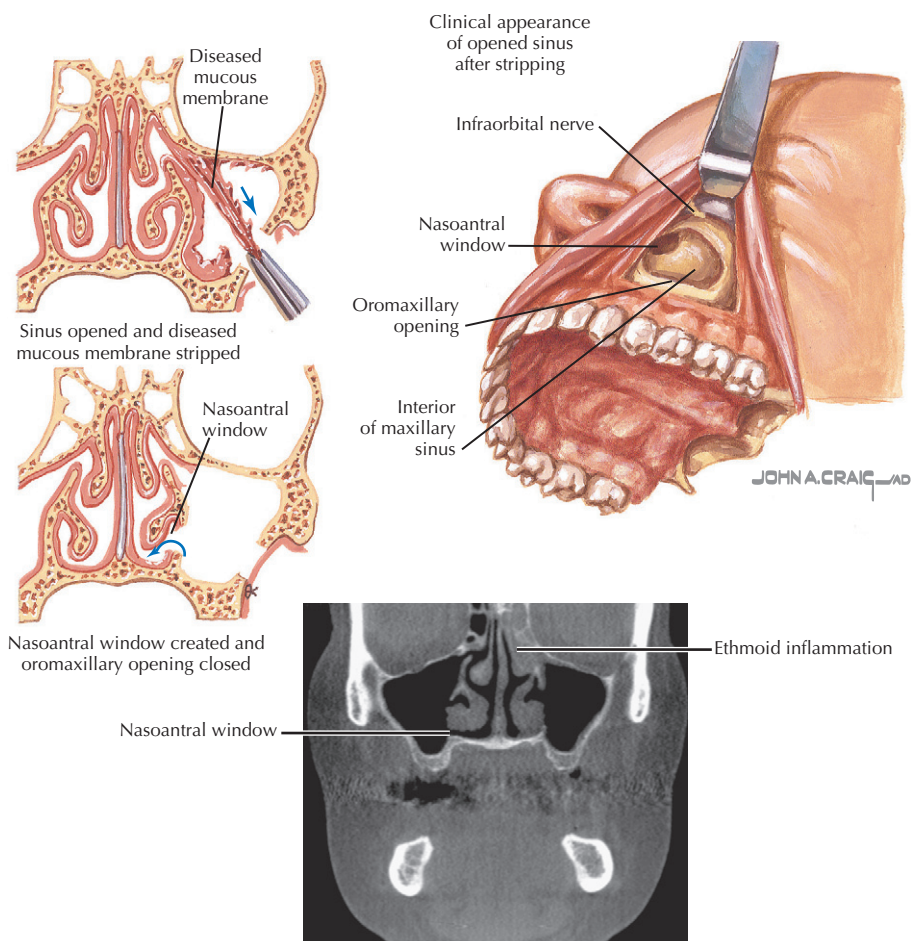
#### *Conditions Treated*

The antrostomy allows drainage of the maxillary sinus into the nasal cavity

With the advent of functional endoscopic sinus surgery for antrostomies, the Caldwell-Luc procedure often is used for exposure and removal of tumors

Used to be commonly performed to treat chronic maxillary sinusitis

Was also used for procedures such as removal of benign tumors and foreign bodies, access to the pterygopalatine fossa, and closure of dental fistulas into the maxillary sinus



## 12 Clinical Correlate

### **SURGICAL PROCEDURES** *CONTINUED*

#### **MAXILLARY IMPLANTS**

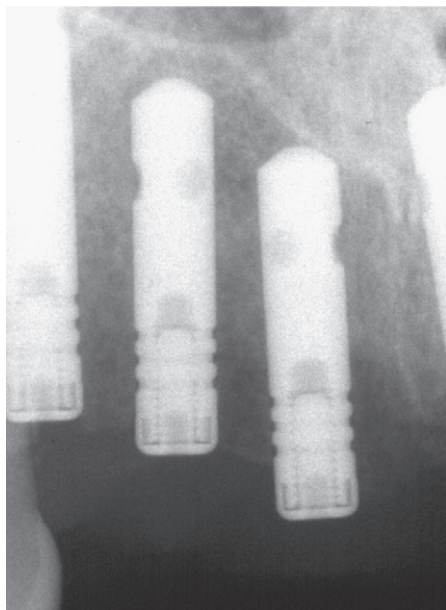
Common dental procedure to add fixed maxillary teeth to the oral cavity

Patient should be in relatively good health

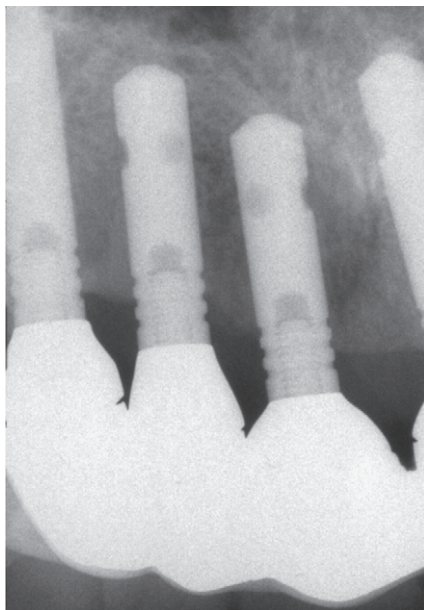
Patient must have sufficient bone in a location suitable for placing an implant

It is becoming more common to use bone grafting before the surgical implant is placed

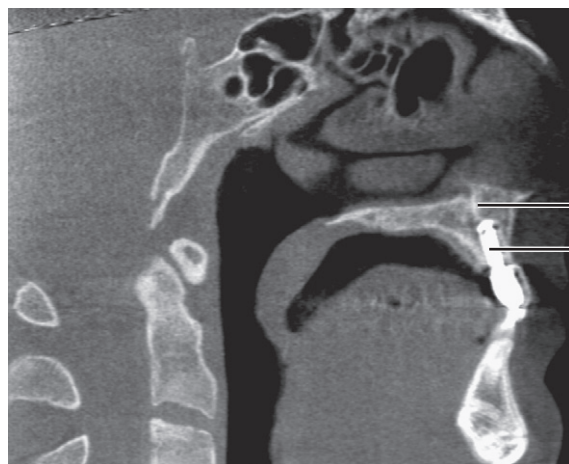
Bone grafts to provide adequate bed for implants may be harvested from the body or as allografts, or may be supplied as xenografts or synthetic bone substitutes



Maxillary implants before teeth are placed



Maxillary implants after teeth are placed on the implant



Nasopalatine canal  
Maxillary implant

# Clinical Correlate

## SURGICAL PROCEDURES *CONTINUED*

### FUNCTIONAL ENDOSCOPIC SINUS SURGERY

Uses an endoscope inserted into the nose to view the nasal cavity and sinuses, thereby eliminating an external incision

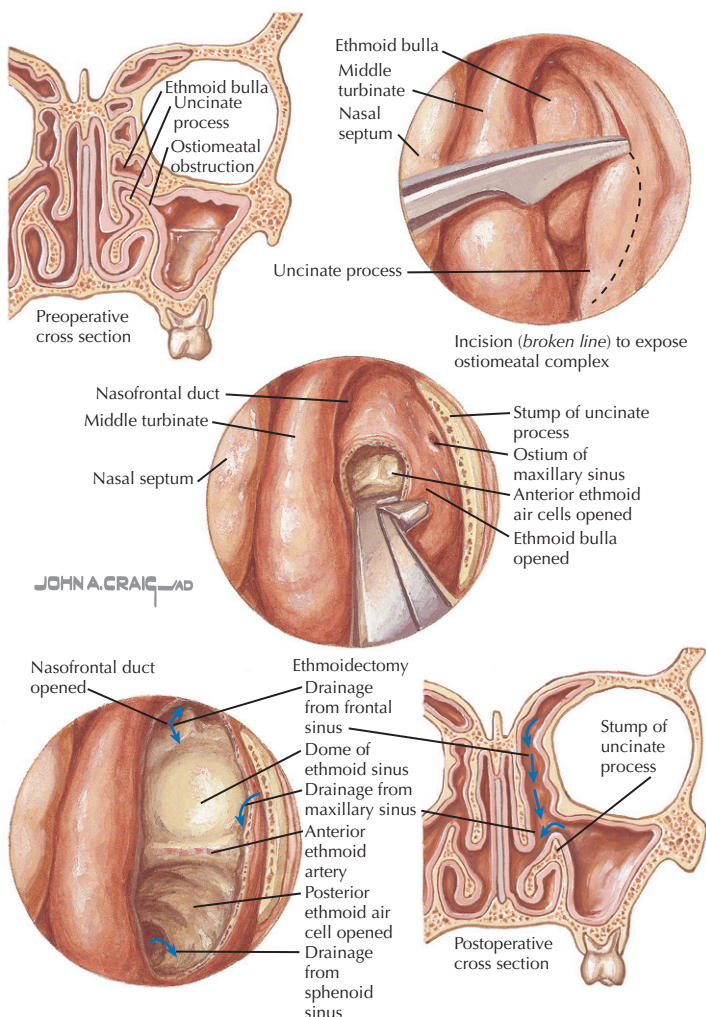
Often an outpatient procedure

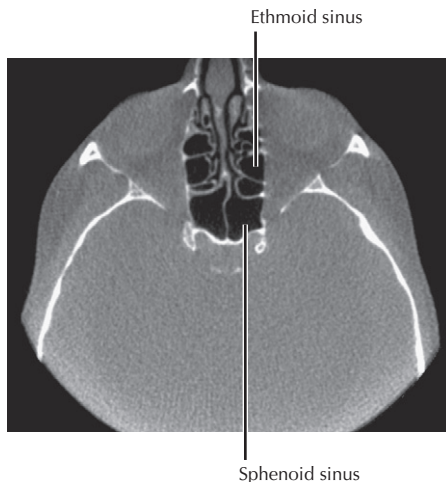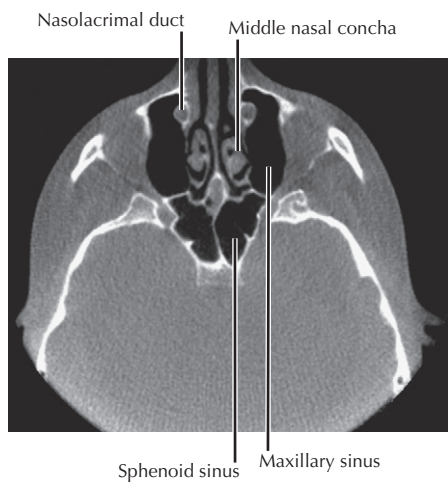
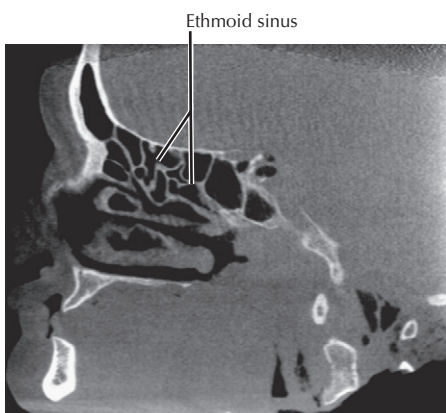
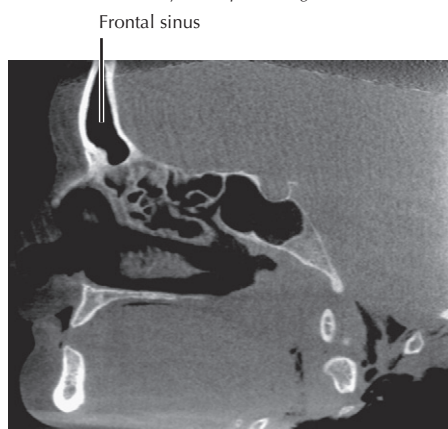
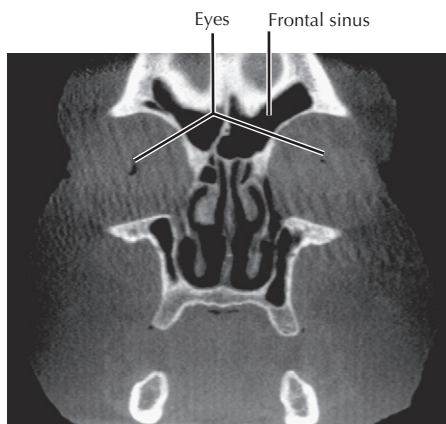
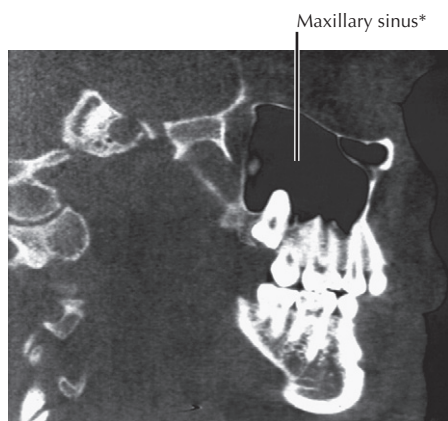
Provides increased visualization of the area, making it easier to remove diseased tissue and leave a greater amount of normal tissue intact

Standard surgical treatment for sinusitis for people whose chronic sinus problems do not respond to medical therapy

Also used for removal of polyps, mucocoeles, tumors, and foreign bodies and for control of epistaxis

Functional Endoscopic Sinus Surgery





## CHAPTER 13

# ORAL CAVITY

Overview and Topographic Anatomy	326
External Anatomy	327
Boundaries of the Oral Cavity	332
Teeth	341
Vascular Supply of the Oral Cavity	352
Nerve Supply of the Oral Cavity	358
Salivary Glands	366
Clinical Correlates	372
Imaging	378



# 13 Overview and Topographic Anatomy

## GENERAL INFORMATION

*Oral cavity:* the space located between the lips and cheeks on the external surface to the palatoglossal fold on the internal surface

The oral cavity is important in mastication, tasting, and talking

The area of the oral cavity can be divided into:

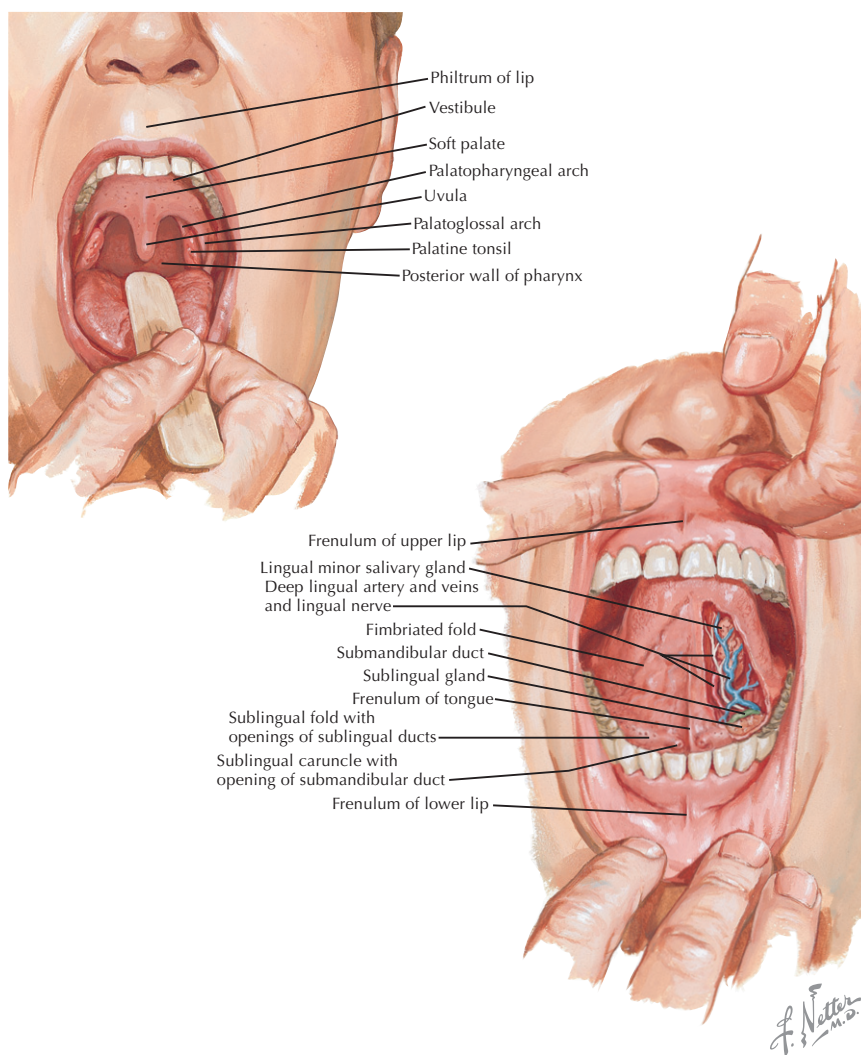
- Vestibule—the area between the teeth and lips or cheek
- Oral cavity proper—the area located internal to the teeth

Posteriorly, the oral cavity is continuous with the oropharynx

The hard palate and the soft palate are important boundaries within the oral cavity

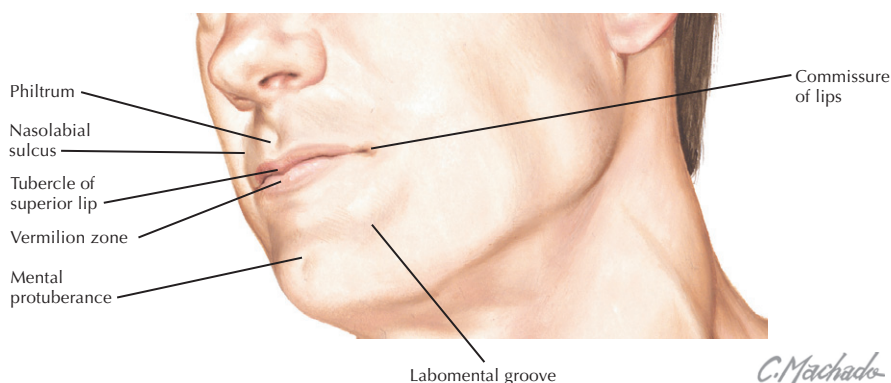
The tongue is a major structure located on the oral cavity floor

All of the major salivary glands—parotid, submandibular, and sublingual—drain into the oral cavity



## EXTERNAL FEATURES

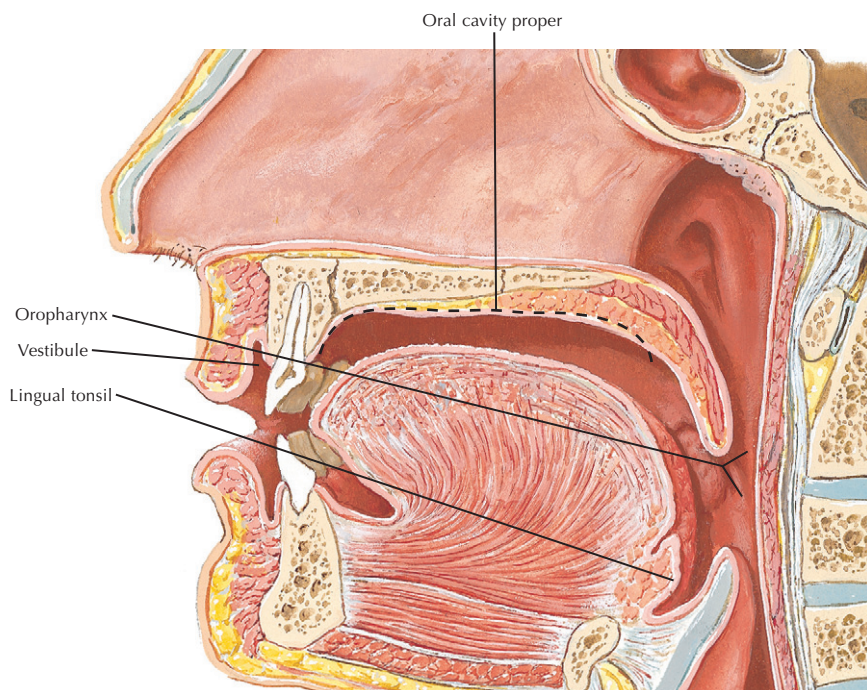
Structure	Comments
Lips	<p>Divided into an upper and a lower lip that surround the opening of the oral cavity</p> <p>Both lips have a muscular “skeleton” composed of the orbicularis oris m.</p> <p>Upper lip is separated from the cheek by the nasolabial groove</p> <p>Lower lip is separated from the chin by the labiomental groove</p> <p>Upper and lower lips meet at the labial commissures</p> <p><b>Vermilion zone</b>—the red area of the lip that is clearly demarcated from the skin of the face at the vermillion border; also known as the red zone</p> <p><b>Philtrum</b>—the depressed area located between the base of the nose and the vermillion border of the upper lip</p> <p>Many mucus-secreting labial glands are located within the submucosal layer of the lips at the area of transition to mucous membrane of the oral cavity, which is nonkeratinized stratified squamous epithelium</p> <p><b>Vestibule</b>—the region between the lips and cheeks and the teeth</p> <p>The fold of tissue created by the vestibule between the lip and teeth is called the vestibular or mucolabial fold</p> <p>As the vestibular fold reflects on the alveolar bone holding the teeth, the mucous membrane abruptly changes into the gingiva</p> <p>Within the vestibular fold are bands of tissue known as labial frenula</p> <p>The labial frenula are pronounced at the maxillary and mandibular midline as the upper and lower frenula, respectively</p> <p>Other accessory frenula also are located in the vestibule</p>
Cheek	<p>Located between the labial commissure and the mucosa overlying the ramus of the mandible</p> <p>Has a muscular “skeleton” composed of the buccinator m.</p> <p>Many mucus-secreting glands, known as molar glands, are located within the submucosal layer of the inside of the cheeks, which is lined by mucous membrane of the oral cavity (nonkeratinized stratified squamous epithelium)</p> <p>Vestibule continues from the region between the lips and teeth posteriorly, to be located between the cheek and the teeth</p> <p>The fold of tissue created by the vestibule between the lip and the teeth is called the vestibular or mucobuccal fold</p> <p>The retromolar region is the only area in which the vestibule and the oral cavity proper communicate</p> <p>The parotid duct drains into the oral cavity at the parotid papilla, located along the mucous membrane of the cheek opposite the 2nd maxillary molar</p> <p>Fordyce’s spots, ectopic sebaceous glands found in the mucosa of the cheeks appearing as yellowish spots, can be observed in the cheek</p>



C. Machado  
—M.D.

# 13 External Anatomy

## EXTERNAL FEATURES CONTINUED

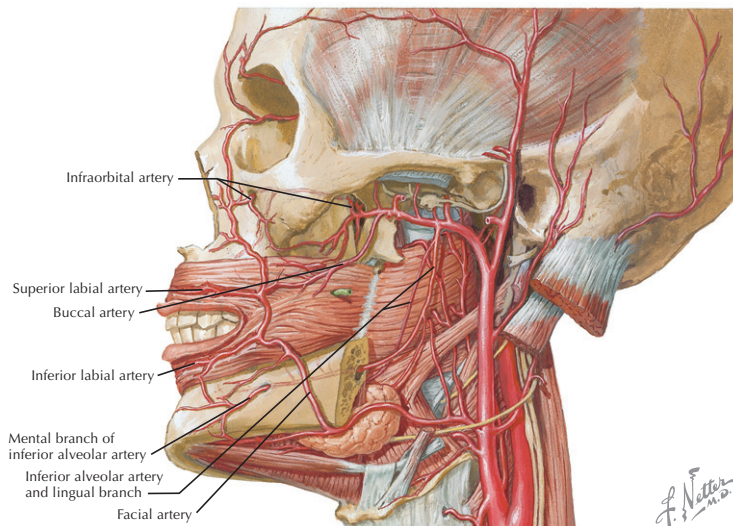


*F. Netter M.D.*

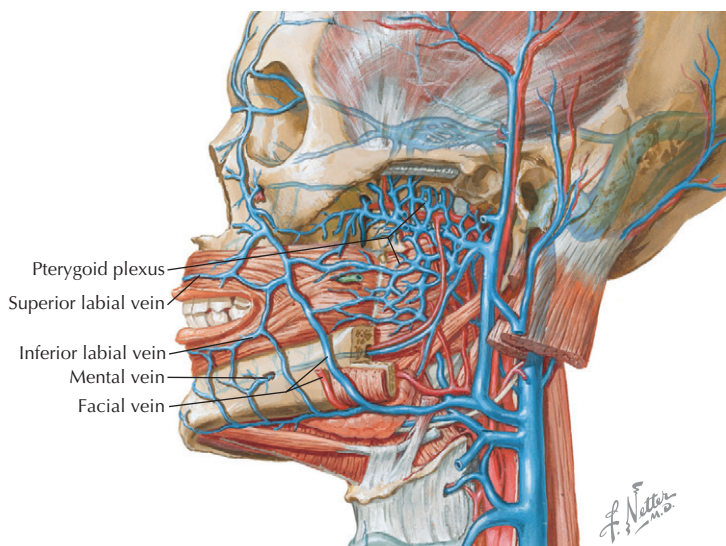
## VASCULAR SUPPLY OF THE LIPS AND CHEEK

ARTERIAL SUPPLY		
Artery	Source	Comments
Superior labial branch of the facial	Facial a. off the external carotid a.	Supplies the structures associated with the upper lip Gives rise to the septal branch that travels to the nasal septum
Superior labial branch of the infraorbital	Infraorbital a. off the maxillary a.	A continuation of the 3rd part of the maxillary a. One of the 3 terminal branches of the infraorbital a., along with the inferior palpebral branch and the nasal branch Accompanied by the nerve and vein of the same name Helps supply the upper lip
Inferior labial branch of the facial	Facial a. off the external carotid a.	Supplies the structures associated with the lower lip
Mental	Inferior alveolar a.	A terminal branch from the inferior alveolar a., which arises from the 1st part of the maxillary a. Emerges from the mental foramen to supply the chin region
Buccal	Maxillary a.	A branch of the 2nd part of the maxillary a. A small artery that runs obliquely in an anterior direction between the medial pterygoid and the insertion of the temporalis m. until it reaches the outer surface of the buccinator m. to supply that muscle and the face

## VASCULAR SUPPLY OF THE LIPS AND CHEEK *CONTINUED*



VENOUS DRAINAGE	
Vein	Comments
Superior labial branch of the facial	Drains the upper lip and joins the facial v.
Inferior labial branch of the facial	Drains the lower lip and joins the facial v.
Mental	Drains the chin and lower lip and joins the pterygoid plexus of veins
Buccal	Drains the cheek and joins the pterygoid plexus of veins

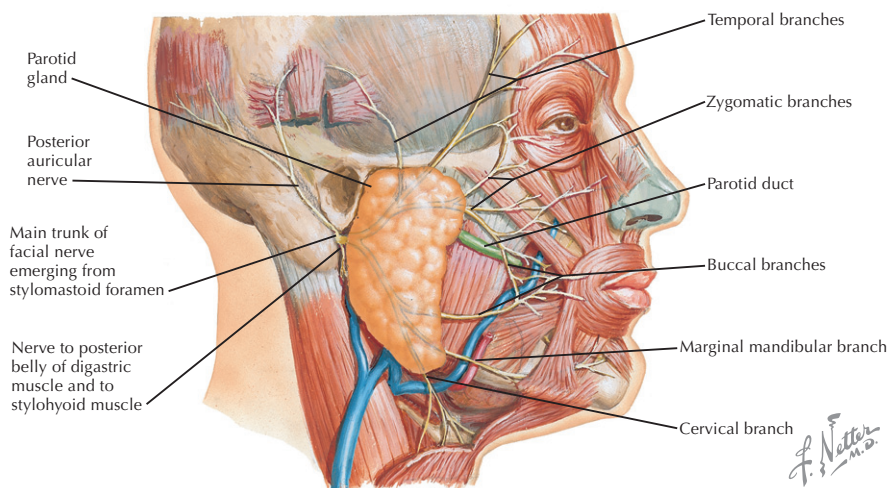




# 13 External Anatomy

## NERVE SUPPLY

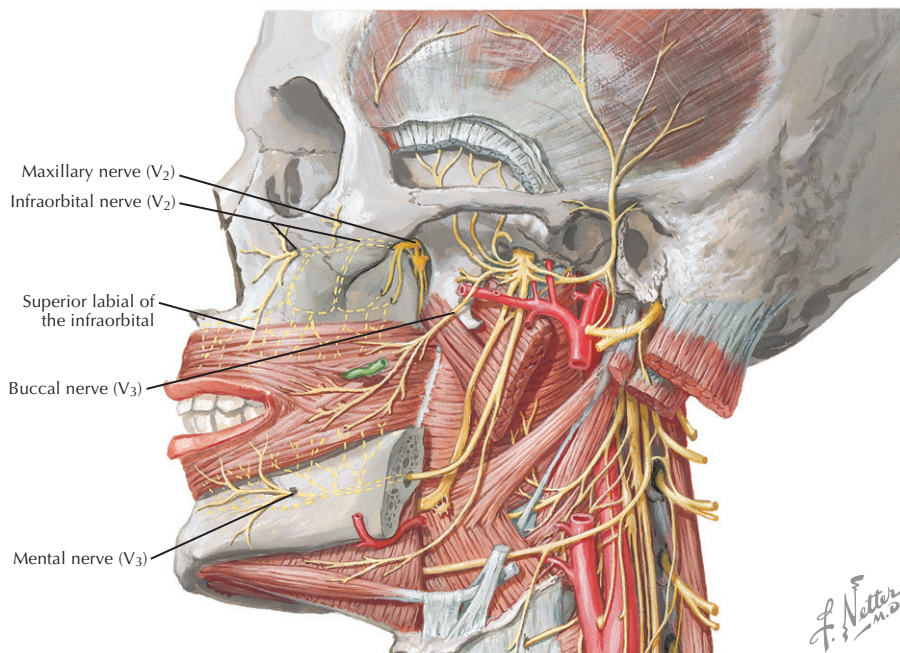
MOTOR INNERVATION		
Nerve	Source	Course
All muscles of facial expression are innervated by the facial n.		
Buccal branch of the facial	Facial n.	Arise from both the temporofacial and cervicofacial trunks of the facial n. These branches supply the muscles along the muscular part of the cheek, including the buccinator and the orbicularis oris mm.
Mandibular branch of the facial		Arises from the cervicofacial trunk and passes anteriorly, supplying the muscles of the lower lip and chin, including the orbicularis oris m.





## NERVE SUPPLY *CONTINUED*

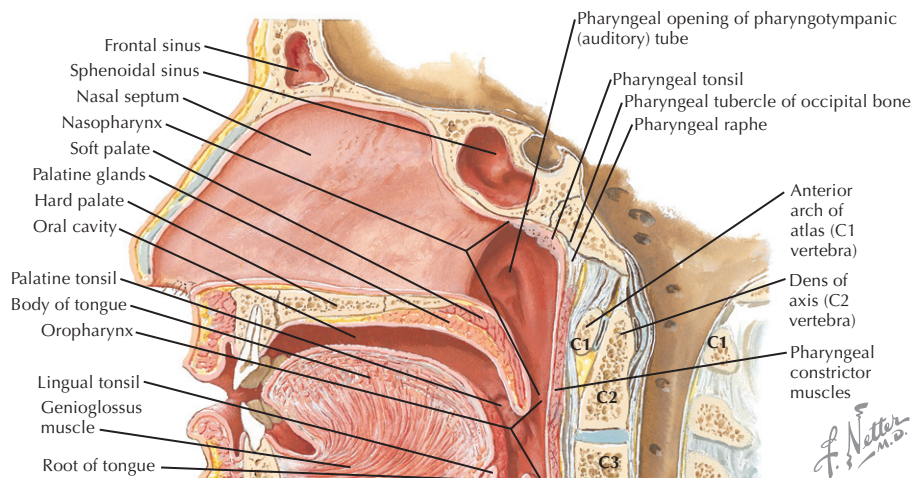
SENSORY INNERVATION		
Nerve	Source	Course
All sensory innervation to the skin of this region is supplied by the trigeminal n.		
Superior labial branch of the infraorbital	Infraorbital n. (a continuation of the maxillary division of the trigeminal n.)	One of the 3 terminal branches of the infraorbital n., along with the inferior palpebral and the nasal, as it exits onto the face via the infraorbital foramen Supplies the skin of the upper lip
Mental	Inferior alveolar n.	1 of the 2 terminal branches of the inferior alveolar n. Emerges through the mental foramen of the mandible in the region of the 2nd mandibular premolar Supplies the skin of the lower lip, chin, and facial gingiva as far posteriorly as the 2nd mandibular premolar
Buccal branch of the mandibular division of the trigeminal	Mandibular division of the trigeminal n.	Passes anteriorly between the 2 heads of the lateral pterygoid m. Descends inferiorly along the lower part of the temporalis m. to emerge from deep to the anterior border of the masseter m. Supplies the skin over the buccinator m. before passing through it to supply the mucous membrane lining its inner surface and the gingiva along the mandibular molars



# 13 Boundaries of the Oral Cavity

## GENERAL INFORMATION

Boundary	Structure
Superior	The roof is the hard palate
Posterosuperior	Soft palate
Lateral	Cheeks
Inferior	The floor is located along the lingual border of the mandible forming a horseshoe-shaped region



## SUPERIOR BORDER: HARD PALATE

The superior border (or roof) of the oral cavity is the hard palate, comprising the anterior 2/3 of the entire palate

Separates the oral cavity from the nasal cavity

Composed of:

- Palatal process of the maxilla
- Horizontal process of the palatine

In the anterior midline, an incisive foramen is located on the right and left sides that transmits the terminal branches of the nasopalatine nerve and sphenopalatine vessels

In the posterolateral region of the hard palate, the greater and lesser palatine foramina are located on the right and left sides; these openings transmit the greater and lesser palatine nn. and vessels

The bones of the hard palate are covered by a thick mucous membrane

The mucous membrane has a small elevation in the anterior midline called the incisive papilla that overlies the incisive foramen

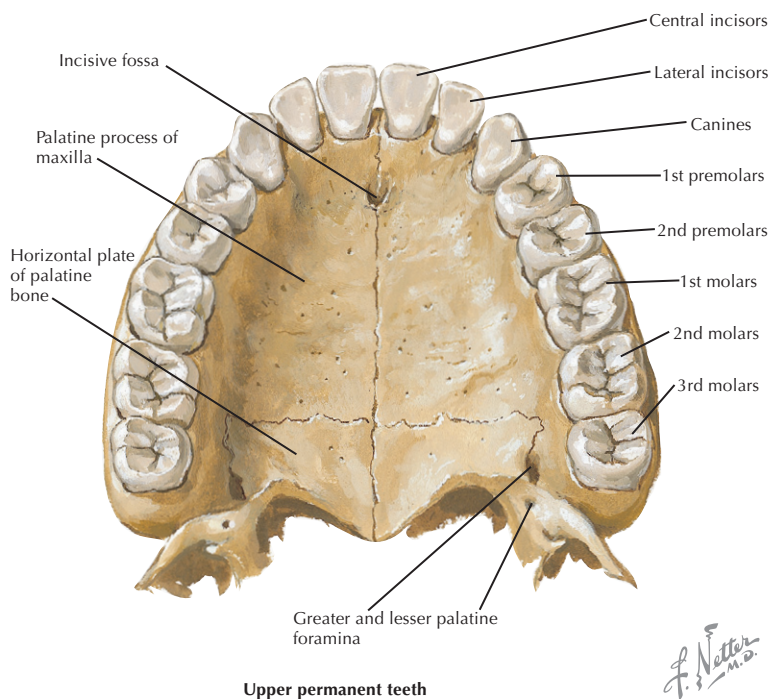
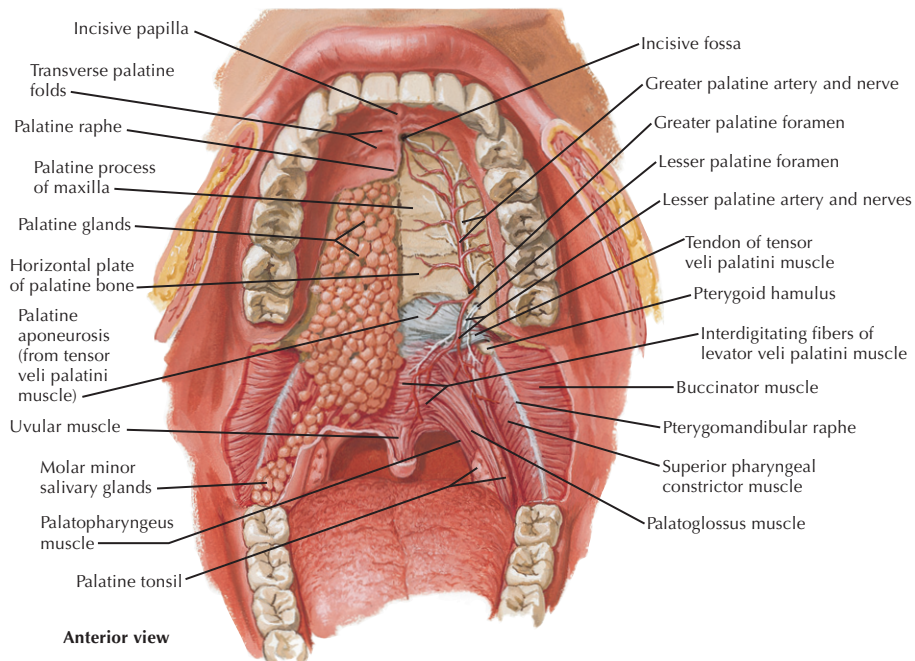
Moving posteriorly from the incisive papilla, the mucous membrane has a thick midline palatal raphe

Lateral transverse ridges called transverse rugae (plicae) are located along the mucous membrane of the hard palate

Deep to the mucous membrane of the hard palate are numerous mucus-secreting glands called palatal glands

# Boundaries of the Oral Cavity

## SUPERIOR BORDER: HARD PALATE *CONTINUED*



## 13 Boundaries of the Oral Cavity

### POSTEROSUPERIOR BORDER: SOFT PALATE

The posterosuperior border of the oral cavity is the soft palate

The soft palate is the continuation of the palate posteriorly and makes up approximately 1/3 of the entire palate

The soft palate separates the oral cavity from the nasopharynx

An abundance of mucus-secreting palatal glands, which are continuous with the hard palate, are located in the soft palate

The soft palate has 3 margins:

- Anteriorly, it is continuous with the hard palate at the vibrating line
- Posterolaterally, it forms the superior portion of the palatoglossal and palatopharyngeal folds
- Posteriorly, the uvula hangs in the center of the posterior free margin

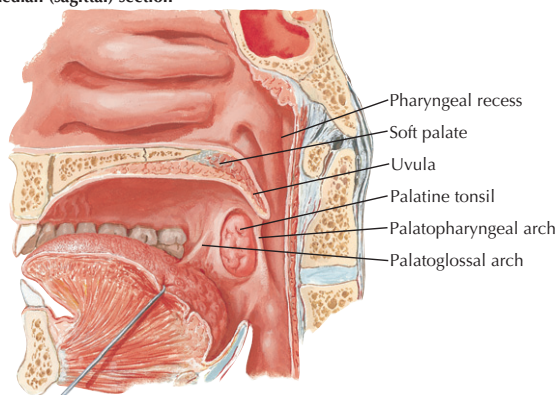
The thick palatine aponeurosis forms the foundation of the soft palate

The soft palate is composed of 5 muscles:

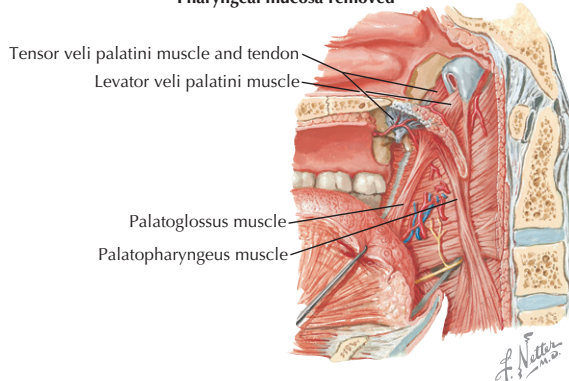
- Musculus uvulae
- Tensor veli palatini
- Levator veli palatini
- Palatopharyngeus
- Palatoglossus (sometimes considered in the grouping of tongue muscles)

The soft palate helps close off the nasopharynx during deglutition by forming a seal at the fold of Passavant

Medial view  
Median (sagittal) section



Pharyngeal mucosa removed



# Boundaries of the Oral Cavity

## POSTEROSUPERIOR BORDER: SOFT PALATE *CONTINUED*

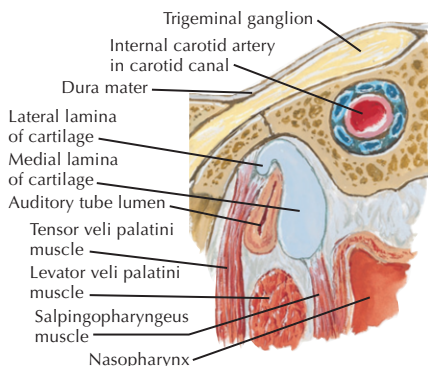
MUSCLES OF THE SOFT PALATE					
Muscle	Origin	Insertion	Actions	Nerve Supply	Comment
Tensor veli palatini	Cartilaginous part of the auditory tube Scaphoid fossa of the sphenoid	Palatine aponeurosis	Pulls the soft palate laterally, which broadens it	Pharyngeal plexus (motor portion from the vagus n. and cranial part of the accessory nn.)	The tendon of the tensor veli palatini m. wraps around the pterygoid hamulus
Musculus uvulae	Posterior nasal spine Palatine aponeurosis	Fibers insert into the muscle of the opposite side	Elevates uvula Pulls uvula laterally		May be bifid
Levator veli palatini	Cartilaginous portion of the auditory tube Petrous portion of the temporal bone	Palatine aponeurosis Fibers also insert into the muscle of the opposite side	Elevates soft palate Pulls soft palate posteriorly, which acts to help close the nasopharynx		The levator veli palatini m. passes through an aperture superior to the superior constrictor m.
Palatopharyngeus	Posterior border of hard palate Palatine aponeurosis	Posterior border of the lamina of the thyroid cartilage	Elevates the pharynx and larynx Acts to help close the nasopharynx		Grouped either with soft palate muscles or with muscles of the pharynx
Palatoglossus	Palatine aponeurosis	Side of the tongue where the fibers mix with the intrinsic muscles of the tongue	Elevates the tongue Narrows the oropharyngeal isthmus for deglutition		Grouped either with extrinsic muscles of the tongue or with muscles of the soft palate



# 13 Boundaries of the Oral Cavity

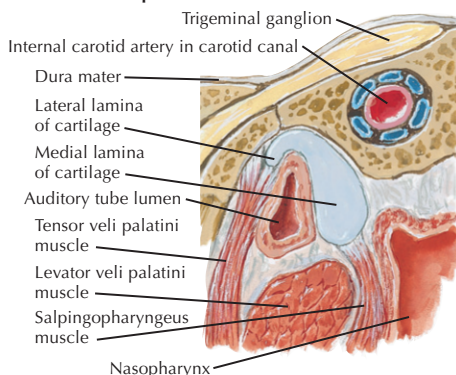
## POSTEROSUPERIOR BORDER: SOFT PALATE *CONTINUED*

**Section through cartilaginous part of pharyngotympanic (auditory) tube, with tube closed**

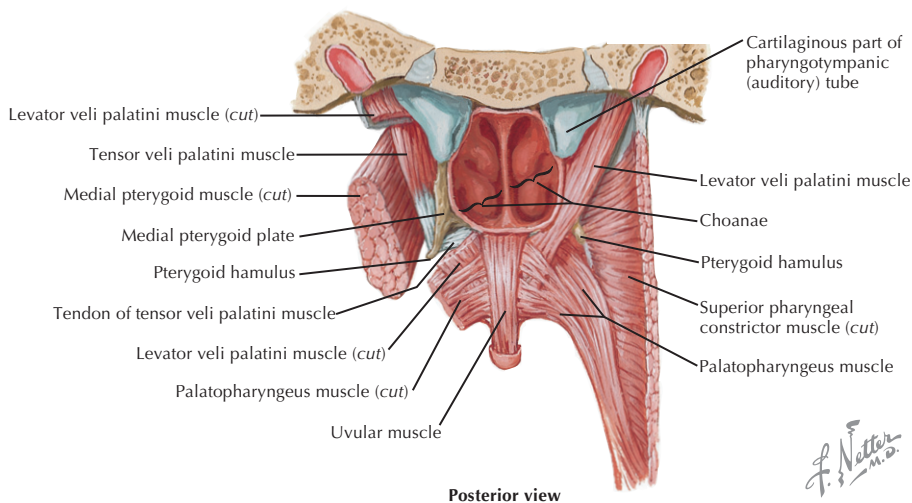


Pharyngotympanic (auditory) tube closed by elastic recoil of cartilage, tissue turgidity and tension of salpingopharyngeus muscles

**Section through cartilaginous part of pharyngotympanic (auditory) tube, with tube open**



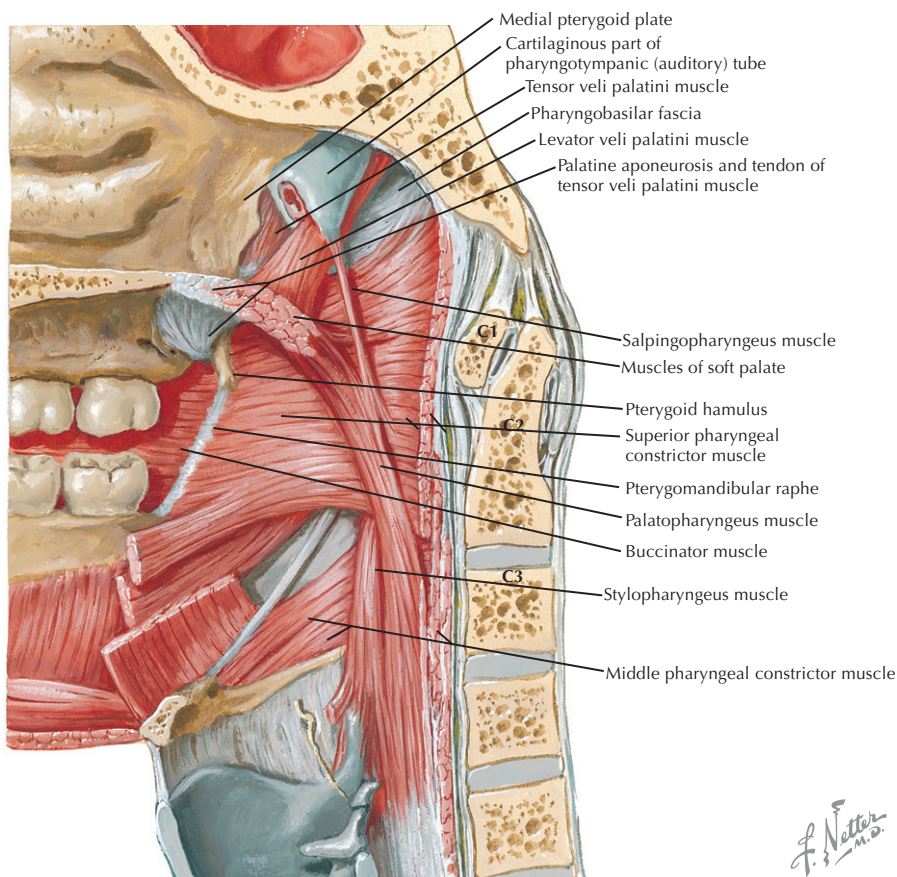
Lumen opened chiefly when attachment of tensor veli palatini muscle pulls wall of tube laterally during swallowing



**Posterior view**

# Boundaries of the Oral Cavity

## POSTEROSUPERIOR BORDER: SOFT PALATE *CONTINUED*



## LATERAL BORDER: CHEEK

The lateral border of the oral cavity extends anteriorly from the labial commissure, posteriorly to the ramus of the mandible

Superior limit of the cheek is the maxillary vestibule; inferior limit is the mandibular vestibule

Mucous membrane of the cheek is stratified squamous epithelium

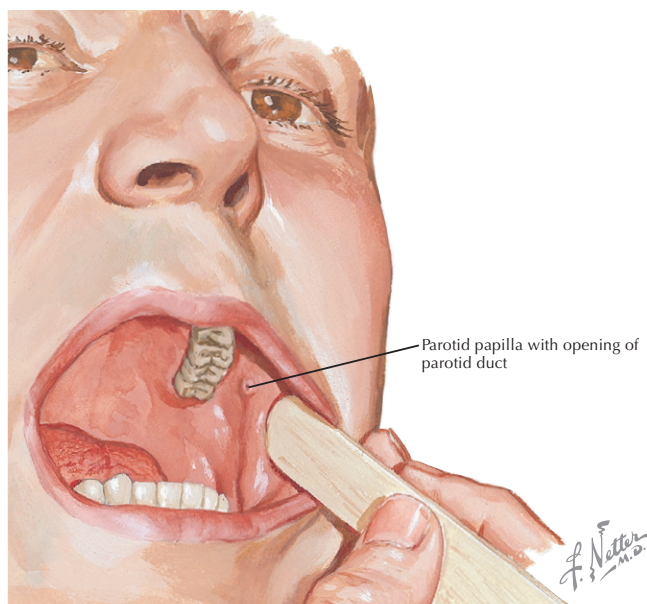
Fordyce's spots are ectopic sebaceous glands that may be observed on the inner surface of the cheek

Parotid papilla is located in the cheek opposite the maxillary 2nd molar

Pterygomandibular raphe is located in the posterior portion and serves as a landmark for the pterygomandibular space

# 13 Boundaries of the Oral Cavity

## LATERAL BORDER: CHEEK *CONTINUED*



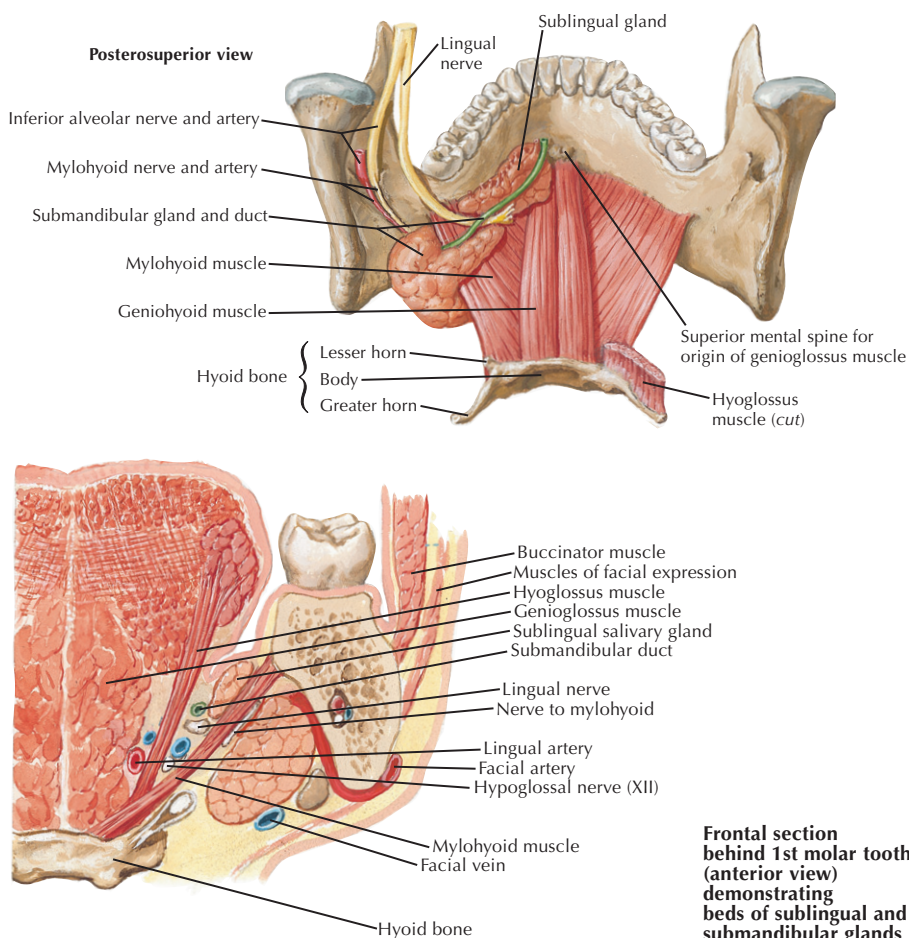
## INFERIOR BORDER: FLOOR OF THE ORAL CAVITY

Structure	Comments
Floor	Inferior border of the oral cavity Located along the lingual border of the mandible forming a horseshoe-shaped region
Tongue	Largest structure in the floor
Lingual frenulum	A midline fold of tissue located at the base of the tongue and extends along the inferior surface of the tongue
Mucous membrane	Stratified squamous epithelium that extends from the tongue to the mandible
Sublingual papilla	A swelling located on both sides of the lingual frenulum at the base of the tongue Marks the entrance of the saliva from the submandibular glands into the oral cavity Continuous with the sublingual folds overlying the sublingual glands on the floor of the oral cavity
Submandibular duct	Lies along the sublingual gland
Lingual n.	Crosses the submandibular duct passing lateral, inferior, and medial to the duct to reach the tongue
Plica fimbriata	Fimbriated folds located lateral to the lingual frenulum
Mylohyoid m.	Forms the muscular sling of the floor of the oral cavity Passes from the mylohyoid line of the mandible to the opposite mylohyoid m. in the midline at the mylohyoid raphe and attaches posteriorly to the hyoid bone
Geniohyoid mm.	Lie superior to the mylohyoid mm. Attach from the inferior genial tubercles of the mandible to the hyoid bone

# Boundaries of the Oral Cavity

## INFERIOR BORDER: FLOOR OF THE ORAL CAVITY *CONTINUED*

MUSCLES OF THE FLOOR OF THE ORAL CAVITY					
Muscle	Origin	Insertion	Actions	Nerve Supply	Comment
Mylohyoid	Mylohyoid line of the mandible	Symphysis menti Mylohyoid raphe Body of the hyoid bone	Raises the floor of the oral cavity Can elevate the hyoid bone	Mylohyoid n. from the inferior alveolar branch of the mandibular division of the trigeminal n.	Forms the sling of the oral cavity
Geniohyoid	Inferior genial tubercle	Body of the hyoid bone	Elevates the hyoid bone	C1 ventral ramus, which follows the hypoglossal n.	Superior to the mylohyoid m.

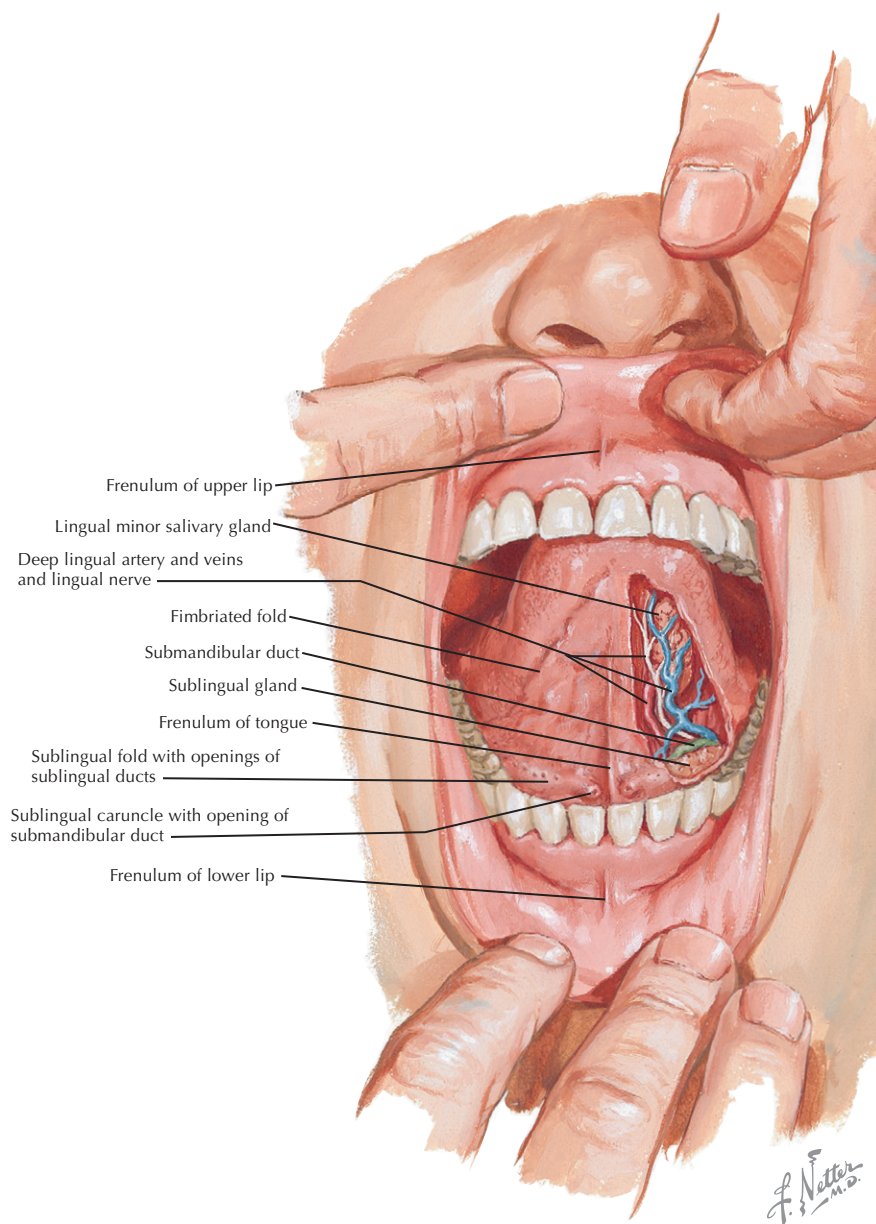


*F. Netter M.D.*



## 13 Boundaries of the Oral Cavity

### INFERIOR BORDER: FLOOR OF THE ORAL CAVITY *CONTINUED*





# Teeth

## GENERAL INFORMATION

Teeth are hard structures attached to the jaws and involved primarily in eating

2 arches contain the teeth:

- Maxillary arch
- Mandibular arch

Humans have 2 sets of teeth during a lifetime:

- Deciduous teeth—the primary dentition
- Permanent teeth—the secondary dentition

Between the ages of 6 and 12 years, there is a mixed dentition, in which both primary and permanent teeth are present in the oral cavity at the same time

### *Deciduous Teeth*

There are 20 total deciduous teeth: 2 incisors, 1 canine, and 2 molars in each of the 4 quadrants of the oral cavity

The primary dentition is represented by the formula  $I_{\frac{1}{2}}C_{\frac{1}{1}}M_{\frac{2}{2}}$ , which specifies the total number of teeth (10) on each side of the oral cavity

No deciduous teeth are present at birth; however, by the 3rd year of life, all 20 deciduous teeth have erupted

### *Permanent Teeth*

There are 32 total permanent teeth: 2 incisors, 1 canine, 2 premolars, and 3 molars in each of the 4 quadrants of the oral cavity

The permanent dentition is represented by the formula  $I_{\frac{1}{2}}C_{\frac{1}{1}}P_{\frac{2}{2}}M_{\frac{3}{3}}$ , which specifies the total number of teeth (16) on each side of the oral cavity

The first permanent tooth to erupt into the oral cavity normally is the mandibular 1st molar

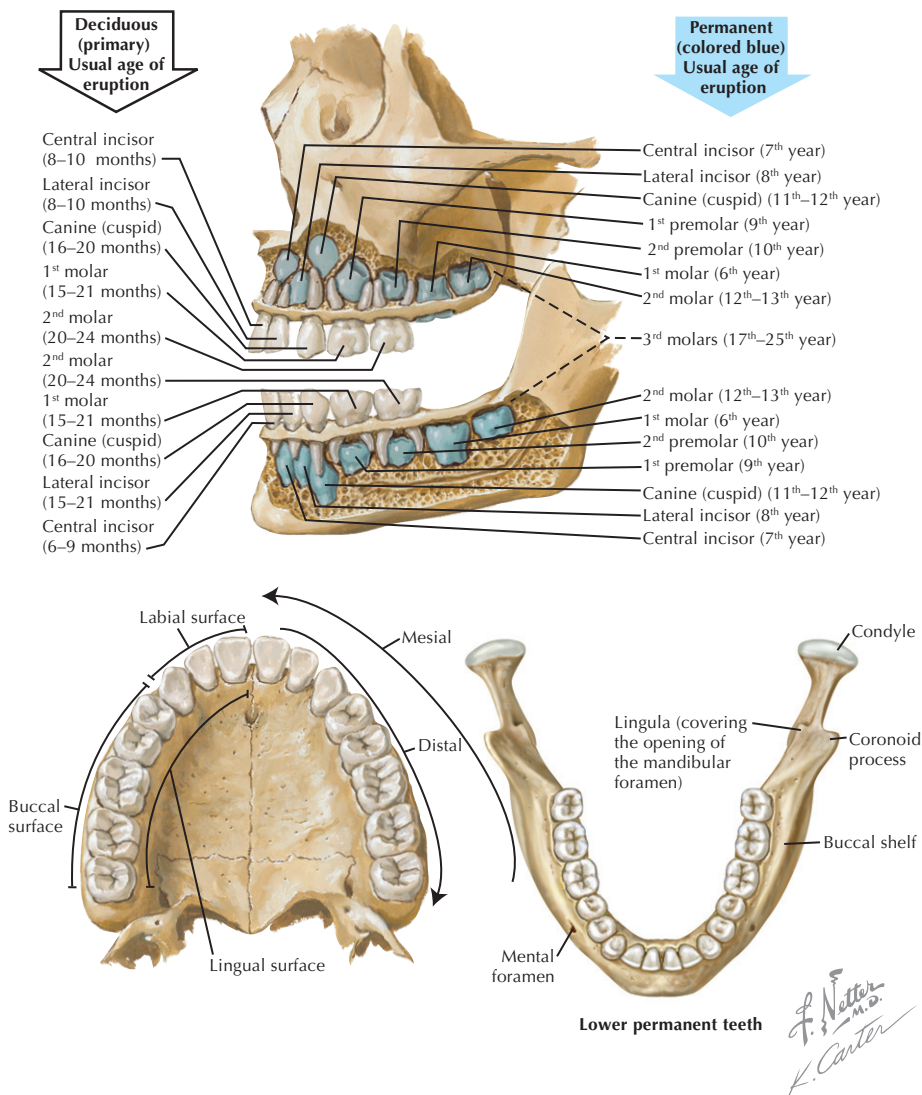
- This eruption occurs at about 6 years of age
- It erupts distal to the primary dentition

The primary teeth eventually are replaced by the permanent teeth

The replacement teeth are termed succedaneous teeth

## SURFACES OF A TOOTH

Labial	The surface of the anterior teeth that is closest to the lip
Buccal	The surface of the posterior teeth that is closest to the cheek
Facial	Used as a synonym for labial or buccal
Lingual	Opposite the tongue in the mandibular arch and opposite the hard palate of the maxillary arch
Mesial	Closest to the midline of the dental arch
Distal	Farthest from the midline of the dental arch
Occlusal	Used for chewing in posterior teeth
Incisal	The cutting edge of anterior teeth

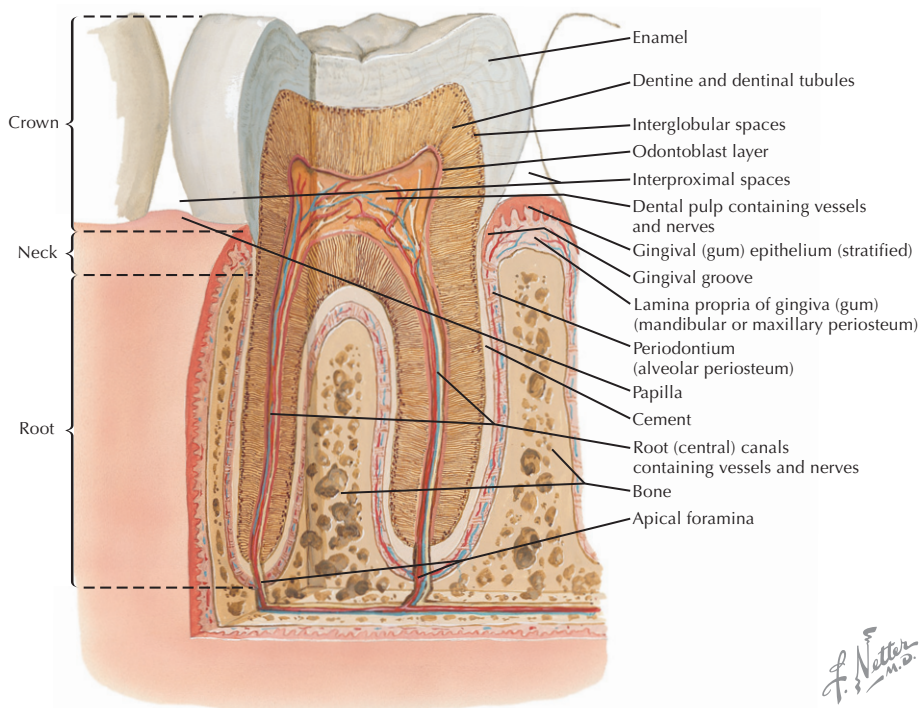
SURFACES OF A TOOTH *CONTINUED*

## BASIC ANATOMY OF A TOOTH

Crown	<i>Anatomic crown:</i> the portion of the tooth that has a surface of enamel <i>Clinical crown:</i> the portion of the tooth that is exposed within the oral cavity
Root	<i>Anatomic root:</i> the portion of the tooth that has a surface of cementum <i>Clinical root:</i> the portion of the tooth that is entrenched within the maxilla or mandible and is not exposed to the oral cavity
Apex of the root	The end tip of the root, which also is the location of a small aperture at the point of each root, which provides an entrance for the neurovascular connective tissue into the pulp cavity

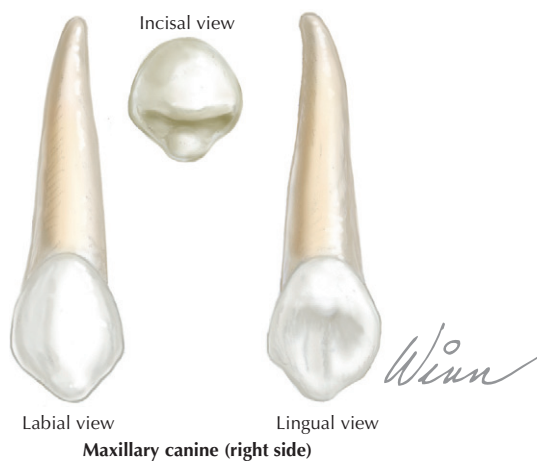
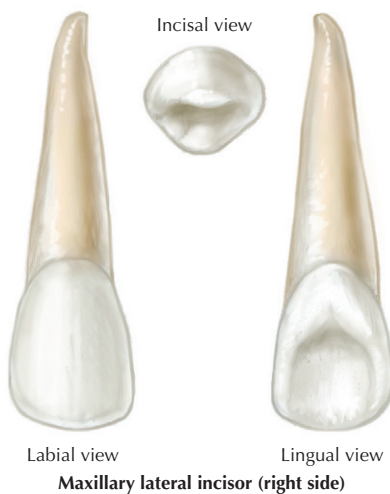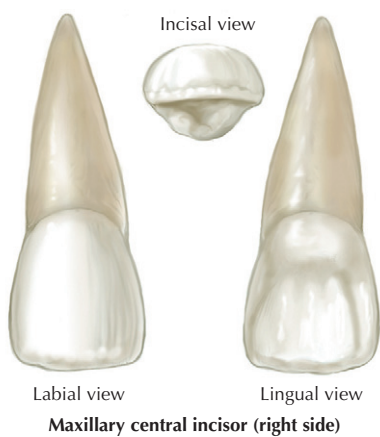
**BASIC ANATOMY OF A TOOTH** *CONTINUED*

Cervical line	The anatomic demarcation between the crown and the root It often is termed the cementoenamel junction (CEJ)
Enamel	The hard, shiny surface of the anatomic crown The hardest portion of the tooth Made of small hexagonal rods, called enamel prisms, that are parallel to one another
Cementum	A thin, dull layer on the surface of the anatomic root Similar in structure and chemical composition to bone With age, cementum increases in thickness
Dentin	The hard tissue that underlies both the enamel and cementum and constitutes the major portion of the tooth A modification of osseous tissue Composed of a number of dental tubules (small wavy and branching tubes) that are located in a dense matrix
Cusp	An elevation on the occlusal surface of molars and premolars that makes up a divisional part of the tooth The incisal edge of canines is referred to as a cusp and is used for prehension (grasping and tearing) of food
Pulp cavity	Contains the dental pulp (highly neurovascular connective tissue) Separated into the <i>pulp chamber</i> , located in the coronal portion of the tooth, and the <i>pulp canal</i> , located in the root portion of the tooth
Cingulum	A convex elevation that is located on the lingual surface of the crowns of anterior teeth just incisal to the CEJ



## TYPES OF TEETH IN THE PERMANENT DENTITION

MAXILLARY INCISORS				
Tooth	Crown	Surfaces	Root(s)	Comments
Central incisor	The widest of all of the anterior teeth, nearly as wide as it is long <i>Cingulum</i> : well-developed	From a labial view, the distal surface is more convex than the mesial surface <i>Mamelons</i> : 3 elevations on the incisal edge of anterior teeth that denote centers of formation Observed in central incisors before they are worn away during function	1 conical root that is triangular in cross section	Incisors are cutting teeth
Lateral incisor	More narrow than the central incisor in a mesial-to-distal measurement	<i>Labial surface</i> : convex <i>Incisal edges</i> on the mesial and distal surfaces: more convex than central incisors <i>Mamelons</i> : tend to be less prominent on the lateral incisor <i>Lingual surface</i> : more concave than on the central incisors <i>Mesial and distal marginal ridges</i> more prominent than central incisor and typically demonstrate a lingual pit	One conical root that is oval in cross section	
MAXILLARY CANINE				
Tooth	Crown	Surfaces	Root(s)	Comments
Canine	<i>Cingulum</i> : prominent	<i>Labial surface</i> : convex <i>Incisal edge</i> : rounded into a cusp that displays a mesial and distal cusp ridge <i>Lingual surface</i> : exhibits a strong ridge from the cusp tip to the cingulum, which divides the lingual surface into a mesial and a distal fossa	1 long and conical root that is rectangular in cross section, with depressions on the mesial and distal surfaces	Also called cuspid; longest tooth in the oral cavity Prehensile tooth

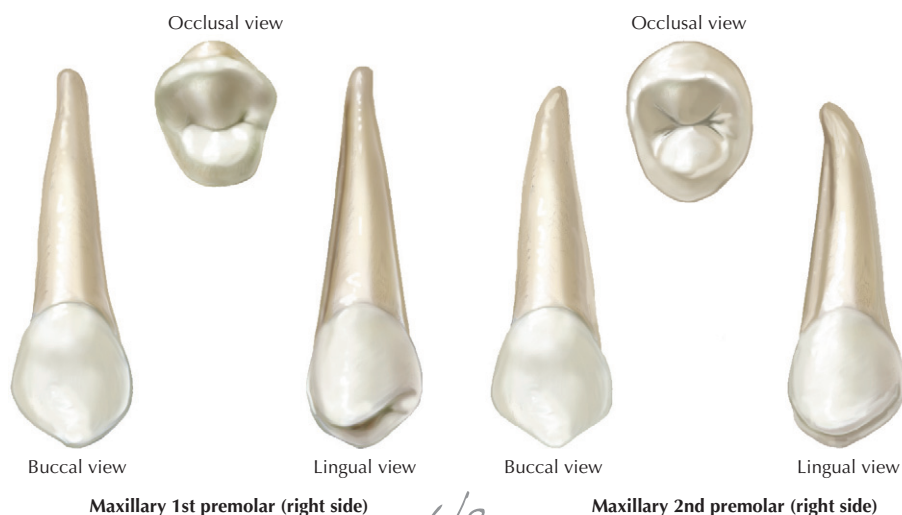
**TYPES OF TEETH IN THE PERMANENT DENTITION** *CONTINUED*



# 13 Teeth

## TYPES OF TEETH IN THE PERMANENT DENTITION *CONTINUED*

MAXILLARY PREMOLARS				
Tooth	Crown	Surfaces	Root(s)	Comments
1st premolar	Shorter than the anterior teeth Wider in a facial-lingual dimension than in a mesial-distal dimension	Has a lingual and a facial cusp <i>Facial surface:</i> convex <i>Facial cusp:</i> long and similar in appearance to the cusp of the canine <i>Lingual cusp:</i> shorter than the facial cusp and positioned mesial of the mesial distal midline Displays a mesial marginal developmental groove	Usually 2 roots—a facial and a lingual root	Often referred to as bicuspid teeth, but a more accepted designation would be premolar teeth Prehensile tooth
2nd premolar	Not as angular in shape as the 1st premolar	<i>Facial surface:</i> convex Has a lingual and a facial cusp • <i>Facial cusp:</i> not as sharp as the facial cusp of the 1st premolar • <i>Lingual cusp:</i> nearly equal in size and similar in shape to the facial cusp	Usually 1 root	Occlusal surface contains supplemental grooves, which gives it a wrinkled appearance Supplements the molars in function

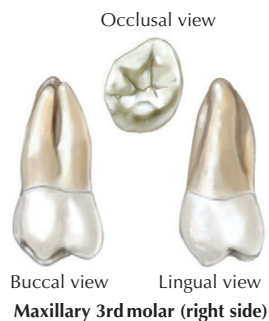
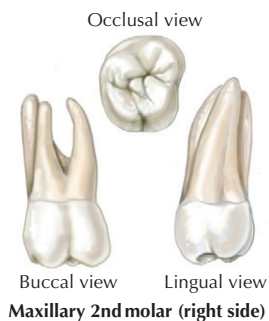
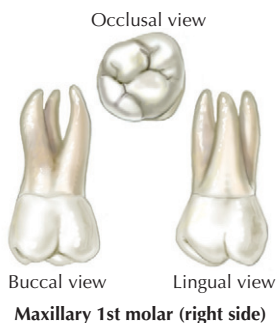


*Winn*

## Teeth

TYPES OF TEETH IN THE PERMANENT DENTITION *CONTINUED*

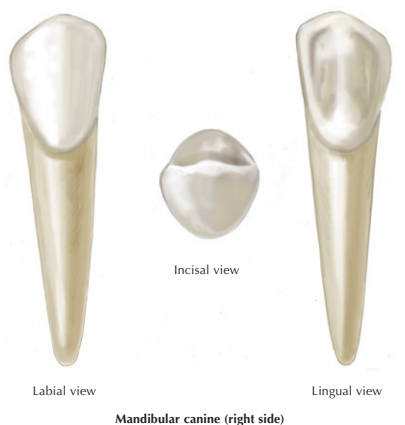
MAXILLARY MOLARS				
Tooth	Crown	Surfaces	Root(s)	Comments
The molar teeth are used for crushing and chewing				
1st molar	Larger in a facial-lingual dimension than it is in a mesial-distal dimension From an occlusal view, the crown is rhomboidal in form	5 cusps: <ul style="list-style-type: none"> <li>• Mesio Buccal cusp</li> <li>• Distobuccal cusp</li> <li>• Mesio lingual cusp</li> <li>• Distolingual cusp</li> <li>• 5th cusp: present on the lingual surface of the mesio lingual cusp and termed the cusp of Carabelli</li> </ul>	3 roots: <ul style="list-style-type: none"> <li>• Mesio Buccal root</li> <li>• Distobuccal root (smallest)</li> <li>• Lingual root (largest)</li> </ul>	Usually the largest of the molar teeth
2nd molar	Supplements the 1st molar in function 2 forms: <ul style="list-style-type: none"> <li>• Resembles the 1st molar with a more extreme rhomboidal form</li> <li>• A heart-shaped form with a poorly developed distolingual cusp</li> </ul>	4 cusps: <ul style="list-style-type: none"> <li>• Mesio Buccal cusp</li> <li>• Distobuccal cusp</li> <li>• Mesio lingual cusp</li> <li>• Distolingual cusp (sometimes absent)</li> </ul> There is no fifth cusp	3 roots: <ul style="list-style-type: none"> <li>• Mesio Buccal root</li> <li>• Distobuccal root</li> <li>• Lingual root</li> </ul>	Smaller than the 1st molar
3rd molar	Great variation in the crown (it may resemble the 1st or 2nd molar)	3-cusp form is more common: <ul style="list-style-type: none"> <li>• Mesio Buccal cusp</li> <li>• Distobuccal cusp</li> <li>• Mesio lingual cusp</li> </ul>	3 roots: <ul style="list-style-type: none"> <li>• Mesio Buccal root</li> <li>• Distobuccal root</li> <li>• Lingual root</li> </ul> The roots usually are fused, functioning as 1 large root	Variable in size Often extracted as a preventive measure



*Winn*

TYPES OF TEETH IN THE PERMANENT DENTITION *CONTINUED*

MANDIBULAR CANINE				
Tooth	Crown	Surfaces	Root(s)	Comments
Canine	Longer than the maxillary canine <i>Cingulum</i> : not as prominent as on the maxillary canine	<i>Incisal edge</i> : rounded into a cusp <i>Mamelons</i> : not usually located on canine teeth <i>Mesial surface</i> of crown and root: relatively straight, without much convexity	1 long and conical root	Also called cuspids Smaller and more symmetrical than the maxillary canine

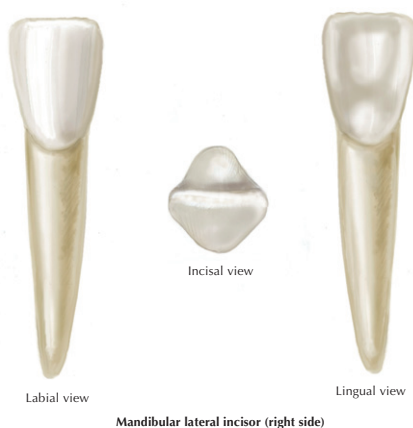
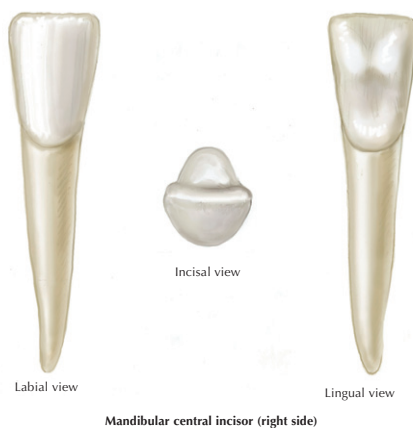


Mandibular canine (right side)

Winn

**TYPES OF TEETH IN THE PERMANENT DENTITION** *CONTINUED*

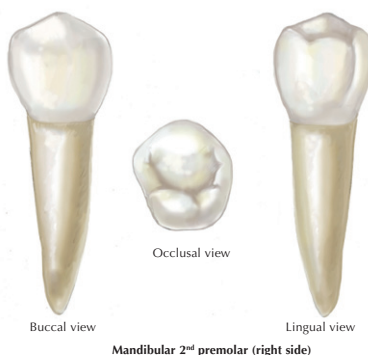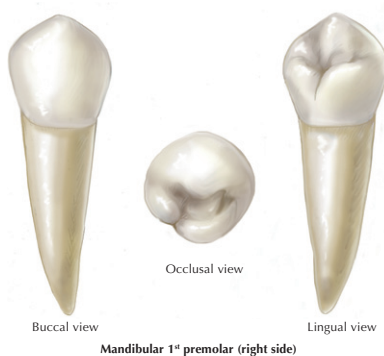
MANDIBULAR INCISORS				
Tooth	Crown	Surfaces	Root(s)	Comments
Central incisor	2/3 the width of the maxillary central incisor Appears bilaterally symmetrical <i>Cingulum</i> : small and poorly developed	<i>Labial surface</i> : convex <i>Lingual surface</i> : concave <i>Mamelons</i> : observed in central incisors before wear <i>Lingual fossa</i> : poorly developed	1 root that is flattened and is wide in a facial-lingual direction	Incisors are cutting teeth
Lateral incisor	Not bilaterally symmetrical	<i>Labial surface</i> : convex <i>Lingual fossa</i> : poorly developed	1 root similar in shape to the central incisor	When viewed from the incisal aspect, the crown appears twisted distally on the root Incisors are cutting teeth



*Winn*

TYPES OF TEETH IN THE PERMANENT DENTITION *CONTINUED*

MANDIBULAR PREMOLARS				
Tooth	Crown	Surfaces	Root(s)	Comments
1st premolar	Diamond-shaped	<i>Facial surface:</i> convex Has a lingual and a buccal cusp <ul style="list-style-type: none"> <li>• Buccal cusp—well developed</li> <li>• Lingual cusp—small and not well developed</li> </ul> Displays a mesial lingual developmental groove	1 root that is oval in cross section, with a slight lingual taper	The smallest of the premolar teeth
2nd premolar	Convex	Demonstrates either of 2 occlusal schemes: <ul style="list-style-type: none"> <li>• A 2-cusp form, with a facial and a lingual cusp</li> <li>• A 3-cusp form, with 2 lingual cusps and a single facial cusp—predominant form</li> </ul> Facial and lingual surfaces are convex <i>Facial cusp</i> is not as sharp as that of the 1st premolar <i>Lingual cusp(s)</i> are smaller than the facial cusp	1 root that is oval in cross section, with a slight lingual taper	Differs in appearance from the 1st premolar Much larger than the 1st premolar

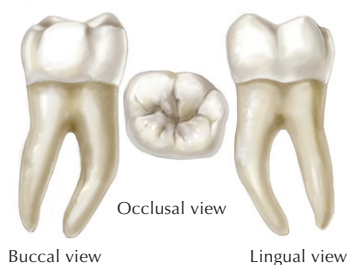
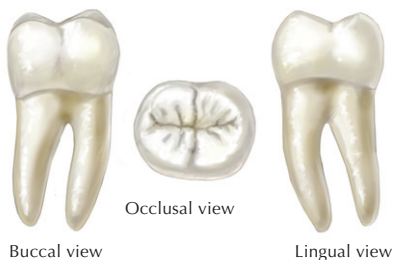
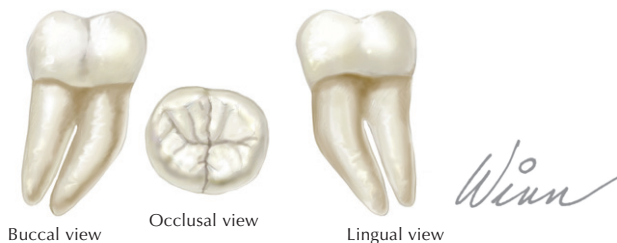


*Winn*



**TYPES OF TEETH IN THE PERMANENT DENTITION** *CONTINUED*

MANDIBULAR MOLARS				
Tooth	Crown	Surfaces	Root(s)	Comments
1st molar	Wider in a mesial-distal dimension than in a facial-lingual length	5 cusps: <ul style="list-style-type: none"> <li>• Mesio Buccal cusp (largest)</li> <li>• Distobuccal cusp</li> <li>• Distal cusp (smallest)</li> <li>• Mesio lingual cusp</li> <li>• Distolingual cusp</li> </ul>	2 roots: <ul style="list-style-type: none"> <li>• Mesial root (containing 2 pulp canals)</li> <li>• Distal root (containing 1 pulp canal)</li> </ul>	Used for crushing and chewing
2nd molar	Normally the 2nd molar is smaller than the 1st molar	4 cusps: <ul style="list-style-type: none"> <li>• Mesio Buccal cusp</li> <li>• Distobuccal cusp</li> <li>• Mesio lingual cusp</li> <li>• Distolingual cusp</li> </ul>	2 roots: <ul style="list-style-type: none"> <li>• Mesial root (containing 2 pulp canals)</li> <li>• Distal root (containing 1 pulp canal)</li> </ul>	Supplements the 1st molar in function
3rd molar	Development is similar to that of the 2nd molar	4 cusps of variable shape and size	2 roots: <ul style="list-style-type: none"> <li>• Mesial root</li> <li>• Distal root</li> </ul> Roots are often fused	Variable, but not as variable as the maxillary 3rd molar Often the smallest of the molar teeth Often extracted as a preventive measure

**Mandibular 1<sup>st</sup> molar (right side)****Mandibular 2<sup>nd</sup> molar (right side)****Mandibular 3<sup>rd</sup> molar (right side)**

# 13 Vascular Supply of the Oral Cavity

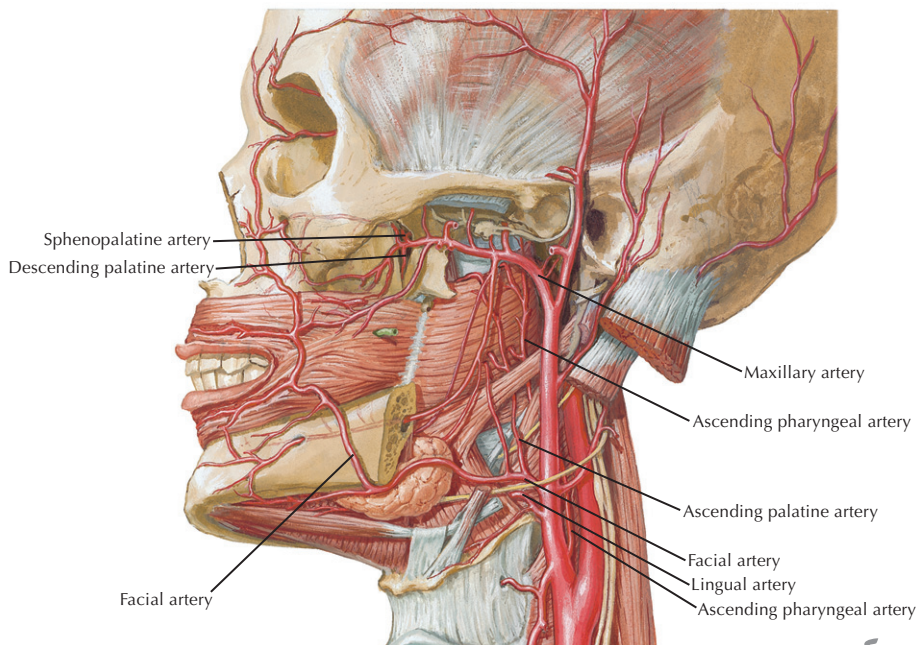
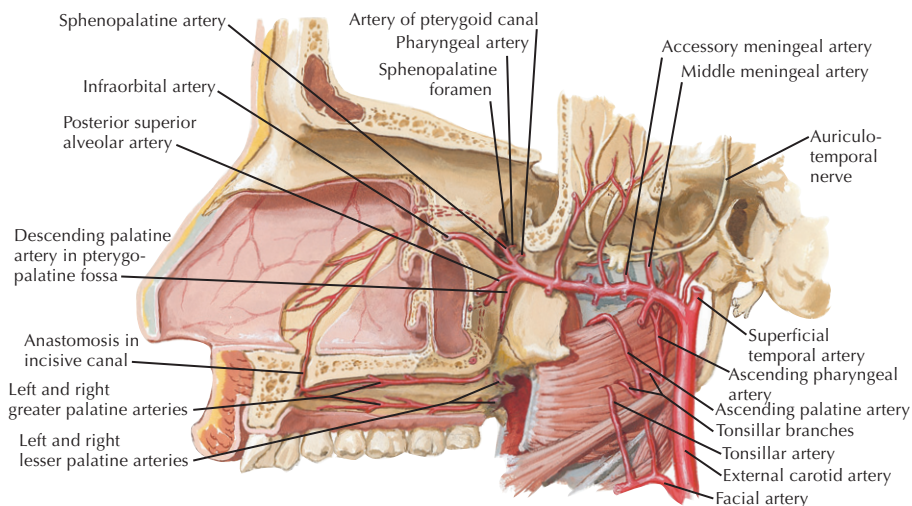
## ARTERIAL SUPPLY

ARTERIAL SUPPLY OF THE PALATE		
Artery	Source	Course
Maxillary	External carotid a.	<p>Gives rise to a series of branches; 3 supply the palate:</p> <ul style="list-style-type: none"> <li>• Sphenopalatine</li> <li>• Greater palatine</li> <li>• Lesser palatine</li> </ul> <p>Gives rise to 3 branches that supply the maxillary arch:</p> <ul style="list-style-type: none"> <li>• Anterior superior alveolar</li> <li>• Middle superior alveolar</li> <li>• Posterior superior alveolar</li> </ul> <p>Gives rise to 1 branch that supplies the mandibular arch:</p> <ul style="list-style-type: none"> <li>• Inferior alveolar</li> </ul>
Sphenopalatine	3rd part of the maxillary a.	<p>Enters the nasal cavity after passing through the sphenopalatine foramen</p> <p>On entering the nasal cavity, gives rise to the posterior superior nasal branches:</p> <ul style="list-style-type: none"> <li>• Posterior superior lateral branch</li> <li>• Posterior superior medial branch, which continues along the nasal septum to enter the hard palate via the incisive canal</li> </ul>
Greater palatine	Descending palatine a. from the 3rd part of the maxillary a.	<p>A branch of the descending palatine a. that travels in the palatine canal</p> <p>Within the canal, the descending palatine a. splits into the:</p> <ul style="list-style-type: none"> <li>• Lesser palatine a.</li> <li>• Greater palatine a.</li> </ul> <p>The greater palatine a. exits the greater palatine foramen and passes anteriorly toward the incisive foramen to supply the hard palate gingiva, mucosa, and palatal glands and anastomose with the terminal branch of the sphenopalatine a., which exits the incisive foramen</p>
Lesser palatine	Descending palatine a. from the 3rd part of the maxillary a.	<p>A branch of the descending palatine a. that travels in the palatine canal</p> <p>Within the canal, the descending palatine a. splits into the:</p> <ul style="list-style-type: none"> <li>• Greater palatine a.</li> <li>• Lesser palatine a.</li> </ul> <p>Lesser palatine a. supplies the soft palate and palatine tonsil</p>
Facial	External carotid a.	<p>Arises in the carotid triangle of the neck</p> <p>Passes superiorly immediately deep to the posterior belly of the digastric m. and the stylohyoid m.</p> <p>Passes along the submandibular gland, giving rise to the submental a., which helps supply the gland</p> <p>Passes superiorly over the body of the mandible at the masseter</p>
Ascending palatine	Facial a.	<p>Supplies the soft palate</p> <p>Ascends between the styloglossus and stylopharyngeus mm. along the side of the pharynx</p> <p>Divides near the levator veli palatini m.</p> <p>A branch follows the levator veli palatini, supplying the soft palate and the palatine glands</p> <p>A 2nd branch pierces the superior constrictor m. to supply the palatine tonsil and auditory tube</p> <p>Anastomoses with the ascending pharyngeal and tonsillar aa.</p>
Ascending pharyngeal	External carotid a.	<p>Arises in the carotid triangle of the neck</p> <p>Lies deep to the other branches of the external carotid a. and under the stylopharyngeus m.</p> <p>Gives rise to pharyngeal, inferior tympanic, posterior meningeal, and palatine branches</p> <p>The palatine branch passes over the superior constrictor m. and sends branches to the soft palate, tonsil, and auditory tube</p>

# Vascular Supply of the Oral Cavity

13

## ARTERIAL SUPPLY *CONTINUED*

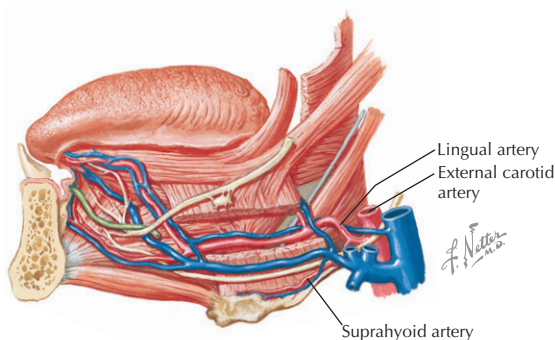


*F. Netter M.D.*

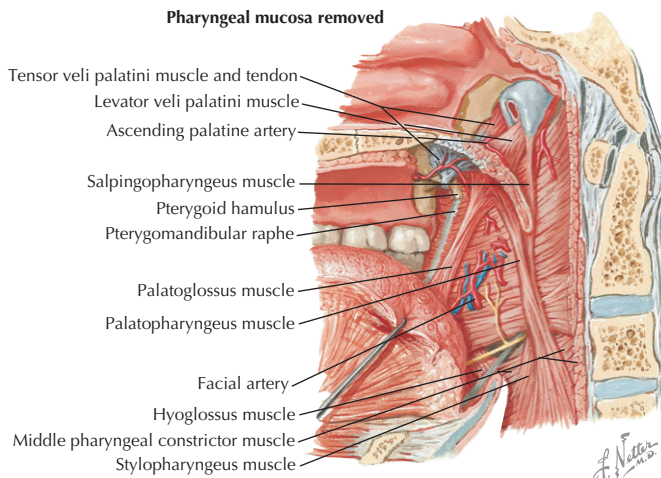
# 13 Vascular Supply of the Oral Cavity

## ARTERIAL SUPPLY *CONTINUED*

ARTERIAL SUPPLY OF THE FLOOR OF THE ORAL CAVITY		
Artery	Source	Course
Facial	External carotid a.	Arises in the carotid triangle of the neck Passes superiorly immediately deep to the posterior belly of the digastric m. and the stylohyoid m. Passes along the submandibular gland, giving rise to the submental a. that helps supply the gland Passes superiorly over the body of the mandible at the masseter m.
Ascending palatine	Facial a.	Supplies the soft palate Ascends between the styloglossus and stylopharyngeus mm. along the side of the pharynx Divides near the levator veli palatini m. A branch follows the levator veli palatini, supplying the soft palate and the palatine glands A 2nd branch pierces the superior constrictor m. to supply the palatine tonsil and auditory tube Anastomoses with the ascending pharyngeal and tonsillar aa.
Submental	Facial a.	Arises in the submandibular triangle of the neck Supplies the submandibular gland and surrounding muscles
Lingual	External carotid a.	Passes superiorly and medially toward the hyoid bone Curves inferiorly and anteriorly, forming a loop that lies on the middle constrictor m. and is passed superficially by the hypoglossal n. Passes deep to the posterior belly of the digastric m. and the stylohyoid m., traveling anteriorly Passes deep to the hyoglossus m. and ascends along the tongue Gives rise to dorsal lingual branches, a sublingual branch, and the deep lingual branch Sublingual branch begins at the anterior margin of the hyoglossus and travels anteriorly between the genioglossus and mylohyoideus mm. to supply the sublingual gland, surrounding muscles, and mucous membrane of the oral cavity and gingiva Deep lingual branch passes anteriorly under the surface of the tongue, then anastomoses with the opposite deep lingual a. at the tip of the tongue



## ARTERIAL SUPPLY *CONTINUED*

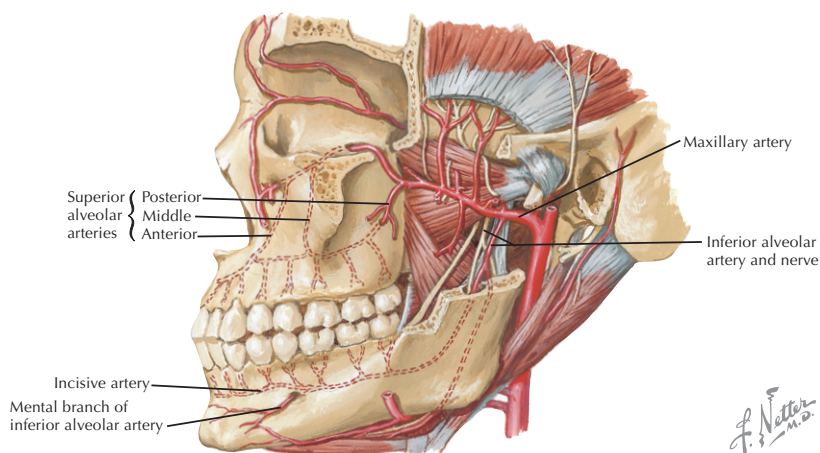


ARTERIAL SUPPLY OF THE MAXILLARY AND MANDIBULAR TEETH		
Artery	Source	Course
Maxillary	External carotid a.	Gives rise to 3 branches that form a plexus to supply the maxillary arch: <ul style="list-style-type: none"> <li>• Anterior superior alveolar</li> <li>• Middle superior alveolar</li> <li>• Posterior superior alveolar</li> </ul> Gives rise to 1 branch that supplies the mandibular arch: <ul style="list-style-type: none"> <li>• Inferior alveolar</li> </ul>
MAXILLARY TEETH		
Anterior superior alveolar	Infraorbital a. (of the maxillary a.)	Arises after the infraorbital a. passes through the inferior orbital fissure and into the infraorbital canal Descends via the alveolar canals to supply part of the maxillary arch Supplies the maxillary sinus and the anterior teeth
Middle superior alveolar	Infraorbital a.	May or may not be present If present, arises from the infraorbital a. of the maxillary after it passes through the inferior orbital fissure and into the infraorbital canal Descends via the alveolar canals to supply the maxillary sinus and supplies the plexus at the canine
Posterior superior alveolar	3rd part of the maxillary a.	Arises before the maxillary a. enters the pterygopalatine fossa Enters the infratemporal surface of the maxilla to supply the maxillary sinus, premolars, and molars
MANDIBULAR TEETH		
Inferior alveolar	3rd part of the maxillary a.	Descends inferiorly following the inferior alveolar n. to enter the mandibular foramen Terminates into the mental and incisive aa. at the region of the 2nd premolar Supplies all of the mandibular teeth
Mental	Inferior alveolar a.	Supplies the labial gingiva of the anterior teeth
Incisive	Inferior alveolar a.	Supplies the anterior teeth



# 13 Vascular Supply of the Oral Cavity

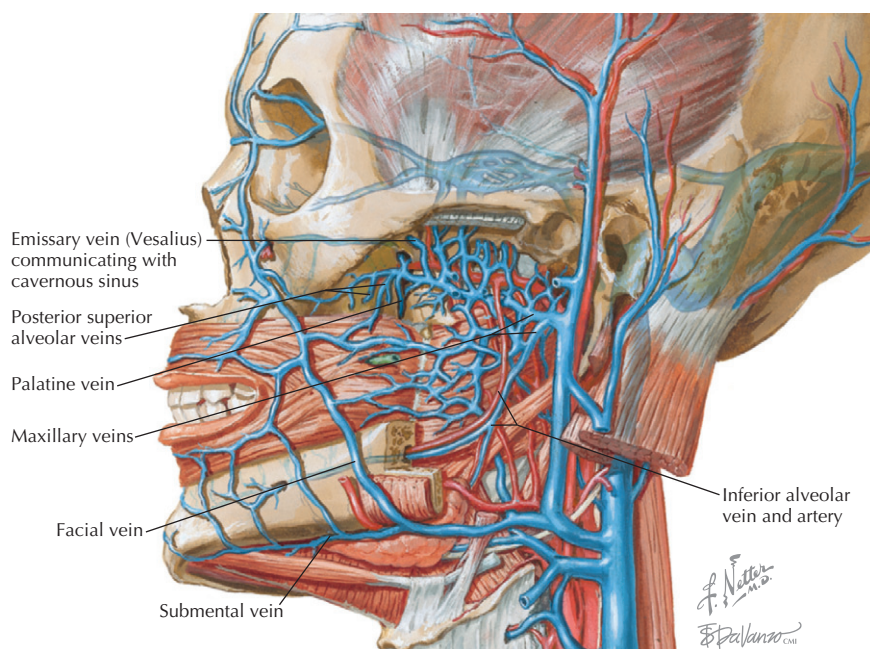
## ARTERIAL SUPPLY *CONTINUED*



## VENOUS DRAINAGE OF THE ORAL CAVITY

VENOUS DRAINAGE OF THE PALATE AND FLOOR OF THE ORAL CAVITY	
Vein	Course
Greater palatine	Connect to the pterygoid plexus
Lesser palatine	
Sphenopalatine	
Lingual	Receives tributaries from the deep lingual vv. on the ventral surface, and dorsal lingual vv. from the dorsal surface of the tongue Passes with the lingual a., deep to the hyoglossus m., and ends in the internal jugular v. The vena comitans nervi hypoglossi, or accompanying vein of the hypoglossal n., begins at the apex of the tongue and may either join the lingual v. or accompany the hypoglossal n. and enter the common facial v., which empties into the internal jugular v.
Submental	Anastomoses with the branches of the lingual v. and the inferior alveolar v. Parallels the submental a. on the superficial surface of the mylohyoid m. Ends in the facial v.
Pharyngeal plexus	Located along the lateral pterygoid m. Most of the vessels in the infratemporal fossa and oral cavity drain into the pterygoid plexus Connected to the cavernous sinus, the pterygoid plexus of veins, and the facial v. Valveless Eventually drains into the maxillary v.
VENOUS DRAINAGE OF THE TEETH	
Vein	Course
Anterior superior alveolar	Drain onto the pterygoid plexus of veins
Middle superior alveolar	
Posterior superior alveolar	
Inferior alveolar	

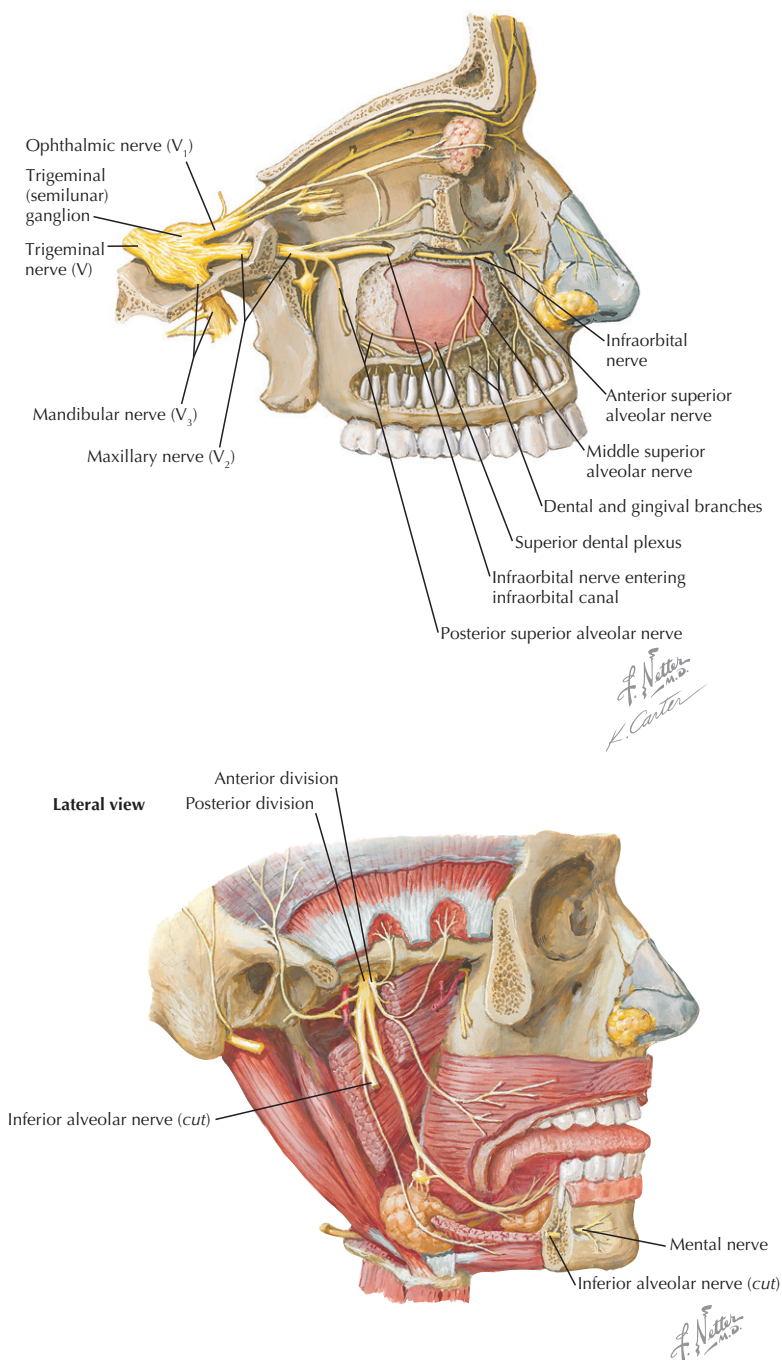
## VENOUS DRAINAGE OF THE ORAL CAVITY *CONTINUED*



# 13 Nerve Supply of the Oral Cavity

## GENERAL INFORMATION

The oral cavity receives its sensory innervation from branches of the maxillary and mandibular divisions of the trigeminal nerve



# Nerve Supply of the Oral Cavity

## SENSORY INNERVATION OF THE MAXILLARY TEETH

Nerve	Source	Course
Maxillary	Trigeminal n.	<p>Sensory in function            Travels along the lateral wall of the cavernous sinus            Passes from the middle cranial fossa into the pterygopalatine fossa via the foramen rotundum            Within the pterygopalatine fossa, it gives rise to 4 branches:</p> <ul style="list-style-type: none"> <li>• Infraorbital (continuation of the maxillary)</li> <li>• Ganglionic</li> <li>• Posterior superior alveolar</li> <li>• Zygomatic</li> </ul> <p>The infraorbital n. gives rise to 2 branches that form a plexus with the posterior superior alveolar to supply the maxillary arch:</p> <ul style="list-style-type: none"> <li>• Anterior superior alveolar</li> <li>• Middle superior alveolar</li> </ul>
Infraorbital	Continuation of the maxillary division of the trigeminal n.	<p>Passes through the inferior orbital fissure to enter the orbit            Passes anteriorly through the infraorbital groove and infraorbital canal and exits onto the face via the infraorbital foramen            Once the infraorbital n. exits onto the face, it divides into 3 terminal branches:</p> <ul style="list-style-type: none"> <li>• Nasal—supplies the ala of the nose</li> <li>• Inferior palpebral—supplies the skin of the lower eyelid</li> <li>• Superior labial—supplies the skin of the upper lip</li> </ul>
Anterior superior alveolar	Infraorbital n. as it travels in the infraorbital canal	As it descends to form the superior dental plexus, it innervates part of the maxillary sinus and generally the incisors and canines
Middle superior alveolar		<p>A variable nerve            As it descends to form the superior dental plexus, it innervates part of the maxillary sinus and the premolars and possibly the mesiobuccal root of the 1st molar</p>
Posterior superior alveolar	Maxillary n. in the pterygopalatine fossa	<p>Travels laterally through the pterygomaxillary fissure to enter the infratemporal fossa            Enters the infratemporal surface of the maxilla            As it descends to form the superior dental plexus, it innervates part of the maxillary sinus and the molars, with the possible exception of the mesiobuccal root of the 1st molar</p>

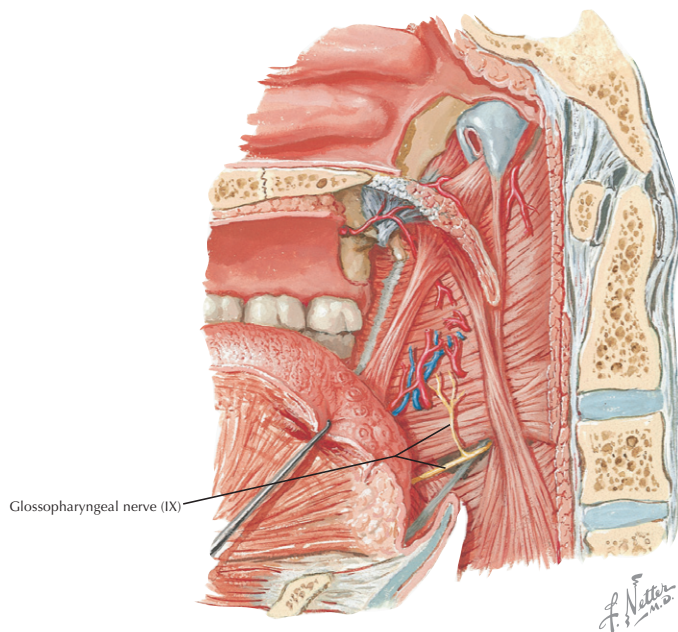
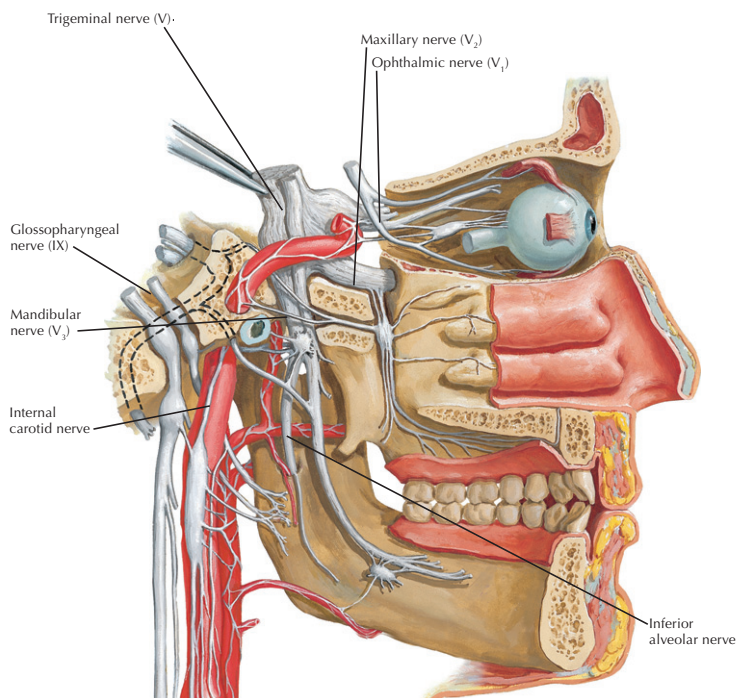
# 13 Nerve Supply of the Oral Cavity

## SENSORY INNERVATION OF THE MANDIBULAR TEETH

Nerve	Source	Course
Mandibular	Trigeminal n.	<p>This division has motor function in addition to sensory function</p> <p>The largest of the 3 divisions of the trigeminal n. Created by a large sensory and a small motor root that unite just after passing through the foramen ovale to enter the infratemporal fossa</p> <p>Immediately gives rise to a meningeal branch and divides into an anterior and a posterior division</p> <p>Anterior division is smaller and mainly motor, with 1 sensory branch (buccal):</p> <ul style="list-style-type: none"> <li>• Masseteric</li> <li>• Anterior and posterior deep temporal</li> <li>• Medial pterygoid</li> <li>• Lateral pterygoid</li> <li>• Buccal</li> </ul> <p>Posterior division is larger and mainly sensory, with 1 motor branch (mylohyoid):</p> <ul style="list-style-type: none"> <li>• Auriculotemporal</li> <li>• Lingual</li> <li>• Inferior alveolar</li> <li>• Mylohyoid</li> </ul>
Inferior alveolar	The largest branch of the mandibular division	<p>Descends following the inferior alveolar a. inferior to the lateral pterygoid and, last, between the sphenomandibular ligament and the ramus of the mandible until it enters the mandibular foramen, where it terminates as the mental and incisive nn. in the area of the 2nd premolar</p> <p>Innervates all mandibular teeth (via inferior alveolar and incisive nn.), periodontal ligaments (via inferior alveolar and incisive nn.), and the gingiva from the premolars anteriorly to the midline (via the mental branch)</p>
Mental	Inferior alveolar n.	Supplies the chin, lip, and facial gingiva and mucosa from the 2nd premolar anteriorly
Incisive		Supplies the teeth and periodontal ligaments from the 1st premolar anteriorly (depends on the location of the branching of the inferior alveolar n. into the incisive and mental nn.)



## SENSORY INNERVATION OF THE MANDIBULAR TEETH *CONTINUED*



# 13 Nerve Supply of the Oral Cavity

## FLOOR OF THE ORAL CAVITY

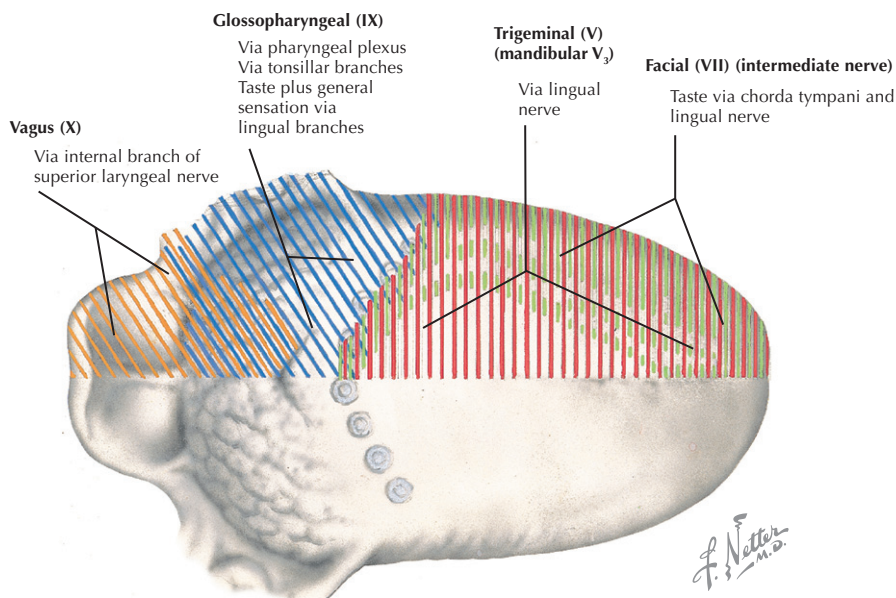
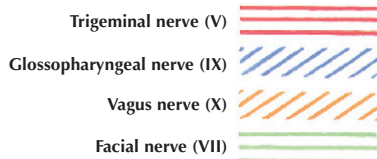
Nerve	Source	Course
Lingual	Mandibular division of the trigeminal n.	<p>Lies inferior to the lateral pterygoid and medial nn. and anterior to the inferior alveolar n. within the infratemporal fossa</p> <p>The chorda tympani branch of the facial n. also joins the posterior part of the lingual n.</p> <p>Passes between the medial pterygoid m. and the ramus of the mandible to pass obliquely to enter the oral cavity, bounded by the superior pharyngeal constrictor m., the medial pterygoid, and the mandible</p> <p>Enters the oral cavity lying against the lingual tuberosity of the mandible</p> <p>The submandibular ganglion is suspended from the lingual n. at the posterior border of the hyoglossus</p> <p>Continues anteriorly and passes on the lateral surface of the hyoglossus</p> <p>Passes from the lateral side, inferiorly, and medially to the submandibular duct to reach the mucosa of the tongue</p> <p>Supplies general somatic afferent (GSA) fibers to the mucous membrane and papilla of the anterior 2/3 of the tongue and gingiva and mucosa on the lingual side of the mandibular teeth</p>
Glossopharyngeal	Medulla oblongata	<p>Passes through the jugular foramen with the vagus and accessory nn.</p> <p>As it passes through the foramen, it passes between the internal carotid a. and the internal jugular v.</p> <p>Continues to pass inferiorly and travels posterior to the stylopharyngeus m.</p> <p>Passes anteriorly with the stylopharyngeus m. and travels between the superior and middle constrictor mm. to be located by the palatine tonsils</p> <p>Small lingual branches arise from it and distribute GSA fibers to the mucous membrane of the posterior 1/3 of the tongue, in addition to the pillars of the fauces</p> <p>In addition, small lingual branches arise from it and distribute special visceral afferent (SVA) fibers to the taste buds in the mucous membrane of the posterior 1/3 of the tongue and the circumvallate papillae</p>
Internal laryngeal	Superior laryngeal branch of the vagus n.	<p>Vagus n. branches from the medulla oblongata and passes through the jugular foramen with the glossopharyngeal and accessory nn.</p> <p>As the vagus n. passes through the foramen, it passes between the internal carotid a. and the internal jugular v.</p> <p>A series of nerves branch from the vagus in the neck, including the superior laryngeal n.</p> <p>Superior laryngeal n. travels inferiorly posterior to the internal carotid a. and on the side of the pharynx and divides into the internal and external laryngeal nn.</p> <p>Internal laryngeal n. passes inferiorly to the larynx and passes through the thyrohyoid membrane along with the superior laryngeal vessels</p> <p>Branches of the internal laryngeal n. distribute the GSA fibers to the base of the tongue at the epiglottic region and to the mucous membranes of the larynx as far inferiorly as the false vocal folds</p> <p>In addition, the branches distribute SVA fibers to the taste buds scattered at the base of the tongue at the epiglottic region</p>

# Nerve Supply of the Oral Cavity

13

## FLOOR OF THE ORAL CAVITY *CONTINUED*

Nerve	Source	Course
Chorda tympani	Facial n. in the tympanic cavity	Carries the preganglionic parasympathetic fibers to the submandibular ganglion and taste fibers to the anterior 2/3 of the tongue Passes anteriorly to enter the tympanic cavity and lies along the tympanic membrane and malleus until exiting the petrotympanic fissure Once it exits the petrotympanic fissure, the chorda tympani joins the posterior border of the lingual n. The lingual n. is distributed to the anterior 2/3 of the tongue and the SVA fibers from the chorda tympani travel to the taste buds in this region



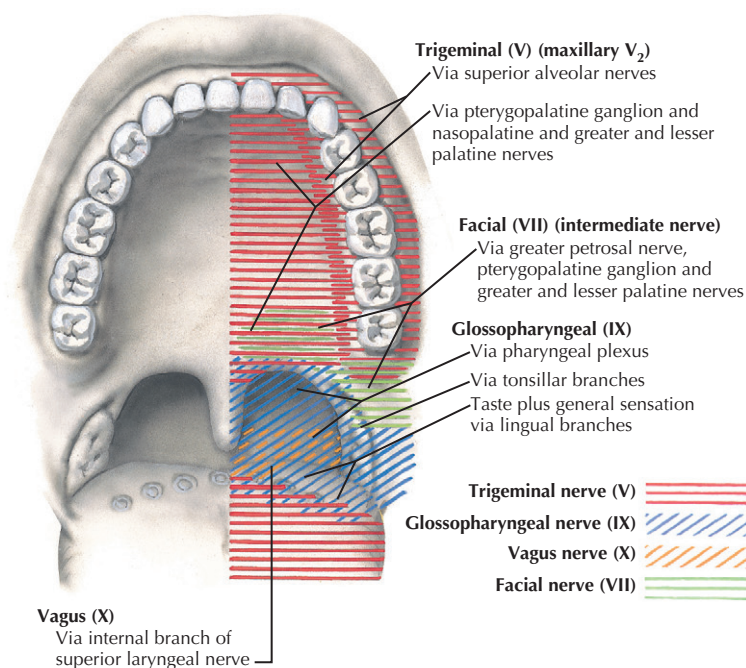
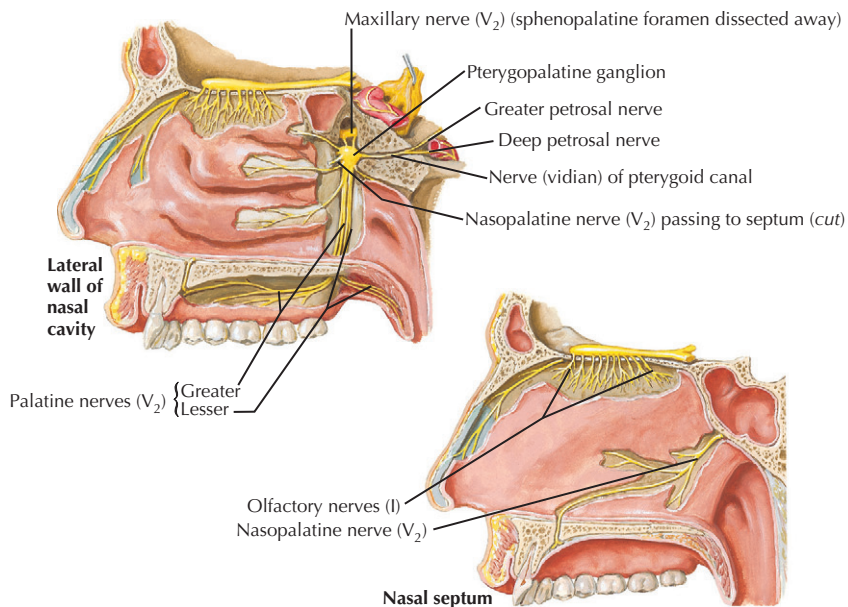
# 13 Nerve Supply of the Oral Cavity

## PALATE

Nerve	Source	Course
Maxillary	Trigeminal n.	<p>Sensory in function  Travels along the lateral wall of the cavernous sinus  Passes from the middle cranial fossa into the pterygopalatine fossa via the foramen rotundum  Within the pterygopalatine fossa, it gives rise to 4 branches:</p> <ul style="list-style-type: none"> <li>• Infraorbital (considered the continuation of the maxillary)</li> <li>• Ganglionic</li> <li>• Posterior superior alveolar</li> <li>• Zygomatic</li> </ul> <p>The infraorbital passes through the inferior orbital fissure to enter the orbit and passes anteriorly through the infraorbital groove and canal and exits onto the face via the infraorbital foramen  Once the infraorbital n. exits onto the face, it divides into 3 terminal branches:</p> <ul style="list-style-type: none"> <li>• Nasal—supplies the ala of the nose</li> <li>• Inferior palpebral—supplies the skin of the lower eyelid</li> <li>• Superior labial—supplies the skin of the upper lip; 3 of its branches form a plexus to supply the maxillary arch:</li> <li>• Anterior superior alveolar</li> <li>• Middle superior alveolar</li> <li>• Posterior superior alveolar</li> </ul>
Nasopalatine	Maxillary division of the trigeminal n. via the pterygopalatine ganglion in the pterygopalatine fossa	<p>Passes through the sphenopalatine foramen to enter the nasal cavity  Passes along the superior portion of the nasal cavity to the nasal septum, where it travels anteroinferiorly to the incisive canal supplying the septum  Once entering the oral cavity, it provides sensory innervation to the palatal gingiva and mucosa from the area anterior to the premolars</p>
Greater palatine		<p>Passes through the palatine canal to enter the hard palate via the greater palatine foramen  Provides sensory innervation to the palatal gingiva and mucosa from the premolars to the posterior border of the hard palate</p>
Lesser palatine		<p>Passes through the palatine canal to enter the hard palate via the lesser palatine foramen  Provides sensory innervation to the soft palate</p>
Glossopharyngeal	Medulla oblongata	<p>Passes through the jugular foramen with the vagus and accessory nn.  As it passes through the foramen, it passes between the internal carotid a. and internal jugular v.  Continues to pass inferiorly and travels posterior to the stylopharyngeus m.  Passes anteriorly with the stylopharyngeus and travels between the superior and middle constrictor mm. to be located by the palatine tonsils  Small lingual branches arise from it and distribute general somatic afferent fibers to the mucous membrane of the posterior 1/3 of the tongue, in addition to the pillars of the fauces</p>

# Nerve Supply of the Oral Cavity

## PALATE CONTINUED





## 13 Salivary Glands

### GENERAL INFORMATION

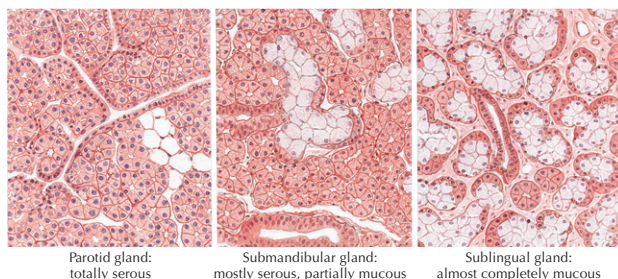
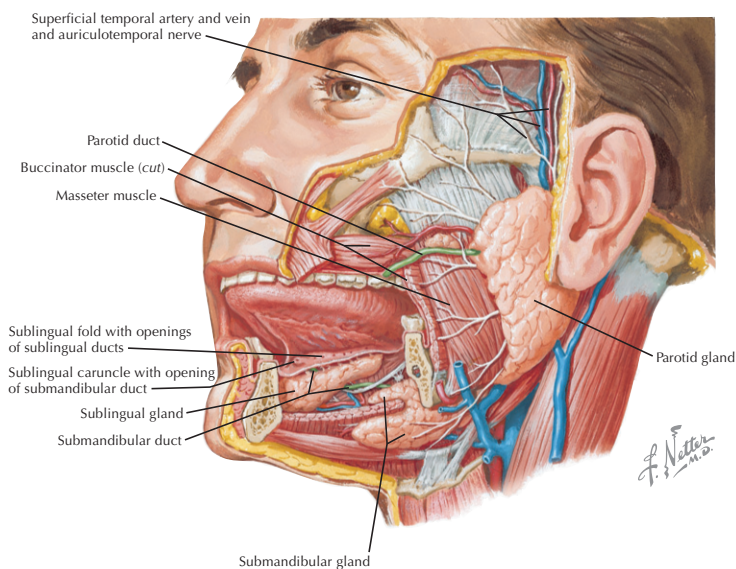
There are 3 pairs of major salivary glands:

- Parotid gland
- Submandibular gland
- Sublingual gland

They secrete saliva into the oral cavity to aid in the digestion, mastication, and deglutition of food

Saliva is mucous or serous in consistency

Many minor salivary glands are ubiquitously distributed throughout the oral mucosa of the oral cavity

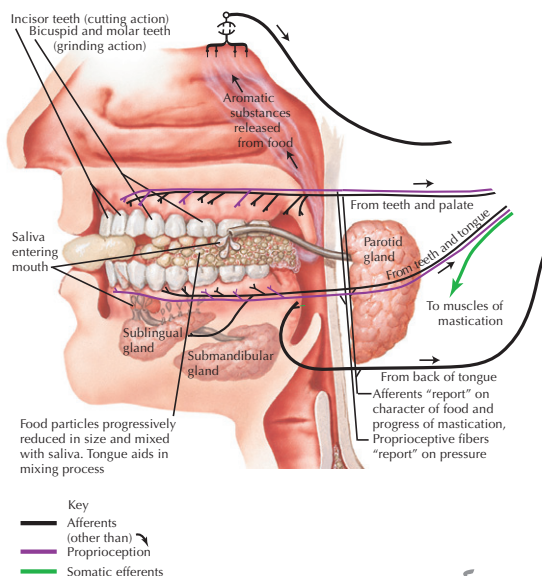


## GENERAL INFORMATION *CONTINUED*

FEATURES OF THE MAJOR SALIVARY GLANDS			
Gland	Duct	Comment	Autonomic Innervation
Parotid	Parotid duct (Stensen's duct)	<p>The largest salivary gland</p> <p>Pyramidal in shape, with up to 5 processes (or extensions)</p> <p>Saliva created by the parotid is serous</p> <p>Facial n. splits the parotid gland into a superficial lobe and a deep lobe, which are connected by an isthmus</p> <p>The parotid duct (Stensen's duct) forms within the deep lobe and passes from the anterior border of the gland across the masseter m. superficially, through the buccinator m. into the oral cavity opposite the 2nd maxillary molar</p>	Glossopharyngeal n.
Submandibular	Submandibular duct (Wharton's duct)	<p>2nd largest salivary gland</p> <p>A mixed salivary gland, secreting both serous and mucous saliva, but predominantly serous-secreting</p> <p>Wraps around the posterior border of the mylohyoid m., to be located in the submandibular triangle of the neck and the floor of the oral cavity</p> <p>The part of the submandibular gland located in the submandibular triangle is referred to as the superficial portion and is surrounded by the investing layer of deep cervical fascia</p> <p>Facial a. crosses between the submandibular gland and the mandible before giving off the submental a., while the facial v. normally lies superficial to the gland</p> <p>Deep portion of the submandibular gland lies in the oral cavity between the hyoglossus m. and the mandible and ends at the posterior border of the sublingual gland</p> <p>The submandibular duct lies along the sublingual gland and empties into the oral cavity at the sublingual papilla</p>	Facial n.
Sublingual	Numerous small ducts opening along the sublingual fold	<p>Smallest of the 3 major salivary glands</p> <p>A mixed salivary gland, secreting both mucous and serous saliva, but predominantly mucus-secreting</p> <p>Located in the oral cavity between the mucosa of the oral cavity and the mylohyoid m.</p> <p>Creates a sublingual fold in the floor of the oral cavity</p> <p>Lies between the sublingual fossa of the mandible and the genioglossus m. of the tongue</p> <p>The submandibular duct lies on the sublingual gland</p> <p>Bartholin's duct, a common duct that drains the anterior part of the gland in the region of the sublingual papilla, may be present</p>	

# 13 Salivary Glands

## GENERAL INFORMATION CONTINUED

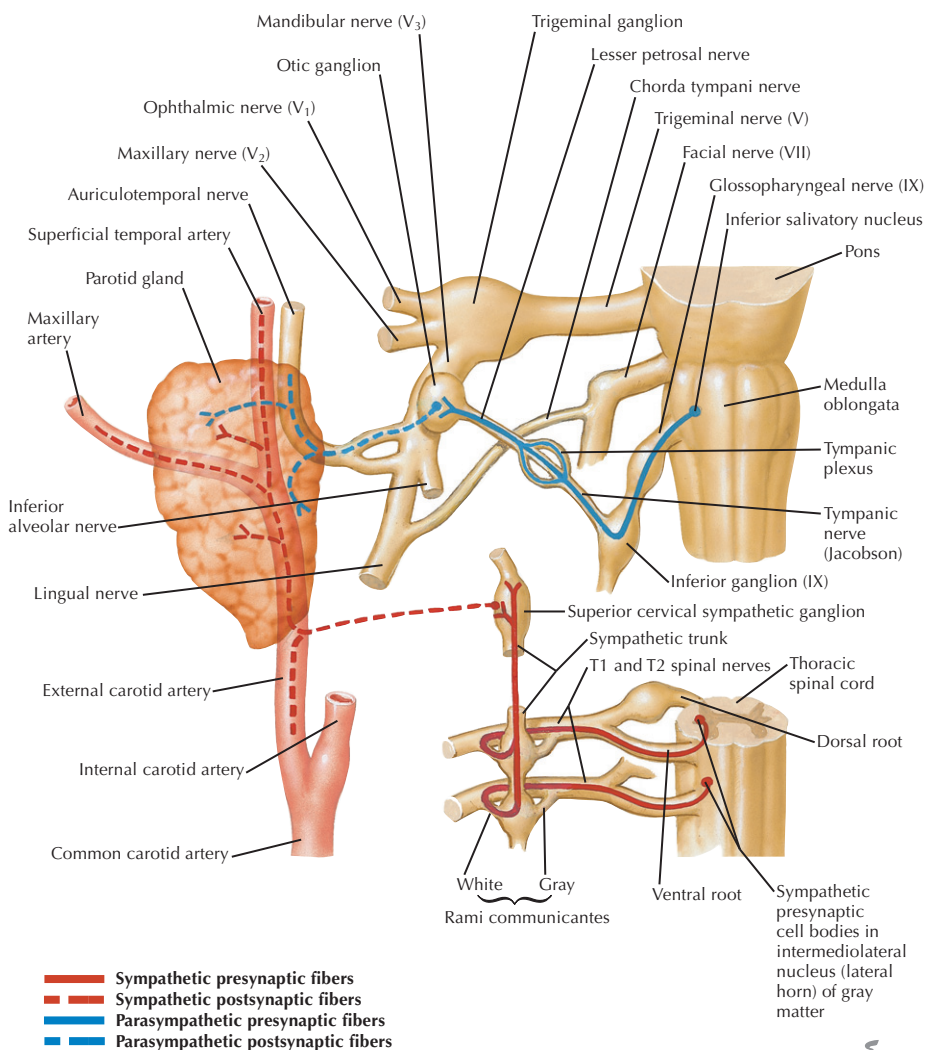


*J. Netter M.D.*

## AUTONOMICS OF THE SALIVARY GLANDS

PARASYMPATHETICS OF THE PAROTID GLAND			
Type of Neuron	Name of Cell Body	Characteristics of the Cell Body	Course of the Neuron
Preganglionic neuron	Inferior salivatory nucleus	A collection of nerve cell bodies located in the medulla	<p>Preganglionic parasympathetic fibers arise from the inferior salivatory nucleus in the medulla</p> <p>Travel through the glossopharyngeal n. and exit the jugular foramen</p> <p>Gives rise to the tympanic branch of cranial n. IX, which reenters the skull via the tympanic canaliculus</p> <p>The tympanic branch of IX forms the tympanic plexus along the promontory of the ear</p> <p>The plexus re-forms as the lesser petrosal n., typically exiting the foramen ovale to enter the infratemporal fossa</p> <p>Lesser petrosal n. joins the otic ganglion</p>
Postganglionic neuron	Otic ganglion	A collection of nerve cell bodies located inferior to the foramen ovale, medial to the mandibular division of the trigeminal	<p>Postganglionic parasympathetic fibers arise in the otic ganglion</p> <p>These fibers travel to the auriculotemporal branch of the trigeminal n.</p> <p>Auriculotemporal n. travels to parotid gland</p> <p>Postganglionic parasympathetic fibers innervate the:</p> <ul style="list-style-type: none"> <li>• Parotid gland</li> </ul>

## AUTONOMICS OF THE SALIVARY GLANDS *CONTINUED*



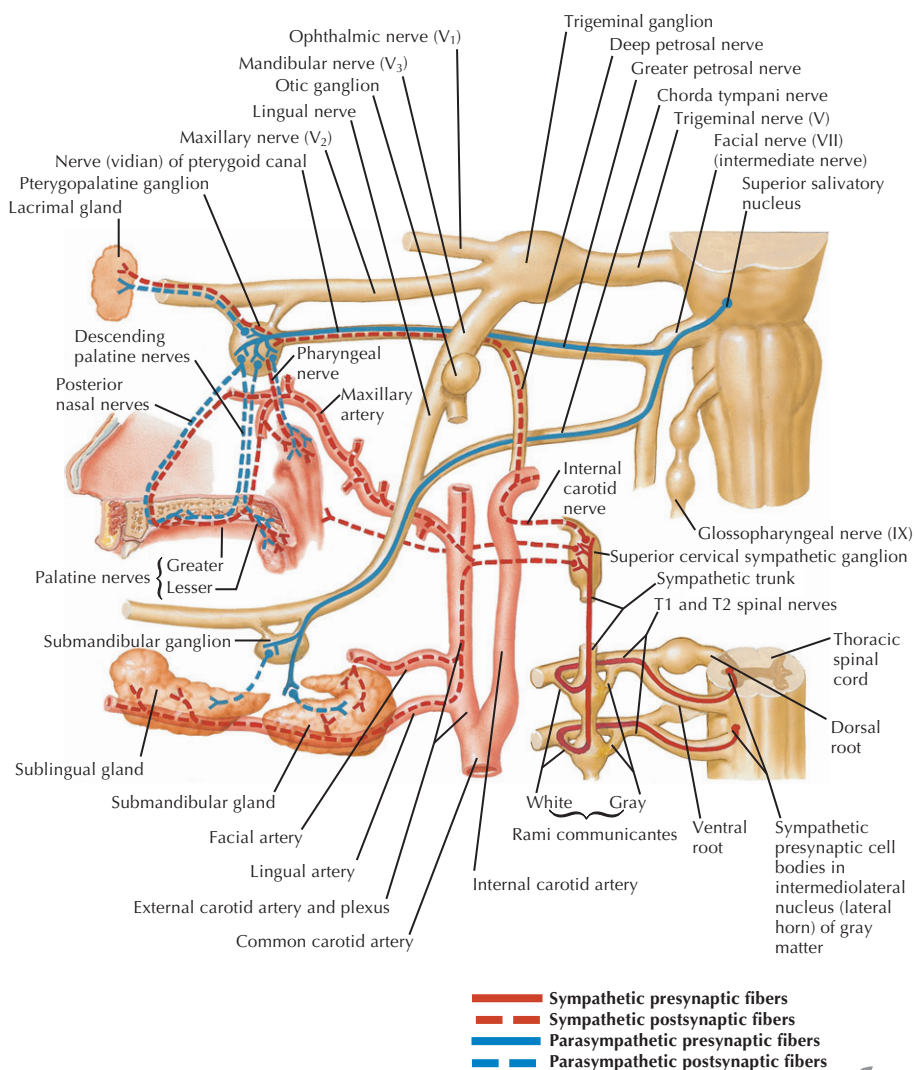
*F. Netter M.D.*

AUTONOMICS OF THE SALIVARY GLANDS *CONTINUED*

PARASYMPATHETICS OF THE SUBMANDIBULAR, SUBLINGUAL, AND MINOR SALIVARY GLANDS			
Type of Neuron	Name of Cell Body	Characteristics of the Cell Body	Course of the Neuron
Preganglionic neuron	Superior salivatory nucleus	<p>A collection of nerve cell bodies located in the pons</p> <p>Travel through the nervus intermedius of the facial n. into the internal acoustic meatus</p> <p>In the facial canal, the facial n. gives rise to 2 parasympathetic branches:</p> <ul style="list-style-type: none"> <li>• Greater petrosal n.</li> <li>• Chorda tympani n.</li> </ul>	<p><b>Greater Petrosal Nerve</b></p> <ul style="list-style-type: none"> <li>• Exits along the hiatus for the greater petrosal n. toward the foramen lacerum, where it joins the deep petrosal n. (sympathetics) to form the nerve of the pterygoid canal (vidian n.)</li> <li>• Vidian n. passes through the pterygoid canal and enters the pterygopalatine fossa, where it joins with the pterygopalatine ganglion</li> </ul> <p><b>Chorda Tympani Nerve</b></p> <ul style="list-style-type: none"> <li>• Exits the petrotympanic fissure to enter the infratemporal fossa, where it joins the lingual n.</li> <li>• Preganglionic fibers travel with the lingual n. into the floor of the oral cavity, where it joins with the submandibular ganglion</li> </ul>
Postganglionic neuron	Pterygopalatine ganglion	<p>A collection of nerve cell bodies located in the pterygopalatine fossa</p> <p>Postganglionic parasympathetic fibers that arise in the pterygopalatine ganglion are distributed to the ophthalmic and maxillary divisions of the trigeminal n. to the:</p> <ul style="list-style-type: none"> <li>• Lacrimal gland</li> <li>• Nasal glands</li> <li>• Palatine glands</li> <li>• Pharyngeal glands</li> </ul>	<p><b>Ophthalmic and Maxillary Division Distribution</b></p> <p>Postganglionic fibers travel along the zygomatic branch of the maxillary division for a short distance to enter the orbit</p> <p>A short communicating branch joins the lacrimal n. of the ophthalmic division of the trigeminal n.</p> <p>These fibers innervate:</p> <ul style="list-style-type: none"> <li>• Lacrimal gland, to cause the secretion of tears</li> </ul> <p><b>Maxillary Division Distribution</b></p> <p>Postganglionic fibers travel along the maxillary division of the trigeminal n. to be distributed along its branches that are located in the nasal cavity, oral cavity, and pharynx (e.g., nasopalatine, greater palatine)</p> <p>These fibers innervate:</p> <ul style="list-style-type: none"> <li>• Nasal glands</li> <li>• Palatine glands</li> <li>• Pharyngeal glands</li> </ul>
	Submandibular ganglion	<p>A collection of nerve cell bodies in the oral cavity</p> <p>Suspended from the lingual n. at the posterior border of the mylohyoid m. immediately superior to the deep portion of the submandibular gland</p>	<p>Postganglionic parasympathetic fibers arise in the submandibular ganglion and are distributed to the:</p> <ul style="list-style-type: none"> <li>• Submandibular gland</li> <li>• Sublingual gland</li> </ul>



## AUTONOMICS OF THE SALIVARY GLANDS *CONTINUED*



## 13 Clinical Correlate

### GINGIVITIS

*Gingivitis*: an inflammation of the gingiva that occurs when bacteria accumulate between the teeth and gingiva

In addition to the inflammation, the gums may demonstrate irritation and bleeding

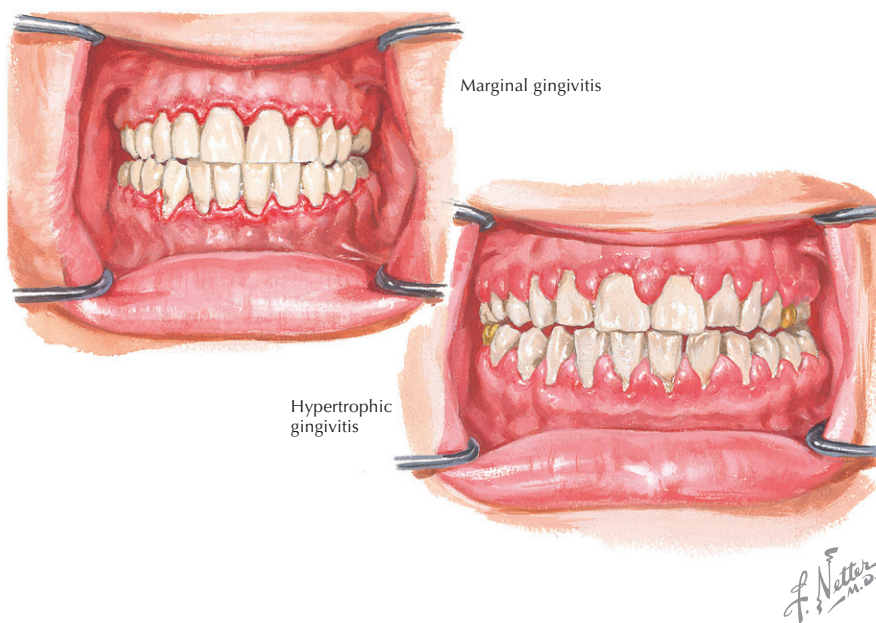
When plaque (composed of bacteria, food debris, and saliva) is deposited on the teeth, it can form tartar if it is not removed

Plaque and tartar cause irritation to the gingiva, and the bacteria (and their toxins) further irritate the gingiva, leading to bleeding and swelling

If gingivitis remains untreated, it may progress to more serious gingival diseases, such as periodontitis

Long-term untreated gingivitis may lead to damage of bone and loss of teeth

Risk factors for gingivitis include poor dental hygiene, pregnancy, diabetes, illness, and human immunodeficiency virus (HIV) infection



## Clinical Correlate

### DENTAL CARIES

Dental caries (tooth decay), leading to "cavities," is caused by bacteria in the oral cavity. The bacteria convert foods into acids and help form plaque (made of bacteria, food debris, and saliva), which is deposited on the teeth.

Plaque that is not removed from the teeth can mineralize to form tartar.

Plaque is most prominent on difficult-to-reach teeth, such as the posterior molars.

Acids formed in the plaque begin to erode the enamel on the surface of the tooth, causing a "cavity."

If not treated, the cavity grows in size, with onset of pain as the nerves and blood vessels of the affected teeth become irritated.

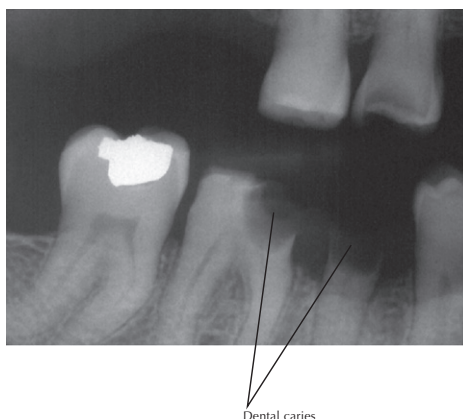
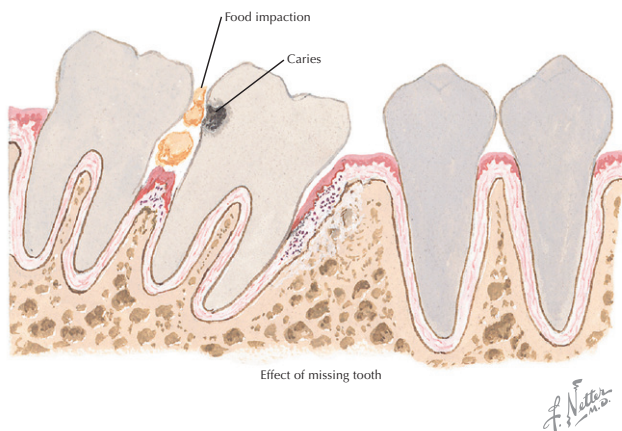
Consuming foods rich in sugar and starch increases the risk of dental caries.

Dental caries can be detected on routine dental examinations.

The damage associated with dental caries cannot be repaired by the affected tooth, which now must be restored.

Fluoride is used to reduce the risk of dental caries by inhibiting demineralization and promoting remineralization of tooth structure.

Saliva helps promote the remineralization process; medications that decrease salivary flow (such as anticholinergics) promote dental caries.



## 13 Clinical Correlate

### TORUS

*Torus*: a nonpathologic bony elevation that occurs in the oral cavity

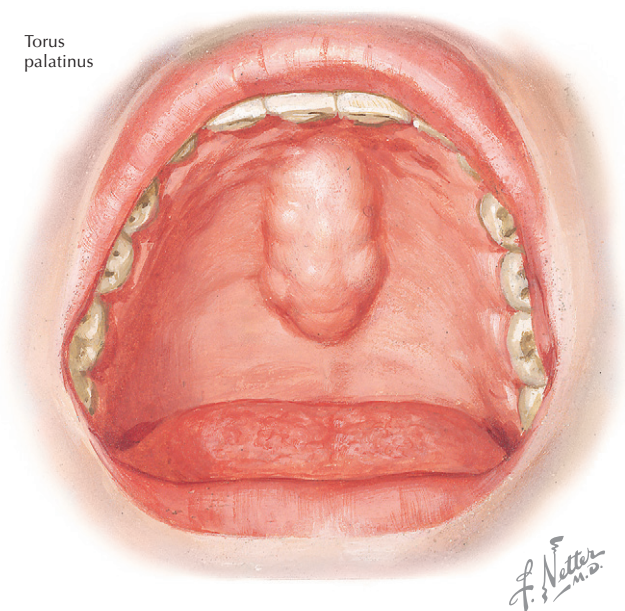
The presence of a torus does not impede eating or verbal communication but can cause difficulty in the application of a dental appliance, such as a denture

2 major types:

- Palatine—a downgrowth of bone in the midline of the hard palate
- Mandibular—an outgrowth of bone that occurs on the lingual surface of the mandible

A torus does not require treatment unless it interferes with normal function or application of dental appliances

Torus  
palatinus



## Clinical Correlate

### MUCOCELE

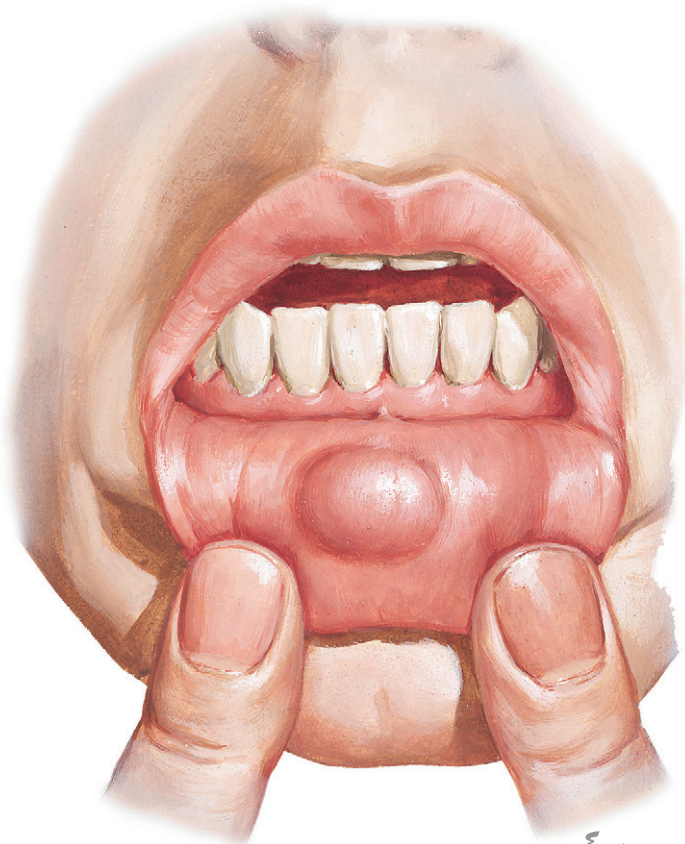
*Mucocele*: a mucous cyst that results from obstruction of the ducts of minor salivary glands (this lesion also can be associated with blockage of the major salivary glands)

Often caused by trauma to the duct system

Usually located on the lingual aspect of the lip

These lesions contain mucin and granulation tissue

Persistent mucoceles often are excised



Mucocele of lip

*F. Netter M.D.*



## 13 Clinical Correlate

### HERPES SIMPLEX

Herpes simplex is the most common cause of viral stomatitis

Caused by exposure to herpes simplex virus type 1 (HSV-1)

HSV-1 usually affects the regions above the waist, causing fever blisters

Most affected people acquire the infection as a child

During the primary infection with HSV-1, multiple vesicles appear on the lips, gingiva, hard palate, and tongue

These vesicles rupture, producing ulcers that heal in 7 to 10 days

After initial exposure, the virus is transported along a retrograde path into the trigeminal ganglion, where it stays inactive and does not replicate

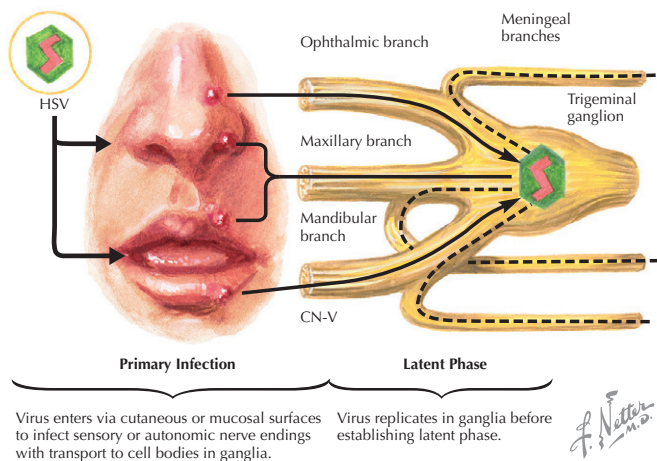
Episodes may recur

Some recurrence triggers:

- Stress
- Fever
- Anxiety
- Exposure to the sun
- Suppressed immune system

Infection can be spread through contact with infected lips

Systemic administration of antiviral agents, such as acyclovir, decreases the duration of the recurrent episodes



## Clinical Correlate

### TONSILLITIS

**Tonsillitis:** an inflammation of the tonsils, the lymph nodes located in the oral cavity and pharynx

There are 3 sets of tonsils:

- Pharyngeal (adenoids)
- Palatine (between the palatoglossal and palatopharyngeal arches)
- Lingual (on posterior 1/3 of the tongue)

These 3 sets of tonsils form Waldeyer's ring

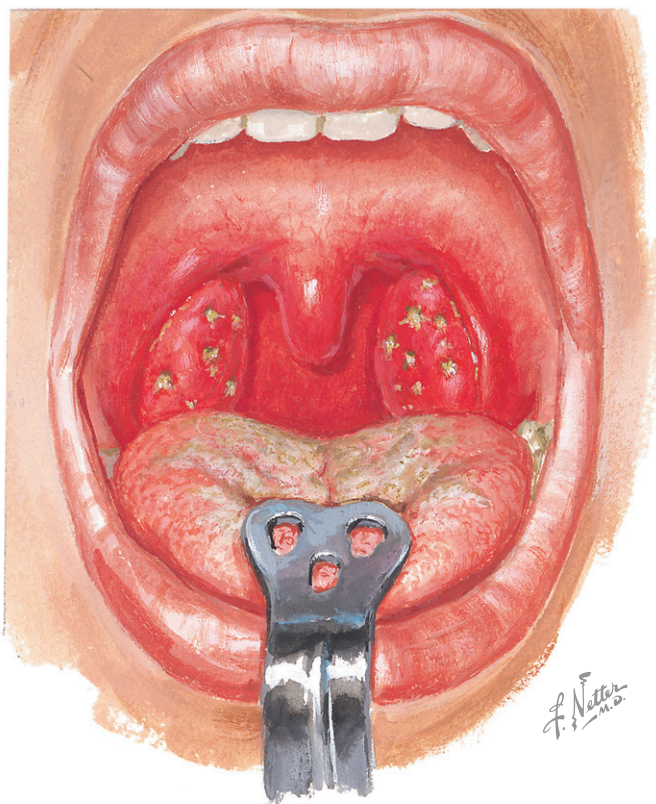
Symptoms of tonsillitis:

- Sore throat
- Dysphagia
- Fever
- Headache

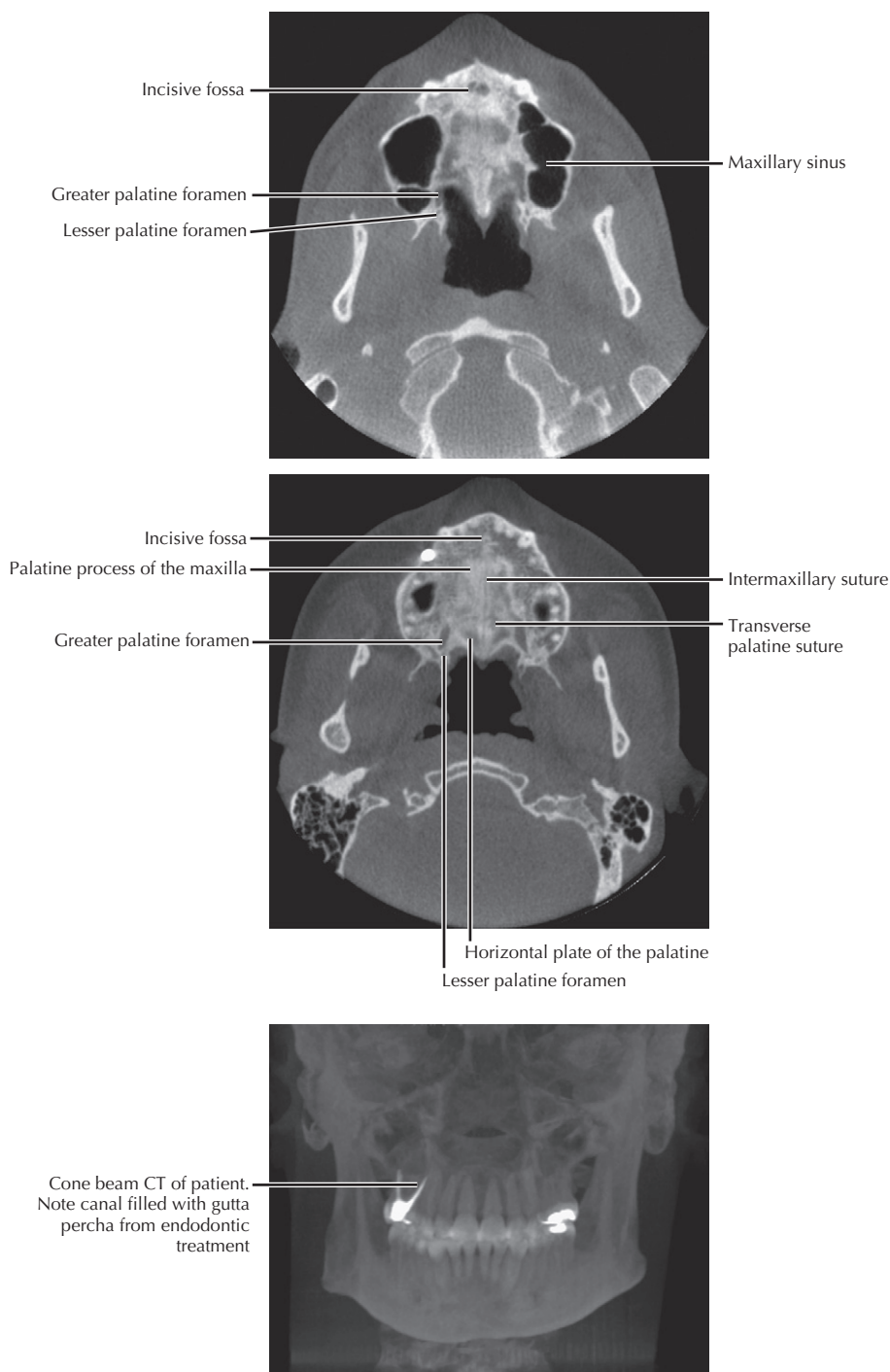
Tonsillitis often is caused by a virus or bacterium

When caused by a bacterial infection, it may be treated by antibiotics

If necessary, a tonsillectomy is performed to remove the tonsils. Palatine tonsils are removed in a tonsillectomy (although the pharyngeal tonsils also may be removed at the same time, especially if they are obstructing nasal breathing)



Acute  
follicular  
tonsillitis



## CHAPTER 14

# TONGUE

Overview and Topographic Anatomy	380
Gross Anatomy	382
Muscles	385
Nerve Supply	388
Vascular Supply	394
Clinical Correlates	397

## 14 Overview and Topographic Anatomy

### GENERAL INFORMATION

**Tongue:** a muscular structure in the oral cavity, divided into 2 parts:

- Oral, movable part
- Pharyngeal, nonmovable part

Median fibrous septum is thick tissue separating the tongue into halves

#### Functions

- Mastication
- Taste
- Talking
- Deglutition

#### Appearance

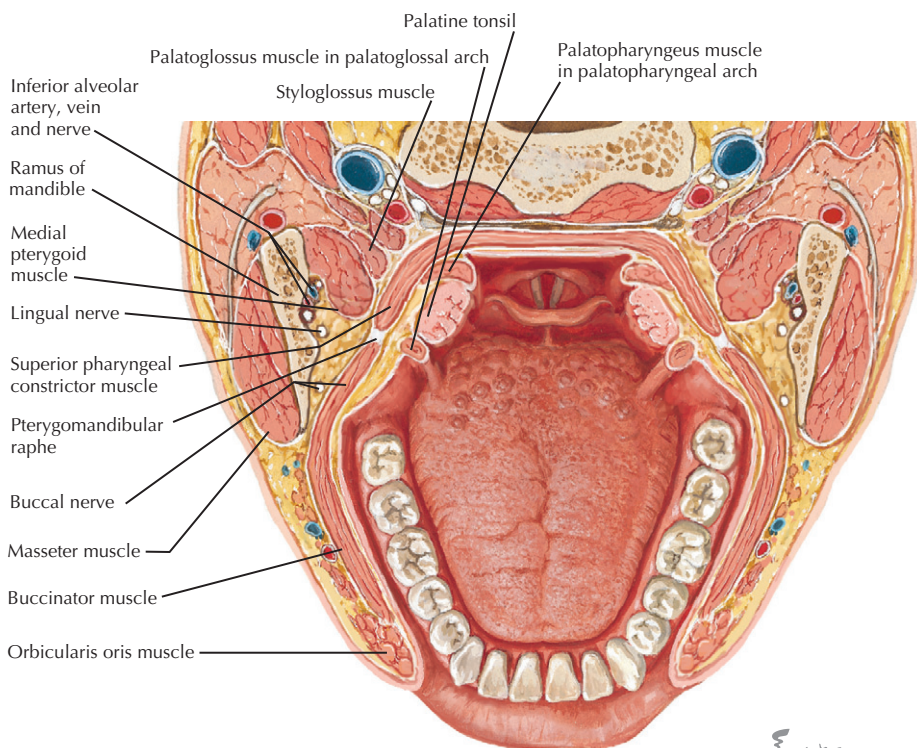
The appearance of the tongue may reflect health problems:

- Fissured tongue
- Black hairy tongue
- Geographic tongue

#### Muscle Types

**Extrinsic**—move the tongue in the oral cavity

**Intrinsic**—change the tongue's shape

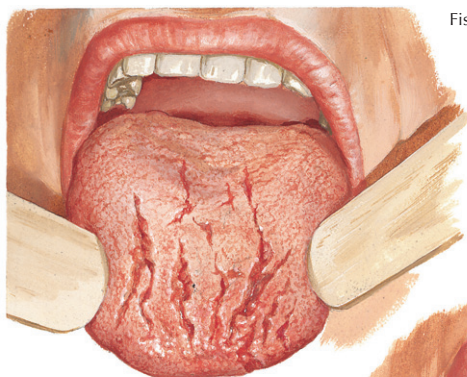


Horizontal section  
below lingula of  
mandible (superior view)  
demonstrating bed  
of parotid gland

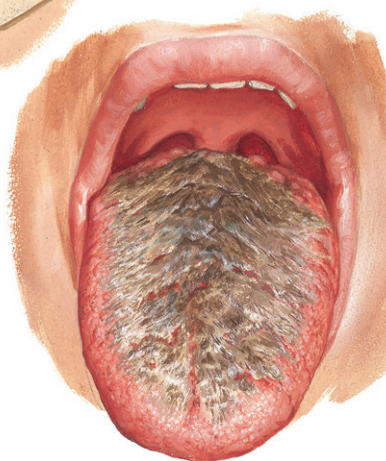*F. Netter M.D.*  
*K. Carter*  
*J. Palanzo CMI*



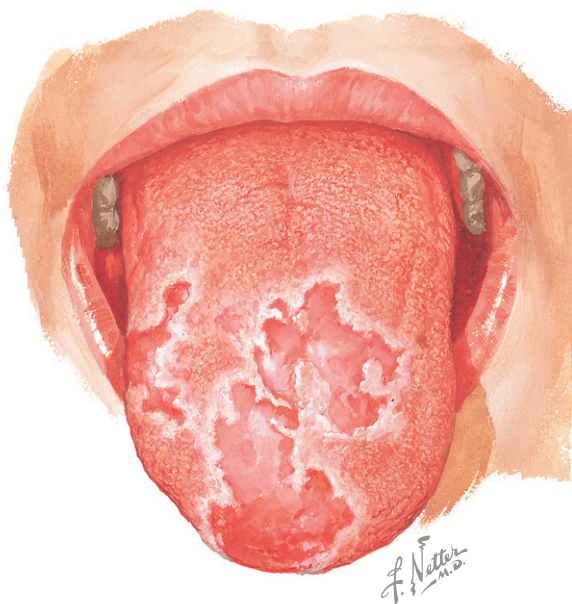
## GENERAL INFORMATION *CONTINUED*



Fissured tongue



Hairy tongue



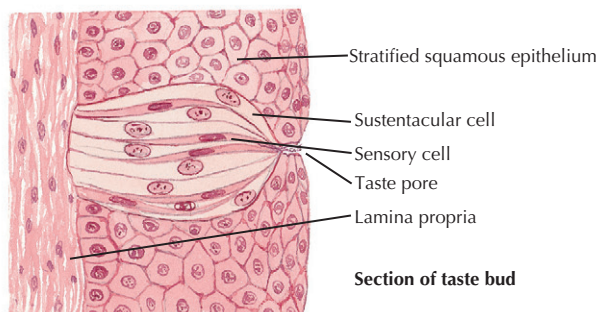
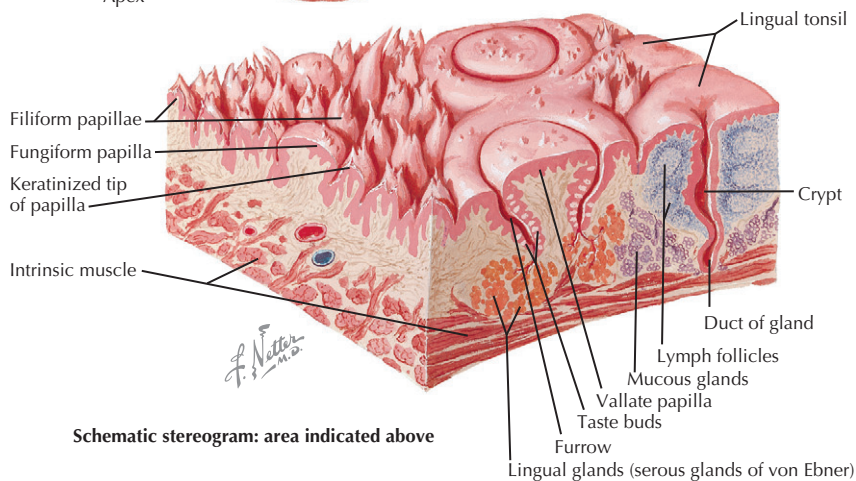
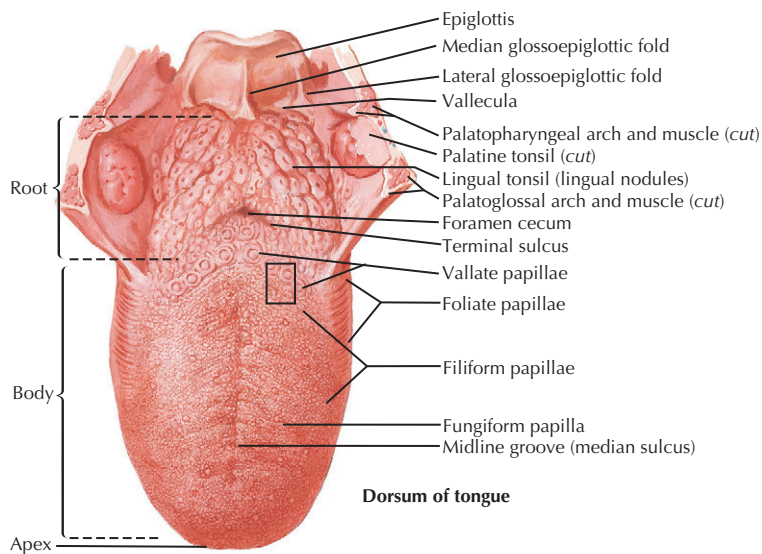
Geographic tongue

**DORSAL SURFACE**

Structure	Description	Comments
Oral portion	Occupies tongue's anterior 2/3	Covered with keratinized stratified squamous epithelium
Pharyngeal portion	Occupies tongue's posterior 1/3	Covered with nonkeratinized stratified squamous epithelium
Sulcus terminalis	A V-shaped groove immediately posterior to the circumvallate papillae	Demarcates junction between the oral and the pharyngeal portions
Foramen cecum	The initial developmental site for the thyroid gland	Located at the angle of the V
Midline septum	Fibrous	Divides tongue into halves
Lingual tonsils	Large nodules of lymphatic tissue	Cover the pharyngeal surface of the tongue
Types of papillae on the tongue's oral portion	Filiform	Most numerous but lack taste buds
	Fungiform—have taste buds	Scattered throughout the dorsum of the tongue
	Foliate—have taste buds	Fairly rudimentary in humans
	Circumvallate—have taste buds	Lie in a row immediately anterior to the sulcus terminalis
Glossoepiglottic folds	Mucous membranes	Connect the posterior portion of the pharyngeal part of the tongue with the epiglottis of the larynx
Palatoglossal arches	Pass from the soft palate to the lateral aspects of the tongue	Also known as the anterior pillar of the fauces
Glands	Mucous and serous	Numerous

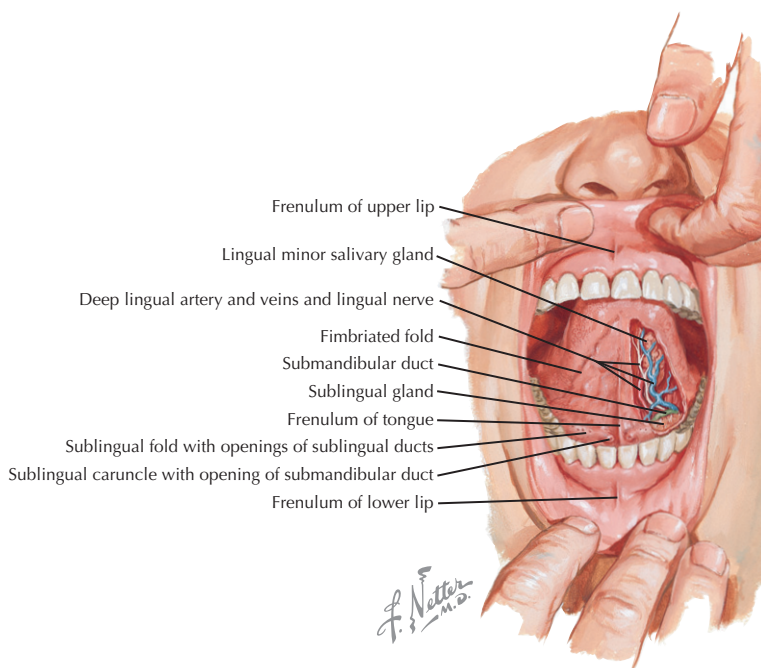
# Gross Anatomy

## DORSAL SURFACE CONTINUED



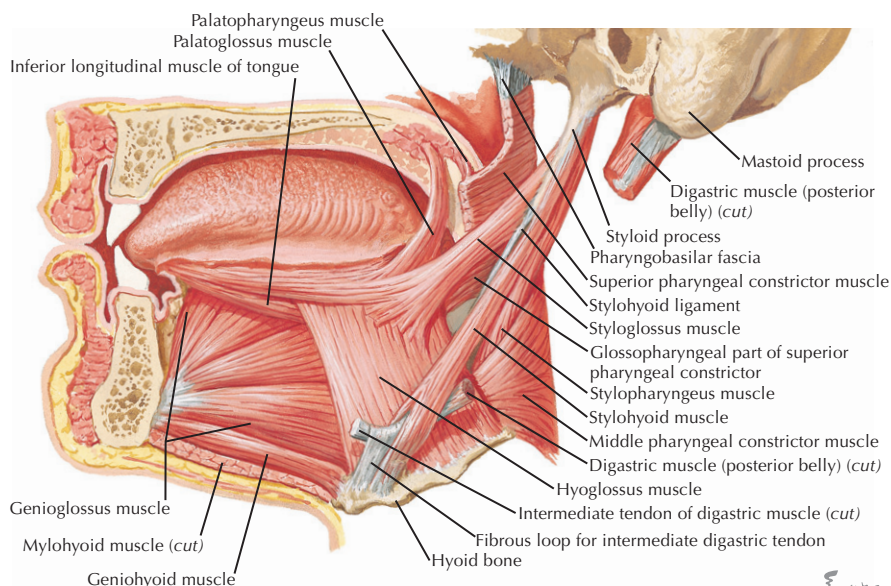
## VENTRAL SURFACE

Structure	Description	Comments
Epithelium	Nonkeratinized stratified squamous	Covers ventral surface
Lingual frenulum	A midline fold	Connects the ventral surface of the tongue to the floor of the oral cavity
Sublingual papilla	A swelling on both sides of the lingual frenulum at the tongue base	Marks the entrance of saliva from the submandibular glands into the oral cavity Continuous with the sublingual folds overlying the sublingual glands on the floor of the oral cavity
Plica fimbriata	Fimbriated folds	Lateral to the lingual frenulum
Deep lingual veins	(See table on Venous Drainage)	Can be observed through the mucosa between the plica fimbriata and the lingual frenulum



## EXTRINSIC TONGUE MUSCLES

Muscle	Origin	Insertion	Actions	Nerve	Comment
Genioglossus	Superior genial tubercle of the mandible	Fibers fan into the tongue substance Some fibers insert into the body of the hyoid	Protracts Depresses	Hypoglossal n.	The lingual a. is located between the genioglossus and hyoglossus mm.
Hyoglossus	Greater and lesser cornu and body of the hyoid	Side of the tongue where fibers mix with the styloglossus m.	Depresses		The lingual n., hypoglossal n., and submandibular duct are located on the lateral surface of the hyoglossus m.
Styloglossus	Tip of styloid process	Side of the tongue where fibers mix with the hyoglossus m.	Retracts Elevates		Smallest of the extrinsic tongue muscles
Palatoglossus	Palatine aponeurosis	Side of the tongue where fibers mix with the intrinsic muscle	Elevates Narrows the oropharyngeal isthmus for deglutition	Pharyngeal plexus (motor portion from the vagus n. and cranial part of the accessory n.)	Grouped as either an extrinsic tongue muscle or a muscle of the soft palate

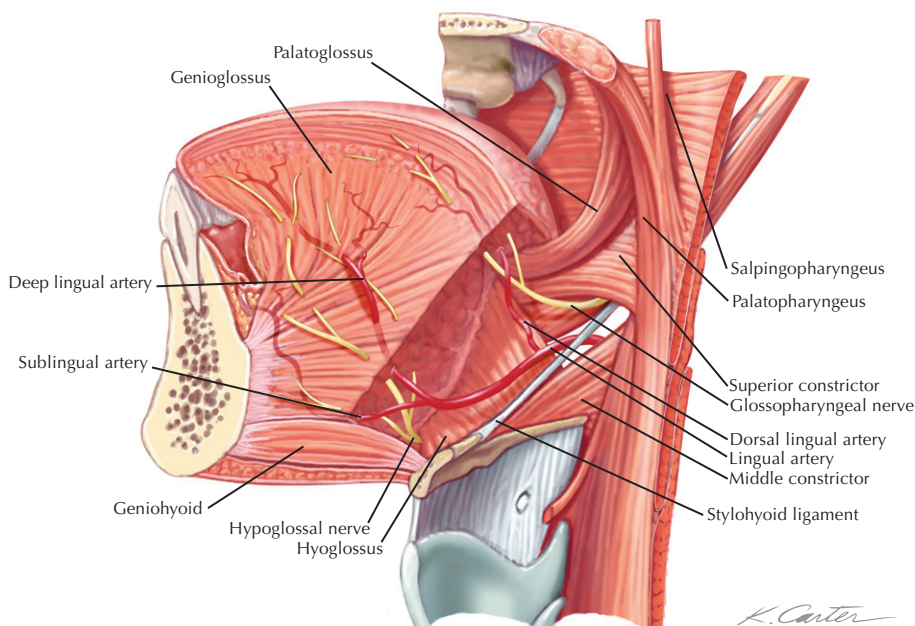


*F. Netter M.D.*



# 14 Muscles

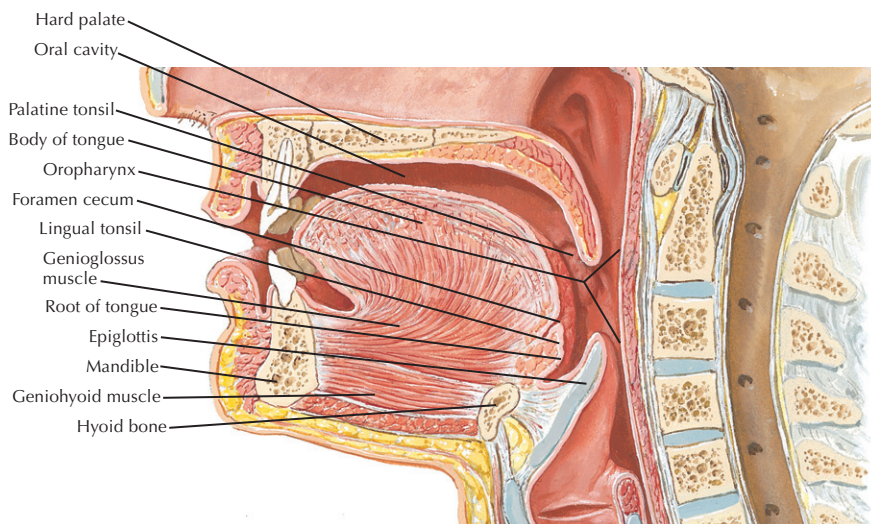
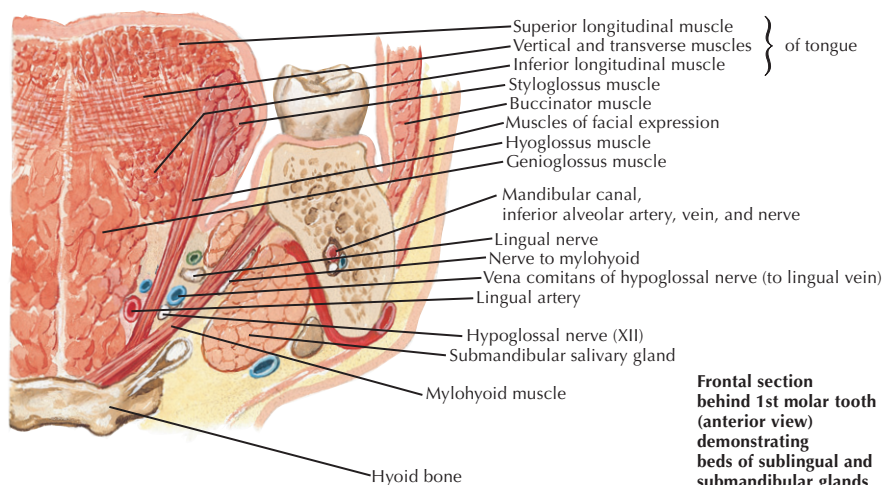
## EXTRINSIC TONGUE MUSCLES *CONTINUED*



## INTRINSIC TONGUE MUSCLES

Muscle	Origin	Insertion	Actions	Nerve	Comment
Superior longitudinal	Median fibrous septum Submucous layer near epiglottis	Submucosa along edges of the tongue	Shortens Curls the tongue's apex <i>upward</i>	Hypoglossal n.	Located immediately deep to the mucous membrane of the tongue's dorsal surface
Inferior longitudinal	Root of the tongue Body of the hyoid	Submucosa at the apex of the tongue	Shortens Curls the tongue's apex <i>downward</i>		Runs the length of the tongue between the hyoglossus and genioglossus mm.
Transverse	Median fibrous septum	Fibrous tissue in the submucosa of the sides of the tongue	Narrows Lengthens		Runs the width of the tongue
Vertical	Submucosa of upper layer of tongue	Submucosa of lower layer of tongue	Broadens Flattens		Runs from the superior to the inferior tongue surface

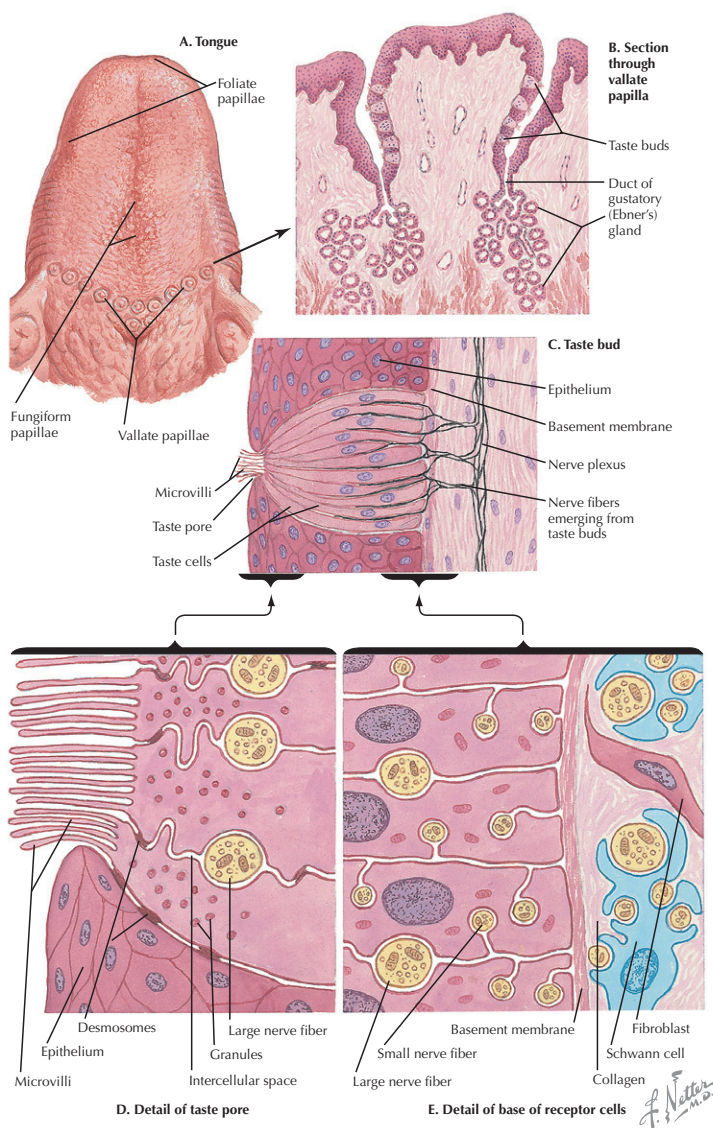
## INTRINSIC TONGUE MUSCLES *CONTINUED*

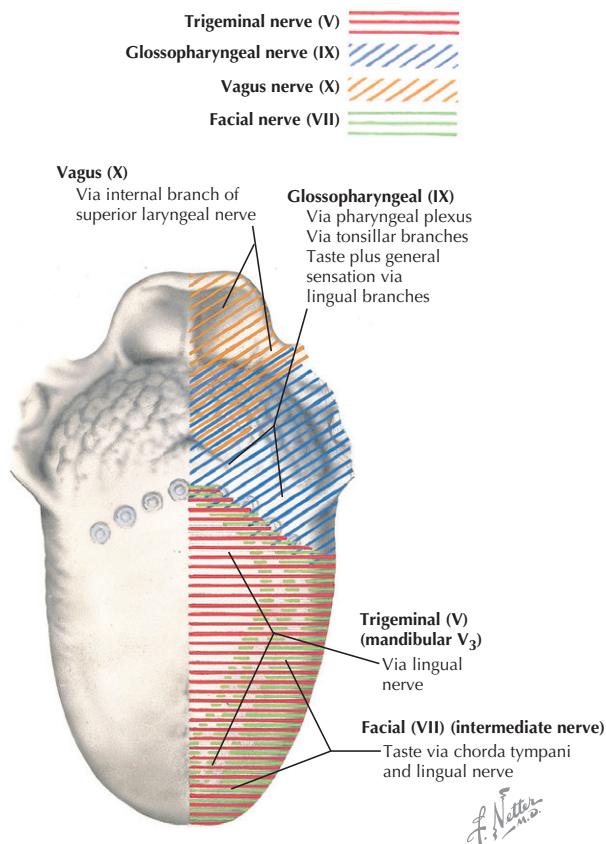


*F. Netter M.D.*

## SENSORY INNERVATION

TYPES OF SENSORY NERVE SUPPLY		
Type	Function	Nerves
General somatic afferent (GSA)	Pain, temperature, discriminative touch	Trigeminal (via lingual), glossopharyngeal, and vagus (via internal laryngeal), to innervate the epithelium and mucosa
Special visceral afferent (SVA)	Taste	Facial (via chorda tympani), glossopharyngeal, and vagus (via internal laryngeal), to innervate the taste buds





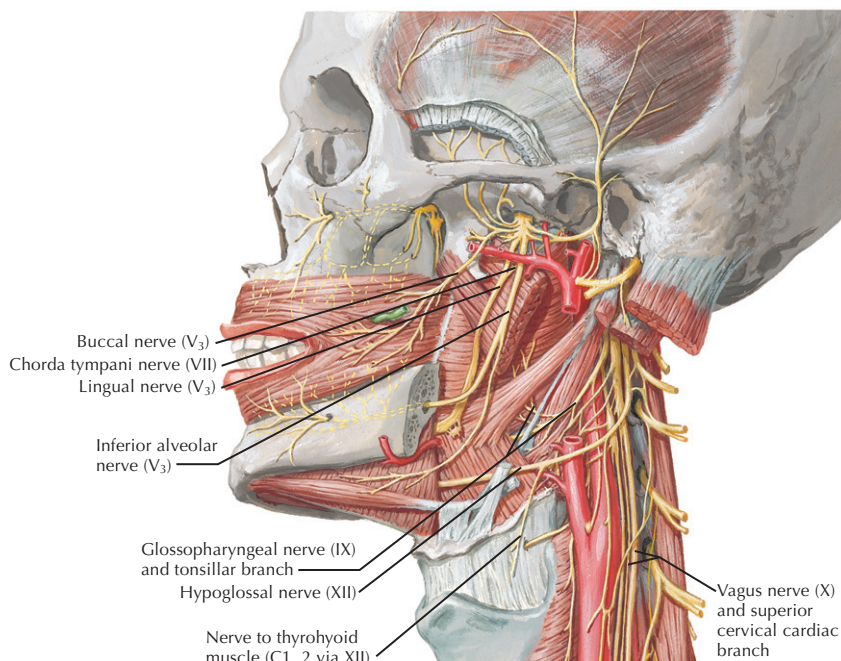
GENERAL SENSORY INNERVATION		
Nerve	Source	Course
Lingual	Mandibular division of the trigeminal n.	<p>Lies inferior to the lateral pterygoid m. and medial and anterior to the inferior alveolar nn. within the infratemporal fossa</p> <p>Chorda tympani branch of the facial n. joins its posterior part</p> <p>Lingual n. passes between the medial pterygoid m. and the ramus of the mandible to pass obliquely, entering the oral cavity bounded by the superior pharyngeal constrictor m., the medial pterygoid, and the mandible</p> <p>Enters the oral cavity lying against the lingual tuberosity of the mandible</p> <p>The submandibular ganglion is suspended from the lingual n. at the posterior border of the hyoglossus m. Continues anteriorly and passes on the lateral surface of the hyoglossus</p> <p>Passes from the lateral side inferiorly and medial to the submandibular duct to reach the mucosa of the tongue</p> <p>Supplies GSA fibers to the epithelium and papillae of the tongue's anterior 2/3, mucosa along the floor of the oral cavity (lingualalveolar ridge), and gingiva on the lingual aspect of the mandibular teeth</p>



# 14 Nerve Supply

## SENSORY INNERVATION *CONTINUED*

GENERAL SENSORY INNERVATION <i>CONTINUED</i>		
Nerve	Source	Course
Glossopharyngeal	Arises as a cranial nerve from the medulla oblongata	<p>Passes through the jugular foramen with the vagus and accessory nn.</p> <p>Within the foramen, it passes between the internal carotid a. and the internal jugular v.</p> <p>Continues inferiorly and posteriorly relative to the stylopharyngeus m.</p> <p>Passes anteriorly with the stylopharyngeus and travels between the superior and middle constrictor mm. to be located by the palatine tonsils</p> <p>Small lingual branches distribute GSA fibers to the epithelium of the tongue's posterior 1/3, in addition to the fauces</p>
Internal laryngeal	Superior laryngeal branch of the vagus n.	<p>Vagus n. branches from the medulla oblongata and passes through the jugular foramen with the glossopharyngeal and accessory nn.</p> <p>Within the foramen, it passes between the internal carotid a. and the internal jugular v.</p> <p>A series of nerves branch from the vagus in the neck, including the superior laryngeal n., which travels inferiorly posterior to the internal carotid a. on the side of the pharynx and divides into the internal and external laryngeal nn.</p> <p>The internal laryngeal n. passes inferior to the larynx and passes through the thyrohyoid membrane with the superior laryngeal vessels</p> <p>Distributes GSA fibers to the tongue's base at the epiglottic region and the mucous membranes of the larynx as far inferiorly as the false vocal folds</p>

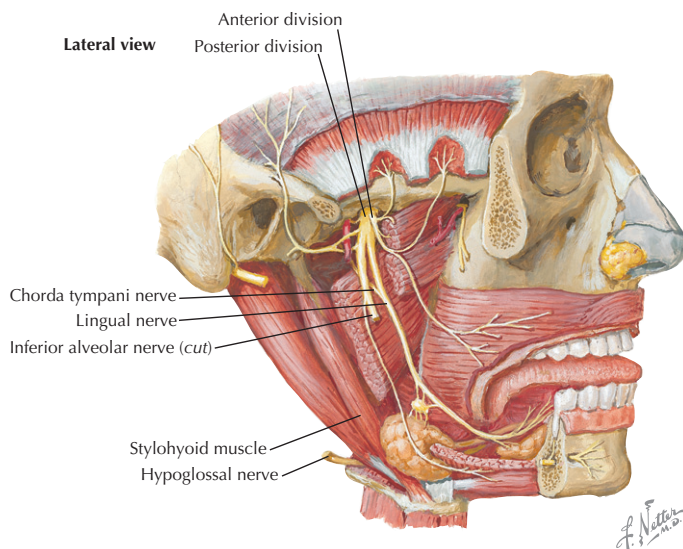


*F. Netter M.D.*



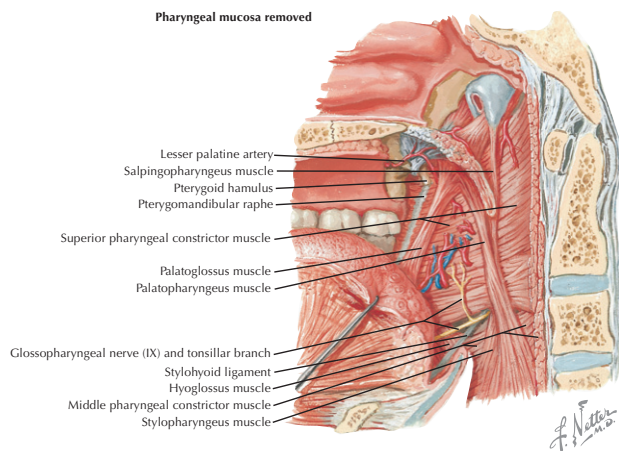
## SENSORY INNERVATION *CONTINUED*

SPECIAL SENSORY INNERVATION		
Nerve	Source	Course
Chorda tympani	Facial n. in the tympanic cavity	<p>Carries preganglionic parasympathetic fibers to the submandibular ganglion and taste fibers to the anterior 2/3 of the tongue</p> <p>Passes anteriorly to enter the tympanic cavity and lies along the tympanic membrane and malleus until exiting the petrotympanic fissure</p> <p>Joins the posterior border of the lingual n.</p> <p>Lingual n. is distributed to the anterior 2/3 of the tongue, and the SVA fibers from the chorda tympani travel to the taste buds in this region</p>
Glossopharyngeal	Arises as a cranial nerve from the medulla oblongata	<p>Passes through the jugular foramen with the vagus and accessory nn.</p> <p>Within the foramen, it passes between the internal carotid a. and the internal jugular v.</p> <p>Continues inferiorly and travels posterior to the stylopharyngeus m.</p> <p>Passes anteriorly with the stylopharyngeus and travels between the superior and middle constrictor mm., to be located by the palatine tonsils</p> <p>Small lingual branches distribute SVA fibers to the taste buds in the mucous membrane of the tongue's posterior 1/3 and the circumvallate papilla</p>
Internal laryngeal	Superior laryngeal branch of the vagus n.	<p>Vagus n. branches from the medulla oblongata and passes through the jugular foramen with the glossopharyngeal and accessory nn.</p> <p>Within the foramen, it passes between the internal carotid a. and the internal jugular v.</p> <p>A series of nerves branch from the vagus in the neck, including the superior laryngeal n., which travels inferiorly posterior to the internal carotid on the side of the pharynx and divides into the internal and external laryngeal nn.</p> <p>The internal laryngeal n. passes inferior to the larynx and passes through the thyrohyoid membrane with the superior laryngeal vessels</p> <p>Distributes SVA fibers to the taste buds scattered at the base of the tongue at the epiglottic region</p>



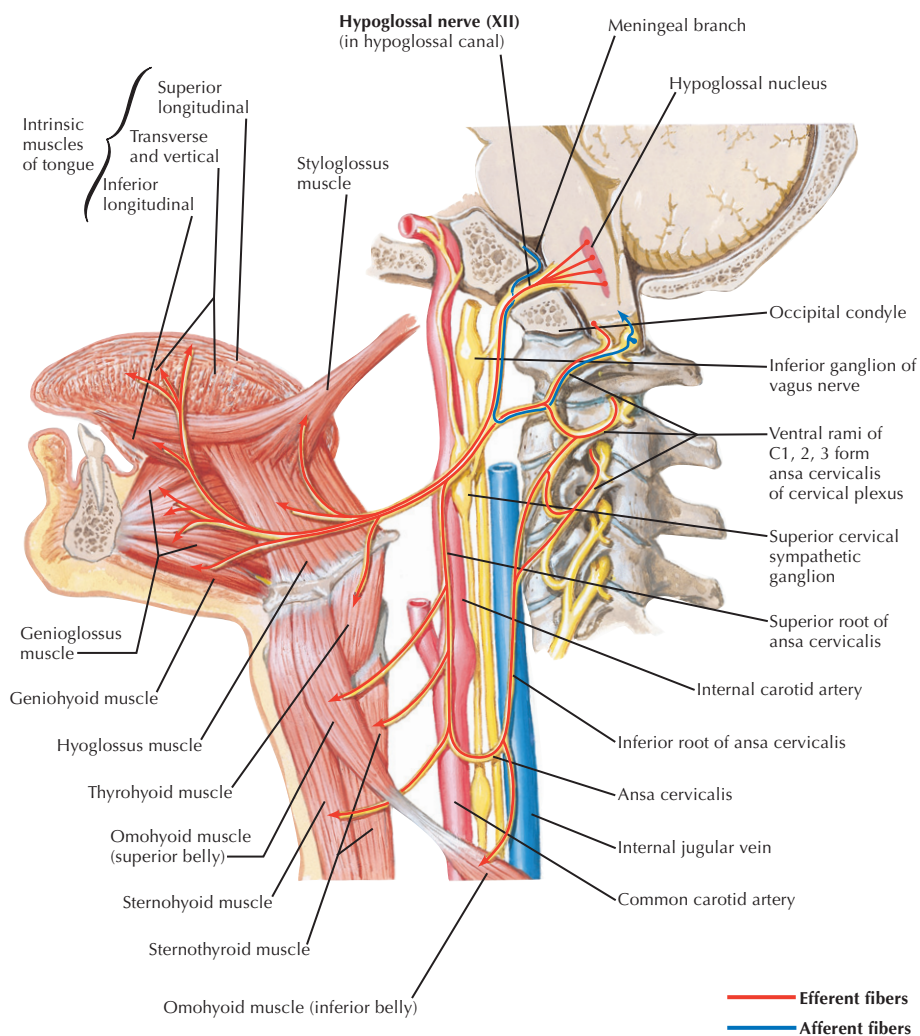
# 14 Nerve Supply

## SENSORY INNERVATION *CONTINUED*



## MOTOR INNERVATION

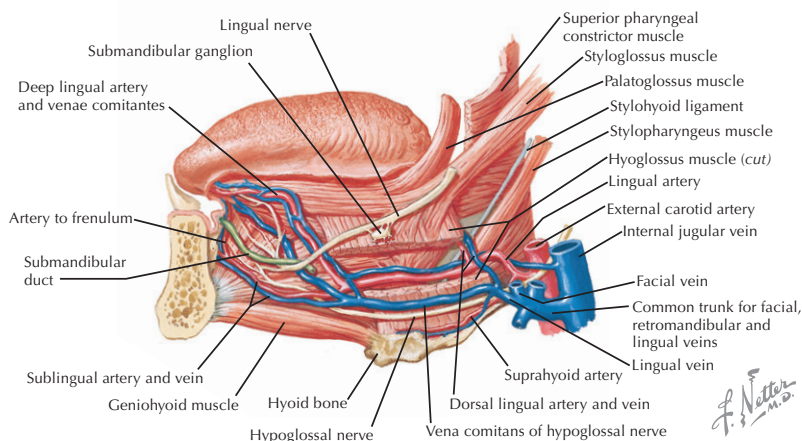
Nerve	Source	Course
Hypoglossal	Arises as a series of rootlets from the medulla oblongata and passes through the hypoglossal canal	Travels inferiorly and is located between the internal carotid a. and the internal jugular v. Passes anteriorly as it wraps around the occipital a. Passes superficial to the external carotid and the loop of the lingual a. in its anterior path Passes deep to the posterior belly of the digastric and the stylohyoid m. and lies superficial to the hyoglossus m. with the accompanying vein of the hypoglossal n. Passes deep to the mylohyoid m. and continues anterior in the genioglossus m. Muscular branches supply all intrinsic tongue muscles: hyoglossus, genioglossus, and styloglossus
Pharyngeal plexus	The motor part of the pharyngeal plexus arises from the pharyngeal branch of the vagus n. and the cranial part of the accessory n.	In the tongue, it innervates the palatoglossus m.
Pharyngeal branch of the vagus	Arises from the upper part of the inferior ganglion of the vagus n. and contains filaments from the cranial portion of the spinal accessory n.	Lies along the upper border of the middle constrictor m., where it forms the pharyngeal plexus Motor branches from the plexus are distributed to the muscles of the pharynx and soft palate (with the exception of the tensor veli palatini m.)
Cranial part of the spinal accessory n.	Emerges as 4 or 5 branches just inferior to the vagus n.'s roots	Passes laterally to the jugular foramen, where it merges with the fibers of the spinal part of the spinal accessory n. While united at this point for a short distance, it also is connected by 1 or 2 branches with the inferior ganglion of the vagus n. Exits through the jugular foramen, separates from the spinal part, and continues over the surface of the inferior ganglion of the vagus Distributed mainly to the pharyngeal branches of the vagus



*F. Netter M.D.*

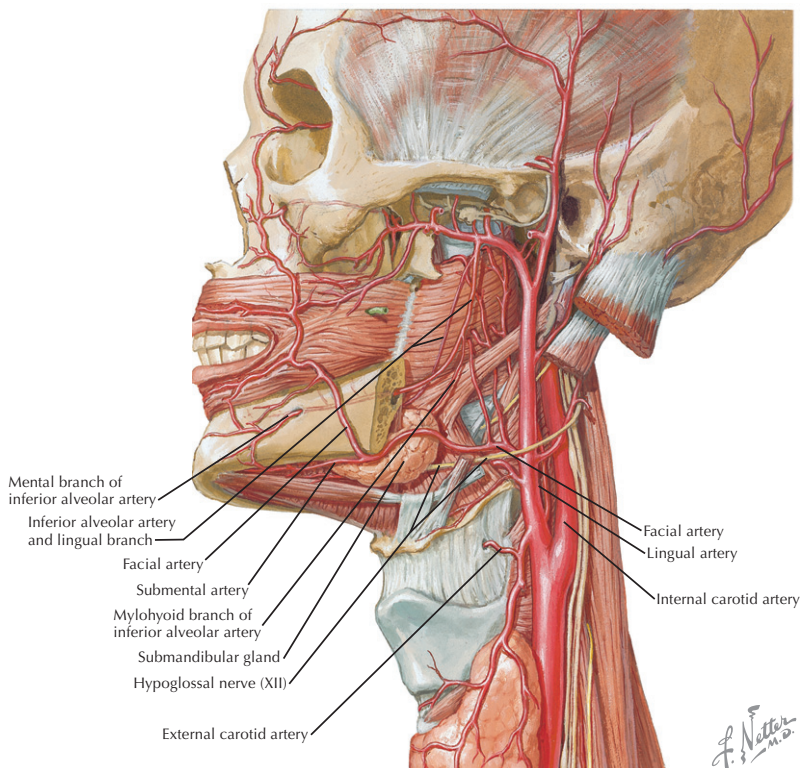
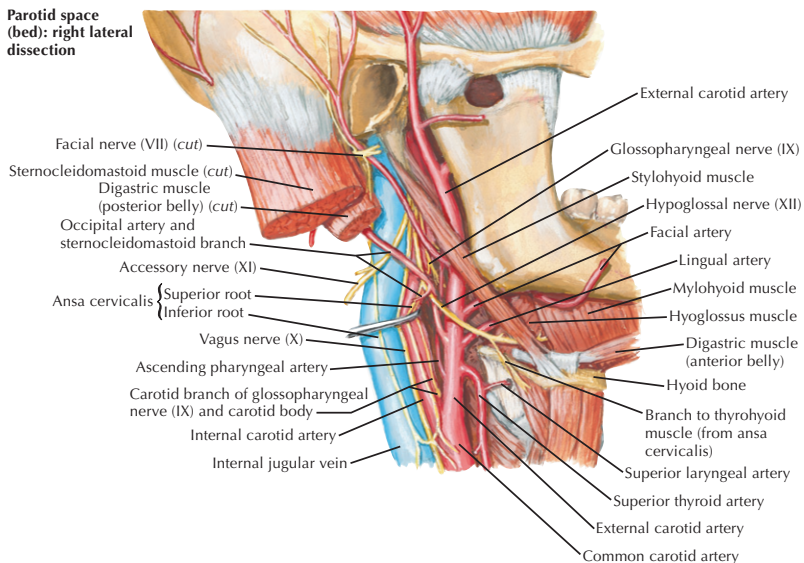
# ARTERIAL SUPPLY

Artery	Source	Course
Lingual	External carotid a. within the carotid triangle	<p>Passes superiorly and medially (obliquely) toward the greater cornu of the hyoid bone and makes a loop by passing anteriorly and inferiorly while traveling superficial to the middle constrictor m.</p> <p>While forming a loop, the artery is crossed superficially by the hypoglossal n.</p> <p>Passes deep to the posterior belly of the digastric m. and the stylohyoid m. as it travels anteriorly, where it gives off a suprahyoid branch that travels on the superior surface of the hyoid bone, supplying the muscles in that area</p> <p>The lingual a. passes deep to the hyoglossus m. and travels anteriorly between it and the genioglossus m.</p> <p>After passing deep to the hyoglossus, 2 to 3 small dorsal lingual aa. are given off at the posterior border of the hyoglossus; they pass in a superior direction to the posterior 1/3 of the dorsum of the tongue and provide vascular supply to the mucous membrane in this region, the palatoglossal arch, the palatine tonsil, the epiglottis, and the surrounding soft palate</p> <p>The lingual a. continues to pass anteriorly and gives off the sublingual branch at the anterior border of the hyoglossus; the sublingual a. passes anteriorly between the genioglossus and mylohyoid mm. to the sublingual gland and provides vascular supply to the gland and the muscles in the area</p> <p>The deep lingual a., the terminal branch or continuation of the lingual a. once the sublingual a. is given off, travels superiorly to reach the tongue's ventral surface</p> <p>Located between the inferior longitudinal m. of the tongue and the mucous membrane, the deep lingual is accompanied by branches of the lingual n., and it anastomoses with the deep lingual a. from the other side</p>
Submental	A branch of the facial a. from the external carotid a.	<p>Given off at the submandibular gland, travels anteriorly superficial to the mylohyoid m.</p> <p>Anastomoses with the sublingual branch of the lingual a. to help supply the tongue</p>



## ARTERIAL SUPPLY *CONTINUED*

**Parotid space  
(bed): right lateral  
dissection**

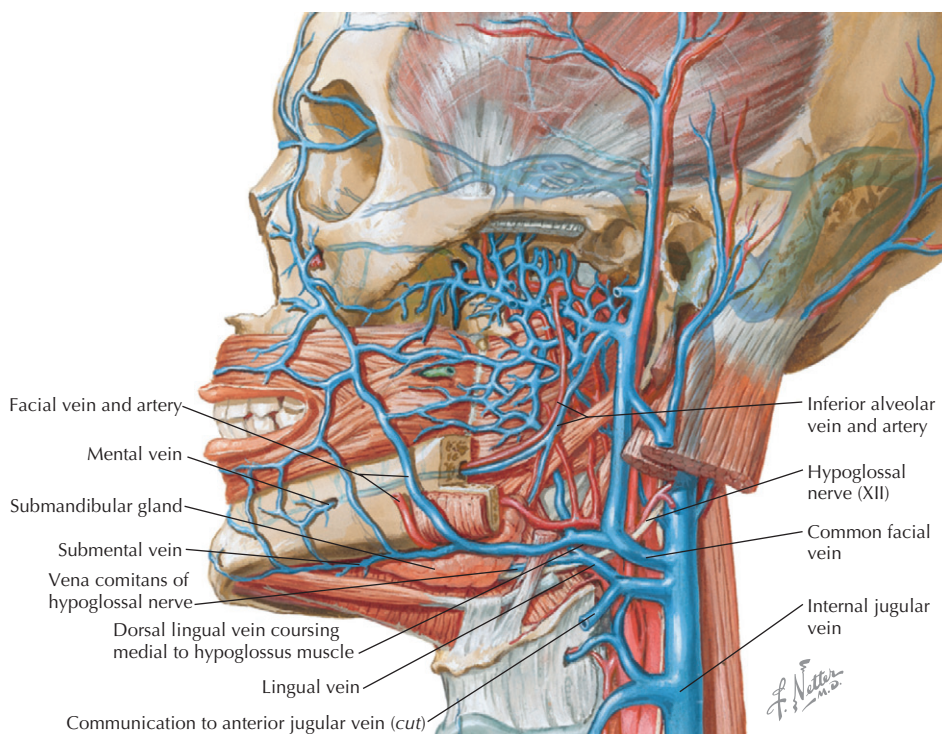




# 14 Vascular Supply

## VENOUS DRAINAGE

Vein	Course
Lingual	<p>Receives tributaries from the deep lingual vv. on the ventral surface, and dorsal lingual vv. from the dorsal surface</p> <p>Passes with the lingual a., deep to the hyoglossus m., and ends in the internal jugular v.</p> <p>The vena comitans nervi hypoglossi, or accompanying vein of the hypoglossal n., begins at the tongue's apex and may either join the lingual v. or accompany the hypoglossal n. and enter the common facial v., which empties into the internal jugular</p>
Submental	<p>Anastomoses with the lingual v.'s branches</p> <p>Parallels the submental a. on the superficial surface of the mylohyoid m. and ends in the facial v.</p>



## Clinical Correlate

### ANKYLOGLOSSIA

Also known as tongue-tie

Condition in which the lingual frenulum is restricted because of an increase in tissue, which leads to reduced tongue mobility

#### *Presentations*

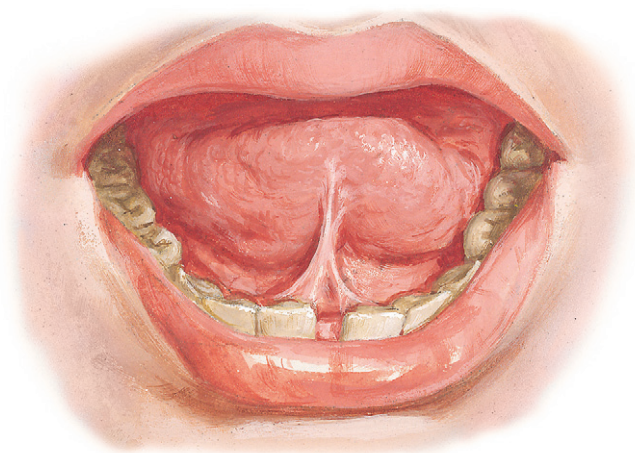
- Tongue may not be capable of protrusion beyond the incisors
- Tongue may not be capable of touching the palate
- Tongue may manifest a V-shaped notch or may appear bilobed on protrusion

#### *Complications*

- Causes problems for babies who breastfeed
- If the tongue cannot clear the oral cavity of food, caries, periodontal disease, and halitosis can result
- If condition is severe, can cause a speech impediment

#### *Treatment*

If necessary, the lingual frenulum may be cut (frenectomy)



Ankyloglossia

**HYPOGLOSSAL NERVE PARALYSIS**

Hypoglossal nerve lesions paralyze the tongue on 1 side

On protrusion, the tongue deviates to the ipsilateral (same) or contralateral side, depending on the lesion site

**LOWER MOTOR NEURON LESION**

Lesions to the hypoglossal nerve cause paralysis on the ipsilateral side:

- Tongue deviates to the paralyzed side on protrusion (the paralyzed muscles will lag, causing the tip to deviate)
- Musculature atrophies on the paralyzed side
- Tongue fasciculations occur on the paralyzed side

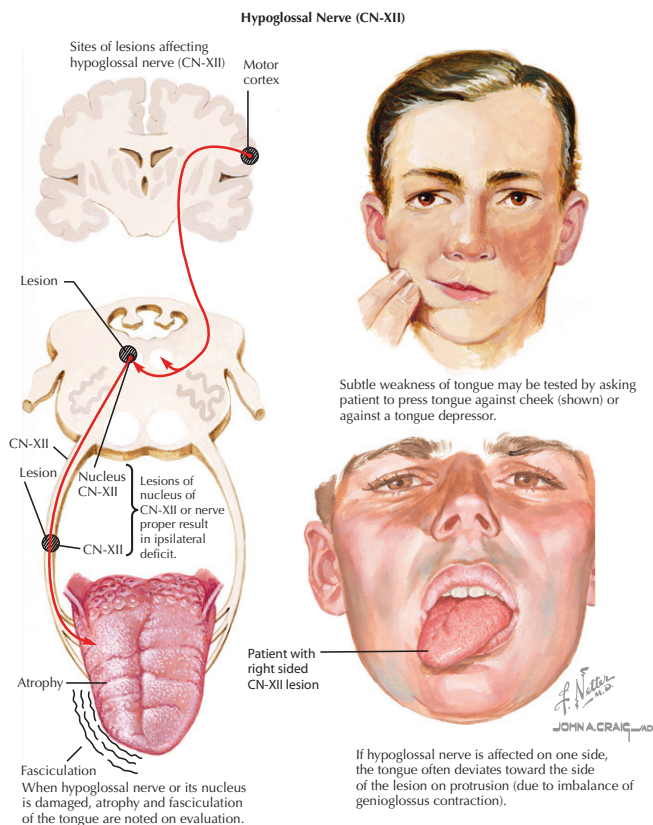
*Example:* With a neck wound that cuts the right hypoglossal nerve, the tongue deviates to the right on protrusion, and the right half of the tongue will later demonstrate atrophy and fasciculations

**UPPER MOTOR NEURON LESION**

Causes paralysis on the contralateral side:

- Tongue deviates to the side *opposite* the lesion
- Musculature atrophies on side *opposite* the lesion

*Example:* After a stroke on the right side of the brain that affects the right upper motor neurons, the tongue deviates to the left on protrusion, and the left half of the tongue will atrophy



## Clinical Correlate

### SQUAMOUS CELL CARCINOMA

Accounts for most cancers of the oral cavity

In the tongue, usually on the anterolateral aspect

Alcohol and tobacco use are risk factors

Premalignant lesions, such as erythroplasia and leukoplakia, should be identified, because early diagnosis and treatment are paramount in long-term survival

Radiographic imaging helps reveal the tumor's extent and location

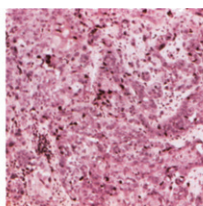
Staging of the tumor guides prognosis

#### *Treatment*

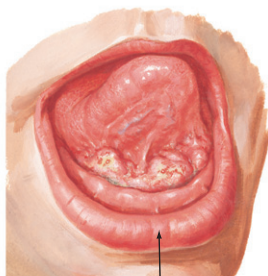
Excision or radiation therapy, or possibly a combination with chemotherapy

If lesion is detected early, excision may suffice

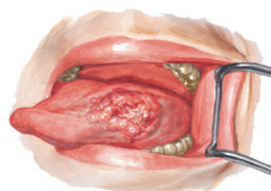
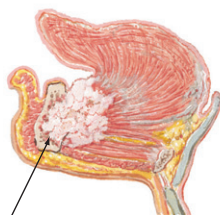
With later tumor stages, a second primary squamous cell carcinoma must be excluded



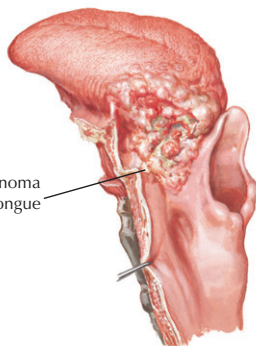
Squamous cell carcinoma



Squamous cell carcinoma of floor of mouth invading mandible



Squamous cell carcinoma of tongue



Squamous cell carcinoma of base of the tongue

## 14 Clinical Correlate

### LEUKOPLAKIA

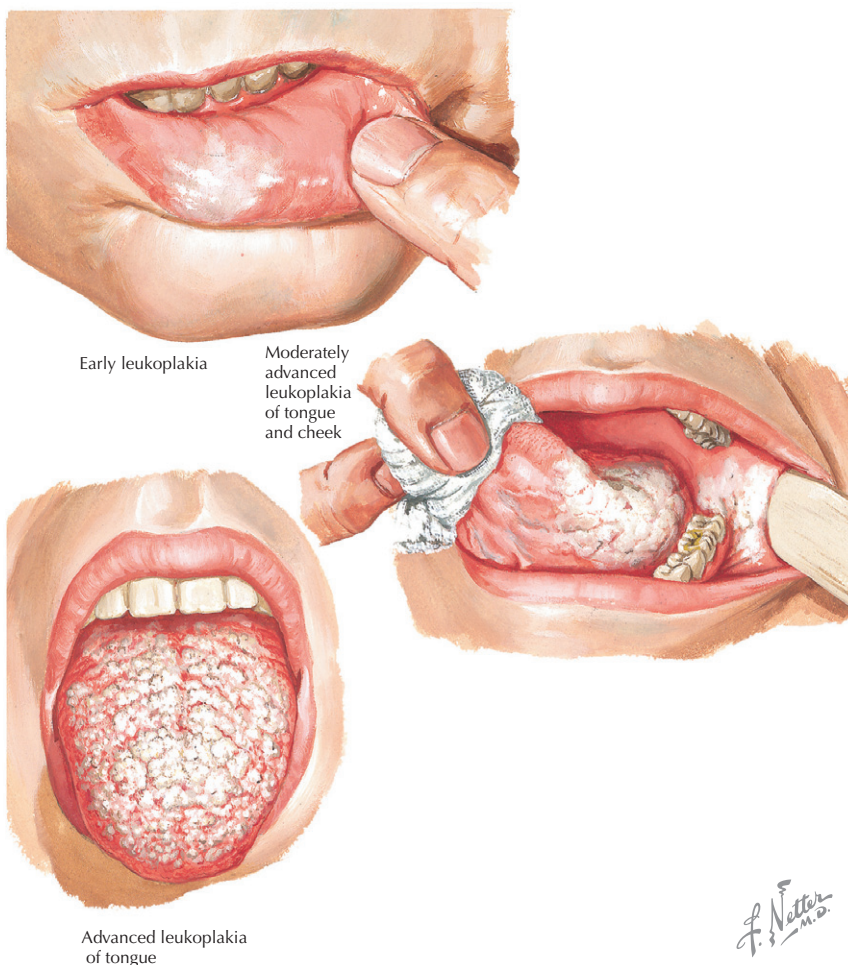
A common premalignant condition of the oral cavity involving the formation of white spots on the mucous membranes of the tongue and inside the mouth

Hairy leukoplakia is a type observed in persons with compromised immune systems

Risk factors:

- Tobacco use
- Alcohol use
- Human immunodeficiency virus (HIV) infection
- Epstein-Barr virus infection

Although a precancerous lesion, it may not progress to oral cancer





## CHAPTER 15

# PHARYNX

Overview and Topographic Anatomy	402
Parts of the Pharynx	404
Muscles	406
Potential Apertures in Pharyngeal Wall	410
Vascular Supply	411
Nerve Supply	414
Clinical Correlate	417

# 15 Overview and Topographic Anatomy

## GENERAL INFORMATION

**Pharynx:** 5-inch muscular tube from base of the skull to the lower border of the cricoid cartilage (C6)

Posterior portion of the pharynx lies against the prevertebral fascia

Lies posterior to the nasal and oral cavities and the larynx and thus is divided into 3 parts:

- Nasopharynx
- Oropharynx
- Laryngopharynx

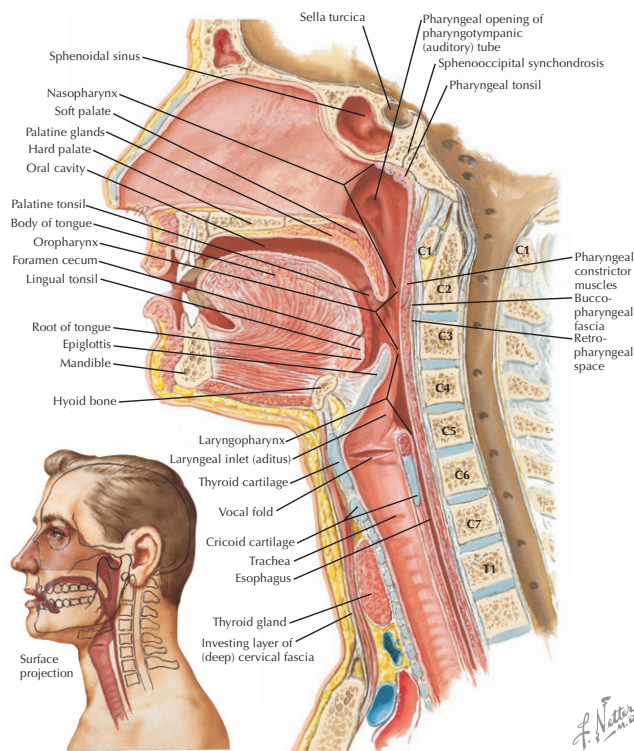
Responsible for properly conducting food to the esophagus and air to the lungs

Composed of:

- Three constrictor muscles
- Three longitudinal muscles
- Cartilaginous part of the pharyngotympanic tube
- Soft palate

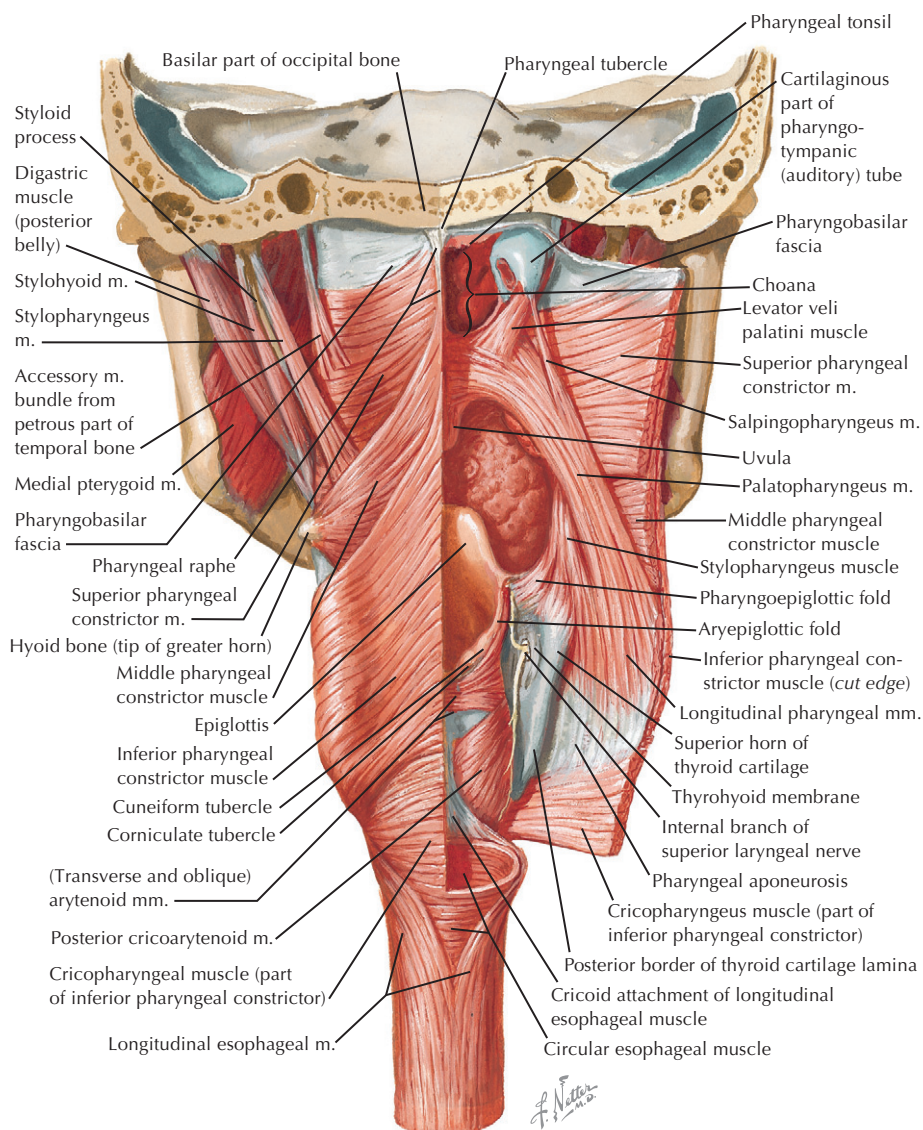
The wall of the pharynx has 5 layers:

- Mucous membrane—the innermost layer
- Submucosa
- Pharyngobasilar fascia—the fibrous layer attached to the skull anchoring the pharynx
- Muscular—3 inner longitudinal and 3 outer circular (constrictor) muscles that overlap such that the superior constrictor is the innermost, whereas the inferior constrictor is the outermost muscle
- Buccopharyngeal fascia—loose layer of connective tissue continuous with the fascia over the buccinator and pharyngeal muscles, and the location of the pharyngeal plexus of nerves and the pharyngeal plexus of veins



# Overview and Topographic Anatomy

## GENERAL INFORMATION *CONTINUED*



# 15 Parts of the Pharynx

## NASOPHARYNX

Boundaries	Major Anatomic Features	Comments
<i>Roof</i> —fornix <i>Floor</i> —soft palate <i>Anterior</i> —choanae of the nasal cavity <i>Posterior</i> —mucosa covering superior constrictor <i>Lateral</i> —mucosa covering superior constrictor	Ostium of the auditory tube opens into the nasopharynx Torus tubarius is an elevation formed by the base of the cartilaginous portion of the auditory tube, which lies superior to the ostium of the tube Salpingopharyngeal fold is mucous membrane that lies over the salpingopharyngeus m., connecting the torus tubarius to the lateral wall of the pharynx Pharyngeal recess is located posterior to the salpingopharyngeal fold and contains the pharyngeal tonsils (adenoids)	Has a respiratory function The auditory tube connects the middle ear with the nasopharynx and helps equalize air pressure on both sides of the tympanic membrane The cartilaginous portion of the auditory tube normally is closed, except during deglutition and yawning The auditory tube allows spread of infections between the middle ear and the nasopharynx

## OROPHARYNX

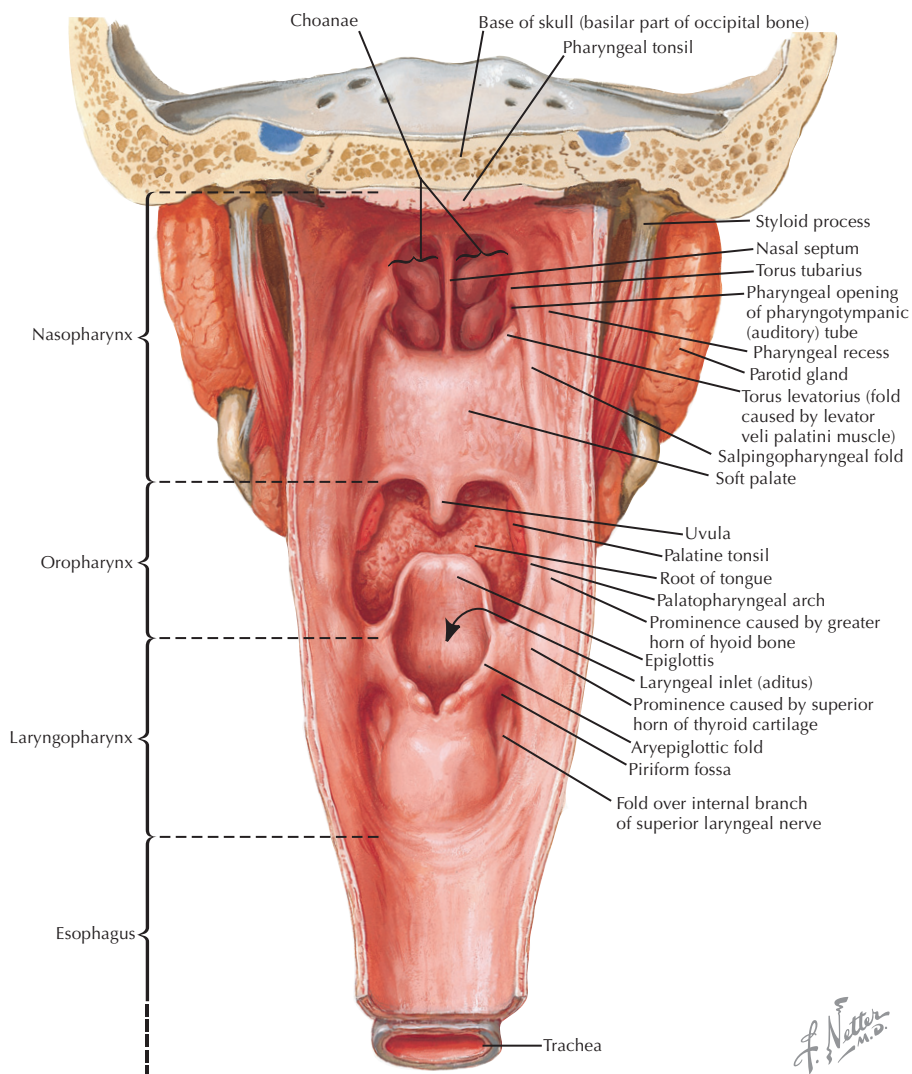
Boundaries	Major Anatomic Features	Comment
<i>Superior</i> —nasopharynx <i>Inferior</i> —posterior 1/3 of the tongue <i>Anterior</i> —palatoglossal fold of the oral cavity <i>Posterior</i> —mucosa covering the superior and middle constrictor mm. <i>Lateral</i> —mucosa covering the superior and middle constrictors	Palatine tonsils are located in the oropharynx between the palatoglossal and palatopharyngeal folds Epiglottic vallecula—the depression immediately posterior to the root of the tongue	Has a respiratory and a digestive function

## LARYNGOPHARYNX

Boundaries	Major Anatomic Features	Comment
<i>Superior</i> —oropharynx <i>Anterior</i> —larynx and epiglottis <i>Posterior</i> —mucosa covering middle and inferior constrictor mm. <i>Lateral</i> —mucosa covering middle and inferior constrictors	Piriform recess is a small depression located on the lateral wall of the laryngopharyngeal cavity on either side of the entrance to the larynx	Communicates with the larynx The piriform recess is a potential location for objects to become lodged

# Parts of the Pharynx

## LARYNGOPHARYNX CONTINUED





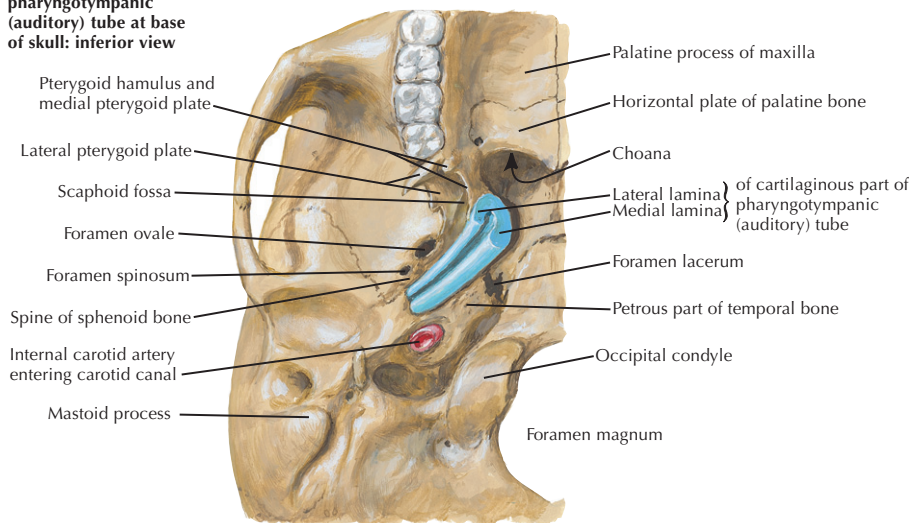
## OVERVIEW

Muscle	Origin	Insertion	Actions	Nerve Supply
Superior constrictor	Pterygoid hamulus Pterygomandibular raphe Retromolar trigone of mandible Side of tongue	Pharyngeal tubercle Pharyngeal raphe	Constricts the <i>upper</i> portion of the pharynx	Pharyngeal plexus (the motor portion of this plexus is formed by the pharyngeal branch of the vagus n. and the cranial part of the spinal accessory n.)
Middle constrictor	Stylohyoid lig. Lesser cornu of hyoid Greater cornu of hyoid	Pharyngeal raphe	Constricts the <i>middle</i> portion of the pharynx	
Inferior constrictor	Oblique line of thyroid cartilage Side of cricoid cartilage		Constricts the <i>lower</i> portion of the pharynx	
Palatopharyngeus	Posterior border of hard palate Palatine aponeurosis	Posterior border of the lamina of the thyroid cartilage	Elevates pharynx Helps close the nasopharynx	Pharyngeal plexus (the motor portion of this plexus is formed by the pharyngeal branch of the vagus n. and the cranial part of the spinal accessory n.)
Salpingopharyngeus	Cartilage of auditory tube		Elevates the upper and lateral portions of the pharynx	
Stylopharyngeus	Medial aspect of base of styloid process		Elevates pharynx Expands the sides of the pharynx	Glossopharyngeal n.

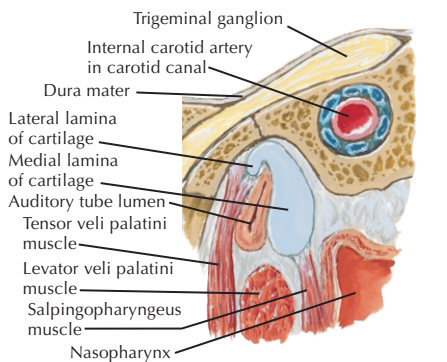
# Muscles

## OVERVIEW CONTINUED

### Cartilaginous part of pharyngotympanic (auditory) tube at base of skull: inferior view

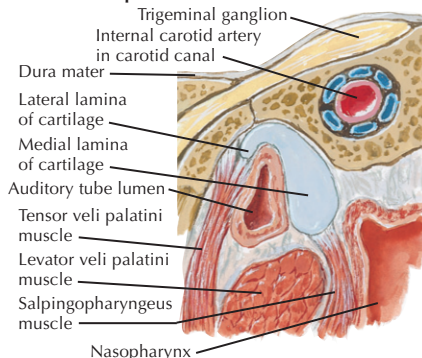


### Section through cartilaginous part of pharyngotympanic (auditory) tube, with tube closed



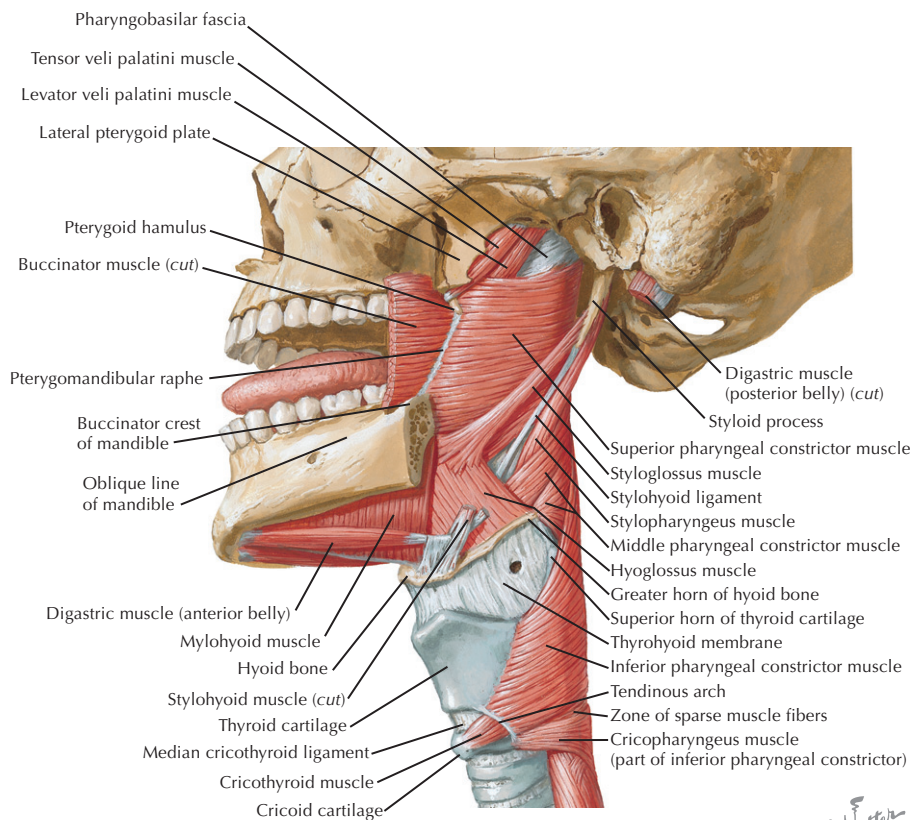
Pharyngotympanic (auditory) tube closed by elastic recoil of cartilage, tissue turgidity and tension of salpingopharyngeus muscles

### Section through cartilaginous part of pharyngotympanic (auditory) tube, with tube open

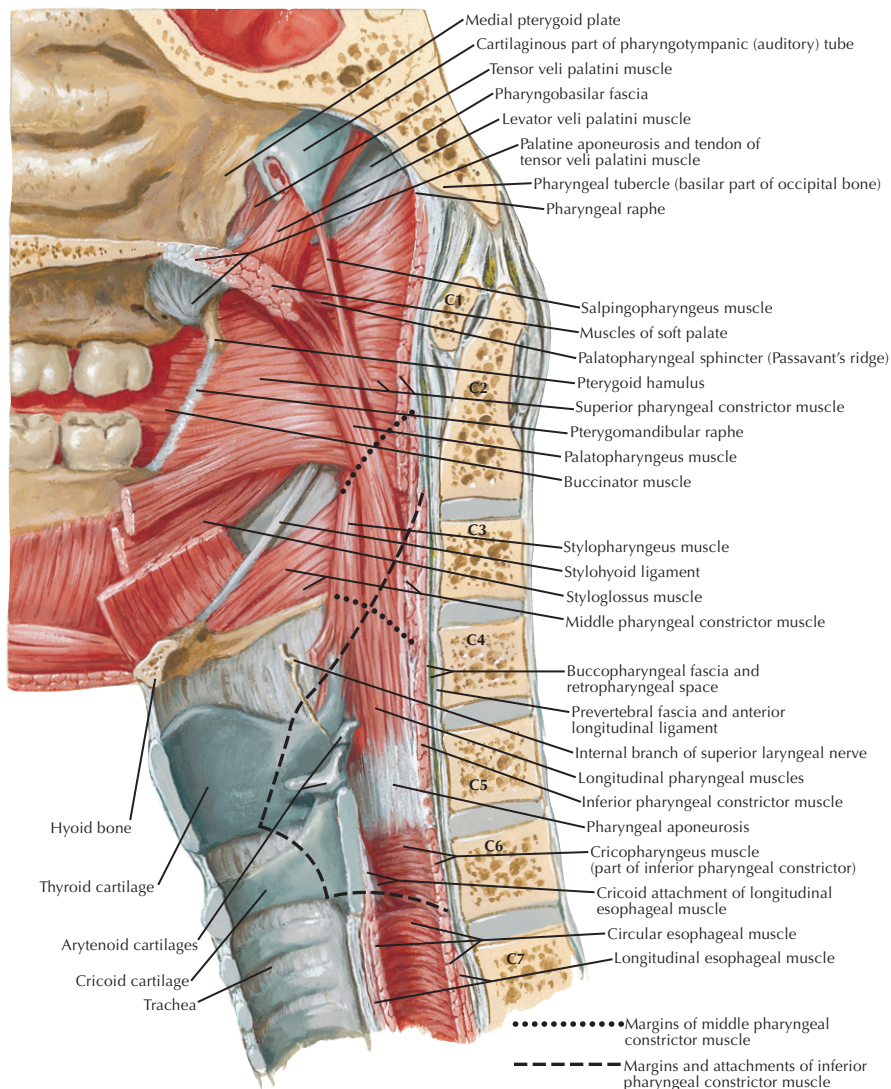


Lumen opened chiefly when attachment of tensor veli palatini muscle pulls wall of tube laterally during swallowing

*F. Netter M.D.*



*F. Netter M.D.*



*F. Netter M.D.*

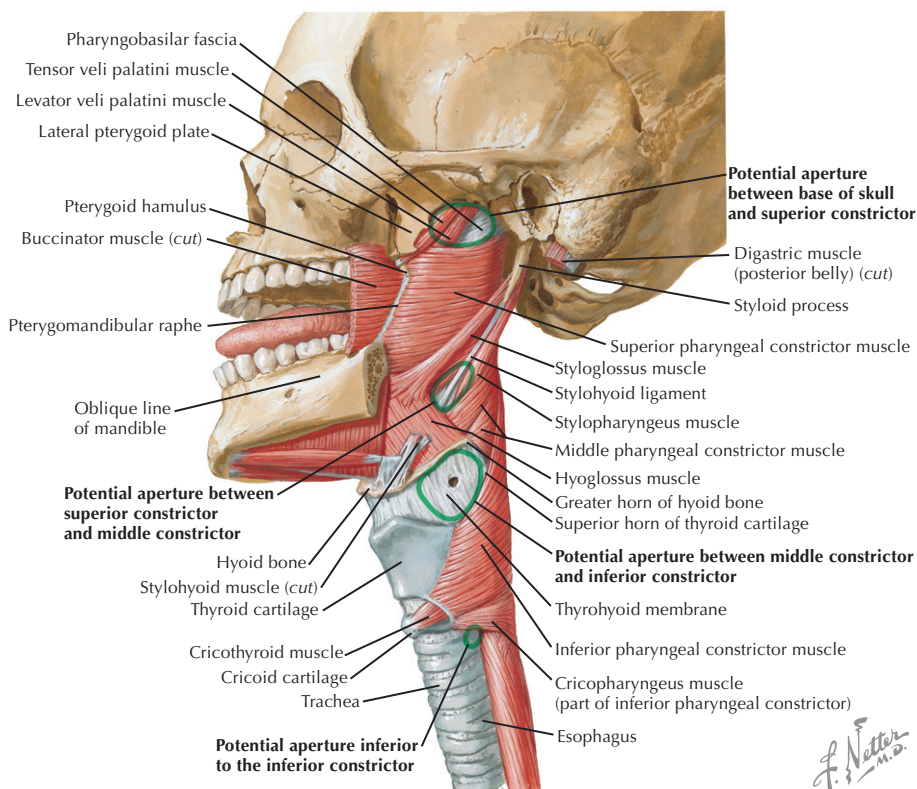
# 15 Potential Apertures in Pharyngeal Wall

## LOCATIONS AND STRUCTURES

The overlapping arrangement of the 3 constrictor muscles leaves 4 potential apertures in the pharyngeal musculature

Anatomic structures enter and exit the pharynx through these potential apertures

OVERVIEW OF POTENTIAL APERTURES	
Location	Anatomic Structures That Pass Through
Between base of the skull and the superior constrictor m.	Auditory tube Levator veli palatini m. Ascending pharyngeal a. Ascending palatine a.
Between the superior and middle constrictor mm.	Stylopharyngeus m. Glossopharyngeal n. Tonsillar branch of the ascending palatine a. Stylohyoid lig.
Between the middle and inferior constrictor mm.	Internal laryngeal n. Superior laryngeal a. and v.
Inferior to the inferior constrictor m.	Recurrent laryngeal n. Inferior laryngeal a. and v.

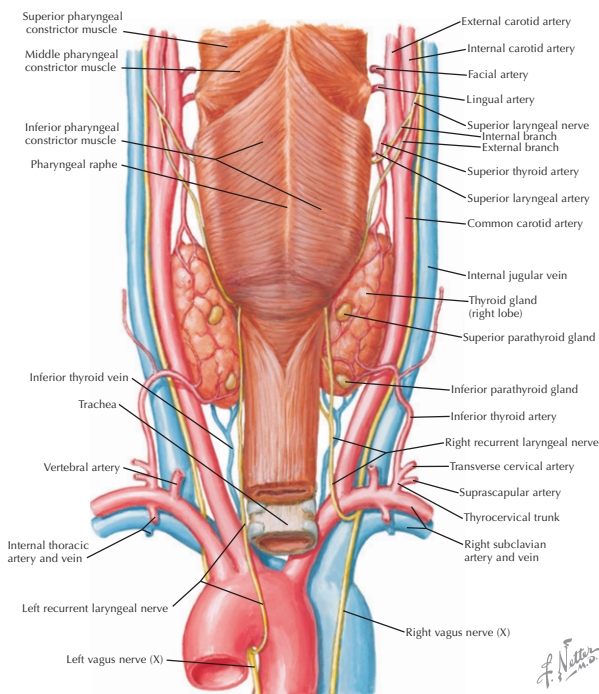
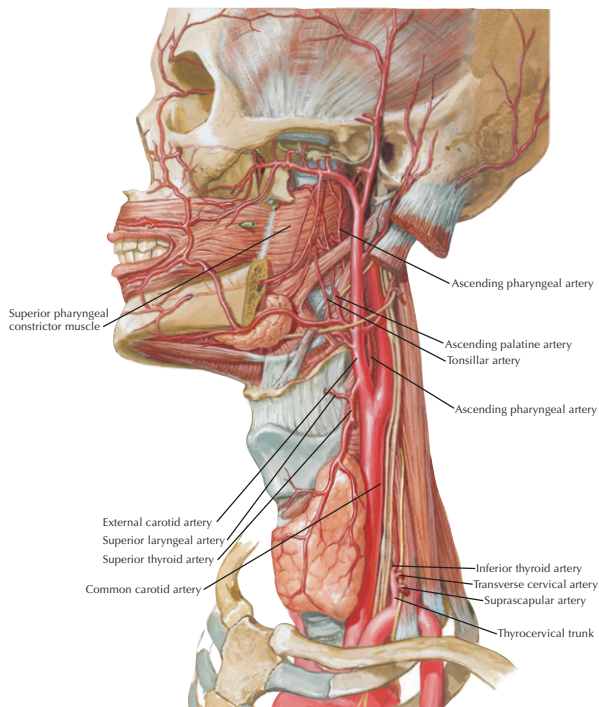




## ARTERIAL SUPPLY

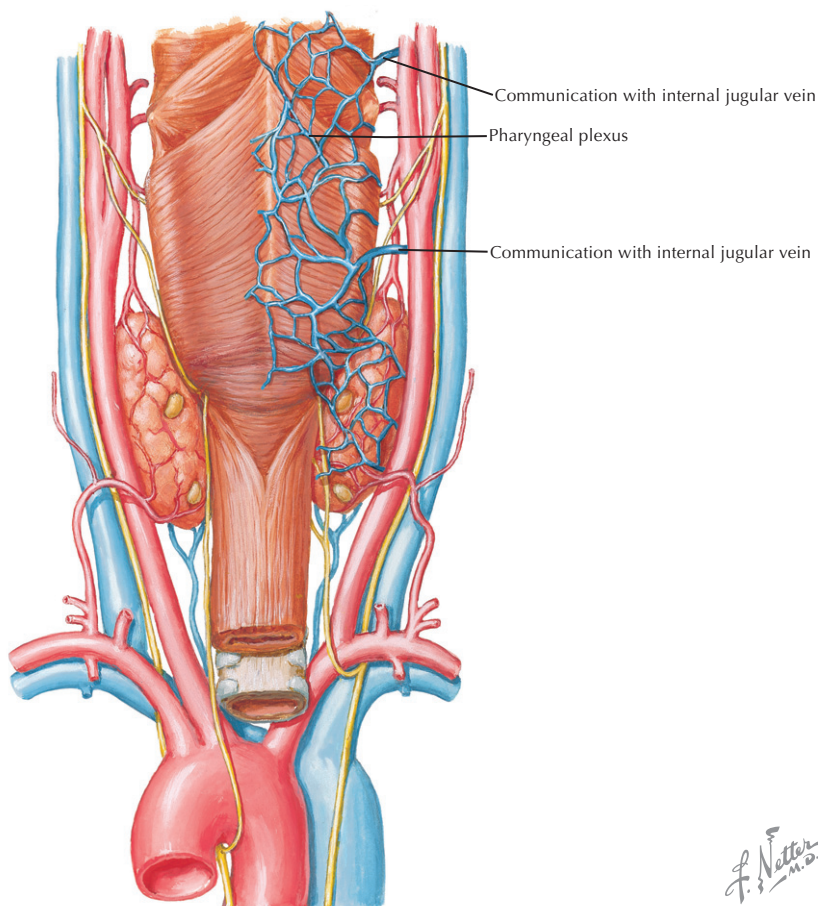
Artery	Source	Course
Ascending pharyngeal	The posterior portion of the external carotid a. near the bifurcation of the common carotid a.	The smallest branch arising from the external carotid a. Ascends superiorly between the lateral aspect of the pharynx and the internal carotid a. <i>Has 2 major sets of branches:</i> <ul style="list-style-type: none"> <li>• Pharyngeal—a series of 3 small branches that supplies the stylopharyngeus and the middle and inferior constrictor mm.</li> <li>• Palatine—supplies the superior constrictor, palatine tonsil, soft palate, and auditory tube</li> </ul>
Ascending palatine	Facial a.	Ascends superiorly along the lateral side of the pharynx, typically between the stylopharyngeus and the styloglossus mm. Passes through the aperture between the base of the skull and the superior constrictor m. to supply it and the soft palate
Tonsillar		While ascending superiorly along the lateral side of the pharynx, it passes into and supplies the superior constrictor m. until reaching the palatine tonsil and root of the tongue
Pharyngeal	The 3rd part of the maxillary a. in the pterygopalatine fossa	Passes posteriorly with the pharyngeal n. into the pharyngeal canal Emerges to supply the superior portion of the nasopharynx and the auditory tube
Superior thyroid	The 1st branch of the external carotid a.	Passes inferiorly along the inferior constrictor m. to supply the thyroid gland
Inferior thyroid	Thyrocervical trunk	Has a series of branches The pharyngeal branch supplies the pharynx

## ARTERIAL SUPPLY *CONTINUED*



## VENOUS DRAINAGE

Vein	Course
Pharyngeal plexus	Located on the outer surface of the pharynx in the buccopharyngeal fascia Gives rise to pharyngeal vv., which drain into the internal jugular v. and also into the pterygoid plexus of veins along the lateral pterygoid m. The pharyngeal vv. also may drain into the facial, lingual, or superior thyroid v.



# 15 Nerve Supply

## GENERAL INFORMATION

Supplies motor and sensory innervation to most of the pharynx

Composed of:

- Pharyngeal branch of the glossopharyngeal nerve
- Pharyngeal branch of the vagus nerve
- Cranial part of the spinal accessory nerve

## PHARYNGEAL PLEXUS

Nerve	Function	Course	Sensory	Motor
Pharyngeal branch of the glossopharyngeal	The major branch of the glossopharyngeal n. that contributes to the pharyngeal plexus Mainly sensory, but has motor function	3 or 4 filaments unite to form 1 pharyngeal branch opposite the middle constrictor m. This branch, along with the pharyngeal branch of the vagus and spinal accessory nn., forms the pharyngeal plexus	Sensory branches contributing to the plexus perforate the pharyngeal muscles and supply its mucous membranes (mainly oropharynx region)	Aids the pharyngeal branch of the vagus n. and cranial part of the spinal accessory n.
Pharyngeal branch of the vagus	The major branch of the vagus n. that contributes to the pharyngeal plexus Mainly motor, but has sensory function	Arises from the upper part of the inferior ganglion of the vagus n. and contains filaments from the cranial portion of the spinal accessory n. (cranial n. XI) Lies along the upper border of the middle constrictor m., where it forms the pharyngeal plexus From the plexus, the motor branches are distributed to the pharyngeal and soft palate muscles (with the exception of the tensor veli palatini m.)	Sensory branches contributing to the plexus perforate the pharyngeal muscles and supply the remainder of the pharyngeal mucous membranes	Superior constrictor, middle constrictor, inferior constrictor, palatopharyngeus, salpingopharyngeus mm.

# Nerve Supply

## PHARYNGEAL PLEXUS *CONTINUED*

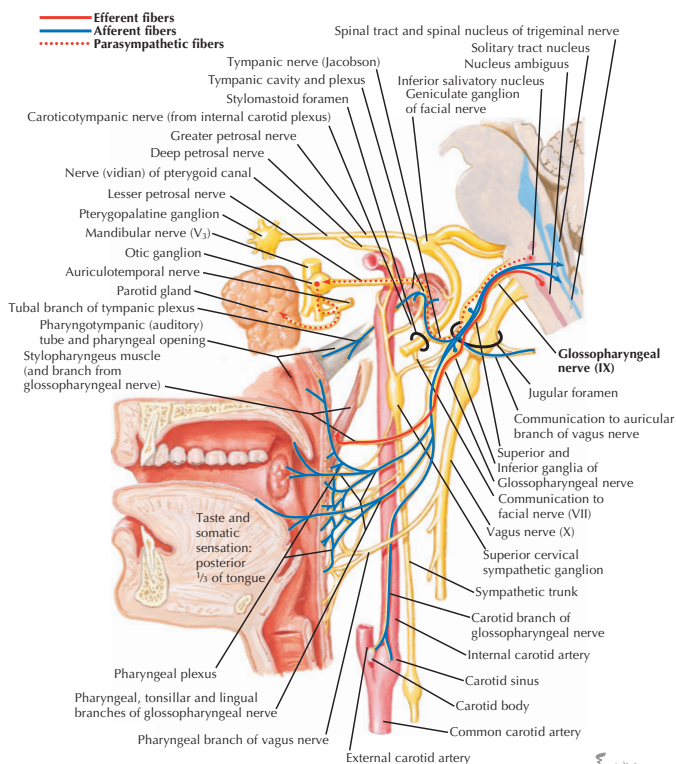
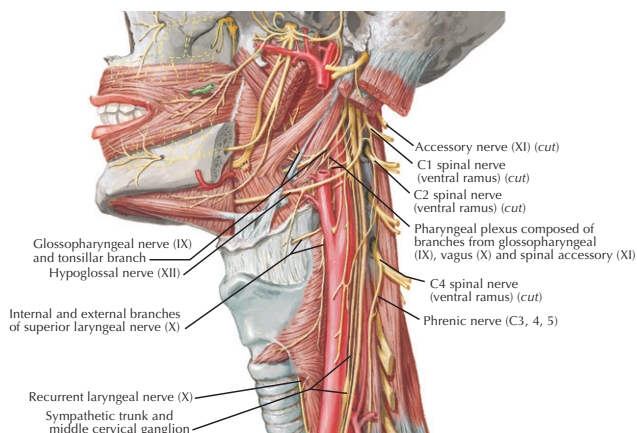
Nerve	Function	Course	Sensory	Motor
Cranial part of the spinal accessory	Contributes with the pharyngeal branch of the vagus to supply the major portion of the motor innervation of the muscles of the pharynx	Emerges as 4 or 5 branches just inferior to the roots of the vagus n. Passes laterally to the jugular foramen, where it merges with fibers of the spinal part of the spinal accessory While united for a short distance, it also is connected by 1 or 2 branches with the inferior ganglion of the vagus It then exits through the jugular foramen, separates from the spinal part, and continues over the surface of the inferior ganglion of the vagus to be distributed mainly to the pharyngeal branches of the vagus		Aids the pharyngeal branch of the vagus n.

## OTHER INNERVATION OF THE PHARYNX

Nerve	Function	Course	Sensory	Motor
Recurrent laryngeal branch of the vagus	A small contributor to the motor innervation of the muscles of the pharynx Provides significant innervation to the larynx	Branch of the vagus Wraps around the aorta posterior to the ligamentum arteriosum on the left side Wraps around the right subclavian a. on the right side Ascends on the lateral side of the trachea until reaching the pharynx, where it passes deep to the inferior constrictor to reach the larynx		Part of the inferior constrictor
Pharyngeal	A small sensory nerve	Arises from the maxillary division of the trigeminal in the pterygopalatine fossa Passes posteriorly through the pharyngeal canal with the artery to enter the nasopharynx	Supplies sensory fibers to the nasopharynx and the auditory tube	



## OTHER INNERVATION OF THE PHARYNX *CONTINUED*



*F. Netter M.D.*

## Clinical Correlate

### DEGLUTITION

*Deglutition*, or swallowing, is a combination of voluntary and involuntary muscular contractions to move a bolus of food from the oral cavity to the esophagus

Deglutition begins when the tip of the tongue is placed into contact with the anterior portion of the palate and the bolus is pushed posteriorly

The soft palate begins to elevate, and Passavant's ridge starts to form in the posterior wall of the pharynx and moves closer to the soft palate

As more of the tongue is pushed against the hard palate, the bolus is moved into the oropharynx, and the soft palate makes contact with Passavant's ridge to close off the nasopharynx from the oropharynx

Once the bolus reaches the epiglottic vallecula, the hyoid and larynx are elevated and the tip of the epiglottis is tipped down slightly over the laryngeal aditus

A "stripping wave" is created on the posterior wall of the pharynx to help move the bolus

Bolus splits into 2 streams that flow on either side of the epiglottis and unite to enter the esophagus

The soft palate is pulled down by the palatopharyngeus muscles and the pressure of the wave from the movement of the bolus, while the stripping wave continues to help move the bolus from the oropharynx

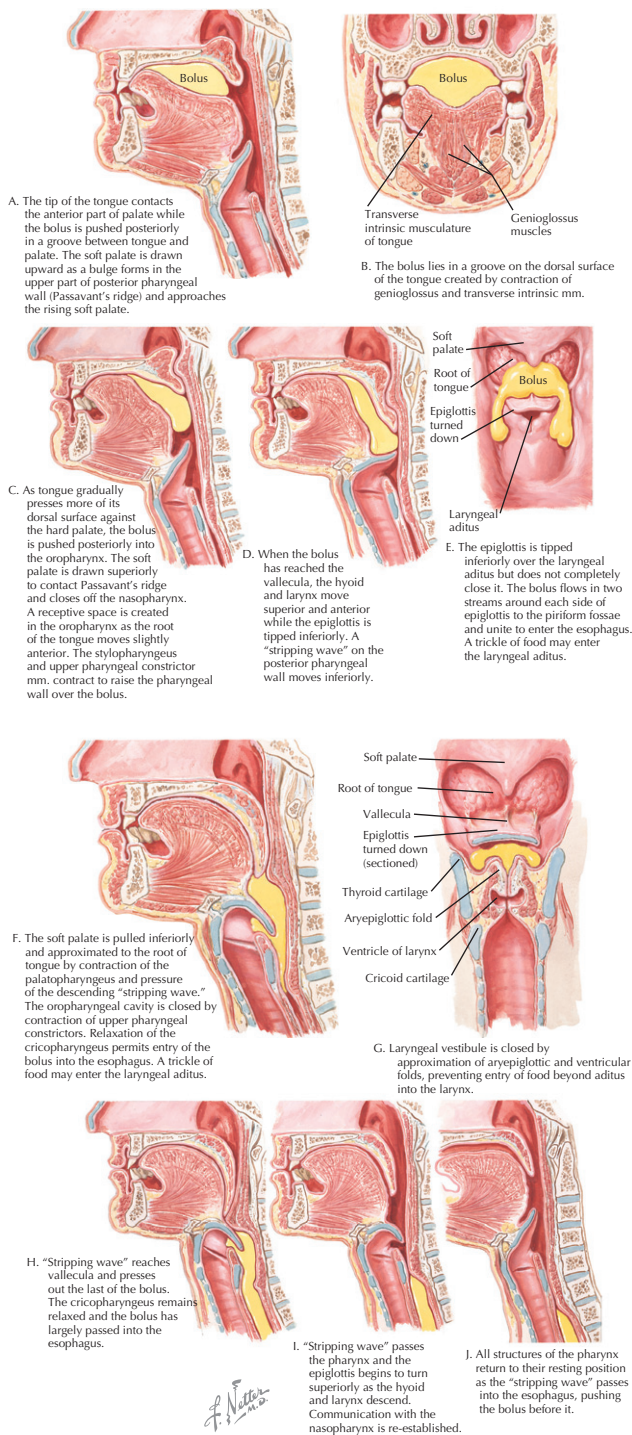
The cricopharyngeal portion of the inferior constrictor relaxes to help the bolus enter the esophagus

Laryngeal vestibule and rima glottidis are closed to prevent the bolus from entering the larynx

Stripping wave empties the last of the bolus from the epiglottic vallecula, and the major portion of the bolus is already in the esophagus

All structures return to their initial position as the stripping wave moves into the esophagus

## DEGLUTITION CONTINUED



## CHAPTER 16

# LARYNX

Overview and Topographic Anatomy	420
Cartilages	422
Membranes and Ligaments	428
Muscles	429
Vascular Supply	431
Nerve Supply	433
Clinical Correlates	435

## 16 Overview and Topographic Anatomy

### GENERAL INFORMATION

*Larynx:* connection between the pharynx and the trachea

Prevents foreign bodies from entering the airways

Designed for the production of sound (phonation)

Shorter in women and children

Formed by 9 cartilages: 3 paired and 3 unpaired

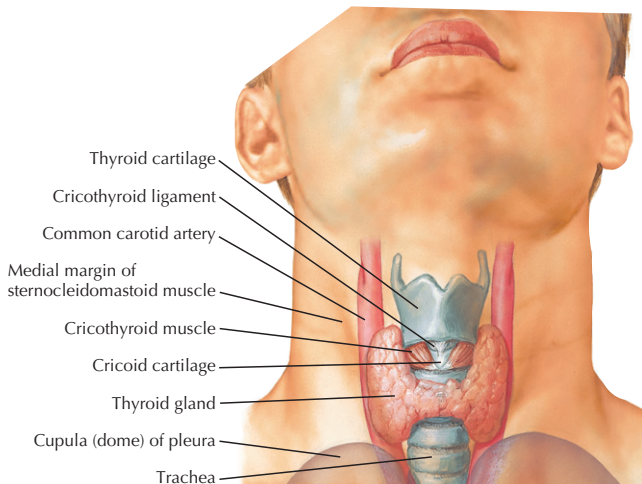
Located in the midline opposite the 3rd to the 6th cervical vertebrae

Regions of the larynx:

- Vestibule
- Ventricle
- Infraglottic

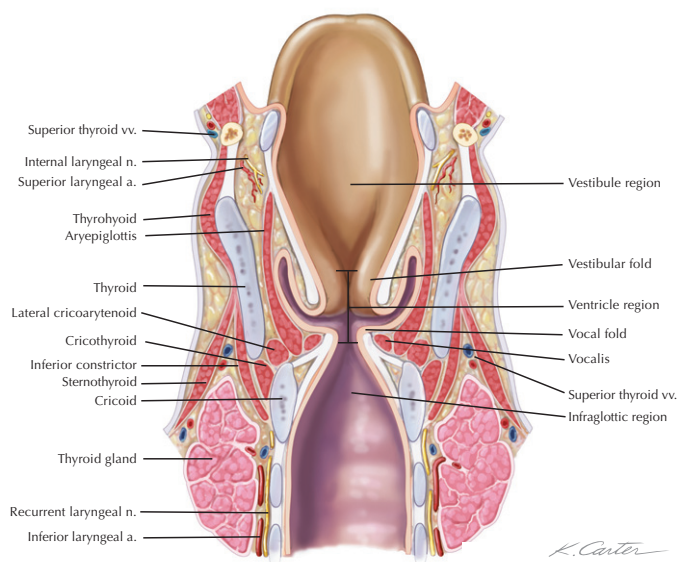
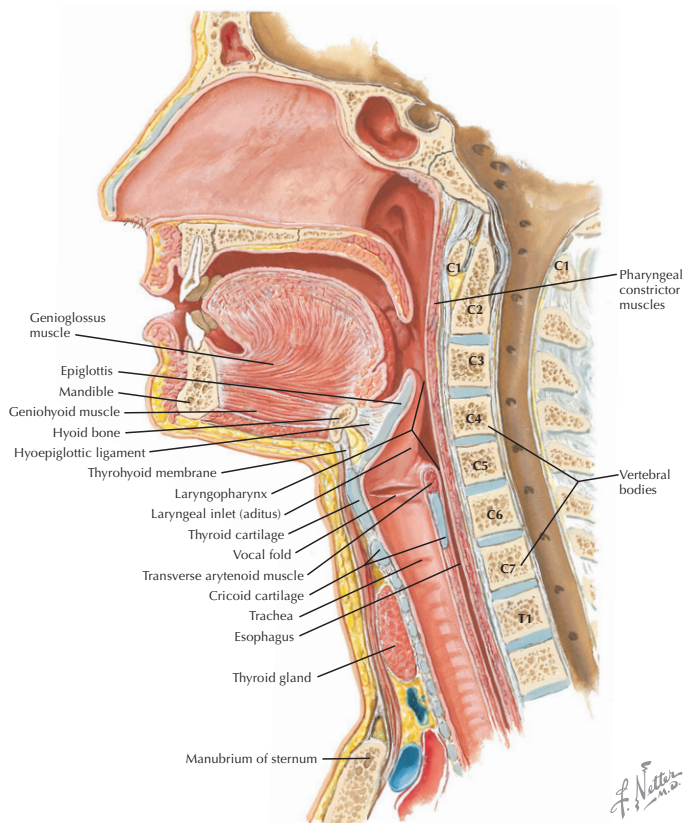
*Relations of the Larynx*

- Anterolateral—infrahyoid muscles, platysma
- Lateral—lobes of the thyroid gland, carotid sheath
- Posterior—it forms the anterior wall of the laryngopharynx
- Superior—base of tongue and vallecula
- Inferior—trachea





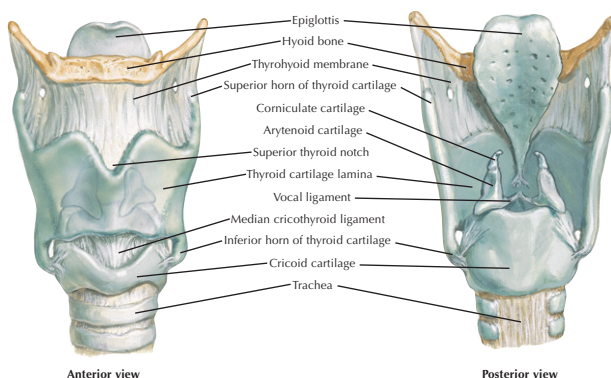
## GENERAL INFORMATION *CONTINUED*



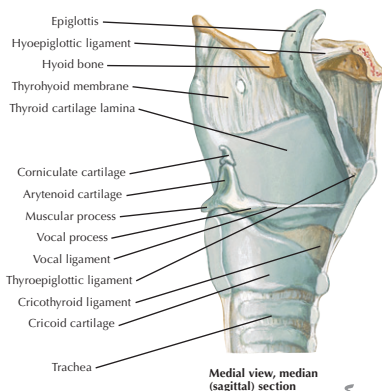
# 16 Cartilages

## GENERAL INFORMATION

Cartilage	Cartilage Type	Paired	Comments
Thyroid	Hyaline	No	Largest of the laryngeal cartilages Connects to the hyoid bone via the thyrohyoid membrane, which allows the internal laryngeal n. and superior laryngeal vessels to pass through to enter the larynx Lies between C4 and C6
Cricoid			Only complete ring of cartilage in the respiratory system Signet in shape Both intrinsic and extrinsic laryngeal muscles attach to the cricoid Lies at C6
Arytenoid			Forms framework of the true vocal cord
Epiglottis	Elastic	No	Helps prevent foreign bodies from entering the larynx
Corniculate (minor)		Yes	Minor cartilages that lie in the aryepiglottic fold
Cuneiform (minor)			



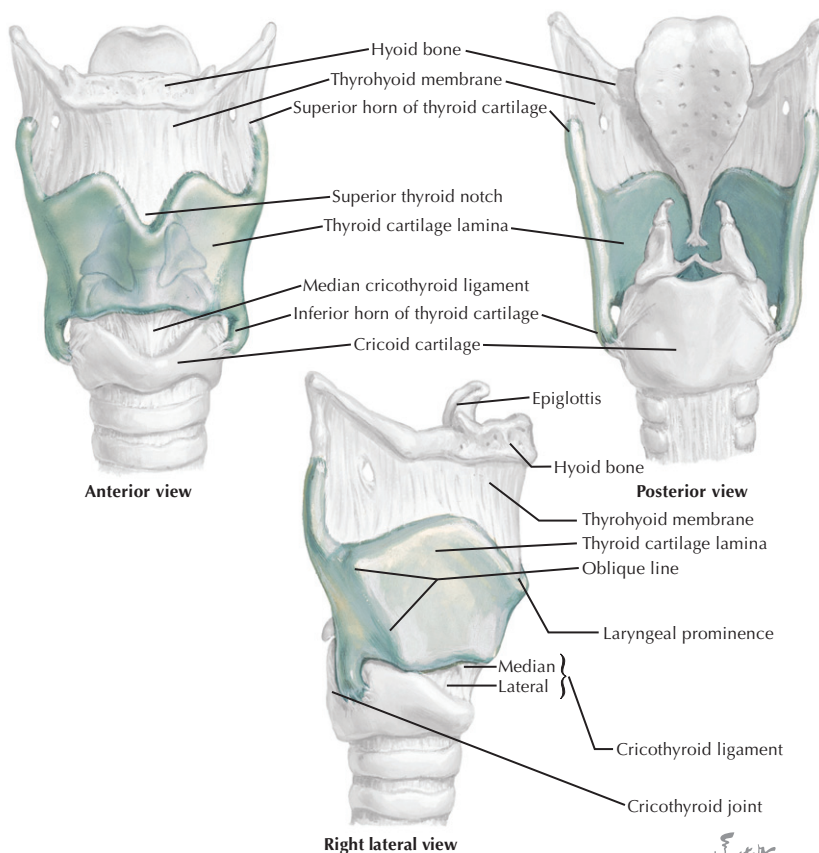
### Anterosuperior view



# Cartilages

## THYROID CARTILAGE

Anatomic Feature	Comments
2 lateral laminae	2 plates that meet at an acute angle in the anterior midline
Laryngeal prominence	Also known as the Adam's apple Formed by the fusion of the 2 lateral lamina Larger in males than in females
Thyroid notch	Superior portion of the laryngeal prominence, which forms a V shape
Superior tubercle	Superior border of the oblique line
Oblique line	Attachment for sternothyroid, thyrohyoid, and inferior constrictor mm. (extrinsic muscles of the larynx)
Inferior tubercle	Inferior border of the oblique line
Superior horn	Provides lateralmost attachment for the thyrohyoid membrane
Inferior horn	Articulates with the cricoid to form the cricothyroid joint

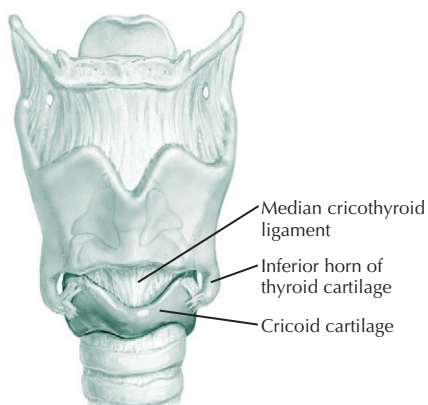


*F. Netter M.D.*

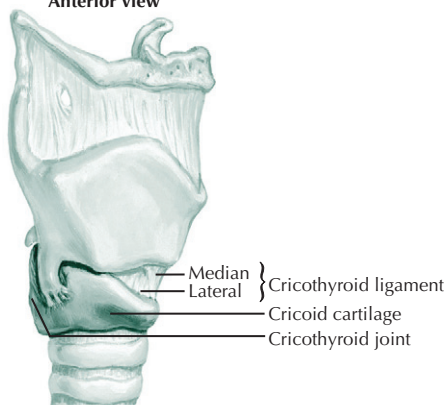
# 16 Cartilages

## CRICOID CARTILAGE

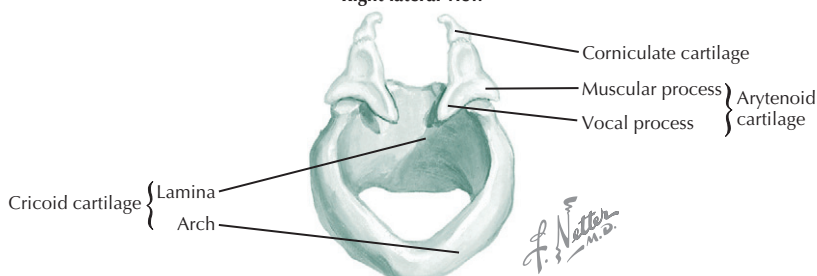
Anatomic Feature	Comments
Arch (anteriorly)	1 cm long Narrow
Lamina (posteriorly)	2 to 3 cm long
Superior border (on the lamina)	Articulates with the arytenoid cartilage to form the cricoarytenoid joint
Inferior border (on the lamina)	Articulates with the inferior cornu of the thyroid cartilage to form the cricothyroid joint



Anterior view



Right lateral view



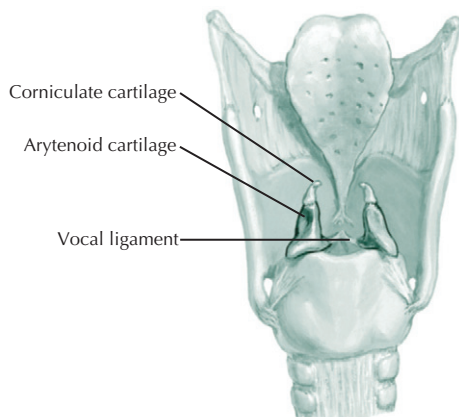
Anterosuperior view

*F. Netter M.D.*

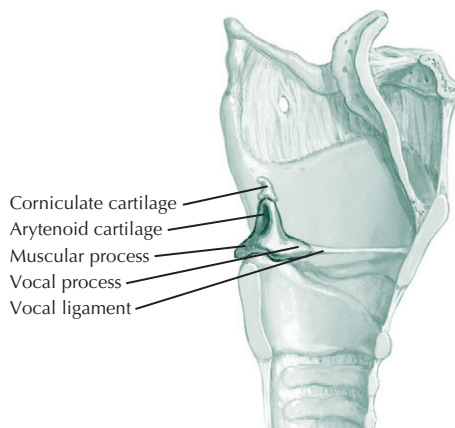
# Cartilages

## ARYTENOID CARTILAGE

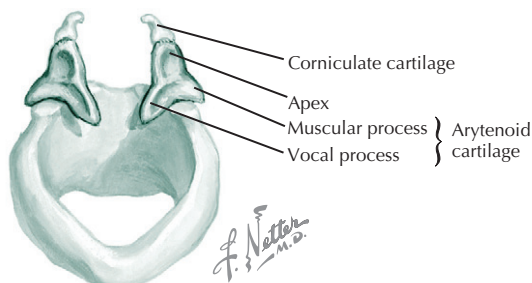
Anatomic Feature	Comments
3 processes: • Muscular (lateral) • Vocal (anterior) • Apex (superior)	Base articulates with cricoid to form the cricoarytenoid joint Vocal process gives rise to true vocal cord



Posterior view



Medial view, median (sagittal) section



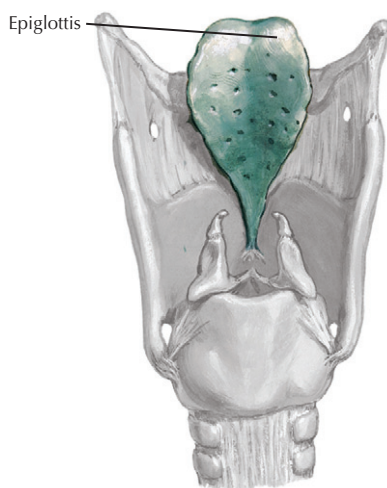
Anterosuperior view



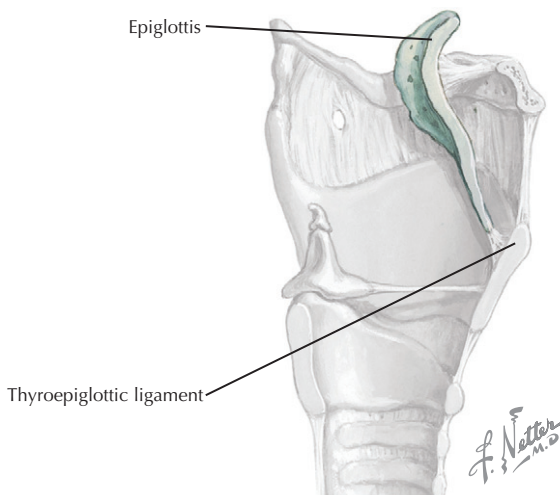
## 16 Cartilages

### EPIGLOTTIS

Anatomic Feature	Comment
Epiglottic tubercle	Pear-shaped



Posterior view

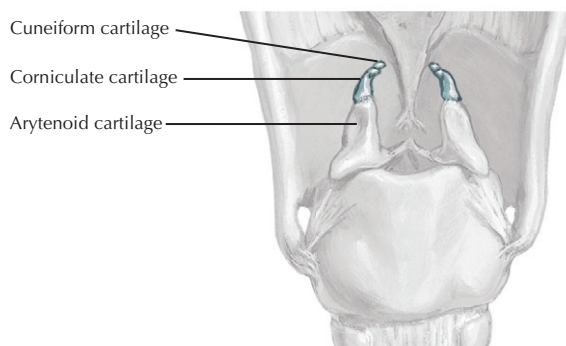


Medial view, median (sagittal) section

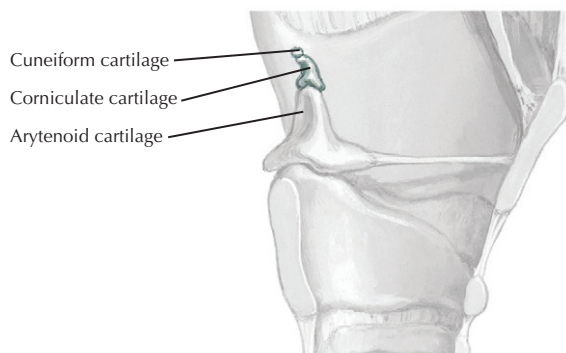
# Cartilages

## MINOR CARTILAGES

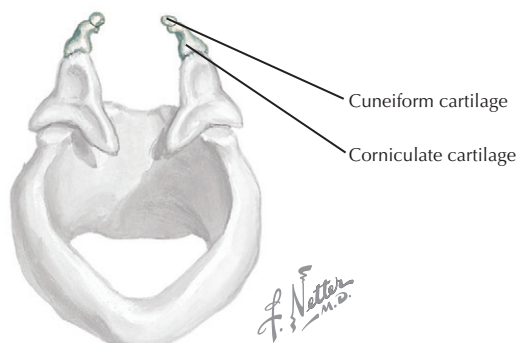
Cartilage	Comments
Corniculate	Lies on the apex of the arytenoid cartilage Helps support the aryepiglottic fold
Cuneiform	Lies superior to the corniculate cartilage Helps support the aryepiglottic fold



Posterior view



Medial view, median (sagittal) section



Anterosuperior view

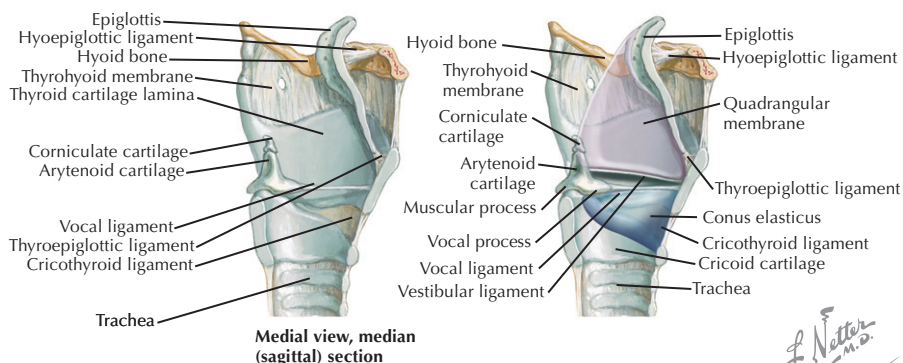
# 16 Membranes and Ligaments

## MAJOR EXTRINSIC LIGAMENTS

Ligament(s)	Location	Comments
2 lateral thyrohyoid ligaments 1 median thyrohyoid ligament Thyrohyoid membrane	Thyroid cartilage to hyoid bone	The thyrohyoid membrane allows passage of the internal laryngeal n. and superior laryngeal vessels
Median cricothyroid ligament	Cricoid cartilage to thyroid cartilage	Primary site for establishing an emergency airway
Cricotracheal ligament	Cricoid cartilage to trachea	Attaches the cricoid cartilage to the first tracheal ring May be used in establishing an emergency airway

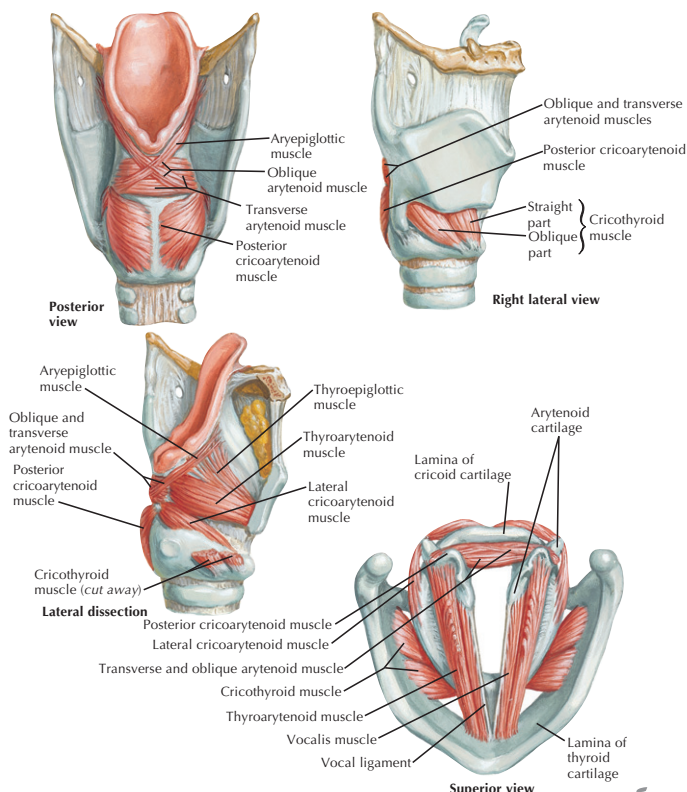
## MAJOR INTRINSIC LIGAMENTS

Ligament	Location	Comments
Vocal ligament	Arytenoid (vocal) to thyroid cartilage	Help form <i>true</i> vocal cord
Conus elasticus	Superior—thyroid, vocal lig., arytenoid (vocal) Inferior—upper border of cricoid	
Quadrangular membrane	Arytenoid to epiglottis	Help form <i>false</i> vocal cord
Vestibular ligament	Free edge of quadrangular membrane	



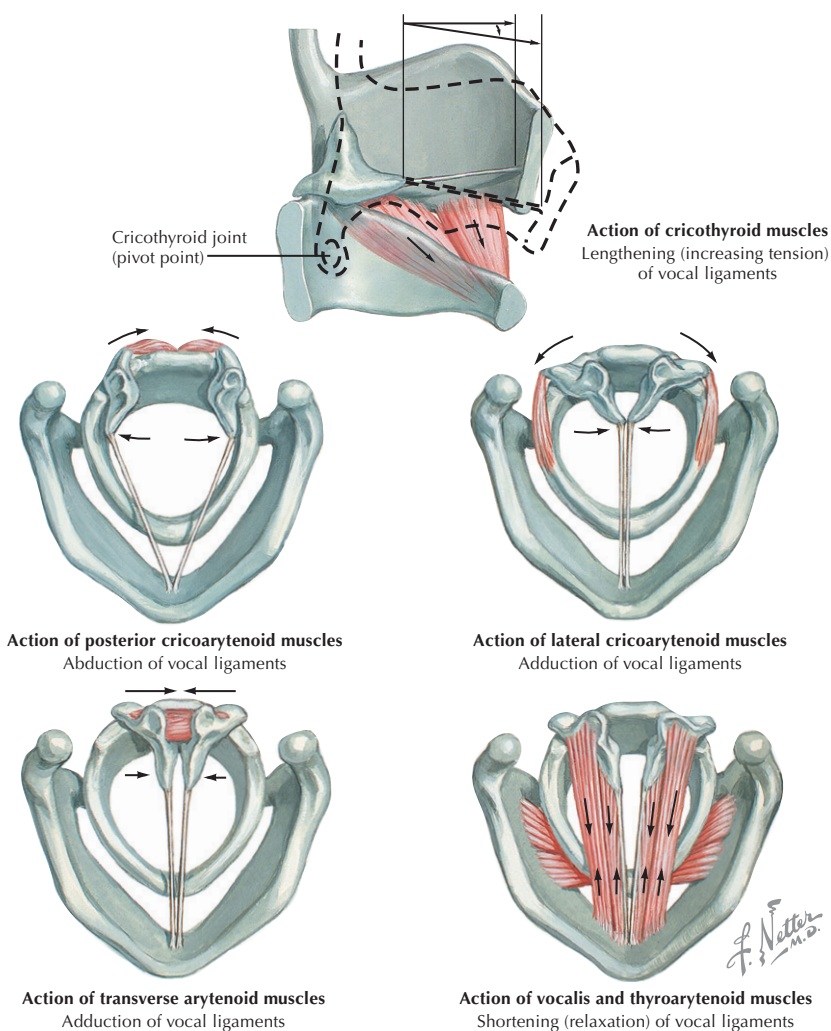
## OVERVIEW

Muscle	Origin	Insertion	Action(s)	Nerve Supply
Cricothyroid	Arch of cricoid	Lamina and inferior cornu of thyroid	Increases tension on vocal ligaments	External laryngeal n.
Thyroarytenoid	Angle of thyroid cartilage	Arytenoid (vocal process)	Decreases tension on vocal ligaments	Recurrent laryngeal n.
Posterior cricoarytenoid	Lamina of cricoid	Arytenoid (muscular process)	Opens rima glottidis	
Lateral cricoarytenoid	Arch of cricoid (lateral portion)		Closes rima glottidis	
Transverse arytenoid	Arytenoid (muscular process)	Opposite arytenoid (muscular process)		
Oblique arytenoid		Opposite arytenoid (apex)		
Aryepiglotticus	Arytenoid (apex)	Epiglottis	Helps close laryngopharyngeal opening	
Thyroepiglotticus	Thyroid lamina			



## OVERVIEW *CONTINUED*

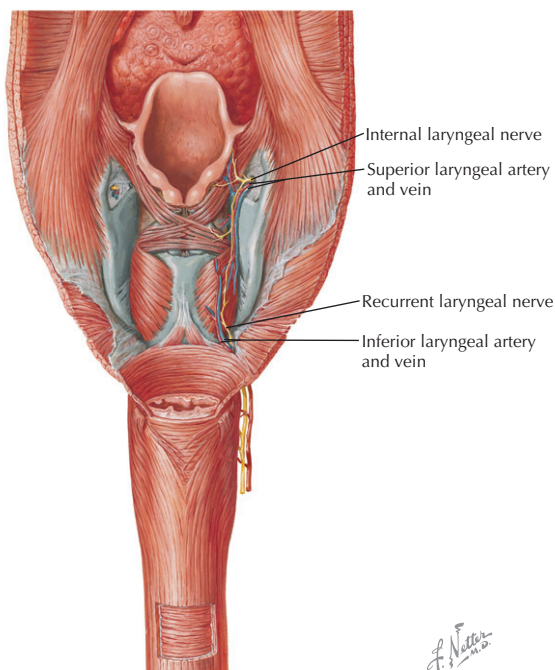
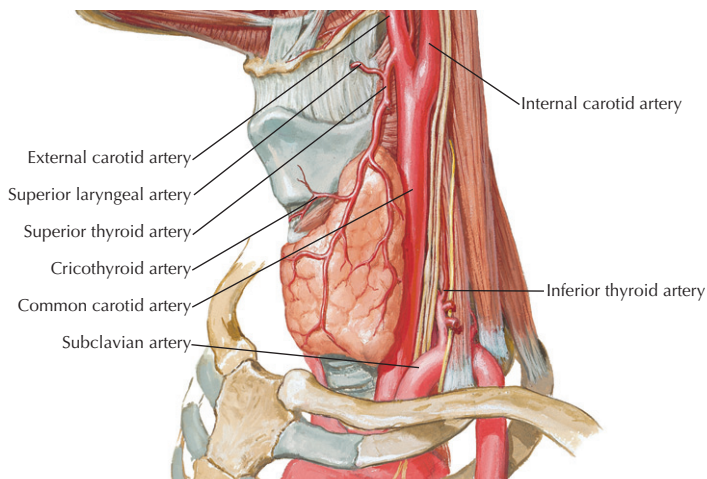
SUMMARY OF MUSCLE ACTIONS			
Altering the Rima Glottidis		Altering Tension on the Vocal Cords	
Muscle	Action	Muscle	Action
Posterior cricoarytenoid	<i>Opens</i> the rima glottidis	Cricothyroid	<i>Increasing</i> tension
Transverse arytenoids Oblique arytenoids Lateral cricoarytenoid	<i>Closes</i> the rima glottidis	Thyroarytenoid	<i>Decreasing</i> tension





## ARTERIAL SUPPLY

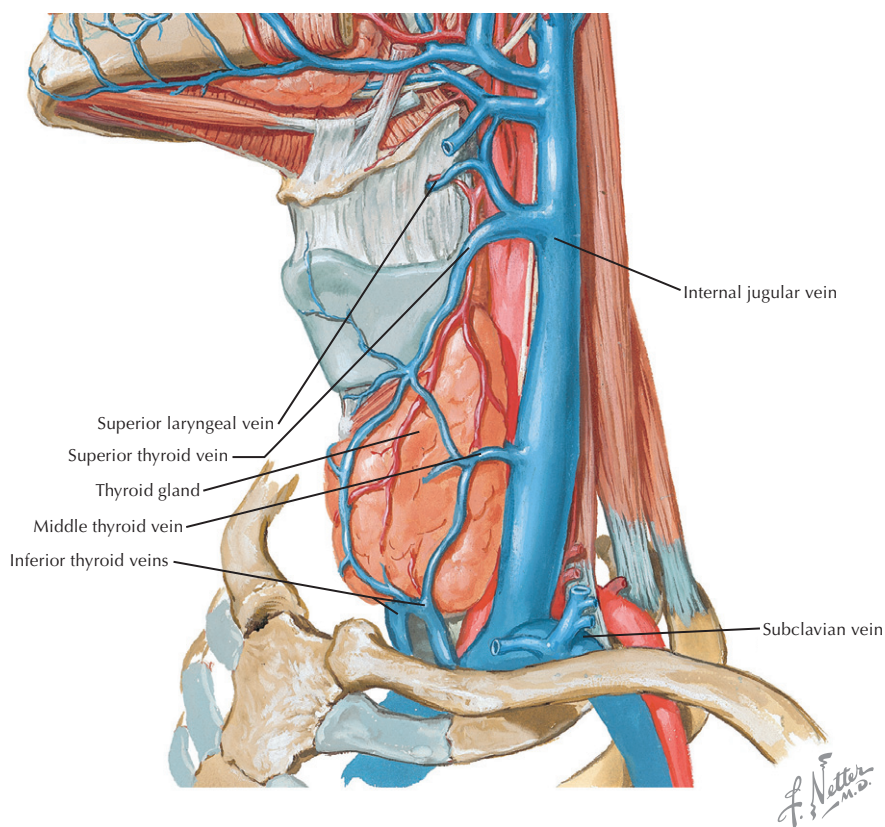
Artery	Source	Course
Superior laryngeal	Superior thyroid a., which arises from the external carotid a.	Passes through the thyrohyoid membrane with the internal laryngeal n. to enter the deep surface of the larynx
Inferior laryngeal	Inferior thyroid a., which arises from the thyrocervical trunk	Passes superiorly on the trachea to reach the posterior border of the larynx Lies immediately deep to the inferior constrictor m. traveling beside the recurrent laryngeal n.



# 16 Vascular Supply

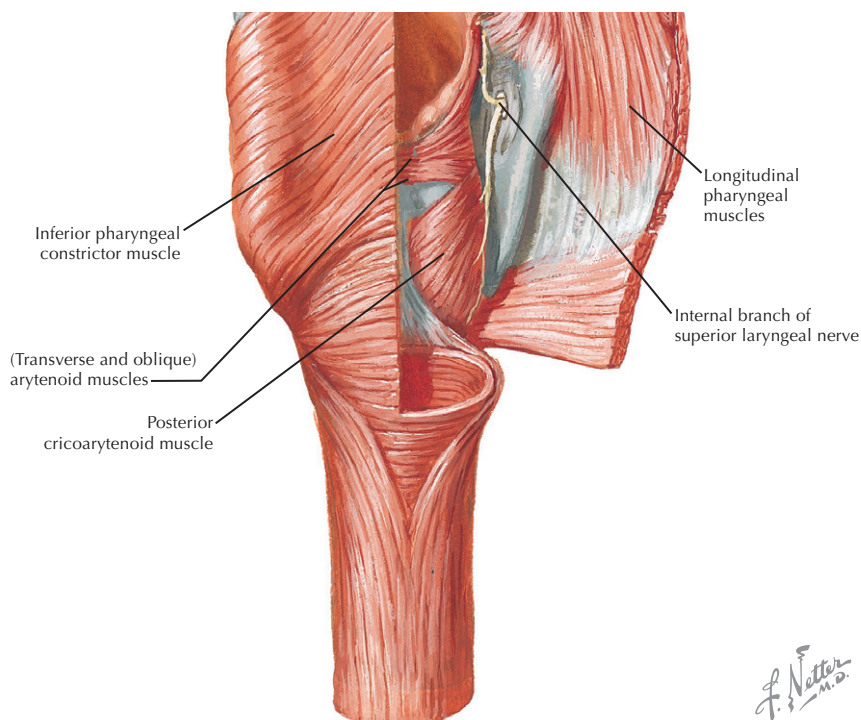
## VENOUS DRAINAGE

Vein	Course
Superior laryngeal	Begins in the deep surface of the superior part of the larynx Passes with the superior laryngeal a. and the internal laryngeal n. Passes through the thyrohyoid membrane to lie on the superficial surface of the larynx Drains into the superior thyroid v., which drains into the internal jugular v.
Inferior laryngeal	Arises within the deep surface of the inferior part of the larynx Passes with the inferior laryngeal a. and the recurrent laryngeal n. Passes inferiorly deep to the inferior constrictor to exit the larynx Drains into the inferior thyroid v., which drains into the brachiocephalic v.



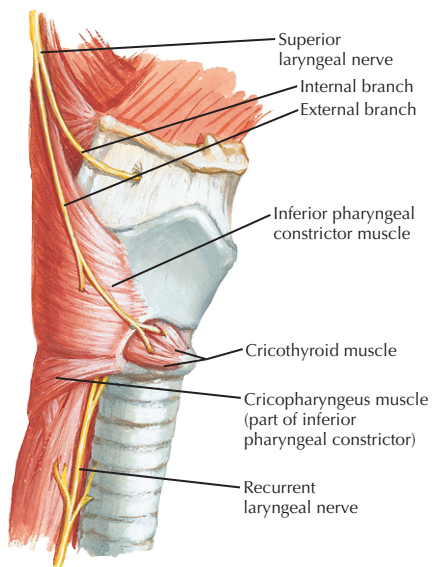
## MOTOR AND SENSORY BRANCHES FROM THE VAGUS NERVE

Nerve	Type	Sensory Target	Muscles Innervated	Comments
Internal laryngeal	Sensory	Membranes above the false vocal folds		Branch of superior laryngeal nerve from the vagus
Recurrent laryngeal	Sensory and motor	Membranes below the false vocal folds	Thyroarytenoid Posterior cricoarytenoid Lateral cricoarytenoid Transverse arytenoid Oblique arytenoid Aryepiglotticus Thyroepiglotticus	Branch of the vagus Wraps around the aorta posterior to the ligamentum arteriosum on the left side Wraps around the right subclavian artery on the right side Ascends on the lateral aspect of the trachea until reaching the pharynx, where it passes deep to the inferior constrictor to reach the larynx
External laryngeal	Motor		Cricothyroid	Branch of superior laryngeal nerve from the vagus

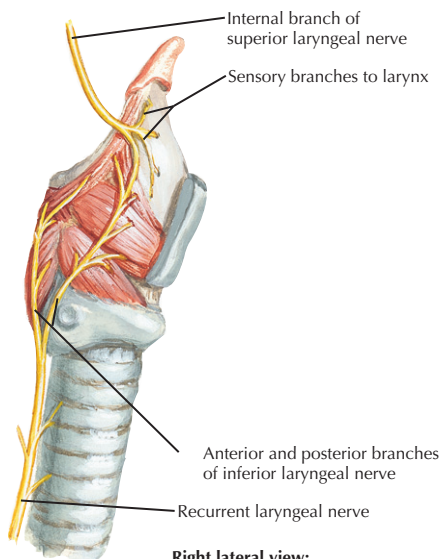


# 16 Nerve Supply

## MOTOR AND SENSORY BRANCHES FROM THE VAGUS NERVE *CONTINUED*



Right lateral view



Right lateral view:  
thyroid cartilage lamina removed

*F. Netter M.D.*

## Clinical Correlate

### EMERGENCY AIRWAY: CRICOTHYROTOMY

*Cricothyrotomy*: a procedure for establishing an emergency airway when other methods are unsuitable

Once the anatomy of the larynx is identified, the procedure can be performed with 2 incisions:

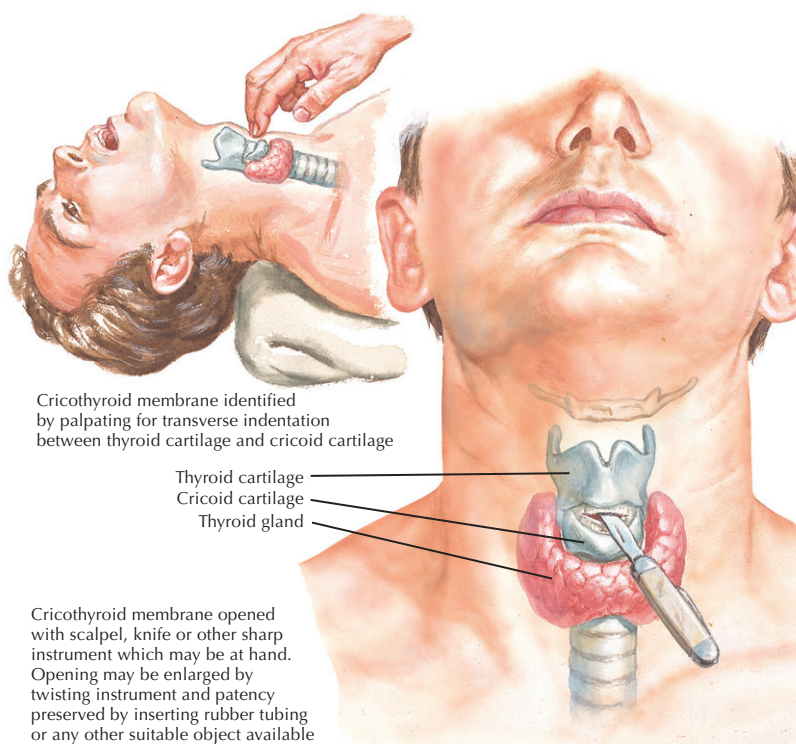
- Incision through the skin
- Incision through the cricothyroid membrane

The correct location for the incision is easiest to find by identifying the thyroid notch on the thyroid cartilage

By sliding the examining finger in an inferior direction, the groove between the thyroid and cricoid cartilages can be located

A 3-cm vertical incision is made through the skin, and the thyrohyoid membrane is located

A small midline incision is made, and a tracheostomy tube is inserted to establish an airway



*F. Netter M.D.*



**LARYNGITIS**

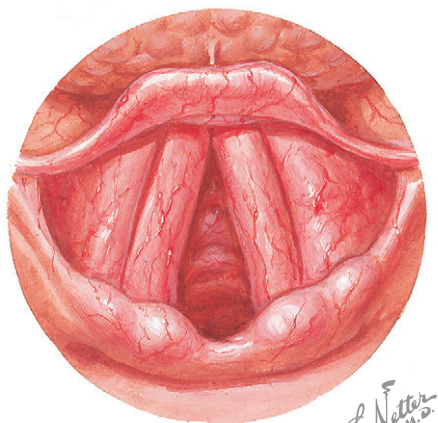
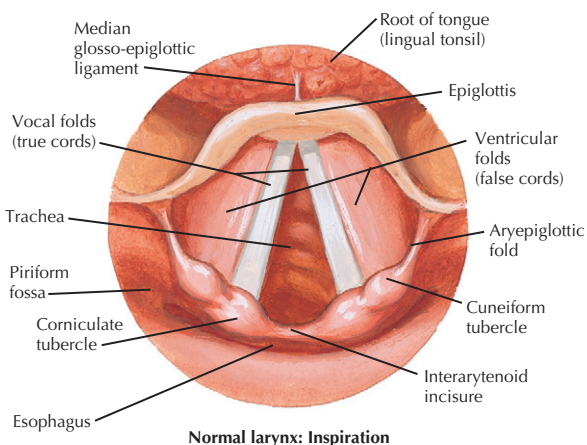
*Laryngitis*: an inflammation of the vocal cords in the larynx that typically does not persist longer than 7 days

Characterized by a weak and hoarse voice, sore throat, and cough

Most common cause is a viral infection, although it may be caused by a bacterial infection

Can also be caused by excessive yelling (such as cheering at a sporting event) and smoking

Because most cases of laryngitis are viral in nature, antibiotics generally are not used as treatment



Acute laryngitis

## CHAPTER 17

# CERVICAL FASCIA

Overview and Topographic Anatomy	438
Fascia of the Neck	440
Fascial Spaces	443
Clinical Correlates	448

## 17 Overview and Topographic Anatomy

### GENERAL INFORMATION

**Fascia:** a band of connective tissue that surrounds structures (such as enveloping muscles), giving rise to potential tissue spaces and pathways that allow infection to spread

#### *Superficial Fascia*

Immediately deep to the skin

Contains fat

#### *Deep Fascia*

Deep to the superficial fascia

Aids muscle movements

Provides passageways for nerves and vessels

Provides attachment for some muscles

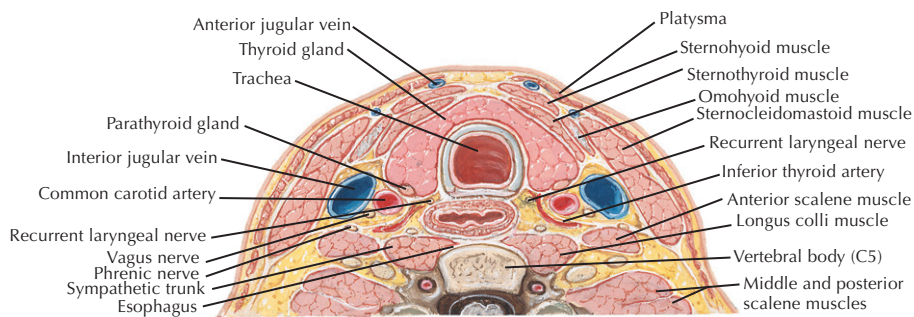
In the neck, it is divided into 4 regions:

- Visceral region
- Musculoskeletal region
- 2 neurovascular compartments

Also divided into 4 layers:

- Superficial layer of deep cervical fascia (investing layer of deep cervical fascia)
- Middle layer of deep cervical fascia
- Deep layer of deep cervical fascia
- Carotid sheath (composed by the contribution of all 3 layers of deep cervical fascia)

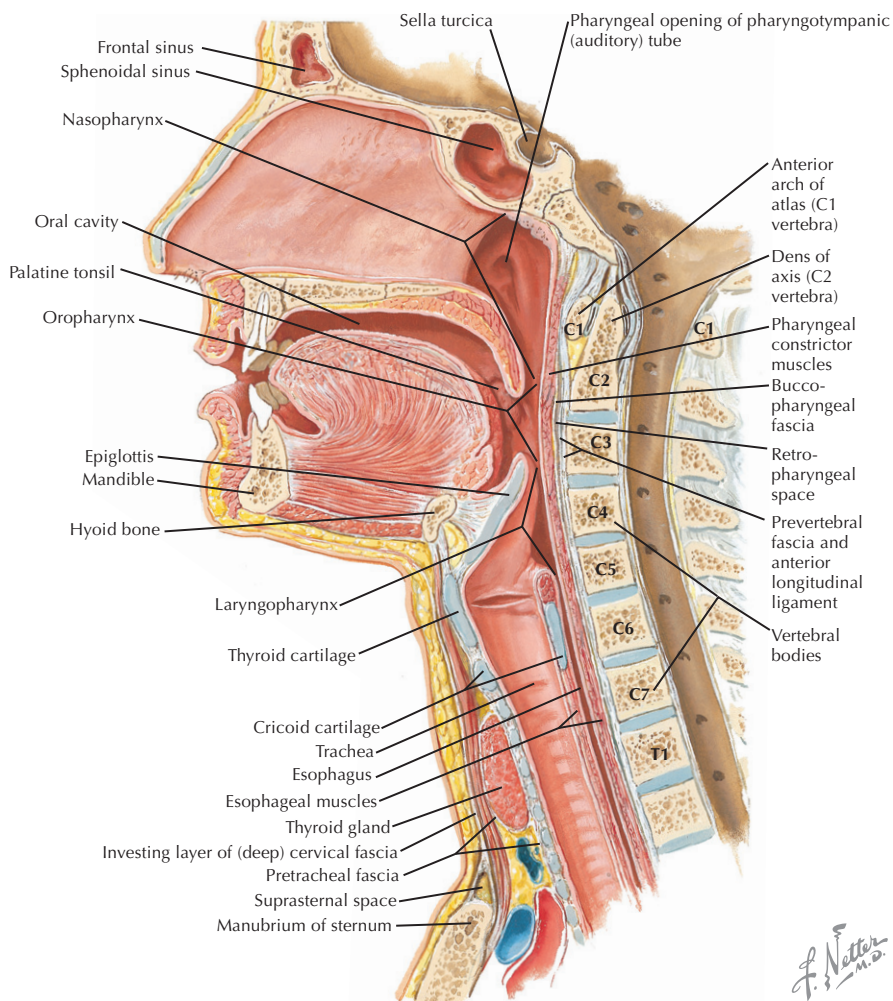
There is no deep fascia in the face, which allows free spread of fluid



*F. Netter M.D.*

# Overview and Topographic Anatomy

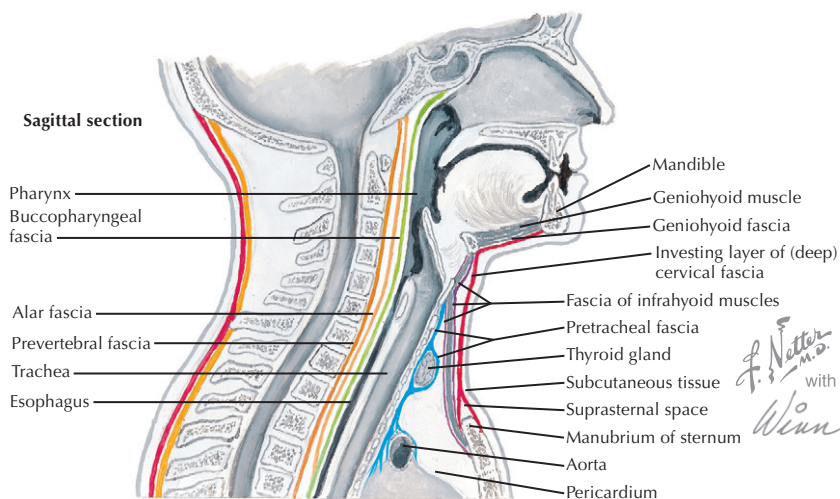
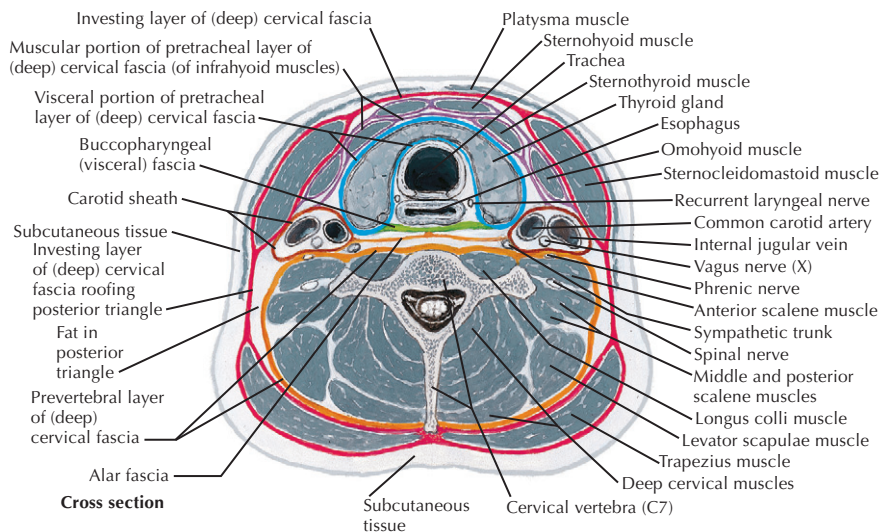
## GENERAL INFORMATION *CONTINUED*



# 17 Fascia of the Neck

## SUPERFICIAL FASCIA

Superficial fascia lies deep to the skin and contains the cutaneous vessels and nerves  
In the neck, the platysma muscle lies within the superficial fascia





# Fascia of the Neck

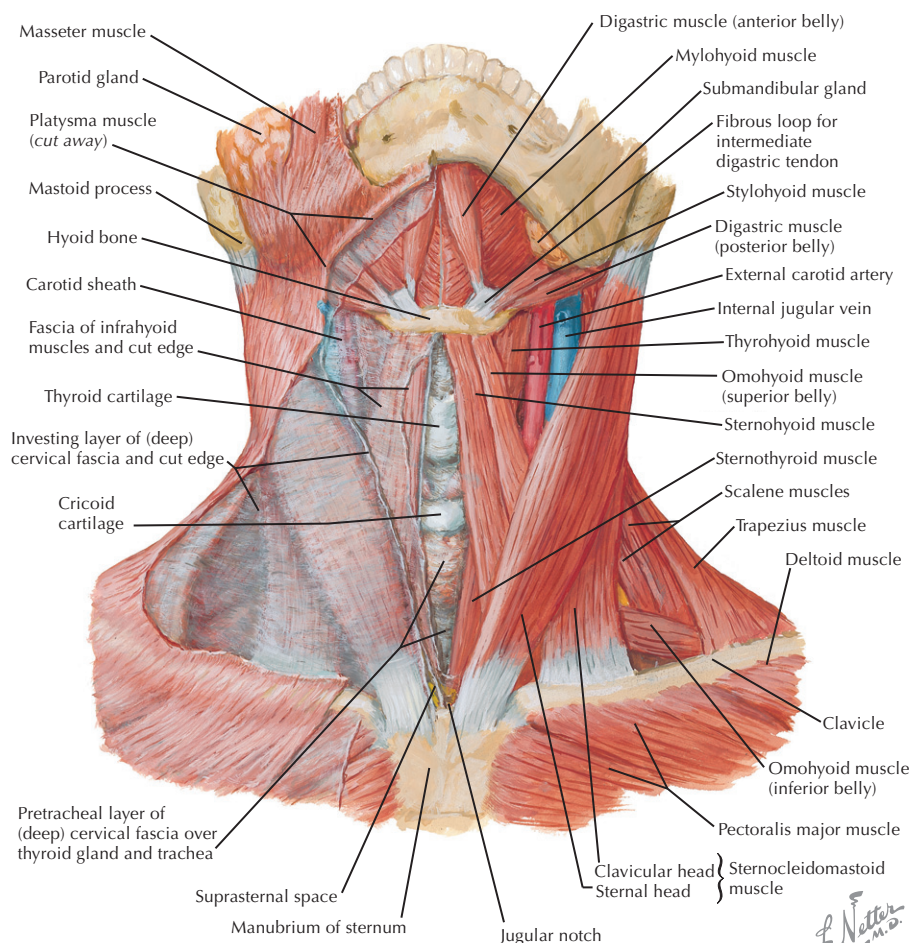
## DEEP FASCIA

SUPERFICIAL LAYER OF DEEP CERVICAL FASCIA			
Layer	Location	Attachment	Comments
Superficial layer of deep cervical fascia (also known as the investing layer of deep cervical fascia)	Immediately deep to the superficial fascia Encircles the neck completely When the layer approaches the sternocleidomastoid and the trapezius mm., it splits to lie on the superficial and deep surfaces	Anterior—chin, hyoid, sternum Posterior—spinous process of cervical vertebra and the ligamentum nuchae Superior—external occipital protuberance, superior nuchal line, mastoid process, inferior border of the zygomatic arch, inferior border of the mandible from the angle to the midline Inferior—sternum (splitting into anterior and posterior parts), clavicle, acromion of the scapula	Forms the roof of the posterior triangle In the area between the mastoid process and the angle of the mandible, this layer splits around the parotid gland to form the parotid fascia Helps define the masticator space
MIDDLE LAYER OF DEEP CERVICAL FASCIA			
Layer	Location	Attachment	Comments
Muscular portion: <i>infrahyoid fascia</i>	Completely surrounds the strap muscles of the neck	Superior—hyoid bone and thyroid cartilage Inferior—sternum	Is continuous across the midline
Visceral portion: <i>buccopharyngeal fascia</i>	Deep to the superficial layer of deep cervical fascia posterior to the pharynx	Superior—base of the skull Inferior—superior mediastinum where the middle layer of deep cervical fascia joins the alar fascia	Posterior to the pharynx and the esophagus
Pretracheal layer of fascia	Deep to the superficial layer of deep cervical fascia	Superior—larynx Inferior—fibrous pericardium in the superior mediastinum of the thorax	Forms a covering around the visceral structures in the neck, such as the thyroid gland, esophagus, and trachea
DEEP LAYER OF DEEP CERVICAL FASCIA			
Layer	Location	Attachment	Comments
Prevertebral layer of fascia	Completely encircles the cervical portion of the vertebral column with its associated pre- and postvertebral muscles	Superior—base of skull Inferior—coccyx	Forms the floor of the posterior triangle Encloses the vertebral muscles Forms the axillary sheath
Alar fascia	An anterior slip of prevertebral fascia found between the middle layer of deep cervical fascia and prevertebral layers of deep cervical fascia	Superior—base of skull Inferior—merges with visceral portion of the middle layer of deep cervical fascia at about the level of T2	Separates the retropharyngeal space from the danger space

# 17 Fascia of the Neck

## DEEP FASCIA *CONTINUED*

COMBINATION OF ALL 3 LAYERS			
Layer	Location	Attachment	Comments
Carotid sheath	In the neck between the investing layer, pretracheal layer, and the prevertebral layer	Superior—base of skull Inferior—merges with connective tissue around arch of the aorta	Contains the internal or common carotid a., internal jugular v., and vagus n.



# Fascial Spaces

## GENERAL INFORMATION

Layers of fascia "create" potential fascial spaces

All are filled by loose areolar connective tissue

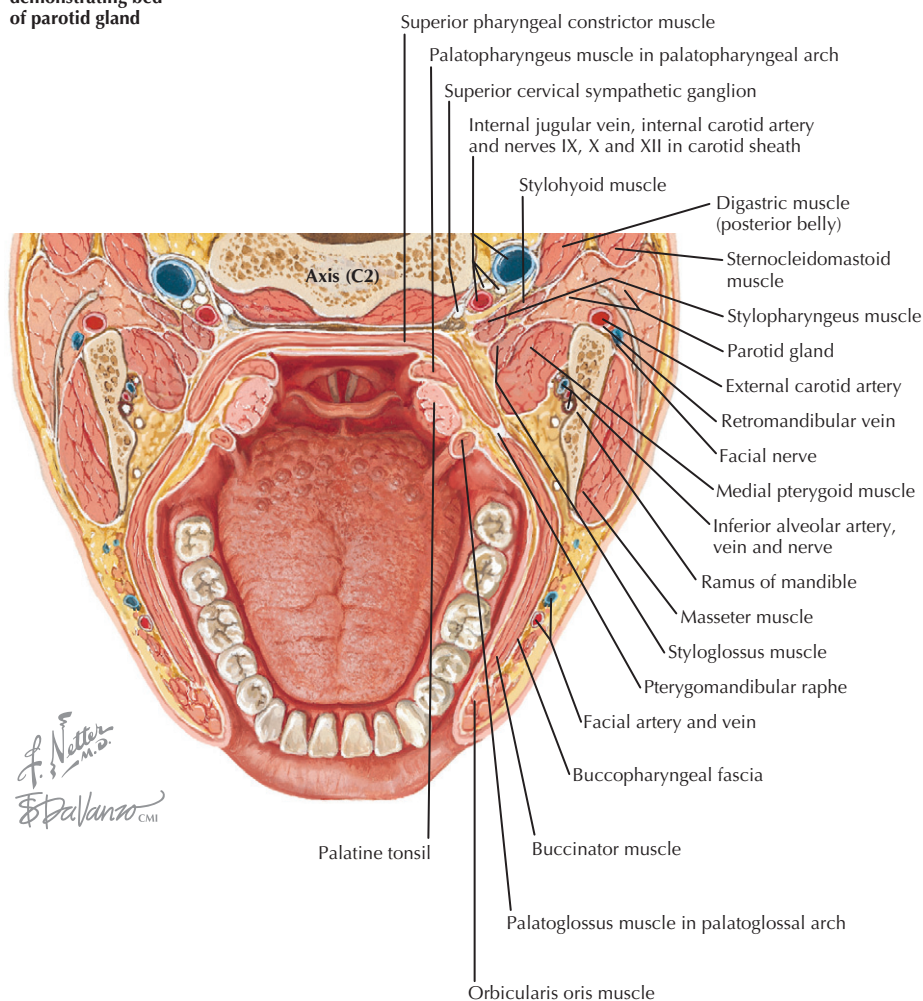
The hyoid bone is the most important anatomic structure in the neck that limits the spread of infection

Most are divided into spaces in relation to the hyoid bone:

- Suprahyoid
- Infrahyoid
- Entire length of the neck

Infections or other inflammatory conditions spread by the path of least resistance to reach the fascial spaces

Horizontal section  
below lingula of  
mandible (superior view)  
demonstrating bed  
of parotid gland

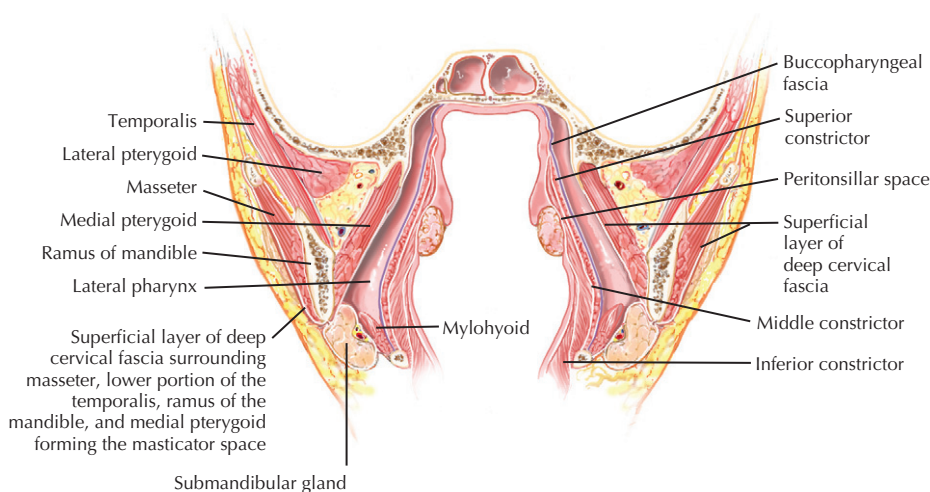


## SUPRAHYOID FASCIAL SPACES

Space	Location	Comments and Potential for Infection
Submandibular	Anterior and lateral—mandible Posterior—hyoid bone Superior—mucosa of the floor of the oral cavity and the tongue Inferior—superficial layer of deep cervical fascia	The anterior part of the peripharyngeal spaces, which create a ring around the pharynx (the retropharyngeal and lateral pharyngeal spaces are the other components) Submandibular space is continuous with the lateral pharyngeal space Divided into 2 <i>parts</i> : <ul style="list-style-type: none"> <li>• Sublingual space</li> <li>• Submaxillary space</li> </ul>
<i>Sublingual</i>	Between the mucosa and the mylohyoid m. Anterior and lateral—mandible Posterior—muscles along the base of the tongue Superior—mucosa of the floor of the oral cavity and the tongue Inferior—mylohyoid m.	Contains the: <ul style="list-style-type: none"> <li>• Hypoglossal n.</li> <li>• Lingual n.</li> <li>• Sublingual gland</li> <li>• Deep part of the submandibular gland</li> <li>• Submandibular duct</li> </ul> Continuous with the submaxillary space along the posterior free border on the mylohyoid m.
<i>Submaxillary</i>	Between the mylohyoid m. and the superficial layer of deep cervical fascia On the superficial surface of the mylohyoid between the anterior and posterior bellies of the digastric m. and the mandible	Contains the: <ul style="list-style-type: none"> <li>• Submandibular gland</li> <li>• Anterior digastric m.</li> </ul> Continuous with the sublingual space along the posterior free border of the mylohyoid m. Because the roots of the 1st, 2nd, and 3rd molars are inferior to the attachment of the mylohyoid on the mandible, infections of these teeth may pass into the submandibular space, which is continuous with the lateral pharyngeal space
Lateral pharyngeal	On the lateral aspect of the pharynx, continuous with the retropharyngeal space posteriorly and the submandibular space anteriorly Extends from the base of the skull to the hyoid bone Extends in an anterosuperior direction to the pterygomandibular raphe Bounded medially by the middle layer of deep cervical fascia (buccopharyngeal fascia) covering the superior constrictor m. of the pharynx and laterally by the superficial layer of deep cervical fascia covering the medial pterygoid m. and the deep portion of the parotid gland	Continuous with the submandibular space anteriorly Continuous with the retropharyngeal space posteriorly Very susceptible to the spread of infections from the teeth, jaws, and pharynx, including the nasopharynx, adenoids, and tonsils
Masticator	Formed when the superficial layer of deep cervical fascia splits to enclose the ramus of the mandible and overlies the masseter m. on the lateral surface and the medial pterygoid m. and lower portion of the temporalis m. on the medial surface	Contains the: <ul style="list-style-type: none"> <li>• Masseter m.</li> <li>• Medial pterygoid m.</li> <li>• Lateral pterygoid m.</li> <li>• Lower portion (insertion) of the temporalis m.</li> <li>• Contents of the pterygomandibular space</li> </ul> Continuous with the temporal space
Temporal	Formed when the superficial layer of deep cervical fascia encloses the temporalis m.	Can be further subdivided into a superficial and a deep space Continuous with the masticator space

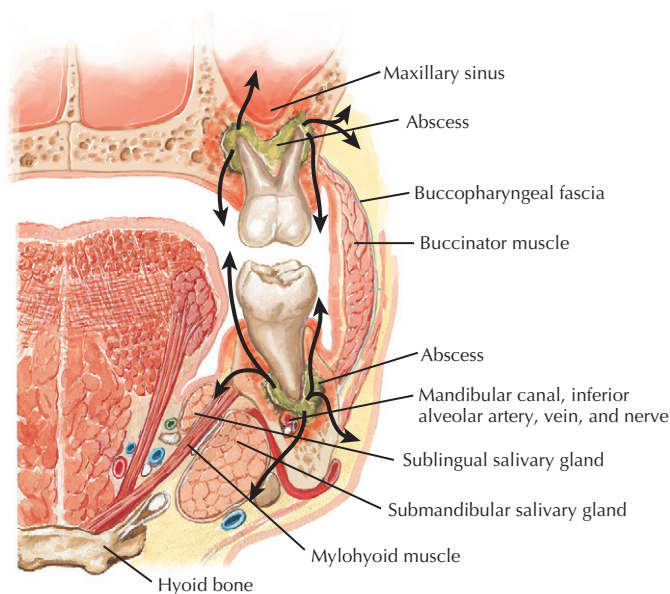
## SUPRAHYOID FASCIAL SPACES *CONTINUED*

Space	Location	Comments and Potential for Infection
Peritonsillar	Anterior—palatoglossal fold Posterior—palatopharyngeal fold Medial—palatine tonsil capsule Lateral—superior constrictor m.	Located within the wall of the pharynx Infections of the peritonsillar space may extend into the lateral pharyngeal space
Parotid gland [space]	Formed when the superficial layer of deep cervical fascia encloses the parotid gland as a capsule	The parotid fascia is weaker on the medial side, and infections of this space can break through the fascia to enter the lateral pharyngeal space
Submandibular gland [space]	Formed when the superficial layer of deep cervical fascia encloses the submandibular gland as a capsule	The inner layer of the capsule is weaker, and infections of this space tend to break through the fascia to this side



**Coronal section posterior to 1st molar tooth (anterior view)**

**Arrows indicate possible paths of infection**



*F. Netter M.D.*  
*Winn*  
*J. Palumbo C.M.D.*



# 17 Fascial Spaces

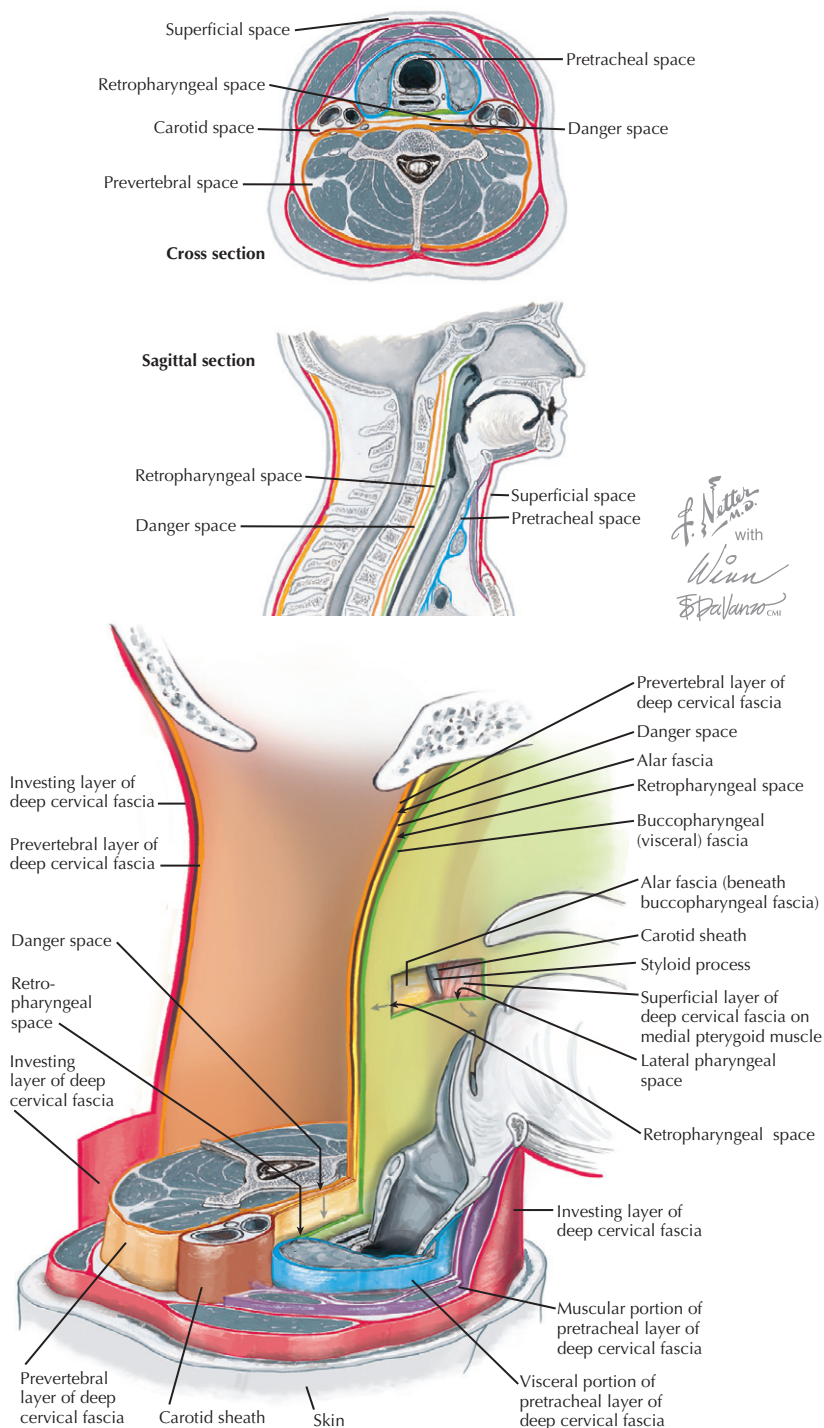
## INFRAHYOID FASCIAL SPACES

Space	Location	Comments and Potential for Infection
Pretracheal (anterior visceral)	Superior—larynx Inferior—superior mediastinum Completely surrounds the trachea and also contains the thyroid and esophagus	Usually infections spread to the pretracheal space only by puncturing the esophagus anteriorly or by a perforation in the retropharyngeal space

## FASCIAL SPACES TRAVERSING THE LENGTH OF THE NECK

Space	Location	Comments and Potential for Infection
Superficial	Between the superficial fascia and the superficial layer of deep cervical fascia Surrounds the platysma m.	Infections are superficial and often observed early Continuous with the face
Retropharyngeal	Posterior to the buccopharyngeal layer of the middle layer of cervical fascia covering the pharynx and esophagus, and anterior to the alar fascia Extends from the base of the skull to about the level of T2, where the 2 layers of fascia fuse The inferior portion of the retropharyngeal space (posterior to the esophagus) is sometimes called the retrovisceral space Continuous with the: <ul style="list-style-type: none"> <li>• Lateral pharyngeal space</li> <li>• Sublingual space</li> </ul>	Infections in this space often are the result of infections in Waldeyer's ring that spread to the retropharyngeal lymph nodes A cellulitis or abscess may eventually result Retropharyngeal infections may continue to spread posteriorly into the danger space
"Danger space"	Posterior to the alar fascia (and fascia where the alar fascia and middle layer of the cervical fascia fuse) and anterior to the prevertebral fascia Extends from the base of the skull to the diaphragm	Via the superior mediastinum, it allows infection to spread into the thorax
Prevertebral	Between the prevertebral fascia and the vertebral column	Closed off superiorly, laterally, and inferiorly, so spread of infections in this space is not common
Carotid sheath	A potential space is created by the carotid sheath Bounded superiorly by the skull base, inferiorly it merges with connective tissue around the aortic arch	Infections from visceral spaces may enter and pass within the carotid sheath

## FASCIAL SPACES TRAVERSING THE LENGTH OF THE NECK CONTINUED



## 17 Clinical Correlate

### LUDWIG'S ANGINA

A severe cellulitis due to bacterial infection (usually from *Streptococcus*, *Actinomyces*, *Prevotella*, *Fusobacterium*, or *Staphylococcus*) in the floor of the oral cavity under the tongue

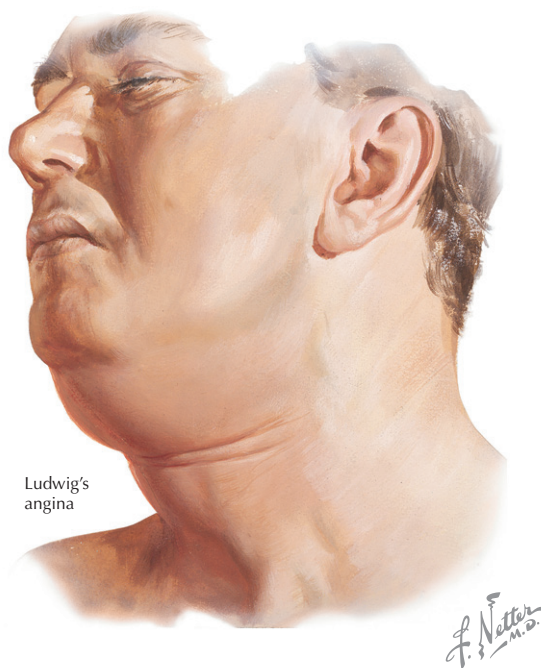
Often begins in the sublingual and submandibular spaces after infection of the premolar teeth or, more commonly, molar teeth (such as an abscess of a mandibular molar) because their roots extend inferior to the mylohyoid line of the mandible

May follow the planes of the fascial spaces to spread in the neck

May cause sufficient neck swelling to block the airway

More common in children

Antibiotic therapy, incision of the neck to drain the infection, and excision of the infected tooth are the possible treatments.



Ludwig's  
angina

# Clinical Correlate

## ABSCESSSES

May spread via the fascial planes of the neck to become more serious, such as in Ludwig's angina

### *Dentoalveolar Abscess (Periapical Abscess)*

An acute lesion characterized by localization of pus in the structures surrounding the apex of a tooth

May originate in the dental pulp and be secondary to dental caries with erosion of enamel and dentin, or to traumatic injury to tooth, allowing bacteria to invade the dental pulp

Resulting pulpitis can progress to necrosis as bacteria invade the surrounding alveolar bone, causing formation of a local abscess

### *Periodontal Abscess*

Typically involves the supporting structures of the teeth, such as the periodontal ligaments and alveolar bone, leading to formation of a local abscess

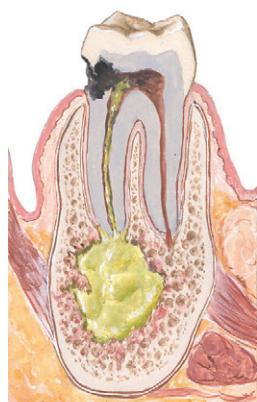## PERICORONITIS

An inflammation around the crown of a tooth from an infection of the gingiva, leading to formation of an abscess

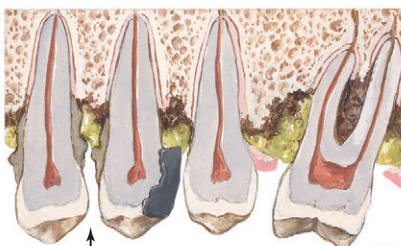Most commonly affected tooth is a partially erupted 3rd mandibular molar



Abscess of the submandibular region



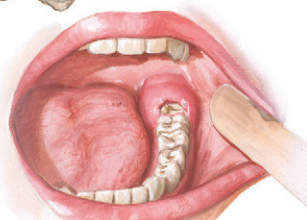Dento alveolar abscess



Origins of infection

Pericoronal abscess about partially erupted 3<sup>rd</sup> molar

Periodontal infection related to:  
A. Subgingival calculus  
B. Overhanging filling margin  
C. Poor contact and "tipping" of tooth



## 17 Clinical Correlate

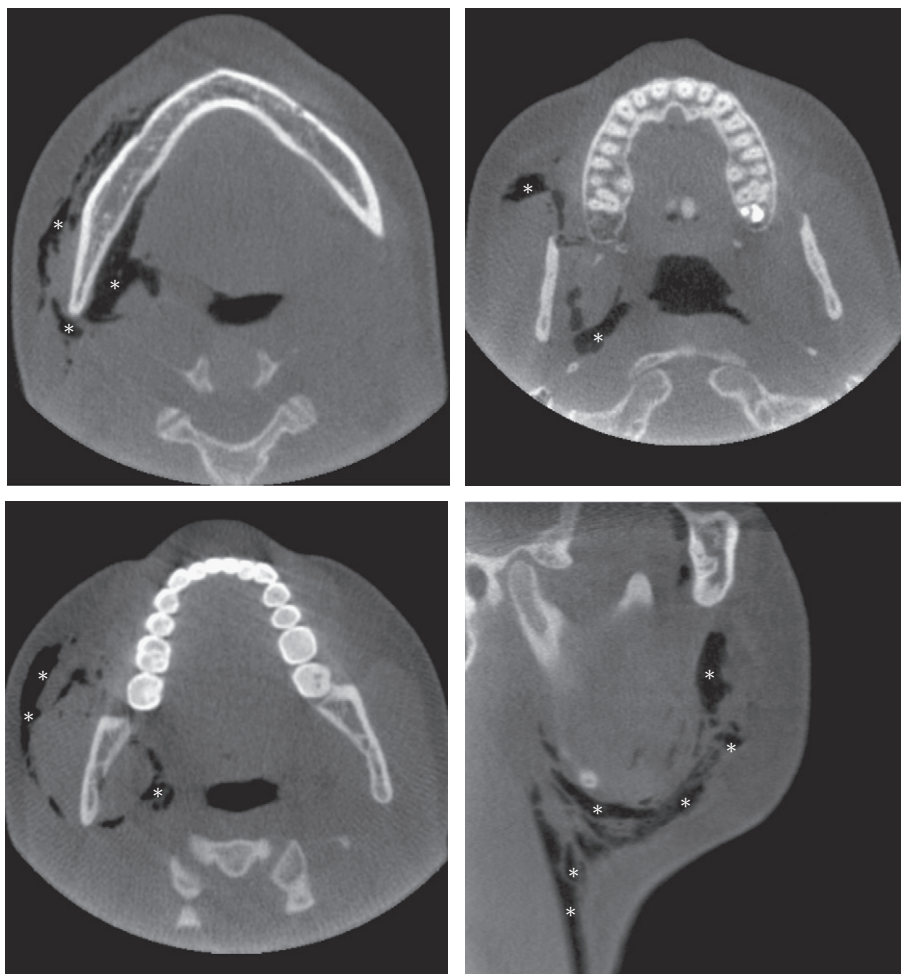
### CERVICAL EMPHYSEMA

Introduction of gas deep to the skin which may be due to trauma, iatrogenic, or infection.

Some causes include fractures of the head and neck, introduction of air from a high speed dental drill, and surgical procedures such as root canals and extractions of mandibular 3rd molars

In the head and neck, cervical emphysema can spread via the fascial planes

May be benign or fatal, depending on the spread



\* Presence of air displaying extension of cervical emphysema



## CHAPTER 18

# EAR

Overview and Topographic Anatomy	452
Structures and Boundaries	455
Muscles	462
Nerve Supply	463
Vascular Supply	468
Clinical Correlates	476

## 18 Overview and Topographic Anatomy

### GENERAL INFORMATION

Dual functions:

- Maintains the balance of the body (vestibular)
- Perceives sound (auditory)

3 divisions:

- external ear
- middle ear
- inner ear

#### *External Ear*

The most superficial portion of the ear, the external ear includes the auricle, external acoustic meatus, and the tympanic membrane

Helps gather sound and direct it to the tympanic membrane

#### *Middle Ear*

Transmits sound vibrations from the tympanic membrane to the inner ear via the ear ossicles: malleus, incus, and stapes

Mainly within the petrous portion of the temporal bone

General shape resembles a biconcave lens

Composed of the tympanic cavity that connects anteriorly with the nasopharynx via the auditory tube and the mastoid air cells posteriorly

Tympanic cavity contains the ear ossicles (malleus, incus, and stapes), muscles (tensor tympani and stapedius muscles), nerves (chorda tympani, tympanic branch of the glossopharyngeal nerve, and lesser petrosal nerve), and tympanic plexus (parasympathetics from the glossopharyngeal nerve plus sympathetics from the superior cervical ganglion via the carotid plexus)

#### *Inner Ear*

Vestibular and auditory structures, which are filled with fluid, make up the inner ear:

- Auditory portion (cochlea) is stimulated by the movement of the fluid
- Vestibular portion (utricle, saccule, and semicircular canals) is stimulated by fluid movement within these chambers

Consists of a membranous labyrinth that lies within an osseous labyrinth

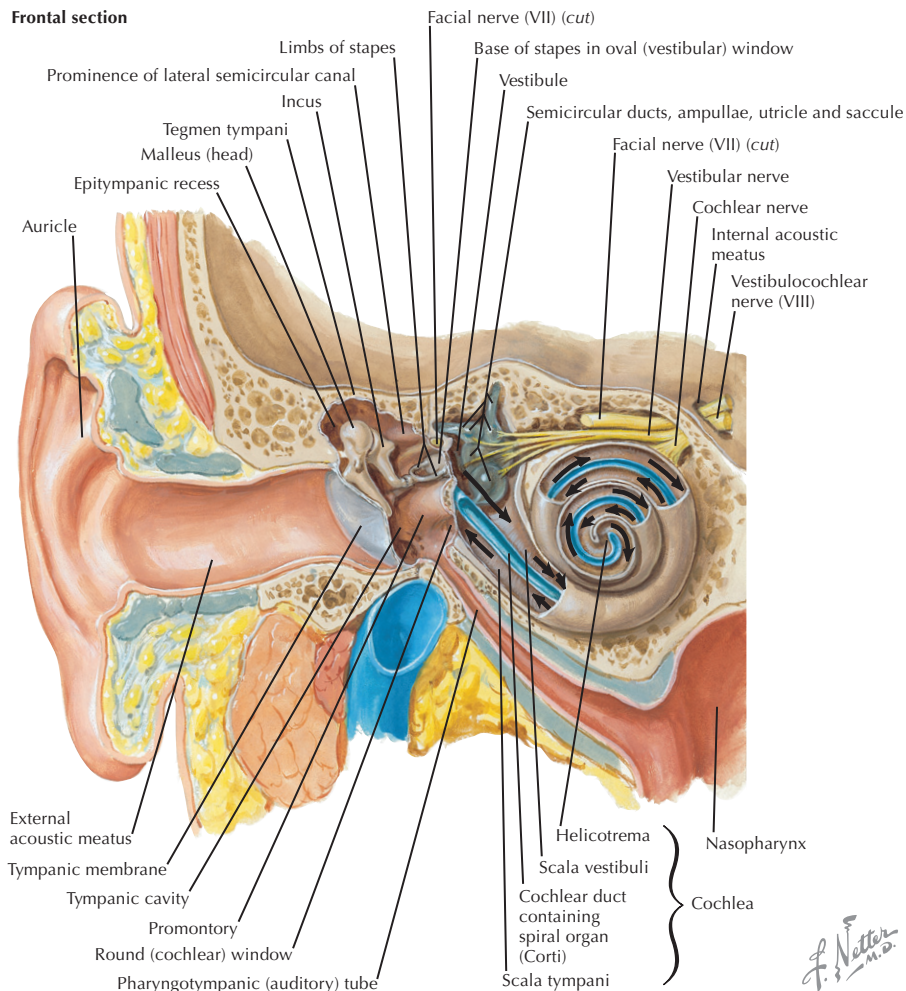
The receptors for auditory and vestibular function are located within the membranous labyrinth

Fluids located in the membranous labyrinth (endolymph) and osseous labyrinth (perilymph) stimulate the auditory and vestibular receptors

The vestibulocochlear nerve enters the internal ear via the internal acoustic meatus

## GENERAL INFORMATION *CONTINUED*

### Frontal section

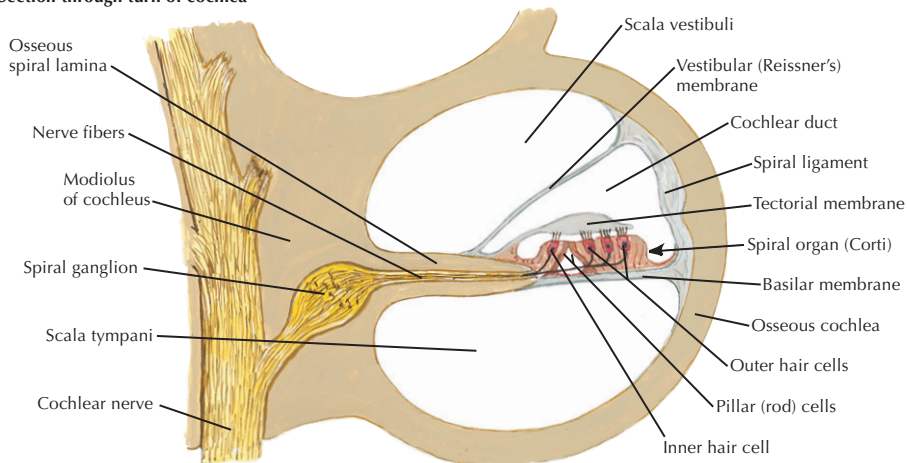


Note: Arrows indicate course of sound waves

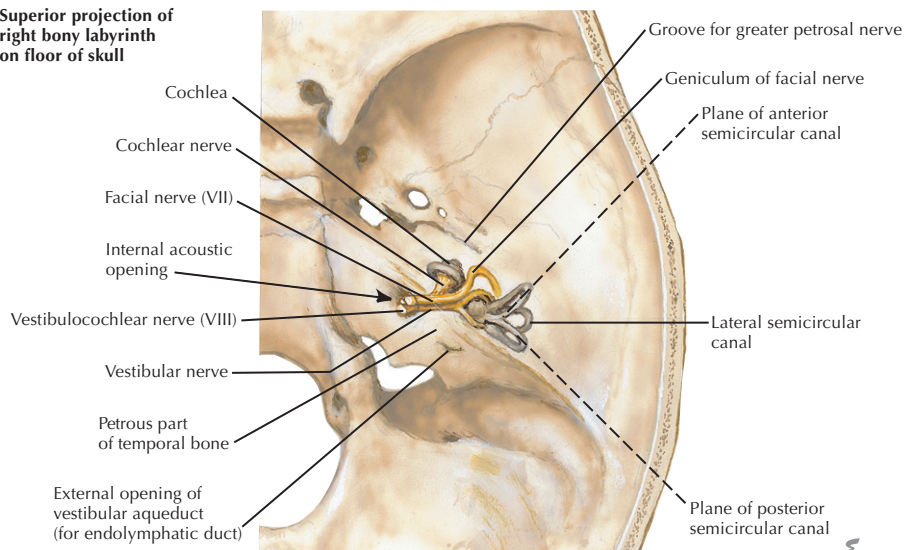
*F. Netter M.D.*

## GENERAL INFORMATION *CONTINUED*

### Section through turn of cochlea



### Superior projection of right bony labyrinth on floor of skull



*F. Netter M.D.*

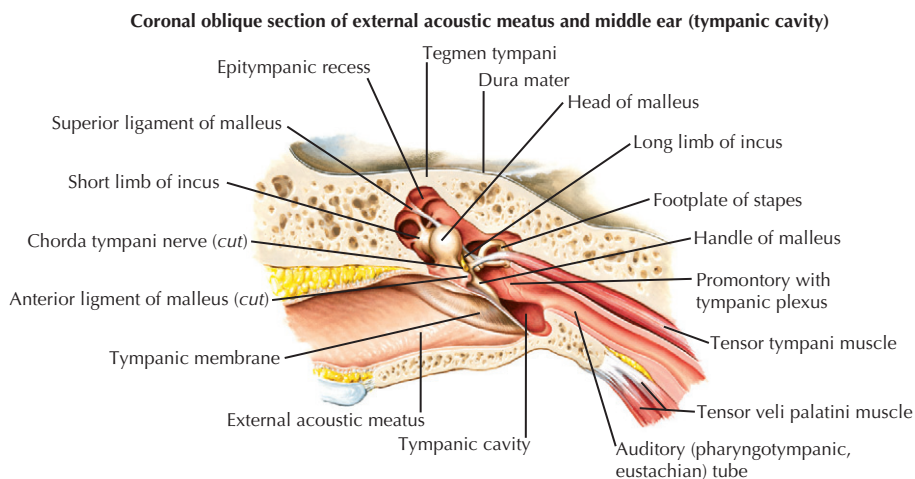
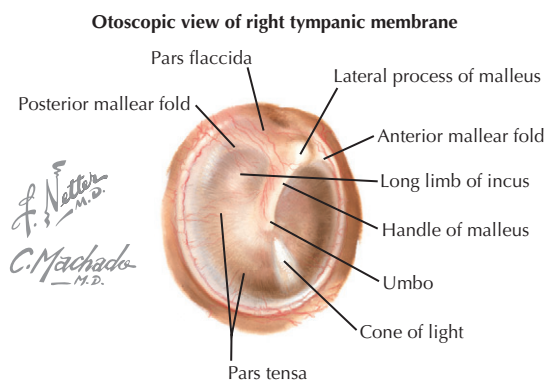
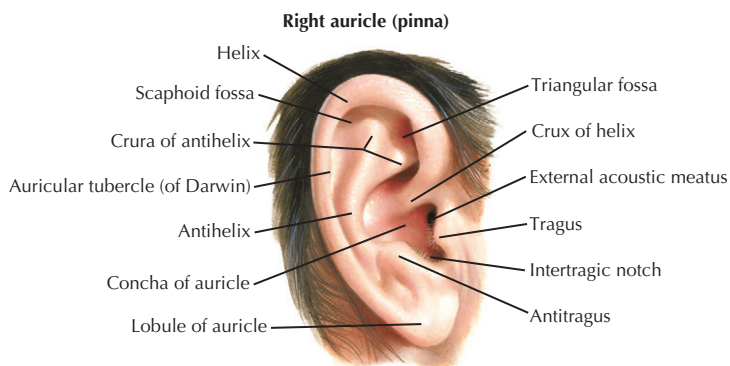
# Structures and Boundaries

## STRUCTURES OF THE EXTERNAL EAR

Structure	Comments
Auricle	<p>An irregularly shaped structure made of elastic cartilage and skin</p> <p>Superior portion has a skeleton of elastic cartilage</p> <p>Inferior portion, the lobule, has no cartilage</p> <p><i>Helix</i>: the outermost curved rim of the auricle, continues anteriorly to blend with the head at the crus helix</p> <p><i>Antihelix</i>: the portion of cartilage that follows along the helix from the inside</p> <p><i>Scaphoid fossa</i>: the depressed area between the helix and antihelix</p> <p><i>Concha</i>: demarcated by the antihelix, it is the depressed area that leads to the external acoustic meatus</p> <p><i>Tragus</i>: extends from the face into the concha</p> <p><i>Antitragus</i>: extends from the inferior portion of the antihelix into the concha and is separated from the tragus by the intertragic notch</p>
External acoustic meatus	<p>The passageway connecting the concha of the auricle to the tympanic membrane</p> <p>Covered by skin rich in sebaceous and cerumen-secreting glands</p> <p>About 2.5 cm in length</p> <p><i>Lateral 1/3</i>: cartilaginous, extends into the temporal bone</p> <p><i>Medial 2/3</i>: osseous, formed by the tympanic, squamous, and petrous portions of the temporal bone</p>
Tympanic membrane	<p>The most medial portion of the external ear that separates it from the middle ear</p> <p>Lies in a groove on the tympanic part of the temporal bone</p> <p>A thin, semitransparent, 3-layered membrane:</p> <ul style="list-style-type: none"> <li>• <i>External layer</i>—derived from skin; composed of stratified squamous epithelium</li> <li>• <i>Middle layer</i>—fibrous, with fibers attaching to the malleus</li> <li>• <i>Inner layer</i>—continuous with the mucous membrane of the middle ear cavity; composed of columnar epithelium with cilia</li> </ul> <p>Anterior and posterior malleolar folds lie on the superior portion of the tympanic membrane</p> <p>Tense and loose portions are called the pars tensa and pars flaccida, respectively</p>

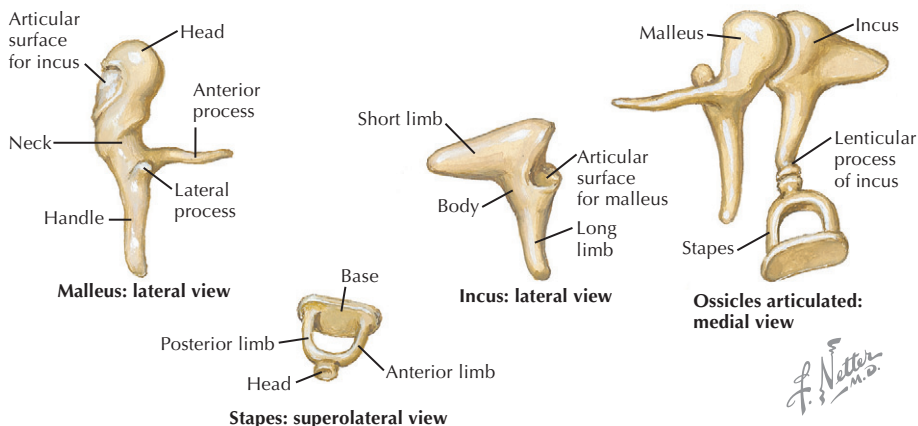


## STRUCTURES OF THE EXTERNAL EAR *CONTINUED*



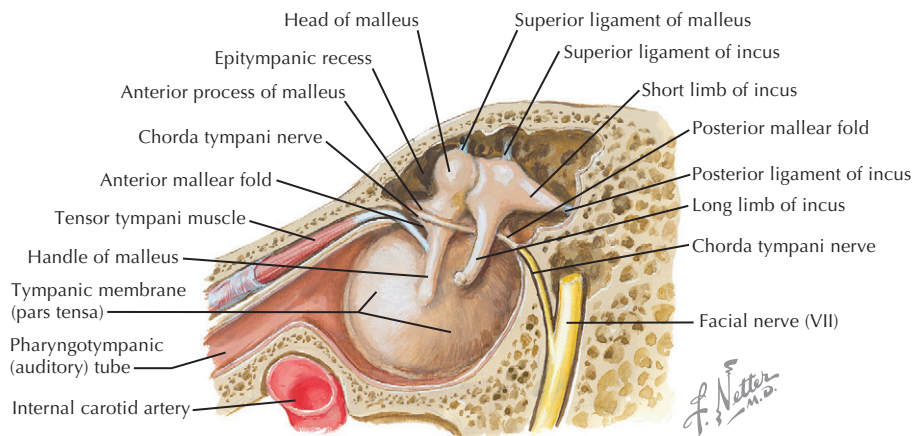
**BOUNDARIES OF THE MIDDLE EAR**

Boundary	Comments
Roof	Made by the tegmen tympani, separating the middle ear from the temporal lobe of the middle cranial fossa
Floor	Thin bone separates the middle ear from the internal jugular v. Tympanic canaliculus, located in the floor of the middle ear; allows the tympanic branch of the glossopharyngeal n. to enter the middle ear
Anterior wall	<i>Auditory tube</i> : located in the middle ear's anterior wall; connects the middle ear with the nasopharynx; equilibrates pressure on either side of the tympanic membrane, and allows proper drainage of the middle ear <i>Lesser petrosal n.</i> exits the middle ear through the anterior wall Postganglionic sympathetic nerve fibers from the internal carotid a. pass through the anterior wall to enter the middle ear
Posterior wall	<i>Facial canal</i> : passes superoinferiorly immediately posterior to the middle ear until it terminates at the stylomastoid foramen <i>Mastoid antrum</i> : located in the superior portion of the posterior wall near the junction with the roof of the middle ear <i>Pyramid</i> : a hollow projection from the posterior wall; contains the tendon of the stapedius m. Posterior cranial fossa and sigmoid sinus are located posterior to the posterior wall
Medial wall	The medial wall separates the middle ear from the inner ear <i>Promontory</i> : a large protuberance created by the cochlea of the inner ear In the superior portion of the medial wall is a protuberance formed by the lateral semicircular canal Inferior to the lateral semicircular canal on the opposite side of the medial wall is the horizontal portion of the facial canal <i>Fenestra vestibuli</i> (oval window—where the footplate of the stapes is located) and <i>fenestra cochleae</i> (round window—an opening covered by a membrane): located in a superior-inferior relationship on the medial wall posterior to the promontory Tendon of the tensor tympani m. enters the middle ear through the medial wall
Lateral wall	The lateral wall separates the middle ear from the external ear; mainly created by the tympanic membrane, with the malleus attached to the membrane at the umbo <i>Epitympanic recess</i> : the region superior to the tympanic membrane that houses portions of the malleus and incus <i>Chorda tympani n.</i> lies along the tympanic membrane and malleus until exiting the petrotympanic fissure

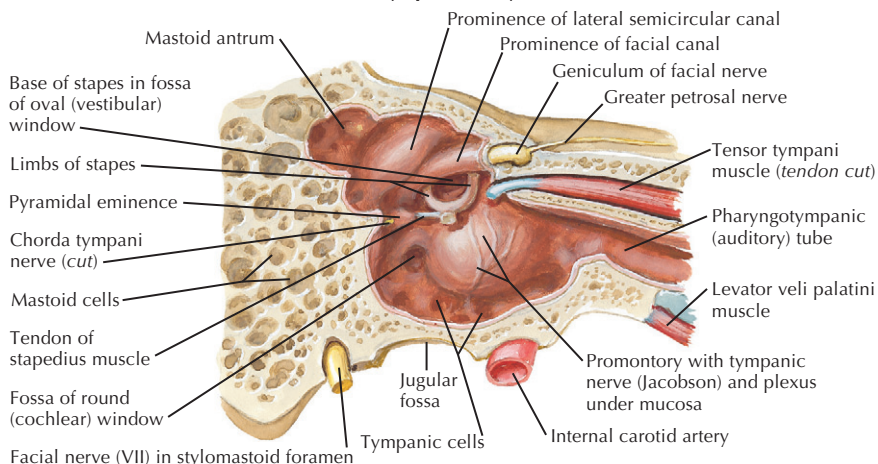
**Auditory ossicles**

## BOUNDARIES OF THE MIDDLE EAR *CONTINUED*

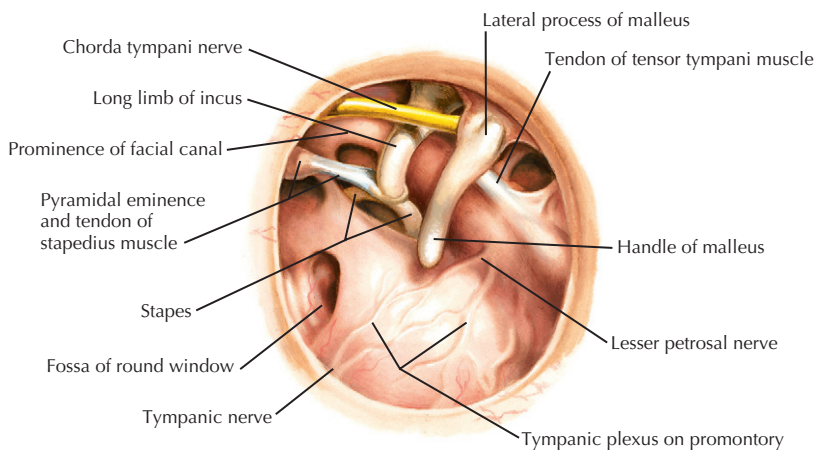
### Lateral wall of tympanic cavity: medial (internal) view



### Medial wall of tympanic cavity: lateral view



### Right tympanic cavity after removal of tympanic membrane (lateral view)



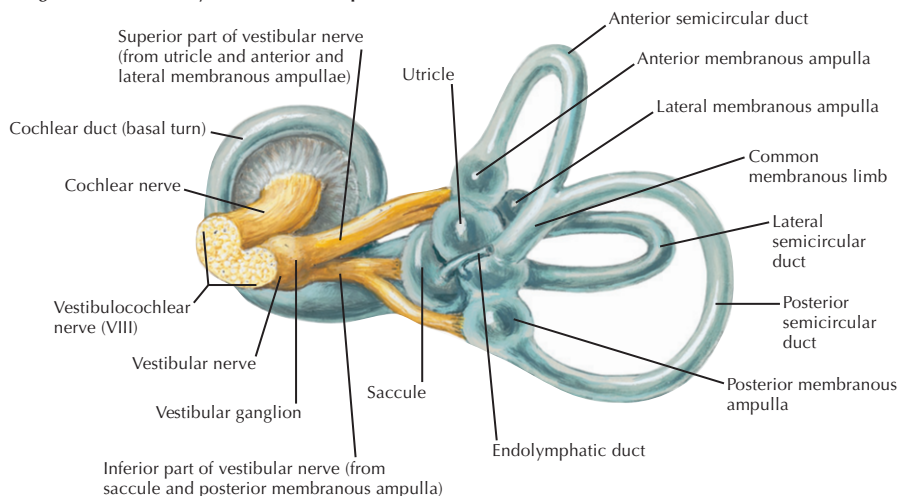
# Structures and Boundaries

## STRUCTURES OF THE INNER EAR

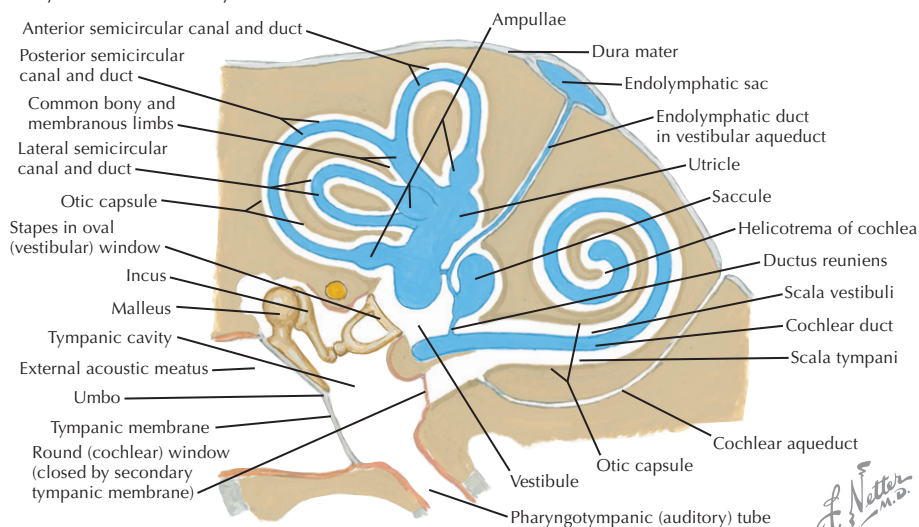
Structure	Description
Osseous labyrinth	Located in the petrous portion of the temporal bone Surrounds the membranous labyrinth and contains perilymph Connects to the middle ear via the fenestra vestibuli and the fenestra cochleae Divided into 3 parts: vestibule, cochlea, and semicircular canals
Vestibule	The middle portion of the osseous labyrinth, it contains the saccule and utricle of the membranous labyrinth Contains an opening for the vestibular aqueduct containing the endolymphatic duct
Cochlea	Anterior portion of the osseous labyrinth contains the cochlear duct of the membranous labyrinth Like a seashell, it spirals around a central point (the modiolus), which carries branches of the cochlear n. to the cochlear duct, for 2 and 3/4 turns, getting progressively smaller while approaching its apex As the cochlea spirals, the spiral lamina is raised from the modiolus Within the spiral lamina, the cochlear duct lies between the scala vestibuli and the scala tympani Scala vestibuli and scala tympani are continuous at the helicotrema at the apex An opening for the aqueduct of the cochlea allows perilymph to drain into the cerebrospinal fluid
Semicircular canals	The posterior portion of the osseous labyrinth <i>3 semicircular canals</i> : anterior, posterior, and lateral <i>Ampulla</i> : a dilated end of each Anterior and posterior semicircular canals have a common crus
Membranous labyrinth	Located within the osseous labyrinth; contains endolymph Divided into 4 parts: cochlear duct, saccule, utricle, and semicircular ducts
Cochlear duct	A spiral structure located within the cochlea Begins at a blind end of the cochlea at the apex and ends where it joins the saccule via the ductus reuniens Triangular in shape, with a base created by the endosteum of the canal known as the spiral ligament and the stria vascularis Roof is formed by the vestibular membrane that separates the cochlear duct from the scala vestibuli Floor is formed by the basilar membrane, on which lies the organ of Corti; separates the duct from the scala tympani
Saccule	A small structure located within the vestibule of the osseous labyrinth Connected to the utricle via the utriculosaccular duct and the endolymphatic duct Sensory receptors (the maculae) are located in the saccule
Utricle	Located within the vestibule of the osseous labyrinth Sensory receptors (maculae) are located in the utricle
Semicircular ducts	Correspond to the semicircular canals of the osseous labyrinth (anterior, posterior, and lateral) Open into the utricle via 5 openings Sensory receptors known as crista are located in the ampullae of the semicircular ducts

## STRUCTURES OF THE INNER EAR *CONTINUED*

### Right membranous labyrinth with nerves: posteromedial view

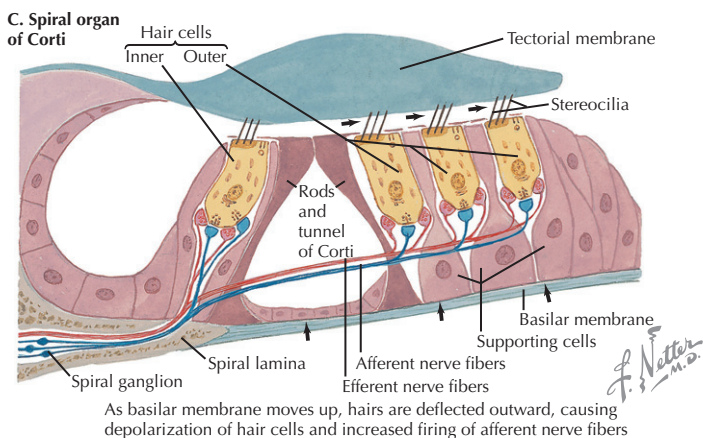
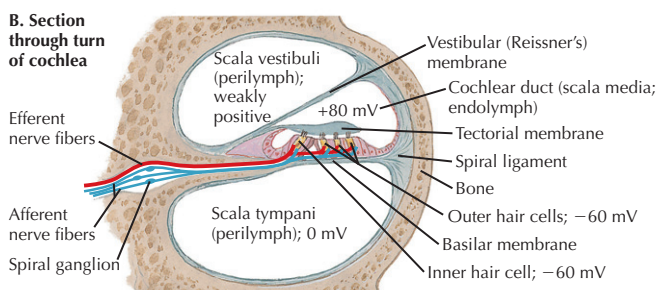
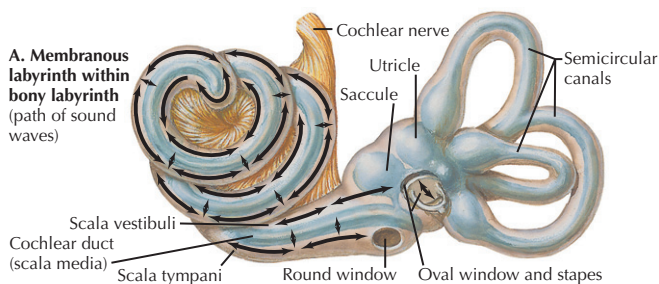


### Bony and membranous labyrinths: schema





## STRUCTURES OF THE INNER EAR *CONTINUED*

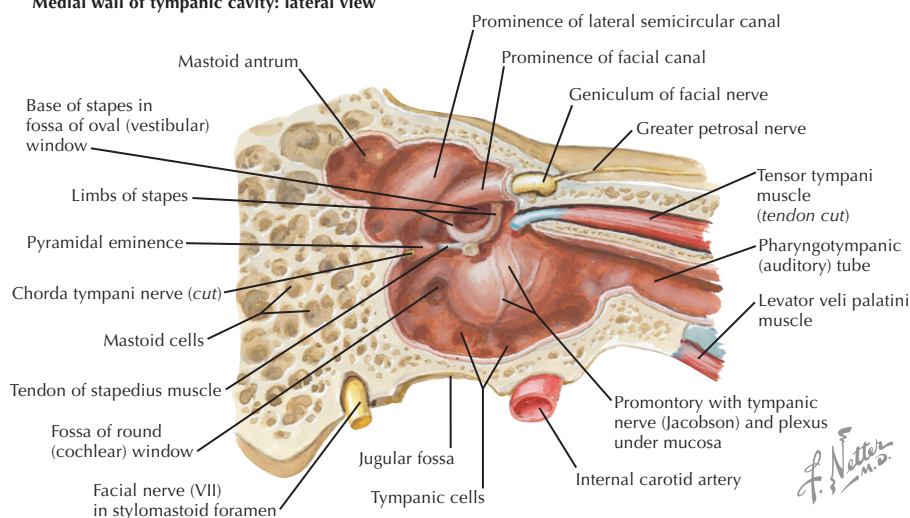




## OVERVIEW

Muscle	Origin	Insertion	Actions	Nerve Supply
Tensor tympani	Bony canal at auditory tube Cartilaginous part of auditory tube Greater wing of the sphenoid	Handle of the malleus	Tenses the tympanic membrane and helps dampen sound vibrations	Mandibular division of the trigeminal n.
Stapedius	Pyramid on posterior wall of the tympanic cavity	Neck of the stapes	Dampens excessive sound vibrations	Stapedius branch of the facial n.

**Medial wall of tympanic cavity: lateral view**

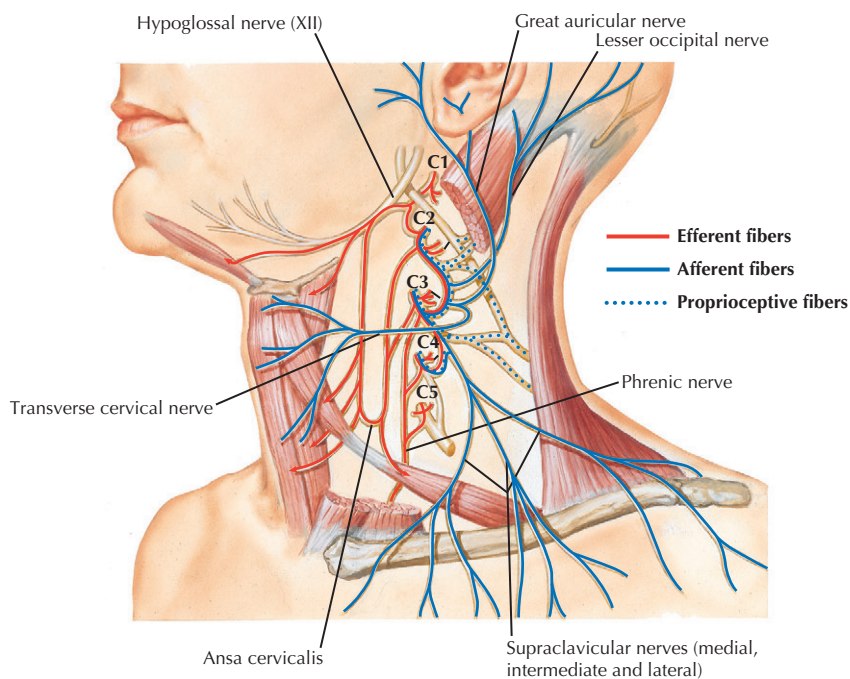
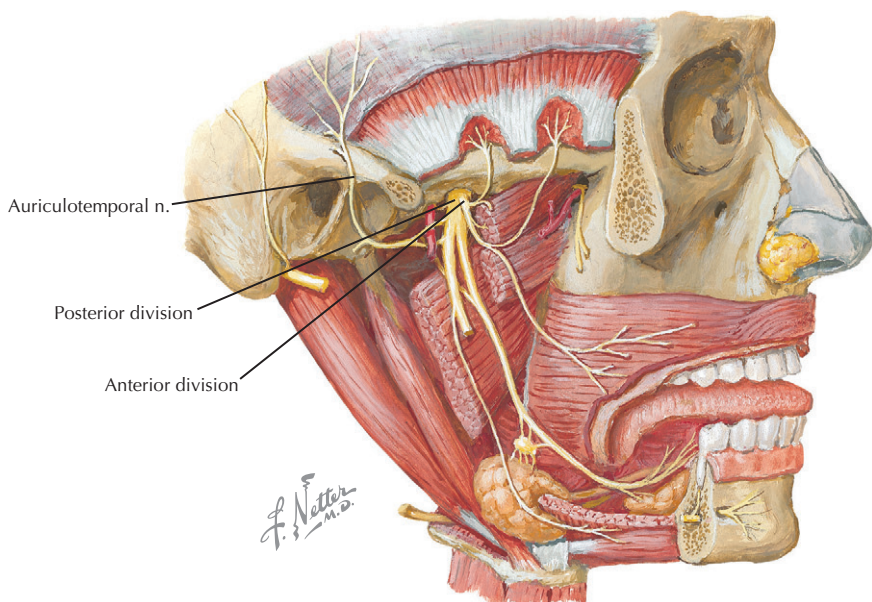


# Nerve Supply

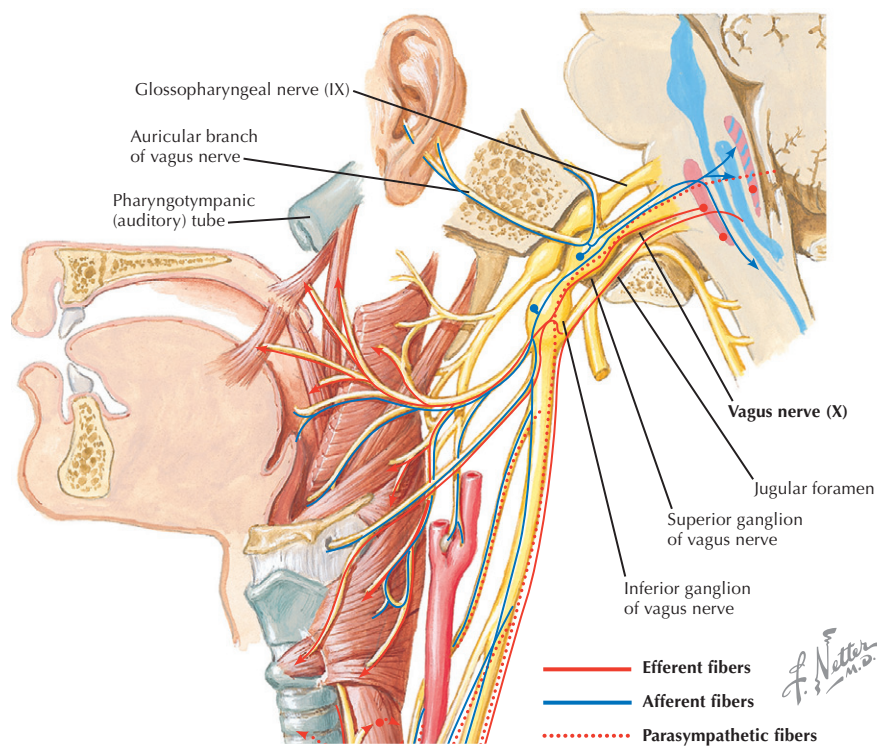
## SENSORY INNERVATION OF THE EXTERNAL EAR

Nerve	Source	Course
Great auricular	Cervical plexus, formed by contributions of C2 and C3 ventral rami	After passing posterior to the sternocleidomastoid m. at Erb's point, it ascends along the sternocleidomastoid, dividing into anterior and posterior branches The posterior branch innervates the skin over the mastoid process, the posterior portion of the auricle, and the concha and lobule
Lesser occipital	Cervical plexus, formed by contributions from C2 ventral ramus	After passing posterior to the sternocleidomastoid m. at Erb's point, it ascends posterior to the sternocleidomastoid along the posterior portion of the head Continues on the head posterior to the auricle Supplies the skin posterior to the auricle
Auriculotemporal	Posterior part of the mandibular division of the trigeminal n.	Normally arises by 2 roots, between which the middle meningeal a. passes Runs posteriorly just inferior to the lateral pterygoid m. and continues to the medial aspect of the neck of the mandible Turns superiorly with the superficial temporal vessels between the auricle and condyle of the mandible deep to the parotid gland On exiting the parotid gland, ascends over the zygomatic arch Innervates the skin in the region of the tragus, crus helix, anterior portion of the external acoustic meatus, and outer surface of the tympanic membrane
Auricular branch of the vagus	Superior ganglion of the vagus n.	Travels posterior to the internal jugular v. and passes along the temporal bone Crosses the facial canal superior to the stylomastoid foramen Enters the mastoid canaliculus between the mastoid process and the tympanic part of the temporal bone and gives rise to 2 branches: <ul style="list-style-type: none"> <li>• 1 branch joins the posterior auricular branch of the facial n.</li> <li>• The 2nd branch innervates the skin of the back of the auricle and the posterior portion of the external acoustic meatus</li> </ul>
Tympanic branch of glossopharyngeal	Branches from the inferior ganglion of the vagus n., located in the petrous portion of the temporal bone	Passes superiorly through the tympanic canaliculus to enter the middle ear In the middle ear, it divides into branches that form part of the tympanic plexus Tympanic plexus gives rise to: <ul style="list-style-type: none"> <li>• Preganglionic parasympathetic fibers to the parotid gland</li> <li>• Postganglionic sympathetic fibers to the parotid gland</li> <li>• Sensory fibers to the middle ear cavity, including the tympanic membrane and auditory tube (mainly from the tympanic branch of the glossopharyngeal n.)</li> </ul>

## SENSORY INNERVATION OF THE EXTERNAL EAR *CONTINUED*



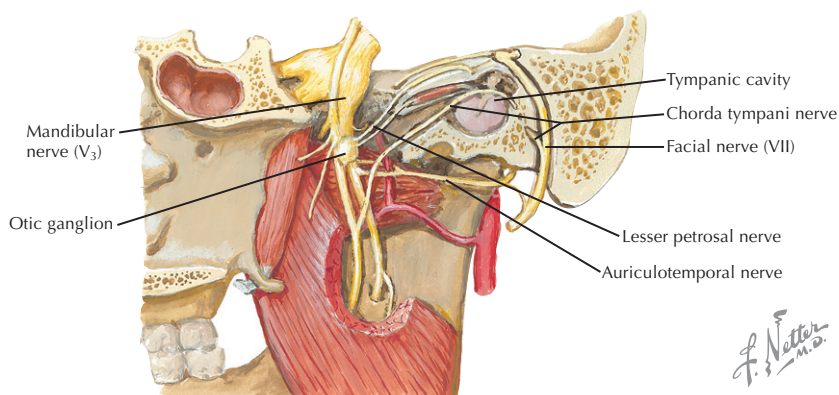
## SENSORY INNERVATION OF THE EXTERNAL EAR *CONTINUED*



## SENSORY INNERVATION OF THE MIDDLE EAR

Nerve	Source	Course
Tympanic plexus	<p>Formed by the:</p> <ul style="list-style-type: none"> <li>• Tympanic branch of the glossopharyngeal n. (arises from the inferior ganglion located in the petrous portion of the temporal bone)</li> <li>• Caroticotympanic nn. (arise from the carotid plexus on the internal carotid a.)</li> </ul>	<p>Tympanic branch of the glossopharyngeal n. passes superiorly through the tympanic canaliculus to enter the middle ear</p> <p>In the middle ear, it divides into branches that form the tympanic plexus</p> <p>Caroticotympanic nn. join the tympanic branch of the glossopharyngeal n.</p> <p>Tympanic plexus gives rise to:</p> <ul style="list-style-type: none"> <li>• Preganglionic parasympathetic fibers to the parotid gland</li> <li>• Postganglionic sympathetic fibers to the parotid gland</li> <li>• Sensory fibers to the middle ear cavity, including the tympanic membrane and auditory tube (mainly from the tympanic branch of the glossopharyngeal)</li> </ul>
Facial	<p>Cranial n. VII has multiple motor and sensory functions</p> <p>Created by:</p> <ul style="list-style-type: none"> <li>• Nervus intermedius, which contains the sensory fibers and the parasympathetic fibers</li> <li>• Motor portion that innervates the muscles derived from the 2nd pharyngeal arch</li> </ul>	<p>Nervus intermedius and motor portions—enter the internal acoustic meatus of the temporal bone</p> <p>Facial n. then passes through the facial canal until it exits the stylomastoid foramen, initially traveling horizontally along the outside of the medial wall of the middle ear; then it bends posteriorly and inferiorly to the middle ear</p> <p>Where the nerve changes direction is in the geniculate ganglion; here the greater petrosal n. is given off to travel anteriorly toward the pterygopalatine fossa</p> <p>Within the facial canal, the nerve gives rise to the nerve to the stapedius m. and the chorda tympani n.</p> <p>Chorda tympani passes anteriorly along the tympanic membrane and the malleus until it exits via the petrotympanic fissure</p> <p>Chorda tympani carries preganglionic parasympathetic fibers to the submandibular ganglion of the oral cavity, and taste fibers to the anterior 2/3 of the tongue</p> <p>Stapedius n. innervates the stapedius m.</p>

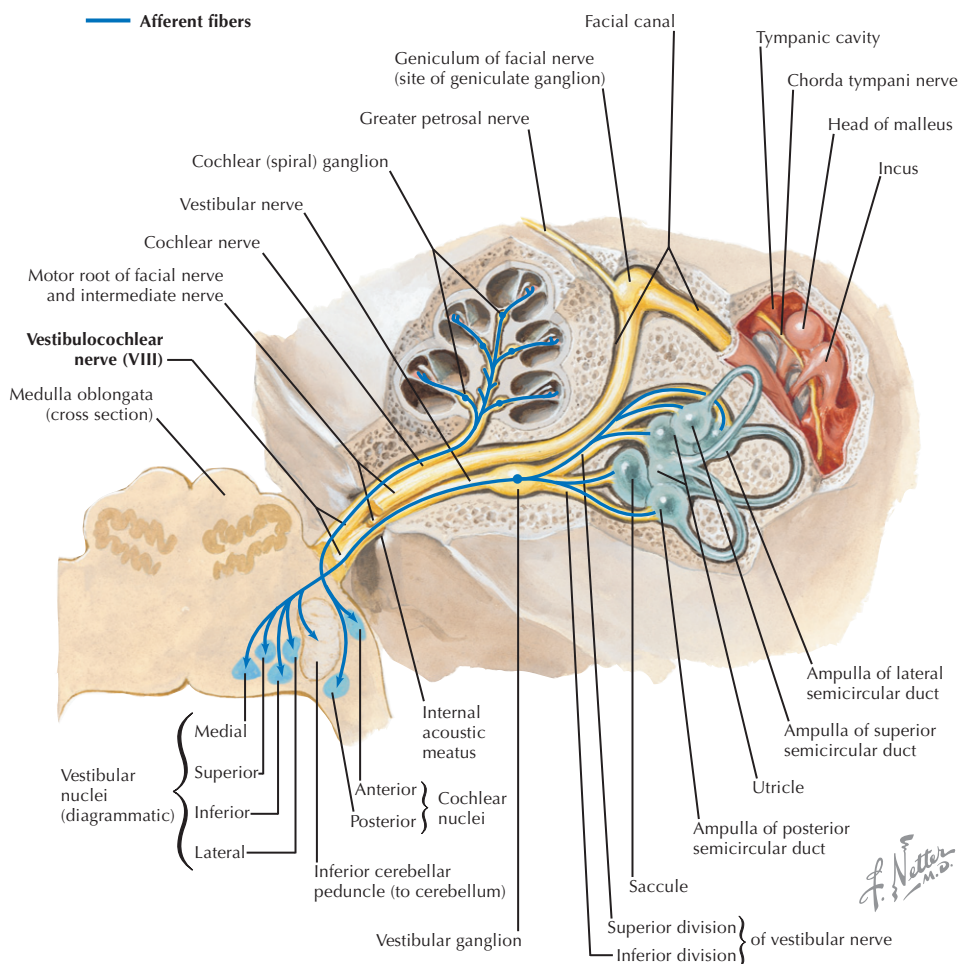
Medial view





## SENSORY INNERVATION OF THE INNER EAR

Nerve	Source	Course
Vestibulocochlear	Also called cranial n. VIII, it emerges between the pons and the medulla oblongata	Enters the internal acoustic meatus with the facial n. Within the internal acoustic meatus, it divides into vestibular branches and the cochlear branch
Vestibular	The vestibular portion has nerve cell bodies in the vestibular ganglion (Scarpa's ganglion)	Divides into superior and inferior branches: <ul style="list-style-type: none"> <li>Superior vestibular branch innervates the maculae of the saccule and utricle and the ampulla of the anterior and lateral semicircular ducts</li> <li>Inferior vestibular branch innervates the macula of the saccule and the ampulla of the posterior semicircular duct</li> </ul>
Cochlear	The cochlear portion has nerve cell bodies in the spiral ganglion	Utilizes the spiral ganglion within the modiolus to pass to the organ of Corti

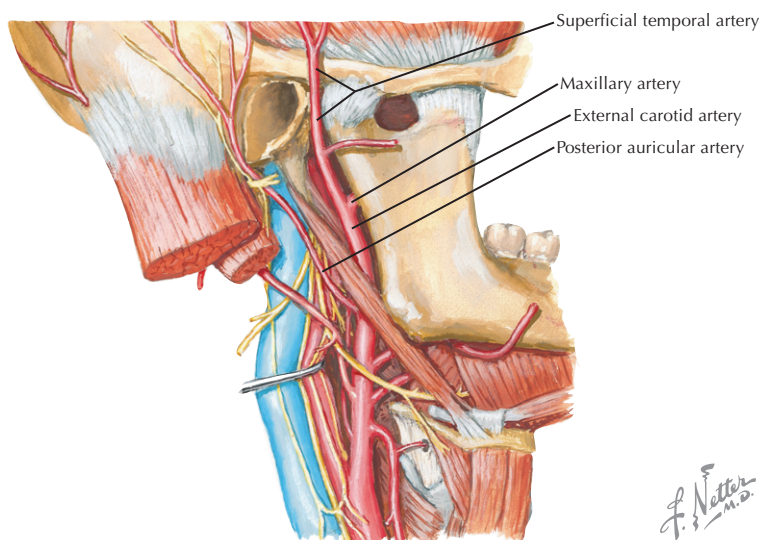




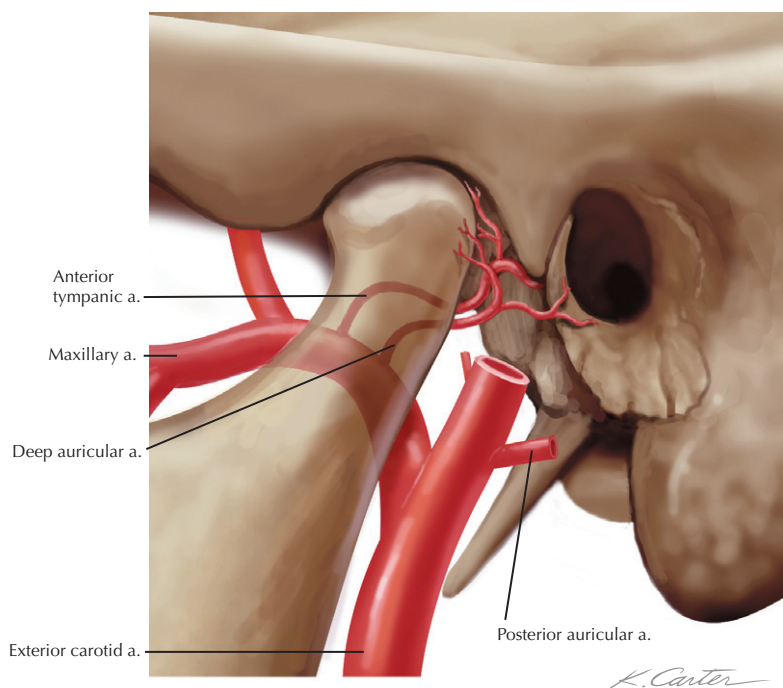
## ARTERIAL SUPPLY OF THE EXTERNAL EAR

Artery	Source	Course
Superficial temporal	A terminal branch of the external carotid a. that arises within the parotid gland	Within the parotid gland, it gives off a transverse facial a. Emerges from the superior part of the parotid gland immediately posterior to the temporomandibular joint and anterior to the external auditory meatus Passes superficial to the root of the zygomatic arch just anterior to the auriculotemporal n. and the auricle While passing superiorly, it gives off branches that supply the auricle and the external acoustic meatus
Posterior auricular	External carotid a. within the parotid gland	Passes superiorly between the mastoid process and cartilage of the ear During its path to anastomose with the superficial temporal and the occipital aa., it supplies the auricle and external acoustic meatus A stylomastoid branch arises from the posterior auricular and enters the stylomastoid foramen to supply the internal surface of the tympanic membrane
Deep auricular	A branch of the maxillary a. (1 of the terminal branches of the external carotid a.) Arises in the same area as for the anterior tympanic a.	Lies in the parotid gland, posterior to the temporomandibular joint, where it supplies that joint Passes into the external acoustic meatus to supply it; then supplies the outer surface of the tympanic membrane
Anterior tympanic	A branch of the maxillary a. (1 of the terminal branches of the external carotid a.)	Given off in the same area as for the deep auricular a. Passes superiorly immediately posterior to the temporomandibular joint Enters the tympanic cavity through the petrotympanic fissure Aids in supplying the inner surface of the tympanic membrane

Parotid space (bed): right lateral dissection



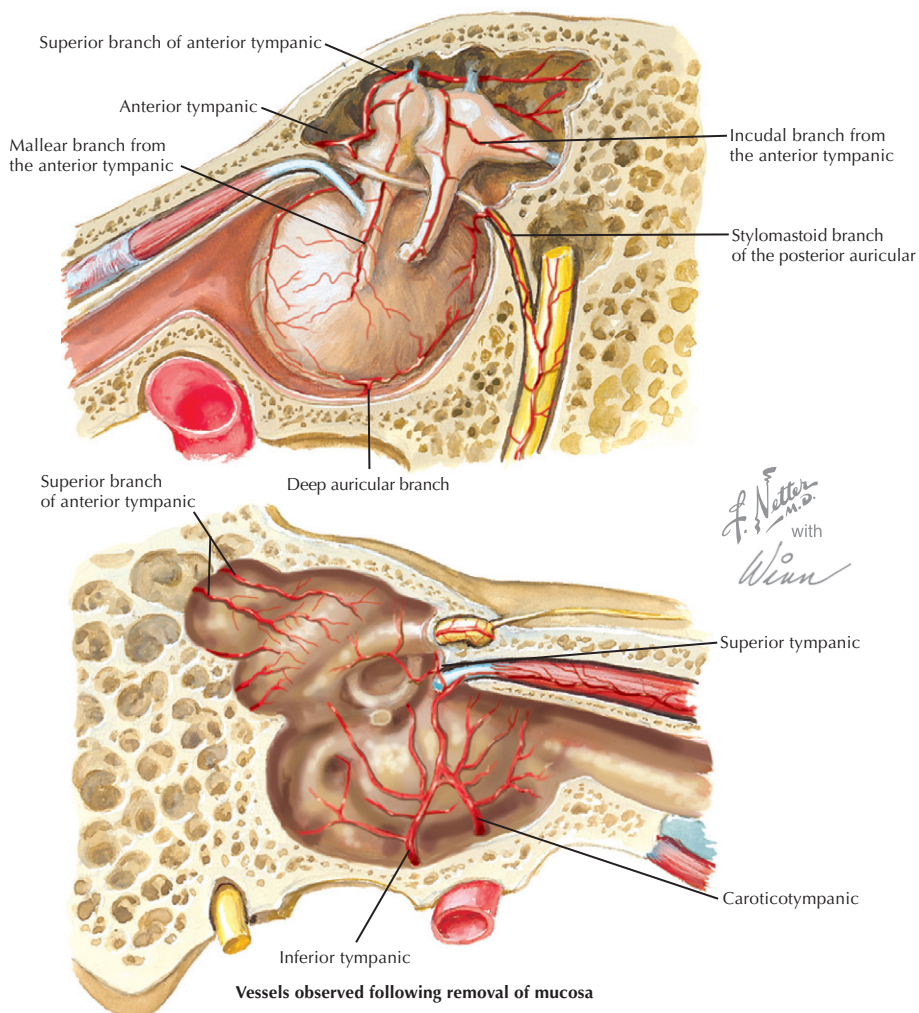
## ARTERIAL SUPPLY OF THE EXTERNAL EAR *CONTINUED*



**ARTERIAL SUPPLY OF THE MIDDLE EAR**

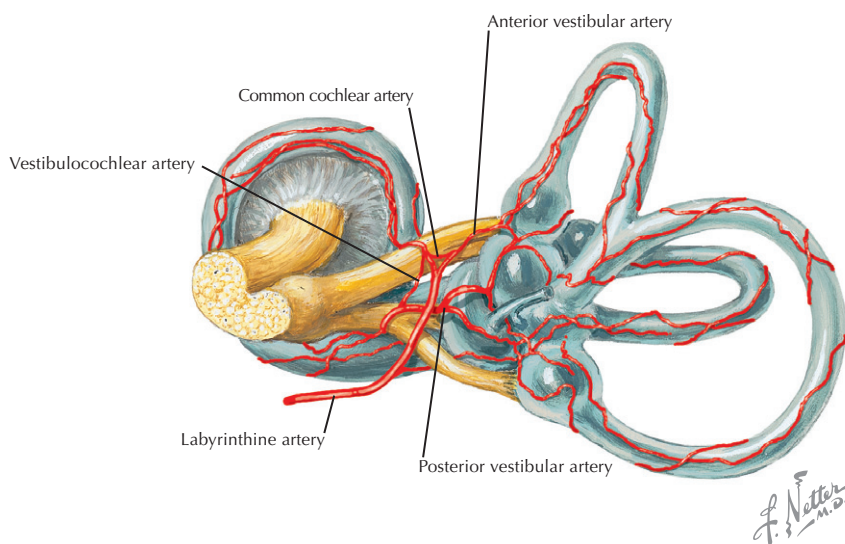
Artery	Source	Course
Posterior auricular	External carotid a. within the parotid gland	<p>Passes superiorly between the mastoid process cartilage of the ear</p> <p>During its path to anastomose with the superficial temporal and the occipital aa., it supplies the auricle and external acoustic meatus</p> <p>A stylomastoid branch arises from the posterior auricular a. and enters the stylomastoid foramen to supply the internal surface of the tympanic membrane</p>
Anterior tympanic	Maxillary a. (1 of the terminal branches of the external carotid a.)	<p>Given off in the same area as for the deep auricular a.</p> <p>Passes superiorly immediately posterior to the temporomandibular joint</p> <p>Enters the tympanic cavity through the petrotympanic fissure</p> <p>Aids in supplying the outer surface of the tympanic membrane and the anterior portion of the tympanic cavity</p>
Inferior tympanic	Ascending pharyngeal a. of the external carotid a.	<p>Ascends deep to the other branches of the external carotid a. and more superiorly to the stylopharyngeus m.</p> <p>Passes into the middle ear through the petrous portion of the temporal bone</p> <p>Helps supply the medial wall of the tympanic cavity</p>
Superior tympanic	Middle meningeal a. of the maxillary a.	<p>Arises from the middle meningeal a. immediately after passing through the foramen spinosum within the middle cranial fossa</p> <p>Passes in the canal of the tensor tympani m. to help supply the tensor tympani and its bony canal</p>
Caroticotympanic branch of the internal carotid	Internal carotid a.	<p>Passes into the tympanic cavity through an aperture in the carotid canal</p> <p>Helps supply the middle ear</p>

## ARTERIAL SUPPLY OF THE MIDDLE EAR CONTINUED

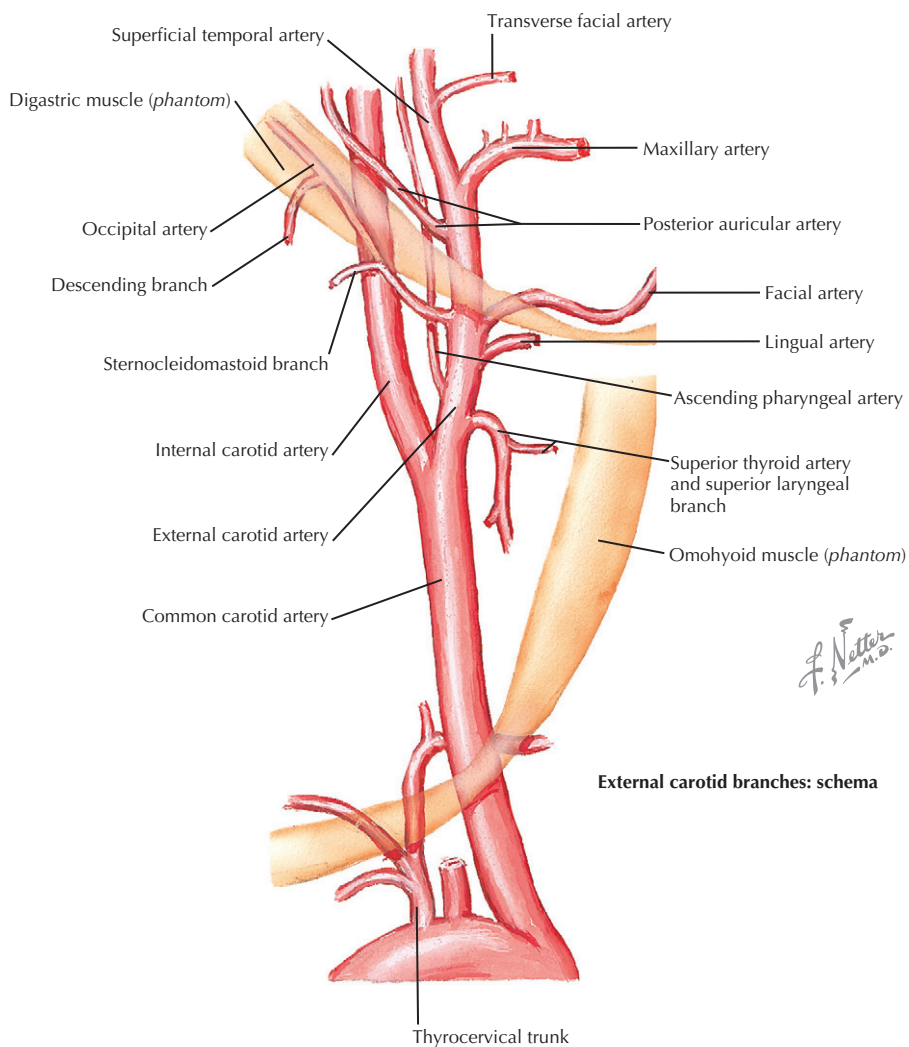


**ARTERIAL SUPPLY OF THE INNER EAR**

Artery	Source	Course
Labyrinthine	Basilar a., which gives rise to the circle of Willis	Passes through the internal acoustic meatus, where it further divides into cochlear and vestibular branches that supply the cochlear and vestibular structures
Posterior auricular	External carotid a. within the parotid gland	<p>Passes superiorly between the mastoid process and cartilage of the ear</p> <p>Anastomoses with the superficial temporal and the occipital aa.</p> <p>A stylomastoid branch arises from the posterior auricular a., enters the stylomastoid foramen, and continues to the inner ear</p> <p>During its path to anastomose with the superficial temporal and the occipital aa., it supplies the auricle and external acoustic meatus</p> <p>Stylomastoid branch supplies the internal surface of the tympanic membrane and the posterior portion of the tympanic cavity; then helps supply the inner ear</p>



## ARTERIAL SUPPLY OF THE INNER EAR *CONTINUED*



External carotid branches: schema



**VENOUS DRAINAGE OF THE EXTERNAL EAR**

Vein	Comments
Superficial temporal	Descends posterior to the zygomatic root of the temporal bone alongside the auriculotemporal n. to enter the substance of the parotid gland Unites with the maxillary v. to form the retromandibular v. Along its path, receives tributaries from the auricle
Posterior auricular	Arises from a plexus of veins created by the occipital and superficial temporal vv. Descends posterior to the auricle to unite with the posterior division of the retromandibular v. to form the external jugular v. Along its path, receives blood from the stylomastoid branch of the posterior auricular v., which drains the auricle, external acoustic meatus, and tympanic membrane
Maxillary	A short vein, sometimes paired, formed by the convergence of the tributaries of the pterygoid plexus Enters the substance of the parotid gland, traveling posteriorly between the sphenomandibular lig. and the neck of the mandible Unites with the superficial temporal v. to form the retromandibular v. Helps drain blood from the external acoustic meatus and tympanic membrane
Pterygoid plexus	An extensive network of veins that parallels the 2nd and 3rd parts of the maxillary a. Receives branches that correspond to the same branches of the maxillary a. Tributaries eventually converge to form a short maxillary v. Communicates with the cavernous sinus, pharyngeal venous plexus, and facial vein via the deep facial v. and ophthalmic vv. Helps drain the external acoustic meatus
Transverse sinus	One of the deep venous sinuses that helps drain the brain Aids in receiving blood from the tympanic membrane

**VENOUS DRAINAGE OF THE MIDDLE EAR**

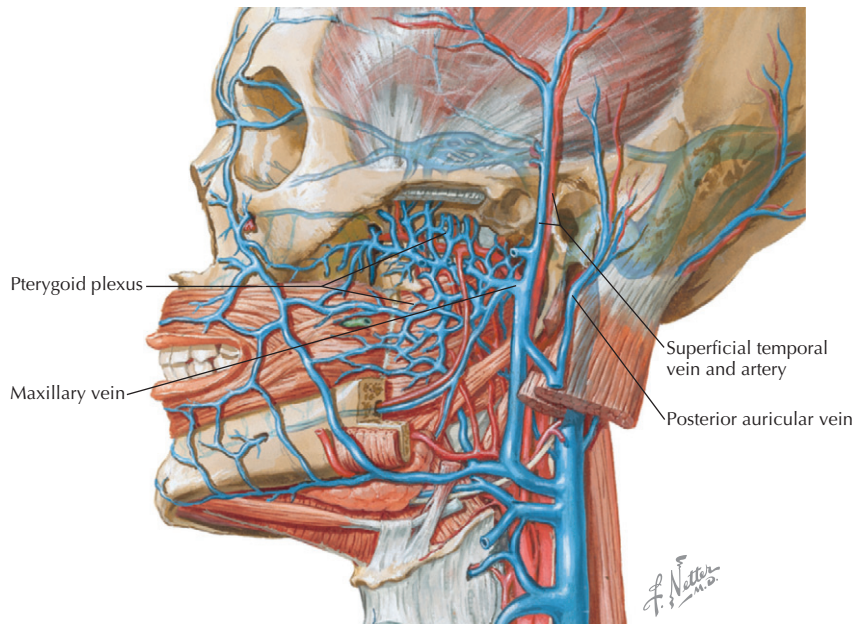
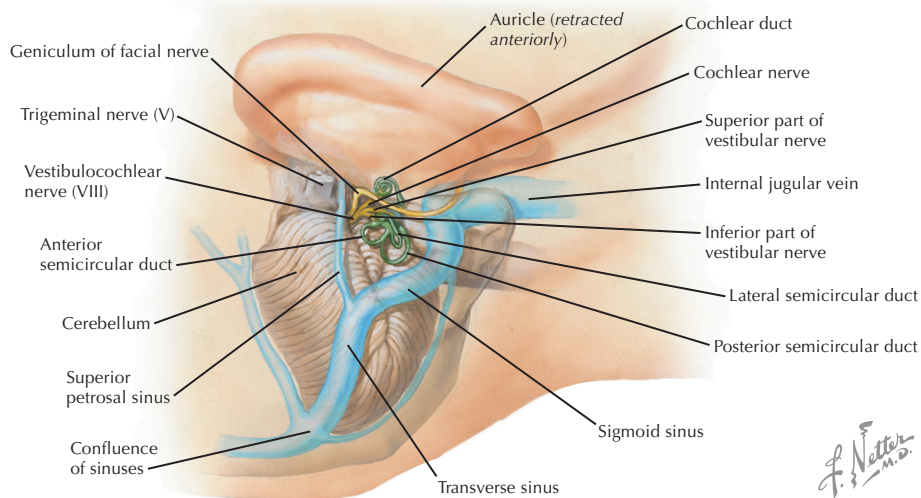
Pterygoid plexus	An extensive network of veins that parallels the 2nd and 3rd parts of the maxillary a. Receives branches that correspond to the same branches of the maxillary a. Tributaries eventually converge to form a short maxillary v. Communicates with the cavernous sinus, pharyngeal venous plexus, and facial vein via the deep facial v. and ophthalmic vv. Helps drain the tympanic cavity
Superior petrosal sinus	One of the deep venous sinuses that helps drain the brain, running along the superior margin of the petrous portion of the temporal bone Aids in receiving blood from the tympanic cavity

**VENOUS DRAINAGE OF THE INNER EAR**

Labyrinthine	Begins in the cochlear and vestibular structures and passes medially through the internal acoustic meatus alongside the labyrinthine a. Drains into the superior petrosal sinus
--------------	--

## VENOUS DRAINAGE OF THE INNER EAR *CONTINUED*

### Lateral projection of right membranous labyrinth



**ACUTE OTITIS EXTERNA**

Infection or inflammation of the auricle and external auditory canal located in the external ear, causing ear pain (otalgia)

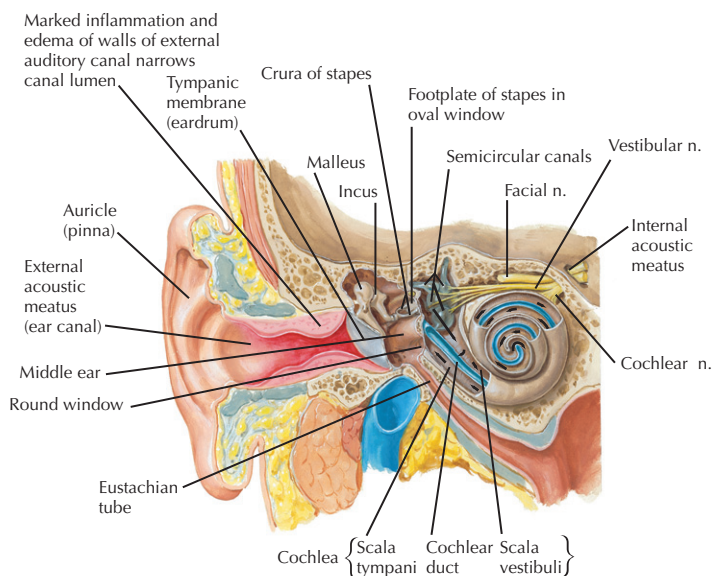
Also called "swimmer's ear"

2 major bacteria are involved: *Staphylococcus aureus* and *Pseudomonas aeruginosa*

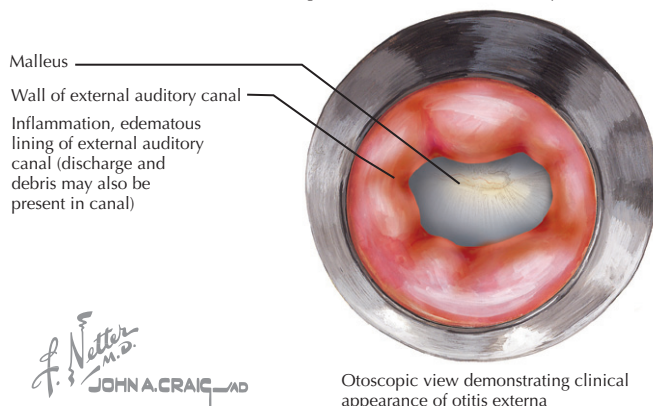
**Pathogenesis**

Excess water from swimming removes some of the ceruminous wax that lines the external auditory canal

Because the wax helps maintain a healthy canal, loss of the wax predisposes the canal to bacterial infections



In otitis externa, inflammation, edema, and discharge are limited to external auditory canal and its walls



Otoscope view demonstrating clinical appearance of otitis externa

# Clinical Correlate

## ACUTE OTITIS MEDIA

An inflammation of the middle ear cavity

More common in children

2 major bacteria are involved: *Streptococcus pneumoniae* and *Haemophilus influenzae*

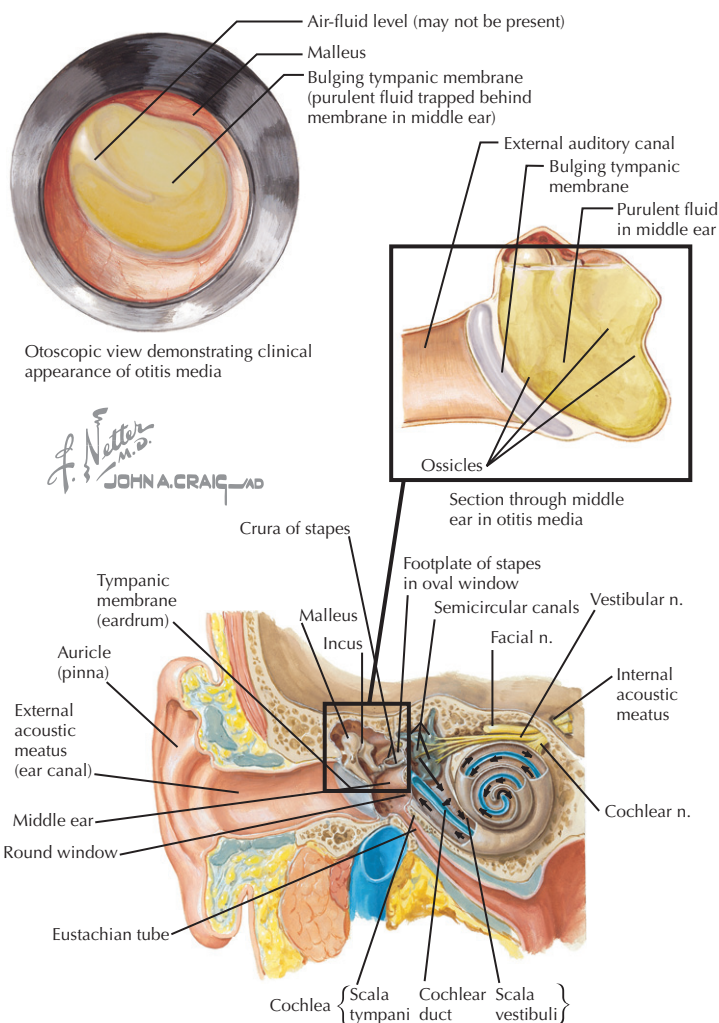
### Pathogenesis

Often results from auditory tube dysfunction

Because the auditory tube allows drainage from the tympanic cavity into the nasopharynx, any blockage leads to a buildup of fluid in the tympanic cavity

When the fluid sits in the tympanic cavity, it predisposes the region to a bacterial infection

The resulting inflammation leads to ear pain (otalgia) and often diminished hearing



## 18 Clinical Correlate

### MASTOIDITIS

A bacterial infection of the mastoid air cells

More common in children than in adults

#### *Pathogenesis*

Although less common since the advent of antibiotics, formerly it often occurred as a complication of acute otitis media, when infection spread from the middle ear cavity to the mastoid air cells

Once within the mastoid air cells, the infection can lead to inflammation and destruction of the mastoid bone

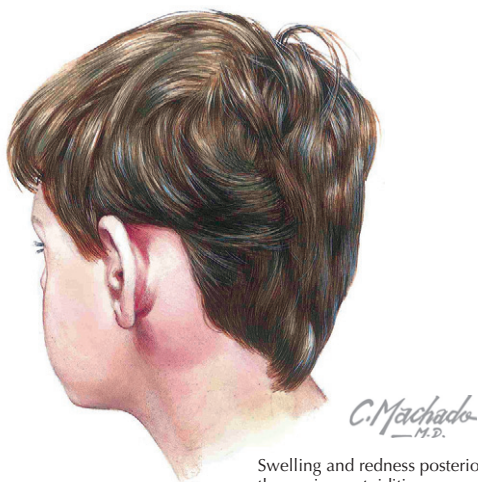Because of the infection's location, it may lead to partial (or total) hearing loss, damage to the mastoid bone, or formation of an epidural abscess, or it may spread to involve the brain

#### *Treatment*

Can be difficult because medications cannot readily reach the mastoid air cells

In some cases, a mastoidectomy may be performed to drain the mastoid if antibiotic therapy is not successful

A myringotomy (creating an opening in the middle ear cavity through the tympanic membrane) is performed to drain the ear in acute otitis media



Swelling and redness posterior to the ear in mastoiditis

## CHAPTER 19

# EYE AND ORBIT

Overview and Topographic Anatomy of the Orbit	480
Osteology of the Orbit	482
Contents of the Orbit	484
Clinical Correlates	507



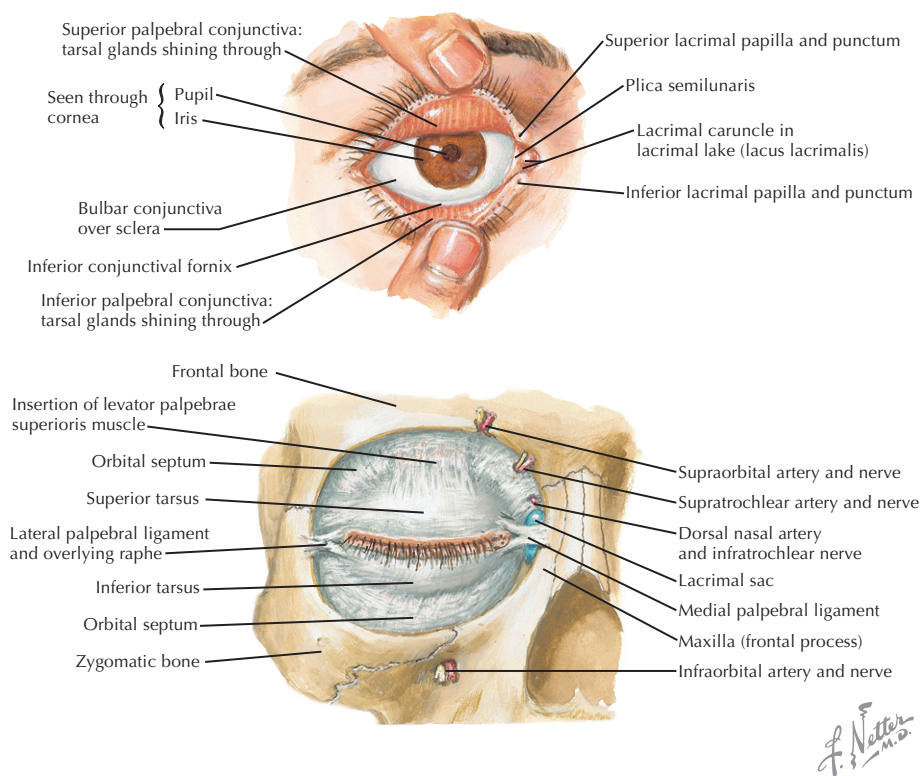
# 19 Overview and Topographic Anatomy of the Orbit

## GENERAL INFORMATION

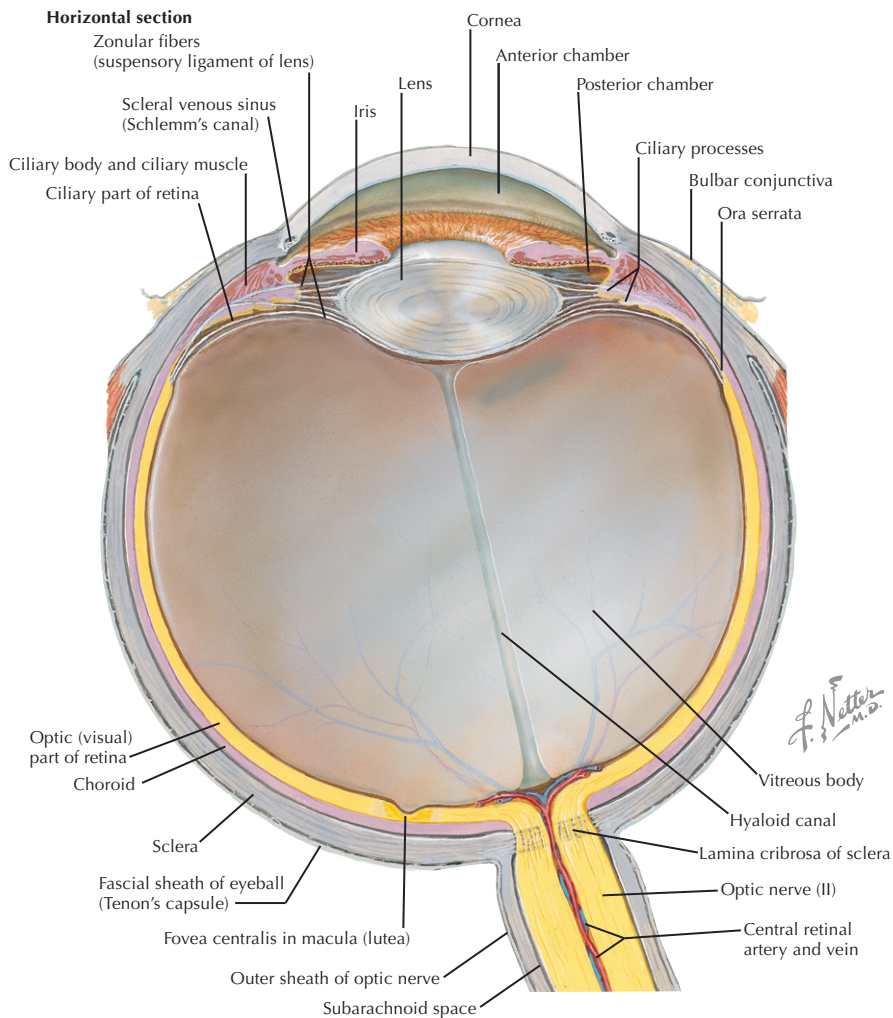
**Orbit:** a pyramid-shaped bony recess in the anterior part of the skull, lined by periosteum called the periorbital fascia

Contents include:

- Eye—organ associated with vision
- Extrinsic muscles
- Optic nerve
- Oculomotor nerve
- Ciliary ganglion
- Trochlear nerve
- Ophthalmic division of the trigeminal nerve
- Abducens nerve
- Ophthalmic artery and branches
- Superior and inferior ophthalmic veins
- Lacrimal apparatus
- Much fatty tissue



## GENERAL INFORMATION *CONTINUED*



# 19 Osteology of the Orbit

## OPENINGS IN THE ORBIT

Opening	Bony Boundaries	Structures Passing through Opening
Optic foramen	Lesser wing of the sphenoid	Optic n. Ophthalmic a.
Superior orbital fissure	Greater wing of the sphenoid Lesser wing of the sphenoid	Lacrimal branch of the trigeminal n.'s ophthalmic division Frontal branch of the trigeminal n.'s ophthalmic division Nasociliary branch of the trigeminal n.'s ophthalmic division Oculomotor n. Trochlear n. Abducens n. Superior ophthalmic v. Inferior ophthalmic v.
Inferior orbital fissure	Greater wing of the sphenoid Maxilla	Infraorbital n. and vessels Zygomatic n. Branch of inferior ophthalmic v. that connects to the pterygoid plexus
Supraorbital foramen	Frontal	Supraorbital n. and vessels Supratrochlear n. and vessels
Infraorbital groove and canal	Maxilla	Infraorbital n. and vessels
Zygomatic foramen (1 or 2 openings)	Zygomatic	Branches of the zygomatic
Nasolacrimal canal	Lacrimal	Nasolacrimal duct
Anterior ethmoidal foramen	Ethmoid Frontal	Anterior ethmoidal n. and vessels
Posterior ethmoidal foramen	Ethmoid Frontal	Posterior ethmoidal n. and vessels

## BONES CREATING THE ORBITAL MARGIN

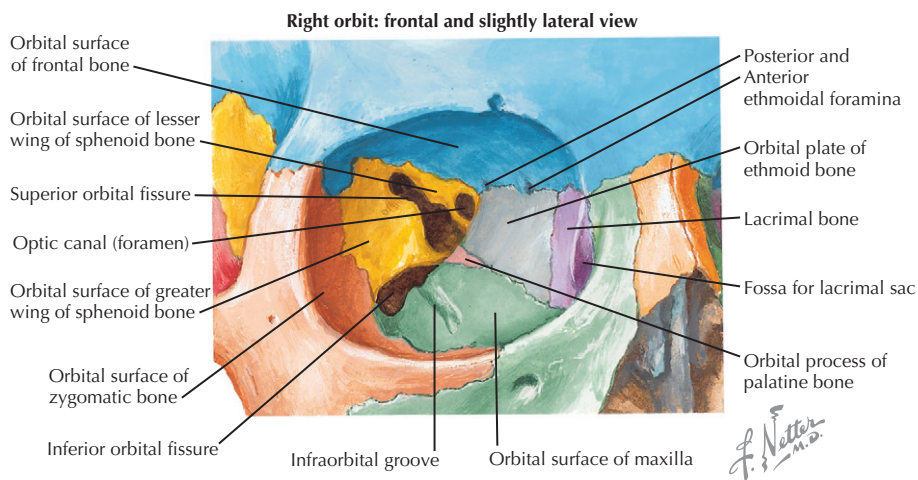
Frontal  
Zygomatic  
Maxilla

## WALLS OF THE ORBIT

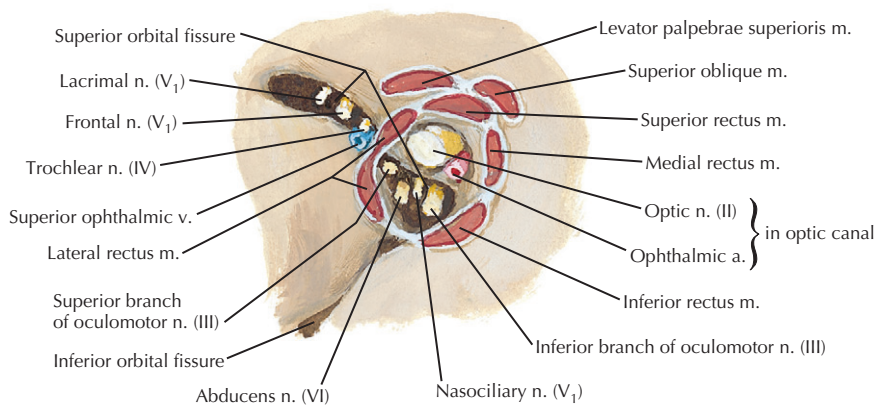
Superior	Frontal (orbital plate) Lesser wing of the sphenoid
Inferior	Maxilla Zygomatic Palatine (orbital process)
Medial	Ethmoid (lamina papyracea) Lacrimal Sphenoid Maxilla
Lateral	Zygomatic Greater wing of the sphenoid

# Osteology of the Orbit

## WALLS OF THE ORBIT *CONTINUED*



### Muscle attachments and nerves and vessels entering orbit



## 19 Contents of the Orbit

### EYE

**Eye:** a spherical globe with a diameter of approximately 2.5 cm that lies in the orbit's anterior portion

Surrounded by a thin capsule called the fascia bulbi (Tenon's capsule):

- Provides support
- Allows for movement

Composed of 3 coats:

- Sclera
- Uveal tract
- Retina

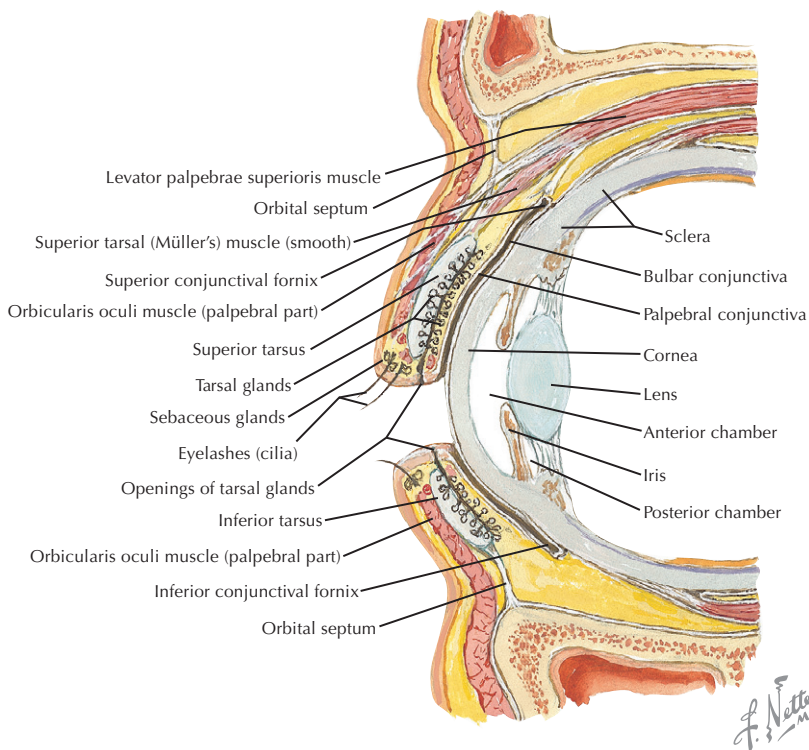
Divided into an anterior and a posterior segment:

**Anterior Segment:**

- Filled with aqueous humor
- Separated into anterior and posterior chambers by the iris
- Contains aqueous humor secreted by the ciliary body and drained through a trabeculated network eventually into the superior ophthalmic vein
- Intraocular pressure is measured in the anterior segment, normally 10 to 20 mm Hg

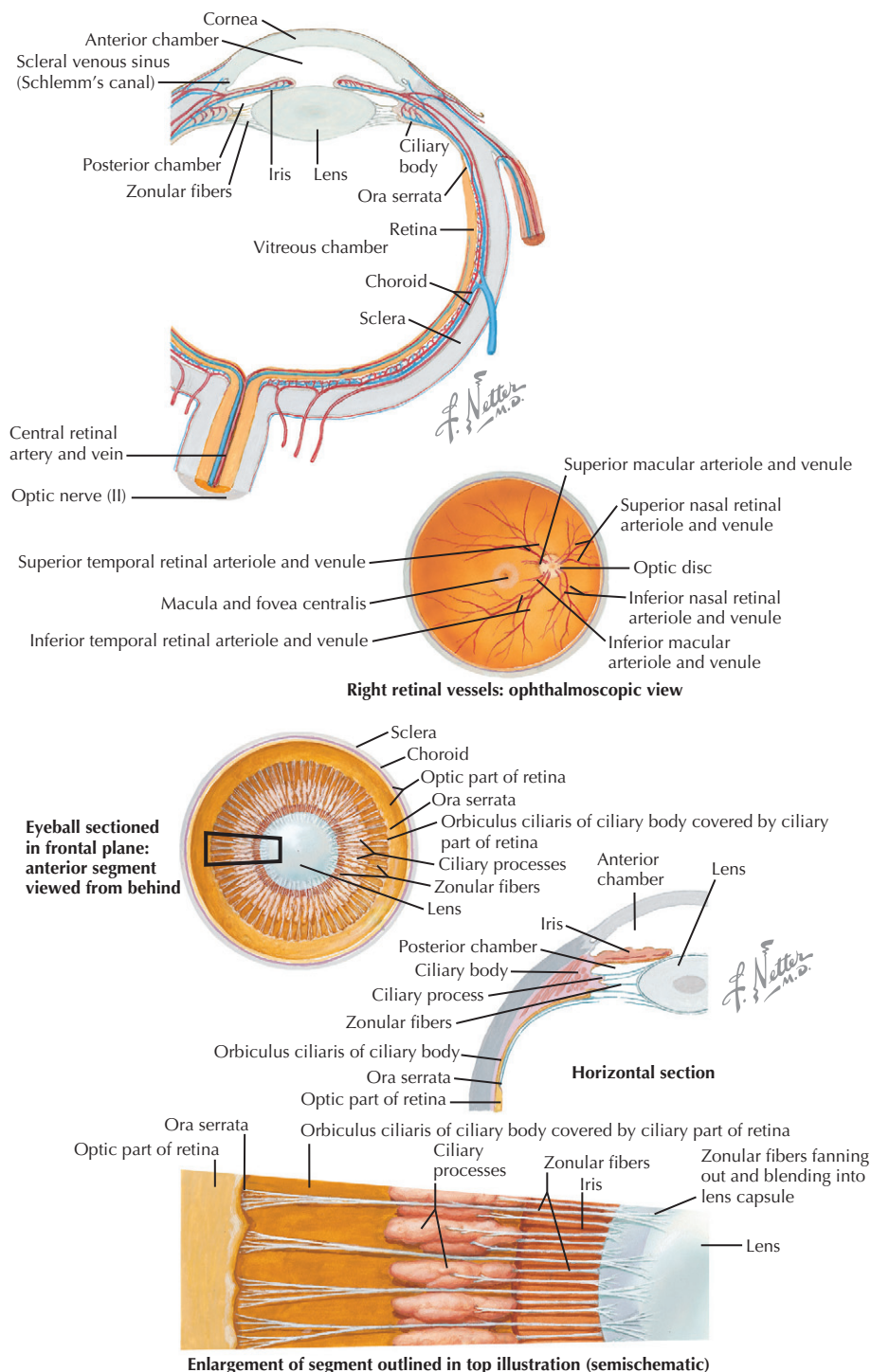
**Posterior Segment:**

- Filled with vitreous fluid
- Called the vitreous cavity



# Contents of the Orbit

## EYE CONTINUED





## 19 Contents of the Orbit

### **EYE** CONTINUED

#### COMPONENTS

##### *Sclera*

The outermost layer, very fibrous

White along the periphery, except for the anterior portion—the cornea, which is transparent

##### *Uveal Tract*

Composed of choroid layer, ciliary body, and iris

##### *Choroid*

- The pigmented vascular layer between the sclera and the retina
- Extends posteriorly from the region of the optic nerve anteriorly, where it is continuous with the ciliary body near the ora serrata (anterior margin of the retina)

##### *Ciliary Body*

- Located between the choroid and the iris
- Ring-shaped; has a series of transparent fibers that form the suspensory ligament of the lens
- Within it is the ciliary muscle, which changes the shape of the lens

##### *Iris*

- A thin disclike structure with a central opening—the pupil
- Separates the aqueous humor into the anterior chamber (anterior to the iris) and the posterior chamber (between the iris and the lens)
- Contains the sphincter and dilator pupillae muscles, which change the pupil's shape in response to light

##### *Lens*

Located posterior to the iris

A transparent biconcave structure responsible for focusing

Connected to the ciliary body by the suspensory ligaments

##### *Retina*

The innermost coat of the eye

Thin and highly vascular

Three areas located on the retina's posterior portion:

- Optic disc
- Macula lutea
- Fovea centralis

##### *Optic Disc*

Area where the optic nerve enters the retina is called the "blind spot"

Retina's central artery enters the eye through the optic disc and divides into superior and inferior branches

##### *Macula Lutea*

Lateral to the optic disc

A depressed, yellow-appearing area that contains the fovea centralis in its center

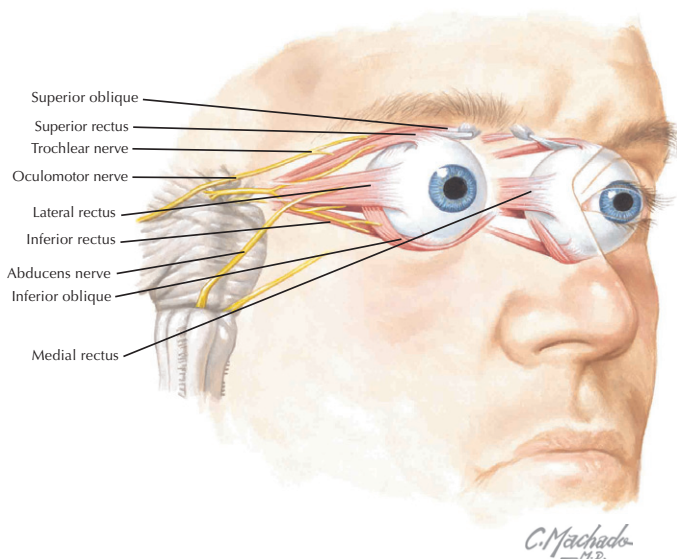
# Contents of the Orbit

## MUSCLES

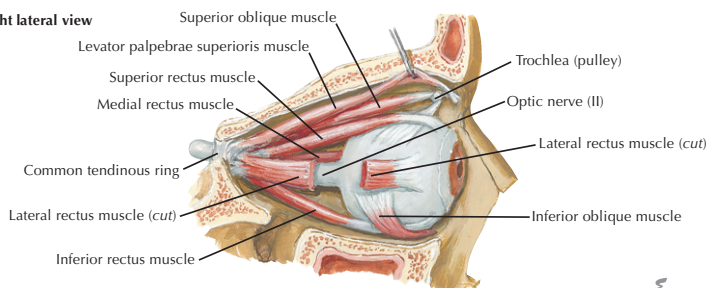
ASSOCIATED EXTRINSIC MUSCLE OF THE ORBIT					
Muscle	Origin	Insertion	Actions	Nerve	Comment
Levator palpebrae superioris	Roof of the orbit	Skin of the upper eyelid	Raises the upper eyelid	Superior division of the oculomotor Sympathetic fibers to the smooth muscle	Opposed by the palpebral part of the orbicularis oculi m. There are smooth muscle fibers which insert into the superior tarsal plate which are innervated by sympathetic fibers Lesions of the sympathetics will lead to a ptosis, or drooping of the upper eyelid
EXTRINSIC MUSCLES OF THE EYE					
Muscle	Origin	Insertion	Actions on Eye	Nerve	Comment
Superior rectus	Common tendinous ring on sphenoid	Superior sclera	Elevation Adduction Intorsion	Superior division of the oculomotor	A check ligament attaches it to the levator palpebrae superioris m. to help elevate the upper eyelid
Inferior rectus		Inferior sclera	Depression Adduction Extorsion	Inferior division of the oculomotor	A check ligament attaches it to the inferior tarsal plate to help depress the lower eyelid
Medial rectus		Medial sclera	Adduction		The most medial of the extraocular muscles
Lateral rectus		Lateral sclera	Abduction	Abducens	Impaired in abducens n. palsy
Superior oblique	Body of the sphenoid	Superior portion of the posterolateral sclera	Depression Abduction Intorsion	Trochlear	Tendon passes through the trochlea, a fibrocartilaginous pulley
Inferior oblique	Maxilla (lateral to the lacrimal groove)	Inferior portion of the posterolateral sclera	Elevation Abduction Extorsion	Inferior division of the oculomotor	Only extraocular muscle that attaches to the maxilla

# 19 Contents of the Orbit

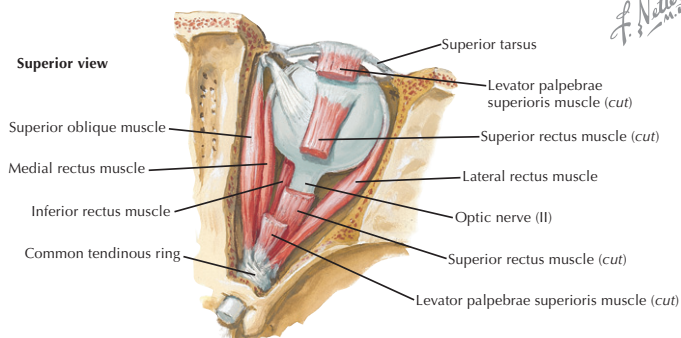
## MUSCLES CONTINUED



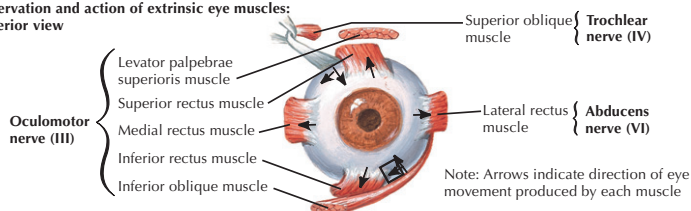
**Right lateral view**



**Superior view**



**Innervation and action of extrinsic eye muscles: anterior view**

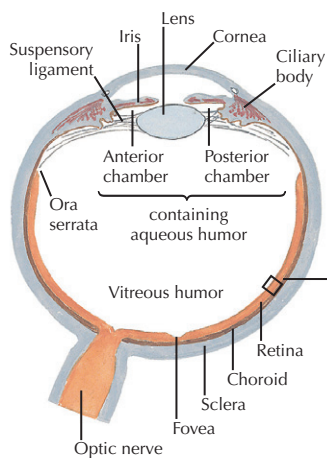




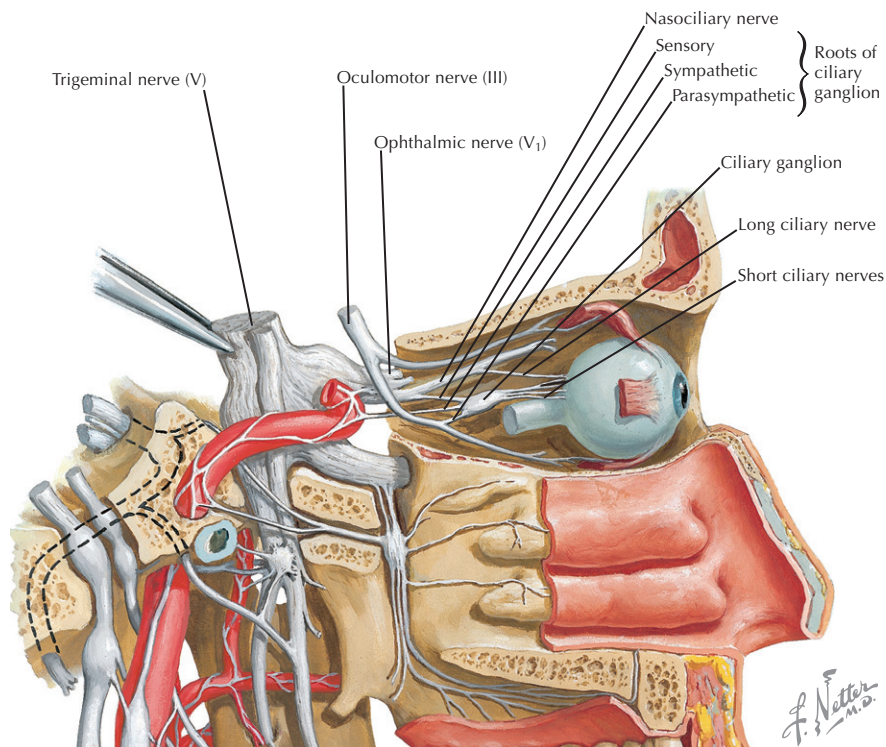
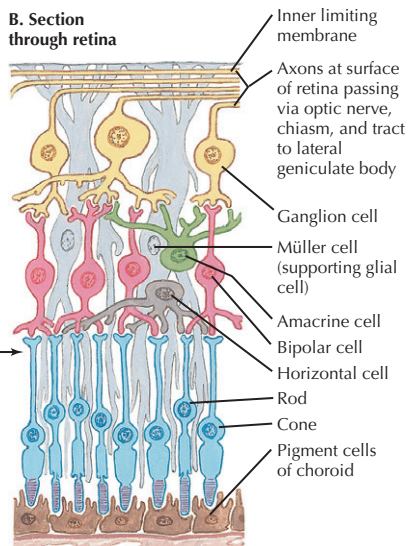
# 19 Contents of the Orbit

## NERVE SUPPLY CONTINUED

**A. Eyeball**



**B. Section through retina**



# Contents of the Orbit

## NERVE SUPPLY *CONTINUED*

### OPTIC NERVE (VISION)

About 25 mm in length, allows for eye movement via the extraocular muscles  
Covered by an outer layer of dura mater and an inner layer of arachnoid, which attach anteriorly to the eye, where the optic n. enters the sclera, and posteriorly, where it merges with the periosteum lining the orbit at the optic foramen

Central a. of the retina enters the optic n. posterior to the bulb of the eye

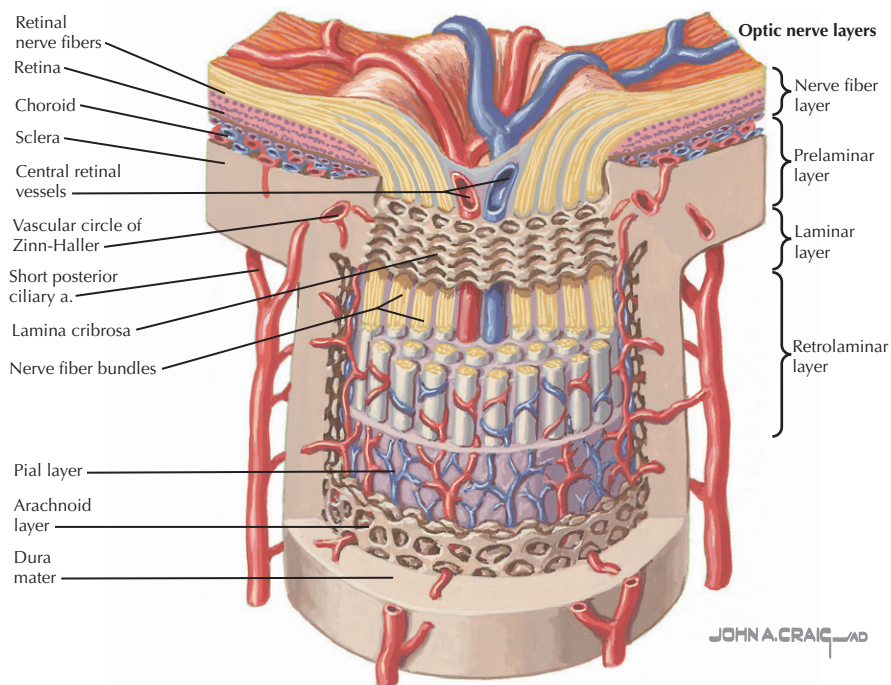
#### Course

Axons from the ganglionic cells of the retina comprise the optic n. and come together at the optic disc  
They leave the eye and travel as the optic n. posteriorly and medially through the orbit

Posteriorly, the optic n. passes through the optic foramen to enter the cranial cavity

The 2 optic nn. meet at the optic chiasm, located superior to the hypophyseal fossa

Optic chiasm gives rise to the optic tracts, which terminate in the lateral geniculate nucleus of the thalamus before giving rise to the optic radiations that terminate in the occipital lobes





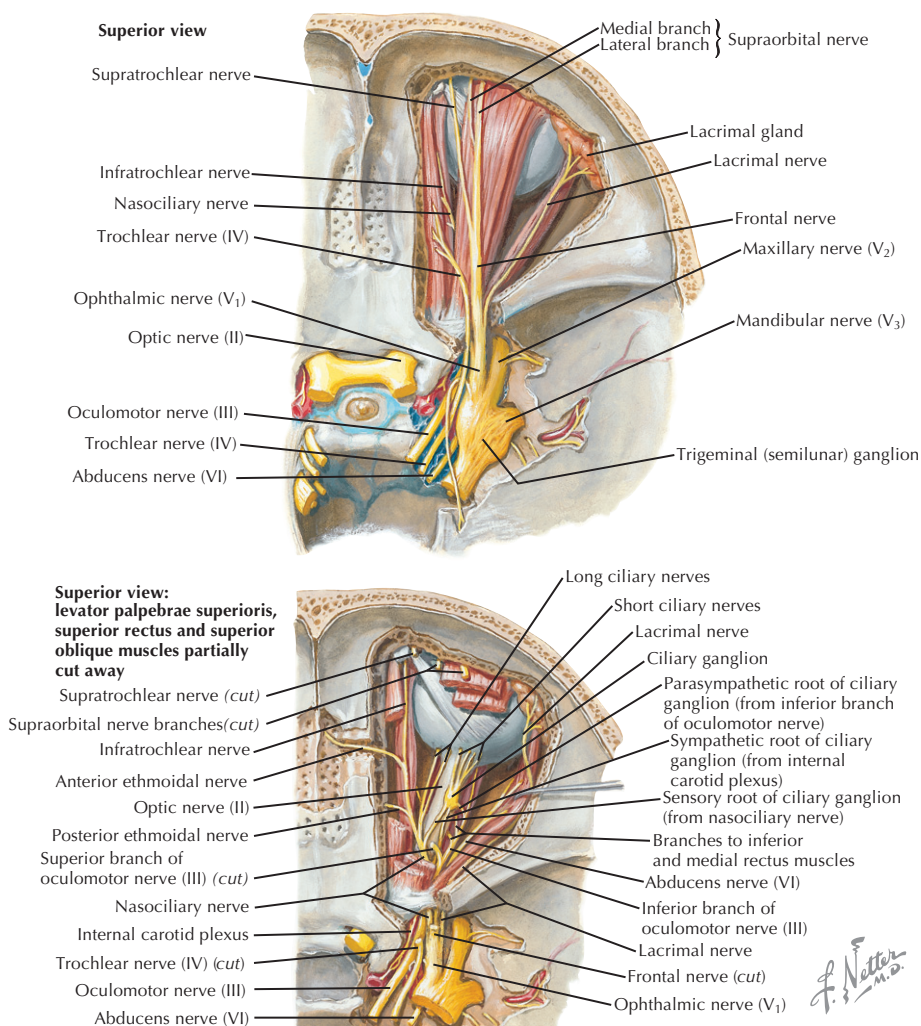
# 19 Contents of the Orbit

## NERVE SUPPLY *CONTINUED*

GENERAL SENSATION		
Ophthalmic Division of the Trigeminal Nerve		
<p>This division, being a branch of the trigeminal n., is sensory in function</p> <p>Arises from the main nerve in the middle cranial fossa</p> <p>Passes anterior on the lateral wall of the cavernous sinus immediately inferior to the oculomotor and trochlear nn., but superior to the maxillary division of the trigeminal</p> <p>Immediately before entering the orbit, through the superior orbital fissure, it divides into 3 major branches: lacrimal, frontal, and the nasociliary nn.</p>		
Nerve	Source	Course
Lacrimal	Ophthalmic division of the trigeminal n.	<p>Smallest branch of the ophthalmic division of the trigeminal n.</p> <p>Passes anteriorly to enter the orbit through the superior orbital fissure</p> <p>In the orbit, it travels on the superior border of the lateral rectus m. with the lacrimal a.</p> <p>Before reaching the lacrimal gland, it communicates with the zygomatic branch of the maxillary division of the trigeminal to receive autonomic nervous fibers</p> <p>Enters the lacrimal gland and supplies it and the conjunctiva before piercing the orbital septum to supply the skin of the upper eyelid</p>
Frontal		<p>Largest branch of the ophthalmic division of the trigeminal n.</p> <p>Passes anteriorly to enter the orbit through the superior orbital fissure</p> <p>In the orbit it passes anteriorly between the periosteum of the orbit and the levator palpebrae superioris m.</p> <p>About halfway in the orbit, it divides into its 2 terminal nerves, the supraorbital and supratrochlear</p>
<i>Supraorbital</i>	Frontal n.: the 2 terminal branches of the frontal n. in the orbit	<p>Passes between the levator palpebrae superioris m. and periosteum of the orbit</p> <p>Continues anteriorly to the supraorbital foramen (notch)</p> <p>At the level of the supraorbital margin, it sends nerve supply to the frontal sinus and ascends superiorly along the scalp</p> <p>Divides into medial and lateral branches, which travel up to the vertex of the scalp</p>
<i>Supratrochlear</i>		<p>Once the supratrochlear a. joins it within the orbit, it continues to pass anteriorly toward the trochlear</p> <p>In the trochlear region, it often supplies the frontal sinus before exiting the orbit</p> <p>Ascends along the scalp, at first deep to the musculature in the region before piercing them to reach the cutaneous innervation along the scalp</p>
Nasociliary	Ophthalmic division of the trigeminal n.	<p>Passes anteriorly to enter the orbit through the superior orbital fissure</p> <p>Enters the orbit lateral to the optic n.</p> <p>Travels across the optic n. anteriorly and medially to lie between the medial rectus and the superior oblique mm. along the medial wall of the orbit</p> <p>All along its path, it gives rise to other nerves, including the sensory root of the ciliary ganglion, and the long ciliary and posterior ethmoidal nn., until terminating into the anterior ethmoidal and infratrochlear nn. near the anterior ethmoidal foramen</p>
<i>Sensory root of the ciliary ganglion</i>	Nasociliary n.	<p>Travels anteriorly on the lateral side of the optic n. to enter the ciliary ganglion</p> <p>Carries general sensory fibers, which are distributed by the short ciliary nn.</p>
<i>Long ciliary</i>		<p>There are 2 to 4 branches that travel anteriorly to enter the posterior part of the sclera of the eye</p>

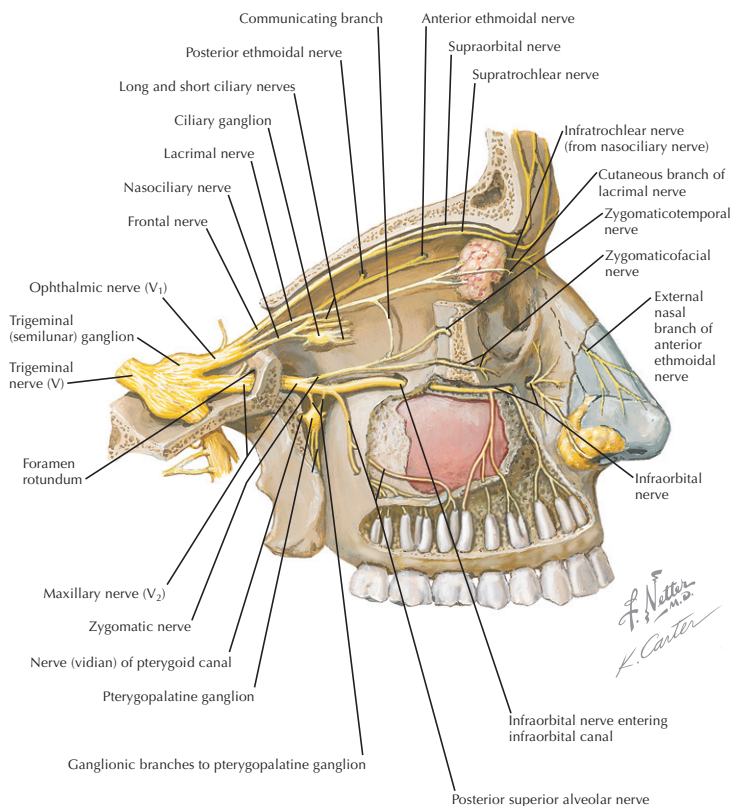
## NERVE SUPPLY CONTINUED

Nerve	Source	Course
Posterior ethmoidal	Nasociliary n.	Travels deep to the superior oblique m. to pass through the posterior ethmoidal foramen Supplies the sphenoid sinus and the posterior ethmoidal sinus
Anterior ethmoidal		Arises on the medial wall of the orbit Enters the anterior ethmoidal foramen and travels through the canal to enter the anterior cranial fossa Supplies the anterior and middle ethmoidal sinuses before entering and supplying the nasal cavity Terminates as the external nasal n. on the face
Infratrochlear		1 of the terminal branches of the nasociliary n. Passes anteriorly on the superior border of the medial rectus m. Passes inferior to the trochlea toward the medial angle of the eye Supplies the skin of the eyelids and bridge of the nose, the conjunctiva, and all of the lacrimal structures



NERVE SUPPLY *CONTINUED*

GENERAL SENSATION		
Maxillary Division of the Trigeminal Nerve		
<p>Travels along the lateral wall of the cavernous sinus</p> <p>Before exiting the middle cranial fossa, it gives off a meningeal branch that innervates the dura mater</p> <p>Passes from the middle cranial fossa into the pterygopalatine fossa via the foramen rotundum</p> <p>Within the pterygopalatine fossa, it gives rise to 4 branches:</p> <ul style="list-style-type: none"> <li>posterior superior alveolar n., zygomatic n., ganglionic branches, and the infraorbital n.</li> </ul> <p>The zygomatic and infraorbital continue within the orbit</p>		
Nerve	Source	Course
Zygomatic	Maxillary division of the trigeminal n.	Enters the orbit via the inferior orbital fissure Within the orbit, it divides into the zygomaticotemporal and zygomaticofacial branches, which exit the orbit along the lateral wall via 1 or 2 zygomatic foramen
Infraorbital		<p>Considered the continuation of the maxillary division of the trigeminal n.</p> <p>Passes through the inferior orbital fissure to enter the orbit</p> <p>Passes anteriorly through the infraorbital groove and infraorbital canal and exits onto the face via the infraorbital foramen</p> <p>Within the infraorbital canal, it gives rise to the anterior superior alveolar and middle superior alveolar nn.</p> <p>Once the infraorbital n. exits onto the face, it divides into 3 terminal branches:</p> <ul style="list-style-type: none"> <li>• Inferior palpebral—supplies the skin of the lower eyelid and conjunctiva</li> <li>• Nasal—supplies the ala of the nose</li> <li>• Superior labial—supplies the skin of the upper lip</li> </ul>

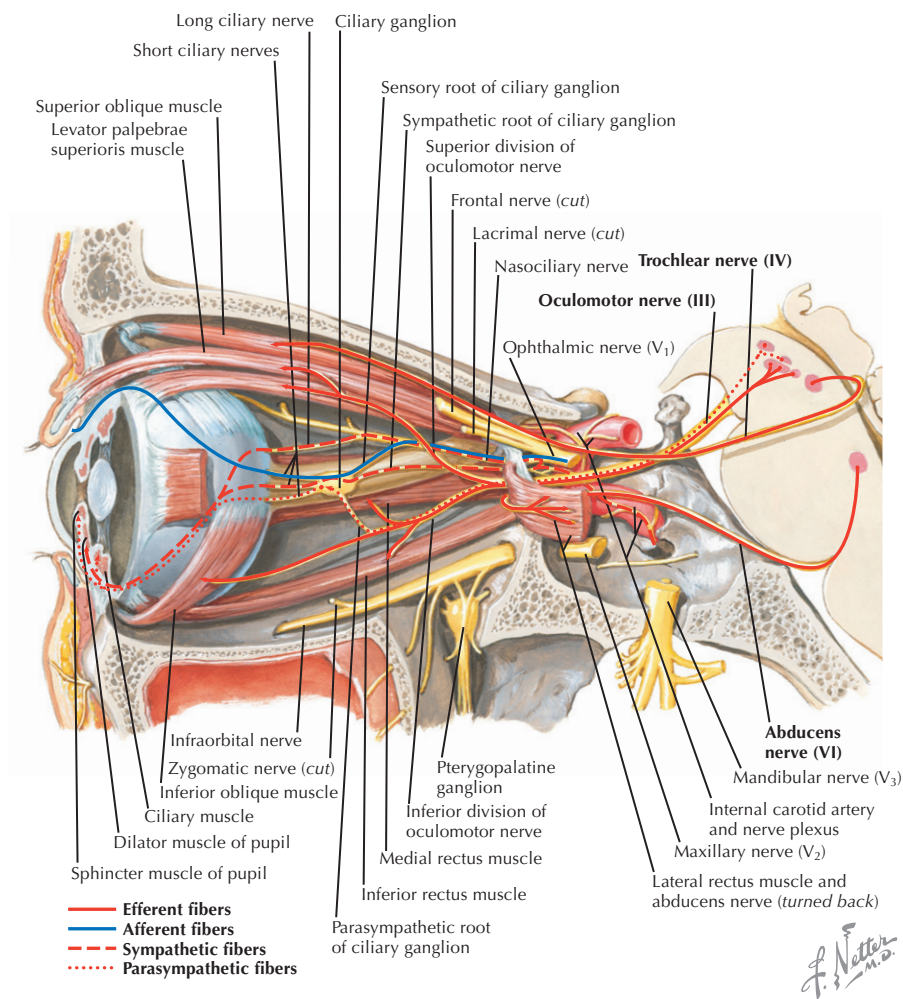


# Contents of the Orbit

## NERVE SUPPLY *CONTINUED*

GENERAL MOTOR		
Nerve	Source	Course
Oculomotor (cranial n. III)	Ventral surface of the midbrain	Innervates 4 of the extraocular muscles—superior rectus, inferior rectus, medial rectus, and the inferior oblique mm.—as well as the levator palpebrae superioris m. Also provides parasympathetic innervation to the intrinsic muscles of the eye Passes anterior on the lateral wall of the cavernous sinus immediately superior to the trochlear n. Immediately before entering the orbit, it divides into superior and inferior divisions; both enter the orbit through the superior orbital fissure
Superior division of the oculomotor	Oculomotor	Enters the orbit via the superior orbital fissure Travels superior to the optic n. to enter the inferior border of the superior rectus m. Passes through the superior rectus to give rise to a branch that enters the inferior surface of the levator palpebrae superioris m.
Inferior division of the oculomotor		Enters the orbit via the superior orbital fissure Immediately divides into 3 muscular branches that enter: <ul style="list-style-type: none"> <li>• The lateral surface of the medial rectus</li> <li>• The superior surface of the inferior oblique</li> <li>• The superior surface of the inferior rectus</li> </ul> Gives rise to the parasympathetic root of the ciliary ganglion
Trochlear (cranial n. IV)	Dorsal surface of the midbrain	Innervates the superior oblique Passes anterior on the lateral wall of the cavernous sinus immediately inferior to the oculomotor n. Enters the orbit via the superior orbital fissure and immediately enters the superior oblique to innervate it
Abducens (cranial n. VI)	Ventral surface of the pons	Travels anteriorly within the cavernous sinus beside the internal carotid a. Enters the orbit via the superior orbital fissure Travels anteriorly to enter the medial surface of the lateral rectus to innervate it

## NERVE SUPPLY CONTINUED



# Contents of the Orbit

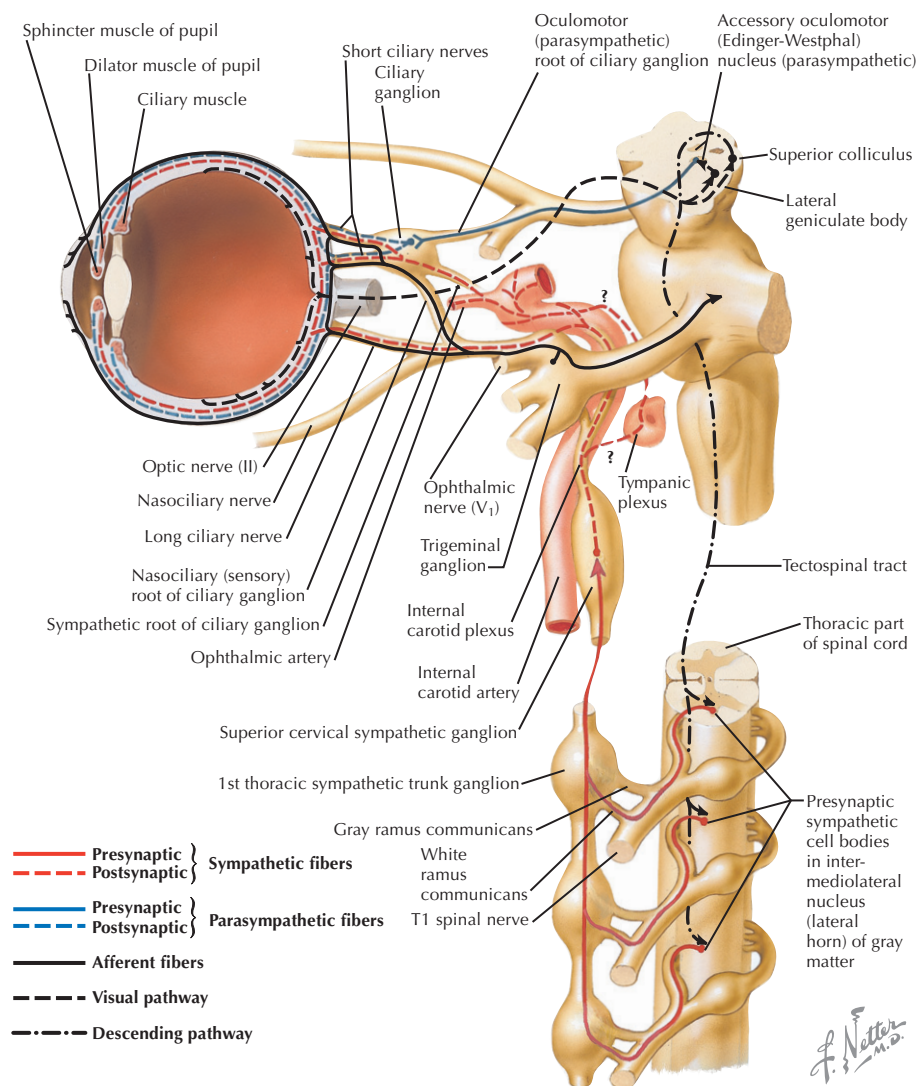
## NERVE SUPPLY *CONTINUED*

PARASYMPATHETICS OF THE EYE			
Type of Neuron	Location of Cell Body	Characteristics of the Cell Body	Course of the Neuron
Preganglionic neuron	Edinger-Westphal nucleus	A collection of nerve cell bodies located in the midbrain	<p>Arise from the Edinger-Westphal nucleus in the midbrain from the oculomotor n.</p> <p>Oculomotor n. passes anteriorly on the lateral wall of the cavernous sinus immediately superior to the trochlear n.</p> <p>Immediately before entering the orbit, the nerve divides into the superior and inferior divisions</p> <p>Both the superior and inferior divisions of the oculomotor enter the orbit through the superior orbital fissure</p> <p>Preganglionic parasympathetic fibers travel in the inferior division</p> <p>A small parasympathetic root passes from the inferior division of the oculomotor to the ciliary ganglion, carrying the preganglionic parasympathetic fibers</p>
Postganglionic neuron	Ciliary ganglion	<p>Located anterior to the optic foramen between the optic n. and the lateral rectus</p> <p><i>3 roots connect to the ciliary ganglion:</i></p> <ul style="list-style-type: none"> <li>• Sensory root from the ophthalmic division of the trigeminal, which carries general sensation fibers to the eye via the short ciliary nn.</li> <li>• Parasympathetic root from the inferior division of the oculomotor, carrying preganglionic parasympathetic fibers to the ganglion</li> <li>• Sympathetic root that arises from the postganglionic sympathetic fibers, which were carried by the internal carotid a.</li> <li>• The short ciliary nn. usually number about 8</li> </ul> <p>Short ciliary nn. arise from the ciliary ganglion to enter the posterior portion of the eye</p> <p>Fibers from all 3 roots pass through the ciliary ganglion and short ciliary nn. to enter the eye</p> <p>Only the parasympathetic fibers synapse in the ciliary ganglion</p>	<p>Arise in the ciliary ganglion, following a synapse with the preganglionic parasympathetic fibers</p> <p>Travel through the short ciliary nn. to enter the eye's posterior portion</p> <p>Innervate the sphincter pupillae m. and the ciliary muscles</p>



# 19 Contents of the Orbit

## NERVE SUPPLY CONTINUED



# Contents of the Orbit

## NERVE SUPPLY *CONTINUED*

ANATOMIC PATHWAY FOR SYMPATHETICS OF THE EYE			
Type of Neuron	Name of Cell Body	Characteristics of the Cell Body	Course of the Neuron
Preganglionic neuron	Intermediolateral horn nucleus	Collection of nerve cell bodies located in the lateral horn nucleus of the spinal cord between spinal segments T1 and T3 (and possibly T4)	Arise from the intermediolateral horn nuclei from T1 to T3 (4) Travel through the ventral root of the spinal cord to the spinal n. Enter the sympathetic chain via a white ramus communicantes Once in the sympathetic chain, the preganglionic fibers for the eye will ascend and synapse with postganglionic fibers in the superior cervical ganglion
Postganglionic neuron	Superior cervical ganglion	Collection of nerve cell bodies located in the superior cervical ganglion, which is located at the base of the skull	Arise in the superior cervical ganglion Postganglionic fibers will follow the internal carotid a. on the carotid plexus As the internal carotid nears the orbit, the postganglionic fibers branch and follow various structures that connect to the eye, such as the ophthalmic a. and its branches, and the long ciliary nn. that arise from the ophthalmic division of the trigeminal n. In the eye, the postganglionic fibers innervate the eye's dilator pupillae m.

## VASCULAR SUPPLY

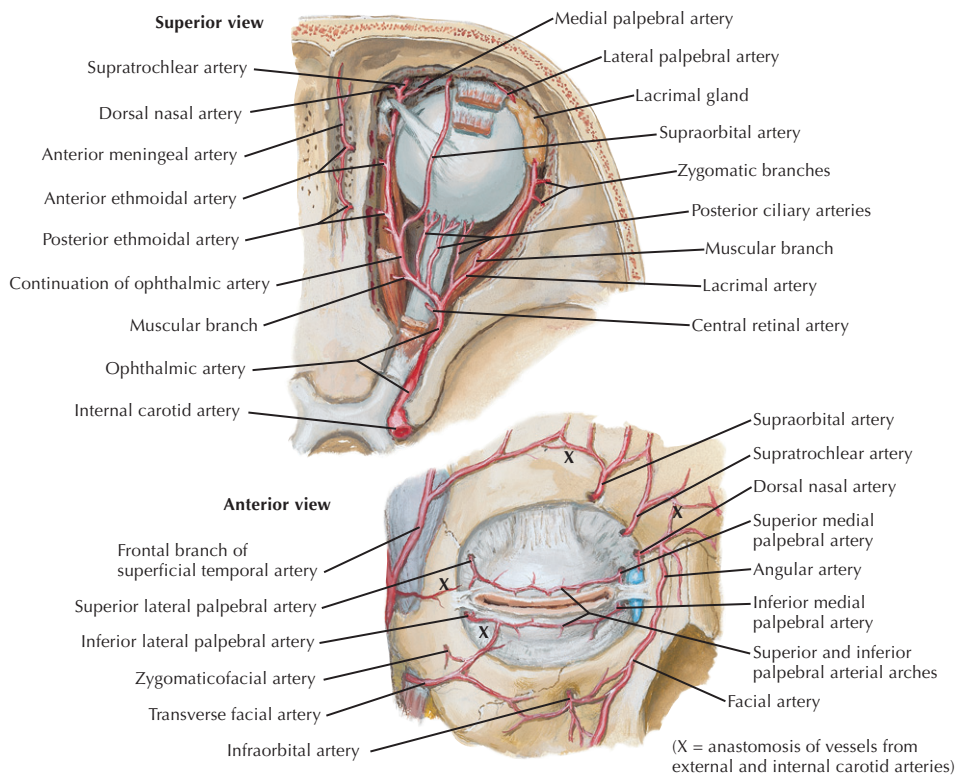
ARTERIAL SUPPLY		
Artery	Source	Course
Ophthalmic	Internal carotid a.	Enters the orbit through the optic foramen immediately inferior and lateral to the optic n. Crosses the optic n. to reach the medial part of the orbit While in the orbit, the artery gives rise to a series of arteries that supply the orbit and associated structures The terminal aa. of the ophthalmic a. anastomose along the scalp and face with the superficial temporal, facial, and infraorbital branches of the maxillary a.
<i>Lacrimal</i>	Ophthalmic a.	Arises near the optic foramen One of the ophthalmic's largest branches Follows the lacrimal n. along the superior border of the lateral rectus m. of the eye to reach and supply the lacrimal gland Gives rise to a series of terminal branches, such as the lateral palpebral, that supply the eyelids and conjunctiva Gives rise to a zygomatic branch that then gives rise to the zygomaticotemporal and zygomaticofacial aa. Supply those regions of the face
<i>Supratrochlear</i>		It exits the orbit at the medial angle accompanied by supratrochlear n. Ascends on the scalp, anastomosing with the supraorbital a. and supratrochlear a. from the opposite side

**VASCULAR SUPPLY** *CONTINUED*

<b>ARTERIAL SUPPLY</b> <i>CONTINUED</i>		
<b>Artery</b>	<b>Source</b>	<b>Course</b>
Supraorbital		Branches from the ophthalmic a. as it passes the optic n. Passes on the medial side of the levator palpebrae superioris and superior rectus mm. to join the supraorbital n. Passes through the supraorbital foramen (notch) and ascends superiorly along the scalp Anastomoses with the supratrochlear a. and superficial temporal a.
Anterior ethmoidal		Travels with the nerve through the anterior ethmoidal canal to supply the anterior and middle ethmoidal sinuses Continues to give rise to a meningeal branch and nasal branches that supply the lateral wall and septum of the nose Then gives rise to the terminal external nasal branch that supplies the external nose
Posterior ethmoidal		Travels through the posterior ethmoidal canal to supply the posterior ethmoidal sinus Gives rise to meningeal and nasal branches that anastomose with branches of the sphenopalatine
<i>External nasal</i>	A terminal branch of the anterior ethmoidal a.	Supplies the area along the external nose at the junction between the nasal bone and the lateral nasal cartilage
Medial palpebral (superior and inferior)	Ophthalmic a. of the internal carotid a.	Arise near the trochlea and exit the orbit to pass along the upper and lower eyelids These arteries anastomose with the other arteries supplying the face in the region
<i>Dorsal nasal (Infratrochlear)</i>	One of the ophthalmic a.'s terminal branches	Exits the orbit along the superomedial border along with the infratrochlear n. Supplies the area along the bridge of the nose
Muscular	Ophthalmic a. from the internal carotid a.	Supply the extraocular muscles of the orbit
<i>Anterior ciliary</i>	Muscular branches from the ophthalmic a.	Pass anteriorly to the anterior surface of the eye following the tendons of the extraocular muscles
Short posterior ciliary	Ophthalmic a. from the internal carotid a.	Usually 6 to 10 arise Travel anteriorly around the optic n. to enter the posterior portion of the eye
Long posterior ciliary		Usually 2 arise Travel anteriorly to enter the posterior portion of the eye near the optic n.
Central a. of the retina		Branches from the ophthalmic a. early on its entrance into the orbit Follows the optic n. and enters the nerve about halfway into the orbit Supplies the retina
Maxillary	1 of 2 terminal branches of the external carotid a.	Gives rise to a series of branches Only the infraorbital branch supplies the orbit
<i>Infraorbital</i>	Maxillary a.	Once the infraorbital exits the infraorbital foramen, the inferior palpebral a. supplies the lower eyelid Supplies some muscles along the floor of the orbit near the inferior orbital canal

# Contents of the Orbit

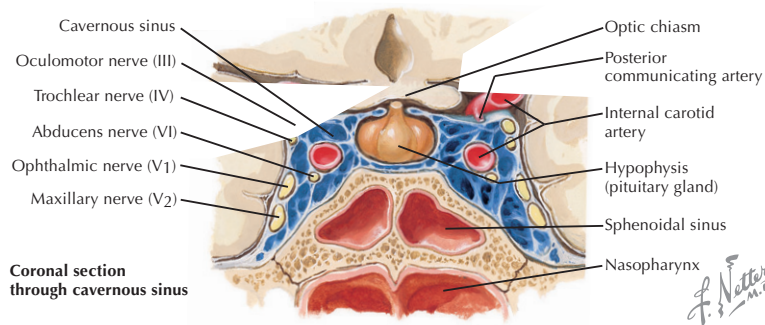
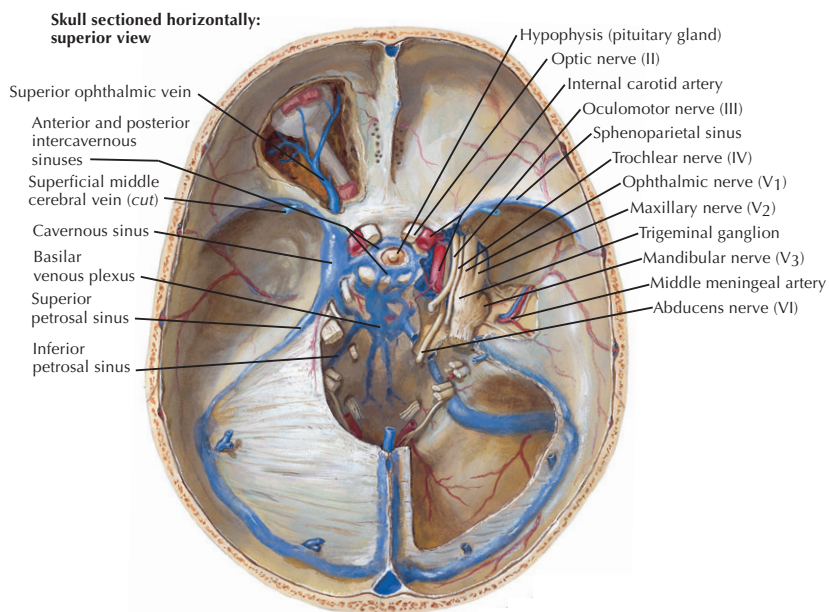
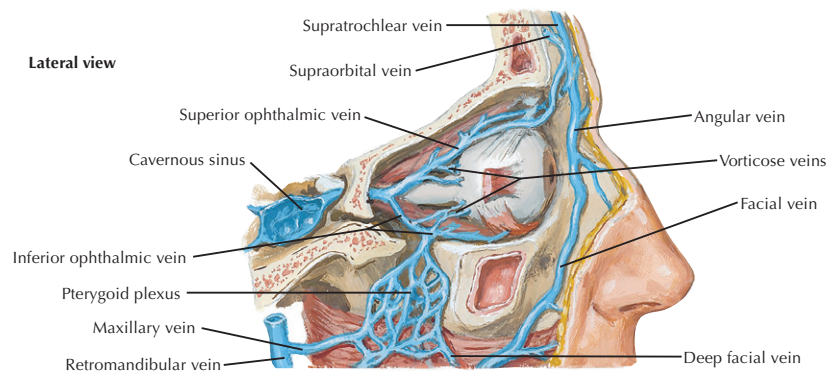
## VASCULAR SUPPLY CONTINUED



*F. Netter M.D.*

**VASCULAR SUPPLY** *CONTINUED*

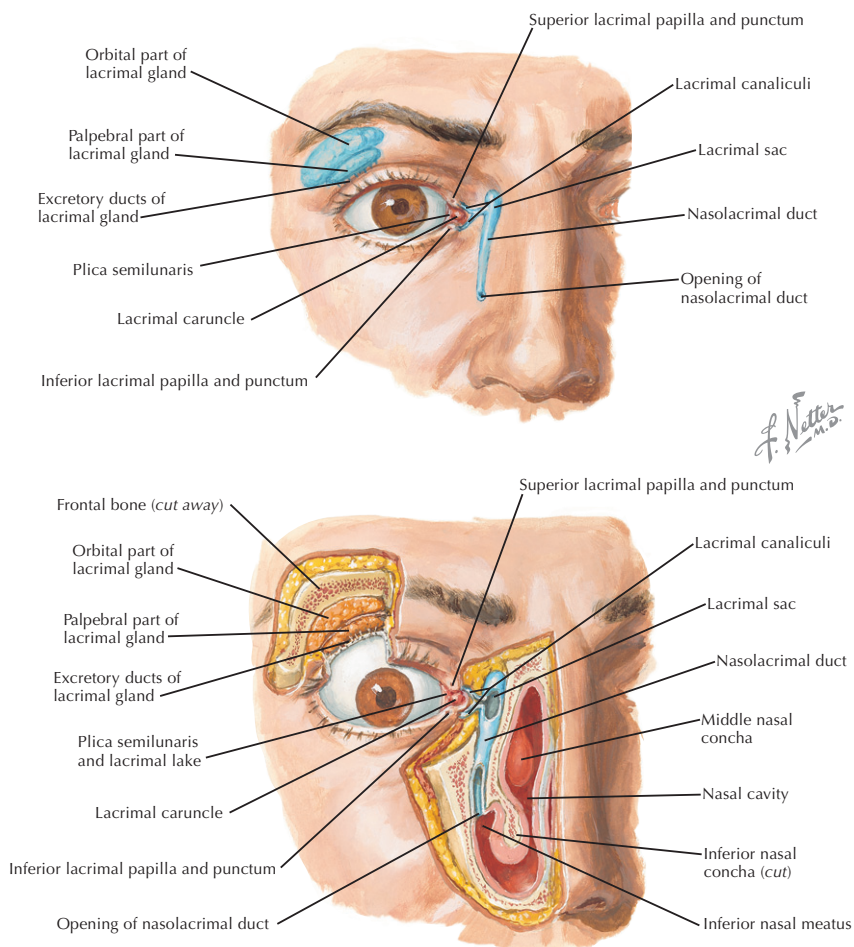
VENOUS DRAINAGE	
Vein	Course
Superficial Veins	
Supraorbital	Begins on the forehead, where it communicates with the superficial temporal v. Passes inferiorly superficial to the frontalis m. and joins the supratrochlear v. at the medial angle of the orbit to form the angular v.
Supratrochlear	Begins on the forehead, where it communicates with the superficial temporal v. Passes inferiorly along the forehead, parallel with the vein of the opposite side At the medial angle of the orbit, the supratrochlear joins the supraorbital v. to form the angular v.
Angular	Forms from the confluence of the supraorbital and supratrochlear vv. along the medial part of the eye Travels along the lateral aspect of the nose to become the facial v.
Facial	Begins as the angular v. Passes inferiorly along the side of the nose, receiving the lateral nasal v. Continues posteroinferiorly across the angle of the mouth to the cheek receiving the superior and inferior labial vv. While passing toward the mandible, the deep facial v. connects to the pterygoid plexus In the submandibular triangle the facial v. joins the anterior branch of the retromandibular to form the common facial v. The facial v. has no valves that can allow blood to backflow
Deep Veins	
Cavernous sinus	A reticulated venous structure located on the lateral aspect of the body of the sphenoid bone Drain posteriorly into the superior and inferior petrosal sinuses Receives blood from the superior and inferior ophthalmic vv. Oculomotor and trochlear nn. and ophthalmic and maxillary divisions of the trigeminal n. lie along the lateral wall of the sinus Abducens n. and internal carotid a. lie in the sinus
Pterygoid plexus	An extensive network of veins that parallels the 2nd and 3rd parts of the maxillary a. Receives branches that correspond to the same branches of the maxillary a. Tributaries to the pterygoid plexus eventually converge to form a short maxillary v. Communicates with the cavernous sinus, pharyngeal venous plexus, facial v. via the deep facial v., and ophthalmic vv.
Communicating Veins	
Superior ophthalmic	Receives blood from the roof of the orbit and the scalp Travels posteriorly to communicate with the cavernous sinus
Inferior ophthalmic	Receives blood from the floor of the orbit Often splits into two branches One branch travels posteriorly with the infraorbital v. that passes through the inferior orbital fissure to communicate with the pterygoid plexus The other branch travels posteriorly to communicate directly with the superior ophthalmic v. in the superior orbital fissure, or it will pass through the fissure to communicate with the cavernous sinus
Infraorbital	Receives blood from the midface via the lower eyelid, lateral side of the nose, and the upper lip Eventually communicates with the pterygoid plexus of veins





## LACRIMAL APPARATUS

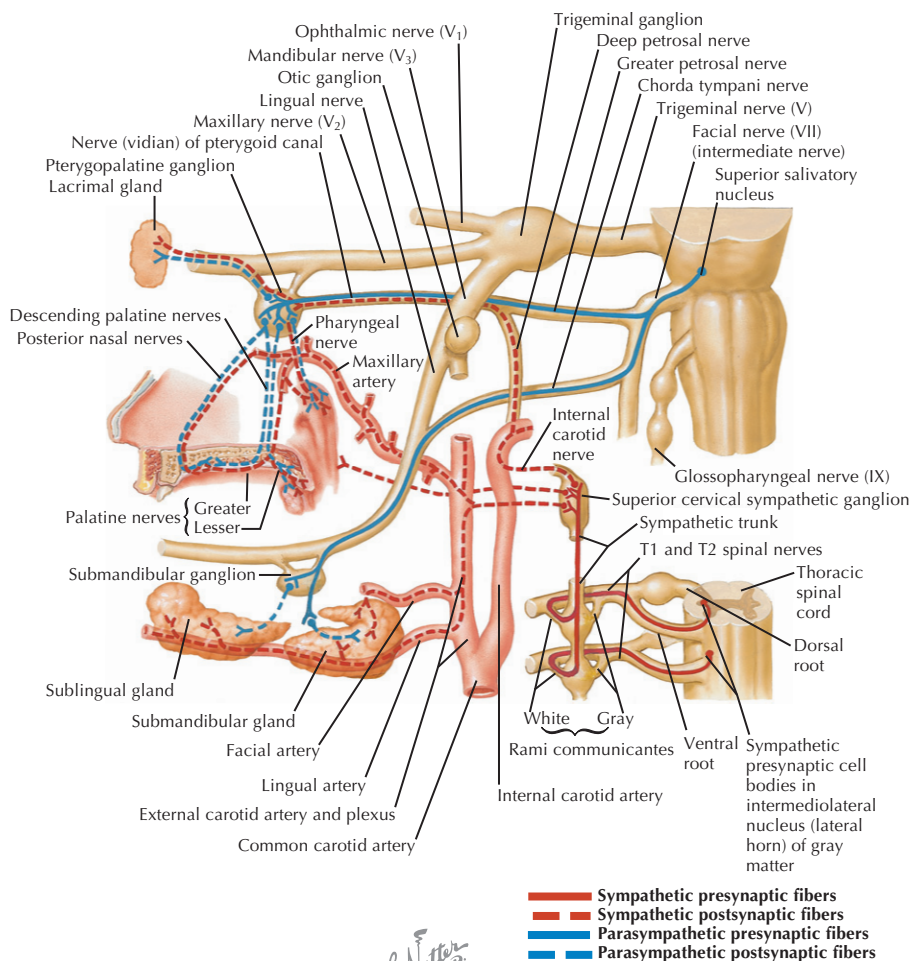
OVERVIEW	
Structure/Function	Description
Lacrimal apparatus	<p>Composed of:</p> <ul style="list-style-type: none"> <li>• Lacrimal gland</li> <li>• Lacrimal canaliculi</li> <li>• Lacrimal sac</li> <li>• Nasolacrimal duct</li> </ul> <p>Secretes and drains all tears</p>
Lacrimal gland	<p>Located in the anterolateral part of the orbit</p> <p>Secretes serous fluid</p> <p>Divided into 2 parts by the lateral tendon of the levator palpebrae superioris m.</p>
Tear formation and absorption	<p>Tears coat the external surface of the eye to prevent drying, act as a lubricant, and contain bactericidal enzymes</p> <p>With blinking, tears are carried across the eye to collect near the medial canthus</p> <p>Tears enter through the lacrimal puncta into the lacrimal canaliculi</p> <p>Lacrimal canaliculi carry the tears to the lacrimal sac</p> <p>Lacrimal sac carries the tears inferiorly through the nasolacrimal duct, which terminates in the inferior meatus</p>



## LACRIMAL APPARATUS *CONTINUED*

PARASYMPATHETICS OF THE LACRIMAL GLAND			
Type of Neuron	Name of Cell Body	Characteristics of the Cell Body	Course of the Neuron
Preganglionic neuron	Superior salivatory nucleus	<p>A collection of nerve cell bodies located in the pons</p> <p>Travel through the nervus intermedius of the facial n. into the internal acoustic meatus</p> <p>In the facial canal, the facial n. gives rise to 2 <i>parasympathetic branches</i>:</p> <ul style="list-style-type: none"> <li>• Greater petrosal n.</li> <li>• Chorda tympani n.</li> </ul>	<p>Lacrimal gland uses the greater petrosal n.</p> <p><b>Greater Petrosal Nerve</b></p> <p>Exits along the hiatus for the greater petrosal n. toward the foramen lacerum, where it joins the deep petrosal n. (sympathetics) to form the nerve of the pterygoid canal (vidian n.)</p> <p>Vidian n. passes through the pterygoid canal and enters the pterygopalatine fossa, where it joins with the pterygopalatine ganglion</p>
Postganglionic neuron	Pterygopalatine ganglion	<p>A collection of nerve cell bodies located in the pterygopalatine fossa</p> <p>Postganglionic parasympathetic fibers that arise in the pterygopalatine ganglion are distributed to the ophthalmic and maxillary divisions of the trigeminal n. to the:</p> <ul style="list-style-type: none"> <li>• Lacrimal gland</li> <li>• Nasal glands</li> <li>• Palatine glands</li> <li>• Pharyngeal glands</li> </ul>	<p>Lacrimal gland uses the ophthalmic and maxillary divisions</p> <p><b>Ophthalmic and Maxillary Division Distribution</b></p> <p>Postganglionic fibers travel along the zygomatic branch of the maxillary division for a short distance to enter the orbit</p> <p>A short communicating branch joins the lacrimal n. of the ophthalmic division of the trigeminal n.</p> <p>These fibers innervate:</p> <ul style="list-style-type: none"> <li>• Lacrimal gland to cause the secretion of tears</li> </ul>

## LACRIMAL APPARATUS *CONTINUED*



## Clinical Correlate

### GLAUCOMA

Damage to the optic nerve often due to increased intraocular pressure

#### *Open Angle Glaucoma*

The most common form

Gradual and can result in gradual loss of vision

Intraocular pressure elevates due to insufficient drainage within the eye's canal system located in the angle of the anterior chamber of the anterior segment

Various medications are successful in treating this form

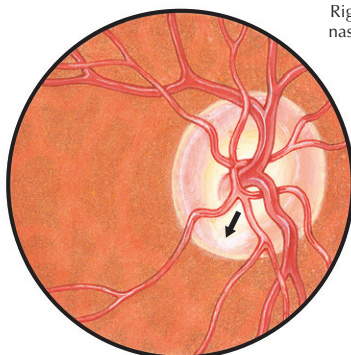
#### *Closed Angle Glaucoma*

Result of an anatomic blockage of the canal system at the angle of the anterior chamber of the anterior segment

*Example:* When the iris opens the pupil very wide and blocks the angle, intraocular pressure rises quickly as a result of the possible abrupt blockage

Early

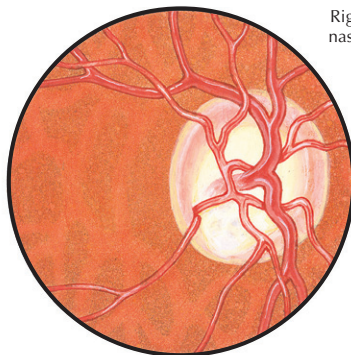
Right eye  
nasal side



Funduscopy: notching of contour of physiologic cup in optic disc with slight focal pallor in area of notching; occurs almost invariably in superotemporal or inferotemporal (as shown) quadrants

Minimally advanced

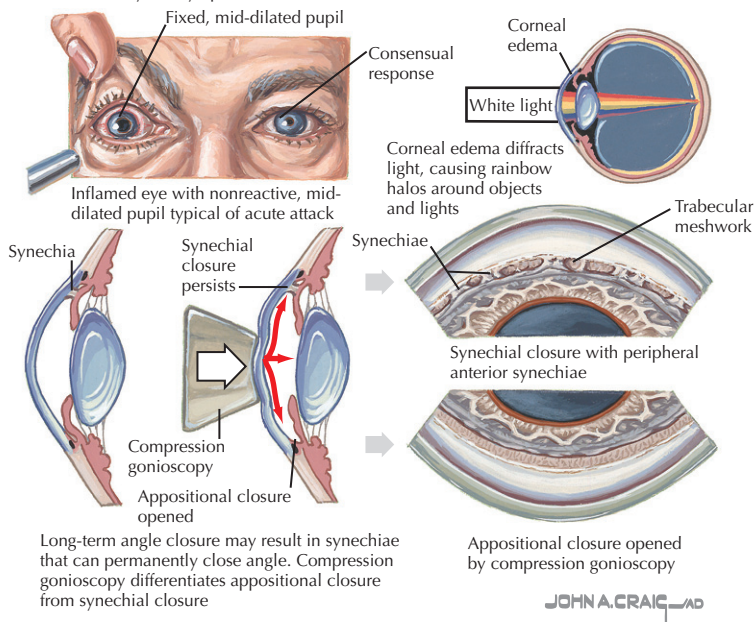
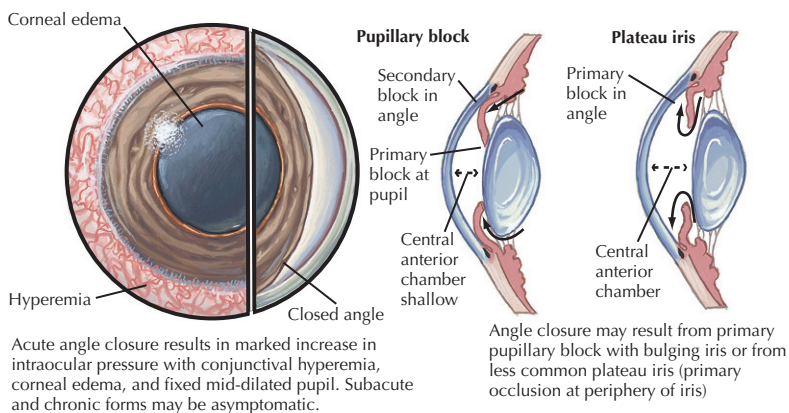
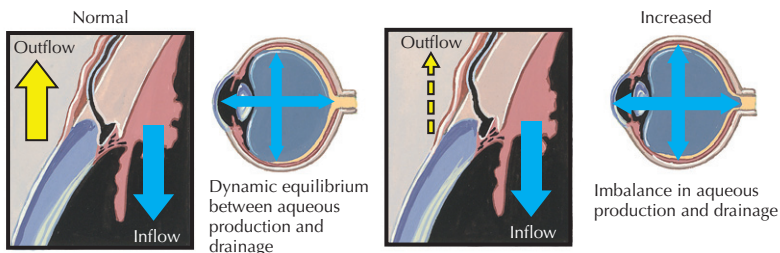
Right eye  
nasal side



Funduscopy: increased notching of rim of cup; thinning of rim of cup (enlargement of cup); deepening of cup; lamina cribrosa visible in deepest areas.

JOHN A. CRAIG MD

## GLAUCOMA CONTINUED





## Clinical Correlate

### DIABETIC RETINOPATHY

Damage to the retina as a result of damage to the blood vessels in the retina due to diabetes

Can occur in all people with diabetes (types 1 and 2)

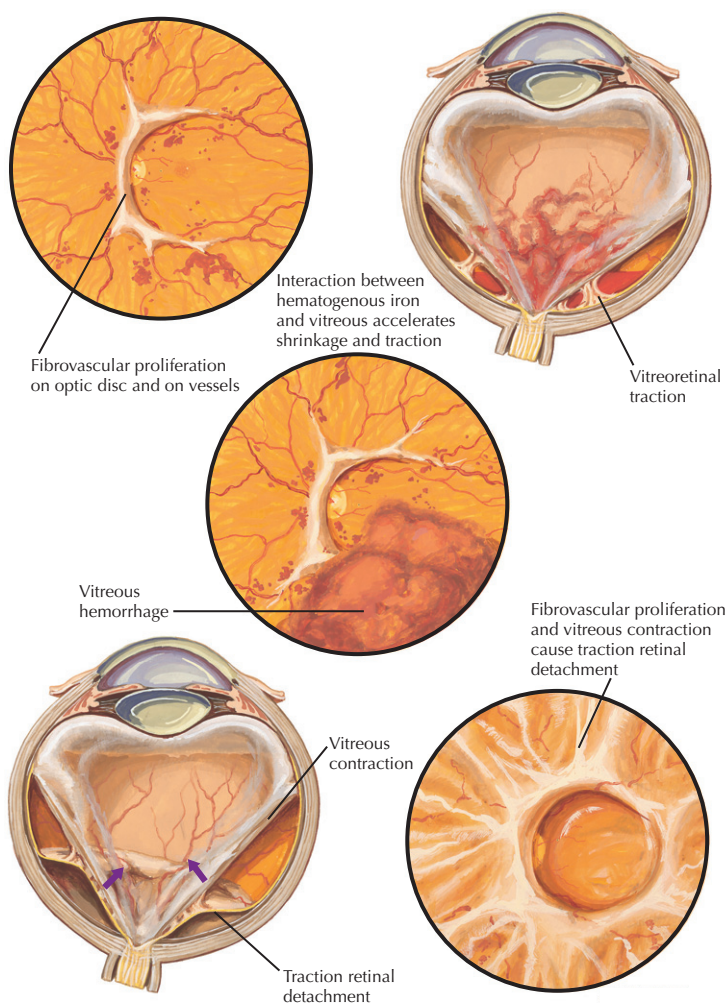
#### *Pathophysiology*

As the retinal blood vessels become damaged, they leak fluid into the eye

If the fluid accumulates around the macula lutea (contains the largest amount of cones for acute vision), macula edema occurs in which visual loss is noted

As the permeability of the vessels worsens, lipoprotein is deposited, leading to formation of hard exudates within the retina

As new blood vessels form, they are fragile and bleed, allowing blood to enter the eye, helping to cloud and destroy the retina



JOHN A. CRAIG MD



**AMETROPIAS**

A series of refractive disorders of the eye that cause blurring of the image on the retina

*Types***Myopia**

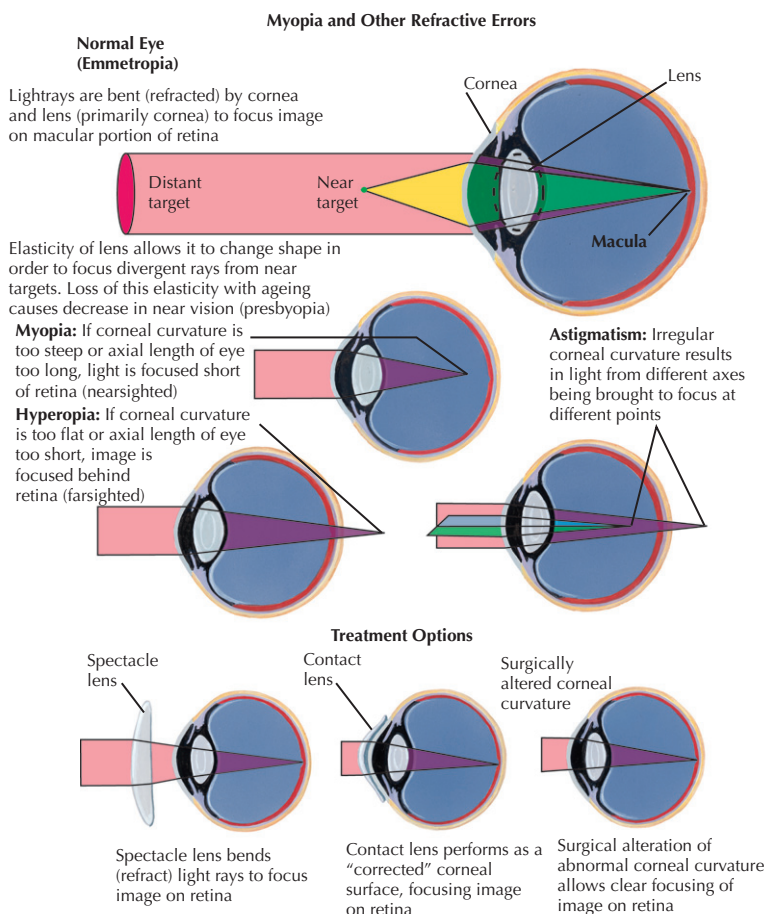
- Image is focused anterior to the retina
- Commonly referred to as nearsightedness

**Hyperopia**

- Image is focused posterior to the retina
- Commonly referred to as farsightedness

**Astigmatism**

- A nonspherical eye allows the parts of the image to focus at multiple locations, rather than in a single area



JOHN A. CRAIG, MD

## **CHAPTER 20**

# **AUTONOMICS OF THE HEAD AND NECK**

Overview of the Autonomic Nervous System	<b>512</b>
Sympathetics of the Head and Neck	<b>519</b>
Parasympathetic Pathways of the Head and Neck	<b>521</b>
Clinical Correlate	<b>534</b>

**GENERAL INFORMATION**

The autonomic nervous system (ANS) has control over the function of many organ systems and tissues

Provides innervation to:

- Cardiac muscle
- Smooth muscle
- Glands

Also provides innervation to the organs of the immune system and metabolic organs (mainly through the sympathetics)

The hypothalamus exerts control over the ANS and helps the body maintain homeostasis

The ANS uses a 2-neuron chain system:

- Preganglionic neurons—the cell bodies are located in the central nervous system (CNS) (i.e., the brain and spinal cord), and their myelinated axons pass out to the autonomic ganglia
- Postganglionic neurons—the cell bodies are located in the autonomic ganglia, which are outside of the CNS, and their unmyelinated axons travel to the effector organ

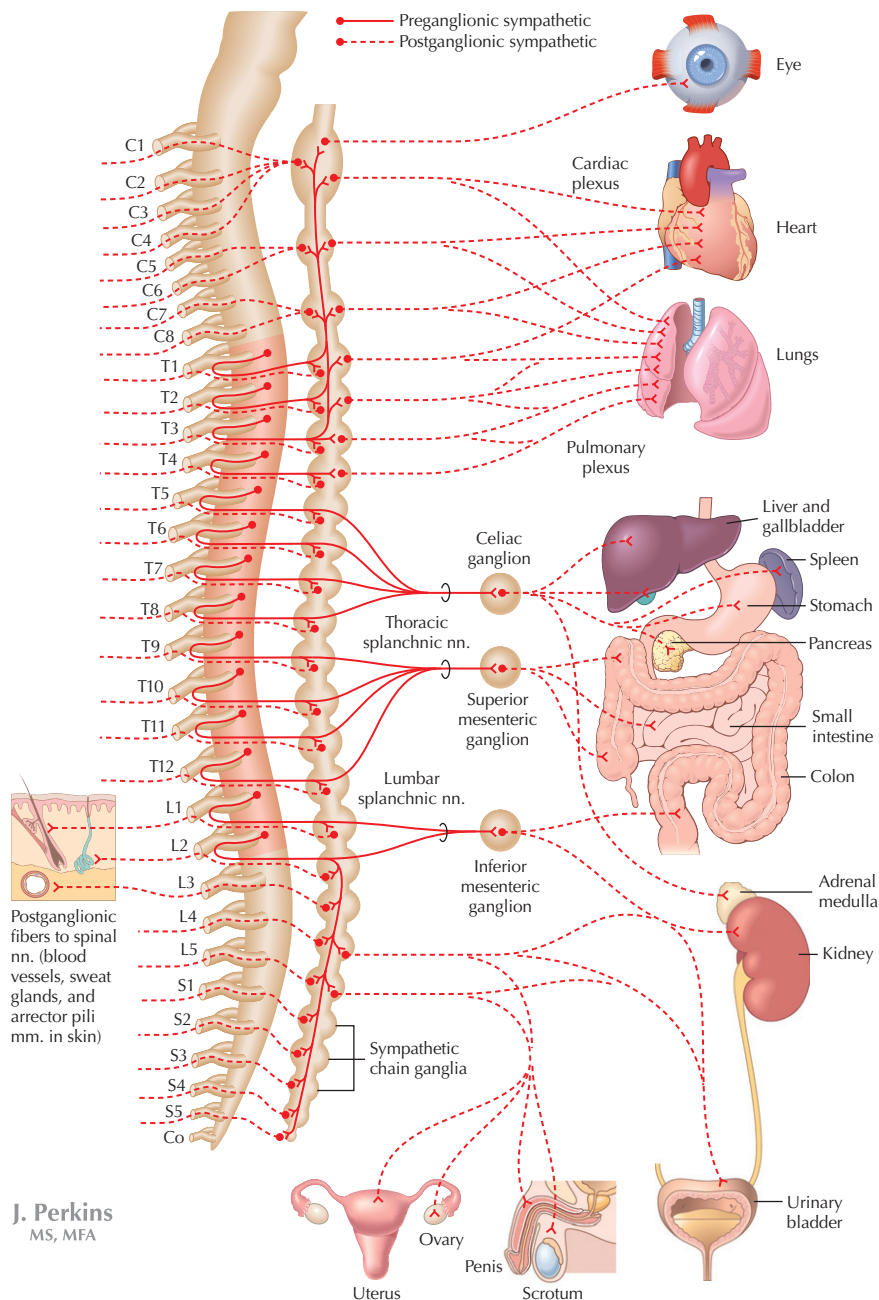
The ANS is divided into 2 parts:

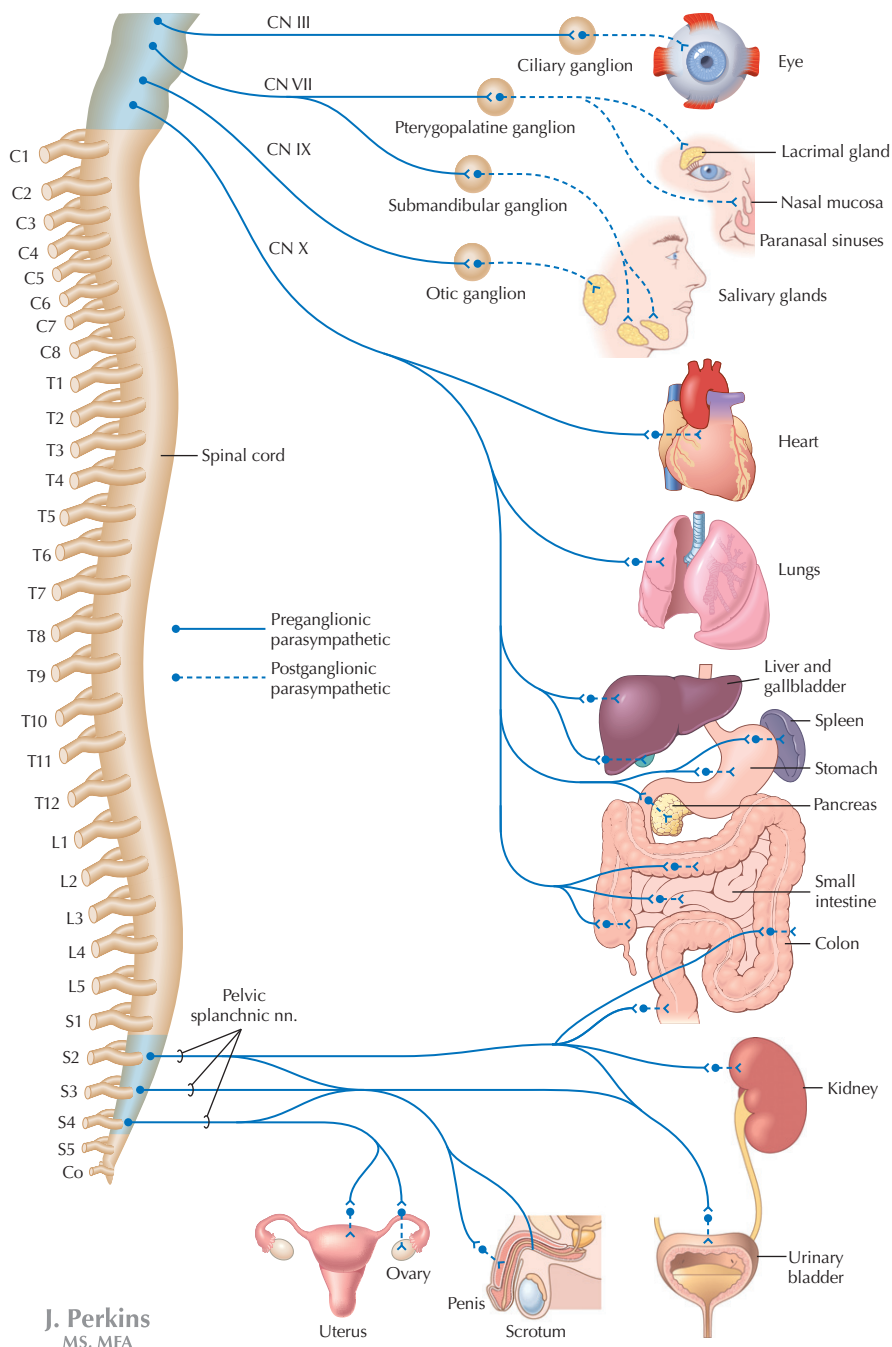
- Parasympathetic—the portion responsible for preserving and restoring energy
- Sympathetic—the portion responsible for preparing the body for emergency situations

Organs typically receive dual innervation, which has an antagonistic action, although there are some notable exceptions, such as the arrector pili muscles (which are sympathetic only) and the male sexual response (erection is parasympathetic, ejaculation is sympathetic)

Acetylcholine and norepinephrine are the 2 major neurotransmitters used in synapses of the ANS

## GENERAL INFORMATION *CONTINUED*



GENERAL INFORMATION *CONTINUED*

## DIVISIONS OF THE AUTONOMIC NERVOUS SYSTEM

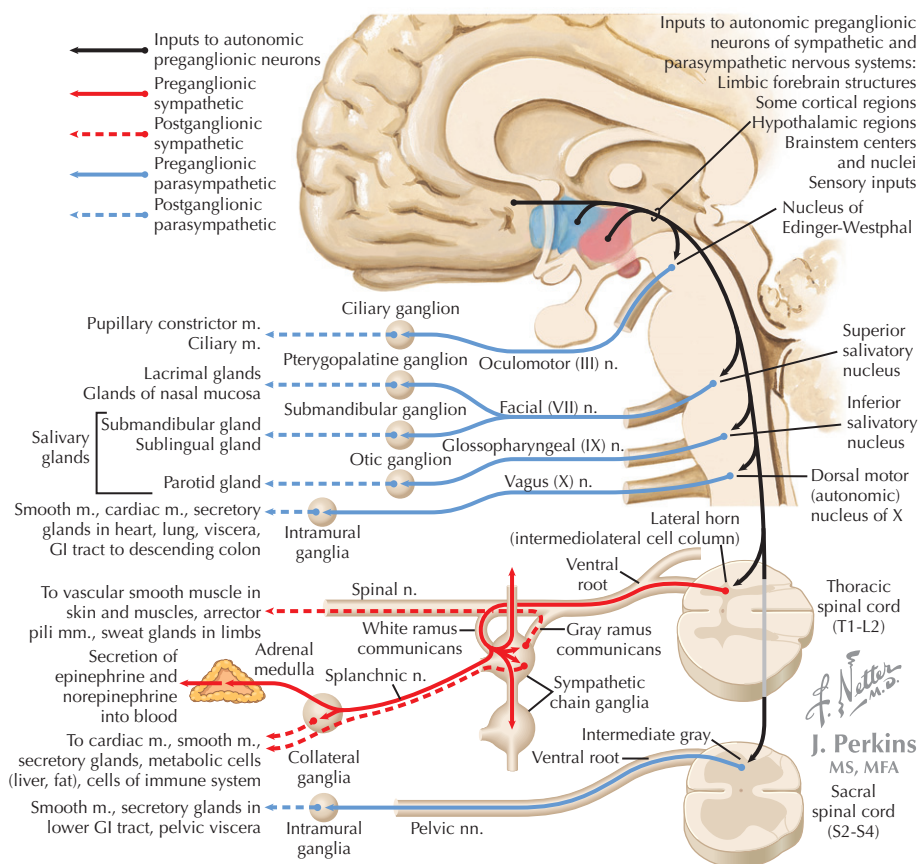
Parasympathetic	Sympathetic
Referred to as craniosacral fibers	Referred to as thoracolumbar fibers
Arise from: <ul style="list-style-type: none"> <li>• Cranial nerves III, VII, IX, and X</li> <li>• Sacral fibers 2–4</li> </ul>	Arise from: <ul style="list-style-type: none"> <li>• Thoracic fibers 1 to 12</li> <li>• Lumbar fibers 1 and 2</li> </ul>
Preganglionic fibers are myelinated and travel from the CNS to their autonomic ganglia (located near their respective effector organ in the head and neck) utilizing acetylcholine as the neurotransmitter at the synapse with the nicotinic receptor	Preganglionic fibers are myelinated and travel from the CNS to their autonomic ganglia (located in the sympathetic chain for the head and neck) utilizing acetylcholine as the neurotransmitter at the synapse with the nicotinic receptor
Postganglionic fibers are unmyelinated and travel from the autonomic ganglia to the effector organ, utilizing acetylcholine as the neurotransmitter at the synapse with the muscarinic receptor	Postganglionic fibers are unmyelinated and travel from the autonomic ganglia to the effector organ, typically utilizing norepinephrine* as the neurotransmitter at the synapse with the $\alpha$ or $\beta$ receptor

\*Main exception to this is in the adrenal gland, where chromaffin cells secrete epinephrine and norepinephrine into the blood.

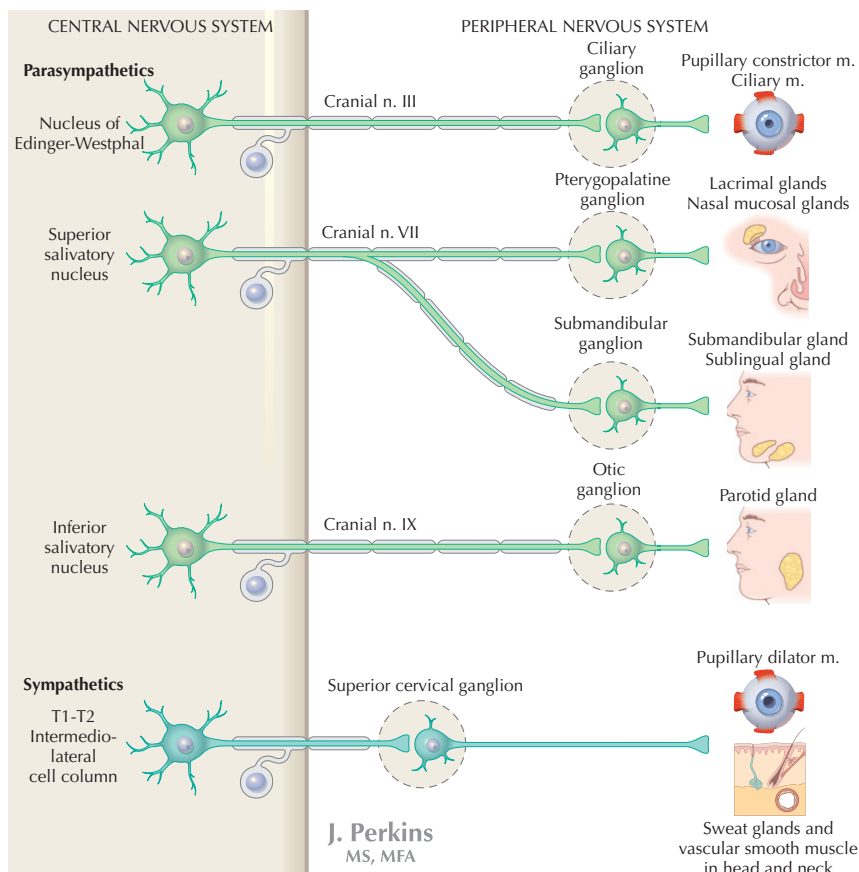
## FUNCTIONS OF THE AUTONOMIC NERVOUS SYSTEM

Parasympathetic	Sympathetic
Responsible for preserving and restoring energy	Responsible for preparing the body for emergency situations
Discharges focally, not as a complete system	Discharges as a complete system
Activated in response to the specific body function that needs to be adjusted (peristalsis, pupillary accommodation)	Activated in response to stressful situations (helps to increase cardiac output, get blood to muscles, and decrease blood flow to the skin and viscera)



FUNCTIONS OF THE AUTONOMIC NERVOUS SYSTEM *CONTINUED*

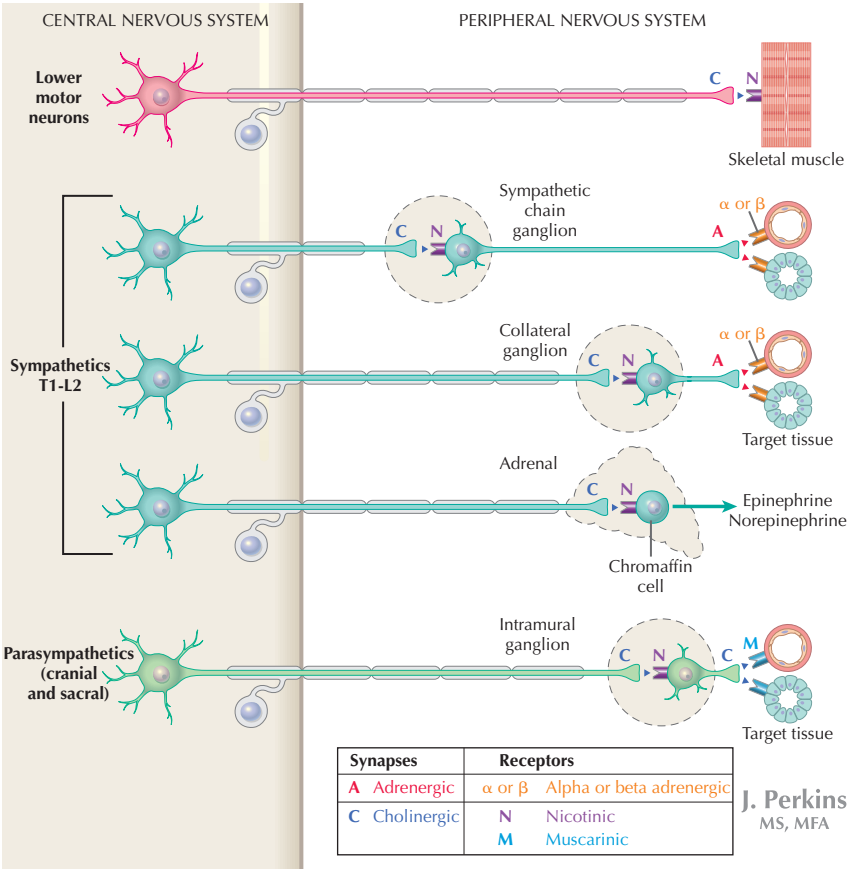
## FUNCTIONS OF THE AUTONOMIC NERVOUS SYSTEM *CONTINUED*



20

Overview of the Autonomic Nervous System

**FUNCTIONS OF THE AUTONOMIC NERVOUS SYSTEM** *CONTINUED*

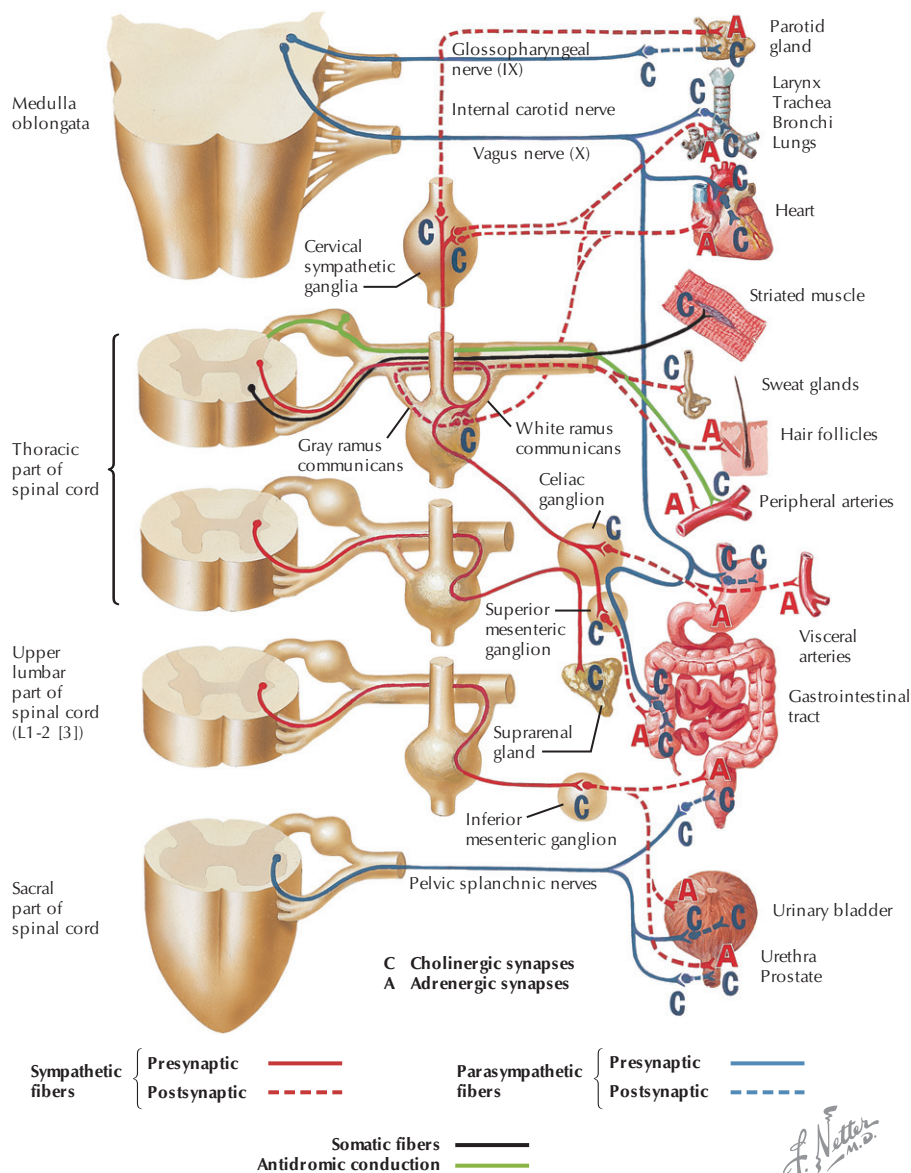


## GENERAL ANATOMIC PATHWAY

Type of Neuron	Name of Cell Body	Characteristics of the Cell Body	Course of the Neuron
Preganglionic fibers	Intermediolateral horn nucleus	Collection of nerve cell bodies located in the lateral horn nucleus of the spinal cord between spinal segments T1 and T3 (and possibly T4)	<p>Fibers arise from the intermediolateral horn nuclei from T1 to T3(4)</p> <p>Travel through the ventral root of the spinal cord to the spinal n.</p> <p>Enter the sympathetic chain via a white ramus communicantes</p> <p>Once in the sympathetic chain, the preganglionic fibers will ascend and synapse with postganglionic fibers in the various sympathetic chain ganglia</p> <p>A majority of the preganglionic fibers will synapse with postganglionic fibers in the superior cervical ganglion, located at the base of the skull</p>
Postganglionic fibers	Superior cervical ganglion* (major part of head and neck)	<p>Collection of nerve cell bodies located in the sympathetic chain</p> <p>The location of the nerve cell body for a majority of the postganglionic neurons is the superior cervical ganglion</p> <p>Others include the middle and inferior cervical ganglia</p>	<p>Postganglionic fibers arise in their respective sympathetic chain ganglia (e.g., superior cervical, middle cervical, inferior cervical nn.)</p> <p>Some of the postganglionic fibers that travel to the periphery (e.g., skin of the neck, blood vessels) will rejoin the spinal nerves in the cervical region via a gray ramus communicantes, to be distributed along the path of the peripheral nerves following the path with blood vessels</p> <p>A majority of the postganglionic fibers join the major blood vessels of the head (namely, the internal carotid a. and branches of the external carotid a.) to follow the vessel until reaching their final effector organ (e.g., dilator pupillae m. of the eye)</p>

\*Location of the cell body for the postganglionic is variable and depends on the course of this neuron.

## GENERAL ANATOMIC PATHWAY CONTINUED



## CRANIAL NERVE III WITH CORRESPONDING SYMPATHETICS

ANATOMIC PATHWAY FOR PARASYMPATHETICS OF THE EYE			
Type of Neuron	Name of Cell Body	Characteristics of the Cell Body	Course of the Neuron
Preganglionic neuron	Edinger-Westphal nucleus	A collection of nerve cell bodies located in the midbrain The Edinger-Westphal nucleus is found medial to the oculomotor nucleus and lateral to the cerebral aqueduct	Fibers arise from the Edinger-Westphal nucleus in the midbrain from the oculomotor n. Oculomotor n. passes anteriorly on the lateral wall of the cavernous sinus immediately superior to the trochlear n. Immediately before entering the orbit, the nerve divides into superior and inferior divisions of the oculomotor Both the superior and the inferior divisions of the oculomotor enter the orbit through the superior orbital fissure Preganglionic parasympathetic fibers travel in the inferior division A small parasympathetic root passes from the inferior division of the oculomotor to the ciliary ganglion carrying the preganglionic parasympathetic fibers
Postganglionic neuron	Ciliary ganglion	Located anterior to the optic foramen between the optic n. and the lateral rectus m. 3 roots connect to the ciliary ganglion: <ul style="list-style-type: none"> <li>• Sensory root from the ophthalmic division of the trigeminal n., which carries general sensation fibers to the eye via the short ciliary n.</li> <li>• Parasympathetic root from the inferior division of the oculomotor n., carrying preganglionic parasympathetic fibers to the ganglion</li> <li>• Sympathetic root, which arises from the postganglionic sympathetic fibers that were carried by the internal carotid a.</li> </ul> The short ciliary nn., usually numbering about 8 total, arise from the ciliary ganglion to enter the posterior portion of the eye Fibers from all 3 roots pass through the ciliary ganglion and short ciliary nn. to enter the eye Only the parasympathetic fibers synapse in the ciliary ganglion	Fibers arise in the ciliary ganglion following a synapse with the preganglionic parasympathetic fibers Travel through the short ciliary nn. to enter the eye's posterior portion Innervate the: <ul style="list-style-type: none"> <li>• Sphincter pupillae m.—constricts the pupil</li> <li>• Ciliary m.—changes the shape of the lens during accommodation</li> </ul>



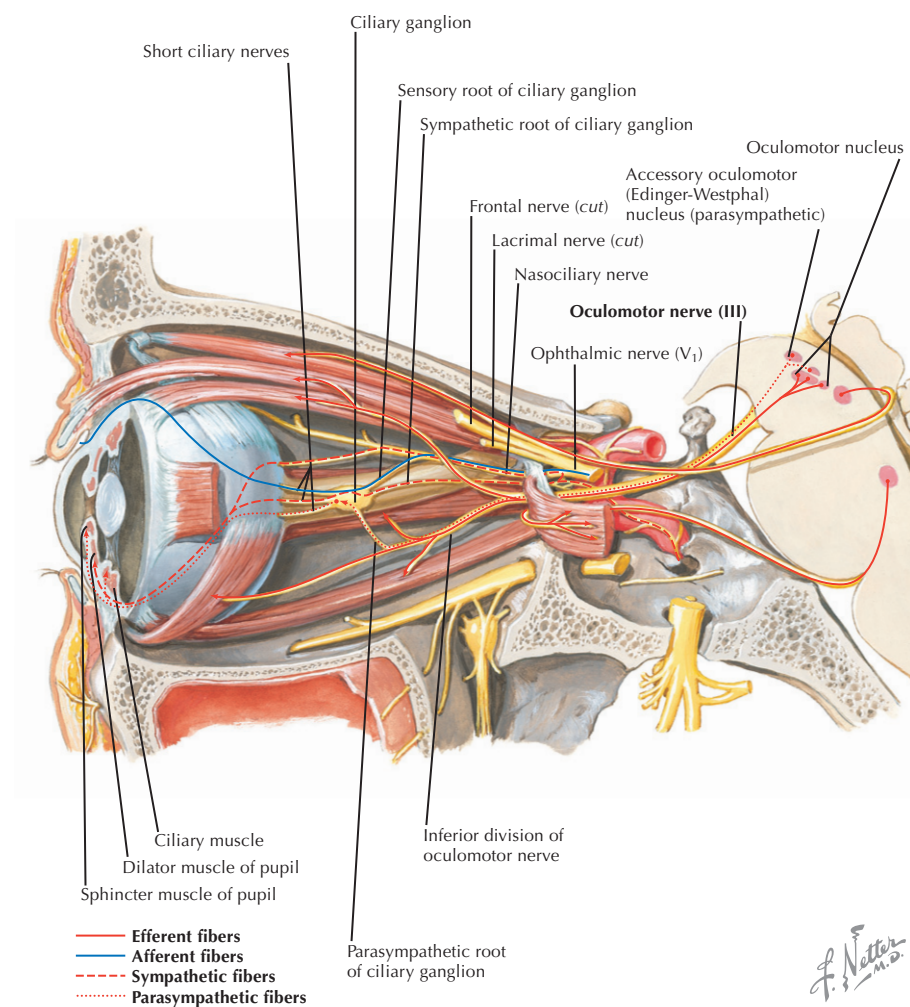
CRANIAL NERVE III WITH CORRESPONDING SYMPATHETICS *CONTINUED*

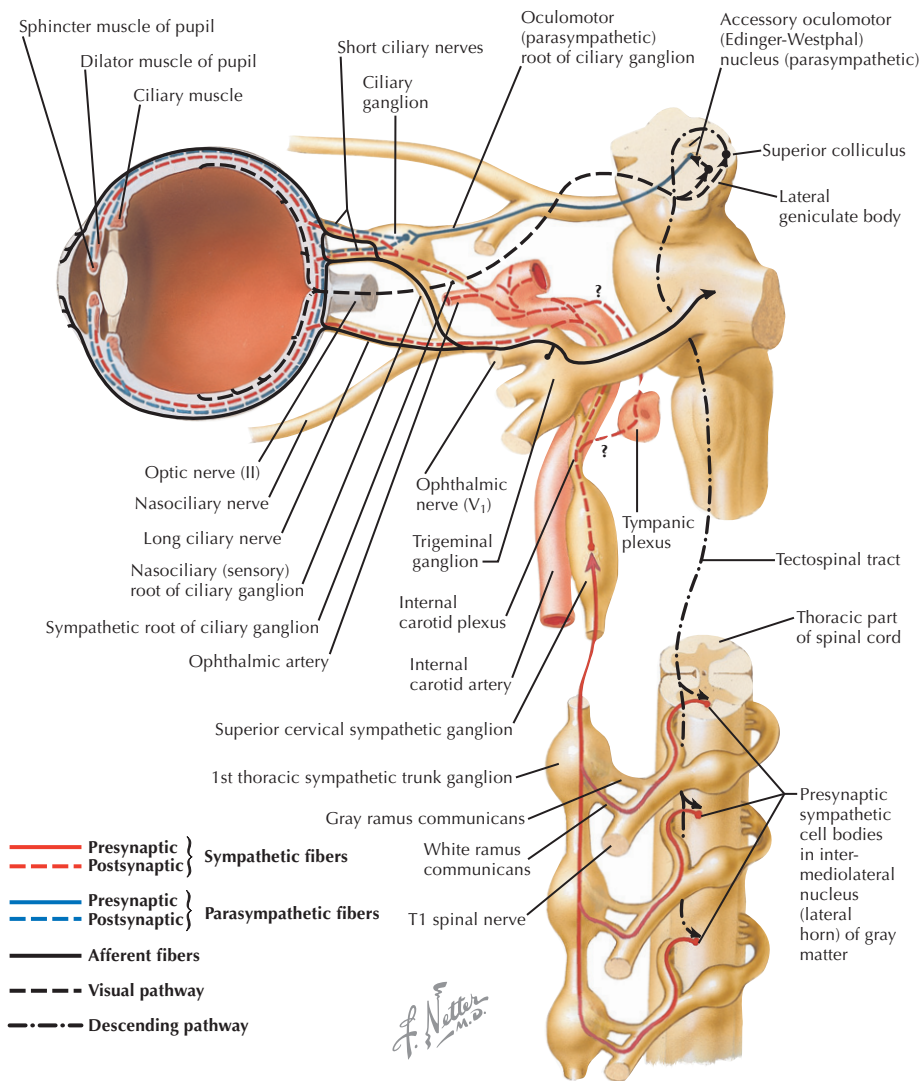
ANATOMIC PATHWAY FOR SYMPATHETICS OF THE EYE			
Type of Neuron	Name of Cell Body	Characteristics of the Cell Body	Course of the Neuron
Preganglionic neuron	Intermediolateral horn nucleus	Collection of nerve cell bodies located in the lateral horn nucleus of the spinal cord between spinal segments T1 and T3 (and possibly T4)	Fibers arise from the intermediolateral horn nuclei from T1 to T3(4) Travel through the ventral root of the spinal cord to the spinal n. Enter the sympathetic chain via a white ramus communicantes Once in the sympathetic chain, the preganglionic fibers for the eye will ascend and synapse with postganglionic fibers in the superior cervical ganglion
Postganglionic neuron	Superior cervical ganglion	Collection of nerve cell bodies located in the superior cervical ganglion, which is located at the base of the skull	Fibers arise in the superior cervical ganglion Postganglionic fibers will follow the internal carotid a. on the carotid plexus As the internal carotid nears the orbit, the postganglionic fibers branch and follow various structures that connect to the eye, such as the ophthalmic a. and its branches, and the long ciliary nn. that arise from the ophthalmic division of the trigeminal n. In the eye, the postganglionic fibers innervate the eye's dilator pupillae m.

# Parasympathetic Pathways of the Head and Neck

20

## CRANIAL NERVE III WITH CORRESPONDING SYMPATHETICS *CONTINUED*



**CRANIAL NERVE III WITH CORRESPONDING SYMPATHETICS** *CONTINUED*

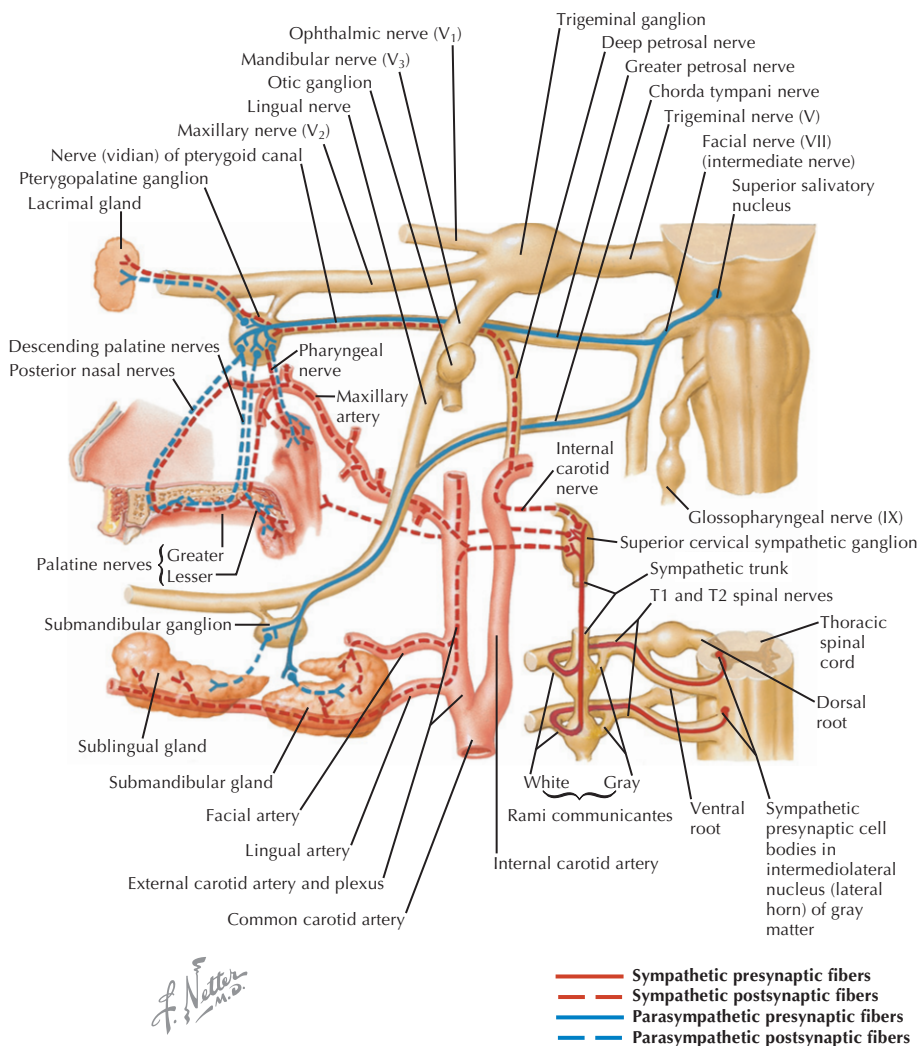
# Parasympathetic Pathways of the Head and Neck

## CRANIAL NERVE VII

ANATOMIC PATHWAY FOR PARASYMPATHETICS OF THE LACRIMAL, NASAL, PALATINE, PHARYNGEAL, SUBMANDIBULAR, AND SUBLINGUAL GLANDS			
Type of Neuron	Name of Cell Body	Characteristics of the Cell Body	Course of the Neuron
Preganglionic neuron	Superior salivatory nucleus	<p>A collection of nerve cell bodies located in the pons</p> <p>Travel through the nervus intermedius of the facial n. into the internal acoustic meatus</p> <p>In the facial canal, the facial n. gives rise to 2 parasympathetic branches:</p> <ul style="list-style-type: none"> <li>• Greater petrosal n.</li> <li>• Chorda tympani n.</li> </ul>	<p><b>Greater Petrosal Nerve</b></p> <ul style="list-style-type: none"> <li>• Exits along the hiatus for the greater petrosal n. toward the foramen lacerum, where it joins the deep petrosal n. (sympathetics) to form the nerve of the pterygoid canal (vidian n.)</li> <li>• Vidian n. passes through the pterygoid canal and enters the pterygopalatine fossa, where it joins with the pterygopalatine ganglion</li> </ul> <p><b>Chorda Tympani Nerve</b></p> <ul style="list-style-type: none"> <li>• Exits the petrotympanic fissure to enter the infratemporal fossa, where it joins the lingual n.</li> <li>• Preganglionic fibers travel with the lingual n. into the floor of the oral cavity, where it joins with the submandibular ganglion</li> </ul>
Postganglionic neuron	Pterygopalatine ganglion	<p>A collection of nerve cell bodies located in the pterygopalatine fossa</p> <p>Postganglionic parasympathetic fibers that arise in the pterygopalatine ganglion are distributed to the ophthalmic and maxillary divisions of the trigeminal n. to the:</p> <ul style="list-style-type: none"> <li>• Lacrimal gland</li> <li>• Nasal glands</li> <li>• Palatine glands</li> <li>• Pharyngeal glands</li> </ul>	<p><b>Ophthalmic and Maxillary Division Distribution</b></p> <p>Postganglionic fibers travel along the zygomatic branch of the maxillary division for a short distance to enter the orbit</p> <p>A short communicating branch joins the lacrimal n. of the ophthalmic division of the trigeminal n.</p> <p>These fibers innervate:</p> <ul style="list-style-type: none"> <li>• Lacrimal gland to cause the secretion of tears</li> </ul> <p><b>Maxillary Division Distribution</b></p> <p>Postganglionic fibers travel along the maxillary division of the trigeminal n. to be distributed along its branches that are located in the nasal cavity, oral cavity, and pharynx (e.g., nasopalatine, greater palatine)</p> <p>These fibers innervate:</p> <ul style="list-style-type: none"> <li>• Nasal glands</li> <li>• Palatine glands</li> <li>• Pharyngeal glands</li> </ul>
	Submandibular ganglion	<p>A collection of nerve cell bodies that is located in the oral cavity</p> <p>It is suspended from the lingual n. at the posterior border of the mylohyoid m. immediately superior to the deep portion of the submandibular gland</p>	<p>Postganglionic parasympathetic fibers arise in the submandibular ganglion and are distributed to the:</p> <ul style="list-style-type: none"> <li>• Submandibular gland</li> <li>• Sublingual gland</li> </ul>

# 20 Parasympathetic Pathways of the Head and Neck

## CRANIAL NERVE VII CONTINUED



# Parasympathetic Pathways of the Head and Neck

20

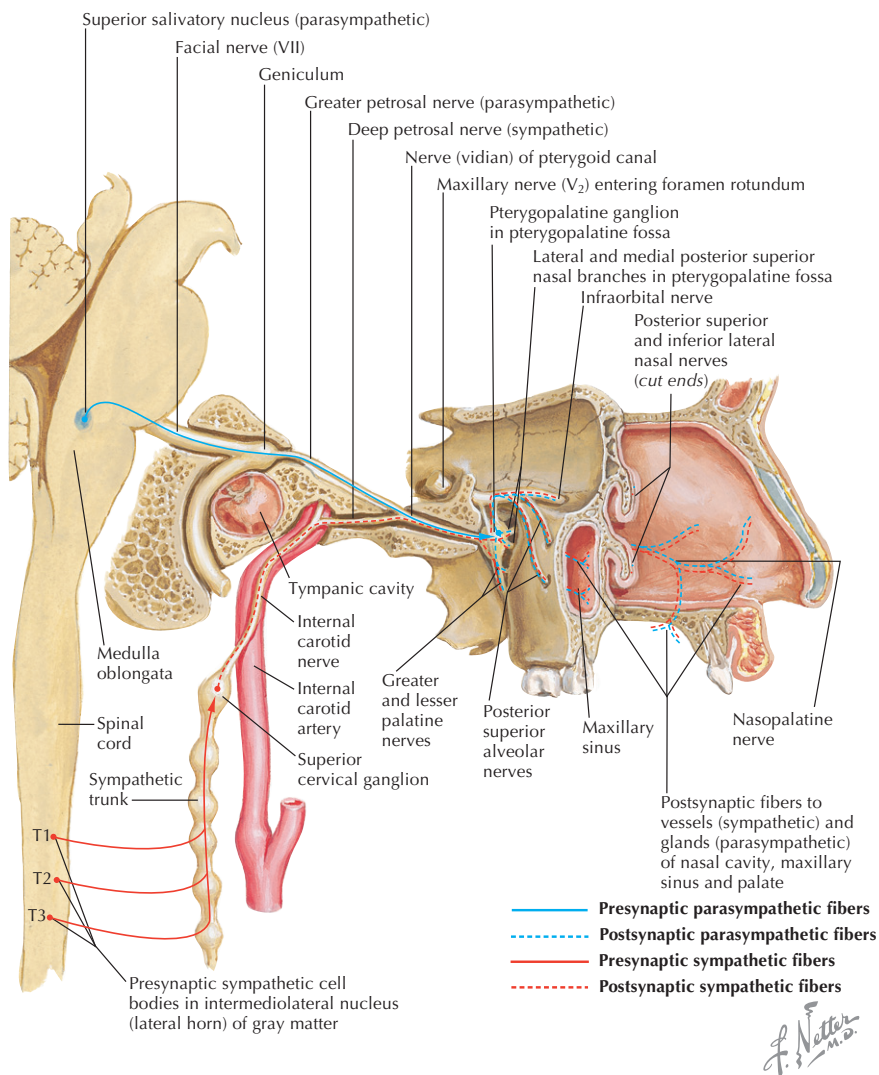
## CRANIAL NERVE VII *CONTINUED*

ANATOMIC PATHWAY FOR SYMPATHETICS OF THE NASAL CAVITY, LACRIMAL GLAND, PALATE, AND SUBMANDIBULAR AND SUBLINGUAL GLANDS			
Type of Neuron	Name of Cell Body	Characteristics of the Cell Body	Course of the Neuron
Preganglionic neuron	Intermediolateral horn nucleus	Collection of nerve cell bodies located in the lateral horn nucleus of the spinal cord between spinal segments T1 and T3 (and possibly T4)	Fibers arise from the intermediolateral horn nuclei from T1 to T3 (4) Travel through the ventral root of the spinal cord to the spinal nerve Enter the sympathetic chain via a white ramus communicantes Once in the sympathetic chain, the preganglionic fibers for the eye will ascend and synapse with postganglionic fibers in the superior cervical ganglion
Postganglionic neuron	Superior cervical ganglion	Collection of nerve cell bodies located in the superior cervical ganglion, which is located at the base of the skull Postganglionic sympathetic fibers follow the internal carotid or external carotid a. to pass near their respective effector organs: <ul style="list-style-type: none"> <li>• Nasal cavity</li> <li>• Palate</li> <li>• Lacrimal gland</li> <li>• Submandibular gland</li> <li>• Sublingual gland</li> </ul>	<p><b>Nasal Cavity and Palate</b></p> <ul style="list-style-type: none"> <li>• Postganglionic sympathetic fibers follow both the <i>internal</i> and <i>external carotid</i> aa.</li> <li>• Postganglionic sympathetic fibers from the internal carotid branch in the region of the foramen lacerum to form the deep petrosal n.</li> <li>• The deep petrosal n. joins the greater petrosal n. (parasympathetics) to form the nerve of the pterygoid canal (vidian n.)</li> <li>• Postganglionic sympathetic fibers travel along the branches of the maxillary division of the trigeminal n. associated with the pterygopalatine ganglion to be distributed along its branches in the nasal cavity and palate</li> <li>• Postganglionic sympathetic fibers from the external carotid branch and follow the maxillary a.</li> <li>• These fibers travel along the branches of the maxillary a. to be distributed along the nasal cavity and palate</li> </ul> <p><b>Lacrimal Gland</b></p> <ul style="list-style-type: none"> <li>• Postganglionic sympathetic fibers follow the internal carotid a.</li> <li>• Postganglionic sympathetic fibers from the internal carotid branch off in the region of the foramen lacerum to form the deep petrosal nerve</li> <li>• The deep petrosal n. joins the greater petrosal n. (parasympathetics) to form the nerve of the pterygoid canal (vidian n.)</li> <li>• Postganglionic fibers travel along the zygomatic branch of the maxillary division for a short distance to enter the orbit</li> <li>• A short communicating branch joins the lacrimal n. of the ophthalmic division of the trigeminal n.</li> <li>• These fibers are distributed to the lacrimal gland</li> </ul> <p><b>Submandibular and Sublingual Glands</b></p> <ul style="list-style-type: none"> <li>• Postganglionic sympathetic fibers follow the external carotid a.</li> <li>• Postganglionic sympathetic fibers branch off the external carotid to follow the arteries that supply the submandibular and sublingual glands</li> </ul>



# 20 Parasympathetic Pathways of the Head and Neck

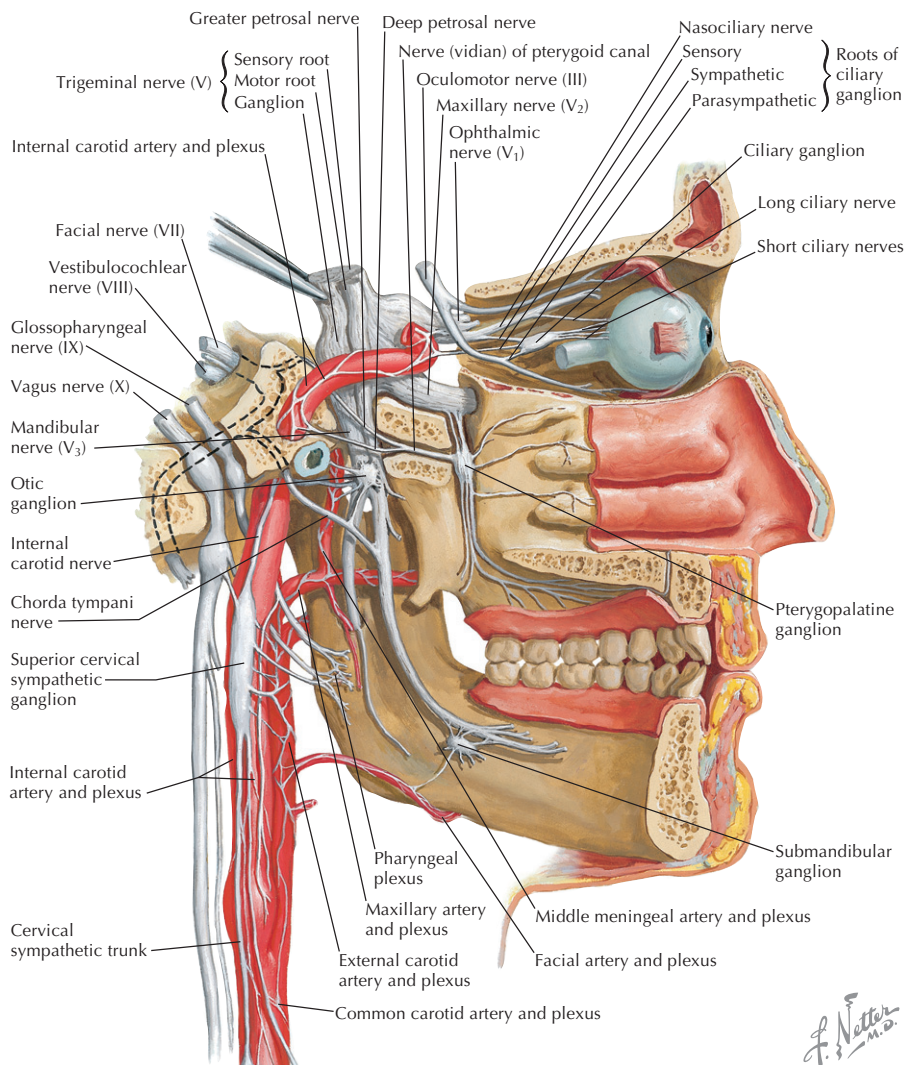
## CRANIAL NERVE VII *CONTINUED*



# Parasympathetic Pathways of the Head and Neck

20

## CRANIAL NERVE VII CONTINUED



**CRANIAL NERVE IX WITH CORRESPONDING SYMPATHETICS**

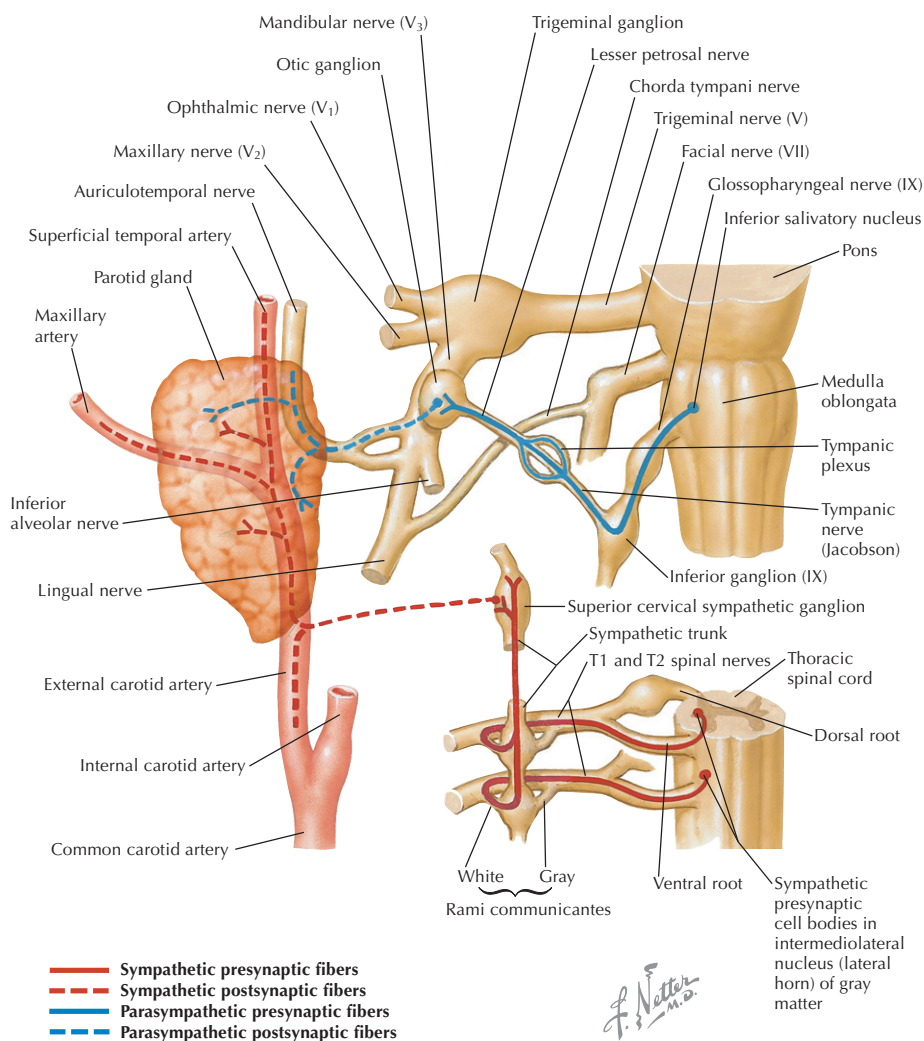
ANATOMIC PATHWAY FOR PARASYMPATHETICS OF THE PAROTID GLAND			
Type of Neuron	Name of Cell Body	Characteristics of the Cell Body	Course of the Neuron
Preganglionic neuron	Inferior salivatory nucleus	A collection of nerve cell bodies located in the medulla	<p>Preganglionic parasympathetic fibers arise from the inferior salivatory nucleus in the medulla</p> <p>Travel through the glossopharyngeal n. and exit the jugular foramen</p> <p>Gives rise to the tympanic branch of IX, which reenters the skull via the tympanic canaliculus</p> <p>The tympanic branch of IX forms the tympanic plexus along the promontory of the ear</p> <p>The plexus re-forms as the lesser petrosal n., which typically exits the foramen ovale to enter the infratemporal fossa</p> <p>Lesser petrosal n. joins the otic ganglion</p>
Postganglionic neuron	Otic ganglion	A collection of nerve cell bodies located inferior to the foramen ovale medial to the mandibular division of the trigeminal n.	<p>Postganglionic parasympathetic fibers arise in the otic ganglion</p> <p>These fibers travel to the auriculotemporal branch of the trigeminal n.</p> <p>Auriculotemporal n. travels to the parotid gland</p> <p>Postganglionic parasympathetic fibers innervate the:</p> <ul style="list-style-type: none"> <li>• Parotid gland</li> </ul>

ANATOMIC PATHWAY FOR SYMPATHETICS OF THE PAROTID GLAND			
Type of Neuron	Name of Cell Body	Characteristics of the Cell Body	Course of the Neuron
Preganglionic neuron	Intermediolateral horn nucleus	Collection of nerve cell bodies located in the lateral horn nucleus of the spinal cord between spinal segments T1 and T3 (and possibly T4)	<p>Fibers arise from the intermediolateral horn nuclei from T1 to T3 (4)</p> <p>Travel through the ventral root of the spinal cord to the spinal n.</p> <p>Enter the sympathetic chain via a white ramus communicantes</p> <p>Once in the sympathetic chain, the preganglionic fibers for the eye will ascend and synapse with postganglionic fibers in the superior cervical ganglion</p>
Postganglionic neuron	Superior cervical ganglion	Collection of nerve cell bodies located in the superior cervical ganglion, which is located at the base of the skull	<p>Fibers arise in the superior cervical ganglion</p> <p>Postganglionic fibers will follow the external carotid a.</p> <p>Branches from the external carotid a. follow the arteries that supply the parotid gland</p>

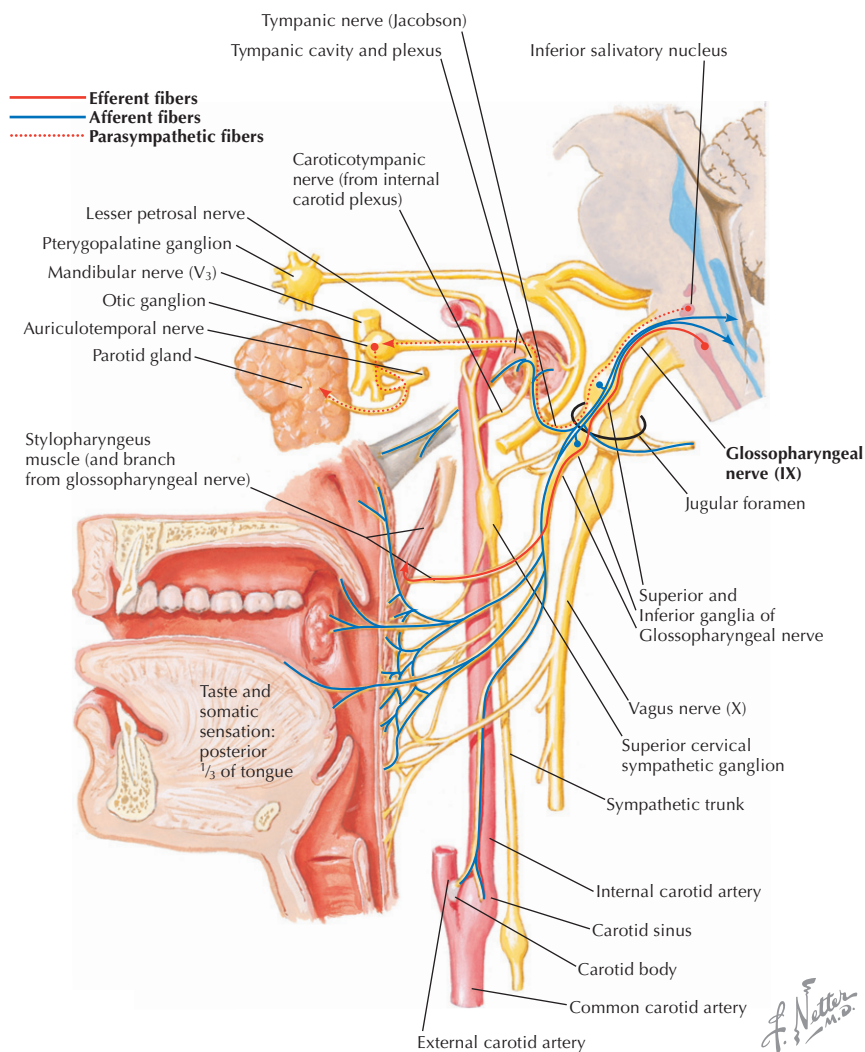
# Parasympathetic Pathways of the Head and Neck

## CRANIAL NERVE IX WITH CORRESPONDING SYMPATHETICS *CONTINUED*

20



## CRANIAL NERVE IX WITH CORRESPONDING SYMPATHETICS *CONTINUED*

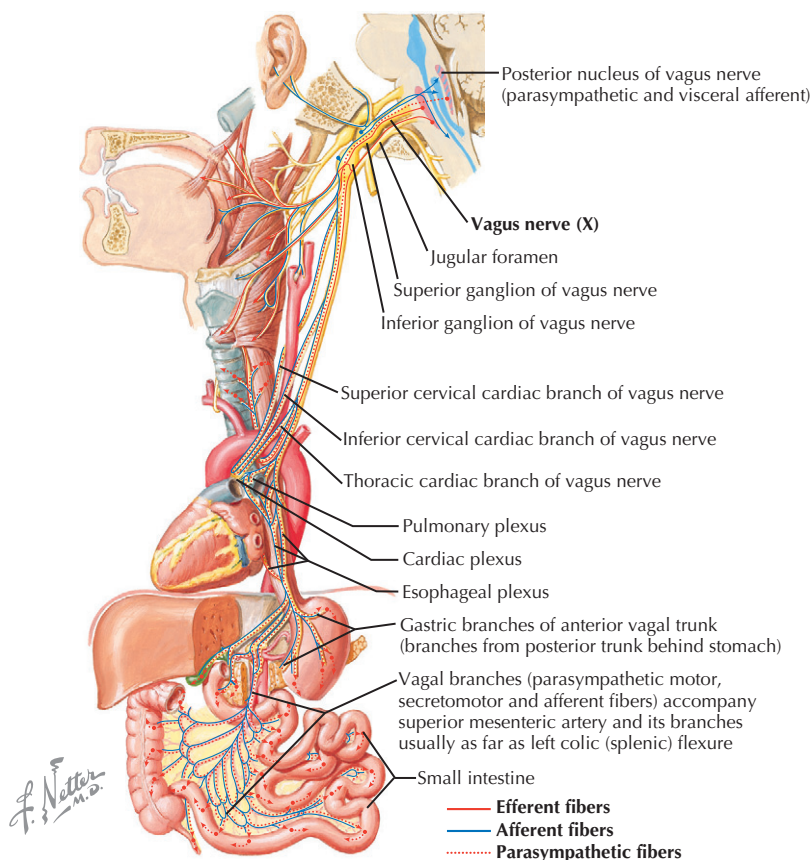




## CRANIAL NERVE X

ANATOMIC PATHWAY FOR PARASYMPATHETICS OF THE VAGUS NERVE*			
Type of Neuron	Name of Cell Body	Characteristics of the Cell Body	Course of the Neuron
Preganglionic neuron	Dorsal motor nucleus	A collection of nerve cell bodies located in the medulla	Preganglionic fibers arise from the dorsal motor nucleus of the vagus in the medulla* Travel through the vagus n. and exit the jugular foramen Various branches connect to intramural ganglia in the thorax and abdomen
Postganglionic neuron	Intramural ganglion	A collection of nerve cell bodies located within the walls of the individual organ	Postganglionic fibers arise in the intramural ganglia These fibers travel to the various effector organs: <ul style="list-style-type: none"> <li>• Cardiac muscle</li> <li>• Smooth muscle of vasculature</li> <li>• Glands</li> </ul>

\*The vagus n. arises in the brainstem but provides parasympathetic innervation to the thorax and greater part of the abdomen, rather than the head and neck. The sympathetics that follow the vagus n. to the thorax and greater part of the abdomen, as well as the sympathetics that follow the parasympathetic pelvic splanchnic nerves, arise from the various paravertebral and prevertebral ganglia associated with the sympathetic chain.





**HORNER'S SYNDROME**

Results from injury or undue stimulus to the sympathetic nerves of the head and neck

Causes may include:

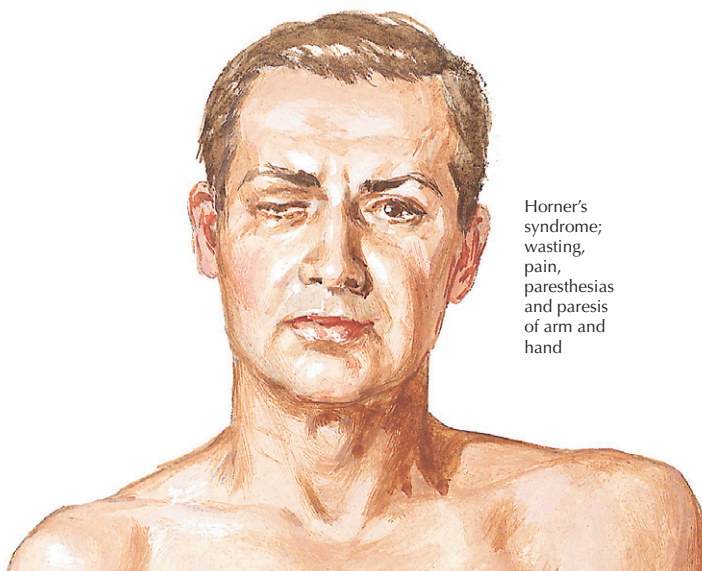
- Stroke
- Neck trauma
- Carotid artery injury
- Pancoast tumors
- Cluster headaches

Pharmacologic tests can help localize which part of the sympathetic pathway has been affected

Treatment depends on the cause (e.g., removal of a tumor)

Clinical manifestations include:

- Miosis (constriction of pupil)
- Ptosis (drooping of eyelid)
- Anhidrosis (decreased sweating)



Horner's syndrome; wasting, pain, paresthesias and paresis of arm and hand

*F. Netter M.D.*

## CHAPTER 21

# INTRAORAL INJECTIONS

Overview and Topographic Anatomy	536
Mandibular Injections	537
Maxillary Injections	546

## 21 Overview and Topographic Anatomy

### GENERAL INFORMATION

Intraoral injections provide adequate pain control for various dental procedures

Many techniques have been developed

All require detailed understanding of head and neck anatomy to maximize proper administration and minimize complications

Injections should not be performed in areas of infection or inflammation

The application of topical anesthetic to the site of injection will help lessen the pain caused by the insertion of the needle

#### *Classification*

- Local injections (field blocks)
- Nerve blocks

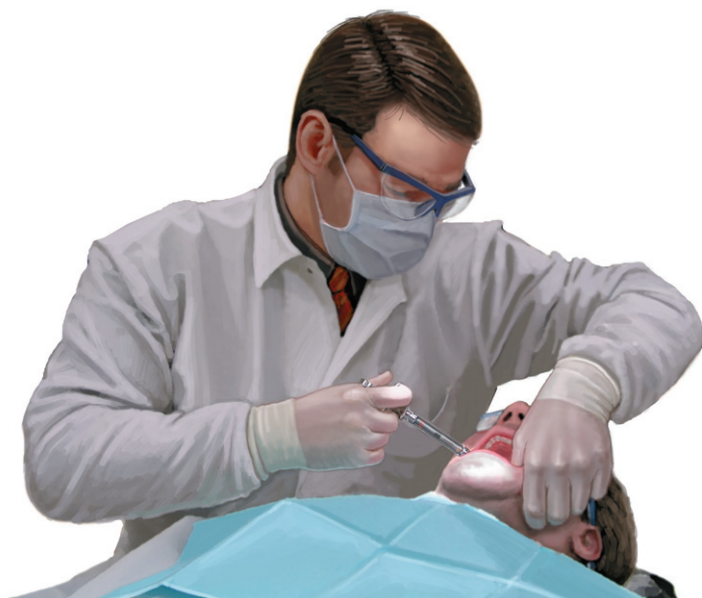#### *Common Blocks*

##### *Mandibular:*

- Inferior alveolar
- Long buccal
- Mental
- Gow-Gates
- Akinosi

##### *Maxillary:*

- Posterior superior alveolar
- Nasopalatine
- Greater palatine
- Infraorbital
- Maxillary division



*K. Carter*

# Mandibular Injections

## INNERVATION AND OSTEOLOGY LANDMARKS

### *Mandible: General Considerations and Landmarks*

The strongest and largest facial bone

Composed of 2 pieces of thick cortical bone: a lingual plate and a buccal plate

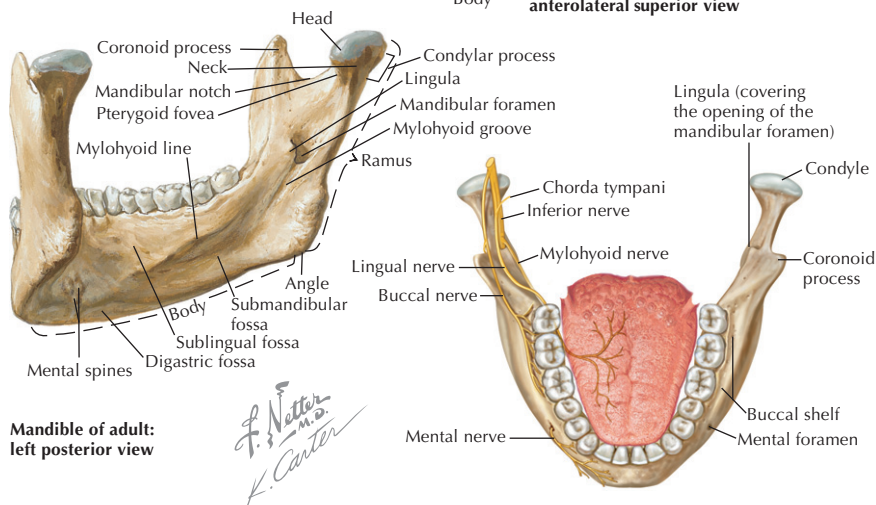
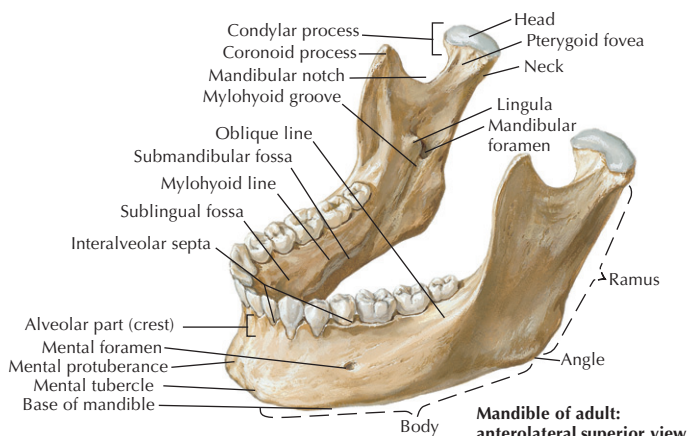
Teeth are contained in the horseshoe-shaped body

Ramus extends superiorly from the angle of the mandible

The coronoid notch is the concavity on the anterior portion of the ramus used to estimate the height of the mandibular foramen, which also is located at the height of the occlusal plane

### *Associated Nerves*

- Inferior alveolar nerve enters the mandible at the mandibular foramen
- Lingual nerve enters the oral cavity passing against the lingual tuberosity
- Buccal nerve lies on the buccal shelf

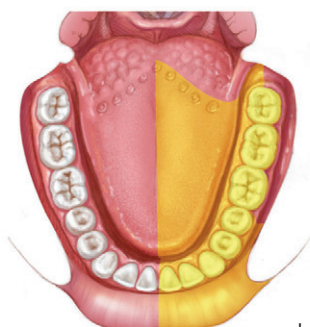


## 21 Mandibular Injections

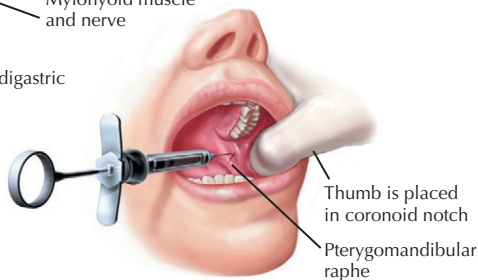
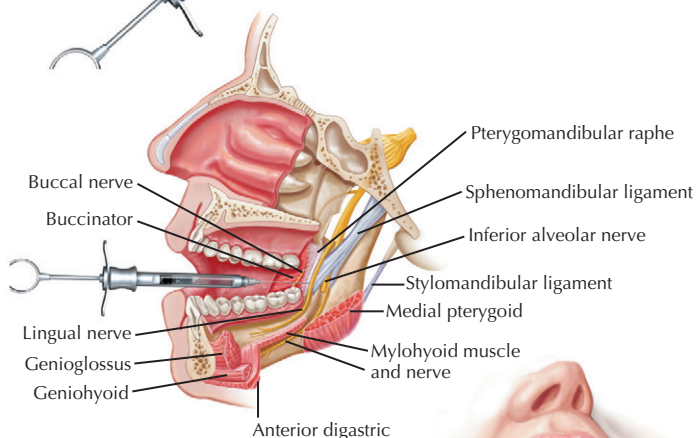
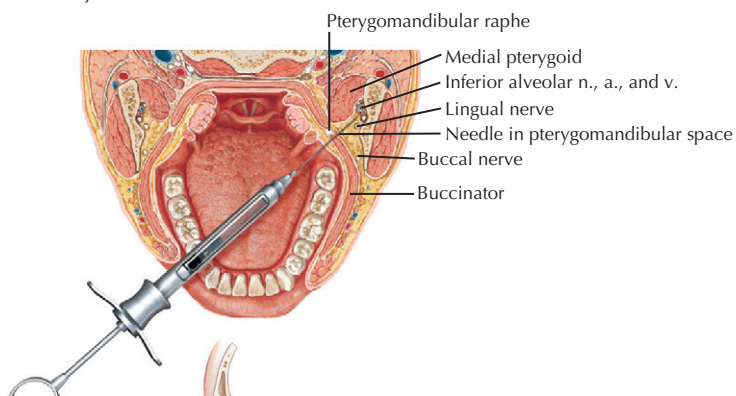
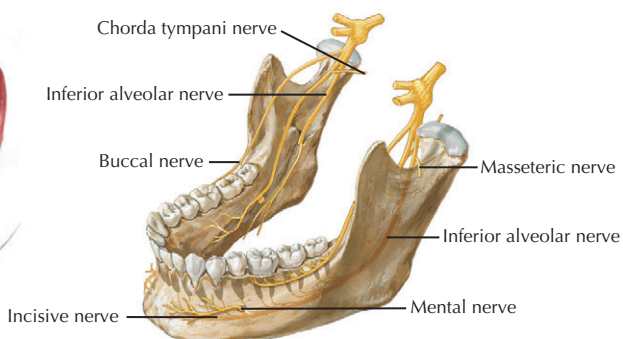
### INFERIOR ALVEOLAR NERVE BLOCK

OVERVIEW
<p>Clinically acceptable mandibular anesthesia is more difficult to achieve than maxillary anesthesia because of the thickness of the cortical bone</p> <p>Requires anesthetic deposition in the pterygomandibular space at the region of the mandibular foramen lateral to the sphenomandibular ligament</p> <p>Requires proper needle penetration and correct needle angulation in the pterygomandibular space</p> <p>Properly performed, it anesthetizes 2 nerves:</p> <ul style="list-style-type: none"> <li>• Inferior alveolar nerve (and its branches—the incisive and mental nerves)</li> <li>• Lingual nerve</li> </ul> <p><b>Areas anesthetized:</b></p> <ul style="list-style-type: none"> <li>• All mandibular teeth (inferior alveolar nerve)</li> <li>• Epithelium of the anterior 2/3rds of the tongue (lingual nerve)</li> <li>• All lingual gingiva and lingual mucosa (lingual nerve)</li> <li>• All buccal gingiva and mucosa from the premolars to the midline (mental nerve)</li> <li>• Skin of the lower lip (mental nerve)</li> </ul>
GENERAL METHODOLOGY
<p><b>Steps:</b></p> <ul style="list-style-type: none"> <li>• Insert the needle into the mucosa between the deepest portion of the coronoid notch (which should represent the vertical height of the mandibular foramen) and just lateral to the pterygomandibular raphe</li> <li>• Orient the needle from the contralateral premolars and advance it along the occlusal plane of the mandible</li> <li>• The needle contacts the mandible after entering 20 to 25 mm (if bone is contacted immediately on penetration into the mucosa, then the temporal crest has been contacted; the needle should be reoriented to allow insertion to the proper depth)</li> <li>• Withdraw the needle slightly and perform aspiration to determine whether the needle is in a blood vessel (inferior alveolar vessels)</li> <li>• After a negative result on aspiration (no blood observed in the syringe), slowly inject the anesthetic into the pterygomandibular space</li> <li>• If the result of aspiration is positive, readjust the needle position and perform aspiration again before injecting into the pterygomandibular space</li> </ul>
CONSIDERATIONS
<p>In <i>children</i>, the mandibular foramen is located closer to the posterior border of the mandible until more bone is added with age</p> <p>In <i>edentulous patients</i>, the alveolar bone is lost; thus, the deepest part of the coronoid notch is lower than normal, which could lead the clinician to aim the needle too low</p> <p>In <i>class II malocclusion</i>, when the mandible is hypoplastic, the mandibular foramen is typically located more inferior than the clinician may think</p> <p>In <i>class III malocclusion</i>, when the mandible is hyperplastic, the mandibular foramen is typically located more superior than the clinician may think</p> <p>A transient, dental-induced <i>Bell's palsy</i> can result if the needle is placed too far posteriorly in the parotid bed and anesthetic is introduced close to the facial nerve</p>

## INFERIOR ALVEOLAR NERVE BLOCK CONTINUED



Area anesthetized by an inferior alveolar injection



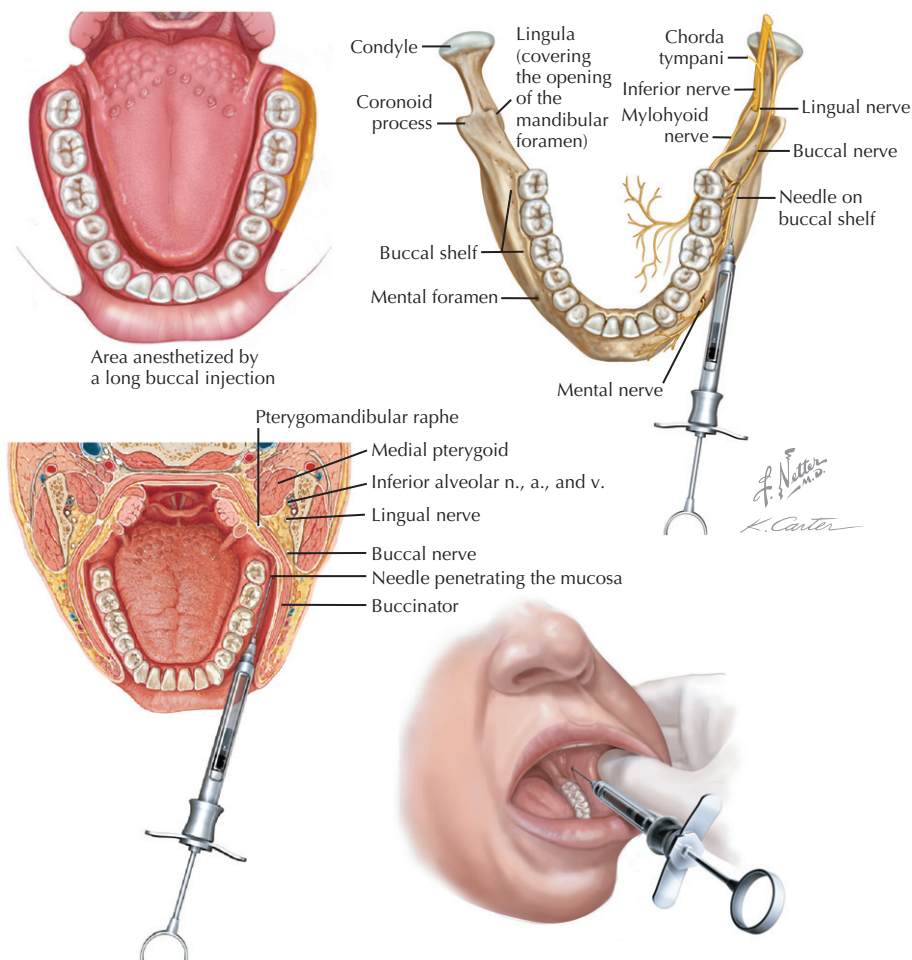
*F. Netter M.D.*  
*R. Carter*



## 21 Mandibular Injections

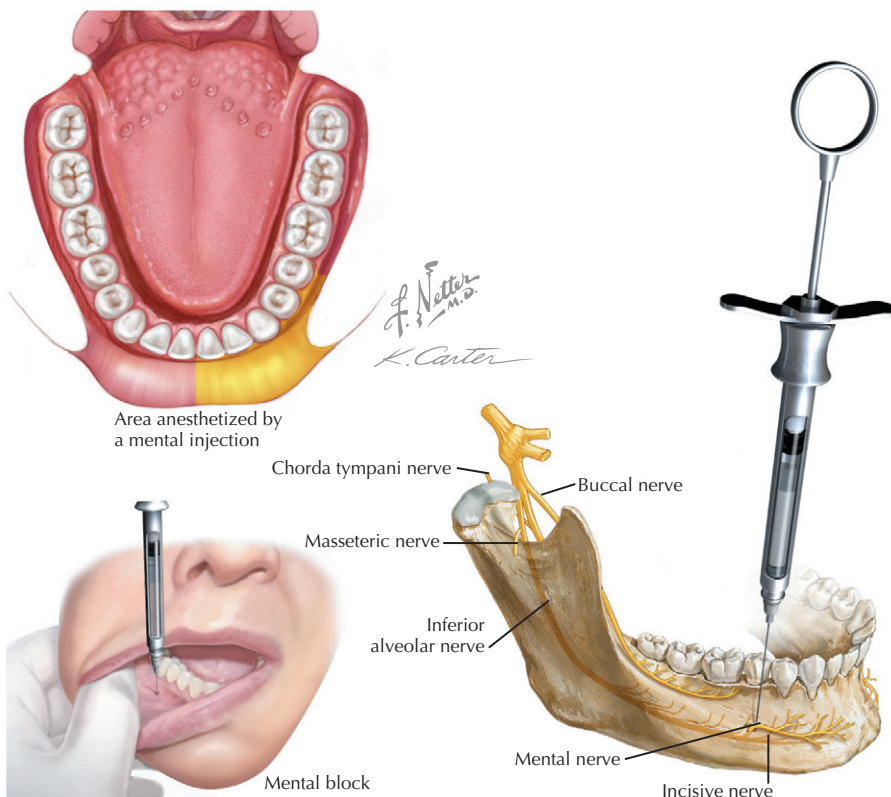
### LONG BUCCAL NERVE BLOCK

OVERVIEW
<p>A branch of the mandibular division of the trigeminal nerve, the long buccal nerve is not anesthetized in an inferior alveolar injection</p> <p>This block anesthetizes all buccal gingiva opposite the mandibular molars, including the retromolar trigone</p>
GENERAL METHODOLOGY
<p><b>Steps:</b></p> <ul style="list-style-type: none"> <li>• Insert the needle into the mucosa posterior to the last molar in the mandibular arch on the buccal side (the needle will be inserted a very short distance—about 2 mm)</li> <li>• Perform aspiration; after a negative result, inject the anesthetic</li> </ul>
CONSIDERATIONS
<p>A hematoma is rare with this block</p> <p>This injection seldom fails</p>



## MENTAL NERVE BLOCK

OVERVIEW
<p>A branch of the inferior alveolar nerve within the mandibular canal</p> <p><b>Areas anesthetized:</b></p> <ul style="list-style-type: none"> <li>• All buccal gingiva and mucosa from the premolars to the midline (mental nerve)</li> <li>• Skin of the lower lip (mental nerve)</li> </ul>
GENERAL METHODOLOGY
<p><b>Steps:</b></p> <ul style="list-style-type: none"> <li>• Locate the mental foramen via palpation</li> <li>• Insert the needle into the mucosa at the mucobuccal fold at the location of the mental foramen (normally around the 2nd mandibular premolar) (the needle will be inserted a short distance in the direction of the mental foramen)</li> <li>• Perform aspiration; after a negative result, slowly inject the anesthetic</li> </ul>
CONSIDERATIONS
<p>X-ray imaging can help the clinician locate the mental foramen if palpation does not do so</p> <p>This block seldom fails</p>



## 21 Mandibular Injections

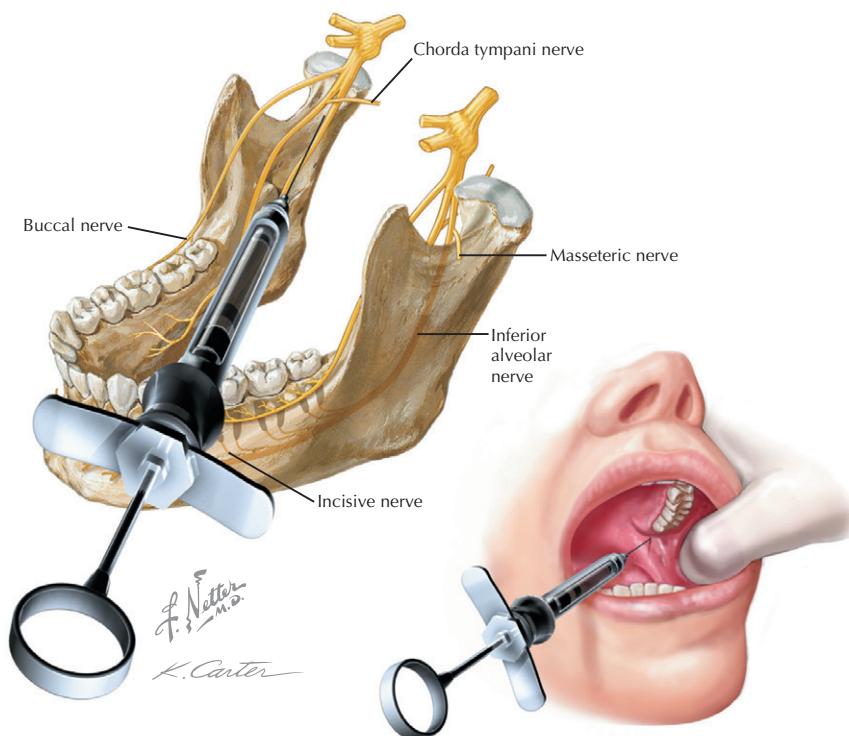
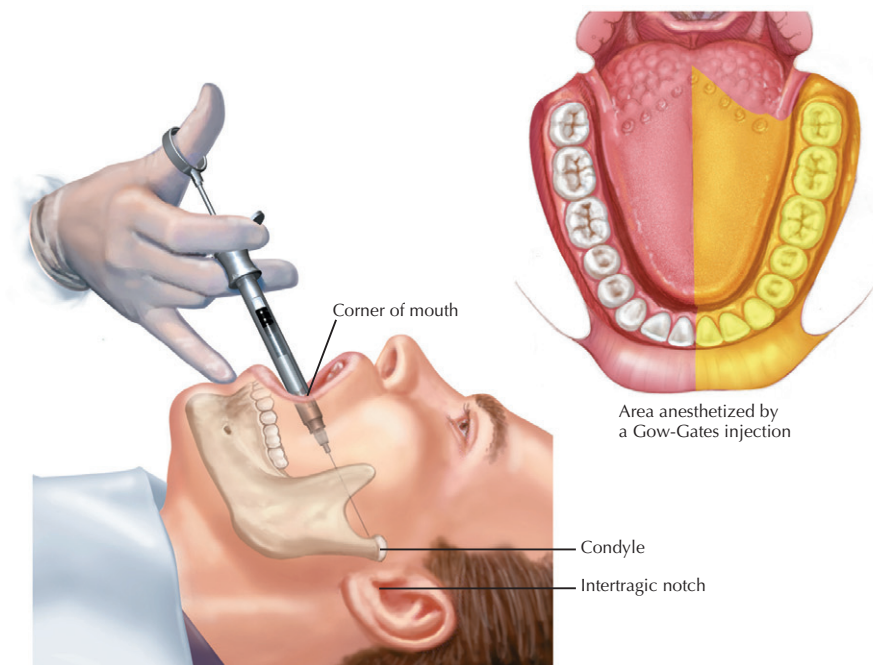
### GOW-GATES BLOCK

OVERVIEW
<p>A variation of the inferior alveolar nerve block, it anesthetizes the following nerves:</p> <ul style="list-style-type: none"> <li>• Inferior alveolar nerve (and its branches, the mental and incisive nerves)</li> <li>• Mylohyoid nerve</li> <li>• Lingual nerve</li> <li>• Long buccal nerve (often)</li> <li>• Auriculotemporal nerve (often)</li> </ul> <p>Low positive aspiration rate relative to that for the standard inferior alveolar nerve block injection</p> <p>When the injection is properly administered, the needle contacts the neck of the mandibular condyle</p> <p><b>Areas anesthetized:</b></p> <ul style="list-style-type: none"> <li>• All mandibular teeth (inferior alveolar nerve)</li> <li>• Epithelium of the anterior 2/3rds of the tongue (lingual nerve)</li> <li>• All lingual gingiva and lingual mucosa (lingual nerve)</li> <li>• All buccal gingiva and mucosa (long buccal and mental nerves)</li> <li>• Skin of the lower lip (mental nerve)</li> <li>• Skin along the temple, anterior to the ear, and posterior part of the cheek (auriculotemporal and buccal nerves)</li> </ul>
GENERAL METHODOLOGY
<p><b>Steps:</b></p> <ul style="list-style-type: none"> <li>• The mouth is opened as wide as possible</li> <li>• Insert the needle high into the mucosa at the level of the 2nd maxillary molar just distal to the mesiolingual cusp</li> <li>• Use the intertragic notch as an extraoral landmark to help reach the neck of the mandibular condyle</li> <li>• Advance the needle in a plane from the corner of the mouth to the intertragic notch from the contralateral premolars (this position varies in accordance with individual flare of the mandible) until it contacts the condylar neck</li> <li>• Withdraw the needle slightly and perform aspiration to observe whether the needle is in a blood vessel</li> <li>• After a negative result on aspiration, slowly inject the anesthetic</li> <li>• Have the patient keep the mouth open for a few minutes after injection, to allow the anesthetic to diffuse around the nerves</li> </ul>
CONSIDERATIONS
<p>Useful for multiple procedures on mandibular teeth and buccal soft tissue</p> <p>Few complications</p> <p>Works well for a bifid inferior alveolar nerve</p>

# Mandibular Injections

## GOW-GATES BLOCK *CONTINUED*

21



## 21 Mandibular Injections

### AKINOSI BLOCK

#### OVERVIEW

A closed-mouth approach for the mandibular nerve block, it anesthetizes the following nerves:

- Inferior alveolar nerve (and its branches, the mental and incisive nerves)
- Mylohyoid nerve
- Lingual nerve

Useful when mandibular depression (opening) is limited, such as with trismus

Considered a “blind” injection

#### **Areas anesthetized:**

- All mandibular teeth (inferior alveolar nerve)
- Epithelium of the anterior 2/3rds of the tongue (lingual nerve)
- All lingual gingiva and lingual mucosa (lingual nerve)
- All buccal gingiva and mucosa from the premolars to the midline (mental nerve)
- Skin of the lower lip (mental nerve)

#### GENERAL METHODOLOGY

#### **Steps:**

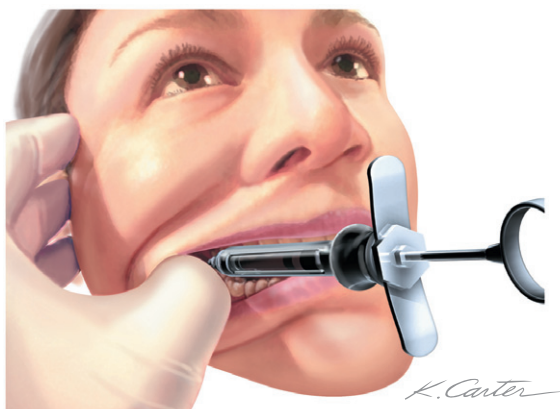- Have the patient close the mouth
- Insert the needle into the mucosa between the medial border of the mandibular ramus and the maxillary tuberosity at the level of the cervical margin of the maxillary molars
- Advance the needle parallel to the maxillary occlusal plane
- Once the needle is advanced approximately 23 to 25 mm, it should be located in the middle of the pterygomandibular space near the inferior alveolar and lingual nerves (*note: no bone will be contacted*)
- After a negative result on aspiration, slowly inject the anesthetic

#### CONSIDERATIONS

Often used in patients with a *limited ability to open the mouth* and when intraoral landmarks for a standard inferior alveolar nerve block are difficult to view

A transient, dental induced *Bell's palsy* can result if the needle is placed too far posteriorly in the parotid bed and anesthetic is introduced close to the facial nerve

Good for patients with a *strong gag reflex* or *macroglоссия*

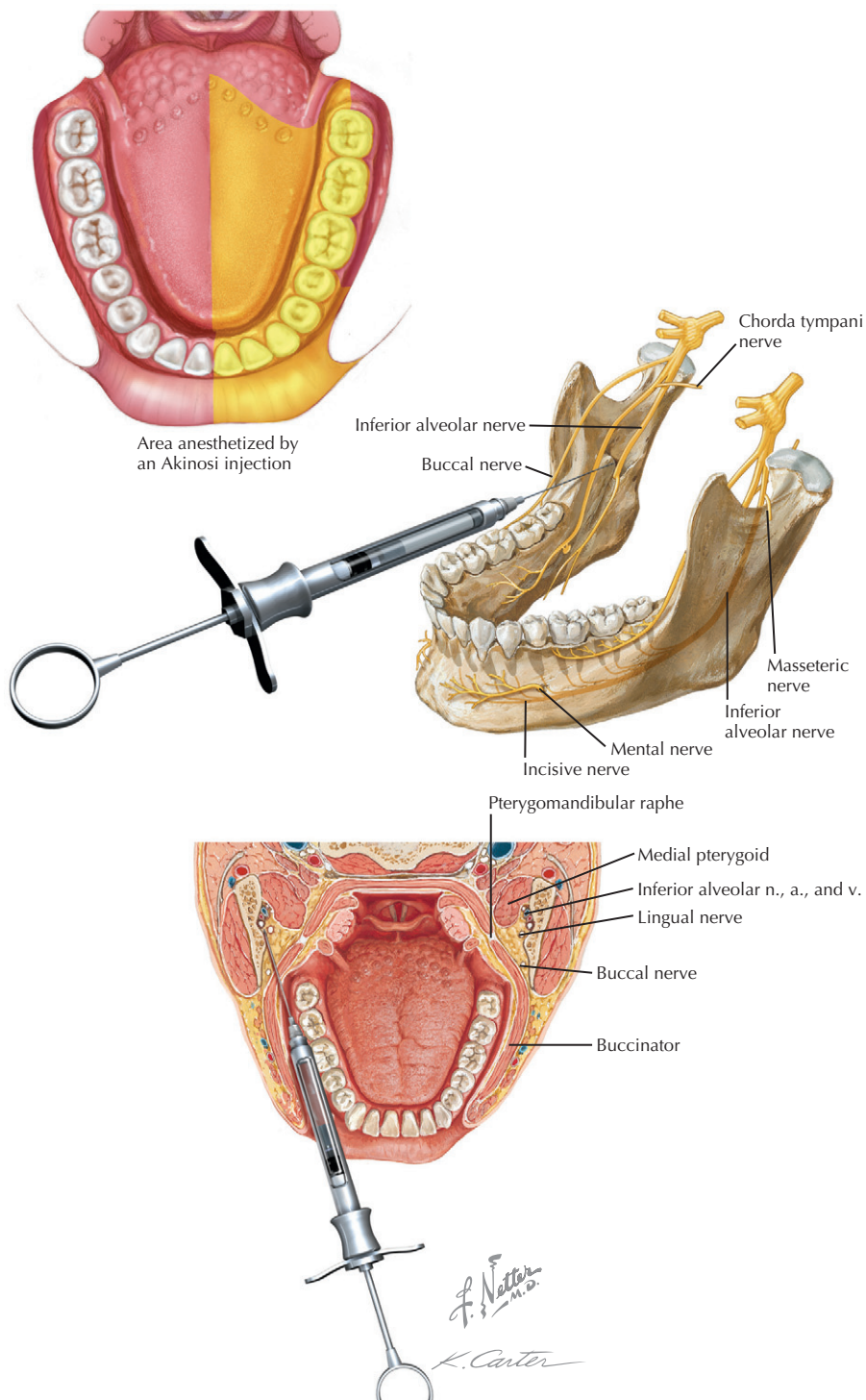




# Mandibular Injections

21

## AKINOSI BLOCK CONTINUED





## 21 Maxillary Injections

### INNERVATION AND OSTEOLOGY LANDMARKS

#### MAXILLA: GENERAL CONSIDERATIONS AND LANDMARKS

One of the largest facial bones

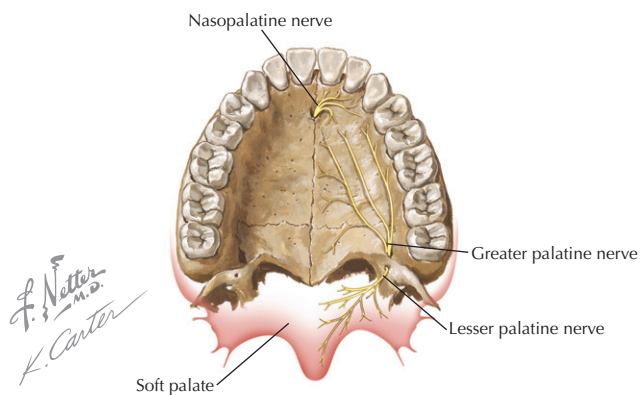
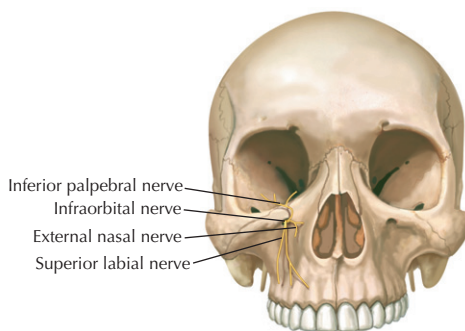
Porous bone, which aids in achieving anesthesia of the maxillary teeth

#### Teeth

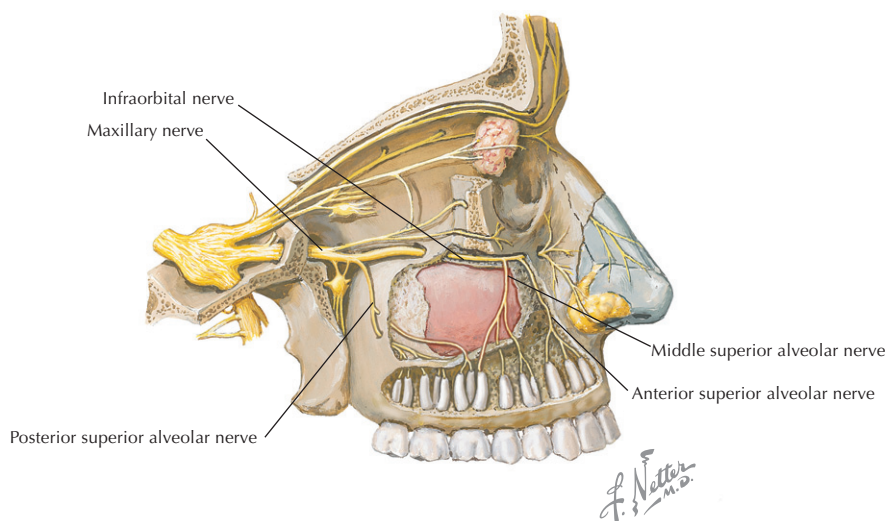
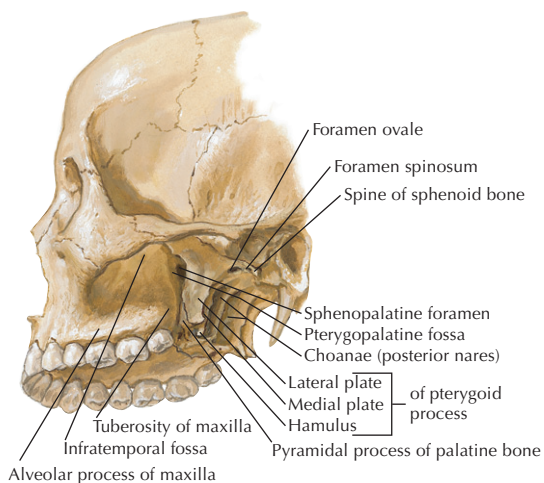
- Contained in the alveolar bone
- Maxillary teeth are supplied by the anterior, middle, and posterior superior alveolar nerves (in some patients, the middle superior alveolar nerve may not be present)

#### Hard Palate

- Composed of the palatal process of the maxilla and the horizontal plate of the palatine
- Supplied by the nasopalatine and greater palatine nerves



## INNERVATION AND OSTEOLOGY LANDMARKS *CONTINUED*



## POSTERIOR SUPERIOR ALVEOLAR NERVE BLOCK

## OVERVIEW

A frequently used block

The injection is in the infratemporal fossa

**Areas anesthetized:**

- All maxillary molars, with the possible exception of the mesiobuccal root of the 1st maxillary molar
- Buccal gingiva opposite the teeth

## GENERAL METHODOLOGY

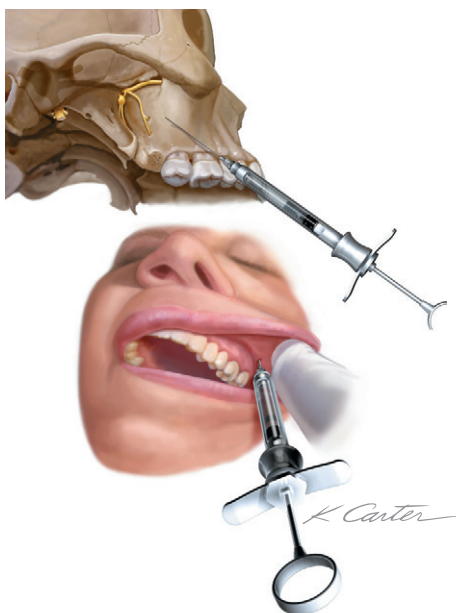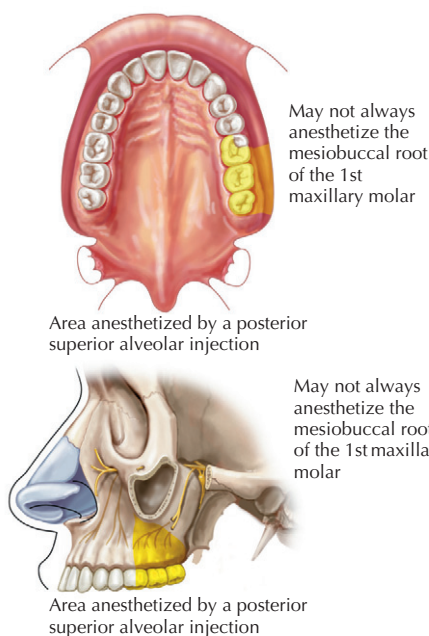
**Steps:**

- With the mouth open, the patient is instructed to deviate the mandible toward the same side as the injection, to produce more work space for the clinician
- Insert the needle into the mucosa at the mucobuccal fold just superior to the maxillary 2nd molar, between the medial border of the ramus of the mandible and the maxillary tuberosity
- In a single motion, the needle needs to be advanced approximately 15 mm in the following x-y-z plane at the same time, to reach the posterior superior alveolar nerve along the posterior surface of the maxilla:
  - Medially at a 45-degree angle to the maxillary occlusal plane
  - Superiorly at a 45-degree angle to the maxillary occlusal plane
  - Posteriorly at a 45-degree angle to the maxillary occlusal plane
- Perform aspiration due to the close proximity of the pterygoid plexus
- After a negative result on aspiration, slowly inject the anesthetic

## CONSIDERATIONS

Significant potential for formation of a hematoma involving the pterygoid plexus

Short needles are preferred, to reduce the risk of hematoma



# Maxillary Injections

## NASOPALATINE NERVE BLOCK

### OVERVIEW

Considered the most painful of dental injections

Because of the sensitivity of the area, pressure anesthesia (e.g., using a cotton swab applicator) is helpful at the site of injection

#### **Areas anesthetized:**

- The area's palatal gingiva and mucosa from the maxillary canine on the right to the maxillary canine on the left side of the maxilla
- Both the right and left nasopalatine nerves, because they exit onto the hard palate in close proximity

Oral mucosa in this region is tightly adhered to the hard palate; thus deposition of anesthetic in the area has less space to diffuse

### GENERAL METHODOLOGY

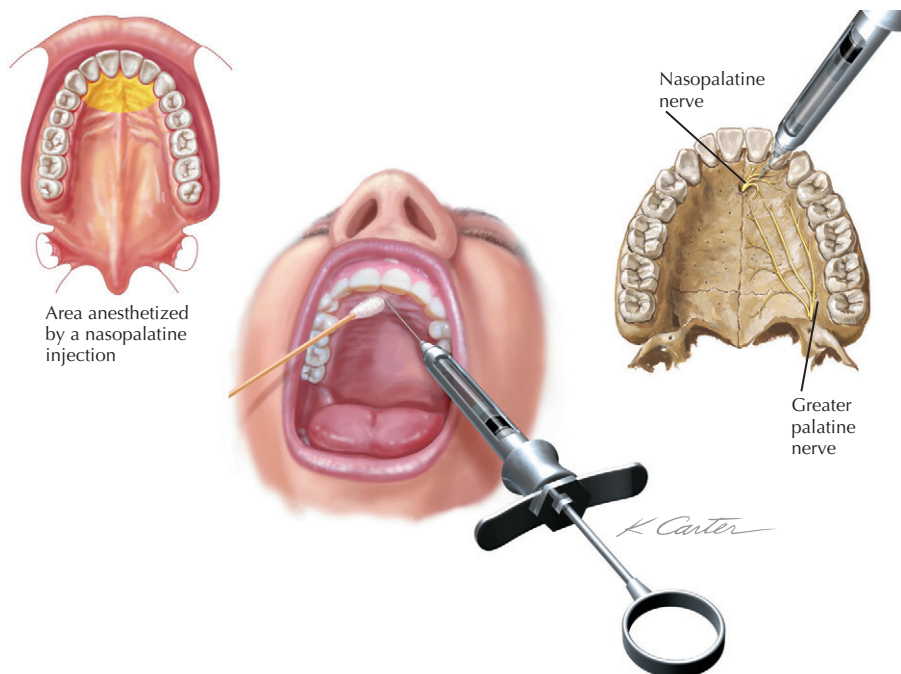
#### **Steps:**

- Use a cotton swab applicator to apply pressure to the injection site
- Insert the needle into the palatal mucosa lateral to the incisive papilla
- Deposit a small amount of anesthetic to help lessen the trauma; the vasoconstrictor norepinephrine then causes the area's soft tissue to blanch
- Advance the needle until it contacts the hard palate
- Withdraw the needle slightly and perform aspiration
- After a negative result on aspiration, very slowly inject the anesthetic

### CONSIDERATIONS

Pressure anesthesia is beneficial to help lessen the pain

Because the tissue is so dense and is attached to the bone, this block requires a slow injection



## 21 Maxillary Injections

### GREATER PALATINE NERVE BLOCK

#### OVERVIEW

Another commonly used block to anesthetize areas of the hard palate

Not as traumatic for the patient as the nasopalatine nerve block

Because of the sensitivity of the area, pressure anesthesia (e.g., using a cotton swab applicator) is helpful at the site of injection

#### **Areas anesthetized:**

- Palatal gingiva and mucosa in the area from the maxillary 1st premolar (anteriorly) to the posterior portion of the hard palate to the midline

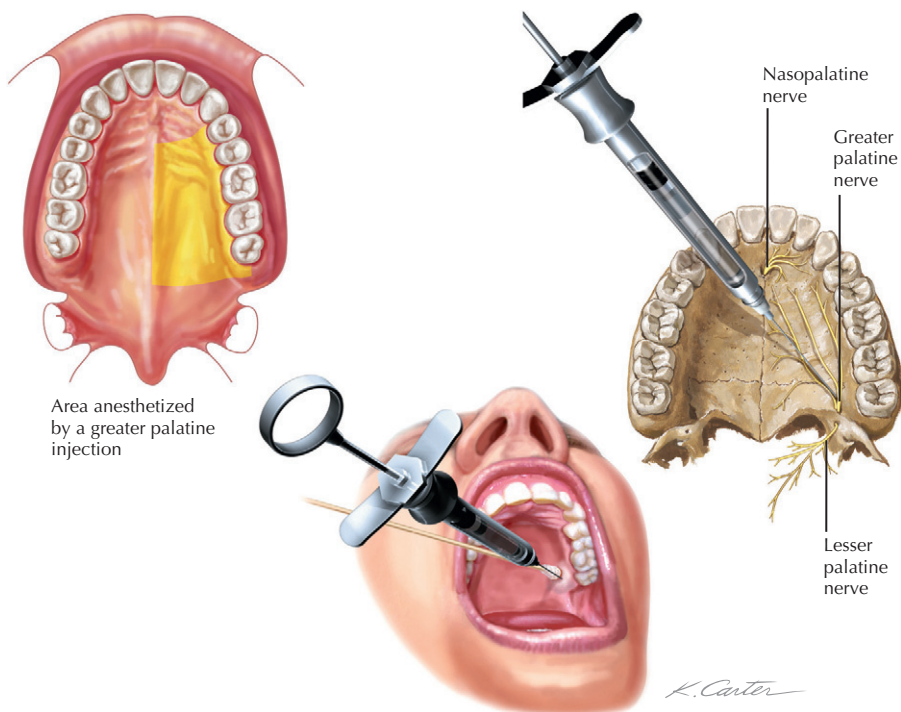
#### GENERAL METHODOLOGY

#### **Steps:**

- Locate the greater palatine foramen by using a cotton swab applicator to press down on the tissue in the region of the 1st maxillary molar, moving posteriorly until the swab dips into the tissue (usually posterior to the 2nd maxillary molar)
- Use a cotton swab applicator to apply pressure to the injection site
- Insert the needle and inject a small amount of anesthetic to lessen patient discomfort; the tissue of the area will begin to blanch from the effects of the anesthetic agent
- Advance the needle until it contacts the hard palate
- Withdraw the needle slightly and perform aspiration
- After a negative result on aspiration, slowly inject the anesthetic

#### CONSIDERATIONS

The clinician should be able to feel the needle contact bone; otherwise, the needle could be too posterior in the soft palate



# Maxillary Injections

## MIDDLE SUPERIOR ALVEOLAR NERVE BLOCK

### OVERVIEW

The middle superior alveolar nerve is reported to be present in about 30% of all people

#### **Areas anesthetized:**

- All maxillary premolars and possibly the mesiobuccal root of the 1st maxillary molar
- Buccal gingiva opposite the teeth

### GENERAL METHODOLOGY

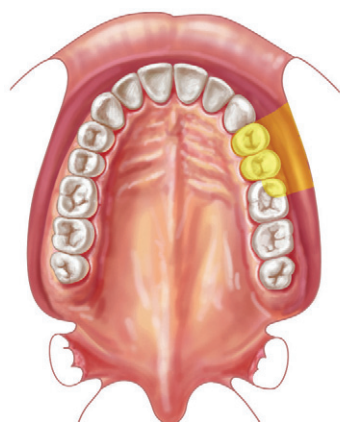
#### **Steps:**

- Insert the needle into the mucosa at the mucobuccal fold just superior to the area of the maxillary 2nd premolar
- Advance the needle until the tip is superior to the apex of the maxillary 2nd premolar for maximum anesthesia
- After a negative result on aspiration, slowly inject the anesthetic

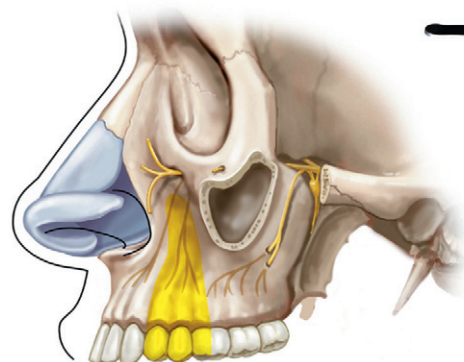
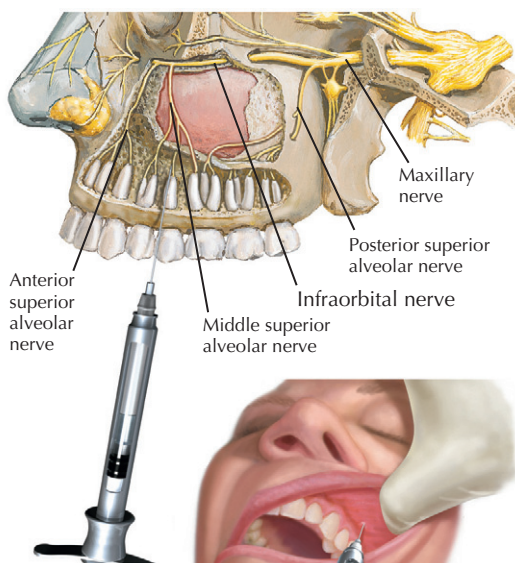
### CONSIDERATIONS

Local infiltrations are a common substitute for this block

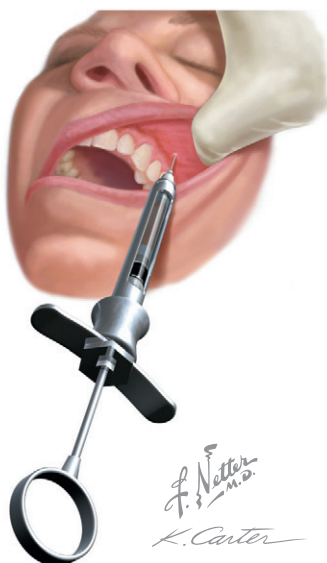This area is somewhat avascular, and hematoma formation is rare



Area anesthetized by a middle superior alveolar injection



Area anesthetized by a middle superior alveolar injection





**INFRAORBITAL/ANTERIOR SUPERIOR ALVEOLAR NERVE BLOCK****OVERVIEW**

Less frequently used because of the risk of the clinician injuring the patient's eye

This block anesthetizes the following nerves:

- Anterior superior alveolar nerve
- Middle superior alveolar nerve
- Infraorbital nerve

**Areas anesthetized:**

- All maxillary teeth from the central incisor to the premolars, with the possible inclusion of the mesiobuccal root of the 1st maxillary molar
- Buccal gingiva opposite these teeth
- Lateral aspect of nose, lower eyelid, and upper lip

**GENERAL METHODOLOGY****Steps:**

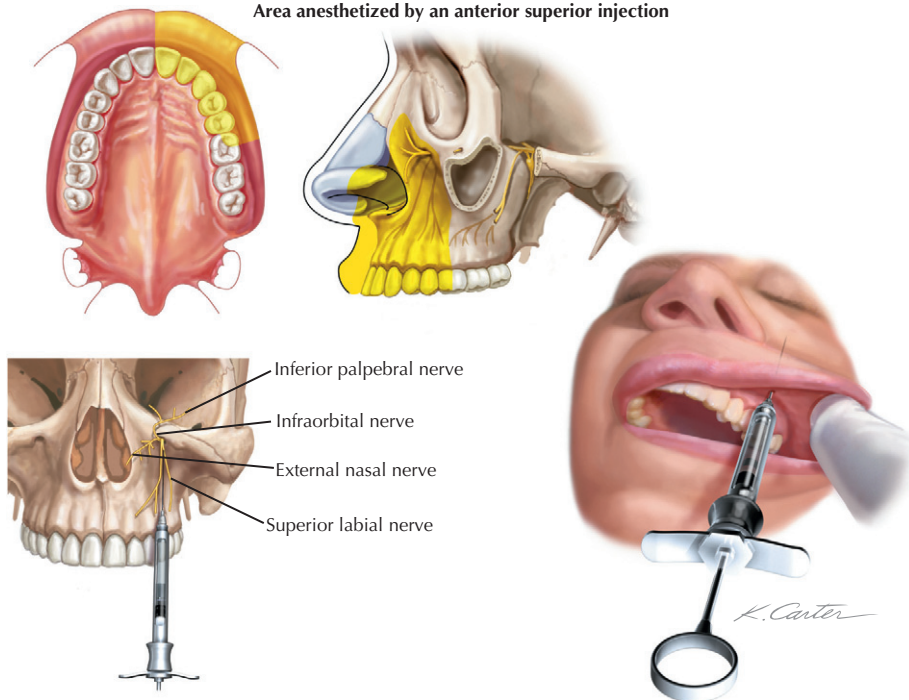
- Locate the infraorbital foramen via palpation
- Insert the needle into the mucosa at the mucobuccal fold in the area superior to the 1st maxillary premolar
- Advance the needle parallel to the long axis of the tooth until it contacts the bone of the infraorbital foramen
- After a negative result on aspiration, slowly inject the anesthetic

**CONSIDERATIONS**

No significant potential for a hematoma

Useful when pulpal anesthesia cannot be achieved in a local infiltration because of dense bone or when anesthesia is required on multiple teeth that would need more than one injection

Area anesthetized by an anterior superior injection



# Maxillary Injections

## MAXILLARY DIVISION BLOCK

### OVERVIEW

An excellent technique to achieve hemimaxillary anesthesia

Anesthetizes all of the branches of the maxillary division of the trigeminal nerve

Useful in extensive quadrant procedures and surgery

With blocking of the entire division, the following nerves are anesthetized:

- Posterior superior alveolar nerve
- Middle superior alveolar nerve
- Anterior superior alveolar nerve
- Nasopalatine nerve
- Greater palatine nerve
- Infraorbital nerve

#### **Areas anesthetized:**

- All maxillary teeth
- All buccal gingiva
- All palatal gingiva and mucosa
- Lateral aspect of nose, lower eyelid, and upper lip

### GENERAL METHODOLOGY

**Goal:** to deposit the anesthetic in the pterygopalatine fossa using its eventual connection with the greater palatine foramen

#### **Steps:**

- Locate the greater palatine foramen by using a cotton swab applicator to press in the region of the 1st maxillary molar, moving posteriorly until the swab dips into the tissue (usually posterior to the 2nd maxillary molar)
- Use a cotton swab applicator to apply pressure to the injection site
- Insert the needle into the mucosa and inject a small amount of anesthetic to lessen patient discomfort; the tissue will begin to blanch as a result of effects of the anesthetic agent
- Insert the needle further and locate the greater palatine foramen with the needle
- Once the foramen is located, insert the needle and advance it approximately 28 to 30mm; at this location, the needle should be in the pterygopalatine fossa
- During the passage, if any bony resistance is met, the needle may be rotated to aid insertion (*note:* under no circumstances should the needle be forced)
- After a negative result on aspiration, slowly inject the anesthetic

### CONSIDERATIONS

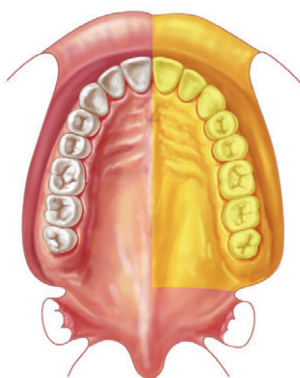
The needle should NEVER be forced into the greater palatine foramen, because occasionally the canal is not vertical, so that forced entry will fracture the bone

Because the orbit is located superior to the pterygopalatine fossa, if the needle is placed too far superiorly, the anesthetic can be deposited in this region, affecting the eye

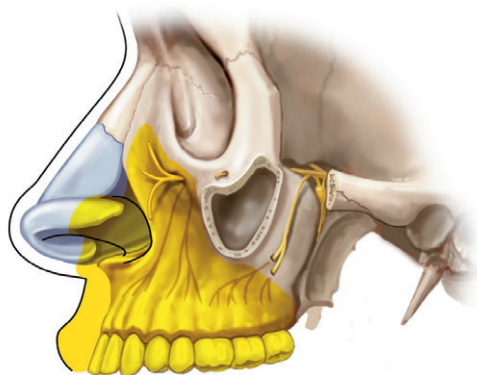
Because the palatine vessels also are contents of the canal, care must be taken to prevent hematoma

## 21 Maxillary Injections

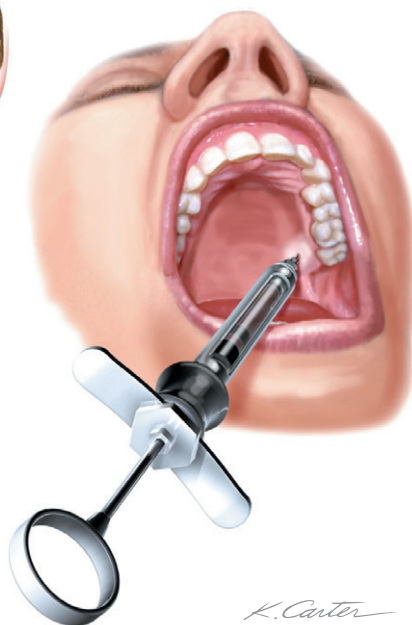
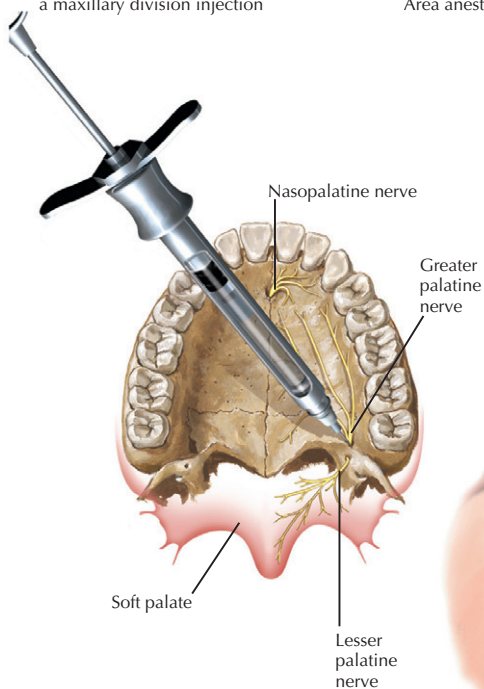
### MAXILLARY DIVISION BLOCK *CONTINUED*



Area anesthetized by  
a maxillary division injection



Area anesthetized by a maxillary division injection



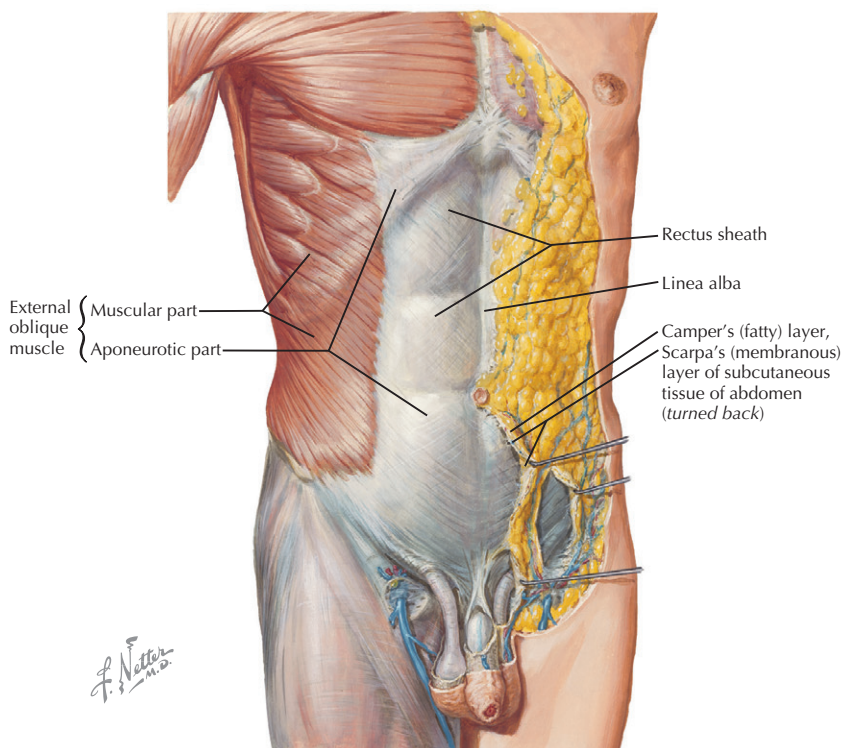
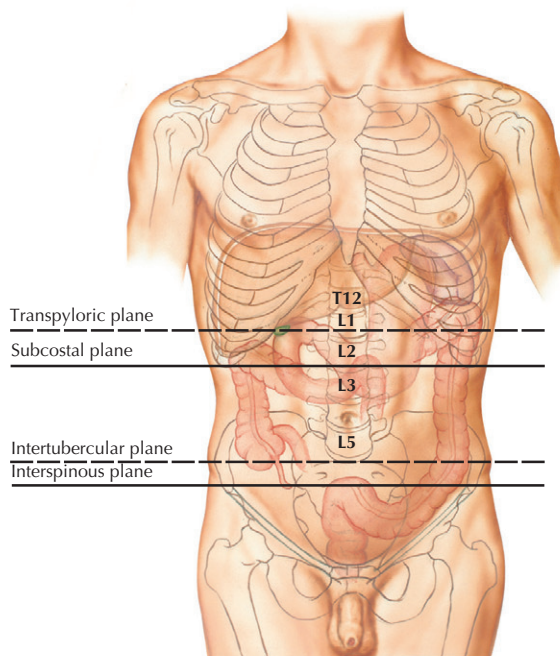
## CHAPTER 22

# INTRODUCTION TO THE UPPER LIMB, BACK, THORAX, AND ABDOMEN

Overview and Topographic Anatomy	556
Osteology	558
Muscles	568
Contents of the Thorax	582
Contents of the Abdomen	589
Vascular Supply	601
Nerve Supply	614

**GENERAL INFORMATION**

Upper limb	<p>The upper limb is the region of the body composed of the:</p> <ul style="list-style-type: none"> <li>• Pectoral girdle</li> <li>• Brachium (arm)</li> <li>• Antebrachium (forearm)</li> <li>• Manus (hand)</li> </ul> <p>It is a very mobile structure that allows objects to be manipulated All motor and sensory innervation is derived from the brachial plexus, which arises from the ventral rami of C5-T1 It is a frequent site of traumatic injury</p>
Back and thorax	<p>The thoracic cavity is divided into:</p> <ul style="list-style-type: none"> <li>• 2 Pleural cavities</li> <li>• Mediastinum</li> </ul>
Anterolateral abdominal wall	<p>Layers of the anterolateral abdominal wall</p> <ul style="list-style-type: none"> <li>• Skin</li> <li>• Superficial fascia</li> <li>• Fatty superficial layer (Camper's)</li> <li>• Membranous superficial layer (Scarpa's)</li> <li>• External oblique</li> <li>• Internal oblique</li> <li>• Transversus abdominis</li> <li>• Transversalis fascia</li> <li>• Extraperitoneal fat</li> <li>• Parietal peritoneum</li> </ul>
Abdomen	<p>Part of the trunk that lies between the thorax and the pelvis, containing:</p> <ul style="list-style-type: none"> <li>• Peritoneal cavity</li> <li>• GI organs</li> <li>• Liver and biliary system</li> <li>• Adrenal glands</li> <li>• Pancreas</li> <li>• Kidneys and upper part of ureters</li> <li>• Nerves and blood vessels</li> </ul> <p>Divided into body planes:</p> <ul style="list-style-type: none"> <li>• Xiphisternal—T9</li> <li>• Transpyloric—L1</li> <li>• Subcostal—L3</li> <li>• Supracristal—L4</li> <li>• Transtuberular—L5</li> <li>• Interspinous—S2</li> </ul>





## UPPER LIMB

## BONES OF THE PECTORAL GIRDLE

## Clavicle

Is convex anteriorly at the sternal end (medial  $\frac{2}{3}$  rds) and concave anteriorly at the acromial end (lateral  $\frac{1}{3}$  rd)

Provides for the attachment of four muscles:

- Pectoralis major
- Deltoid
- Trapezius
- Sternocleidomastoid

Transmits force from the upper limb to the axial skeleton

Is paired

Is frequently fractured

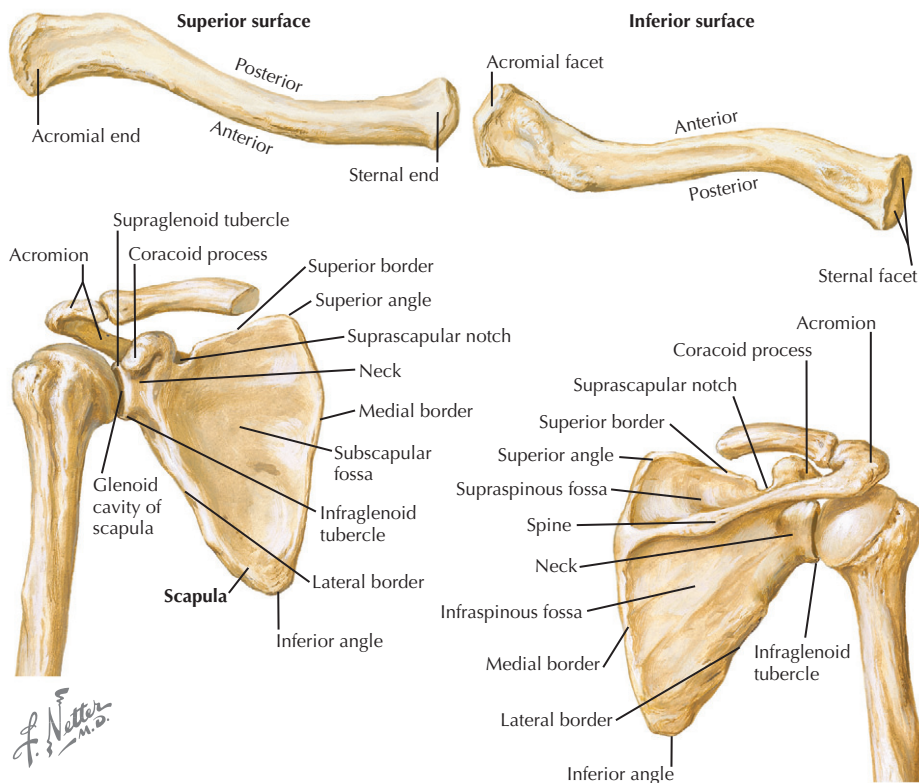
## Scapula

Is flat and triangular in shape

Is paired

Has numerous parts:

- Costal surface—provides attachment for subscapularis
- Spine—provides attachment for trapezius and deltoid
- Acromion—provides attachment for trapezius and deltoid and articulates with clavicle
- Glenoid cavity—articulates with the head of the humerus
- Supraglenoid tubercle—provides attachment for the long head of the biceps brachii
- Infraglenoid tubercle—provides attachment for the long head of the triceps brachii
- Scapular notch—is crossed superiorly by the transverse scapular ligament; suprascapular n. passes inferior to ligament while suprascapular vv. pass superior to ligament
- Coracoid process—provides attachment for pectoralis minor, short head of biceps brachii, and coracobrachialis



# Osteology

## UPPER LIMB *CONTINUED*

### BONES OF THE UPPER LIMB

#### Humerus

Articulates with the scapula, ulna, and radius

Also known as the arm

Longest bone of the upper limb

Has eight centers of ossification

Has 16 major parts:

- Head—smooth surface that articulates with the glenoid cavity of the scapula
- Anatomical neck—oblique passing groove that provides attachment for the articular capsule
- Greater tubercle—provides attachment for 3 rotator cuff muscles: supraspinatus, infraspinatus, and teres minor
- Lesser tubercle—provides attachment for 1 rotator cuff muscle: subscapularis
- Intertubercular groove—between greater and lesser tubercles; long head of the biceps brachii located in groove
- Surgical neck—axillary nerve and posterior humeral circumflex vv. lie in contact with medial portion of surgical neck
- Radial groove—posterior surface of humerus where radial n. and profunda brachii vv. are located
- Deltoid tuberosity—provides attachment of deltoid
- Capitulum—rounded distal end of the lateral humerus that provides articulation with the radius (head)
- Trochlea—pulley-shaped distal end of the medial humerus that provides articulation with the ulna (trochlear notch)
- Olecranon fossa—depression on posterior humerus superior to trochlea; provides area for olecranon process of ulna to occupy during extension of antebrachium
- Coronoid fossa—depression on anterior humerus superior to trochlea that provides area for coronoid process to occupy during flexion of antebrachium
- Radial fossa—depression on anterior humerus superior to capitulum that provides area for radius (head) during flexion of antebrachium
- Supracondylar ridges—sharp elevations of bone on lateral portion of distal humerus that provides attachment of brachial fascia
- Medial epicondyle—elevation at distal part of medial supracondylar ridge; ulnar n. and superior ulnar collateral vv. are located posterior
- Lateral epicondyle—elevation at distal part of lateral supracondylar ridge

#### Radius

Articulates with capitulum of humerus superiorly

Articulates with scaphoid and lunate inferiorly

Is shorter than ulna

Is frequently fractured at distal end (Colles fracture)

Has 3 major anatomical structures:

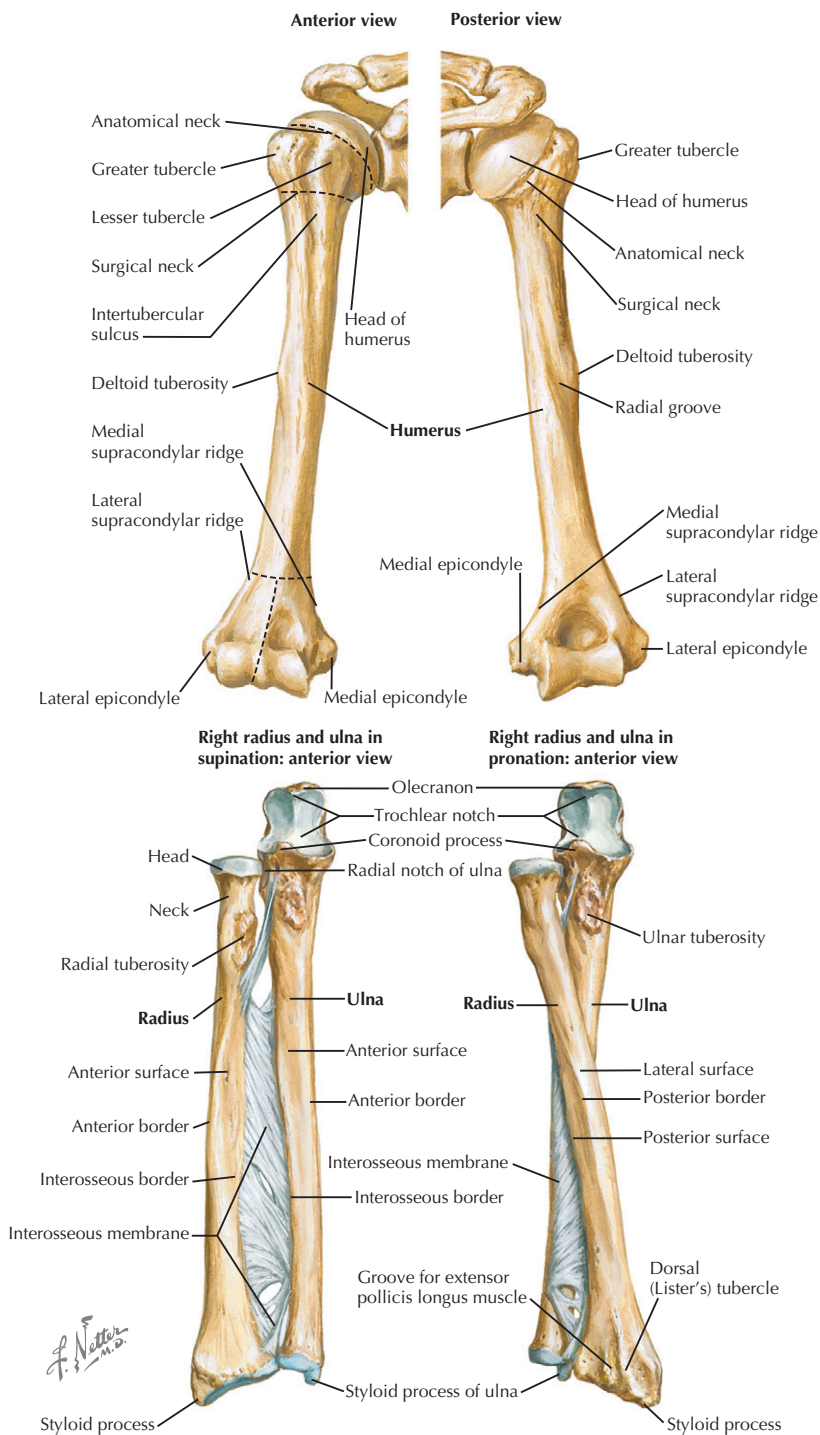
- Head—proximal end of radius; provides articulation with capitulum of humerus
- Radial tuberosity—provides attachment for biceps brachii
- Styloid process—provides attachment for brachioradialis

#### Ulna

Articulates with trochlea of humerus

Has 6 major anatomical structures:

- Olecranon—proximal portion of ulna; provides attachment for triceps brachii
- Coronoid process—provides attachment for brachialis
- Trochlear notch—depression for articulation with trochlea of humerus
- Radial notch—depressed area for radius (head)
- Head—distal portion of ulna
- Styloid process—projects posterior and medial



# Osteology

## UPPER LIMB *CONTINUED*

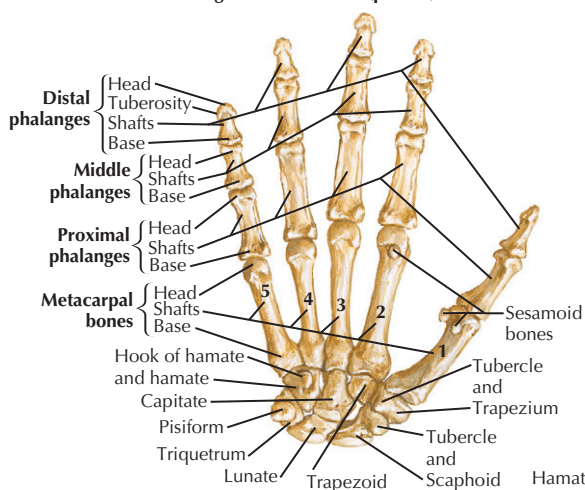
### CARPAL BONES

Is described in 2 rows:

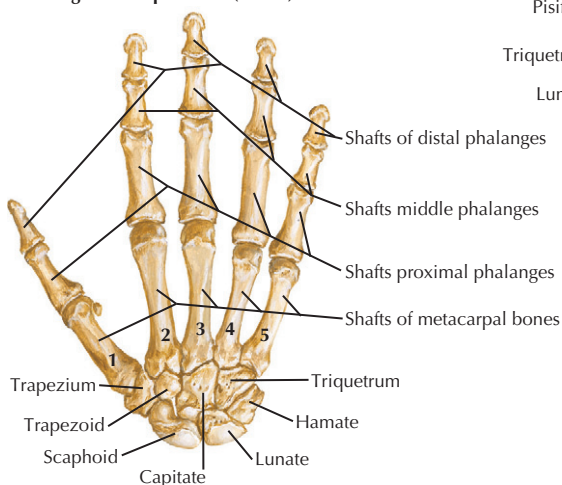
Proximal row (lateral to medial)

- Scaphoid—frequently fractured
  - Lunate
  - Triquetrum
  - Pisiform
- Distal row (lateral to medial)
- Trapezium
  - Trapezoid
  - Capitate
  - Hamate

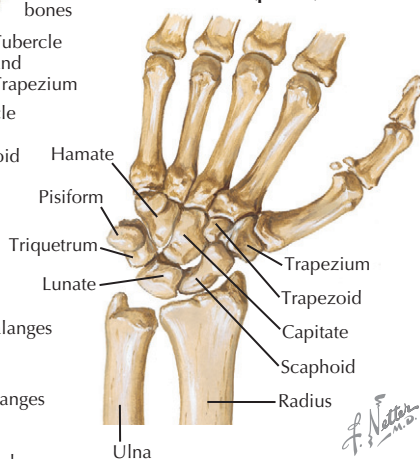
Right hand: anterior (palmar) view



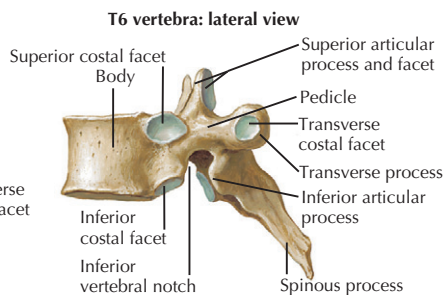
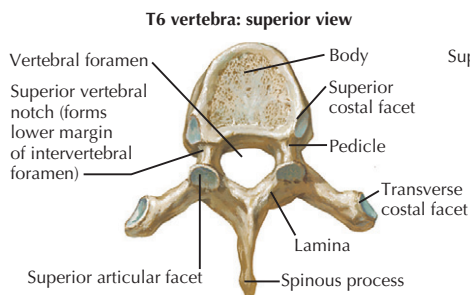
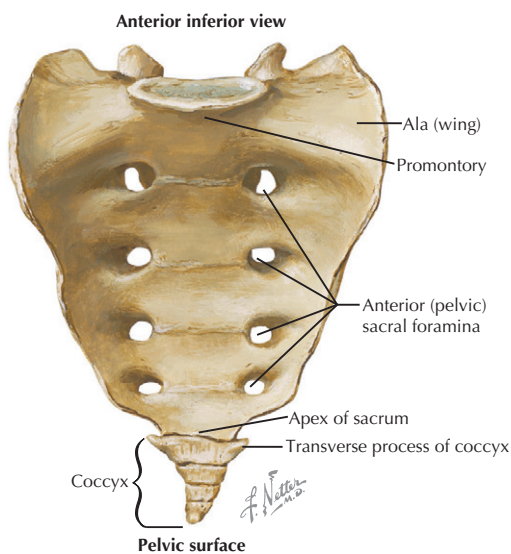
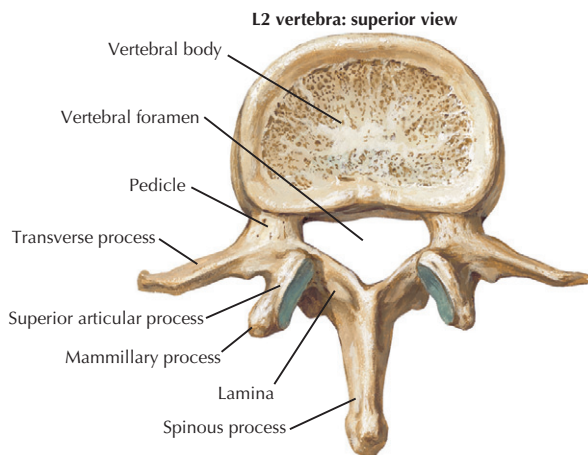
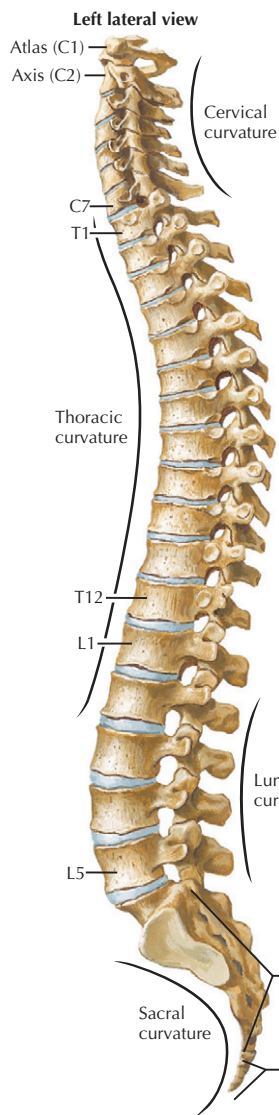
Right hand: posterior (dorsal) view



Anterior (palmar) view



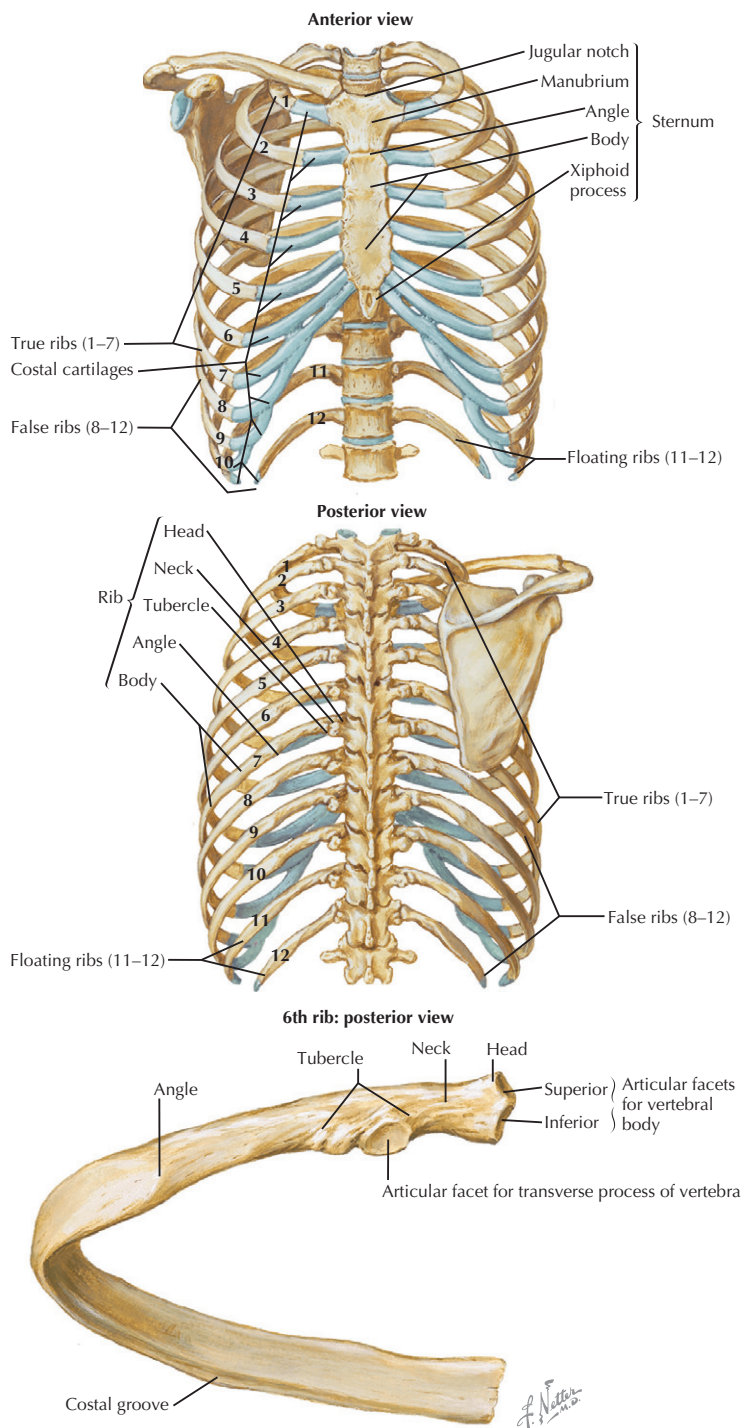
BONES OF BACK	
Overview	
Vertebral column includes 33 vertebrae <ul style="list-style-type: none"> <li>• 7 Cervical</li> <li>• 12 Thoracic</li> <li>• 5 Lumbar</li> <li>• 5 Sacrum</li> <li>• 4 Coccygeal</li> </ul> Functions include: <ul style="list-style-type: none"> <li>• Support of body weight</li> <li>• Posture</li> <li>• Locomotion</li> <li>• Protection of spinal cord and spinal roots</li> </ul> Important vertebral levels <ul style="list-style-type: none"> <li>• T2—Suprasternal</li> <li>• T3—Spine of scapula</li> <li>• T7—Inferior angle of the scapula</li> <li>• T9—Xiphoid process</li> <li>• L1—Transpyloric plane</li> <li>• L3—Subcostal plane</li> <li>• L4—Supracristal plane</li> </ul>	
Parts of the Typical Vertebra	
Body Vertebral arch <ul style="list-style-type: none"> <li>• Pedicles</li> <li>• Superior and inferior articulating facet</li> <li>• Transverse process</li> <li>• Lamina</li> <li>• Spinous process</li> <li>• Superior and inferior vertebral notch</li> <li>• Intervertebral foramen</li> </ul>	
Vertebra	Characteristics
Cervical	Covered in osteology chapter
Thoracic	12 in number Costal facets on body and transverse process Long spinous processes Heart-shaped body
Lumbar	5 in number Thick body No costal facets
Sacrum	5 in number Fused Four pairs of sacral foramina Sacral hiatus
Coccyx	3–5 in number (typically 4) Fused Mainly provides muscle and ligament attachment





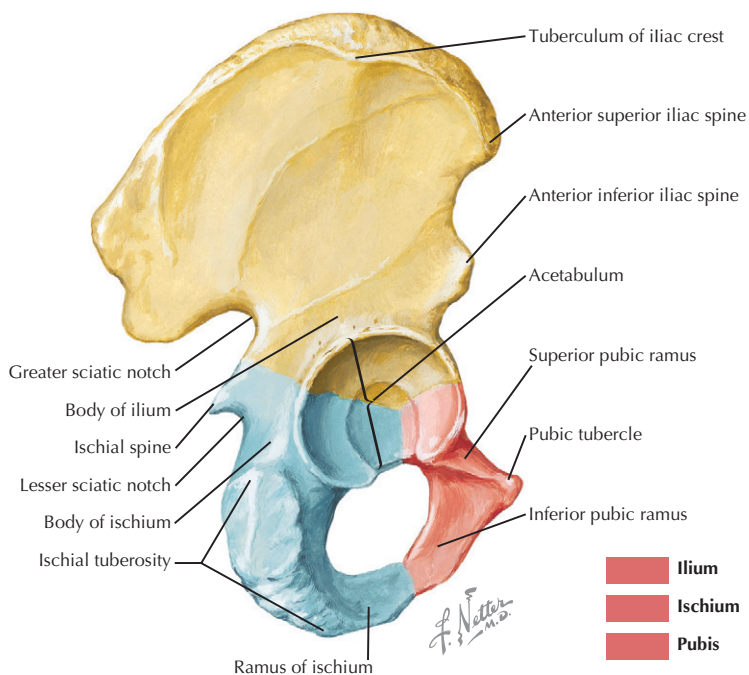
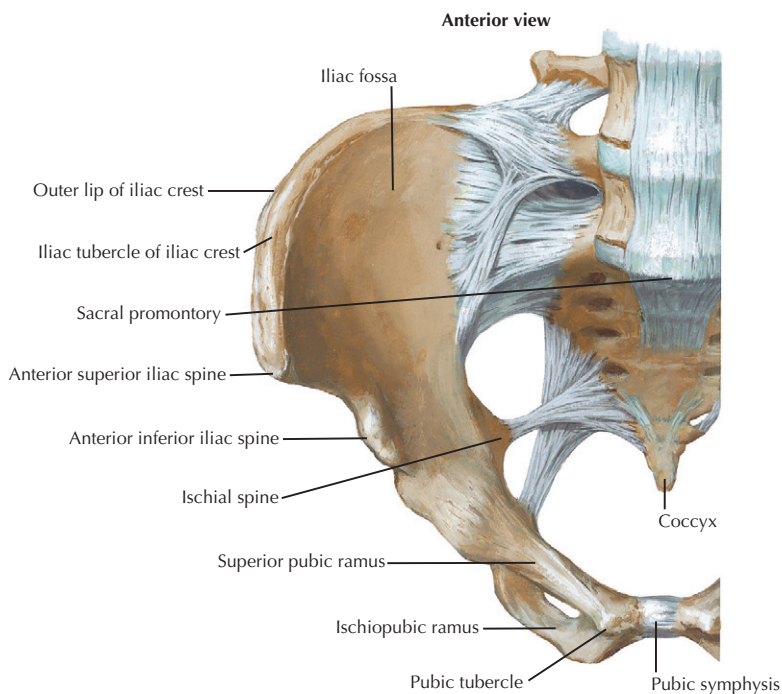
## THORAX

BONES OF THORAX	
Overview	
<p>Landmarks Include:</p> <ul style="list-style-type: none"> <li>• Midclavicular</li> <li>• Midaxillary</li> <li>• Scapular</li> <li>• Suprasternal notch</li> <li>• Sternal angle</li> </ul> <p>The thoracic apertures:</p> <ul style="list-style-type: none"> <li>• Superior thoracic aperture <ul style="list-style-type: none"> <li>• Boundaries <ul style="list-style-type: none"> <li>• Body of T1 vertebra</li> <li>• 1st pair of ribs and cartilages</li> <li>• Manubrium (superior portion)</li> </ul> </li> <li>• Major contents <ul style="list-style-type: none"> <li>• Trachea</li> <li>• Esophagus</li> <li>• Great vessels and nerves</li> <li>• Lungs</li> </ul> </li> </ul> </li> <li>• Inferior thoracic aperture <ul style="list-style-type: none"> <li>• Boundaries <ul style="list-style-type: none"> <li>• Body of T12 vertebra</li> <li>• 12th pair of ribs</li> <li>• Costal margins</li> <li>• Xiphoid process</li> </ul> </li> </ul> </li> </ul>	
Sternum	
Parts	Characteristics
Manubrium	<p>Superior part of sternum            Quadrangular in shape            Superior border is known as jugular notch or suprasternal notch (vertebral level T2)            Articulates with:</p> <ul style="list-style-type: none"> <li>• Clavicle</li> <li>• 1st costal cartilage</li> <li>• 2nd costal cartilage</li> <li>• Body of Sternum</li> </ul>
Body	<p>Longest part of sternum            Articulates with 2nd through 7th rib            Articulates with:</p> <ul style="list-style-type: none"> <li>• Manubrium at manubriosternal joint (vertebral level T4)</li> <li>• Xiphoid process (vertebral level T9)</li> </ul>
Xiphoid process	Cartilaginous process, which ossifies
Ribs	
Type	Characteristics
Vertebrosteral	<p>Ribs 1–7            Known as “true ribs” because they articulate with the sternum through the costal cartilage            Articulate with the sternum through the costal cartilage</p>
Vertebrochondral	<p>Ribs 8–10            Known as “false ribs” because they do not possess a direct articulation to the sternum            These ribs articulate to a common cartilaginous connection to the sternum            Ribs 11–12</p>
Vertebral	<p>Most commonly known as “floating ribs”            They are “false ribs” because they do not possess a direct articulation to the sternum            Do not articulate with the sternum and end in the posterior abdominal wall</p>



## ABDOMEN

BONES OF ABDOMEN	
Overview	
<p>Formed by 3 structures:</p> <ul style="list-style-type: none"> <li>• Sacrum</li> <li>• Coccyx</li> <li>• Os coxae (hip bone) <ul style="list-style-type: none"> <li>• Ilium</li> <li>• Ischium</li> <li>• Pubis</li> </ul> </li> </ul> <p>Inferior portion of abdomen that provides connection of the spinal column to the femur</p> <p>Functions include:</p> <ul style="list-style-type: none"> <li>• Bear weight</li> <li>• Locomotion</li> <li>• Posture</li> <li>• Provide muscle and ligament attachment</li> </ul> <p>Has a pelvic cavity that is divided by the pelvic brim into:</p> <ul style="list-style-type: none"> <li>• False pelvis—superior to pelvic brim and contains inferior portion of abdominal cavity</li> <li>• True pelvis—inferior to pelvic brim and contains the: <ul style="list-style-type: none"> <li>• Bladder</li> <li>• Terminal colon and rectum</li> <li>• Some reproductive and accessory reproductive organs: <ul style="list-style-type: none"> <li>• Prostate</li> <li>• Seminal vesicles</li> <li>• Vas deferens</li> <li>• Uterus with uterine tubes and ovary</li> <li>• Vagina</li> </ul> </li> </ul> </li> </ul>	
Os Coxae	
Parts	Characteristics
Ilium	<p>Largest part of the hip bone</p> <p>Comprised of the:</p> <ul style="list-style-type: none"> <li>• Ala (wing)</li> <li>• Body</li> </ul> <p>Provides muscle and ligament attachments</p>
Ischium	<p>Most posterior and inferior portion of the hip bone</p> <p>Comprised of the:</p> <ul style="list-style-type: none"> <li>• Body</li> <li>• Superior ischial ramus</li> <li>• Inferior Ischial ramus</li> </ul> <p>Provides muscle and ligament attachments</p>
Pubis	<p>Most anterior portion of the hip bone</p> <p>Comprised of the:</p> <ul style="list-style-type: none"> <li>• Superior pubic ramus</li> <li>• Inferior pubic ramus</li> </ul> <p>Provides muscle and ligament attachment</p> <p>Right and left hip bones articulate at the pubic symphysis</p>



## UPPER LIMB

MUSCLES OF PECTORAL REGION				
Muscle	Origin	Insertion	Actions	Nerve Supply
Pectoralis major	Clavicular head <ul style="list-style-type: none"> <li>• Clavicle (medial half)</li> </ul> Sternocostal head <ul style="list-style-type: none"> <li>• Anterior surface of sternum</li> <li>• Upper 6 costal cartilages</li> </ul>	Lateral lip of intertubercular groove	Flexion of humerus Adduction of humerus Medial rotation of humerus	Medial pectoral n. Lateral pectoral n.
Pectoralis minor	Ribs 3–5	Coracoid process	Protraction of scapula Aids in stabilization of scapula	Medial pectoral n.
Serratus anterior	Ribs 1–8	Medial border of scapula	Protraction of scapula Rotates the scapula Aids in stabilization of the scapula	Long thoracic n.
Subclavius	1st rib and 1st costal cartilage	Inferior surface of clavicle	Aids in depressing lateral part of clavicle	N. to subclavius

Perforating branches of internal thoracic artery and anterior cutaneous branches of intercostal nerves

Pectoralis major muscle

Cephalic vein

Latissimus dorsi muscle

Long thoracic nerve and lateral thoracic artery

Thoracoacromial artery

Cephalic vein

Pectoralis major muscle (cut)

Intercostorachial nerve

Long thoracic nerve and lateral thoracic artery

Pectoralis minor muscle

Lateral cutaneous branches of intercostal nerves and posterior intercostal arteries

Lateral thoracic artery

Lateral cutaneous branches of intercostal nerves and posterior intercostal arteries

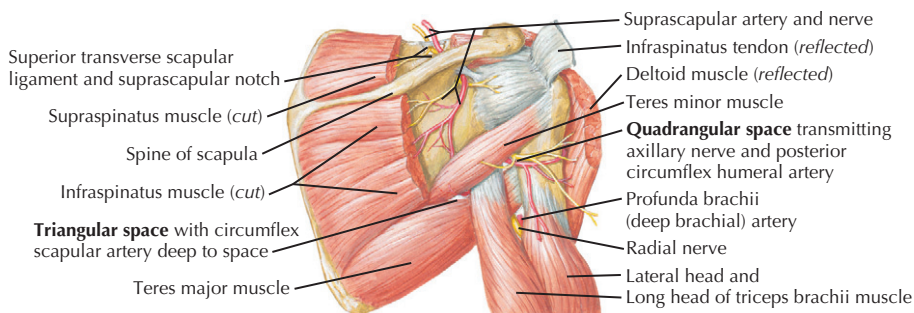
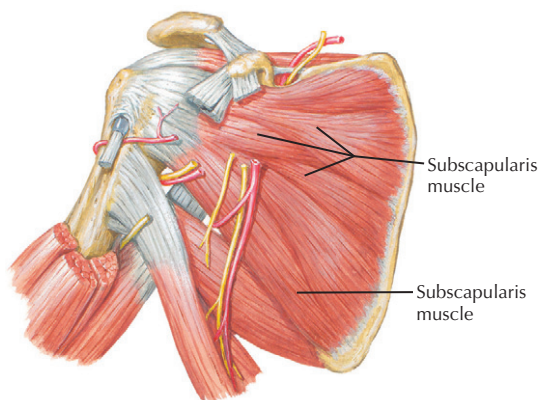
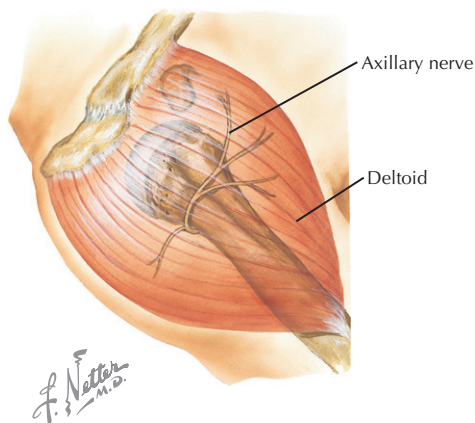
Serratus anterior muscle

Long thoracic nerve

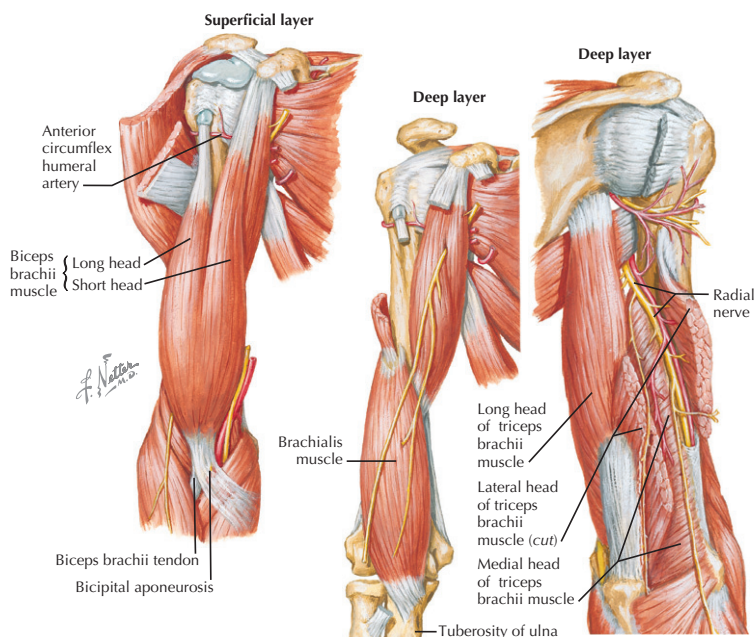
*J. Netter M.D.*  
*C. Machado M.D.*

MUSCLES OF SHOULDER				
Muscle	Origin	Insertion	Actions	Nerve Supply
Deltoid	<ul style="list-style-type: none"> <li>• Lateral 1/3rd of clavicle</li> <li>• Acromion</li> <li>• Spine of scapula</li> </ul>	Deltoid tuberosity	<ul style="list-style-type: none"> <li>• Abduction of humerus</li> <li>• Anterior fibers aid in flexion of humerus and medial rotation of humerus</li> <li>• Posterior fibers aid in extension of humerus and lateral rotation of humerus</li> </ul>	Axillary n.
Teres major	Inferior angle of posterior scapula	Medial lip of intertubercular groove	<ul style="list-style-type: none"> <li>• Adduction of humerus</li> <li>• Medial rotation of humerus</li> </ul>	Lower subscapular n.
Supraspinatus	Supraspinous fossa	Greater tubercle (superior facet)	<ul style="list-style-type: none"> <li>• Abduction of humerus (1st 10–15 degrees)</li> <li>• Aids in holding humerus in glenoid cavity</li> </ul>	Suprascapular n.
Infraspinatus	Infraspinous fossa	Greater tubercle (middle facet)	<ul style="list-style-type: none"> <li>• Lateral rotation of humerus</li> <li>• Aids in holding humerus in glenoid cavity</li> <li>• Aids in adduction</li> </ul>	Suprascapular n.
Teres minor	Lateral border of scapula	Greater tubercle (inferior facet)	<ul style="list-style-type: none"> <li>• Lateral rotation of humerus</li> <li>• Aids in holding humerus in</li> <li>• Aids in adduction</li> </ul>	Axillary n.
Subscapularis	Subscapular fossa	Lesser tubercle	<ul style="list-style-type: none"> <li>• Medial rotation of humerus</li> <li>• Aids in holding humerus in glenoid cavity</li> <li>• Aids in adduction</li> </ul>	Upper subscapular n. Lower subscapular n.

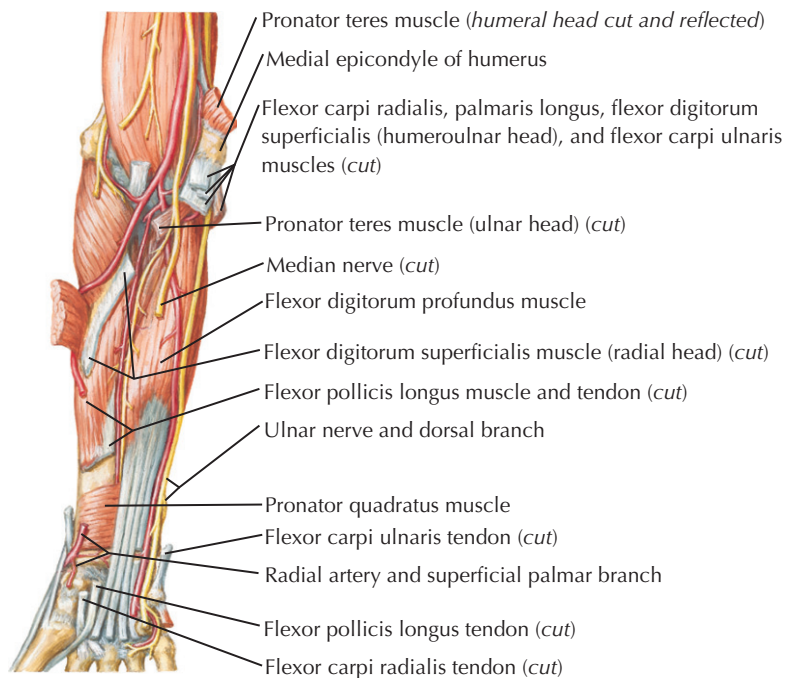
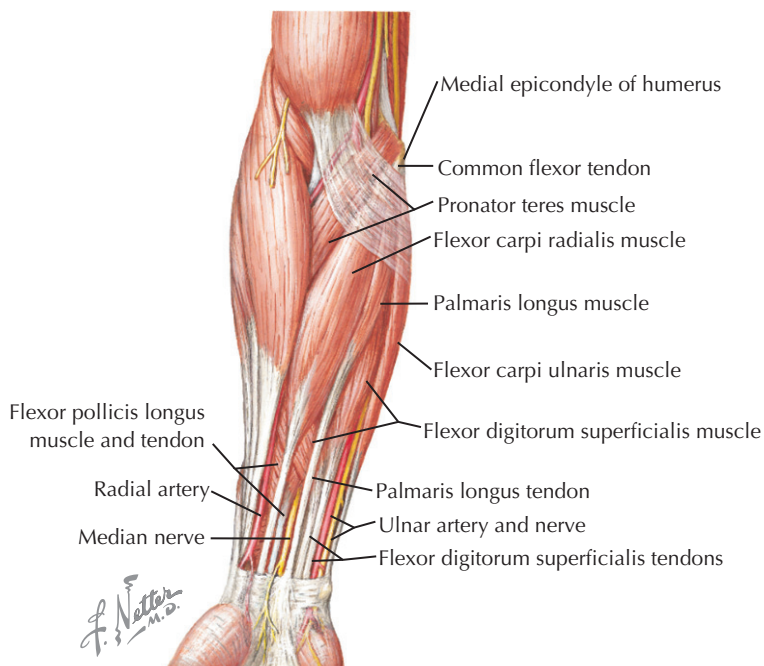




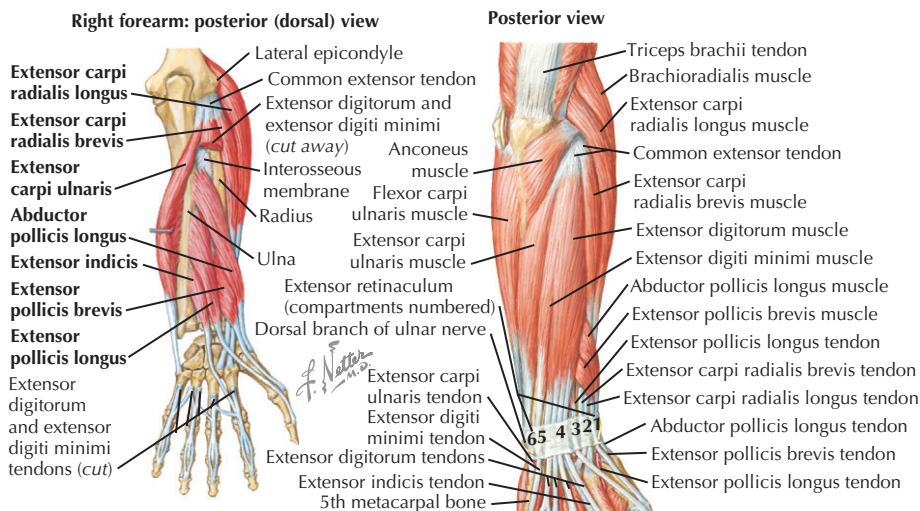
MUSCLES OF BRACHIUM				
Muscle	Origin	Insertion	Actions	Nerve Supply
Biceps brachii	Long head • Supraglenoid tubercle Short head • Coracoid process	Radial tuberosity of radius	<ul style="list-style-type: none"> <li>• Flexion of antebrachium</li> <li>• Supination of antebrachium</li> <li>• Aids in flexion of brachium</li> </ul>	Musculocutaneous n.
Brachialis	Anterior surface of distal portion of humerus	<ul style="list-style-type: none"> <li>• Coronoid process of ulna</li> <li>• Ulnar tuberosity</li> </ul>	Flexion of antebrachium	Musculocutaneous n.
Coracobrachialis	Coracoid process	Middle third of medial humerus	<ul style="list-style-type: none"> <li>• Flexion of brachium</li> <li>• Adduction of brachium</li> </ul>	Musculocutaneous n.
Triceps brachii	Long head • Infraglenoid tubercle Lateral head • Superior to radial groove Medial head • Inferior to radial groove	Olecranon of ulna	<ul style="list-style-type: none"> <li>• Extension of antebrachium</li> <li>• Long head aids in slight adduction of brachium</li> </ul>	Radial n.
Anconeus	Lateral epicondyle of humerus	Olecranon of ulna	Extension of antebrachium	Radial n.



MUSCLES OF FLEXOR SURFACE OF ANTEBRACHIUM				
Superficial Group				
Muscle	Origin	Insertion	Actions	Nerve Supply
Pronator teres	Medial epicondyle of humerus Coronoid process of ulna	Lateral surface of radius (middle portion)	Pronation of antebrachium Weak flexion of antebrachium	Median n.
Flexor carpi radialis	Medial epicondyle of humerus	Base of 2nd and 3rd metacarpal	Flexion of antebrachium (little) Flexion of hand Abduction of hand	Median n.
Palmaris longus	Medial epicondyle of humerus	Palmar aponeurosis	Weak flexion of antebrachium Flexion of hand	Median n.
Flexor carpi ulnaris	Medial epicondyle of humerus Posterior ulna	Pisiform Hamate (hook) Base of 5th metacarpal	Weak flexion of antebrachium Flexion of hand Adduction of hand	Ulnar n.
Intermediate Group				
Flexor digitorum superficialis	Medial epicondyle of humerus Coronoid process Radius (oblique line)	Middle phalanges of digits 2–5	Weak flexion of antebrachium Flexion of hand Flexion of proximal interphalangeal joints of digits 2–5	Median n.
Deep Group				
Flexor digitorum profundus	Anterior and medial surface of ulna Interosseous membrane	Base of distal phalanges of digits 2–5	Flexion of hand Flexion of distal interphalangeal joints of digits 2–5	Anterior interosseous of the median n. (lateral half) Ulnar n. (medial half)
Flexor pollicis longus	Anterior surface of radius Interosseous membrane	Base of distal phalanx of thumb	Flexion of thumb	Anterior interosseous of the median n.
Pronator quadratus	Anterior surface of distal ulna	Anterior surface of distal radius	Pronation of antebrachium	Anterior interosseous of the median n.

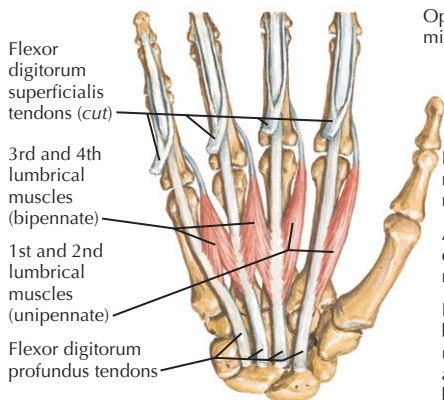


MUSCLES OF EXTENSOR SURFACE OF ANTEBRACHIUM				
Muscle	Origin	Insertion	Actions	Nerve Supply
Brachioradialis	Lateral supracondylar ridge of humerus	Styloid process of distal radius	Flexion of antebrachium	Radial n.
Extensor carpi radialis longus	Lateral epicondyle of humerus	Base of 2nd metacarpal	Extension of wrist Abduction of wrist Weakly aids in flexion of forearm	Radial n.
Extensor carpi radialis brevis		Base of 3rd metacarpal	Extension of wrist Abduction of wrist Weakly aids in flexion of forearm	Deep radial n.
Extensor digitorum		Joins extensor expansion of digits 2–5	Extension of wrist Extension of digits 2–5	
Extensor digiti minimi		Joins extensor expansion of the extensor digitorum tendon of proximal phalanx 5th digit	Extension of 5th digit (little finger)	Posterior interosseous n.
Extensor carpi ulnaris	Lateral epicondyle of humerus Posterior ulna	Base of 5th metacarpal	Extension of wrist Adduction of hand	Posterior interosseous n.
Supinator	Lateral epicondyle of humerus Ulna	Radial tubercle Oblique line of radius	Supination	Deep radial n.
Extensor indicis	Posterior ulna Interosseous membrane	Joins extensor expansion of the extensor digitorum of index finger (2nd digit)	Extension of index finger (2nd digit)	Posterior interosseous n.
Abductor pollicis longus	Lateral posterior ulna Interosseous membrane Posterior radius	Base of 1st metacarpal (lateral side)	Abducts 1st digit Adducts wrist	Posterior interosseous n.
Extensor pollicis longus	Posterior ulna Interosseous membrane	Base of distal phalanx of 1st digit	Extension of distal phalanx of 1st digit Helps extend and abduct wrist	Posterior interosseous n.
Extensor pollicis brevis	Posterior ulna Interosseous membrane Posterior radius	Base of proximal phalanx of 1st digit	Extend and abduct 1st digit	Posterior interosseous n.

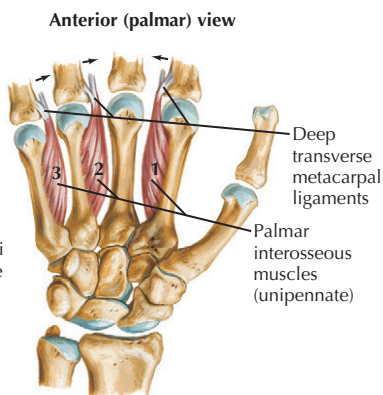
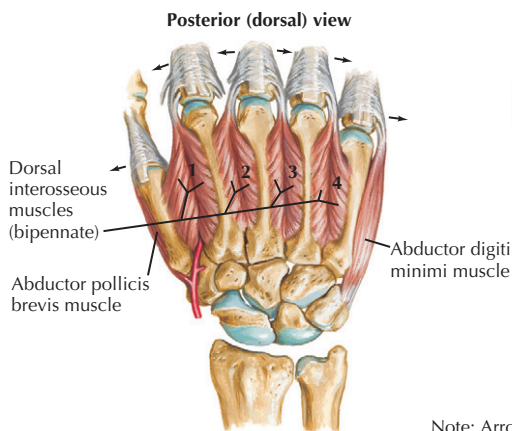
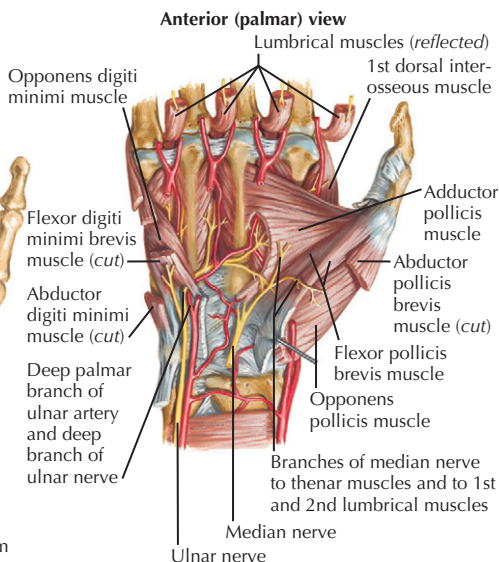


MUSCLES OF THE HAND				
Muscle	Origin	Insertion	Actions	Nerve Supply
Abductor pollicis brevis	Flexor retinaculum Tubercle of scaphoid Tubercle of trapezium	Base of proximal phalanx of thumb (radial side)	Abduction of thumb Aids in opposition of thumb Aids in extension of thumb	Recurrent branch of median n.
Opponens pollicis	Flexor retinaculum Tubercle of trapezium	1st metacarpal (radial side)	Opposition of thumb	Recurrent branch of median n.
Flexor pollicis brevis		Base of proximal phalanx of thumb (radial side)	Flexion of thumb at metacarpophalangeal joint	
Abductor digiti minimi	Flexor retinaculum Pisiform	Base of proximal phalanx of 5th digit	Abduction of 5th digit (little finger)	Deep branch of ulnar n.
Opponens digiti minimi	Flexor retinaculum Hamulus of hamate	Shaft of 5th metacarpal	Flexion of 5th metacarpal Laterally rotate 5th metacarpal	
Flexor digiti minimi brevis	Flexor retinaculum Hamulus of hamate	Base of proximal phalanx of 5th digit	Flexion of metacarpophalangeal joint of 5th digit	
Palmaris brevis	Flexor retinaculum Palmar aponeurosis	Skin of palm	Raises hypothenar eminence	Superficial branch of ulnar n.
Adductor pollicis • Oblique head • Transverse head	• Capitate, 2nd & 3rd metacarpals • Shaft of 3rd metacarpal	Base of proximal phalanx of thumb	Adduction of thumb	Deep branch of ulnar n.
Lumbrical • 1st and 2nd are unipennate • 3rd & 4th are bipennate	1st and 2nd—Radial side of flexor digitorum profundus tendons of index and middle fingers 3rd—Side of flexor digitorum profundus tendons of middle and ring fingers 4th—Side of flexor digitorum profundus tendons of ring and little fingers	Extensor expansion	Flexion of proximal phalanx Extension of middle and distal phalanges	• Recurrent branch of median n. for 1st & 2nd lumbricals • Deep branch of ulnar n. for 3rd & 4th lumbricals
Dorsal interosseous (bipennate)	1st—Radial side of 2nd metacarpal; ulnar side of 1st metacarpal 2nd—Radial side of 3rd metacarpal; ulnar side of 2nd metacarpal 3rd—Radial side of 4th metacarpal; ulnar side of 3rd metacarpal 4th—Radial side of 5th metacarpal; ulnar side of 4th metacarpal	1st—Radial side of 2nd proximal phalanx; extensor expansion 2nd—Radial side of 3rd proximal phalanx; extensor expansion 3rd—Ulnar side of 3rd proximal phalanx; extensor expansion 4th—Ulnar side of 4th proximal phalanx; extensor expansion	Abduction of fingers from the middle finger Aid in flexion of metacarpophalangeal joint Aid in extension of interphalangeal joints	Deep branch of ulnar n.
Palmar interosseous (unipennate)	1st—Ulnar side of 2nd metacarpal 2nd—Radial side of 4th metacarpal 3rd—Radial side of 5th metacarpal	1st—Ulnar side of proximal phalanx of 2nd digit 2nd—Radial side of proximal phalanx of 4th digit 3rd—Radial side of proximal phalanx of 5th digit	Adduction of fingers toward the middle finger Aid in flexion of metacarpophalangeal joint Aid in extension of interphalangeal joints	

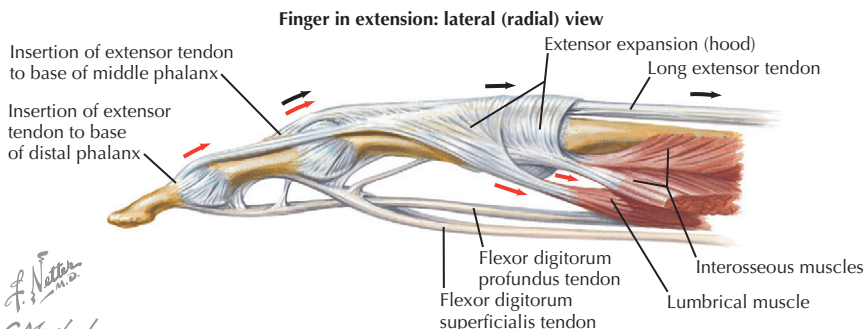




**Note:** Flexor digitorum superficialis and profundus tendons encased in synovial sheaths are bound to phalanges by fibrous digital sheaths made up of alternating strong annular (A) and weaker cruciform (C) parts (pulleys).



**Note:** Arrows indicate action of muscles.

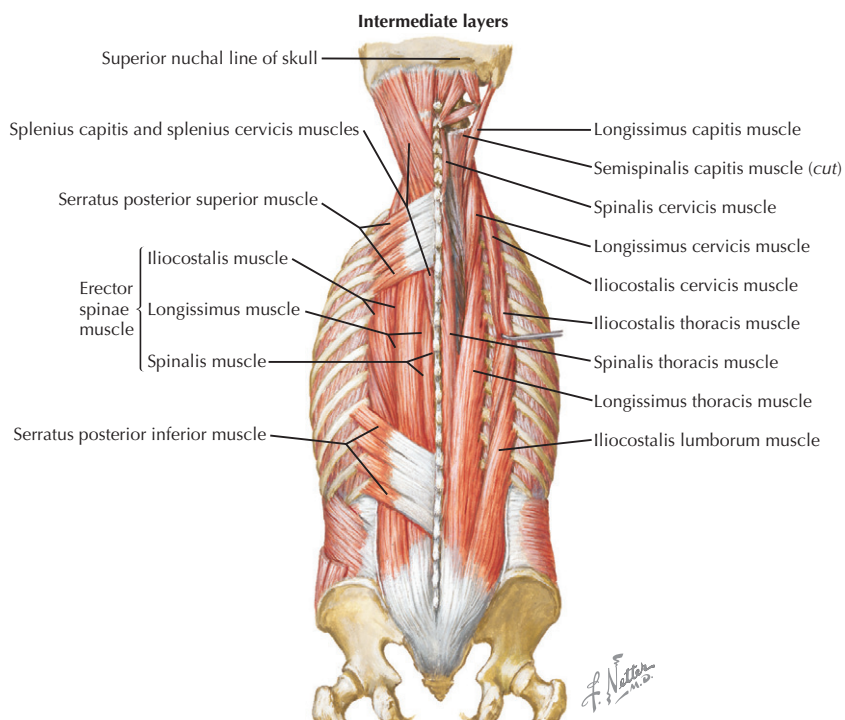
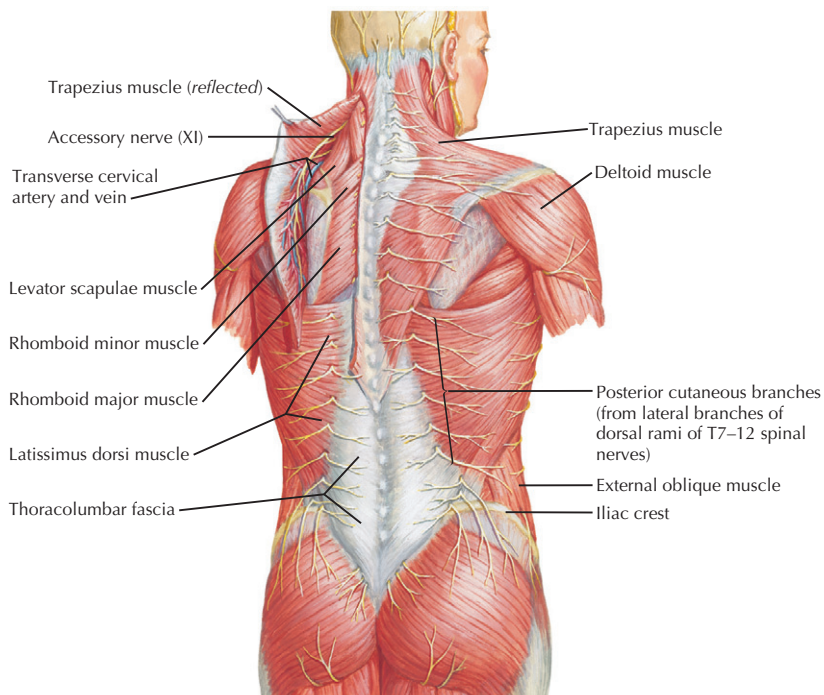


**Note:** Black arrows indicate pull of long extensor tendon; red arrows indicate pull of interosseous and lumbrical muscles.

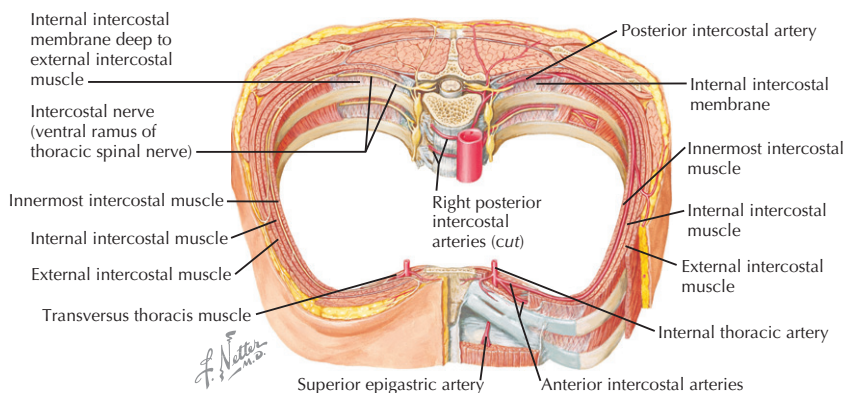
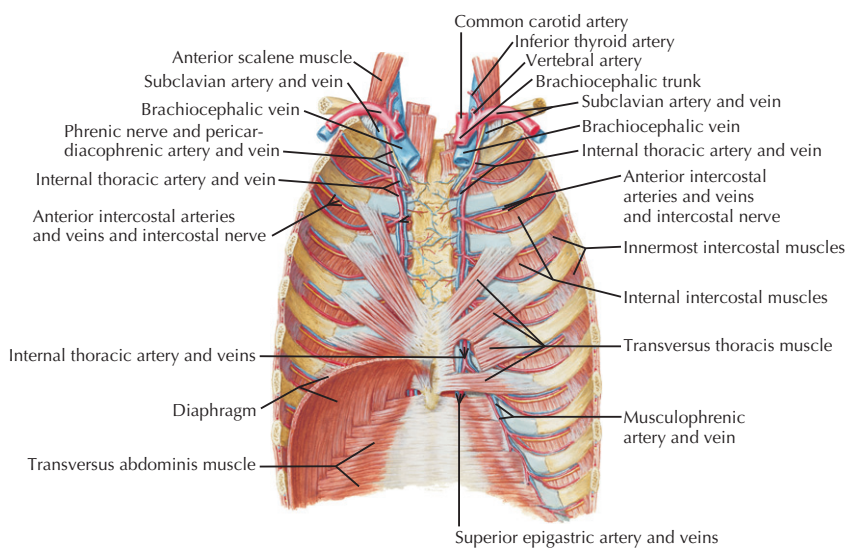
*F. Netter M.D.*  
*C. Machado M.D.*

OVERVIEW OF MUSCLES OF BACK		
Extrinsic	Superficial	Connect upper limb to trunk
	Intermediate	Superficial respiratory muscles such as serratus posterior
Intrinsic	Superficial	Splenius muscles
	Intermediate	<ul style="list-style-type: none"> <li>• Spinalis <ul style="list-style-type: none"> <li>• S. thoracis</li> <li>• S. cervicis</li> <li>• S. capitis</li> </ul> </li> <li>• Longissimus <ul style="list-style-type: none"> <li>• L. thoracis</li> <li>• L. cervicis</li> <li>• L. capitis</li> </ul> </li> <li>• Iliocostalis <ul style="list-style-type: none"> <li>• I. lumborum</li> <li>• I. thoracis</li> <li>• I. cervicis</li> </ul> </li> </ul>
	Deep (transversospinal)	<ul style="list-style-type: none"> <li>• Semispinalis <ul style="list-style-type: none"> <li>• S. thoracis</li> <li>• S. cervicis</li> <li>• S. capitis</li> </ul> </li> <li>• Multifidus</li> <li>• Rotatore (long and short)</li> </ul>
Others	<ul style="list-style-type: none"> <li>• Interspinales</li> <li>• Intertansversarii</li> </ul>	

MAJOR EXTRINSIC MUSCLES OF THE BACK				
Muscle	Origin	Insertion	Actions	Nerve Supply
Trapezius	External occipital protuberance, ligamentum nuchae, spinous processes of C7-T12	Lateral 1/3 of clavicle, acromion, and spine of scapula	Elevate pectoral girdle Retract pectoral girdle Depress pectoral girdle Rotate scapula	Spinal accessory n.
Latissimus dorsi	Spinous processes of T7–12, thoracolumbar fascia, iliac crest, inferior 3–4 ribs	Floor of intertubercular groove	Extend humerus Adduct humerus Medial rotate humerus	Thoracodorsal n.
Levator scapulae	Transverse processes of C1–4	Superior angle of scapula	Elevates scapula	Dorsal scapular n.
Rhomboid major	Spinous processes of T2–5	Medial border of scapula below the spine of the scapula	Retracts scapula Helps rotate scapula	Dorsal scapular n.
Rhomboid minor	Ligamentum nuchae, spinous processes of C7-T1	Medial border at the level of the spine of the scapula	Retracts scapula Helps rotate scapula	Dorsal scapular n.



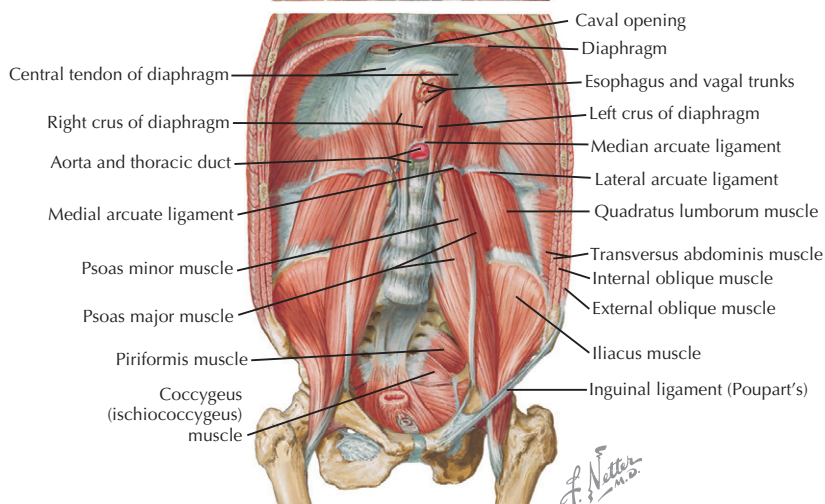
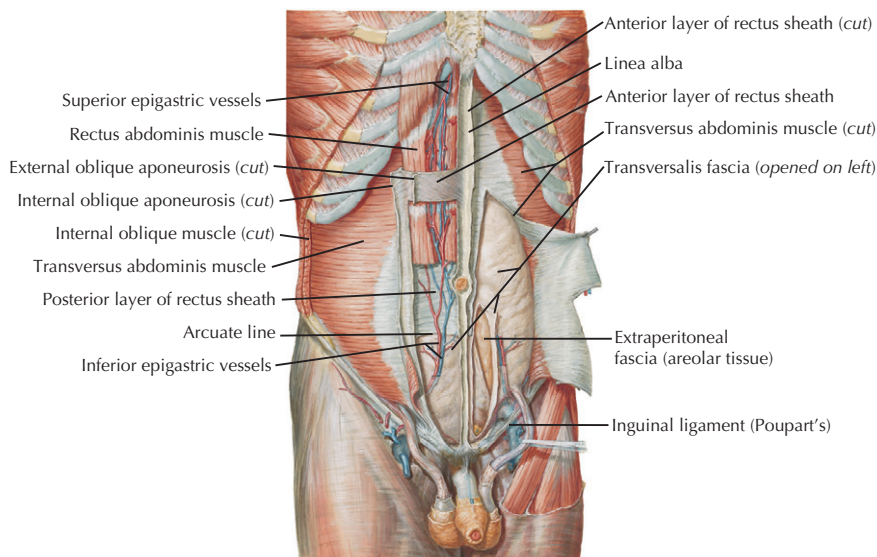
Muscle	Origin	Insertion	Actions	Nerve Supply
External intercostal	Inferior border of ribs	Upper border of ribs	Extend from tubercles to angles of ribs and aid in respiration by elevating ribs for inspiration	Intercostal n. in intercostal space
Internal intercostal	Inferior border of ribs	Upper border of ribs	Extend from sternum to cartilages and aid in respiration by depressing ribs for exhalation	Intercostal n. in intercostal space
Transversus thoracis	Posterior body of sternum and xiphoid	Inferior border of costal cartilages of ribs 2–6	Depresses ribs	Intercostal n. in intercostal space
Innermost intercostal	Inferior border of ribs	Upper border of ribs	Aid in respiration by depressing ribs for exhalation	Intercostal n. in intercostal space
Subcostal	Near angle of rib in lower thorax	2 or 3 ribs inferior	Helps raise ribs	Intercostal n. in intercostal space



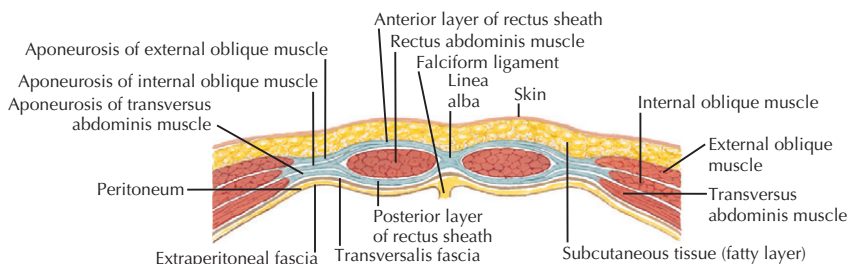
## ABDOMEN

Muscle	Origin	Insertion	Actions	Nerve Supply
External oblique	Ribs 5–12	Muscular <ul style="list-style-type: none"> <li>• Anterior half of iliac crest</li> </ul> Aponeurotic <ul style="list-style-type: none"> <li>• Xiphoid process</li> <li>• Linea alba</li> <li>• Pubic symphysis, crest and tubercle</li> <li>• Anterior superior iliac spine</li> </ul>	Compresses abdomen Flexes abdomen Rotates trunk to contralateral side	Ventral rami of T7–T12
Internal oblique	Thoracolumbar fascia, anterior 2/3 of Iliac crest, lateral 2/3 of Inguinal ligament	Muscular <ul style="list-style-type: none"> <li>• Ribs 10–12</li> </ul> Aponeurotic <ul style="list-style-type: none"> <li>• Above arcuate line—Splits to form rectus sheath <ul style="list-style-type: none"> <li>• Anterior rectus sheath</li> <li>• Posterior rectus sheath</li> </ul> </li> <li>• Below arcuate line <ul style="list-style-type: none"> <li>• Forms conjoint tendon</li> <li>• Anterior rectus sheath</li> </ul> </li> </ul>	Compresses abdomen Flexes abdomen Rotates trunk to ipsilateral side	Ventral rami of T7–L1
Transversus abdominis	Thoracolumbar fascia, anterior 2/3 of Iliac crest, lateral 1/3 of inguinal ligament, lower 6 costal cartilages	Aponeurotic <ul style="list-style-type: none"> <li>• Above arcuate line <ul style="list-style-type: none"> <li>• Forms posterior rectus sheath</li> </ul> </li> <li>• Below arcuate line <ul style="list-style-type: none"> <li>• Forms conjoint tendon</li> <li>• Anterior rectus sheath</li> </ul> </li> </ul>	Compresses abdomen	Ventral rami of T7–L1
Rectus abdominis	Pubic symphysis, crest and tubercle	Costal cartilages of ribs 5, 6, and 7	Compresses abdomen Flexes abdomen	Ventral rami of T7–T12
Diaphragm	Sternal portion <ul style="list-style-type: none"> <li>• Xiphoid process</li> </ul> Costal portion <ul style="list-style-type: none"> <li>• Costal cartilages and ribs 7–12</li> </ul> Lumbar portion <ul style="list-style-type: none"> <li>• Lateral arcuate ligament</li> <li>• Medial arcuate ligament</li> <li>• Crura <ul style="list-style-type: none"> <li>• Right crus—L1–3</li> <li>• Left crus—L1 and 2</li> </ul> </li> </ul>	Central tendon	Contraction causes central tendon to depress, creating a negative pressure in the thoracic cavity, thus causing inhalation	Phrenic n.
Psoas major	Transverse processes of L1–5 Sides of bodies of T12–L5	Lesser trochanter of femur	Flexes femur Aids in flexing spine Aids in lateral flexion	Ventral rami of L2 and L3
Iliacus	Iliac fossa	Lesser trochanter of femur	Flexes femur	Femoral n.
Quadratus lumborum	Iliac crest	12th rib Transverse processes of L1–4	Lateral flexion	Ventral rami of T12–L4





### Section above arcuate line



Aponeurosis of internal oblique muscle splits to form anterior and posterior layers of rectus sheath. Aponeurosis of external oblique muscle joins anterior layer of sheath; aponeurosis of transversus abdominis muscle joins posterior layer. Anterior and posterior layers of rectus sheath unite medially to form linea alba.



## PLEURAL CAVITY

There are 2 pleural cavities

The cavity is composed of a 2-layered pleural sac that secretes a thin layer of serous fluid

- Visceral layer—lines the lung and fissures
- Parietal layer—lines the wall of the cavity
  - Costal—lines the cavity along the ribs
  - Mediastinal—lines the cavity along the mediastinum
  - Diaphragmatic—lines the cavity along the diaphragm
  - Cervical (cupula)—lines the cavity forming a dome in the ribs opposite the apex of the lung

Pleural reflections—Abrupt lines where the parietal pleura folds back or changes direction

- Vertebral (posterior)—where costal pleura is continuous with the mediastinal pleura at the vertebral column
- Costal (inferior)—where costal pleura is continuous with diaphragmatic pleura
- Sternal (anterior)—where costal pleura is continuous with the mediastinal pleura posterior to sternum

Boundaries

- Anterior midline—6th rib (right) 4th rib (left)
- Midclavicular line—8th rib
- Midaxillary line—10th rib
- Scapular line—12th rib

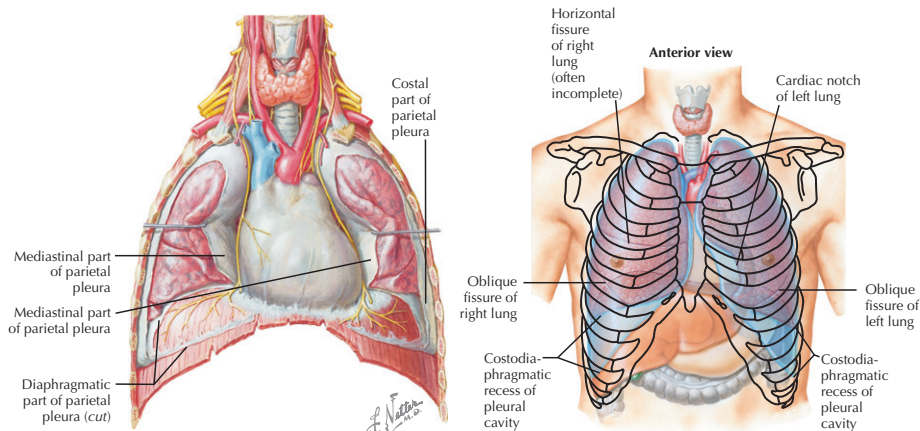
Inferior border of lungs in quiet respiration

- Anterior midline—6th rib (right) 4th rib (left)
- Midclavicular line—6th rib
- Midaxillary line—8th rib
- Scapular line—10th rib

Pleural recesses—potential spaces in the pleural cavity where parts of the parietal pleura contact one another during quiet respiration

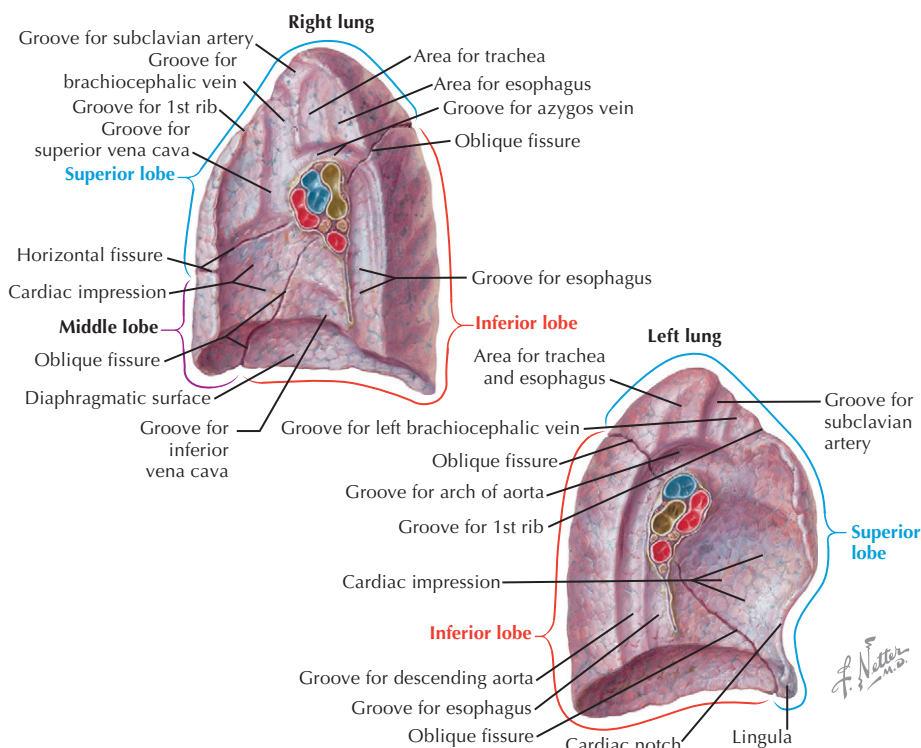
- Costomediastinal—potential space where costal and mediastinal pleurae come together
- Costodiaphragmatic—potential space where costal and diaphragmatic pleurae come together

Pulmonary ligament—a fold created where the mediastinal pleura at the root of the lung come together and extend inferiorly



## LUNGS

Surface anatomy	<ul style="list-style-type: none"> <li>• Apex—extends 1 inch into neck</li> <li>• Base—concave area that is located on the convexity of the diaphragm</li> <li>• Costal—large convex area that conforms to the thoracic cavity</li> <li>• Mediastinal—area in contact with the mediastinal pleura</li> <li>• Hilus—area where the structures that make the root of the lung enter and exit</li> </ul>
Lobes	<ul style="list-style-type: none"> <li>• Right lung                             <ul style="list-style-type: none"> <li>• Superior</li> <li>• Middle</li> <li>• Inferior</li> </ul> </li> <li>• Left lung                             <ul style="list-style-type: none"> <li>• Superior</li> <li>• Inferior</li> </ul> </li> </ul>
Air conduction system	<ul style="list-style-type: none"> <li>• Primary bronchus—travels to lung</li> <li>• Right bronchus—more vertical, wider in diameter, shorter</li> <li>• Left bronchus—less vertical, narrower in diameter, longer</li> <li>• Secondary bronchus—travels to lobes</li> <li>• Tertiary bronchus—travels to bronchopulmonary segment</li> </ul>
Fissures	<ul style="list-style-type: none"> <li>• Oblique                             <ul style="list-style-type: none"> <li>• Right lung—separates superior and middle lobes from inferior lobe</li> <li>• Left lung—separates superior and inferior lobes</li> </ul> </li> <li>• Horizontal—between superior and middle lobes of right lung beginning at oblique fissure and paralleling the 4th rib anteriorly</li> </ul>
Borders	<ul style="list-style-type: none"> <li>• Anterior</li> <li>• Posterior</li> <li>• Inferior</li> </ul>
Structures located on the root of the lung	<ul style="list-style-type: none"> <li>• Pulmonary vv.</li> <li>• Bronchus</li> <li>• Bronchial vv.</li> <li>• Pulmonary plexus</li> <li>• Lymphatics</li> </ul>

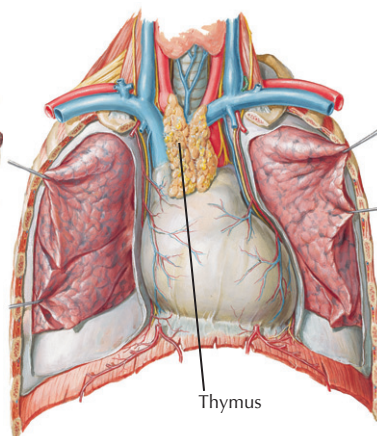
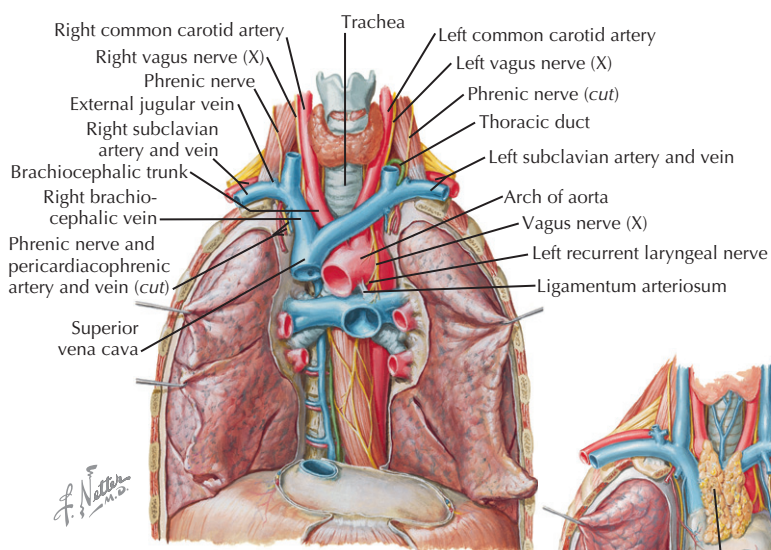


**MEDIASTINUM**

Region in the middle of the thorax between the two pleural sacs

Subdivided into superior and inferior

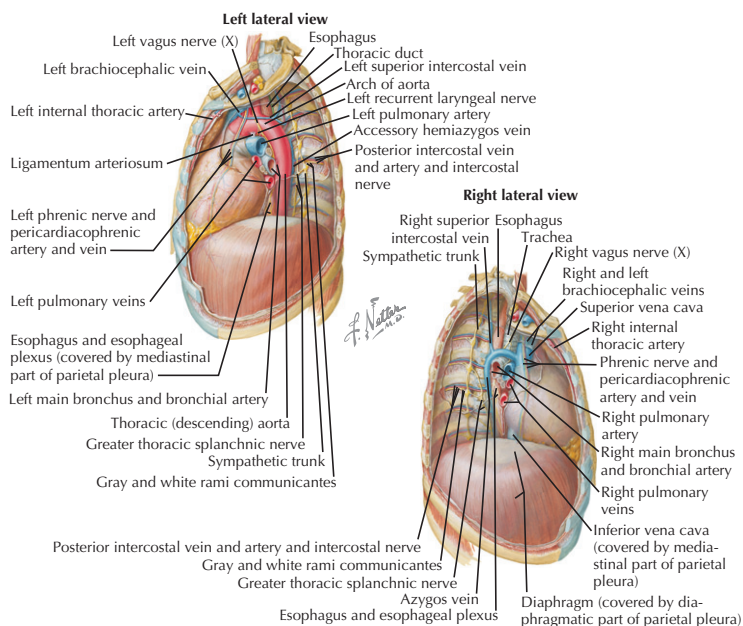
SUPERIOR MEDIASTINUM	
Plane of 1st rib to horizontal plane at T4	
Major Contents	
Vessels	<ul style="list-style-type: none"> <li>• Superior vena cava</li> <li>• Brachiocephalic veins</li> <li>• Arch of the aorta: brachiocephalic artery, left common carotid artery, left subclavian artery</li> <li>• Thoracic duct</li> </ul>
Nerves	<ul style="list-style-type: none"> <li>• Phrenic nerve</li> <li>• Vagus nerve</li> <li>• Left recurrent laryngeal nerve</li> <li>• Plexus: <ul style="list-style-type: none"> <li>• Cardiac plexus branches (P &amp; S branches)</li> <li>• Pulmonary plexus branches (P &amp; S branches)</li> </ul> </li> </ul>
Viscera	<ul style="list-style-type: none"> <li>• Esophagus</li> <li>• Trachea</li> <li>• Thymus (remnants)</li> </ul>



# Contents of the Thorax

## MEDIASTINUM CONTINUED

INFERIOR MEDIASTINUM	
Anterior Mediastinum	
Borders	<ul style="list-style-type: none"> <li>• Lower border of superior mediastinum to diaphragm (T9)</li> <li>• Body of sternum and transversus thoracis to fibrous pericardium</li> </ul>
Contents	<ul style="list-style-type: none"> <li>• No major structures</li> <li>• Remnants of the thymus</li> <li>• Lymph nodes</li> </ul>
Middle Mediastinum	
Borders	<ul style="list-style-type: none"> <li>• Lower border of superior mediastinum to diaphragm (T9/T10)</li> <li>• Anterior and posterior borders are the fibrous pericardium</li> </ul>
Contents	<ul style="list-style-type: none"> <li>• Heart and pericardium</li> <li>• Vessels (roots of the great vessels):               <ul style="list-style-type: none"> <li>• Ascending aorta</li> <li>• Pulmonary trunk (with origins of pulmonary arteries)</li> <li>• Superior vena cava</li> <li>• Pericardiophrenic vv.</li> </ul> </li> </ul>
Nerves	<ul style="list-style-type: none"> <li>• Phrenic</li> </ul>
Posterior Mediastinum	
Borders	<ul style="list-style-type: none"> <li>• Lower border of superior mediastinum to diaphragm (T12)</li> <li>• Fibrous pericardium to vertebral column</li> </ul>
Contents	<ul style="list-style-type: none"> <li>• Esophagus</li> <li>• Thoracic aorta (and branches):               <ul style="list-style-type: none"> <li>• Posterior intercostal arteries</li> <li>• Bronchial arteries</li> <li>• Esophageal arteries</li> </ul> </li> <li>• Azygos venous system</li> <li>• Hemiazygos and accessory hemiazygos</li> <li>• Thoracic duct</li> <li>• Cisterna chyli</li> <li>• Vagus</li> <li>• Esophageal plexus</li> <li>• Sympathetic trunk               <ul style="list-style-type: none"> <li>• Greater splanchnic nerve (T5–9)</li> <li>• Lesser splanchnic nerve (T10–11)</li> <li>• Least splanchnic nerve (T12)</li> </ul> </li> </ul>



# HEART

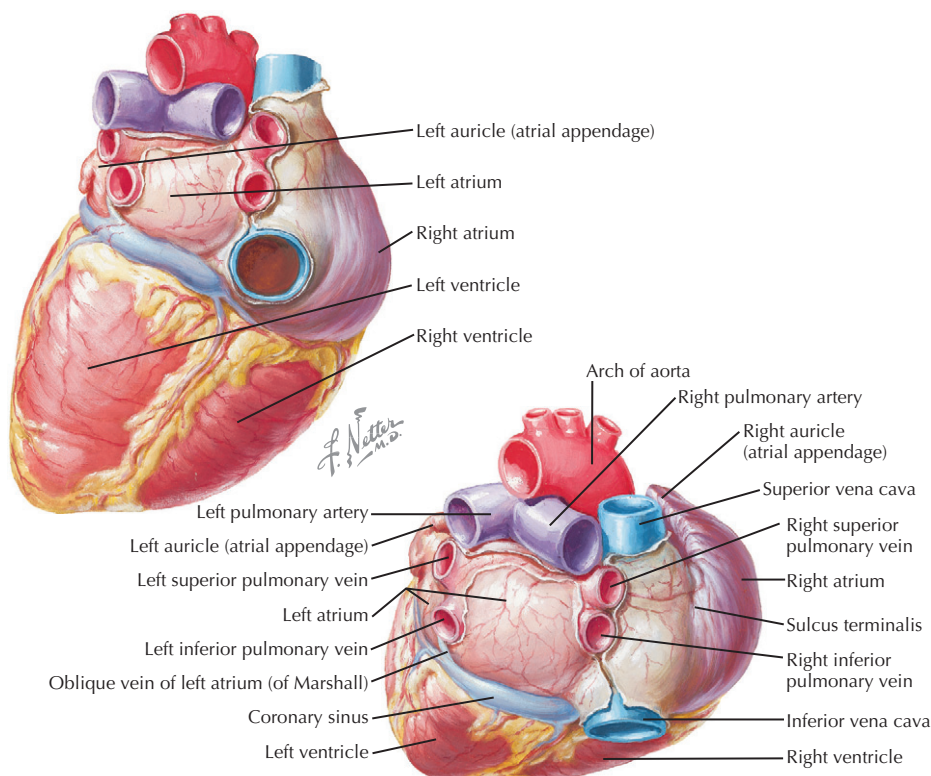
## PERICARDIUM

A double-walled fibroserous sac that encloses the heart and the roots of the great vessels  
Subdivided into:

- Fibrous pericardium—outer layer
- Serous pericardium—secretes serous fluid
  - Parietal pericardium—lines wall of pericardium
  - Visceral pericardium—lines the heart

## SURFACES OF THE HEART

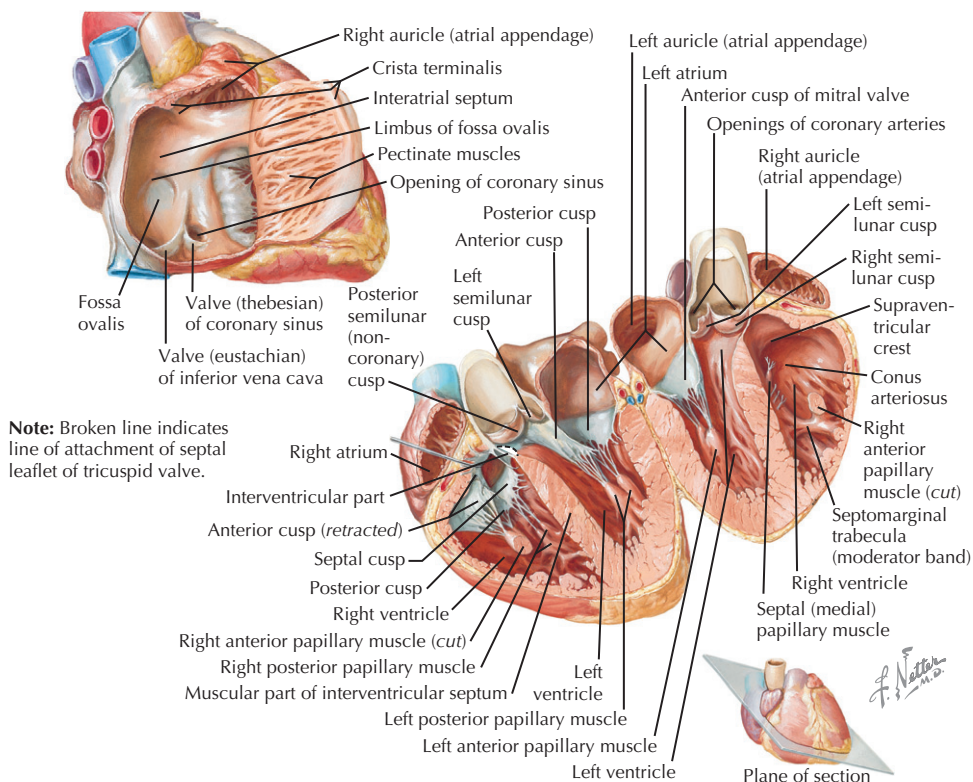
Inferior or diaphragmatic surface	<ul style="list-style-type: none"> <li>• Shape—concave</li> <li>• Position—lower border of T8, T9</li> <li>• Formed by—largely left ventricle, some right ventricle</li> </ul>
Posterior surface	<ul style="list-style-type: none"> <li>• Shape—quadrilateral</li> <li>• Position—opposite 5th–8th thoracic vertebrae</li> <li>• Formed by—largely left atrium, some right atrium</li> </ul>
Anterior or sternocostal surface	<ul style="list-style-type: none"> <li>• Shape—flattened</li> <li>• Position—posterior to sternum and costal cartilages 3–6</li> <li>• Formed by               <ul style="list-style-type: none"> <li>• Atrial region—largely right atrium and left auricle</li> <li>• Ventricular region—largely right ventricle, some left ventricle</li> </ul> </li> </ul>
Right surface	<ul style="list-style-type: none"> <li>• Shape—convex</li> <li>• Position—just lateral to the right border of the sternum</li> <li>• Formed by—right atrium</li> </ul>
Left surface	<ul style="list-style-type: none"> <li>• Shape—convex</li> <li>• Position—1/2 inch to left of manubriosternal junction to apex</li> <li>• Formed by—largely left ventricle, some left auricle</li> </ul>





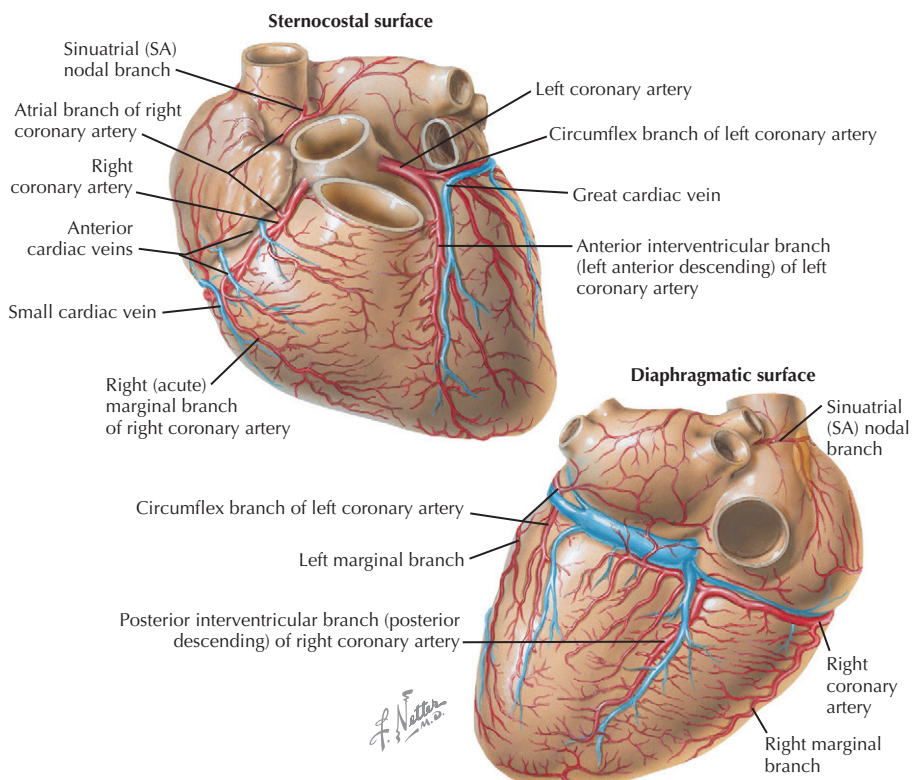
CHAMBERS OF THE HEART	
Right atrium	<ul style="list-style-type: none"> <li>• Pectinate muscle</li> <li>• Fossa ovalis</li> <li>• Coronary sinus opening</li> <li>• Superior and inferior vena cava opening</li> <li>• Valves of the coronary sinus and inferior vena cava</li> </ul>
Right ventricle	<ul style="list-style-type: none"> <li>• Tricuspid valve</li> <li>• Trabeculae carneae</li> <li>• Papillary muscles (anterior, posterior, and septal)</li> <li>• Chordae tendineae</li> <li>• Septomarginal trabeculae</li> <li>• Conus arteriosus (infundibulum)</li> </ul>
Left atrium	<ul style="list-style-type: none"> <li>• Pectinate muscle in the auricle</li> </ul>
Left ventricle	<ul style="list-style-type: none"> <li>• Bicuspid valve</li> <li>• Trabeculae carneae</li> <li>• Papillary muscles (anterior and posterior)</li> <li>• Chordae tendineae</li> <li>• Membranous part of the interventricular septum</li> </ul>

VALVES OF THE HEART
<p>Atrioventricular—close during systole to prevent the backflow of blood into the atrium</p> <ul style="list-style-type: none"> <li>• Tricuspid—between right atrium and right ventricle</li> <li>• Bicuspid (mitral)—between left atrium and left ventricle</li> </ul> <p>Semilunar—close during diastole to prevent the backflow of blood into the ventricles</p> <ul style="list-style-type: none"> <li>• Pulmonary—between pulmonary artery and right ventricle</li> <li>• Aortic—between aorta and left ventricle</li> </ul>





CORONARY CIRCULATION OF THE HEART	
Arterial supply	<ul style="list-style-type: none"> <li>• Right coronary                             <ul style="list-style-type: none"> <li>• Arises from the right aortic sinus</li> <li>• Major branches include:                                     <ul style="list-style-type: none"> <li>• Conus a.</li> <li>• Marginal</li> <li>• Sinus nodal a.</li> <li>• Posterior interventricular a.</li> <li>• Atrioventricular nodal a.</li> </ul> </li> </ul> </li> <li>• Left coronary                             <ul style="list-style-type: none"> <li>• Major branches include:                                     <ul style="list-style-type: none"> <li>• Anterior interventricular a.</li> <li>• Diagonal a.</li> <li>• Circumflex a.</li> <li>• Marginal a.</li> </ul> </li> </ul> </li> </ul>
Venous supply	<ul style="list-style-type: none"> <li>• Cardiac veins                             <ul style="list-style-type: none"> <li>• Coronary sinus                                     <ul style="list-style-type: none"> <li>• Great cardiac v.</li> <li>• Middle cardiac v.</li> <li>• Posterior vein of the left ventricle</li> <li>• Oblique vein of the left atrium</li> <li>• Small cardiac v.</li> </ul> </li> <li>• Anterior cardiac v.</li> </ul> </li> <li>• Venae cordis minimae</li> </ul>



# Contents of the Abdomen

## STOMACH

Part of the foregut

There are 4 anatomical parts of the stomach:

- Cardia—where esophagus enters the stomach
- Fundus—created by the superior portion of the greater curvature
- Body—primary central area
- Pylorus—inferior portion that continues to narrow until reaching the pyloric sphincter

The mucosal lining of the stomach are raised elevations known as *gastric rugae*

There are 2 major curvatures:

- Greater curvature—provides attachment for some remnants of the dorsal mesogastrium:
  - Gastrophrenic
  - Gastrosplenic
  - Greater omentum
- Lesser curvature—provides attachment for remnants of the ventral mesogastrium:
  - Lesser omentum
    - Hepatogastric portion (hepatoduodenal portion does not attach to the stomach)

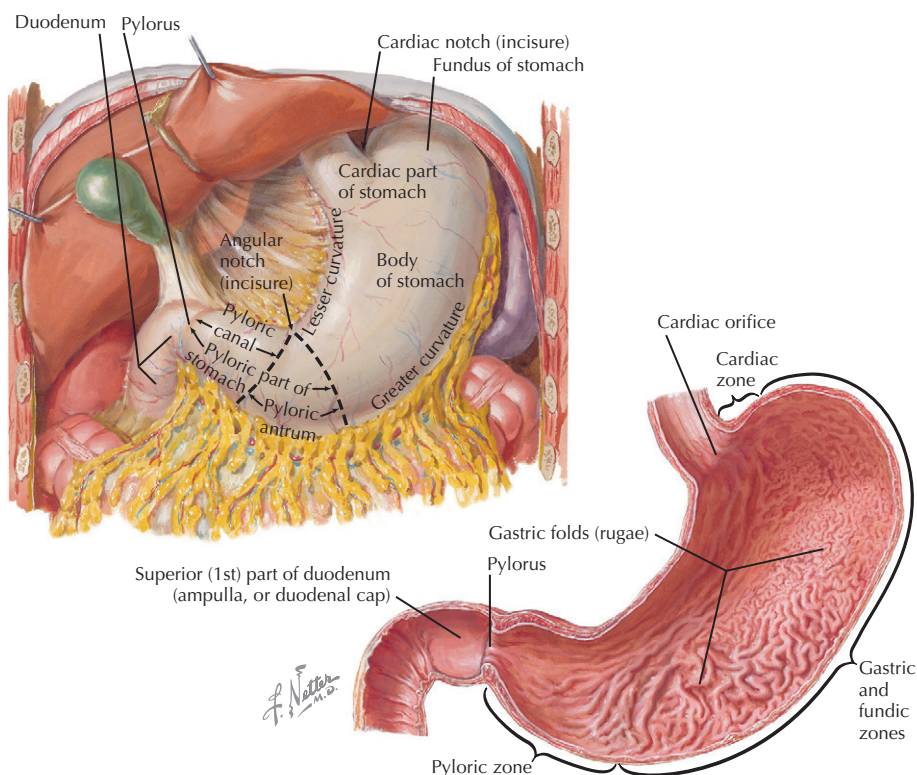
There are 2 sphincters associated with the stomach:

- Esophageal—not an anatomical sphincter
- Pyloric—has a thick muscular sphincter

Receives extensive autonomic nerve supply

Is supplied by branches of the celiac artery

Releases pepsin and hydrochloric acid to aid in digestion



## 22 Contents of the Abdomen

### DUODENUM

Is the first of the 3 parts of the small intestine:

- Duodenum
- Jejunum
- Ileum

Part of the foregut and midgut

There are 4 anatomical parts of the duodenum:

- 1st part—intraperitoneal, part of foregut
- 2nd part—retroperitoneal, part of foregut
  - Minor duodenal papilla—where accessory pancreatic duct (if present) drains
  - Major duodenal papilla—where pancreas, liver, and gallbladder drain
- 3rd part—retroperitoneal, part of midgut
- 4th part—retroperitoneal, part of midgut

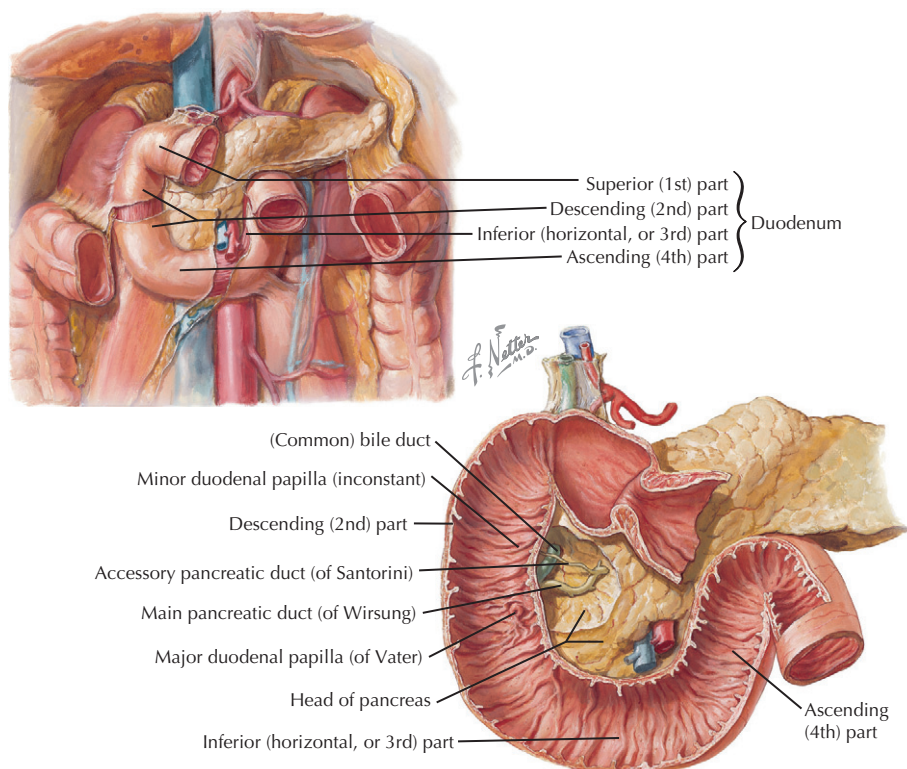
The mucosal lining of the duodenum are raised elevations known as *plicae circulares*

Receives extensive autonomic nerve supply

Is supplied by branches of the celiac and superior mesenteric arteries

Is the portion of the small intestine where the majority of chemical digestion occurs

A major histological feature is the presence of mucus-secreting glands, Brunner's glands



## Contents of the Abdomen

### JEJUNUM AND ILEUM

Are the final 2 parts of the small intestine:

- Duodenum
- Jejunum
- Ileum

Part of the midgut

Is intraperitoneal

Is suspended by the mesentery proper

The mucosal lining has raised elevations known as *plicae circulares*

Receives extensive autonomic nerve supply

Is supplied by branches of the superior mesenteric artery

#### JEJUNUM

Is about 7–8 feet in length

Has scattered lymphatic nodules and very few Brunner's glands

Has prominent *plicae circulares*

Vascular supply has large prominent arterial arcades terminating with long vasa recta

#### ILEUM

Is about 6–12 feet in length

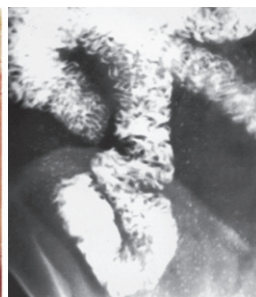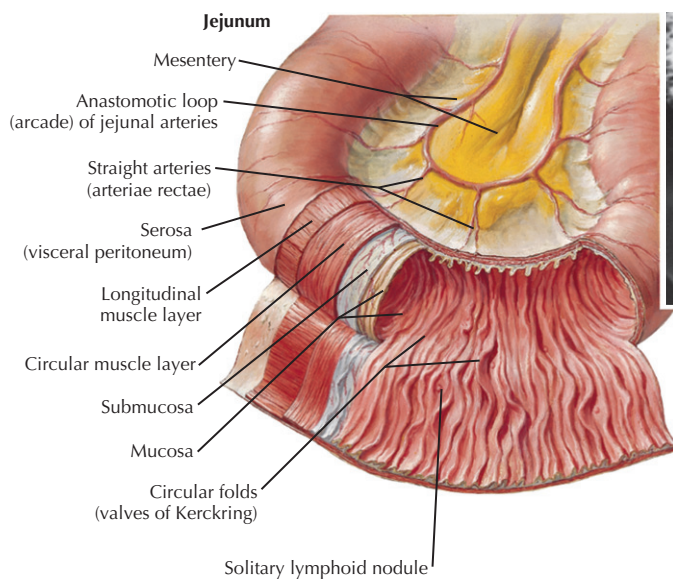
Ileum has extensive Peyer's patches (lymphatic nodules)

Has fewer *plicae circulares* than the jejunum

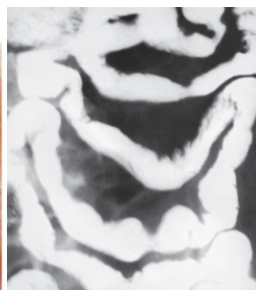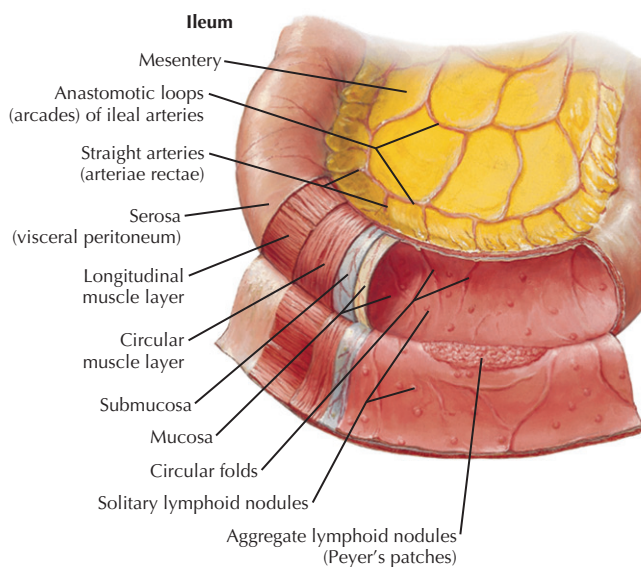
Vascular supply has large smaller layers of arterial arcades terminating with short, compact vasa recta

Ends in the large intestine at the ileocecal valve

Is the embryological connection to the umbilicus via the vitelline duct; a Meckel's diverticulum is a remnant of the duct in the adult

JEJUNUM AND ILEUM *CONTINUED*

Barium radiograph of jejunum



Barium radiograph of ileum

*F. Netter M.D.*



# Contents of the Abdomen

## LARGE INTESTINE

Is divided into:

- Cecum with appendix
- Ascending colon
- Transverse colon
- Descending colon
- Sigmoid colon
- Rectum

Has the following characteristic features:

- Taeniae coli—3 separate bands of longitudinal muscle
- Haustra—pouch-like appearance caused by the contraction of the taeniae coli
- Epiplonic appendages—small pouches of fat along the peritoneum

Part of the midgut and hindgut

Is intraperitoneal and retroperitoneal

The mucosal lining has raised elevations known as *plicae semilunares*

Receives extensive autonomic nerve supply

Is supplied by branches of the superior mesenteric and inferior mesenteric arteries

Major function is the absorption of water from the indigestible waste and expulsion from the body

## CECUM

Is intraperitoneal

Connects ileum to the large intestine at the ileocecal valve

Blind pouch

Appendix is a small (typically around 4 inches) blind tubular intraperitoneal structure connected to the cecum

## ASCENDING COLON

Is retroperitoneal

Begins at ileocecal valve and ascends

Makes a colic impression on the liver and makes a sharp turn to the left side of the body known as the right colic (hepatic) flexure before continuing as the transverse colon

## TRANSVERSE COLON

Is intraperitoneal, suspended by the transverse mesocolon

Longest portion of the large intestine

At the area of the spleen, makes a sharp turn to travel inferiorly, known as the left colic (splenic) flexure before continuing as the descending colon

## DESCENDING COLON

Is retroperitoneal

Descends until it ends at the sigmoid colon

Terminal portion of the descending colon is often called the iliac colon because it lies in the iliac fossa

Typically has a smaller diameter than the ascending colon



**LARGE INTESTINE** *CONTINUED***SIGMOID COLON**

Is intraperitoneal, suspended by the sigmoid mesocolon

Begins at the level of the pelvic brim

Travels toward the midline, where it ends at the rectum

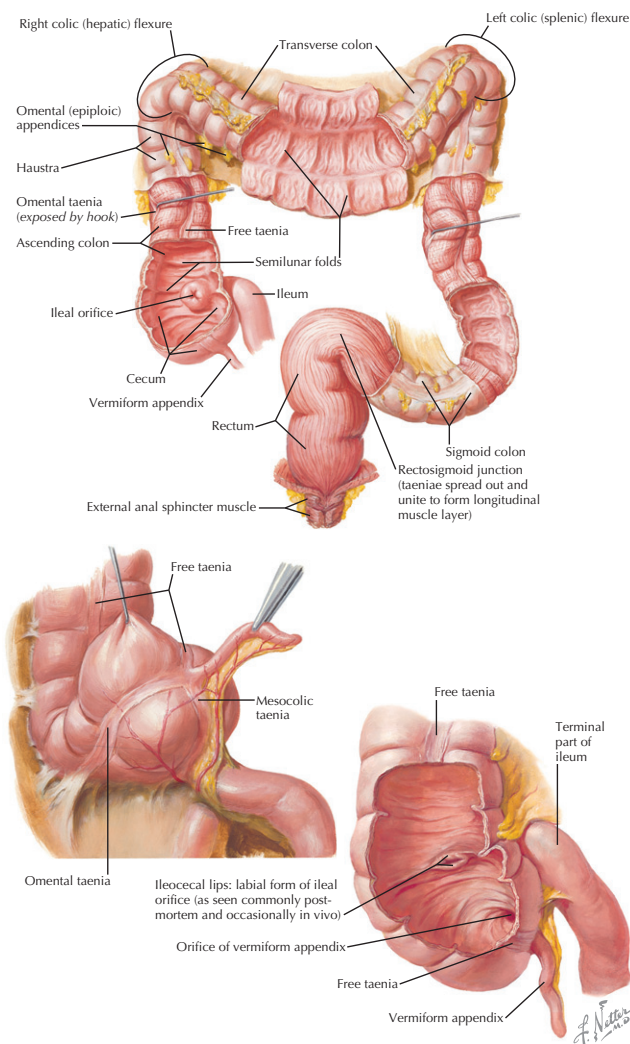
**RECTUM**

Begins as intraperitoneal, but is retroperitoneal until it passes through the pelvic floor

Is about 4–5 inches in length

Does not have taeniae coli as the separate bands merge to form a complete band of longitudinal muscle at the rectum

Ends at the anus



# Contents of the Abdomen

## LIVER

Large, multifunctional organ, including:

- Detoxification
- Glycogen storage
- Production of hormones
- Synthesis of plasma proteins
- Production of bile

Divided into 4 anatomical lobes:

- Right—largest lobe
- Caudate—located between fissure for the ligamentum venosum and the inferior vena cava
- Quadrate—located between fissure for the ligamentum teres hepatis (round ligament of the liver) and the gallbladder
- Left—flattened lobe

Is further subdivided into functional segments based on the vascular supply

Is completely covered by visceral peritoneum except an area where the liver connects with the diaphragm, known as the *bare area*

The porta hepatis is the central portion of the liver where the following structures enter and exit:

- Hepatic portal vein—provides 75% of the blood to the liver
- Proper hepatic artery—provides 25% of the blood to the liver
- Common bile duct

Is intraperitoneal

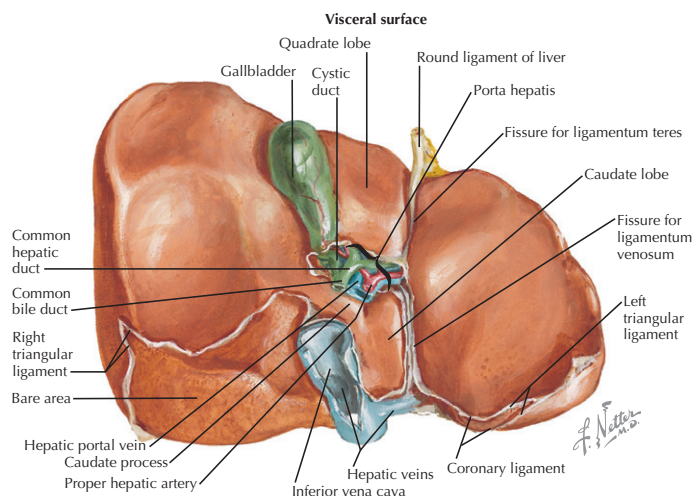
Is supplied by branches of the celiac artery

All remnants of the ventral mesentery attach to the liver:

- Falciform ligament
- Coronary ligament
- Triangular ligament
- Lesser omentum
  - Hepatogastric ligament
  - Hepatoduodenal ligament

The liver is subject to numerous pathologies, including:

- Hepatitis
- Cirrhosis
- Cancer



## 22 Contents of the Abdomen

### PANCREAS

The pancreas functions as 2 types of glands:

- Endocrine—Islets of Langerhans producing hormones
- Exocrine—Compound tubuloalveolar pancreatic acini producing digestive enzymes

Comprised of 4 major parts:

- Head—is located in the “C” or curve formed by the duodenum; is retroperitoneal
  - Uncinate process—an extension of the head crossed by the superior mesenteric vv.
- Neck—constricted portion of pancreas connecting the head to the body; is retroperitoneal
- Body—largest part of the pancreas separated from the stomach by the omental bursa, is retroperitoneal
- Tail—extends into the lienorenal ligament with the splenic vv. to the spleen

Is part of the foregut

Develops as 2 separate outgrowths from the 2nd part of the duodenum:

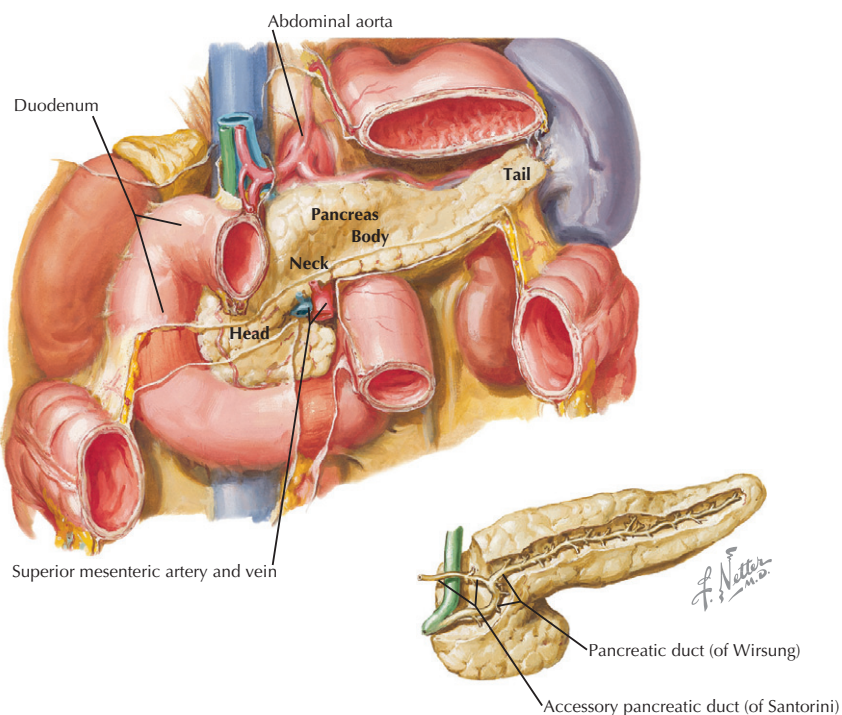
- Ventral pancreatic bud—an outgrowth of the hepatic bud
  - Develops into the head and neck of the pancreas
- Dorsal pancreatic bud—a direct outgrowth of the 2nd of the duodenum
  - Develops into the body and tail of the pancreas

Drains into the 2nd part of the duodenum

- Main pancreatic duct—drains into the major duodenal papilla by joining the common bile duct forming the hepatopancreatic ampulla
- Accessory pancreatic duct—drains into the minor duodenal papilla (if present and patent)

Is supplied by branches of the celiac and superior mesenteric arteries

Receives extensive autonomic nerve supply



# Contents of the Abdomen

## GALLBLADDER AND DUCT SYSTEM

### GALLBLADDER

Small intraperitoneal organ

Is part of the foregut

Stores and concentrates bile, which emulsifies fat during digestion

Is located in a fossa on the liver where the linea semilunaris attaches to the ribcage at the 9th costal cartilage

Divided into 3 parts:

- Fundus
- Body
- Neck

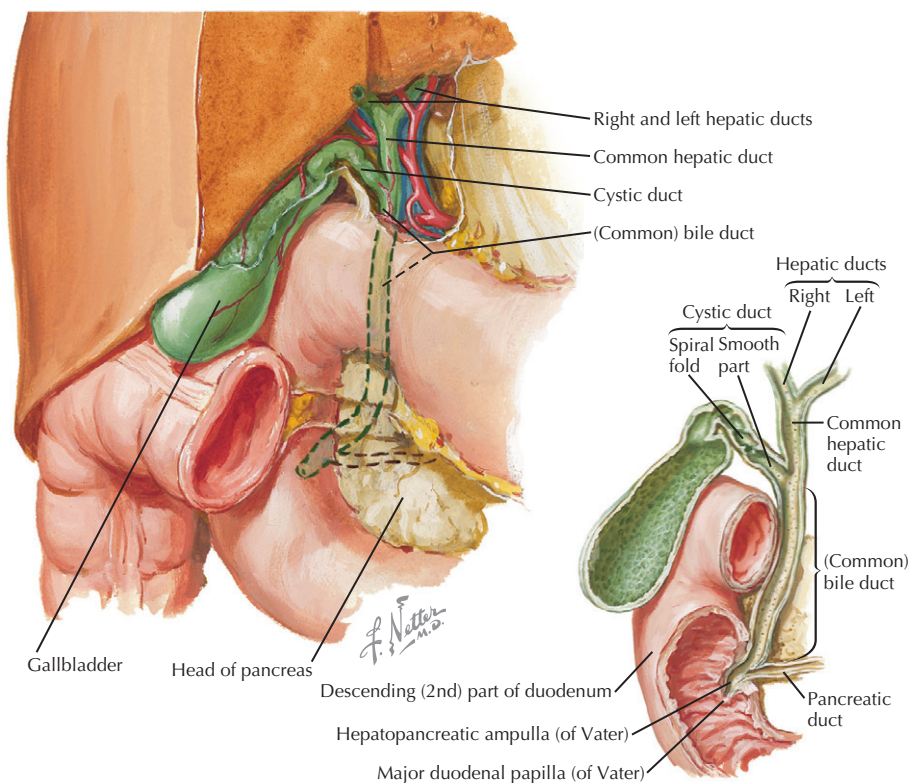
Is supplied by branches of the celiac artery

Receives extensive autonomic nerve supply

### DUCT SYSTEM

The cystic duct joins the common hepatic duct to form the common bile duct

The common bile duct joins the main pancreatic duct within the substance of the pancreas to form the hepatopancreatic ampulla, which passes through the wall of the 2nd part of the duodenum into the major duodenal papilla



**SPLEEN**

A lymphatic organ on the left side of the body divided into:

- Red pulp
- White pulp

Is intraperitoneal

- Major functions include:
- Storage of red blood cells
- Filters red blood cells
- Removes old red blood cells
- Storage of monocytes

Is not a derivative of the foregut, although receives its arterial supply from branches of the celiac artery

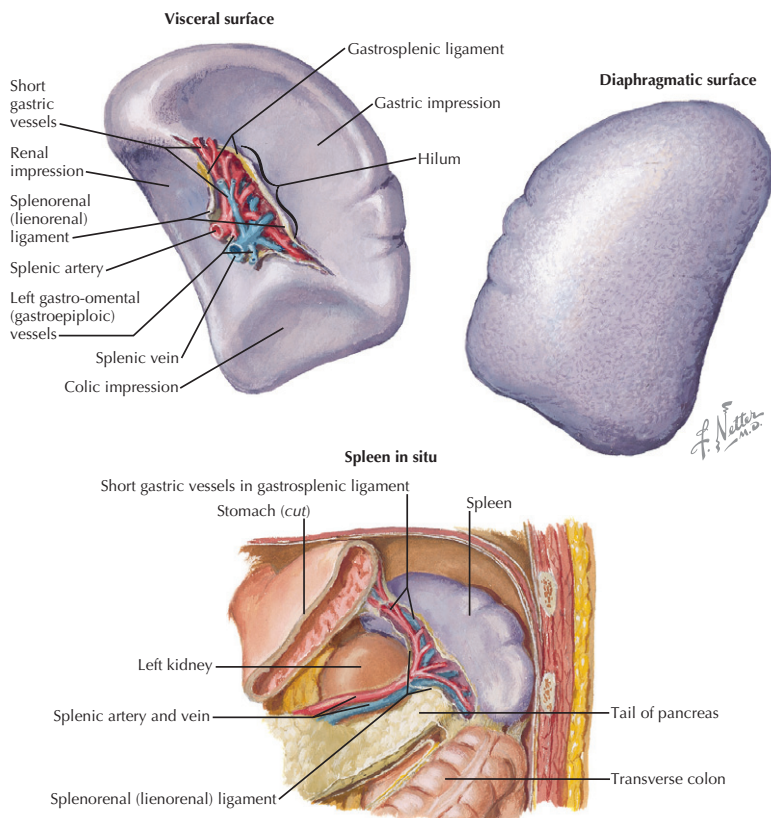
Is located between the 9th and 11th ribs, paralleling the 10th rib

Has contact with 4 organs:

- Stomach
- Large intestine
- Left kidney
- Tail of pancreas

Is suspended by dorsal mesentery of the foregut:

- Lienorenal—contains tail of the pancreas and splenic vv.
- Gastrosplenic—contains short gastric vv. and left gastroepiploic vv.



# Contents of the Abdomen

## KIDNEY, URETER, AND SUPRARENAL GLAND

### KIDNEY

Paired organ

Is retroperitoneal

Has multiple functions, including:

- Filter blood
- Regulate electrolytes
- Regulate blood pressure
- Produce hormones

Nephron is function unit

Located between T11–L3, with hilum at L1

Left kidney is slightly larger than the right kidney

Right kidney is slightly inferior to the left kidney due to the liver

Surrounded by a tough capsule

Divided into:

- Cortex
- Medulla

Receives arterial supply from renal vv.

Receives extensive autonomic nerve supply

### URETER

Is retroperitoneal

Carries urine from kidney to the bladder

Begins at hilum, or L1 and travels inferior to the bladder

Common sites of kidney stones include:

- Uteropelvic junction
- Crossing Iliac vv. on pelvis
- Junction with bladder

### SUPRARENAL GLAND

Also known as *adrenal gland*

Are endocrine glands

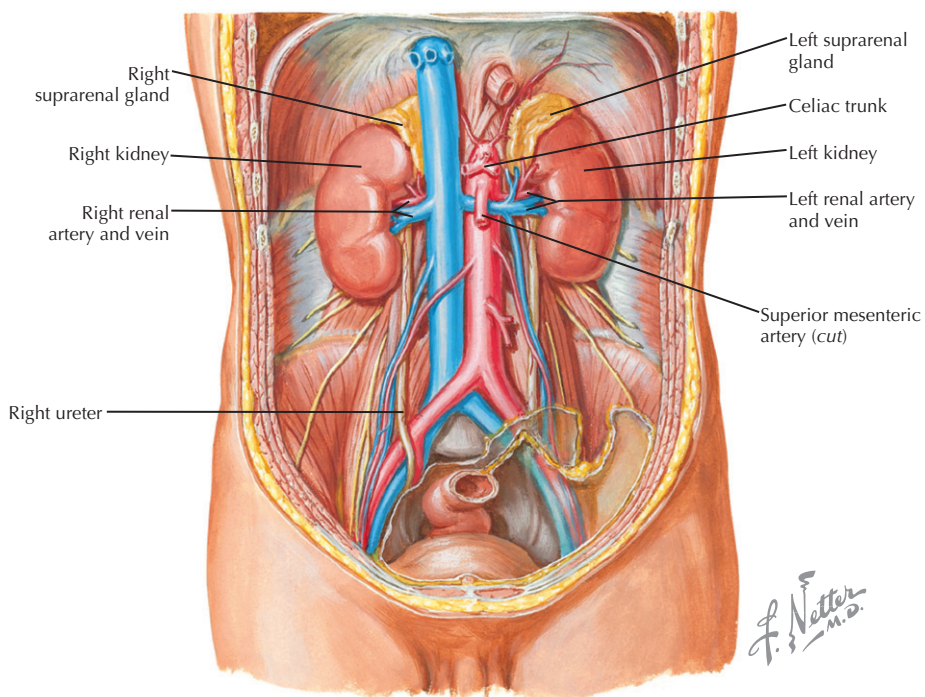
Divided into:

- Cortex—responsible for production of mineralocorticoids, glucocorticoids, and androgens
- Medulla—responsible for catecholamines via sympathetic response (fight or flight)

Receives threefold arterial supply:

- Superior suprarenal—from inferior phrenic a.
- Middle suprarenal—from aorta
- Inferior suprarenal—from renal a.



**KIDNEY, URETER, AND SUPRARENAL GLAND** *CONTINUED*

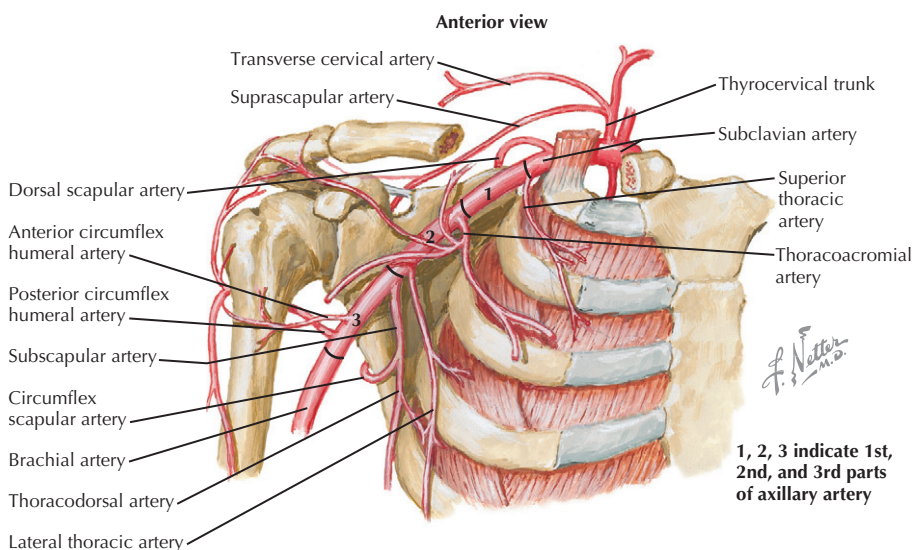
# Vascular Supply

## UPPER LIMB

### Arterial Supply of the Axilla

Axillary—is divided into 3 parts based on its relationship to the pectoralis minor

- 1st part
  - Superior thoracic—supplies 1st two intercostal spaces
- 2nd part
  - Thoracoacromial
  - Pectoral
  - Acromial
  - Deltoid—accompanies cephalic v.
  - Clavicular—helps supply acromioclavicular joint
  - Lateral thoracic—follows inferior border of pectoralis minor to thorax
- 3rd part
  - Subscapular
  - Scapular circumflex—located in triangular space
  - Thoracodorsal—passes with thoracodorsal n. to latissimus dorsi
  - Posterior humeral circumflex—travels in quadrangular space with axillary n.
  - Anterior humeral circumflex



## 22 Vascular Supply

### UPPER LIMB *CONTINUED*

#### *Arterial Supply of the Brachium*

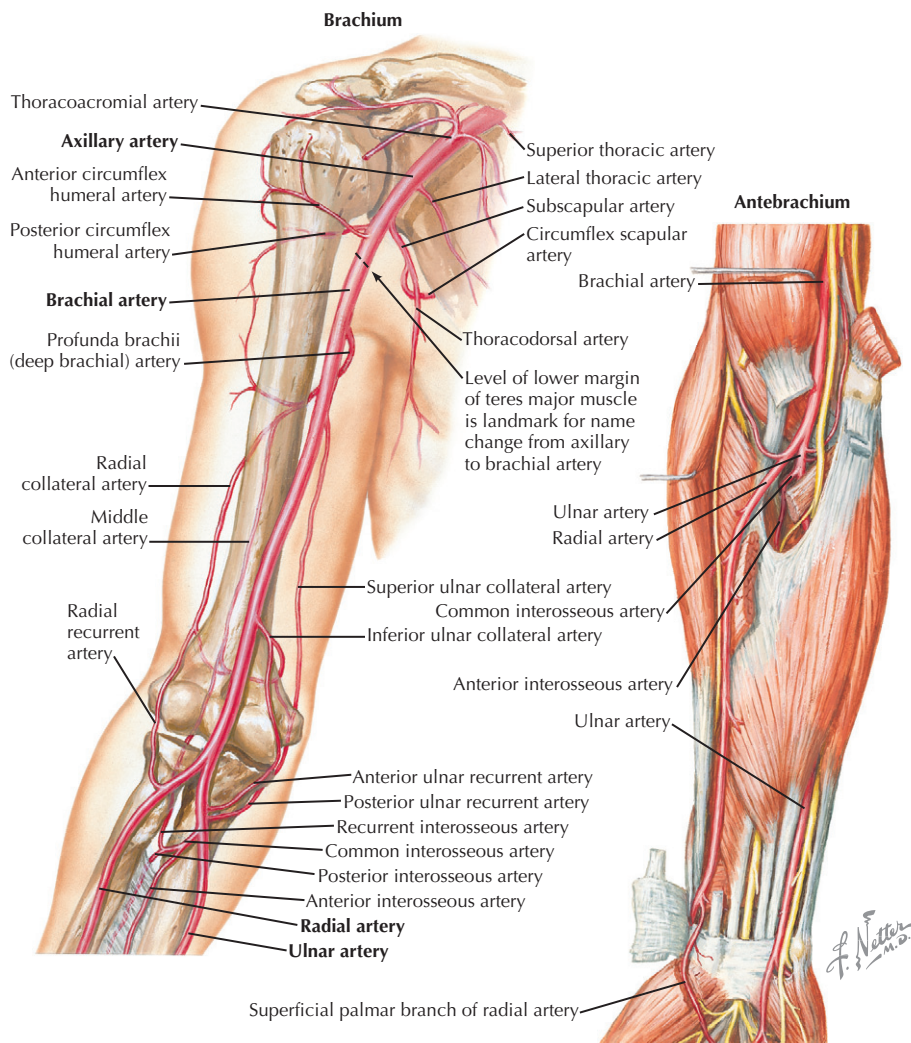
Brachial—begins at inferior border of teres major

- Profunda brachii
  - Middle collateral
  - Radial collateral
- Superior ulnar collateral—passes with ulnar n. posterior to medial epicondyle
- Inferior ulnar collateral
- Muscular branches

#### *Arterial Supply of the Antebrachium*

Brachial—divides into:

- Radial
  - Radial recurrent
  - Palmar carpal branch
  - Superficial palmar branch
- Ulnar
  - Anterior ulnar recurrent
  - Posterior ulnar recurrent
  - Common interosseous
  - Palmar carpal branch

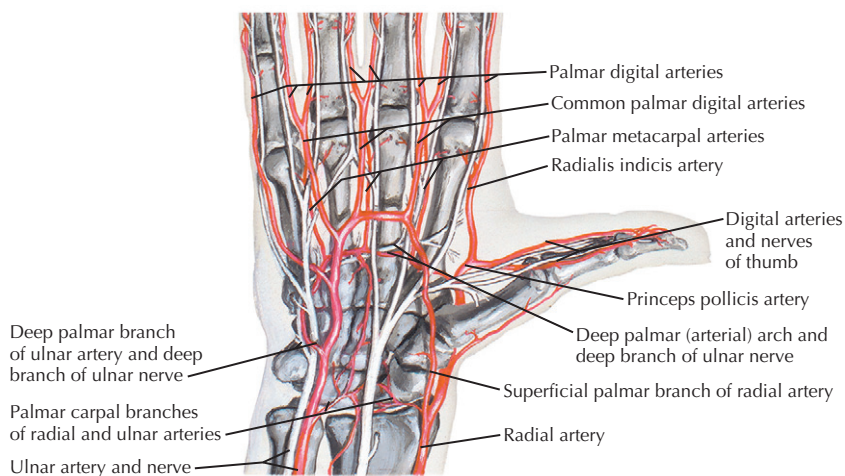
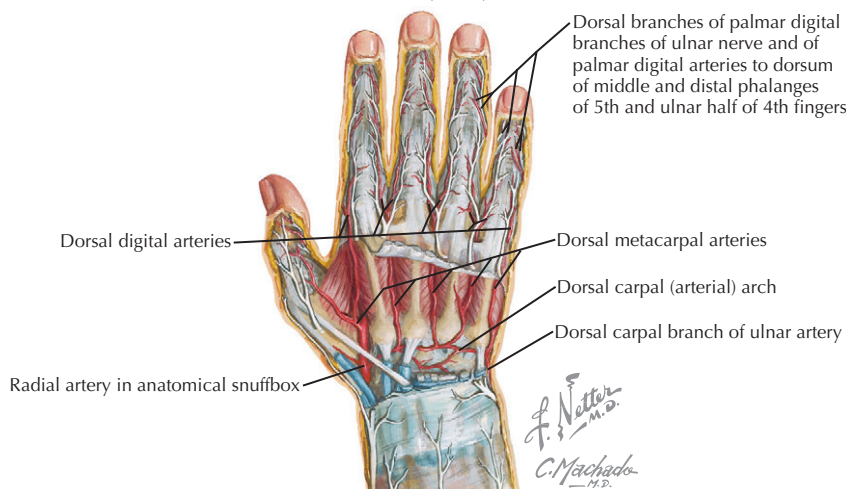


**UPPER LIMB** CONTINUED*Carpus and Manus***Ulnar**

- Dorsal carpal branch
- Deep branch of the ulnar
- Palmar carpal branch
- Superficial palmar arch
  - Common palmar digital
  - Proper palmar digital

**Radial**

- Princeps pollicis
- Radialis indicis
- Deep palmar arch

**Posterior (dorsal) view**

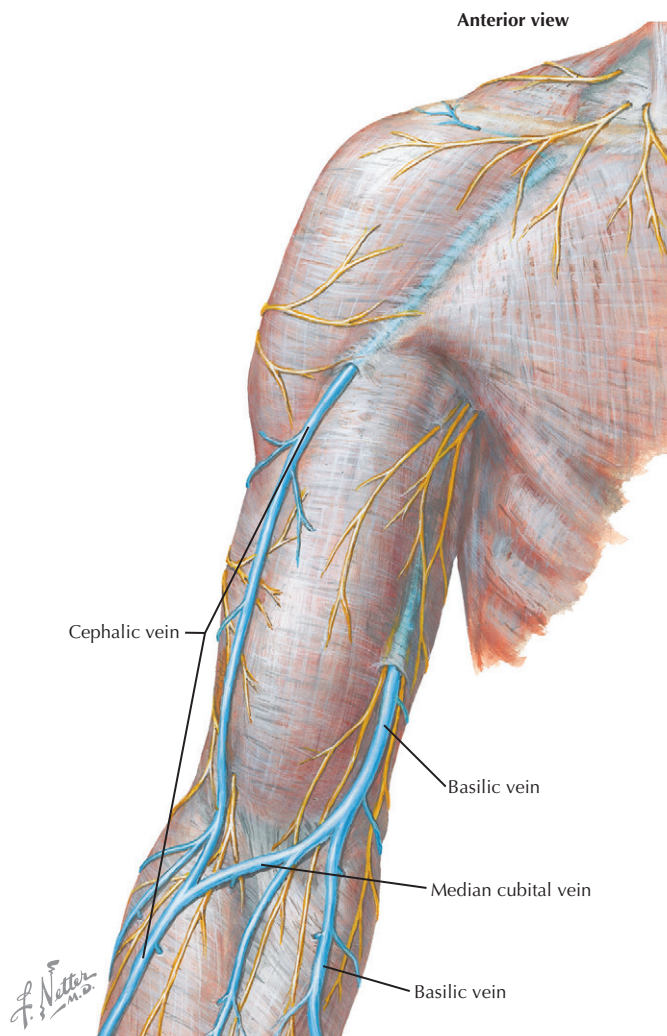
# Vascular Supply

## UPPER LIMB *CONTINUED*

### *Veins*

Two types of veins:

- Superficial—lie in superficial fascia
  - Cephalic
  - Basilic
- Deep (have either):
  - Single similar-sized vein following the artery of the upper limb (e.g., subclavian vein or axillary vein)
  - Vena comitans—accompanying vein
    - A pairing of veins with both surrounding the artery
    - Typically any veins that are distal to the axillary v. is a vena comitans (e.g., brachial veins, ulnar veins, and radial veins), which are paired around the artery of the same name



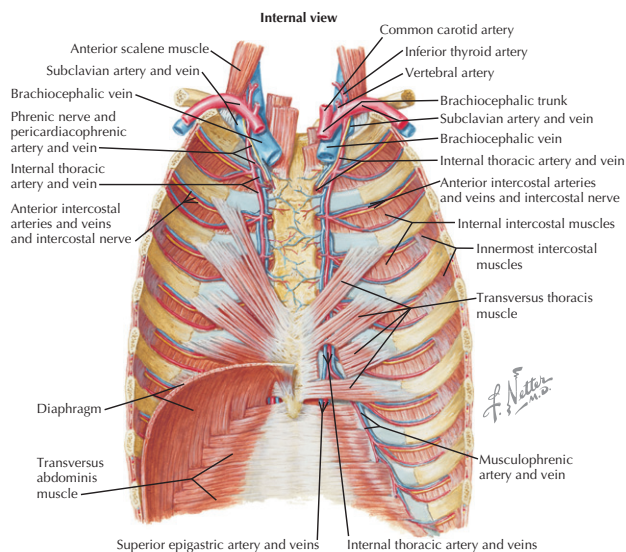


**THORAX****Arterial**

- Internal thoracic—arises from subclavian a.
  - Pericardiophrenic
  - Terminates as:
    - Musculophrenic
    - Superior epigastric
- Intercostal arteries
  - Posterior intercostal
    - 2 (Costocervical trunk)
    - 9 (Thoracic aorta)
    - 1 Subcostal (thoracic aorta)
  - Anterior intercostal
    - 6 (Internal thoracic)
    - 3 (Musculophrenic)
- Esophageal
- Bronchial
  - Right (3rd posterior intercostal a.)
  - 2 Left (aorta)

**Veins**

- Azygos system
  - Posterior intercostal vv.
  - Esophageal vv.
  - Bronchial vv.
  - Right side of thorax
    - Right supreme intercostal v.
    - Right superior intercostal v.
  - Left side of thorax
    - Left supreme intercostal v.
    - Left superior intercostal v.
    - Accessory hemiazygos v.
    - Hemiazygos v.



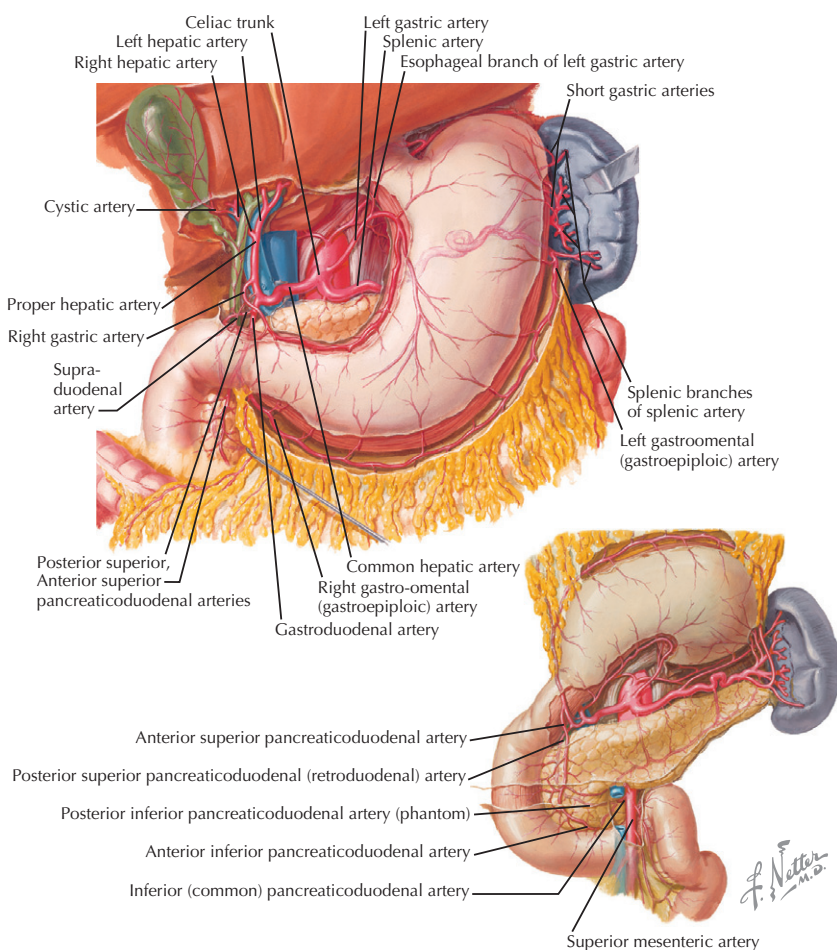
# Vascular Supply

## ABDOMEN

### Unpaired Visceral Arteries

**Celiac Artery** (Artery of the Foregut)—arises at T12

- Left gastric
- Common hepatic
  - Proper hepatic
    - Right gastric
    - Left hepatic
    - Right hepatic
    - Cystic
  - Gastroduodenal
    - Supraduodenal
    - Right gastroepiploic
    - Anterior and posterior superior pancreaticoduodenal
- Splenic
  - Pancreatic branches
  - Short gastric
  - Left gastroepiploic



**ABDOMEN** *CONTINUED***Superior Mesenteric Artery** (Artery of the Midgut)—arises at L1

- Anterior and posterior inferior pancreaticoduodenal

- Jejunum mesenteric

- Arterial arcades and vasa recta

- Ileum mesenteric

- Arterial arcades and vasa recta

- Ileocolic

- Appendicular

- Right colic

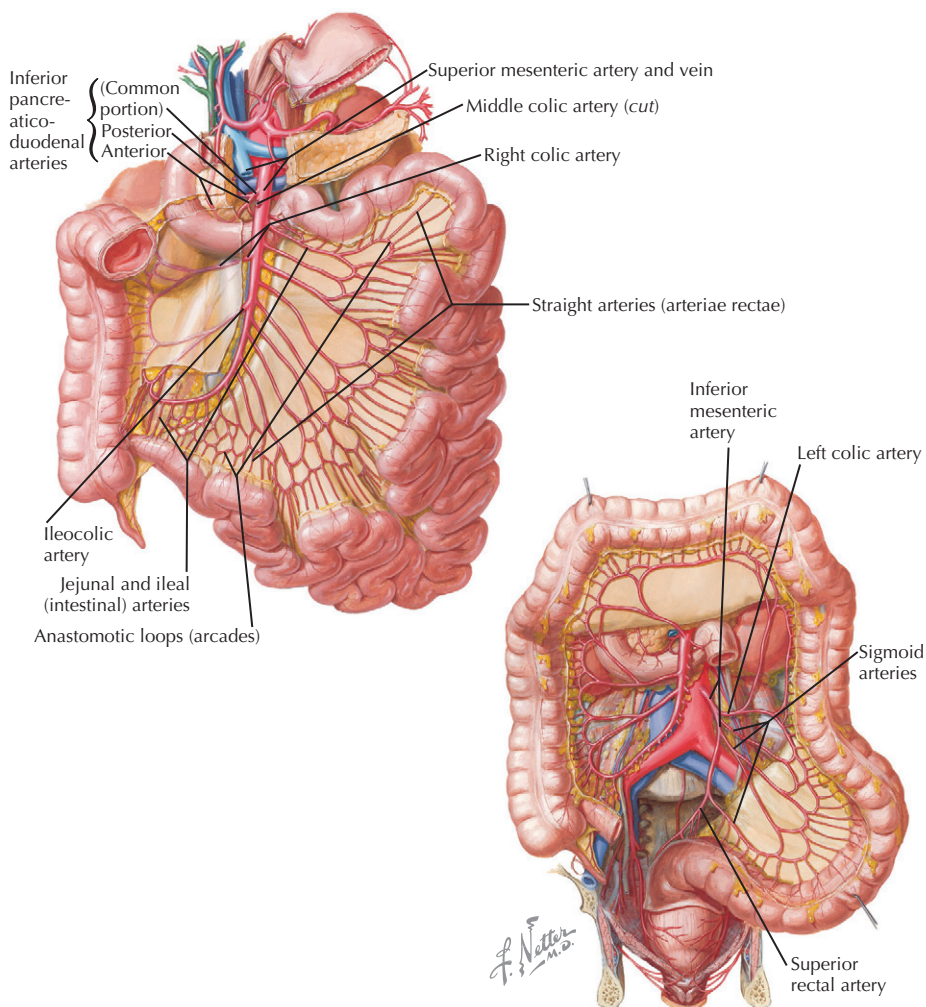
- Middle colic

**Inferior Mesenteric Artery** (Artery of the Hindgut)—arises at L3

- Left colic

- Sigmoid

- Superior rectal



# Vascular Supply

## POSTERIOR ABDOMEN

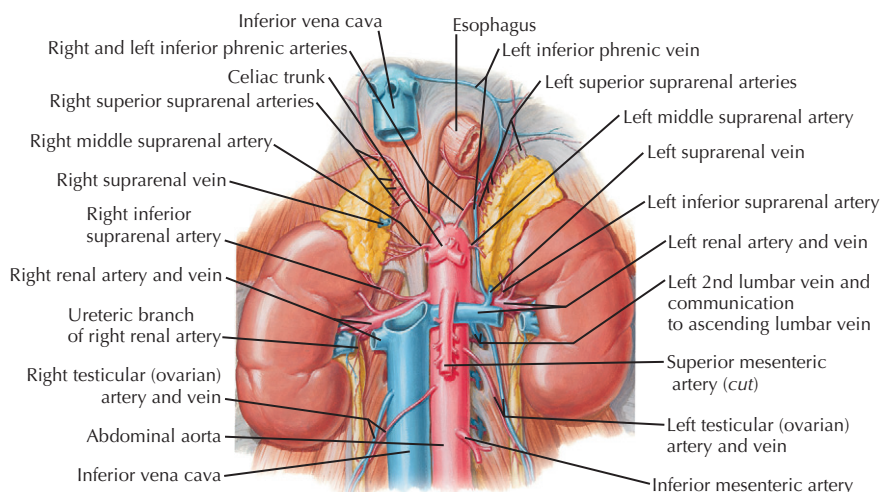
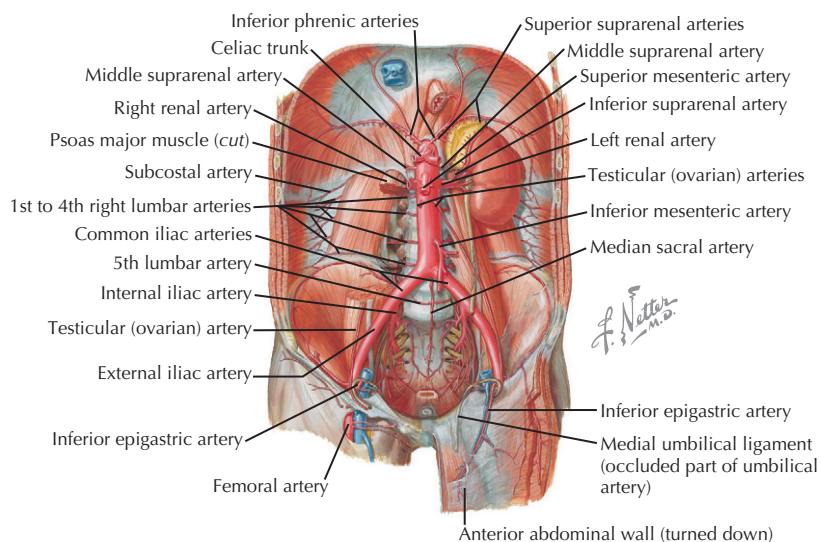
### Paired Visceral and Parietal Arteries

Paired Visceral Branches—paired branches supplying organs

- Renal—arises at L2
- Gonadal—arises between L2 and L3
  - Testicular
  - Ovarian
- Suprarenal
  - Superior—arises from the inferior phrenic
  - Middle—arises from the aorta
  - Inferior—arises from the renal

Paired Parietal (Body Wall) Branches—paired branches supplying the wall

- Inferior phrenic
- Lumbar—4 arise from the aorta





## ABDOMEN

*Venous Supply of the Viscera*

Veins that drain the abdominal viscera closely follow the celiac, superior mesenteric, and inferior mesenteric arteries

These veins eventually drain into the hepatic portal vein, which passes into the liver, allowing the liver to clear the blood of any wastes and to store nutrients

The hepatic portal vein is formed by the:

- Superior mesenteric vein
- Splenic vein

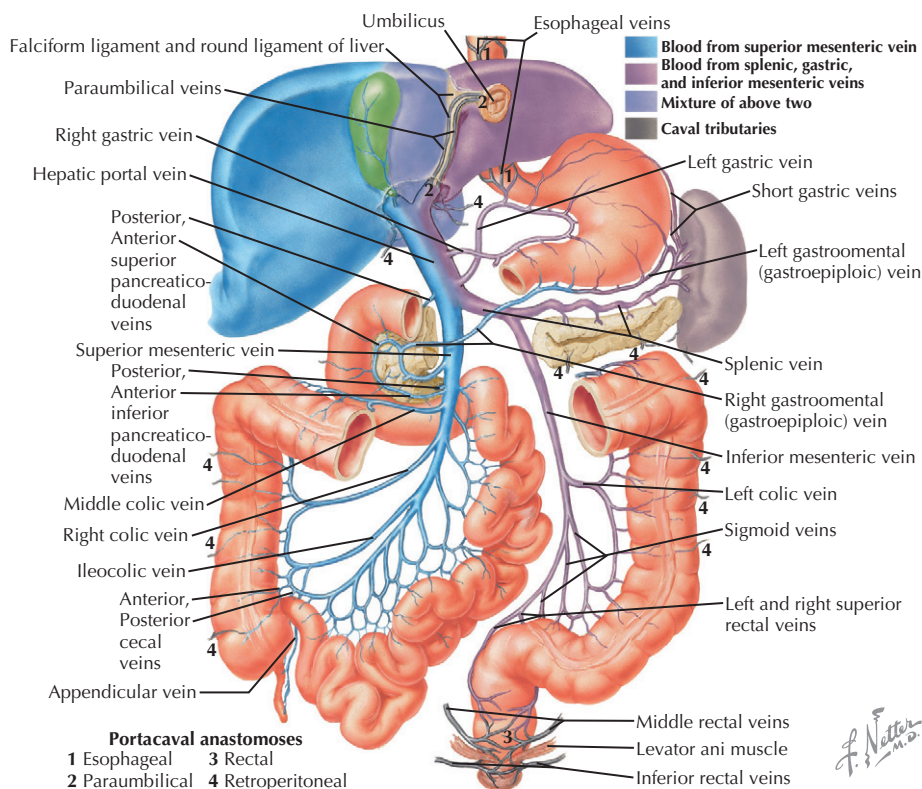
After passing through the liver, the blood returns into the systemic system via hepatic veins into the inferior vena cava

Since the veins in this region lack valves, they take the path of least resistance

If there is an obstruction in the path of the hepatic portal vein, the blood will attempt to return the blood toward the heart by bypassing the block and utilizing anastomosis between the portal system and the systemic system (vena cava)

There are 4 major collaterals between the portal and systemic systems:

- Esophageal
- Paraumbilical
- Rectal
- Retroperitoneal



# Vascular Supply

## ABDOMEN *CONTINUED*

### *Hepatic Portal Vein*

- Minor direct tributaries include:
  - Cystic v.
  - Right gastric v.
  - Left gastric v.
    - Esophageal vv.
  - Posterior superior pancreaticoduodenal v.
- Major tributaries include:
  - Superior mesenteric vein
    - Right gastroepiploic v.
      - Anterior superior pancreaticoduodenal v.
      - Anterior inferior pancreaticoduodenal v.
    - Posterior inferior pancreaticoduodenal v.
    - Middle colic v.
    - Jejunal mesenteric vv.
      - Venous anastomotic loops
      - Vasa recta
    - Ileal mesenteric vv.
      - Venous anastomotic loops
      - Vasa recta
    - Ileocolic v.
    - Right colic v.
  - Splenic v.
    - Pancreatic branches
    - Short gastric v.
    - Left gastroepiploic v.
    - Inferior mesenteric—sometimes joins to form hepatic portal v.
      - Left colic v.
      - Sigmoid vv.
      - Superior rectal v.

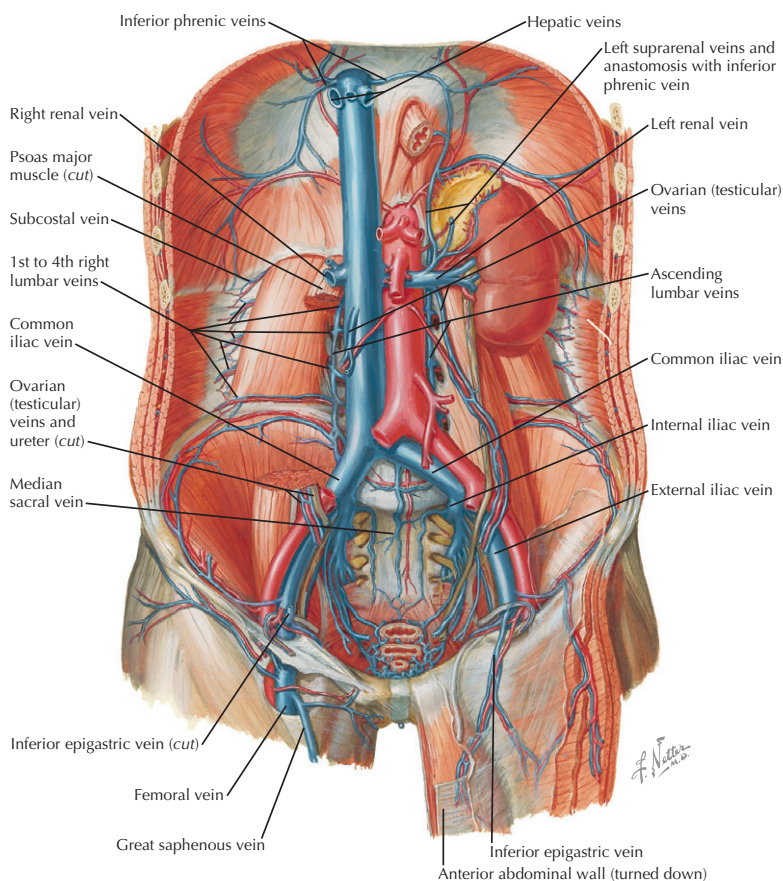


**POSTERIOR ABDOMEN***Venous Supply of the Posterior Abdominal Wall*

Veins of the posterior abdominal wall drain into the inferior vena cava

Tributaries include:

- Hepatic vv.
  - Right hepatic v.
  - Middle hepatic v.
  - Left hepatic v.
- Inferior phrenic v.
- Suprarenal v.
- Renal v.
  - Left gonadal v.
    - Testicular
    - Ovarian
- Right gonadal v.
  - Testicular
  - Ovarian
- Subcostal v.
- Lumbar vv.



# Nerve Supply

## UPPER LIMB

Alternating joining and branching of nerves to reorganize the terminal branches with contributions from multiple spinal cord levels

Origin from ventral rami of 5th to 8th cervical and 1st thoracic spinal nerves

General organization is:

- 5 Ventral rami
- 3 Trunks
- 6 Divisions
- 3 Cords
- 6 Branches

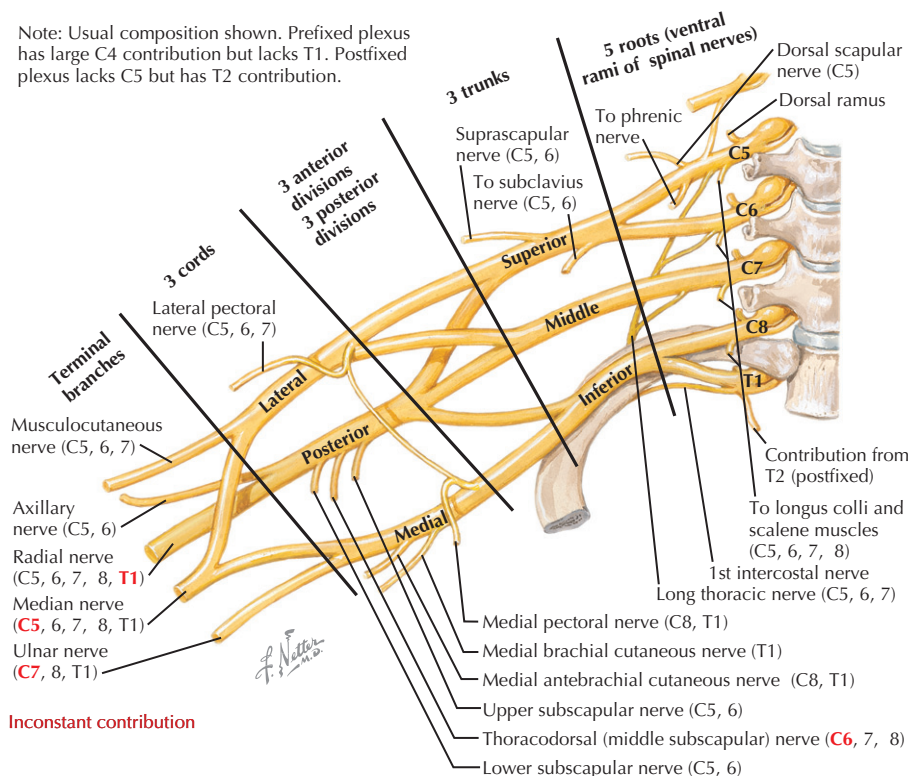
Nerves to muscles on ventral and dorsal surfaces of upper limb are derived from anterior and posterior divisions, respectively.

Location and arterial relations:

- Rami and trunks—Posterior triangle of neck—Subclavian a.
- Divisions—Behind clavicle—Subclavian and 1st part of axillary a.
- Cords—Axilla—2nd part of axillary a.
- Branches—Axilla—3rd part of axillary a.

Key landmark of "M" formed by medial and lateral cords and terminal branches

Note: Usual composition shown. Prefixed plexus has large C4 contribution but lacks T1. Postfixed plexus lacks C5 but has T2 contribution.



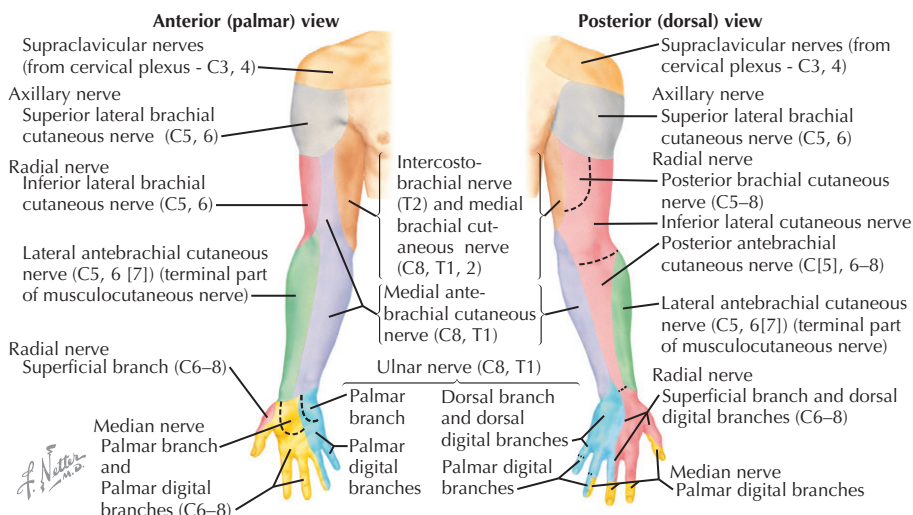
Inconstant contribution

## UPPER LIMB

BRACHIAL PLEXUS		
Nerve	Source	Comments
Dorsal scapular (C5)	Ventral rami	Passes posteriorly to lie along the medial border of the scapula Innervates the: <ul style="list-style-type: none"> <li>• Levator scapula</li> <li>• Rhomboid major</li> <li>• Rhomboid minor</li> </ul>
Long thoracic (C5, C6, C7)	Ventral rami	Passes inferiorly along the serratus anterior Innervates the serratus anterior
Muscular branches	Ventral rami	Supplies the scalenes and longus colli
Subclavius (C5)	Upper trunk	Innervates the subclavius
Suprascapular (C5, C6)	Upper trunk	Innervates the: <ul style="list-style-type: none"> <li>• Supraspinatus</li> <li>• Infraspinatus</li> </ul>
Lateral pectoral (C5, C6, C7)	Lateral cord	Innervates the clavicular head of the pectoralis major
Musculocutaneous (C5, C6, C7)	Lateral cord	Passes into the coracobrachialis to enter the flexor compartment of the brachium After passing through the coracobrachialis, it travels distally in the brachium between the biceps brachii and the brachialis Innervates the: <ul style="list-style-type: none"> <li>• Coracobrachialis</li> <li>• Biceps brachii</li> <li>• Brachialis</li> </ul> Terminates as the lateral cutaneous nerve of the antebrachium upon exiting the distal compartment
Median (C5, C6, C7) from lateral head (C8, T1) from medial head	Lateral and medial cord	Brachium: Has no motor or sensory branches in the arm Antebrachium: No sensory branches in antebrachium Innervates: <ul style="list-style-type: none"> <li>• Pronator teres</li> <li>• Flexor carpi radialis longus</li> <li>• Palmaris longus</li> <li>• Flexor digitorum superficialis</li> </ul> Has 1 major motor branch innervating the deep flexor muscles: <ul style="list-style-type: none"> <li>• Flexor pollicis longus</li> <li>• Flexor digitorum profundus</li> <li>• Pronator quadratus</li> </ul> Manus: Sensory branches: <ul style="list-style-type: none"> <li>• Palmar cutaneous branch—lateral portion of palm</li> <li>• Common palmar digital branches—lateral portion of palm</li> <li>• Proper palmar digital branches—palmar surface of 1st, 2nd, 3rd, and lateral half of 4th digit</li> </ul> Motor branches: Recurrent branch of median <ul style="list-style-type: none"> <li>• Opponens pollicis</li> <li>• Abductor pollicis brevis</li> <li>• Flexor pollicis brevis</li> </ul> Motor branches to 1st and 2nd lumbricals
Medial brachial cutaneous (T1)	Medial cord	Provides sensory innervation to the medial aspect of the superior portion of the brachium

BRACHIAL PLEXUS		
Nerve	Source	Comments
Medial antebrachial cutaneous (C8, T1)	Medial cord	Provides sensory innervation to the medial aspect of the inferior portion of the brachium
Medial pectoral (C8, T1)	Medial cord	Innervates: <ul style="list-style-type: none"> <li>• Pectoralis minor</li> <li>• Sternal head of pectoralis major</li> </ul>
Ulnar (C7, C8, T1)	Medial cord	Brachium: <p>Has no motor or sensory branches in the arm</p> Antebrachium: <p>Has no sensory branches in the antebrachium</p> Innervates: <ul style="list-style-type: none"> <li>• Flexor carpi ulnaris</li> <li>• Flexor digitorum profundus (medial half)</li> </ul> Manus: <p>Sensory branches:</p> <ul style="list-style-type: none"> <li>• Dorsal cutaneous n.—posterior surface of medial portion of manus</li> <li>• Dorsal digital branches—dorsal aspect of 5th digit and medial half of 4th digit</li> <li>• Palmar cutaneous n.—medial aspect of palm</li> <li>• Common palmar cutaneous branches—distal portion of medial aspect of palm</li> <li>• Proper palmar digital branches—palmar surface of 5th digit and medial half of 4th digit</li> </ul> <p>Motor branches:</p> <p>Superficial ulnar n.</p> <ul style="list-style-type: none"> <li>• Palmaris brevis</li> </ul> <p>Deep ulnar n.</p> <ul style="list-style-type: none"> <li>• Abductor digiti minimi</li> <li>• Flexor digiti minimi brevis</li> <li>• Opponens digiti minimi</li> <li>• Adductor pollicis</li> <li>• Dorsal interosseous</li> <li>• Palmar interosseous</li> <li>• 3rd and 4th lumbrical</li> </ul>
Upper subscapular (C5, C6)	Posterior cord	Innervates the upper portion of the subscapularis
Thoracodorsal (C6, C7, C8)	Posterior cord	Innervates the latissimus dorsi
Lower subscapular (C5, C6)	Posterior cord	Innervates: <ul style="list-style-type: none"> <li>• Lower portion of the subscapularis</li> <li>• Teres major</li> </ul>
Axillary (C5, C6)	Posterior cord	Innervates: <ul style="list-style-type: none"> <li>• Deltoid</li> <li>• Teres minor</li> </ul> <p>Has a sensory branch on the lateral aspect of the superior portion of the brachium:</p> <ul style="list-style-type: none"> <li>• Superior lateral cutaneous branch</li> </ul>

BRACHIAL PLEXUS		
Nerve	Source	Comments
Radial (C5, C6, C7, C8, T1)	Posterior cord	<p>Brachium:</p> <p>Innervates the:</p> <ul style="list-style-type: none"> <li>• Triceps brachii</li> <li>• Anconeus</li> </ul> <p>Has 2 sensory branches:</p> <ul style="list-style-type: none"> <li>• Inferior lateral cutaneous nerve—sensory on lateral aspect of inferior brachium</li> <li>• Posterior cutaneous nerve—sensory on posterior surface of brachium</li> </ul> <p>Antebrachium:</p> <p>Has 1 sensory branch:</p> <ul style="list-style-type: none"> <li>• Posterior cutaneous nerve of the antebrachium</li> </ul> <p>Innervates the:</p> <ul style="list-style-type: none"> <li>• Brachioradialis</li> <li>• Extensor carpi radialis longus</li> </ul> <p>Divides into a:</p> <ul style="list-style-type: none"> <li>• Superficial radial (sensory in manus)</li> <li>• Deep radial (motor in antebrachium)</li> </ul> <p>Deep radial innervates:</p> <ul style="list-style-type: none"> <li>• Extensor carpi radialis brevis</li> <li>• Supinator</li> </ul> <p>Deep radial passes through the supinator to the posterior surface becoming the posterior interosseus</p> <p>The posterior interosseus innervates:</p> <ul style="list-style-type: none"> <li>• Extensor digitorum</li> <li>• Extensor carpi ulnaris</li> <li>• Extensor indicis</li> <li>• Extensor digiti minimi</li> <li>• Extensor pollicis longus</li> <li>• Abductor pollicis longus</li> <li>• Extensor pollicis brevis</li> </ul> <p>Manus:</p> <p>Sensory branches:</p> <ul style="list-style-type: none"> <li>• Superficial radial nerve—dorsal aspect of manus</li> <li>• Dorsal digital branches—dorsal aspect of 1st digit</li> </ul> <p>There are no motor branches in the manus</p>

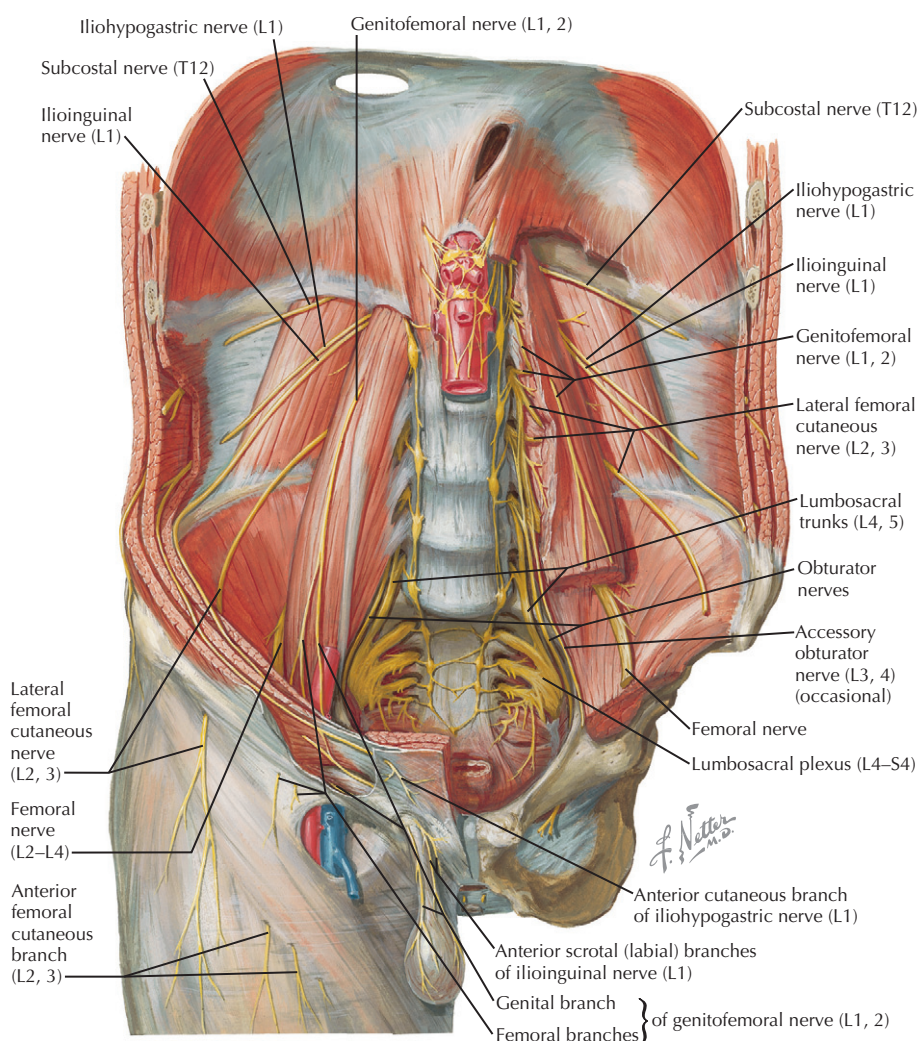


# Nerve Supply

## POSTERIOR ABDOMINAL WALL

### Nerves

- Subcostal—T12
- Iliohypogastric—L1
- Ilioinguinal—L1
- Lateral femoral cutaneous nerve—L2, L3
- Genitofemoral—L1, L2
  - Genital branch—cremaster
  - Femoral branch—sensory on thigh
- Femoral—L2, L3, L4
- Obturator—L2, L3, L4







**Appendix A**  
Questions and Answers

- All of the following are derivatives of the 1st pharyngeal arch except one. Which one is the exception?
  - Masseter
  - Incus
  - Sphenomandibular ligament
  - Posterior digastric
  - Tensor veli palatini
- All of the following contribute to the formation of the skull except one. Which one is the exception?
  - Lateral plate mesoderm
  - Endoderm
  - Neural crest
  - Paraxial mesoderm
  - All of the above (A-D) contribute to the formation of the skull.
- All of the following are parts of the 1st pharyngeal arch that contribute to the tongue except one. Which one is the exception?
  - Lateral lingual swelling
  - Tuberculum impar
  - Hypobranchial eminence
  - Receives GSA innervation from the trigeminal nerve
  - All of the above (A-D) are parts of the 1st pharyngeal arch that contribute to the tongue.
- All of the following statements about the formation of the palate are correct except one. Which one is the exception?
  - The primary and secondary palatal tissues meet at the incisive foramen.
  - The primary palate, secondary palate, and nasal septum fuse to form the definitive palate.
  - Swellings of the maxillary prominence form shelves that project laterally and are separated by the tongue.
  - The primary palate forms from the intermaxillary segment.
  - All of the above (A-D) are correct.

- All of the following statements are correct except one. Which one is the exception?
  - The frontal lobe of the brain occupies the anterior cranial fossa.
  - The occipital lobe of the brain occupies the posterior cranial fossa.
  - The lacrimal bone is paired.
  - The palatine bone is paired.
  - The mandible articulates with the temporal bone.
- All of the following are associated with the sphenoid bone except one. Which one is the exception?
  - The foramen spinosum is located in the sphenoid bone.
  - The pterygoid canal is located in the sphenoid bone.
  - The foramen rotundum is located in the sphenoid bone.
  - The body of the sphenoid contains the sphenoid paranasal sinus.
  - The sphenoid bone is paired.
- All of the following are parts of the maxilla except one. Which one is the exception?
  - Zygomatic process
  - Body
  - Palatine process
  - Pterygoid process
  - Alveolar process
- All of the following structures pass through the fissure/foramen listed except one. Which one is the exception?
  - Ophthalmic artery passes through the optic canal.
  - Glossopharyngeal nerve passes through the jugular foramen.
  - Middle meningeal artery passes through the foramen spinosum.
  - Maxillary division of the trigeminal nerve passes through the foramen rotundum.
  - Frontal nerve passes through the inferior orbital fissure.

9. All of the following fissure/foramen are located in or formed by the bones listed except one. Which one is the exception?
  - A. Tympanic canaliculus—temporal bone
  - B. Carotid canal—occipital bone
  - C. Jugular foramen—temporal and occipital bones
  - D. Petrotympanic fissure—temporal bone
  - E. Hypoglossal canal—occipital bone

### QUESTIONS CHAPTER 3 **BASIC NEUROANATOMY AND CRANIAL NERVES**

10. All of the following statements are correct except one. Which one is the exception?
  - A. There are 5 pairs of sacral spinal nerves.
  - B. Neurons can have multiple axons.
  - C. A characteristic of a neuron is irritability.
  - D. Neurons are the structural and functional unit of the nervous system.
  - E. A multipolar neuron has 3 or more processes from the cell body.
11. All of the following neuroglial cells are located in the central nervous system except one. Which one is the exception?
  - A. Astrocytes
  - B. Oligodendrocytes
  - C. Schwann cells
  - D. Microglia
  - E. All of the above (A-D) are located in the central nervous system.
12. Which of the following functional columns innervates smooth muscle?
  - A. GSA
  - B. SSE
  - C. SVA
  - D. GVE
  - E. SSA
13. Which of the following represents the location of the cell bodies of primary taste fibers (SVA) in the facial nerve?
  - A. Tractus solitarius
  - B. Submandibular ganglion
  - C. Geniculate ganglion
  - D. Pterygopalatine ganglion
  - E. Superior salivatory nucleus
14. In one of the following lists, the functional column responsible for innervating GSE muscle are found in all of the cranial nerves. Identify the letter that corresponds to that list.
  - A. III, VII, IX, and X
  - B. III, IV, VI, and XII
  - C. I, VII, IX, and X
  - D. V, VII, IX, and X
  - E. III, IV, VI, and X

### QUESTIONS CHAPTER 4 **THE NECK**

15. All of the following are a content, muscle, or the cranial nerve that innervates a muscle that makes a border of the submental except one. Which one is the exception?
  - A. Anterior digastric
  - B. Trigeminal nerve
  - C. Anterior jugular vein
  - D. Submental lymph node
  - E. All of the above (A-D) are a content, muscle, or the nerve that innervates a muscle that makes a border of the submental triangle.
16. All of the following statements are correct except one. Which one is the exception?
  - A. The dorsal scapular nerve is a content of the posterior triangle.
  - B. The suprascapular nerve is a content of the posterior triangle.
  - C. The posterior scalene muscle attaches to the 1st rib.
  - D. The external jugular vein is a content of the posterior triangle.
  - E. The phrenic nerve lies anterior to the anterior scalene muscle.

17. Which of the following vessels are accompanied by a nerve that has the same name?
  - A. Submental vessels
  - B. Superior laryngeal vessels
  - C. Transverse cervical vessels
  - D. Suprascapular vessels
  - E. All of the following vessels (A-D) are accompanied by a nerve that has the same name.
18. All of the following are either a muscle or the nerve that innervates a muscle that makes a border of the carotid triangle except one. Which one is the exception?
  - A. Omohyoid
  - B. Facial nerve
  - C. Trigeminal nerve
  - D. Ansa cervicalis
  - E. Spinal accessory nerve
19. All of the following statements are correct except one. Which one is the exception?
  - A. The submental triangle is paired.
  - B. The larynx is a content of the muscular triangle.
  - C. Part of the thyroid gland can be observed at vertebral level C6.
  - D. The parathyroid glands are a content of the muscular triangle.
  - E. The submandibular gland is a content of the submandibular triangle.

## QUESTIONS CHAPTER 5

## SCALP AND MUSCLES OF FACIAL EXPRESSION

20. All of the following statements concerning the scalp are correct except one. Which one is the exception?
  - A. Loose areolar connective tissue lies deep to the aponeurosis.
  - B. The prolific arterial blood supply to the scalp is in the connective tissue layer.
  - C. The skin, connective tissue, aponeurosis, and loose areolar connective tissue layers are referred to as the scalp proper.
  - D. The pericranium covers the outer surface of the cranium.
  - E. Emissary veins connect the connective tissue layer to the dural venous sinuses, providing channel for infections to spread.
21. All of the following nerves provide at least some sensory innervation to either the face, the scalp, or both, except one. Which one is the exception?
  - A. Dorsal ramus of C1
  - B. Mental nerve
  - C. Zygomaticofacial nerve
  - D. External nasal nerve
  - E. Great auricular nerve
22. All of the following statements are correct except one. Which one is the exception?
  - A. The risorius muscle aids in grinning.
  - B. The stapedius is innervated by the facial nerve.
  - C. The buccal nerve from the trigeminal innervates the buccinator.
  - D. The palpebral portion of the orbicularis oculi aids in closing the eyes during blinking.
  - E. Levator anguli oris elevates the angle of the mouth.
23. All of the following arteries supplying the face, the scalp, or both, arise directly from the external carotid artery except one. Which one is the exception?
  - A. Lacrimal
  - B. Facial
  - C. Superficial temporal
  - D. Posterior auricular
  - E. Occipital
24. Which of the following muscles is not innervated by the trigeminal nerve?
  - A. Inferior head of the lateral pterygoid
  - B. Posterior belly of digastric
  - C. Masseter
  - D. Tensor veli palatini
  - E. Temporalis

**QUESTIONS CHAPTER 6 PAROTID BED AND GLAND**

25. All of the following borders of the parotid bed are matched with the correct structure except one. Which one is the exception?
- A. Anterior—masseter
  - B. Posterior—mastoid process of the temporal bone
  - C. Superior—external acoustic meatus
  - D. Medial—transverse process of the axis
  - E. Posteromedial—stylohyoid muscle
26. All of the following statements are correct except one. Which one is the exception?
- A. Approximately 75% or more of the parotid gland overlies the masseter muscle.
  - B. Facial nerve enters the parotid fossa by passing between the stylohyoid muscle and the posterior belly of the digastric muscle.
  - C. Deep lobe of the parotid gland lies adjacent to the lateral pharyngeal space.
  - D. Buccal and zygomatic branches of the facial nerve form an anastomosing loop superficial to the parotid duct.
  - E. Capsule of the parotid gland is from the superficial cervical fascia.
27. All of the following statements concerning the autonomic innervation of the parotid gland are correct except one. Which one is the exception?
- A. Preganglionic parasympathetic fibers arise from the inferior salivatory nucleus.
  - B. Postganglionic parasympathetic fibers arise from the otic ganglion.
  - C. Postganglionic sympathetic fibers arise from the superior cervical ganglion.
  - D. Preganglionic parasympathetic fibers travel in the greater petrosal nerve.
  - E. Preganglionic parasympathetic fibers travel in the tympanic branch of the glossopharyngeal nerve.

**QUESTIONS CHAPTER 7 TEMPORAL AND INFRATEMPORAL FOSSAE**

28. All of the following are boundaries of the temporal fossa except one. Which one is the exception?
- A. The zygomatic process of the frontal bone is an anterior border.
  - B. The lesser wing of the sphenoid is a posterior border.
  - C. The zygomatic arch is the inferior border.
  - D. The superior temporal line of the skull is the superior border.
  - E. The frontal bone is part of the floor.
29. All of the following are boundaries of the infratemporal fossa except one. Which one is the exception?
- A. The anterior border is the posterior surface of the maxilla.
  - B. The styloid process is a posterior border.
  - C. The ramus of the mandible is a lateral border.
  - D. The medial pterygoid plate is a medial border.
  - E. The infratemporal surface of the sphenoid (greater wing of the sphenoid) is a superior border.
30. All of the following are contents of the infratemporal fossa except one. Which one is the exception?
- A. Pterygopalatine ganglion
  - B. Chorda tympani nerve
  - C. Pterygoid plexus of veins
  - D. Maxillary artery and its branches
  - E. Medial pterygoid
31. All of the following are branches of the 1st part (mandibular part) of the maxillary artery except one. Which one is the exception?
- A. Anterior tympanic
  - B. Middle meningeal
  - C. Inferior alveolar
  - D. Deep auricular
  - E. Pterygoid



**QUESTIONS CHAPTER 8** ***MUSCLES OF MASTICATION***

32. Which of the following depresses the mandible?
  - A. Temporalis (posterior fibers)
  - B. Medial pterygoid
  - C. Lateral pterygoid
  - D. Masseter
  - E. All of the above (A-D) depress the mandible.
33. The deep head of the medial pterygoid originates on which of the following?
  - A. Inferior border of the anterior 2/3rds of the zygomatic arch
  - B. Medial surface of the lateral pterygoid plate
  - C. Medial surface of the medial pterygoid plate
  - D. Lateral surface of the medial pterygoid plate
  - E. Lateral surface of the lateral pterygoid plate
34. Which of the following retrudes the mandible?
  - A. Temporalis (posterior fibers)
  - B. Medial pterygoid
  - C. Lateral pterygoid
  - D. Masseter
  - E. All of the above (A-D) retrude the mandible.
35. The muscles of mastication are innervated by which of the following?
  - A. Trigeminal nerve
  - B. Facial nerve
  - C. Glossopharyngeal nerve
  - D. Vagus nerve
  - E. Hypoglossal nerve

**QUESTIONS CHAPTER 9** ***TEMPOROMANDIBULAR JOINT***

36. Which of the following describes the articular surface of the mandibular condyles?
  - A. Avascular fibrous connective tissue
  - B. Hyaline cartilage
  - C. Elastic cartilage
  - D. Loose areolar connective tissue
  - E. None of the above (A-D)
37. All of the following statements concerning the articular disc are correct except one. Which one is the exception?
  - A. Composed of dense fibrous connective tissue
  - B. Avascular in its central portion
  - C. Divided into 2 bands
  - D. Located between the squamous portion of the temporal bone and the condyle
  - E. Contiguous posteriorly with the bilaminar zone that blends with the capsule
38. Rotational movement of the temporomandibular joint occurs in which of the following?
  - A. Superior compartment
  - B. Inferior compartment
  - C. Superior and inferior compartments
  - D. Bilaminar zone
  - E. None of the above (A-D)
39. All of the following statements concerning the capsule of the temporomandibular joint are correct except one. Which one is the exception?
  - A. Completely encloses the articular surface of the temporal bone and the condyle
  - B. Composed of fibrous connective tissue
  - C. Lined by a highly vascularized synovial membrane
  - D. Has various sensory receptors including nociceptors
  - E. Toughened on the posterior aspect by ligaments

40. The sphenomandibular ligament attaches from the spine of the sphenoid to which of the following?
- A. Lingula of the mandible
  - B. Styloid process
  - C. Condylar process
  - D. Coronoid process
  - E. Zygomatic arch

#### QUESTIONS CHAPTER 10 **PTERYGOPALATINE FOSSA**

41. The nasopalatine nerve exits the pterygopalatine fossa by passing through which of the following?
- A. Pharyngeal
  - B. Sphenopalatine foramen
  - C. Inferior orbital fissure
  - D. Palatine canal
  - E. Foramen rotundum
42. Which of the following nerves pass through the pterygomaxillary fissure?
- A. Posterior superior alveolar
  - B. Zygomatic
  - C. Infraorbital
  - D. Maxillary division of the trigeminal
  - E. Nerve of the pterygoid canal
43. All of the following nerves of the maxillary division of the trigeminal travel communicate with the pterygopalatine ganglion except one. Which one is the exception?
- A. Greater palatine
  - B. Lesser palatine
  - C. Pharyngeal
  - D. Posterior superior alveolar
  - E. Nasopalatine

#### QUESTIONS CHAPTER 11 **NOSE AND NASAL CAVITY**

44. All of the following are a lateral relation of the lateral wall of the nasal cavity except one. Which one is the exception?
- A. Ethmoid sinus
  - B. Orbit
  - C. Pterygopalatine fossa
  - D. Vomer
  - E. Maxillary sinus
45. All of the following are correct except one. Which one is the exception?
- A. Epistaxis is often caused by a rupture of a vessel in Kiesselbach's plexus.
  - B. The ethmoid bone is a superior boundary of the nasal cavity.
  - C. The infratrochlear nerve supplies, at least in part, the nose.
  - D. The palatine process of the maxilla is a superior boundary of the nasal cavity.
  - E. The horizontal plate of the palatine is an inferior boundary of the nasal cavity.
46. All of the following are a superior boundary of the nasal cavity except one. Which one is the exception?
- A. Frontal sinus
  - B. Anterior cranial fossa
  - C. Maxillary sinus
  - D. Sphenoid sinus
  - E. Frontal lobe of the brain
47. The nasolacrimal duct drains into the:
- A. Superior meatus
  - B. Middle meatus
  - C. Inferior meatus
  - D. Bulla ethmoidalis
  - E. Hiatus semilunaris

48. All of the following nerves that supply the nasal cavity are branches of the maxillary division of the trigeminal nerve except one. Which one is the exception?
- Anterior ethmoid
  - Infraorbital
  - Nasopalatine
  - Posterior superior nasal
  - Posterior inferior nasal

## QUESTIONS CHAPTER 12 **PARANASAL SINUSES**

49. Which of the following sinuses drains into the superior meatus?
- Sphenoid sinus
  - Posterior ethmoid sinus
  - Maxillary sinus
  - Frontal sinus
  - Anterior ethmoid sinus
50. All of the following are correct except one. Which one is the exception?
- The nasal cavity is an inferior relation of the frontal sinus.
  - The supraorbital nerve, at least in part, provides sensory innervation to the frontal sinus.
  - The posterior ethmoid sinus is an inferior relation of the frontal sinus.
  - The frontal sinus drains into the middle meatus.
  - The forehead is an anterior relation of the frontal sinus.
51. All of the following are correct except one. Which one is the exception?
- The posterior ethmoid artery, at least in part, supplies the sphenoid sinus.
  - The anterior ethmoid nerve, at least in part, supplies the sphenoid sinus.
  - The sphenoid sinus drains into the sphenoethmoidal recess.
  - The nasal cavity is an anterior relation of the sphenoid sinus.
  - The hypophyseal fossa is a superior relation of the sphenoid sinus.
52. All of the following are correct except one. Which one is the exception?
- The orbit is a lateral relation of the ethmoid sinus.
  - The frontal lobe of the brain is a posterior relation of the anterior ethmoid sinus.
  - The ethmoid sinuses are supplied, at least in part, by the posterior lateral nasal branches.
  - The ethmoid sinuses are supplied, at least in part, by the anterior ethmoid nerve.
  - The ethmoid sinuses are supplied, at least in part, by the posterior ethmoid nerve.
53. All of the following are correct except one. Which one is the exception?
- The infraorbital nerve is a superior relation of the maxillary sinus.
  - The nasal cavity is a medial relation of the maxillary sinus.
  - The 2nd maxillary molar is an inferior relation of the maxillary sinus.
  - The posterior superior alveolar nerve provides innervation to, at least in part, the maxillary sinus.
  - The ostium of the maxillary sinus is located on the inferior part of the wall of the sinus.

## QUESTIONS CHAPTER 13 **ORAL CAVITY**

54. All of the following boundaries of the oral cavity are correct except one. Which one is the exception?
- The superior boundary is the roof of the hard palate.
  - The lateral boundary is the cheek.
  - The posterior-superior boundary is the soft palate.
  - The inferior boundary is the floor located along the lingual border of the mandible.
  - The anterior border is the choanae.
55. All of the following statements concerning the hard palate are correct except one. Which one is the exception?
- Is composed of the palatal process of the maxilla
  - Separates the oral cavity from the nasal cavity
  - Is covered by a thin mucous membrane
  - Is composed of the horizontal process of the palatine
  - Has lateral transverse ridges called transverse rugae on the mucous membrane

56. All of the following muscles of the soft palate are innervated by the pharyngeal plexus of nerves except one. Which one is the exception?
- Tensor veli palatini
  - Levator veli palatini
  - Musculus uvulae
  - Palatoglossus
  - Palatopharyngeus
57. All of the following statements concerning the surfaces of the tooth are correct except one. Which one is the exception?
- The labial surface is the surface of the anterior teeth that is closest to the lip.
  - The mesial surface is the surface closest to the midline of the dental arch.
  - The incisal surface is the cutting edge of the anterior teeth.
  - The distal surface is the surface farthest from the midline of the dental arch.
  - The buccal surface is the surface of the anterior teeth that is furthest from the cheek.
58. All of the following are involved in the autonomic pathway to the sublingual gland except one. Which one is the exception?
- Chorda tympani nerve
  - Inferior salivatory nucleus
  - Superior salivatory nucleus
  - Submandibular ganglion
  - All of the above (A-D) are involved in the autonomic pathway to the sublingual gland.

#### QUESTIONS CHAPTER 14 TONGUE

59. Which of the following nerves does not provide any sensory innervation to the tongue?
- Lingual nerve
  - Glossopharyngeal nerve
  - Hypoglossal nerve
  - Internal laryngeal nerve
  - All of the above (A-D) provide some sensory innervation to the tongue.
60. Which vessel is responsible for rapid absorption of drugs such as nitroglycerin?
- Sublingual artery
  - Sublingual vein
  - Deep lingual artery
  - Deep lingual vein
  - Dorsal lingual artery
61. All of the following statements concerning the hypoglossal nerve are correct except one. Which one is the exception?
- Innervates the intrinsic muscles of the tongue
  - Exits the skull through the hypoglossal canal
  - Lies superficial to the lingual artery
  - Passes deep to the hyoglossus muscle
  - Innervates the styloglossus
62. A patient with a lesion of the left hypoglossal nerve will present with which of the following signs?
- Loss of general sensation over the anterior 2/3rds of the left side of the tongue
  - Partial loss of taste
  - Deviation of the tongue to the left upon protrusion
  - Loss of general sensation from the left margin of the tongue
  - Deviation of the tongue to the right upon protrusion
63. All of the following statements concerning the lingual artery are correct except one. Which one is the exception?
- Branches off of the external carotid artery
  - Lies superficial to the middle constrictor
  - Lies superficial to the hyoglossus
  - Has a sublingual branch
  - Has a deep lingual branch

## QUESTIONS CHAPTER 15 PHARYNX

64. All of the following are correct except one. Which one is the exception?
  - A. The superior constrictor attaches to the pterygoid hamulus.
  - B. The stylopharyngeus is innervated by the glossopharyngeal nerve.
  - C. The middle constrictor attaches to the hyoid bone.
  - D. The ostium of the auditory tube is located in the nasopharynx.
  - E. All of the above (A-D) are correct.
65. All of the following are correct except one. Which one is the exception?
  - A. The tongue is the floor of the nasopharynx.
  - B. The ostium of the auditory tube is located on the lateral wall of the nasopharynx.
  - C. The anterior relation of the nasopharynx is the choanae.
  - D. The superior constrictor attaches to the pterygomandibular raphe.
  - E. The vallecula is the space between the posterior 1/3rd of the tongue and the epiglottis.
66. Which of the following does not pass through the pharyngeal aperture, which is located superior to the superior constrictor?
  - A. Ascending pharyngeal artery
  - B. Ascending palatine artery
  - C. Levator veli palatini
  - D. Auditory tube
  - E. Tensor veli palatini
67. All of the following either contribute to, or are innervated by, the pharyngeal plexus except one. Which one is the exception?
  - A. Spinal portion of the spinal accessory nerve
  - B. Palatopharyngeus
  - C. Vagus nerve
  - D. Middle constrictor
  - E. Salpingopharyngeus
68. Which of the following vessels that supplies the pharynx is a branch of the facial artery?
  - A. Ascending pharyngeal
  - B. Ascending palatine
  - C. Pharyngeal
  - D. Superior thyroid
  - E. Inferior thyroid

## QUESTIONS CHAPTER 16 LARYNX

69. All of the following statements concerning the larynx are correct except one. Which one is the exception?
  - A. The larynx is formed by 9 cartilages.
  - B. The larynx is larger in females.
  - C. The larynx is located between cervical vertebrae C3-C6.
  - D. A lateral relation of the larynx is the carotid sheath.
  - E. A superior relation of the larynx is the vallecula.
70. Which muscle(s) act(s) as an antagonist to the transverse arytenoid muscle?
  - A. Oblique arytenoid muscle
  - B. Thyroarytenoid
  - C. Posterior cricoarytenoid muscle
  - D. Cricothyroid muscle
  - E. A and C only
71. All of the following statements concerning the larynx are correct except one. Which one is the exception?
  - A. The primary site for establishing an emergency airway is the median cricothyroid ligament.
  - B. The epiglottis is composed of elastic cartilage.
  - C. The cricoid cartilage is the only cartilage of the larynx that is a complete ring.
  - D. The cranial nerve responsible for innervation of the larynx is the vagus (X).
  - E. All of the above (A-D) are correct.

72. The free edge of the quadrangular membrane is also known as the:  
 A. Conus elasticus  
 B. Vocal ligament  
 C. Vocalis  
 D. Cricovocal membrane  
 E. Vestibular ligament
73. All of the following statements concerning the true vocal cord are correct except one. Which one is the exception?  
 A. Is made up, at least in part, by the conus elasticus  
 B. Is located inferior to the false vocal cord  
 C. Is made up, at least in part, by the vocal ligament  
 D. Receives its sensory innervation from the glossopharyngeal nerve  
 E. All of the above (A-D) are correct.

## QUESTIONS CHAPTER 17 CERVICAL FASCIA

74. All of the following are contents of the carotid sheath except one. Which one is the exception?  
 A. Vagus nerve  
 B. Common carotid artery  
 C. Internal jugular vein  
 D. External carotid artery  
 E. Internal carotid artery
75. All of the following are contents of the sublingual space except one. Which one is the exception?  
 A. Hypoglossal nerve  
 B. Lingual nerve  
 C. Sublingual gland  
 D. Submandibular duct  
 E. Anterior digastric
76. All of the following statements concerning the lateral pharyngeal space are correct except one. Which one is the exception?  
 A. Is continuous with the retropharyngeal space posteriorly  
 B. Is continuous with the submandibular space anteriorly  
 C. Extends from the base of the skull to the hyoid bone  
 D. Contains the masseter  
 E. Bounded medially by the buccopharyngeal fascia

## QUESTIONS CHAPTER 18 EAR

77. All of the following statements concerning the middle ear are correct except one. Which one is the exception?  
 A. The roof of the middle ear is made by the tegmen tympani.  
 B. The auditory tube is located in the anterior wall of the middle ear.  
 C. The promontory is located along the medial wall of the middle ear.  
 D. The epitympanic recess is located along the posterior wall.  
 E. The tendon of the tensor tympani enters the middle ear through the medial wall.
78. All of the following are parts of the membranous labyrinth except one. Which one is the exception?  
 A. Cochlear duct  
 B. Sacculle  
 C. Utricle  
 D. Semicircular canals  
 E. Malleus
79. All of the following vessels supply the external ear except one. Which one is the exception?  
 A. Superficial temporal artery  
 B. Deep auricular artery  
 C. Posterior auricular artery  
 D. Anterior tympanic artery  
 E. Middle meningeal artery



**QUESTIONS CHAPTER 19 EYE AND ORBIT**

80. All of the following bones make up the medial wall of the orbit except one. Which one is the exception?  
A. Maxilla  
B. Lacrimal  
C. Ethmoid  
D. Nasal  
E. All of the above (A-D) make up the medial wall of the orbit.
81. Which of the following is a boundary of the optic foramen?  
A. Ethmoid  
B. Greater wing of the sphenoid  
C. Lesser wing of the sphenoid  
D. Frontal  
E. Lacrimal
82. The greater wing of the sphenoid bone and maxilla are separated by which of the following?  
A. Optic foramen  
B. Dorsum sella  
C. Inferior orbital fissure  
D. Superior orbital fissure  
E. None of the above
83. If the inferior oblique muscle is paralyzed, in what position will the eye point?  
A. Up and out  
B. Down and in  
C. Down and out  
D. Up and in  
E. Up

**QUESTIONS CHAPTER 20 AUTONOMICS OF THE HEAD AND NECK**

84. All of the following are correct except one. Which one is the exception?  
A. A collection of nerve cell bodies in the peripheral nervous system is called a ganglion.  
B. Glands are innervated by the autonomic nervous system.  
C. Skeletal muscle is innervated by the autonomic nervous system.  
D. Cardiac Muscle is innervated by the autonomic nervous system.  
E. A preganglionic sympathetic neuron begins in the central nervous system.
85. At vertebral level L1, what is the connection to the sympathetic chain that allows preganglionic sympathetic fibers to enter?  
A. Grey ramus  
B. White ramus  
C. Dorsal ramus  
D. Ventral ramus  
E. None of the above (A-D)
86. All of the following are correct except one. Which one is the exception?  
A. White ramus is unmyelinated.  
B. Parasympathetics are also called craniosacral fibers.  
C. The nervus intermedius contains preganglionic parasympathetic fibers.  
D. Preganglionic fibers are myelinated.  
E. Gray ramus contains postganglionic parasympathetic nerves.
87. The greater petrosal nerve carries  
A. Preganglionic parasympathetic fibers  
B. Postganglionic sympathetic fibers  
C. Postganglionic parasympathetic fibers  
D. Preganglionic sympathetic fibers  
E. A and B only  
F. B and C only  
G. A and D only

88. Preganglionic parasympathetics are found in all of the following nerves except one. Which one is the exception?
- Tympanic branch of IX
  - Tympanic plexus
  - Lesser petrosal
  - Chorda tympani
  - All of the above (A-D) contain preganglionic parasympathetics.

## QUESTIONS CHAPTER 21 *INTRAORAL INJECTIONS*

89. All of the following areas are anesthetized in an inferior alveolar nerve block except one. Which one is the exception?
- All mandibular teeth
  - Epithelium of posterior 1/3rd of the tongue
  - All lingual gingiva
  - Skin of the lower lip
  - All lingual mucosa
90. Which of the following injections is considered a "blind injection?"
- Inferior alveolar nerve block
  - Gow-Gates nerve block
  - Akinosi nerve block
  - Mental nerve block
  - Posterior superior alveolar nerve block
91. Which of the following nerve blocks has a significant risk for a hematoma of the pterygoid plexus?
- Inferior alveolar nerve block
  - Nasopalatine nerve block
  - Infraorbital nerve block
  - Greater palatine nerve block
  - Posterior superior alveolar nerve block

## QUESTIONS CHAPTER 22 *INTRODUCTION TO THE UPPER LIMB, BACK, THORAX, AND ABDOMEN*

92. The lateral cord of the brachial plexus is derived from:
- Ventral rami of C5-T1
  - Ventral rami of C5-C7
  - Ventral rami of C8-T1
  - Ventral rami of C7 only
  - Dorsal rami of C5-T1
93. All of the following are contents of the posterior mediastinum except one. Which one is the exception?
- Esophagus
  - Lesser splanchnic nerve
  - Thoracic duct
  - Bronchial arteries
  - Trachea
94. All of the following are contents of the superior mediastinum except one. Which one is the exception?
- Inferior vena cava
  - Trachea
  - Thoracic duct
  - Vagus
  - Esophagus
95. From what immediate vessel does the inferior suprarenal artery arise?
- Inferior phrenic artery
  - Abdominal aorta
  - Renal artery
  - Lumbar artery
  - Gonadal artery

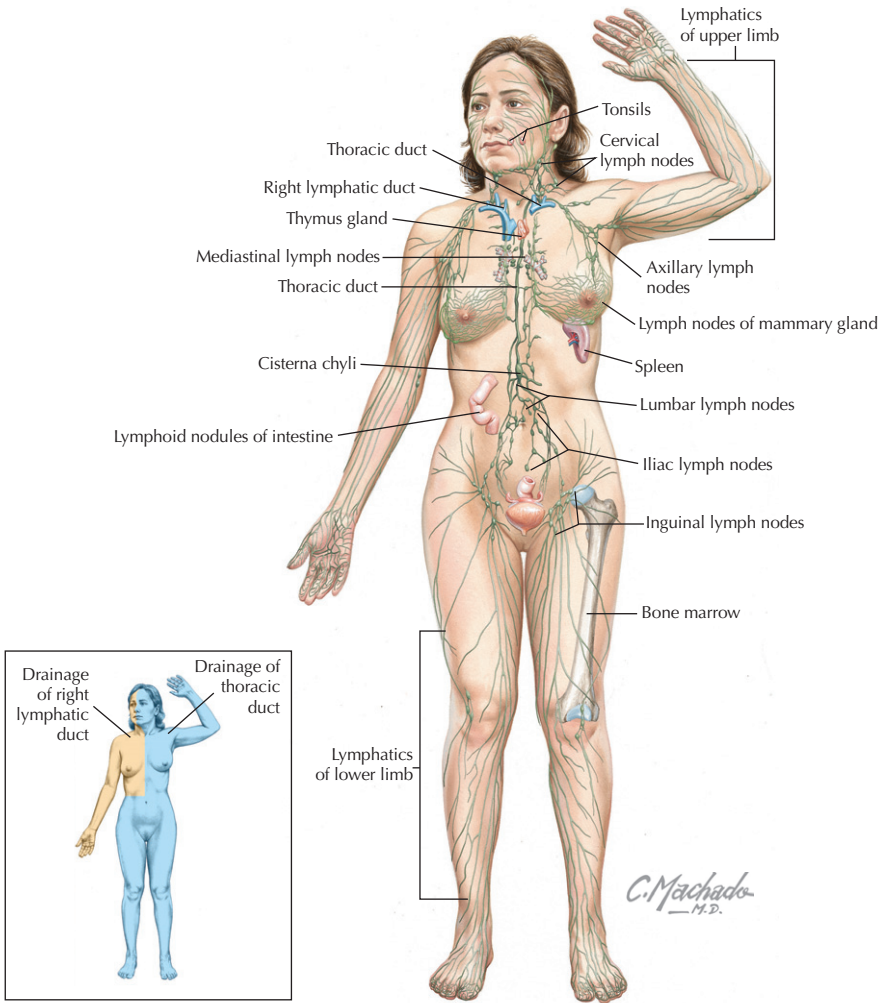
96. Which of the following structures is a retroperitoneal organ?
- Transverse colon
  - Spleen
  - Head and neck of pancreas
  - 4th part of the duodenum
  - Kidney
  - C and D only
  - C and E only
  - B, C, and E only
  - A, C, and E only
  - C, D, and E only
97. The nerve that innervates the muscle that INITIATES Abduction is which of the following?
- Upper subscapular
  - Dorsal scapular
  - Suprascapular
  - Axillary
  - Lower subscapular
98. Which of the following nerves arise as immediate branches from the upper trunk of the brachial plexus?
- Suprascapular
  - Subclavius
  - Supraclavicular
  - Dorsal scapular
  - Long thoracic
  - A & B only
  - A & C only
  - B & C only
  - A, B, & C only
  - A, B, C, & D only
99. Which of the following structures is found between the right lobe of the liver and the quadrate lobe of the liver?
- Ligamentum venosum
  - Ligamentum arteriosum
  - Inferior vena cava
  - Gallbladder
  - A & B
100. Which of the following attach to the Lesser tubercle?
- Teres minor
  - Supraspinatus
  - Subscapularis
  - Infraspinatus
  - A, B, & C only

## Appendix B

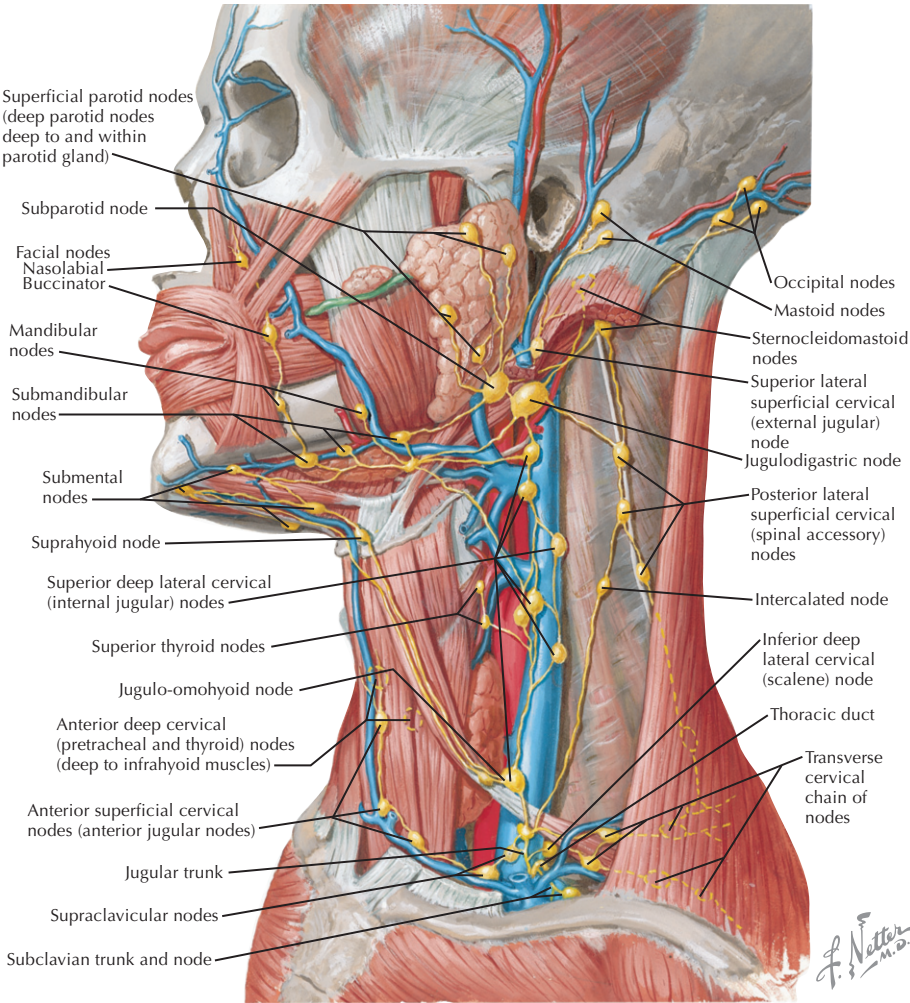
# Lymphatics

Overview and the Lymphatic System	634
Lymph Vessels and Nodes of Head and Neck	635
Lymphatic Drainage of Mouth and Pharynx	636

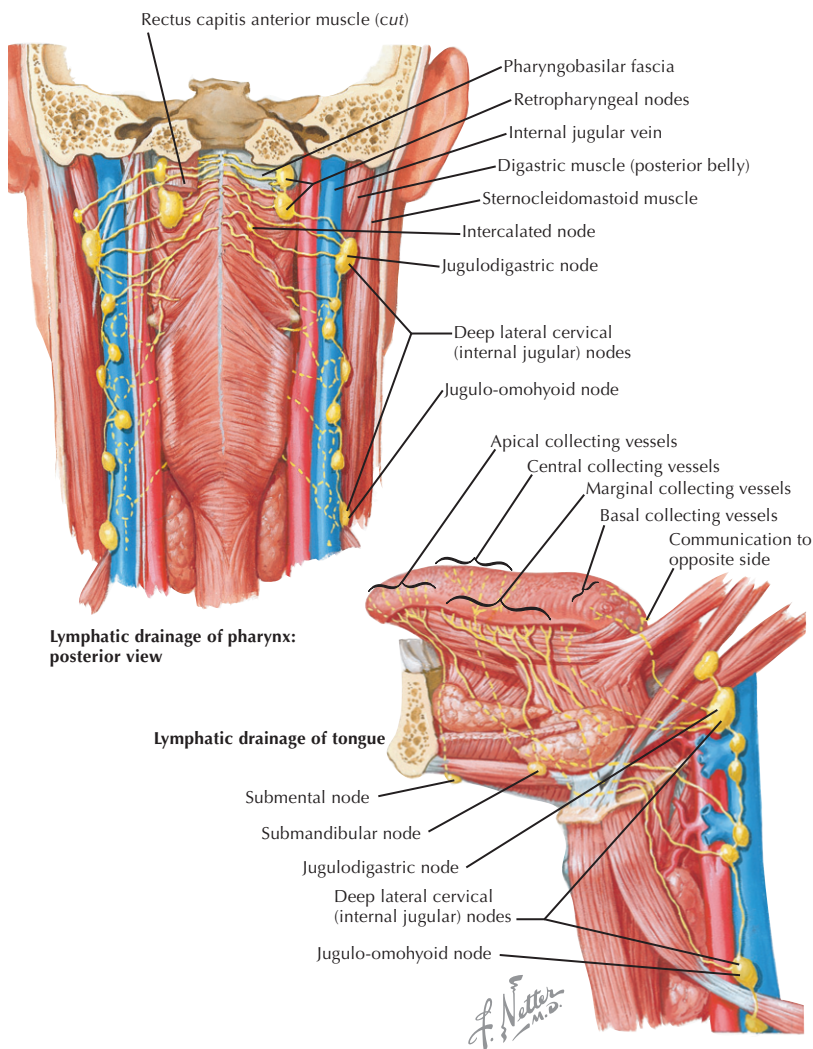
# Lymphatics



# Lymphatics







**A**

- Abdomen.** *See also* Abdominal wall  
arterial supply to  
paired parietal, 609, 609f  
paired visceral, 609, 609f  
unpaired visceral, 607-608, 607-608f  
bones of, 566t, 567f  
duodenum in, 590, 590f  
gallbladder and duct system in, 597, 597f  
ileum in, 591, 592f  
jejunum in, 591, 592f  
kidneys in, 599, 600f  
large intestine in, 593-594, 594f  
liver in, 595, 595f  
muscles of, 580t, 581f  
overview of, 556t, 557f  
pancreas in, 596, 596f  
spleen in, 598, 598f  
stomach in, 589, 589f  
suprarenal glands in, 599, 600f  
ureters in, 599, 600f  
viscera of, venous drainage from, 610-611, 610f
- Abdominal wall**  
anterolateral, overview of, 556t, 557f  
posterior  
nerve supply to, 617, 617f  
venous drainage from, 612, 612f
- Abducens (VI) nerve**  
eye and orbit innervation by, 495t, 496f  
fibers and functional column types of, 80f, 80t  
ophthalmoplegia and, 103, 103f, 183  
in peripheral nervous system, 74, 74f
- Abductor digiti minimi muscle,** 575t, 576f
- Abductor pollicis brevis muscle,** 574f, 574t, 575t, 576f
- Abductor pollicis longus muscle,** 574f, 574t
- Abscesses,** 449
- Accessory meningeal artery,** 212t, 213f
- Accessory nerve.** *See* Spinal accessory (XI) nerve
- Acute otitis externa,** 476, 476f
- Acute otitis media,** 477, 477f
- Acyclovir,** 376
- Adam's apple,** 423t
- Adenocarcinoma,** of parotid gland, 199, 199f
- Adenoids,** 377, 404t, 405f
- Adenoma,** of parotid gland, 199
- Adrenal glands,** 599, 600f
- Afferent general or special functional columns,** of cranial nerves, 74f, 75, 75f
- Akinosi nerve block,** 544t, 545f
- Ala,** of nose, 268f
- Alar, deep layer of deep fascia and,** 108
- Alar branches of facial artery,** 271t
- Alar cartilage,** 268, 269f, 278f
- Alar fascia,** 440f, 441t
- Alar fibrofatty tissue,** 269f
- Alar ligament,** 59t, 60f
- Allergic rhinitis,** 297, 297f
- Alveolar process**  
of mandible, 45t  
of maxilla, 43t, 44f, 110f
- Alveolar ridge,** 24f
- Alveolus,** 23, 63
- Amacrine cell,** 490f
- Ametropias,** 510f
- Ampulla,** of semicircular canals, 459t
- Anatomic crown,** 342t
- Anatomic root,** 342t
- Anconeus muscle,** 571t
- Aneurysms,** nerves affected by, 103, 103f
- Angular artery,** 168f, 169t, 170f, 172f, 283f
- Angular part of levator labii superioris muscle,** 162t
- Angular tract of Eisler,** 187t
- Angular vein**  
from eye and orbit, 502t, 503f  
from face, 168f, 173t, 174f  
from nose, 272f, 272t
- Ankyloglossia,** 397, 397f
- Ankylosis,** of TMJ, 245, 246f
- Ansa cervicalis**  
carotid triangle and, 115t, 116f  
infrahyoid muscles and, 128t  
muscular triangle and, 117t, 118f  
neck innervation by, 145, 145t, 146f  
omohyoid muscle and, 127t
- Antebrachium,** muscles of, 572t, 573f, 574f, 574t
- Anterior auricular artery,** 168f
- Anterior auricular muscle,** 166t, 167f
- Anterior ciliary artery,** 500t
- Anterior cranial fossa,** 277t
- Anterior deep cervical lymph nodes,** 635f
- Anterior deep temporal artery**  
to infratemporal fossa, 212t, 213f  
to masticatory muscles, 228t, 229f  
to temporal fossa, 206t, 206t
- Anterior deep temporal nerve,** 209f
- Anterior deep temporal vein,** 207t, 230t
- Anterior digastric muscle,** 82t, 82t, 112f, 113, 114f
- Anterior division of anterior deep temporal branch of mandibular nerve**  
course of, 89t  
infratemporal fossa, 216t, 217f, 218f  
masticatory muscles, 231t, 232f  
temporal fossa, 208t
- Anterior division of buccal branches of mandibular nerve**  
course of, 89t  
face, 178f, 178t  
infratemporal fossa, 216t, 217f, 218f  
parotid bed, 186, 186f, 189f
- Anterior division of lateral pterygoid branch of mandibular nerve,** 89t, 216t, 217f
- Anterior division of medial pterygoid branch of mandibular nerve,** 89t, 216t, 217f
- Anterior division of posterior deep temporal branch of mandibular nerve**  
course of, 89t  
infratemporal fossa, 216t, 217f, 218f  
masticatory muscles, 231t, 232f  
temporal fossa, 208t  
temporomandibular joint, 242t
- Anterior ethmoid foramen**  
anterior view, 55f, 55t  
in orbit, 482t  
in superior view of cranial base, 51t, 52f
- Anterior ethmoidal artery**  
to ethmoid sinuses, 309f, 309t  
to eye and orbit, 500t, 501f  
to frontal sinuses, 305f, 305t  
to nasal cavity, 281t, 282f
- Anterior ethmoidal nerve**  
internal and external nasal branches of, 285f, 288f, 289f  
in nasociliary branch of trigeminal nerve ophthalmic division, 84t, 85f, 88f
- Anterior ethmoidal nerve, course of**  
ethmoid sinuses, 310f, 310t  
eye and orbit, 493f, 493t  
nasal cavity, 287t

# Index

Anterior jugular vein, 117t, 119t  
 Anterior longitudinal ligament, 409f  
 Anterior malleolar fold, 455t, 458f  
 Anterior median fissure, of spinal cord, 71f  
 Anterior nares, 268, 268f  
 Anterior nasal spine, 269f  
 Anterior superior alveolar artery, 312f, 312t, 355t, 356f  
 Anterior superior alveolar nerve  
   course of, 87t, 88f  
   maxillary sinus, 313f, 313t  
   teeth, 359t  
   intraoral injections and, 546  
   nasal branch of, 288f  
 Anterior superior alveolar nerve block, 552f, 552t  
 Anterior superior alveolar vein, 356t  
 Anterior triangle  
   general information about, 111, 111-112f  
   as neck descriptor, 108  
   subdivisions of  
     carotid, 115, 115t, 116f  
     muscular, 117, 117t, 118f  
     submandibular, 113, 113t, 114f  
     submental, 119, 119f, 119t  
 Anterior tympanic artery  
   to external ear, 468t, 469f  
   to infratemporal fossa, 212t, 213-214f  
   to middle ear, 470t, 471f  
   to temporomandibular joint, 240f, 240t  
 Antihelix, of auricle, 455t  
 Antitragus, 455t, 456f  
 Antrostomy, 321  
 Apex of nose, 268  
 Apex of root of a tooth, 342t  
 Apex process of arytenoid cartilage, 425f, 425t  
 Apical foramina, 343f  
 Apical ligament of dens, 59t, 60f  
 Aponeurosis, 156f, 156t, 158f  
 Appendix, 593, 594f  
 Arachnoid, of spine, 71f  
 Arachnoid foveae, 28t  
 Arthritis, of TMJ, 245, 246f  
 Articular disc, 236, 236f, 237t  
 Aryepiglottic fold, 403f, 405f, 418f  
 Aryepiglottic muscle, 429f, 429t  
 Arytenoid cartilages, 409f, 422f, 422t, 425f, 425t, 427f  
 Arytenoid swelling, tongue development and, 17f, 17t  
 Ascending colon, 593, 594f  
 Ascending palatine artery  
   to oral cavity floor, 354t, 355f  
   to palate, 352t, 353f  
   to pharynx, 411t, 412f  
 Ascending pharyngeal artery  
   carotid triangle and, 115t, 116f  
   to neck, 132, 132t, 134t, 135f  
   to palate, 352t, 353f  
   to pharynx, 411t, 412f  
 Asterion, parietal bones at, 29t  
 Astigmatism, 510, 510f  
 Astrocytes, 67, 67f  
 Atlantoaxial joint, major internal ligaments for, 60f  
 Atlanto-occipital membrane, 58f, 58t, 122  
 Atlas (C1)  
   as cervical vertebrae, 56f, 56t  
   Jefferson fracture of, 64, 64f  
   rotary subluxation of, torticollis and, 150f  
   suboccipital triangle and, 122, 122f  
   transverse ligament of, 59t, 60f  
 Atrium, of nose, 268  
 Atrophy, of tongue, 106f, 398, 398f  
 Auditory tube. *See* Pharyngotympanic tube  
 Auricle, 455t, 456f  
 Auricular branch of vagus (X) nerve, 139t, 463t, 465f  
 Auricular group, of muscles of facial expression, 166t, 167f  
 Auricular muscle, 166t  
 Auricular tubercle (of Darwin), 456f  
 Autonomic nervous system, 511-534. *See also*  
   Parasympathetic nervous system; Sympathetic nervous system  
   2-neuron chain system, 512  
   clinical correlate for, 534, 534f

Autonomic nervous system (*Continued*)  
   divisions of, 512, 515t  
   functions of, 515t, 516-518f  
   general information about, 512, 513-514f  
   parotid gland innervation by, 194t  
   peripheral nervous system and, 72  
   salivary glands in, 368f, 368t, 369f, 370t, 371f  
   vagus nerve in, 533f, 533t  
 Axis (C2), 56f, 56t  
   fractures of, 64, 64f  
 Axons, 66, 66f

## B

Back  
   bones of, 562t, 563f  
   muscles of, 577t, 578f  
 Bacterial infections, 196, 200  
 Basilar artery, 103, 103f  
 Basilar membrane, 454f, 461f  
 Bell's palsy, 93t, 196, 197f, 538t, 544t  
 Biceps brachii muscle, 571t, 572f  
 Bilaminar zone, of TMJ, 238t  
 Bipolar neurons, 66, 66f  
 Bitemporal hemianopsia, 78t  
 Black hairy tongue, 380, 381f  
 Bleeding, mandibular fractures and, 63f  
 Blepharoplasty, 164t  
 Blind spot, 486  
 Bone(s), 25-64  
   articulations of, 27f, 27t  
   cervical vertebrae, 56-60, 562t, 563f  
   derived from pharyngeal arches, 4, 5t, 6f, 6t  
   fractures of, 62-64, 62-64f, 154  
   general information about, 26  
   intraoral injections and  
     mandibular, 537, 537f  
     maxillary, 546, 546-547f  
   skull. *See* Skull  
 Bone marrow, 634f  
 Brachial plexus  
   neck innervation by, 147f, 147t  
   posterior triangle and, 120t, 121f  
   in root of the neck, 125t  
   upper limb innervation by, 614-616t, 616f  
 Brachialis muscle, 571t, 572f  
 Brachiocephalic veins, 125t, 126f  
 Brachioradialis muscle, 574f, 574t  
 Brachium, 571f, 571t, 602, 602f  
 Brain, 68f, 69, 69f  
 Brainstem, 69  
 Bregma, 29f, 29t  
 Buccal artery  
   to face, 169t, 170f  
   to infratemporal fossa, 212t, 213f  
   to lips and cheeks, 328t, 329f  
   to masticatory muscles, 228t, 229f  
 Buccal branches of facial nerve, 161t, 180t, 181f, 330f, 330t  
 Buccal branches of mandibular nerve, 331f, 331t  
 Buccal nerve, 537, 539f, 540f  
 Buccal shelf, 45t  
 Buccal surface of teeth, 341t, 342f  
 Buccal vein, 173t, 230t, 329f, 329t  
 Buccinator lymph nodes, 635f  
 Buccinator muscle  
   cheeks and, 327t  
   facial expression and, 162t, 163f  
   long buccal nerve block and, 540f  
   mastication and, 224f, 226f, 227f, 233  
   oral cavity floor and, 339f  
   pharyngeal muscles and, 408f, 409f  
   soft palate and, 337f  
 Buccopharyngeal fascia, 409f, 440f, 441t, 445f

## C

C cells, 123  
 Calcarine fissure, 78f  
 Calcitonin, 123  
 Caldwell-Luc procedure, 321, 321f  
 Camper's layer, of abdominal wall, 556t, 557f  
 Canines (cuspids), 342f, 344t, 345f, 348f, 348t

- Capsule**  
 of inner ear, 460f  
 of parotid gland, 186, 187t, 188t, 199, 202f, 445t  
 of temporomandibular joint, 238t, 239f, 240f, 242f, 243  
 of vertebral joints, 58f, 60f
- Carbamazepine**, 182
- Cardiac vagal branches of vagus nerve**, 139t, 140t
- Caries**, 373, 373f
- Caroticotympanic branch of internal carotid artery**, 470t, 471f
- Carotid arteries. See Common carotid arteries; External carotid artery; Internal carotid artery**
- Carotid canal**  
 in inferior view of cranial base, 53t, 54f  
 in superior view of cranial base, 51t, 52f  
 temporal bone and, 32t, 33f
- Carotid sheath**, 108, 442f, 442t  
 fascial space and, 446t, 447f
- Carotid triangle**, 109f, 111, 115, 115t, 116f
- Carpal bones**, 561f, 561t
- Carpus**, 604, 604f
- Cartilage**, derived from pharyngeal arches, 5t, 6f, 6t
- Cartilaginous neurocranium**, 10, 12t
- Cauda equina**, 70f
- Cavernous sinus**  
 eye and orbit drained by, 502t, 503f  
 face drained by, 173, 173f, 174f, 174t  
 sphenoid bone and, 34t  
 sphenoidal sinus and, 314, 314f
- Cavernous sinus syndrome**, 183, 184f
- Cecum**, 593, 594f
- Celiac artery**, 607, 607f
- Cellulitis**, 317, 446t, 448
- Cementum**, 343t
- Central incisors**, 342f, 344t, 345f, 349f, 349t
- Central nervous system**, 517f  
 brain and, 68f, 69, 69f  
 spinal cord and, 70, 70-71f
- Central retinal artery**, 485f, 500t, 501f
- Central retinal vein**, 485f
- Central sulcus (of Rolando)**, 68f, 69
- Cerebellum**, 30t, 69, 69f
- Cerebral aneurysms, ophthalmoplegia and**, 103, 103f
- Cerebral nerves. See Cranial nerves**
- Cerebrovascular accidents**, 104
- Cerebrum**, 68f, 69
- Cervical branch of facial nerve**, 180t, 181f, 189f
- Cervical emphysema**, 450, 450f
- Cervical enlargement, of spinal cord**, 70, 70f
- Cervical fascia**, 437-450  
 clinical correlates for, 448-450, 448-450f  
 deep, 441-442t, 442f  
 general information about, 438, 438-439f  
 spaces of, 443, 443f  
 infrahyoid, 446t  
 suprahyoid, 444-445t, 445f  
 traversing length of neck, 446t, 447f  
 superficial, 440, 440f
- Cervical ganglia**, 148, 148f
- Cervical line, of tooth**, 343t
- Cervical lymph nodes**, 634f
- Cervical plexus**  
 facial innervation by, 175, 175f, 179f, 179t  
 neck innervation by, 143, 144f, 145, 145t, 146f  
 scalp innervation by, 159, 159t, 160f
- Cervical spinal nerves**, 70, 70f, 73f  
 ventral rami of, 121f, 128t
- Cervical vertebrae**  
 fractures of, 64, 64f  
 major ligaments of  
 external, 58f, 58t  
 internal, 59t, 60f  
 parts and characteristics of, 56f, 56t, 57f, 562t, 563f
- Cheeks. See also Facial expression**  
 arterial supply to, 328t, 329f  
 development of, 13t  
 motor innervation of, 330f, 330t  
 as oral cavity boundary, 337, 338f  
 sensory innervation of, 331f, 331t
- Cheeks (Continued)**  
 structural features of, 327t  
 venous drainage from, 329f, 329t
- Children, inferior alveolar nerve block in**, 538t
- Choanae (posterior nares)**, 16f, 277f, 277t, 404t, 405f
- Chorda tympani branch of facial nerve, course of**  
 infratemporal fossa, 210, 219t, 220f, 221f  
 for lacrimal, nasal, palatine, pharyngeal, submandibular, and sublingual glands, 525t  
 oral cavity floor, 363t, 636f  
 salivary glands, 370t  
 tongue, 391f, 391t
- Chorda tympani nerve**, 456f, 457t, 458f, 539f
- Choroid**, 485f, 486, 490f
- Chromosome 5, Treacher Collins syndrome and**, 21
- Chromosome 22, DiGeorge syndrome and**, 22
- Ciliary body**, 485f, 486, 490f
- Ciliary ganglion**  
 characteristics of, 521t  
 GVE fibers and, 80t  
 nerve roots connected to, 497t, 498f  
 nerve supply to nasal cavity and, 289f  
 in orbit, 490f, 493f
- Ciliary muscle**, 81f
- Ciliary processes**, 485f
- Cingulum**, 343t
- Circular esophageal muscle**, 403f, 409f
- Circumvallate papillae. See Vallate papillae**
- Class II malocclusion, inferior alveolar nerve block in**, 538t
- Class III malocclusion, inferior alveolar nerve block in**, 538t
- Clavicle**, 112f, 120, 558f, 558t
- Cleft lip and palate**, 23, 24f
- Clinical crown**, 342t
- Clinical root**, 342t
- Clivus**, 30t, 34t, 35f, 60f
- Closed angle glaucoma**, 507
- Coccygeal area, of spinal cord**, 70
- Coccygeal spinal nerves**, 70, 70f, 73f
- Coccyx**, 70f, 562t, 563f
- Cochlea**, 454f, 459t
- Cochlear duct**, 459t, 460f, 461f
- Cochlear nerve**, 467f, 467t
- Collateral ligaments**, 238t
- Commissure of lips**, 268f, 327f, 327t
- Common carotid arteries**, 125t, 135f, 158f, 168f. *See also*  
 External carotid artery; Internal carotid artery
- Common facial vein**, 115t, 116f
- Common tendinous ring**, 487t, 488f
- Complete cleft of lip and palate**, 23, 24f
- Compressor naris muscle**, 164t
- Concha bullosa**, 298f
- Conchae**  
 of auricle, 455t, 456f  
 nasal  
 ethmoid labyrinth and, 38t  
 in facial skeleton, 155f  
 inferior, 41f, 41t, 42f, 279f, 298f  
 lacrimal bones and, 36f, 36t  
 on lateral walls, 276, 276f  
 middle, 279f, 279t, 280f, 298f  
 as nasal cavity boundary, 277t, 278f  
 structures articulating with, 27f, 27t  
 structures drained by, 279-280f, 279t
- Condylar canal**, 51t, 52f, 53t, 54f
- Condylar process**, 45t, 46f, 110t, 210t
- Cone of light**, 456f
- Cones, retinal**, 78t, 79f, 490f
- Connective tissue**  
 of the scalp, 156f, 156t, 159t  
 structures, derived from pharyngeal arches, 5t
- Consciousness, trigeminal (V) nerve and**, 82t
- Constrictor muscles. See Pharyngeal constrictor muscles**
- Conus elasticus**, 428f, 428t
- Conus medullaris**, 70f
- Coracobrachialis muscle**, 571t
- Corniculate cartilage**, 422f, 422t, 427f, 427t
- Corniculate tubercle**, 403f
- Coronoid arch**, 537
- Coronoid notch**, 538t, 539f

# Index

- Coronoid process, 45t, 46f, 63, 110f
  - Corpus callosum, 69f
  - Corrugator supercilii muscle, 164t, 165f
  - Corti, spiral organ of, 95f, 95t, 461f
  - Costal facets, 57f
  - Costocervical artery, 132, 132t, 133f
  - Cranial nerves, 74-102. *See also* Neuroanatomy
    - I (olfactory). *See* Olfactory (I) nerves
    - II (optic). *See* Optic (II) nerve
    - III (oculomotor). *See* Oculomotor (III) nerve
    - IV (trochlear). *See* Trochlear (IV) nerve
    - V (trigeminal). *See* Trigeminal (V) nerve
    - VI (abducens). *See* Abducens (VI) nerve
    - VII (facial). *See* Facial (VII) nerve
    - VIII (vestibulocochlear). *See* Vestibulocochlear (VIII) nerve
    - IX (glossopharyngeal). *See* Glossopharyngeal (IX) nerve
    - X (vagus). *See* Vagus (X) nerve
    - XI (spinal accessory). *See* Spinal accessory (XI) nerve
    - XII (hypoglossal). *See* Hypoglossal (XII) nerve
    - clinical correlates for, 103-106, 103-106f
    - derived from pharyngeal arches, 4, 5t
    - fibers and functional column types of, 75
    - general information about, 74
    - orbit innervation by, 489t, 491-494t, 491f, 493-494f
    - peripheral nervous system and, 72
    - spinal nerves and, 73f
  - Cranial part of spinal accessory nerve, 140t, 392t, 414, 415t
  - Craniosacral fibers, 515t
  - Cranium, development of, 10, 10t, 11f, 12t
  - Cretinism, 151
  - Cribriform plate
    - of ethmoid bone, 38t, 39f, 40f, 77f
    - foramina of, 51t, 52f
    - as nasal cavity boundary, 277f, 277t
    - nerve supply to nasal cavity and, 289f
  - Cricoaeroid joint, 425t
  - Cricoid cartilage
    - of larynx, 422f, 422t, 424f, 424t
    - in neck, 109f, 110f, 112f
    - pharynx and, 409f
  - Cricoid cartilage arch, 424f, 424t
  - Cricoid cartilage lamina, 424f, 424t
  - Cricopharyngeal portion of inferior constrictor muscle, 417, 418f
  - Cricopharyngeus muscle, 403f, 408f, 409f
  - Cricothyroid joint, 423f, 423t, 424f, 424t
  - Cricothyroid ligament, 423f
  - Cricothyroid membrane, 435, 435f
  - Cricothyroid muscles, 112f, 429f, 429t, 430f, 430t
  - Cricothyrotomy, 435, 435f
  - Cricotracheal ligament, 428t
  - Crista galli, 38t, 40f, 298f
  - Cristae, of semicircular canals, 95f, 95t
  - Crown, of a tooth, 342t, 343f
  - Cruciate ligament, 59t, 60f
  - Crura, of antihelix, 456f
  - Crus helix, 455t, 459t
  - Crux of helix, 456f
  - Cuneiform cartilage, 422t, 427f, 427t
  - Cuneiform tubercle, 403f
  - Cuneus, 69f
  - Cuspids, 342f, 344t, 345f, 348f, 348t
  - Cusps, of teeth, 343t
- D**
- Danger space, 446t, 447f
  - Deep auricular artery
    - to external ear, 468t, 469f
    - to infratemporal fossa, 212t, 213-214f
    - to temporomandibular joint, 240f, 240t
  - Deep cervical fascia. *See also* Carotid sheath
    - carotid triangle and, 115
    - deep layer of, 108, 109f, 441t
    - general information about, 438, 438-439f
    - investing layer of. *See* Superficial layer of deep cervical fascia
    - middle layer of, 108, 441t
    - superficial layer of. *See* Superficial layer of deep cervical fascia
  - Deep facial vein, 174t, 272f
  - Deep lateral cervical lymph nodes, 636f
  - Deep layer of deep cervical fascia, 108, 109f, 441t
  - Deep lingual artery, 326f, 340f, 384f, 394f, 394t
  - Deep lingual nerves, 326f, 340f
  - Deep lingual veins, 326f, 340f, 384t
  - Deep petrosal nerve, 292f
  - Deep temporal arteries, 170f, 206f, 206t
  - Deep temporal veins, 207t
  - Deglutition
    - mastication and, 224, 233, 234f
    - pharyngotympanic tube and, 407f
    - process of, 417, 418f
    - soft palate and, 334
  - Deltoid muscle, 569t, 570f
  - Dendrites, 66, 66f
  - Dens
    - apical ligament of, 59t, 60f
    - of axis, 56f, 56t, 57f
    - fractures of, 64f
  - Dental caries, 373, 373f
  - Dental implants, 322, 322f
  - Denticulate ligament, 71f
  - Dentin, 343f, 343t
  - Dentoalveolar abscess, 449, 449f
  - Depressor anguli oris muscle, 161t, 163f
  - Depressor labii inferioris muscle, 162t, 163f
  - Depressor septi (nasi) muscle, 164t, 165f
  - Descending colon, 593, 594f
  - Descending palatine artery, 251f, 252t, 253f
  - Descending palatine vein, 254t
  - Diabetic retinopathy, 509, 509f
  - Diaphragm, 580t, 581f
  - Diencephalon, 69
  - Digastric fossa, 46f
  - Digastric muscle
    - in anterior neck, 109f
    - facial nerve and, 93t
    - parotid gland and, 187t
    - pharyngeal muscles and, 408f
    - subdividing triangles by, 127f, 127t
    - submental triangle and, 119
    - in suprahyoid region, 111, 128t
  - Digastric triangle, 113. *See also* Submandibular triangle
  - DiGeorge syndrome, 22, 22f
  - Dilator naris muscle, 164t
  - Diplopia, 80t
  - Discriminative touch (sensation), 82t, 90-91t, 92f, 388t
  - Distal surface of teeth, 341t, 342f
  - Dorsal column, 72f
  - Dorsal interosseus muscles, 575t, 576f
  - Dorsal motor nucleus, 533t
  - Dorsal nasal artery
    - to eye and orbit, 500t, 501f
    - to face, 170f, 171t
    - to nose, 270f, 270t
  - Dorsal rami
    - cervical spinal nerves and, 122f
    - in peripheral nervous system, 72f
    - scalp innervation by, 159, 159t, 160f
    - sensory innervation of neck by, 143, 143t, 144f
  - Dorsal root, 71f, 72f
  - Dorsal scapular artery, 120t, 121f, 132, 132t, 133f
  - Dorsum of nose, 268
  - Dorsum sellae, 34t, 35f
  - Drug reactions, 149
  - Dry mouth, 201, 201f
  - Duct system, of abdomen, 597, 597f
  - Ductus reuniens, 460f
  - Duodenum, 590, 590f
  - Dura mater, 28, 70f, 71f
  - Dystonia, 149
- E**
- Ears, 451-478
    - arterial supply to
      - external, 468-469f, 468t
      - inner, 472-473f, 472t
      - middle, 470t, 471f

**Ears** (*Continued*)

- clinical correlates for, 476-478, 476-478f
  - embryonic development of, 14f
  - general information about, 452, 453-454f
  - glossopharyngeal nerve to, 97t, 98f
  - muscles of, 462f, 462t
  - sensory innervation of
    - external, 463t, 464-465f
    - inner, 467f, 467t
    - middle, 466f, 466t
  - structures and boundaries of
    - external, 455t, 456f
    - inner, 459t, 460-461f
    - middle, 457-458f, 457t
  - Treacher Collins syndrome and, 21, 21f
  - venous drainage from, 474t, 475f
  - vestibulocochlear nerve to, 95-96f, 95t
- Ecchymosis**, 63f
- Ectoderm**, 2, 4, 4f
- Edema**, periorbital, 183, 184f
- Edentulous patients**, 538t
- Edinger-Westphal nucleus**
- characteristics of, 521t
  - GVE fibers and, 80f, 80t, 81f
  - parasympathetics of the eye and, 497t, 498f
- Efferent general or special functional columns, of cranial nerves**, 74f, 75, 75f
- Embryonic development**, 1-24
- clinical correlates for, 19-22f, 19-23, 24f
  - of face, 13, 13-14f, 13t
  - general information about, 2-3f
  - of palate, 15, 15-16f
  - of pharyngeal arches, 4, 4f
    - anomalies of, 20-22, 20-22f
    - derivatives of, 5t, 6f, 6t
  - of pharyngeal clefts, 7, 7f, 7t, 9t
  - of pharyngeal membranes, 7, 7f, 7t, 9t
  - of pharyngeal pouches, 7, 7f, 7t, 8f
    - anomalies of, 19, 19f
  - of skull, 10, 10-12t, 11-12f
  - of thyroid gland, 18, 18f
  - of tongue, 17f, 17t
- Emissary vein**, 284t
- Enamel**, of teeth, 343f, 343t
- Endoderm**, 2, 4, 4f
- Endolymphatic duct**, 459t, 460f
- Endolymphatic sac**, 460f
- Endoscopic surgery, of paranasal sinuses**, 323, 323f
- Epicranial muscle**, 165f
- Epiglottic vallecula**, 404t, 417, 418f
- Epiglottis**, 110f, 422f, 422t, 426f, 426t
- embryonic development of, 17f, 17t
  - laryngopharynx and, 404t, 405f
  - swallowing and, 417, 418f
  - tongue and, 387f
- Epistaxis**, 294-295, 295f
- Epithalamus**, 69
- Epitympanic recess**, 457t, 458f
- Erythroplasia**, of tongue, 399
- Esophagus**, 15f, 108, 117t, 125t
- Ethmoid artery**, 270t. *See also* Anterior ethmoidal artery; Posterior ethmoidal artery
- Ethmoid bone**
- anatomy of, 38t, 39f
  - in facial skeleton, 155f
  - nasal cavity and, 277f, 277t, 278f
  - orbital plate of, 483f
  - structures articulating with, 27f, 27t
- Ethmoid bulla**, 38t
- Ethmoid cartilage**, 15f
- Ethmoid labyrinth**, of ethmoid bone, 38t
- Ethmoid sinuses**
- arterial supply to, 309f, 309t
  - Caldwell-Luc procedure in, 321f
  - drainage of, 303t
  - features of, 301-302f, 301t
  - general information about, 307, 307-308f
  - imaging of, 324f
  - nasal cavity and, 277t

**Ethmoid sinuses** (*Continued*)

- nerve supply to, 310f, 310t
  - sinusitis in, 317
- Ethmoidal branches of venous plexus**, 284t
- Exophthalmos**, 183
- Extensor carpi radialis brevis muscle**, 574f, 574t
- Extensor carpi radialis longus muscle**, 574f, 574t
- Extensor carpi ulnaris muscle**, 574f, 574t
- Extensor digiti minimi muscle**, 574f, 574t
- Extensor digitorum muscle**, 574f, 574t
- Extensor indicis muscle**, 574f, 574t
- External acoustic meatus**, 455, 456f. *See also* External ear
- embryonic development of, 9t
  - parotid gland and, 187t
- External carotid artery**
- branches of, to ear, 473f
  - carotid triangle and, 115t, 116f
  - to external ear, 468f, 468t, 469f
  - to face, 158f, 168, 168f, 169t
  - to masticatory muscles, 228t
  - to neck, 132, 134t, 135f
  - to nose, 269f, 271f
  - to parotid space (bed), 135f, 190f, 190t
  - to tongue, 394t, 395f
- External ear**
- arterial supply to, 468-469f, 468t
  - sensory innervation of, 463t, 464-465f
  - structures of, 455t, 456f
  - venous drainage from, 474t
- External intercostal muscle**, 579f, 579t
- External jugular lymph nodes**, 635f
- External jugular vein**, 120t, 121f
- External laryngeal nerve**, 433t, 434f
- External nasal artery**, 171t, 172t, 270f, 270t, 500t
- External nasal nerve**, 84t, 85f, 176t, 273t, 274f
- External oblique muscle**, 556t, 557f, 580t, 581f
- External superior laryngeal nerve**, 416f
- Eyeball**, 79f
- Eyes**. *See also* Orbit
- anatomy of, 480, 480-481f
  - clinical correlates for, 507-510, 507-510f
  - components of, 484-485f, 486
  - general information about, 484
  - muscles of, 487t, 488-489f
  - parasympathetics of, 497t, 498f, 521t
  - sympathetics of, 498f, 499t, 522t
- F**
- Face**. *See also* Facial expression, muscles of
- arterial supply to, 168, 168f
  - external carotid artery and branches in, 169t, 170f
  - ophthalmic artery and branches in, 171t, 172f
  - bones of, 155f
  - cervical plexus of, 179f, 179t
  - clinical correlates for, 182-183, 182-184f
  - embryonic development of, 13-14
  - fascia of, 438
  - general information about, 154, 154f, 155f
  - innervation of, general information about, 175, 175f
  - mandibular division of trigeminal nerve in, 178f, 178t
  - maxilla and, 43t
  - maxillary division of trigeminal nerve in, 176-177t, 177f
  - motor innervation of, 180t, 181f
  - ophthalmic division of trigeminal nerve in, 176t, 177f
  - sensory innervation of, 176-179t, 177-179f
  - venous drainage from, 173
    - communicating veins, 174f, 174t
    - deep veins, 174f, 174t
    - superficial veins, 173f, 173t
- Facelififts**, 154
- Facial artery**
- to face, 168f, 169t, 170f, 172f, 174f
  - to lips and cheeks, 328t, 329f
  - to nasal cavity, 281, 282t, 292f
  - to neck, 132, 132t, 134t, 135f
  - to nose, 269, 270f, 271t
  - to oral cavity floor, 354t, 355f
  - to palate, 352t, 353f
  - submandibular triangle and, 113t, 114f



# Index

- Facial canal, 457t  
 Facial expression. *See also* Cheeks; Lip(s); Scalp muscles of, 161-167  
     auricular group, 166t, 167f  
     embryotic development of, 15f  
     facial nerve and, 93t  
     general information about, 161  
     nasal group, 164t, 165f  
     neck group, 166t, 167f  
     oral group, 161-162t, 163f  
     orbital group, 164t  
     scalp group, 166t, 167f  
 Facial (VII) nerve  
     Bell's palsy and, 197f  
     buccal branches of. *See* Buccal branches of facial nerve  
     cervical branch of. *See* Cervical branch of facial nerve  
     chorda tympani branch of, 210, 219t, 220f  
     course of, 83f  
         face, 180t, 181f  
         middle ear, 466f, 466t  
         nasal cavity, 293f  
         oral cavity, 330f, 330t  
     digastric muscle and, 127t, 128t  
     fibers and functional column types of, 93t, 94f  
     for lacrimal, nasal, palatine, pharyngeal, submandibular, and sublingual glands  
     parasympathetics of, 525t, 526f  
     sympathetics of, 527t, 528-529f  
     mandibular branch of. *See* Mandibular branch of facial nerve  
     marginal mandibular branch of. *See* Marginal mandibular branch of facial nerve  
     as middle ear boundary, 458f  
     within parotid bed, 186, 186f, 187f, 188t, 189f  
     in peripheral nervous system, 73f, 74, 74f  
     pharyngeal arches and, 4f, 5t  
     salivary gland innervation by, 367t  
     sensory facial innervation by, 175, 175f, 331f, 331t  
     stylohyoid muscle and, 128t  
     temporal branches of. *See* Temporal branches of facial nerve  
     tongue innervated by, 389f  
 Facial surface of teeth, 341t  
 Facial vein  
     from eye and orbit, 502t, 503f  
     from face, 168f, 173t, 174f  
     from neck, 136, 136t, 137f, 138f  
     from nose, 272f, 272t  
     submandibular triangle and, 113t, 114f  
 False pelvis, 566t  
 False ribs, 564t, 565f  
 Fasciculation, of tongue, 106f, 398, 398f  
 Fatty superficial layer, of abdominal wall, 556t, 557f  
 Fenestra cochleae, 457t, 458f, 460f, 461f  
 Fenestra vestibuli, 457t  
 Fibrous loop, for intermediate digastric tendon, 112f  
 Filiform papillae, 17f, 382t, 383f  
 Filium terminale, 70f  
 Fimbriated fold, 326f, 340f, 384f  
 Fissured tongue, 380, 381f  
 Fistulas, of parotid gland, 202, 202f  
 Flexor carpi radialis muscle, 572t, 573f  
 Flexor carpi ulnaris muscle, 572t, 573f  
 Flexor digitorum profundus muscle, 572t, 573f  
 Flexor digitorum superficialis muscle, 572t, 573f  
 Flexor pollicis brevis muscle, 575t, 576f  
 Flexor pollicis longus muscle, 572t, 573f  
 Floor  
     of middle ear, 457t  
     of oral cavity, 338t, 339-340f, 339t  
         arterial supply to, 354t  
         sensory innervation of, 362-363t, 363f  
         venous drainage from, 356t  
 Fold of Passavant, 334. *See also* Passavant's ridge  
 Foliate papillae, 17f, 382t, 388f  
 Fontanelles, 11t, 29t, 48f, 49f  
 Food bolus. *See* Swallowing  
 Foramen cecum  
     embryotic development of, 17f, 18  
     frontal bone and, 28t  
     in superior view of cranial base, 51t, 52f  
     of tongue, 382t, 383f, 387f  
 Foramen lacerum, 51t, 52f, 53t, 54f  
 Foramen magnum, 31f, 51t, 52f, 53t, 54f  
 Foramen ovale  
     in cranial base, 51t, 52f, 53t, 54f, 110f  
     sphenoid bone and, 34t, 35f  
 Foramen rotundum  
     pterygoid canal and, 263f  
     pterygopalatine fossa and, 249t, 250f, 251f  
     sphenoid bone and, 34t, 35f  
     in superior view of cranial base, 51t, 52f  
 Foramen spinosum  
     in cranial base, 51t, 52f, 53t, 54f, 110f  
     sphenoid bone and, 34t, 35f  
 Foramen transversarium, 56f, 56t, 57f  
 Fordyce's spots, 327t, 337  
 Fornix, 404t  
 Fovea centralis, 486  
 Fractures  
     of cervical vertebrae, 64, 64f  
     Le Fort, 62, 62f  
     mandibular, 63, 63f  
     nasal, 154  
     zygomatic, 61, 61f, 154  
 Frenula  
     embryotic development of, 17f  
     labial, 326f, 327t, 340f  
     lingual, 338t, 340f  
 Frey's syndrome, 198, 198f  
 Frontal bone  
     anatomy of, 28f, 28t  
     in facial skeleton, 154, 154f, 155f  
     orbital margin and, 482t, 483f  
     root of nose and, 268, 269f  
     structures articulating with, 27f, 27t  
 Frontal branch of trigeminal nerve ophthalmic division, 84t, 85f  
 Frontal lobe, 68f, 69  
 Frontal nerve, 492t, 493f  
 Frontal process, 43t, 44f  
 Frontal sinuses  
     arterial supply to, 305f, 305t  
     drainage of, 303t  
     features of, 301-302f, 301t  
     general information about, 304, 304f  
     imaging of, 324f  
     nasal cavity and, 277f, 277t, 278f  
     nerve supply to, 306f, 306t  
     sinusitis in, 317  
     surgical obliteration of, 320, 320f  
 Frontalis muscle, 166t  
 Frontonasal prominence, 4, 13, 13f, 13t  
 Funduscopy, 507f  
 Fungiform papillae, 17f, 382t, 383f, 388f  
**G**  
 Gag reflexes, Akinosi nerve block and, 544t  
 Galea aponeurosis, 156f, 156t, 160f  
 Gallbladder and duct system, 597, 597f  
 Ganglia, 66, 66f  
 Ganglionic branches, 86t, 176t, 255t, 256f, 257t  
 General functional columns, of cranial nerves, 75. *See also* GSA function; GSE function; GVA function; GVE function  
 Geniculum of facial nerve, 454f, 458f  
 Genioglossus muscle  
     hypoglossal nerve paralysis and, 106  
     hypoglossal nerve to, 102f, 102t  
     oral cavity floor and, 339f  
     origin of, 111f  
     tongue and, 385-386f, 385t, 387f  
 Geniohyoid fascia, 440f  
 Geniohyoid muscle  
     oral cavity floor and, 338t, 339f, 339t, 387f  
     in suprahyoid region, 111, 111f, 128t

- Geographic tongue, 380, 381f
- Gingiva
- Akinosi block and, 544t
  - embryotic development of, 16f, 17f
  - Gow-Gates block and, 542t
  - greater palatine nerve block and, 550t
  - inferior alveolar nerve block and, 538t
  - infraorbital nerve block and, 552t
  - long buccal nerve block and, 540t
  - maxillary division nerve block and, 553t
  - mental nerve block and, 541t
  - middle superior alveolar nerve block and, 551t
  - nasopalatine nerve block and, 549t
  - posterior superior alveolar nerve block and, 548t
  - teeth and, 343f
- Gingival groove, 343f
- Gingivitis, 372, 372f
- Glabella, 268f
- Glaucoma, 507, 507-508f
- Glenoid fossa, 32t
- Glossoepiglottic folds, 382t, 383f
- Glossopharyngeal (IX) nerve
- corresponding sympathetics, 530t
  - course of
    - floor of oral cavity, 362t, 363f
    - palate, 364t, 365f
    - pharynx, 414t, 416f
    - tongue, 389f, 390f, 390t, 391t, 392f
  - fibers and functional column types of, 97t, 98f
  - neck innervation by, 139t, 141f
  - in peripheral nervous system, 73f, 74, 74f
  - pharyngeal arches and, 4f, 5t
  - salivary gland innervation by, 367t
  - tongue development and, 17t
- Glossoptosis, 20, 20f
- Glycopyrrolate, 198
- Golgi apparatus, 66, 66f
- Gonadal tumors, 152
- Gow-Gates nerve block, 542t, 543f
- Graves' disease, 152
- Gray matter, of spinal cord, 70, 71f
- Gray ramus communicans, 72f, 73f
- Great auricular nerve, course of
- external ear, 463t, 464f
  - face, 179f, 179t
  - neck, 145t, 146f
  - parotid bed, 192-193f, 192t
  - scalp, 160f
- Greater occipital nerve, 122t, 159t, 160f
- Greater palatine arteries
- to nasal cavity, 281t, 283f
  - to palate, 352t, 353f
  - to pterygopalatine fossa, 251f, 253f
- Greater palatine foramen
- hard palate and, 332, 333f
  - imaging of, 378f
  - in inferior view of cranial base, 53t, 54f
  - nasal cavity and, 278f
- Greater palatine nerve
- course of, 88f
    - ethmoid sinuses, 310t
    - nose, 275f, 287t, 288f, 293f
    - palate, 364t, 365f
    - pterygopalatine fossa, 251f, 253f
  - intraoral injections and, 546, 546f
  - pterygopalatine ganglion and, 86t, 257t, 258f, 260f
- Greater palatine nerve block, 550f, 550t
- Greater palatine vein, 356t
- Greater petrosal nerve groove, 454f
- Greater petrosal nerve, parasympathetics associated with
- for lacrimal, nasal, palatine, pharyngeal, submandibular, and sublingual glands, 525t
  - for lacrimal gland, 505t
  - for nasal cavity, 290t, 292f, 293f
  - for pterygopalatine fossa, 259t, 260f
  - for salivary glands, 370t, 371f
- Greater wing of sphenoid bone
- anatomy of, 34t, 35f
  - infratemporal fossa and, 210t, 211f
- Greater wing of sphenoid bone (*Continued*)
- orbital surface of, 483f
  - temporal fossa and, 205f, 205t
- Grinning muscle, 162t
- GSA (general somatic afferent) function
- characteristics of, 75
  - facial nerve and, 93t
  - glossopharyngeal nerve and, 97t
  - hypoglossal nerve and, 102t
  - tongue and, 388t
  - trigeminal nerve and, 82t
  - vagus nerve and, 99t
- GSE (general somatic efferent) function, 75, 80t
- GVA (general visceral afferent) function, 75, 93t, 97t, 99t
- GVE (general visceral efferent) function, 75, 80t, 93t, 97t, 99t
- Gyri, 68f, 69
- H**
- Haemophilus influenzae*, 477
- Hair cells, inner and outer, 461f
- Hairy leukoplakia, of tongue, 400, 400f
- Hairy tongue, 380, 381f
- Hand
- arterial supply to, 604, 604f
  - muscles of, 575t, 576f
- Hangman's fracture, 64, 64f
- Hard palate, 326, 332, 332t, 333f
- nerve blocks to, 546, 550t
- Hashimoto's thyroiditis, 151
- Head and neck. *See also* Neck
- development of. *See also* Embryonic development
    - general information about, 2-3f
    - pharyngeal arches, 4
  - parasympathetic pathways of, 521-533
  - sympathetics of, 519-520
    - general anatomic pathway, 519t, 520f
- Heart
- chambers of, 586-587f, 587t
  - circulation in, 588f, 588t
  - pericardium of, 586t
  - surfaces of, 586f, 586t
  - valves of, 587f, 587t
- Helicotrema, 460f
- Helix, of auricle, 455t, 456f
- Hemianopsia, homonymous or bilateral, 78t
- Hepatic portal vein, 611
- Herpes simplex virus (HSV-1), 196, 376, 376f
- Hiatus for greater petrosal nerve, 51t, 52f
- Hiatus for lesser petrosal nerve, 51t, 52f
- Hiatus semilunaris, 38t, 39f
- Hip bone, 566t, 567f
- Homonymous hemianopsia, 78t
- Horizontal cell, 490f
- Horizontal plate, of palatine bone, 41f, 41t, 44f, 378f
- Horner's syndrome, 534, 534f
- Human immunodeficiency virus (HIV) infection, 200f
- Humerus, 559t, 560f
- Hyoglossus muscle, 102f, 102t, 408f
- Hyoid bone
- fascial spaces and, 443
  - in neck, 110f
    - anterior triangle and, 111, 111f
    - submandibular triangle and, 114f
    - submental triangle and, 119
  - in oral cavity, 339f
  - pharynx and, 409f
  - swallowing and, 417, 418f
- Hyoid cartilage, 15f
- Hyperopia, 510, 510f
- Hyperthyroidism, 152, 152f
- Hypobranchial eminence, 17t
- Hypoglossal canal
- in inferior view of cranial base, 53t, 54f
  - in lateral portion of occipital bone, 30t, 31f
  - in superior view of cranial base, 51t, 52f
- Hypoglossal (XII) nerve
- carotid triangle and, 115t, 116f
  - embryotic development of, 15f

# Index

## Hypoglossal (XII) nerve (*Continued*)

- fibers and functional column types of, 102f, 102t
- lesions affecting, 106, 106f
- neck innervation by, 140t, 141f, 142f
- paralysis of, 106, 398, 398f
- in peripheral nervous system, 74, 74f
- submandibular triangle and, 113, 113t, 114f
- tongue innervation by, 392t, 393f

## Hypoglossus muscle

- carotid triangle and, 115
- oral cavity floor and, 339f
- submandibular triangle and, 113, 114f
- tongue and, 385-386f, 385t

## Hypophyseal fossa, 34t, 35f

## Hypothalamic sulcus, 69f

## Hypothalamus, 69

## Hypothyroidism, 151, 151f

## I

## Ileum, 591, 592f

## Iliacus muscle, 580t, 581f

## Iliocostalis cervicis muscle, 577t, 578f

## Iliocostalis lumborum muscle, 577t, 578f

## Iliocostalis thoracis muscle, 577t, 578f

## Ilium, 566t, 567f

## Incisal surface of teeth, 341t

## Incisive artery, 355t, 356f

## Incisive canal, 289f

## Incisive foramen, 15, 53t, 54f, 332

## Incisive fossa, 44f, 333f, 378f

## Incisive nerve, 360t

## Incisive papilla, 332, 333f

## Incisors

- embryonic development of, 15
- mandibular, 349f, 349t, 350f, 350t
- maxillary, 344t, 345f

## Incus, 456f, 457f, 458f

## Infections

- abscesses, 449, 449f
- Bell's palsy and, 196
- fascial spaces and, 443
  - in infrahyoid region, 446t
  - in suprahyoid region, 444-445t, 445f
  - traversing length of neck, 446t, 447f
- Ludwig's angina, 448, 448f
- of paranasal sinuses, 300, 319f
- sinusitis, 317, 317-318f

## Inferior alveolar artery, 212t, 213f, 355t, 356f

## Inferior alveolar nerve, 542t, 543f, 544t, 545f

## Inferior alveolar nerve block, 538t, 539f

## Inferior alveolar vein, 356t, 357f

## Inferior compartment of temporomandibular joint, 236f, 238t, 239f

## Inferior constrictor muscle. *See* Inferior pharyngeal constrictor muscle

## Inferior deep lateral cervical lymph nodes, 635f

## Inferior division of the oculomotor nerve, 495t, 496f

## Inferior horn, of thyroid cartilage, 423f, 423t

## Inferior labial artery, 169t, 170f, 328t, 329f

## Inferior labial vein, 173t, 174f, 329f, 329t

## Inferior lamina, of TMJ, 236f, 238t

## Inferior laryngeal arteries, 431f, 431t

## Inferior laryngeal nerve, 434f

## Inferior laryngeal vein, 432t

## Inferior lateral palpebral artery, 501f

## Inferior longitudinal band, 59t

## Inferior longitudinal muscle, 386t

## Inferior mediastinum, 585f, 585t

## Inferior mesenteric artery, 608, 608f

## Inferior nasal conchae, 41f, 41t, 42f, 279t, 298f

## Inferior nasal meatus, 279f, 279t, 280f, 303t

## Inferior oblique muscle, 487t, 488-489f

## Inferior oblique capitis muscle, 122, 122f, 122t, 131f, 131t

## Inferior ophthalmic vein

- from eye and orbit, 502t
- from face, 174f, 174t
- from nose, 272t
- from pterygopalatine fossa, 254f, 254t

## Inferior orbital fissure

- anterior view, 55f, 55t
- as orbital opening, 482t
- pterygopalatine fossa and, 249t, 250f

## Inferior palpebral artery, 500t

## Inferior palpebral branch of infraorbital nerve, 87t

## Inferior petrosal sinus, 32t

## Inferior pharyngeal constrictor muscle

- carotid triangle and, 115
- of pharynx, 403f, 406t, 408f, 409f
- potential apertures in pharyngeal wall and, 410f, 410t

## Inferior rectus muscle, 487t, 488-489f

## Inferior salivatory nucleus, parasympathetics of parotid gland and, 368t, 369f

- anatomic pathway for, 194t, 221t, 222f, 530t, 531-532f

## Inferior thyroid artery

- inferior parathyroid glands and, 123
- muscular triangle and, 117t, 118f
- to pharynx, 411t, 412f
- thyroid gland and, 123, 124f

## Inferior thyroid vein, 117t, 123, 124f, 125t, 126f

## Inferior tubercle, of thyroid cartilage, 423t

## Inferior tympanic artery, 470t, 471f

## Inferior wall of orbit, 482t

## Infrahyoid fascia, 440f, 441t

## Infrahyoid fascial spaces, 443, 446t

## Infrahyoid muscles, 128t

## Infrahyoid region, of neck, 111

## Infraorbital artery

- to eye and orbit, 500t, 501f
- to face, 168f, 169t, 170f, 172f
- to nasal cavity, 283f
- to pterygopalatine fossa, 252t, 253f

## Infraorbital canal, maxillary division nerve branches within, 87t, 88f

## Infraorbital fissure, 263f

## Infraorbital foramen, 55f, 55t, 87t

## Infraorbital groove and canal, 482t

## Infraorbital nerve

- course of, 86t
    - eye and orbit, 494f, 494t
    - face, 176t, 177f, 177t
    - lips and cheeks, 328t, 329f
    - maxillary sinus, 313f, 313t
    - nasal cavity, 287t, 293f
    - nose, 273t, 274f
    - pterygopalatine fossa, 255t, 256f
    - teeth, 359t
  - pterygopalatine fossa and, 251f
- ## Infraorbital nerve block, 552f, 552t
- ## Infraorbital vein, 168f, 174f, 174t, 254t, 502t
- ## Infraspinatus muscle, 569t, 570f
- ## Infratemporal fossa, 210-222
- anatomy of, 204, 204f
  - arterial supply to, 212-213t, 213-214f
  - bordering structures of, 210t
  - contents of, 210, 210-211f
  - maxilla and, 43t
  - of neck, 110f
  - nerve supply to, 216-217t, 217-218f, 219t, 220-222f, 221t
  - pterygopalatine fossa and, 250f, 251f
  - venous drainage from, 215f, 215t

## Infratrochlear artery, 270t, 500t

## Infratrochlear nerve

- course of
  - eye and orbit, 493t
  - face, 176t, 177f
  - nose, 273t, 274f, 289f
- in nasociliary branch of trigeminal nerve ophthalmic division, 84t

## Inguinal lymph nodes, 634f

## Injections, intraoral, 535-554

- general information about, 536
- mandibular, 537-545

## Akinosi, 544t, 545f

## Gow-Gates, 542t, 543f

## inferior alveolar, 538t, 539f

## landmarks for, 537, 537f

- Injections, intraoral (*Continued*)  
 long buccal, 540f, 540t  
 mental, 541f, 541t  
 maxillary, 546-554  
 anterior superior alveolar, 552f, 552t  
 greater palatine, 550f, 550t  
 infraorbital, 552f, 552t  
 landmarks for, 546, 546-547f  
 maxillary division, 553t, 554f  
 middle superior alveolar, 551f, 551t  
 nasopalatine, 549f, 549t  
 posterior superior alveolar, 548f, 548t
- Inner ear  
 nerve supply to, 467t  
 structures and boundaries of, 459t, 460-461f
- Inner hair cells, 454f
- Inner horizontal part of lateral ligaments, 238t
- Inner limiting membrane, 490f
- Innervated intercostal muscle, 579f, 579t
- Insula, 68f, 69
- Intercalated lymph nodes, 635f, 636f
- Intermaxillary segment, 13t, 15
- Intermaxillary suture, 269f
- Intermediate mesoderm, 2, 3f
- Intermediolateral horn nucleus, characteristics of  
 for eye, 498f, 499t, 522t  
 general, 519t  
 for nasal cavity, 290t  
 for nasal cavity, lacrimal gland, and submandibular and sublingual gland, 527t  
 for parotid gland, 194t, 530t  
 for pterygopalatine fossa, 261t
- Internal acoustic meatus. *See also* Inner ear  
 facial nerve and, 95t  
 in superior view of cranial base, 51t, 52f  
 in temporal bones, 32t  
 vestibulocochlear nerve and, 95t
- Internal branch of superior laryngeal nerve, 363f, 409f
- Internal carotid artery  
 carotid triangle and, 115t, 116f  
 to face, 158f, 168, 168f  
 as middle ear boundary, 458f  
 to neck, 132, 134t, 135f  
 to nose, 269f, 292f
- Internal intercostal muscle, 579f, 579t
- Internal jugular lymph nodes, 635f, 636f
- Internal jugular vein  
 carotid triangle and, 115t, 116f  
 muscular triangle and, 118f  
 from neck, 136, 136t, 137f, 138f  
 pharyngeal plexus and, 413f  
 in root of the neck, 124f, 125t, 126f  
 submandibular triangle and, 114f
- Internal laryngeal nerve, course of  
 floor of oral cavity, 362t, 363f  
 larynx, 433f, 433t, 434f  
 tongue, 390t, 391t
- Internal nasal nerve, 84t, 273t, 274f
- Internal oblique muscle, 580t, 581f
- Internal superior laryngeal nerve, 416f
- Interspinous plane, 556t, 557f
- Intertragic notch, 455t
- Intertubercular plane, 556t, 557f
- Intervertebral foramina, 57f
- Intervertebral joints, 57f
- Intralingual ectopic thyroid, 19, 19f
- Intramural ganglion, 533t
- Intratracheal ectopic thyroid, 19, 19f
- Investing layer of deep cervical fascia  
 of neck, 440f, 441t, 442f  
 parotid gland and, 187f, 187t  
 posterior triangle and, 120  
 sternocleidomastoid muscle and, 108  
 trapezius muscle and, 108, 109f
- Iris, 484-485f, 486
- Ischium, 566t, 567f
- Isthmus faucium, 17f
- J**
- Jefferson fracture, 64, 64f
- Jejunum, 591, 592f
- Jugular foramen, 30t, 33f, 51t, 53t, 54f
- Jugular fossa, 31f, 32t, 33f, 458f, 462f
- Jugular vein. *See* Anterior jugular vein; External jugular vein;  
 Internal jugular vein
- Jugulodigastric lymph nodes, 635f, 636f
- Jugulo-omohyoid lymph nodes, 635f, 636f
- K**
- Kidneys, 599, 600f
- L**
- Labial surface of teeth, 341t, 342f
- Labiomental groove, 327f, 327t
- Labyrinthine artery, 472f, 472t
- Labyrinthine vein, 474t
- Lacrimal apparatus, 504f, 504t, 505t, 506f
- Lacrimal artery, 171t, 282f, 499t, 501f
- Lacrimal bones  
 anatomy of, 36f, 36t  
 in facial skeleton, 155f  
 nasal cavity and, 277t  
 orbit walls and, 483f  
 structures articulating with, 27f, 27t
- Lacrimal canaliculi, 280f, 504f, 504t
- Lacrimal caruncle, 280f, 504f
- Lacrimal fossa, 36t
- Lacrimal glands  
 GVE fibers of facial nerve and, 93t  
 in lacrimal apparatus, 504f, 504t  
 orbital and palpebral parts of, 280f  
 parasympathetics of, 505t, 506f  
 anatomic pathway for, 525t, 526f  
 sympathetic of  
 anatomic pathway for, 506f, 527t, 528-529f  
 traversing pterygopalatine fossa, 261-262t
- Lacrimal nerve  
 course of, 83t, 88f  
 eye and orbit, 492t, 493f  
 face, 176t, 177f  
 nasal cavity, 289f
- Lacrimal part of orbicularis oculi muscle, 164t
- Lacrimal sac, 13t, 280f, 504f, 504t
- Lambda, parietal bones at, 29t
- Lamina propria, 383f  
 of gingiva, 343f
- Large intestine, 593-594, 594f
- Laryngeal aditus, 417, 418f
- Laryngeal nerve, 114f, 116f
- Laryngeal prominence, 423f, 423t
- Laryngeal vein, 114f
- Laryngeal vestibule, 417, 418f
- Laryngitis, 436, 436f
- Laryngopharynx, 404t, 405f
- Laryngotracheal groove, 17t
- Larynx, 419-436  
 anatomy of, 420, 420-421f  
 in anterior neck, 108  
 arterial supply to, 431f, 431t  
 carotid triangle and, 115t  
 cartilages of, 422f, 422t  
 arytenoid, 425f, 425t  
 cricoid, 424f, 424t  
 epiglottis, 426f, 426t  
 minor, 427f, 427t  
 thyroid, 423f  
 clinical correlates for, 435-436, 435-436f  
 lesions affecting, 104, 104f  
 membranes and ligaments of, 428f, 428t  
 motor and sensory branches from vagus nerve to, 433f, 433t  
 muscles of, 429f, 429t, 430f, 430t  
 muscular triangle and, 117t  
 in suboccipital triangle, 123  
 swallowing and, 417, 418f  
 venous drainage from, 432f, 432t
- Lateral collateral ligament, 238-239t, 239f

# Index

- Lateral cricoarytenoid muscle, 429f, 429t, 430f, 430t
- Lateral crus, 269f
- Lateral incisors, 342f, 344t, 345f, 349f, 349t
- Lateral ligaments, 238-239t, 239f
- Lateral nasal artery, 169t, 170f, 172f, 270f, 271t
- Lateral nasal cartilage, 268, 269f
- Lateral nasal prominence, 13, 14f
- Lateral nasal vein, 173t
- Lateral palpebral artery, 501f
- Lateral pharyngeal fascial space, 444t
- Lateral plate mesoderm, 2, 3f, 4
- Lateral pterygoid muscle
  - infratemporal fossa and, 210, 211f
  - mastication and, 224f, 225t, 226f, 227f, 233
  - pharyngeal muscles and, 408f
  - trigeminal nerve innervation of, 82f, 82t
- Lateral pterygoid nerve, 231t, 232f
- Lateral pterygoid plate, 110f
- Lateral rectus muscle, 80f, 80t, 487t, 488-489f
- Lateral semicircular canal, 454f
- Lateral sulcus (of Sylvius), 69
- Lateral thyrohyoid ligaments, 428t
- Lateral wall of orbit, 482t
- Lateral walls
  - of middle ear, 457t
  - of nasal cavity, 77f, 276
- Latissimus dorsi muscle, 577t, 578f
- Le Fort fractures, 62, 62f
- Left recurrent laryngeal nerve, 104f, 126f
- Lens, 484-485f, 486
- Lesser occipital nerve, 145t, 159t, 160f, 463t, 464f
- Lesser palatine arteries
  - to nasal cavity, 283f
  - to nose, 271f
  - to palate, 352t, 353f
  - to pterygopalatine fossa, 251f, 253f
- Lesser palatine foramen
  - hard palate and, 332, 333f
  - imaging of, 378f
  - in inferior view of cranial base, 53t, 54f
  - nasal cavity and, 278f
- Lesser palatine nerve
  - course of, 87t, 88f
  - nose, 275f, 288f, 293f
  - palate, 364t, 365f
  - pterygopalatine ganglion and, 251f, 256f, 257t, 258f, 260f
- Lesser palatine vein, 356t
- Lesser petrosal nerve, 210, 219t, 221f, 458f
- Lesser wing of sphenoid bone, 34t, 35f, 483f
- Lesser's triangle, 113
- Leukoplakia, 399, 400, 400f
- Levator anguli oris muscle, 161t, 163f
- Levator labii superioris alaeque nasi muscle, 162t, 163f
- Levator labii superioris muscle, 162t, 163f
- Levator palpebrae superioris muscle, 487t, 488-489f
- Levator scapulae muscle, 120, 121f, 577t, 578f
- Levator veli palatini muscle
  - mastication and, 227f
  - pharyngeal muscles and, 408f
  - pharyngotympanic tube and, 336-337f, 407f, 458f
  - in soft palate, 334, 334f, 335t
- Ligamenta flava, 58f, 58t
- Ligamentum nuchae, 58f, 58t
- Light touch (sensation), 82t, 90-91t, 92f
- Lingual artery
  - carotid triangle and, 115t, 116f
  - to neck, 132, 132t, 134t, 135f
  - to oral cavity floor, 354f, 354t
  - submandibular triangle and, 113, 113t, 114f
  - to tongue, 394-395f, 394t
- Lingual frenulum, 338t, 384f, 384t, 397, 397f
- Lingual minor salivary gland, 340f, 384f
- Lingual nerve
  - course of
    - floor of oral cavity, 362t, 363f
    - tongue, 389t, 390f, 391f
  - Gow-Gates block and, 542t
  - inferior alveolar nerve block and, 538t, 539f
- Lingual nerve (*Continued*)
  - intraoral injections and, 537
  - as oral cavity floor border, 338t, 339f
- Lingual surface of teeth, 341t, 342f
- Lingual thyroid, 19, 19f
- Lingual tonsils, 328f, 332f, 377
  - pharyngeal portion of tongue and, 382t, 383f, 387f
- Lingual vein
  - carotid triangle and, 115t
  - from neck, 136, 136t, 137f
  - from oral cavity, 356t
  - submandibular triangle and, 113t
  - from tongue, 396f, 396t
- Lingula, 45t
- Lip(s). *See also* Facial expression
  - arterial supply to, 328t, 329f
  - clefing of, 23, 24f
  - commissure of, 154f
  - embryotic development of, 13t, 14f, 16f
  - frenulum of, 326f, 340f
  - infraorbital nerve block and, 552t
  - maxillary division nerve block and, 553t
  - motor innervation of, 330f, 330t
  - sensory innervation of, 331f, 331t
  - structural features of, 327t
  - venous drainage from, 329f, 329t
- Liver, 595, 595f
- Lobule of auricle, 455t, 456f
- Long buccal nerve block, 540f, 540t
- Long buccal nerve, Gow-Gates block and, 542t
- Long ciliary nerves, 84t, 85f, 490f, 492t, 493f
- Long posterior ciliary artery, 500t
- Long thoracic nerve, 120t
- Longissimus capitis muscle, 577t, 578f
- Longissimus cervicis muscle, 577t, 578f
- Longissimus thoracis muscle, 577t, 578f
- Longus capitis muscle, 129t, 130f
- Longus colli muscle, 129t, 130f
- Loose areolar connective tissue, 156f, 156t
- Lower motor neurons, 518f
- Ludwig's angina, 448, 448f
- Lumbar area, of spinal cord, 70
- Lumbar spinal nerves, 70, 70f, 73f
- Lumbar splanchnic nerves, 73f
- Lumbar vertebrae, 562t, 563f
- Lumbosacral enlargement, of spinal cord, 70, 70f
- Lumbrical muscles, 575t, 576f
- Lumen of larynx, 15f
- Lung tumors, voice effects from, 104, 104f
- Lungs, 583f, 583t
- Lymph nodes (lymphatics), 633-636
  - of head and neck, 635f
  - of pharynx, 636f
  - submandibular, 113t
  - submental, 119t
  - of tongue, 636f
- Lymphosarcoma, 199f
- Lysosomes, 66, 66f

## M

- Macroglossia, 544t
- Macula lutea, 486
- Maculae, of utricle and saccule, 95-96f, 95t
- Macular zone, 78f
- Malleus, 457f, 457t, 458f
- Mamelons, 344t
- Mandible
  - anatomy of, 45t, 46f
  - buccinator crest of, 408f
  - dislocation of, 244, 244f
  - embryotic development of, 15f
  - in facial skeleton, 154, 154f, 155f
  - fractures of, 63, 63f
  - hypoplastic, 20, 20f, 21
  - oblique line of, 408f
  - structures articulating with, 27f, 27t
  - TMJ and opening of, 243, 243f
- Mandibular arch, 341

- Mandibular branch of facial nerve, 161t, 180t, 181f, 330f, 330t
- Mandibular condyles, 236, 237t, 542t
- Mandibular division ( $V_3$ ) of trigeminal (V) nerve  
branches within, 89t, 90f  
course of, 83f  
face, 175, 175f, 177f, 178t  
infratemporal fossa, 210, 216-217t, 217f  
in masticatory muscles, 233  
masticatory muscles, 231t, 232f  
scalp, 159t, 160f  
teeth, 360t, 361f  
temporal fossa, 208t
- GSA fibers and, 82f, 82t
- oral cavity innervation by, 358, 358f
- pharyngeal arches and, 4f
- sensory innervation of neck by, 144f
- temporal fossa innervation by, 209f
- Mandibular injections, 537, 537f
- Mandibular lymph nodes, 635f
- Mandibular mucosa, 538t
- Mandibular notch, 45t, 46f
- Mandibular processes, 4, 5t
- Mandibular prominence, 13, 13t
- Mandibular ramus  
fractures at, 63  
intraoral injections and, 537, 537f  
mandible and, 27f, 45t, 46f  
neck anatomy and, 109f, 110f  
parotid bed and, 187f, 187t, 189f
- Mandibular teeth. *See* Teeth, mandibular
- Mandibular torus, 374
- Manubrium, 125, 564t, 565f
- Manus, 557t
- Marginal mandibular branch of facial nerve, 189f, 208f
- Masseter muscle  
mastication and, 224f, 225t, 226f, 233  
parotid gland and, 186, 187t  
trigeminal nerve innervation of, 82f, 82t
- Masseteric artery, 112t, 213f, 228t, 229f
- Masseteric branch of mandibular nerve, 89t, 216t, 218f
- Masseteric nerve, 231t, 232f, 242t, 539f
- Masseteric vein, 230t
- Mastication, muscles of, 223-234  
anatomy of, 224, 224f, 225t, 226-227f  
arterial supply to, 228t, 229f  
clinical correlate for, 233, 234f  
motor branches of trigeminal nerve in, 231t, 232f  
sensory fibers of trigeminal nerve in, 91t  
venous drainage from, 230f, 230t
- Masticator fascial space, 444t, 445f
- Mastoid air cells, 32t
- Mastoid antrum, 457t, 458f
- Mastoid canaliculus, 53t, 54f
- Mastoid foramen, 51t, 52f
- Mastoid lymph nodes, 635f
- Mastoiditis, 478f
- Maxilla  
anatomy of, 43-44f, 43t  
anterior nasal spine of, 269f  
in facial skeleton, 154, 155f  
infratemporal fossa and, 210f, 210t, 211f  
nasal cavity and, 277t, 278f  
orbital margin and, 482t, 483f  
palatine process of, 332, 333f  
pterygopalatine fossa and, 249t  
root of nose and, 268  
structures articulating with, 27f, 27t
- Maxillary arch, 341
- Maxillary artery  
to external ear, 468t, 469f  
to eye and orbit, 500t  
to face, 169t, 170f  
to infratemporal fossa, 210, 212-213t, 213-214f  
to masticatory muscles, 228t, 229f  
to nasal cavity, 281t, 281t  
to nose, 269, 271f, 271t  
to palate, 352t, 353f  
to parotid space (bed), 190f, 190t
- Maxillary artery (*Continued*)  
to pterygopalatine fossa, 251f, 252t, 253f  
to teeth, 355t
- Maxillary division ( $V_2$ ) of trigeminal (V) nerve  
across pterygopalatine fossa, 259t, 260f, 261t  
branches within, 86-87t, 88f  
associated with pterygopalatine ganglia, 257t, 258f  
course of, 83f, 144f  
eye and orbit, 489t, 494f, 494t  
face, 175, 175f, 176-177t, 177f  
infratemporal fossa, 217f, 217t  
maxillary sinus, 313f, 313t  
nasal cavity, 285, 285f, 287t, 292f, 293f  
nose, 273t, 274f, 275f  
oral cavity, 358, 358f  
palate, 364t, 365f  
pterygopalatine fossa, 255t  
scalp, 159t, 160f  
teeth, 359t
- GSA fibers and, 82f, 82t
- nerve blocks to, 553t, 554f
- parasympathetics associated with, 525t
- pharyngeal arches and, 4f
- Maxillary processes, 4, 5t
- Maxillary prominence, 13, 13t, 15
- Maxillary sinus  
arterial supply to, 312f, 312t  
boundaries and relations of, 277t  
Caldwell-Luc procedure in, 321, 321f  
conchae and, 279f  
development of, 43t  
drainage of, 303t  
features of, 301-302f, 301t  
general information about, 311, 311-312f  
imaging of, 298f, 324f, 378f  
nerve supply to, 293f, 313f, 313t  
sinusitis in, 317, 318f
- Maxillary teeth. *See* Teeth, maxillary
- Maxillary vein  
from ears, 474t  
from face, 174f  
from parotid bed, 191t  
from pterygopalatine fossa, 254f  
from temporal fossa, 207f, 207t  
from temporomandibular joint, 241f, 241t
- Meckel's cartilage, 15f, 45t
- Medial collateral ligament, 238t, 239f
- Medial crus, 269f
- Medial nasal prominence, 13, 14f
- Medial palpebral artery, 500t, 501f
- Medial pterygoid muscle  
infratemporal fossa and, 210, 211f  
mastication and, 224f, 225t, 227f, 233  
parotid gland and, 187f, 187t  
trigeminal nerve innervation of, 82f, 82t
- Medial pterygoid nerve, 231t, 232f
- Medial rectus muscle, 487t, 488-489f
- Medial wall  
of middle ear, 457t  
of orbit, 482t
- Median cricothyroid ligament, 423f, 428t
- Median sulcus, 383f
- Median thyrohyoid ligament, 428t
- Mediastinum  
inferior, 585f, 585t  
superior, 584f, 584t
- Medulla, 69
- Medulla oblongata, 69f, 73f
- Membranous labyrinth, 95-96f, 459t, 460f, 475f
- Membranous neurocranium, 10, 12t
- Membranous superficial layer, of abdominal wall, 556t, 557f
- Meningeal nerve, 86t, 88f
- Meningitis, 317
- Mental artery, 169t, 170f, 328t, 329f, 355t
- Mental branch of inferior alveolar artery, 356f
- Mental branch of inferior alveolar nerve, 178f, 178t, 331f, 360t
- Mental foramen, 45t, 46f, 55f, 55t, 541t
- Mental nerve, 539f, 541f



# Index

- Mental nerve block, 541f, 541t
  - Mental protuberance, 327f
  - Mental vein, 173t, 174f, 329f, 329t
  - Mentalis muscle, 162t, 163f
  - Mesencephalic nucleus, 90t
  - Mesial surface of teeth, 341t, 342f
  - Mesoderm, 2, 4, 5t
  - Meyer loop, 78f
  - Microglia, 67, 67f
  - Micrognathia, 20, 20f
  - Midbrain, 69, 69f, 92f
  - Middle constrictor muscle. *See* Middle pharyngeal constrictor muscle
  - Middle cranial fossa, 86t
  - Middle ear, 456f, 457-458f, 457t, 466t
  - Middle layer of deep cervical fascia, 108, 441t
  - Middle meningeal artery, 212t, 213f
  - Middle nasal conchae, 279f, 279t, 280f, 298f
  - Middle nasal meatus
    - anatomy of, 279f, 279t
    - drainage of, 303t
    - ethmoid sinuses and, 307
    - frontal sinuses and, 304
    - maxillary sinus and, 311
  - Middle pharyngeal constrictor muscle
    - anatomy of, 406t, 408f, 409f
    - carotid triangle and, 115
    - potential apertures in pharyngeal wall and, 410f, 410t
  - Middle superior alveolar artery, 312f, 312t, 355t, 356f
  - Middle superior alveolar nerve
    - course of, 87t, 88f
    - maxillary sinus, 313f, 313t
    - nasal cavity, 289f
    - teeth, 359t
    - intraoral injections and, 546, 547f
  - Middle superior alveolar nerve block, 551f, 551t
  - Middle superior alveolar vein, 356t
  - Middle temporal artery, 206f, 206t, 228t, 229f
  - Middle temporal vein, 207f, 207t, 230f, 230t
  - Middle thyroid vein, 115t, 123, 136, 136t, 137f
  - Midline groove of tongue, 383f
  - Midline septum, of tongue, 382t
  - Minor's starch iodine test, 198
  - Mitochondria, 66, 66f
  - Modiolus of cochleas, 454f, 459t
  - Molar glands, cheeks and, 327t
  - Molars
    - deciduous vs. permanent, 342f
    - mandibular, 351f, 351t
    - maxillary, 347f, 347t
    - posterior superior alveolar nerve block and, 548f, 548t
  - Mucobuccal fold, 327t
  - Mucocele, 375, 375f
  - Müller cell, 490f
  - Multipolar neurons, 66, 66f
  - Mumps, 200, 200f
  - Muscular branch of ophthalmic artery, 500t, 501f
  - Muscular process of arytenoid cartilage, 425f, 425t
  - Muscular triangle, 109f, 111, 117, 117t, 118f
  - Musculoskeletal region of cervical fascia, 440f, 441t
  - Musculus uvulae, 334, 335t
  - Myasthenia gravis, 104, 104f
  - Mydriasis, 80t
  - Mylohyoid line, 45t, 46f
  - Mylohyoid muscle
    - oral cavity floor and, 338t, 339t
    - pharyngeal muscles and, 408f
    - submandibular triangle and, 113, 114f
    - submental triangle and, 119
    - in suprahyoid region, 111, 111f, 112f, 128t
    - trigeminal nerve innervation of, 82f, 82t
  - Mylohyoid nerve, 113t, 339f, 542t, 544t
  - Myopia, 510, 510f
- N**
- Nasal bones
    - anatomy of, 36f, 36t
    - anterolateral view, 269f
  - Nasal bones (*Continued*)
    - in facial skeleton, 154, 154f, 155f, 268, 268f
    - nasal cavity and, 277f, 278f
    - structures articulating with, 27f, 27t
  - Nasal branch of infraorbital artery, 270f, 271t
  - Nasal branch of infraorbital nerve, 87t, 273t, 274f, 275f
  - Nasal cavity, 266-298
    - anatomy of, 276, 276f
    - arterial supply to, 281, 281-282t
    - autonomics traversing pterygopalatine fossa and, 261t
    - bones of, 303f
    - boundaries and relations of, 277-278f, 277t
    - clinical correlates for, 294-297, 295-297f
    - conchae of. *See* Conchae, nasal
    - general information about, 266, 266-267f
    - imaging of, 298f
    - maxilla and, 43t
    - parasympathetics of, 290t
      - anatomic pathway for, 525t, 526f
      - sensory innervation of, 285, 285-286f, 287-288t
    - sympathetics of, 290-291t
      - anatomic pathway for, 527t, 528-529f
    - venous drainage from, 284t
  - Nasal group, of muscles of facial expression, 164t, 165f
  - Nasal placodes, 13
  - Nasal septum
    - deviated, 296, 296f, 298f
    - embryotic development of, 15f, 16f
    - ethmoid bone and, 38t
    - nasal cavity and, 276, 277f
    - vomer and, 40t
  - Nasal sinuses. *See* Paranasal sinuses
  - Nasal venous plexus, 276, 284f, 284t
  - Nasal vestibule, 268, 276f, 277f
  - Nasalis muscle, 164t, 165f
  - Nasociliary branch, of trigeminal nerve ophthalmic division, 84t, 85f, 88f, 176t
  - Nasociliary nerve
    - course of, 310t, 492t, 493f
    - ophthalmic division (V<sub>1</sub>) and, 83t, 84t, 85f, 88f
  - Nasofrontal vein, 168f
  - Nasolabial groove, 327t
  - Nasolabial lymph nodes, 635f
  - Nasolabial sulcus, 268f, 327f
  - Nasolacrimal canal, 482t
  - Nasolacrimal duct
    - drainage of, 303t
    - embryotic development of, 13t
    - nasal cavity and, 276
    - opening of, 278f, 279f, 280f, 504f
    - orbit and, 482t, 504t
  - Nasopalatine nerve
    - course of, 87t
      - nasal cavity, 293f
      - nose, 275f, 287t, 288f, 289f
      - palate, 364t, 365f
    - intraoral injections and, 546f
    - nasopalatine nerve block and, 549t
    - pterygopalatine fossa and, 251f
    - pterygopalatine ganglion and, 257t, 258f
  - Nasopalatine nerve block, 549f, 549t
  - Nasopharynx, 404t, 405f
  - Neck, 107-152. *See also* Cervical vertebrae; Head and neck
    - arterial supply to
      - carotid, 134t, 135f
      - subclavian, 132, 132t, 133f
    - cervical plexus of, 145, 145t, 146f
    - clinical correlates for, 149, 149-152f, 151-152
    - cranial nerves of, 139-140t, 141-142f
    - deep fascia of, 441-442t, 442f
    - fascial spaces traversing length of, 443, 446t, 447f
    - general information about, 108, 109-110f
    - infrahyoid muscle of, 128t
    - lymphatics of, 635f
    - prevertebral muscles of, 129t, 130f
    - root of, 125, 125t, 126f
    - sensory innervation of, 143, 143t, 144f
    - suboccipital triangle of, 131f, 131t
    - superficial fascia of, 440, 440f

- Neck (*Continued*)  
 suprahyoid muscle of, 128t  
 sympathetics in, 148, 148f  
 triangles of  
   anterior, 111, 111-119f  
   muscles bordering, 127t  
   muscles subdividing, 127t  
   posterior, 120, 120t, 121f  
   suboccipital, 122, 122f, 122t  
   venous drainage from, 136, 136t, 137-138f  
   ventral rami nerves of, 147f, 147t  
   visceral contents of, 123, 124f  
 Neck group, of muscles of facial expression, 166t, 167f  
 Neck tumors, voice effects from, 104, 104f  
 Nervous system  
   central, 68-71f, 69-70. *See also* Brain; Spinal cord  
   peripheral. *See* Peripheral nervous system  
   tissues of, 66-67, 66-67f  
 Neural crest, 2, 3f, 4, 5t  
 Neural plate, 3f  
 Neuroanatomy. *See also* Cranial nerves; Nervous system  
   clinical correlates for, 103-106, 103-106f  
   nervous tissue, 66-67, 66-67f  
 Neurocranium, 10  
 Neuroectoderm, 2  
 Neuroglia, 67, 67f  
 Neurons, 66, 66f  
   postganglionic. *See* Postganglionic neurons  
   preganglionic. *See* Preganglionic neurons  
   for trigeminal nerve sensory system, 90t, 91t  
 Neurotubules, 66, 66f  
 Nissl substance, 66, 66f  
 Norma basalis, 50f, 50t  
 Norma frontalis, 47f, 47t  
 Norma lateralis, 49f, 49t  
 Norma occipitalis, 47f, 47t  
 Norma verticalis, 48f, 48t  
 Nose, 266-297. *See also* Nasal cavity  
   anatomy of, 268, 268-269f, 303f  
   arterial supply to, 269, 269-271f, 270-271t  
   clinical correlates for, 294-297, 295-297f  
   embryotic development of, 13-14f, 13t, 15-16f  
   frontal bone and, 28f, 28t  
   general information about, 266, 266-267f  
   imaging of, 298f  
   infraorbital nerve block and, 552t  
   lateral wall of, 77f  
   maxillary division nerve block and, 553t  
   sensory innervation of, 273t, 274-275f  
   venous drainage from, 272f, 272t  
 Nosebleeds, 269, 294-295, 295f  
 Nostrils, 268, 268f  
 Nuchal lines, 30t  
 Nucleus, 66, 66f  
 Nucleus solitarius, 93t
- O**  
 Oblique arytenoid muscles, 430t  
 Oblique cricoarytenoid muscle, 429f, 429t  
 Oblique head of adductor pollicis muscle, 575t, 576f  
 Oblique line  
   mandibular, 408f  
   external, 45t, 46f  
   of thyroid cartilage, 423f, 423t  
 Occipital artery  
   carotid triangle and, 115t, 116f  
   to neck, 132, 132t, 134t, 135f  
   posterior triangle and, 120t  
   to scalp, 157t, 158f, 160f  
 Occipital bone, 27t, 30t, 31f  
 Occipital condyles, 30t, 31f  
 Occipital lobe, 68f, 69, 78f  
 Occipital lymph nodes, 635f  
 Occipital triangle, 120  
 Occipital vein  
   from neck, 136, 136t, 137f  
   posterior triangle and, 120t  
   from scalp, 157t, 158f  
 Occipitalis muscle, 166t, 167f  
 Occlusal surface of teeth, 341t  
 Oculomotor (III) nerve  
   with corresponding sympathetics, 521-524  
   as cranial nerve, 73f  
   eye and orbit innervation by, 489t, 490f  
   course of, 495t, 496f  
   eye muscles and, 488f  
   fibers and functional column types of, 80-81f, 80t  
   ophthalmoplegia and, 103, 103f, 183  
   in peripheral nervous system, 74, 74f  
 Odontoid process, 56f, 56t  
   fractures of, 64, 64f  
 Olfactory bulb, 76-77f, 286f, 289f  
 Olfactory epithelium, 276, 286f, 287t  
 Olfactory gland, 77f  
 Olfactory mucosa, 76f, 77f, 286f  
 Olfactory (I) nerves  
   nasal cavity innervation by, 275f, 285, 285f, 288f  
   in peripheral nervous system, 74, 74f  
   SVA fibers and, 76-77f, 76t  
 Olfactory tract, 289f  
 Oligodendrocytes, 67, 67f  
 Omoclavicular triangle, 120  
 Omohyoid muscle  
   in infrahyoid region, 111, 112f, 128t  
   of neck, 109f  
   subdividing triangles, 127f, 127t  
 Open angle glaucoma, 507  
 Ophthalmic artery  
   to ethmoid sinuses, 309t  
   to eye, 499t, 501f  
   to face, 170f, 171t  
   to frontal sinuses, 305f, 305t  
   to nasal cavity, 281, 281t, 282f  
   to nose, 269, 270t  
   to sphenoid sinus, 315t  
 Ophthalmic division (V<sub>1</sub>) of trigeminal (V) nerve  
   branches of, 83-84t, 83f, 84f  
   course of  
     eye and orbit, 490f, 492-493t, 493f  
     face, 175, 175f, 176t, 177f  
     nasal cavity, 285, 285f, 287t, 292f  
     nose, 273t, 274f  
     pterygopalatine fossa, 259t, 260f  
     scalp, 159t, 160f  
   frontal sinuses innervation by, 304, 306f, 306t  
   GSA fibers and, 82f, 82t  
   parasympathetics associated with, 525t  
   pharyngeal arches and, 4f  
   sensory innervation of neck by, 144f  
 Ophthalmoplegia, 103, 103f, 183  
 Opponens pollicis muscle, 575t, 576f  
 Optic canal (foramen)  
   anterior view, 55f, 55t  
   as orbital opening, 482t, 483f  
   sphenoid bone and, 34t, 35f  
   superior view, 51t, 52f  
 Optic chiasm, 173f  
 Optic disc, 485f, 486  
 Optic (II) nerve  
   eye and orbit innervation by, 490f, 491f, 491t  
   fibers and functional column types of, 78-79f, 78t  
   in peripheral nervous system, 74, 74f  
 Ora serrata, 485f, 490f  
 Oral cavity, 325-378  
   anatomy of, 326, 326-327f  
   arterial supply to, 354t  
   boundaries and borders for  
     general information about, 332t  
     inferior (floor), 338-339t, 339-340f  
     lateral (cheeks), 337, 338f  
     posterosuperior (soft palate), 334, 334f, 335t, 336-337f  
     superior (hard palate), 332, 332t, 333f  
   clinical correlates for, 372-377, 372-377f  
   external features of, 327t  
   lips and cheeks, 327-328f, 327t  
   motor innervation of, 330f, 330t

# Index

## Oral cavity (*Continued*)

- sensory innervation of, 331f, 331t
    - vascular supply of, 328-329t, 329f
  - floor of. See Floor, of oral cavity
  - imaging of, 378f
  - nasal cavity and, 277f, 277t
  - palate of. See Palate
  - salivary glands and, 366, 366f, 367t
  - sensory innervation of, 362-363t, 363f
    - general information about, 358, 358f
    - palate, 364t, 365f
    - salivary glands, 368f, 368t, 369f, 370t, 371f
    - teeth, 359-360t, 361f
  - teeth in. See Teeth
  - venous drainage from, 356t, 357f
- Oral group, of muscles of facial expression, 161-162t, 163f
- Oral mucosa, 327t
- Akinosi block and, 544t
  - Gow-Gates block and, 542t
  - maxillary division nerve block and, 553t
  - nasopalatine nerve block and, 549t
- Oral vestibule, 326, 326f, 328f
- Orbicularis ciliaris of ciliary body, 485f
- Orbicularis oculi muscle, 164t, 165f
- Orbicularis oris muscle, 161t, 163f, 224f, 226f, 327t
- Orbit, 479-510
- arterial supply to, 499-500t, 501f
  - bones creating margins of, 482t, 483f
  - cranial nerve supply to, 489t, 491-494t, 491f, 493-494f
  - eye, 484, 484-485f, 486
  - frontal bone and, 28f, 28t
  - general information about, 480, 480f
  - lacrimal apparatus of, 504-505t, 504f, 506f
  - lacrimal bones and, 36t
  - maxilla and, 43t, 44f
  - maxillary division nerve block and, 553t
  - motor innervation of, 489t, 495t, 496f
  - muscles of, 487t, 488-489f
  - nasal cavity and, 277t
  - openings in, 482t
  - sensory innervation of, 489t, 492-494t, 493-494f
  - sphenoid bone and, 34t, 35f
  - venous drainage from, 502t, 503f
  - walls of, 482t, 483f
  - zygomatic bones and, 37t
- Orbital branch of pterygopalatine ganglion, 316f, 316t
- Orbital group, of muscles of facial expression, 164t
- Orbital part of lacrimal gland, 280f
- Orbital part of orbicularis oculi muscle, 164t, 165f
- Oropharynx, 326, 328f, 404t, 405f
- Os coxae, 567t, 567t
- Osseous cochlea, 454f
- Osseous labyrinth, 459t
- Osseous spiral lamina, 454f
- Ossicles, 457f
- Osteoarthritis, of TMJ, 245, 246f
- Osteology. See Bone(s)
- Osteomyelitis, 317, 319f, 320
- Ostium, 404t
- Otalgia, 477
- Otic ganglion, 220f, 222f, 369f, 531-532f
  - characteristics of, for parotid gland, 194t, 221t, 368t, 530t
  - course of, 219t
  - GVE fibers and, 97t, 98f
  - to infratemporal fossa, 210
- Otitis externa, acute, 476, 476f
- Otitis media, acute, 477, 477f
- Outer hair cells, 454f

## P

### Pain

- abducens palsy and, 103, 103f
- facial nerve and, 93t
- glossopharyngeal nerve and, 97t
- in middle ear, 477
- nasopalatine nerve block and, 549t
- tongue and, 388t
- trigeminal nerve and, 82t, 90-91t, 92f
- trigeminal neuralgia and, 182, 182f

- Palatal (palatine) glands, 332, 332f, 333f, 334
- parasympathetics of, 525t, 526f

### Palate

- arterial supply to, 352t
- clefing of, 20-23, 20f, 24f
- embryotic development of, 15, 15-16f
- hard, 326, 332, 332t, 333f
- nasal cavity and, 277t
- sensory innervation of, 364t, 365f
- soft, 326, 326f, 334, 334f, 335t, 336-337f
- sympathetics of, 261t, 527t, 528-529f
- venous drainage from, 356t

### Palatine aponeurosis, 409f

### Palatine bone

- anatomy of, 41f, 41t
- in facial skeleton, 154
- horizontal process of, 332
- nasal cavity and, 277f, 277t, 278f
- orbital process of, 483f
- pterygopalatine fossa and, 248f, 249t
- structures articulating with, 27t

### Palatine canal, 249t, 251f

- Palatine (palatal) glands, 332, 332f, 333f, 334, 525t
- parasympathetics of, 525t, 526f

### Palatine process, of maxilla, 43t, 44f

- hard palate and, 332, 333f
- imaging of, 378f
- nasal cavity and, 277t

### Palatine raphe, 16f, 17f, 332, 333f

### Palatine tonsil

- hard palate and, 333f
- in oral cavity, 326f, 332f
- oropharynx and, 404t
- soft palate and, 334f
- tongue and, 387f
- tonsillitis and, 377

### Palatine torus, 374, 374f

### Palatoglossal arches, 326f, 334f, 382t

### Palatoglossal fold, 404t

### Palatoglossus muscles, 334, 334f, 335t, 385-386f, 385t

### Palatopharyngeal arch, 326f, 334f

### Palatopharyngeus muscles

- oral cavity and, 334, 334f, 335t, 336f
- pharynx and, 406t, 409f
- swallowing and, 417, 418f

### Palatopharyngeus sphincter, 409f. See also Passavant's ridge

### Palmar interossei muscles, 575t, 576f

### Palmaris brevis muscle, 575t, 576f

### Palmaris longus muscle, 572t, 573f

### Palpebral part of lacrimal gland, 280f

### Palpebral part of orbicularis oculi muscle, 164t, 165f

### Pancreas, 596, 596f

### Parafollicular cells, 123

### Paranasal sinuses, 299-324

- anatomy of, 303f
- clinical correlates for, 317, 317-323f, 320-323
- drainage regions of, 303t
- ethmoid. See Ethmoid sinuses
- features of, 300-302f, 301t
- frontal. See Frontal sinuses
- frontal bone and, 28t
- general information about, 300
- imaging of, 324f
- maxillary. See Maxillary sinus
- nasal cavity and, 276
- nerve supply to, 293f
- sphenoid. See Sphenoid sinus

### Parasympathetic nervous system, 512

- cranial nerve III with corresponding sympathetics, 521-522t, 523-524f
- cranial nerve VII with corresponding sympathetics, 525t, 526f, 527t, 528-529f
- cranial nerve IX with corresponding sympathetics, 530t, 531-532f
- cranial nerve X with corresponding sympathetics, 533f, 533t
- functions of, 515t, 517f, 518f
- nasal cavity and, 290t
- parotid bed in, 194t, 195f
- parotid gland and, 221t, 222f

- Parathyroid glands, 18f, 108, 117t, 123, 124f  
 Parathyroid hormone, 123  
 Paraxial mesoderm, 2, 4  
 Parietal bones, 27f, 27t, 29f, 29t, 155f  
 Parietal lobe, 68f, 69  
 Parieto-occipital sulcus, 69  
 Parkinson's disease, 104, 104f  
 Parotid bed, 185-202  
   arterial supply to, 190f, 190t  
   clinical correlates for, 196-202, 197-202f  
   general information about, 186  
   major structures of, 188t, 189f  
   parasympathetics of, 194t  
   recess of, 187f, 187t  
   sensory nerves of, 192-193f, 192t  
   sympathetics of, 194t  
   venous drainage from, 191f, 191t  
 Parotid duct, 188t, 189f, 327t, 367t  
 Parotid gland  
   borders and structures of, 187f, 187t  
   features of, 188t, 367t  
   general information about, 366, 366f  
   glossopharyngeal nerve to, 97t  
   inferior portion of, 113t  
   parasympathetics of, 221t, 222f, 368f, 368t, 369f  
     anatomic pathway for, 530t  
   as parotid bed structure, 189f  
   submandibular triangle and, 114f  
   sympathetics of, 530t, 531-532f  
   tumors of, 199, 199f  
 Parotid gland fascial space, 445t  
 Parotid papilla, 337, 338f  
 Parotitis, 200, 200f  
 Pars flaccida, 455t, 456f  
 Pars tensa, 455t, 456f, 458f  
 Passavant's ridge, 409f, 417, 418f. *See also* Fold of Passavant  
 Pectoral girdle, bones of, 558f, 558t  
 Pectoral region muscles, 568t  
 Pectoralis major muscle, 109f, 568f, 568t  
 Pectoralis minor muscle, 568f, 568t  
 Pedicles, 56t, 562t, 563f  
 Pelvic splanchnic nerves, 73f  
 Pelvis, 563f, 566t, 567f  
 Periapical abscess, 449, 449f  
 Pericardium, 586t  
 Pericoronitis, 449, 449f  
 Pericranium, 156t  
 Periodontal abscess, 449, 449f  
 Periodontitis, 372  
 Periodontium, 343f  
 Periorbita, 308f, 489f  
 Periorbital edema, 183, 184f  
 Peripheral nervous system  
   functions of, 517f, 518f  
   general information about, 72, 72f, 73f  
 Peritonsillar fascial space, 445f, 445t  
 Perpendicular plate  
   of ethmoid bone, 38t, 39f, 40f  
   of palatine bone, 41f, 41t  
 Petrotympanic fissure, 32t, 33f, 53t, 54f  
 Petrous part, of temporal bone, 32t, 33f, 454f  
 Pharyngeal aponeurosis, 403f, 409f  
 Pharyngeal arches  
   abnormalities related to, 20-22, 20-22f  
   cranial nerves of, 4f  
   derivatives of, 5t, 6f, 6t  
   embryotic development of, 2, 4  
   facial development from, 13, 13-14f, 13t  
   skull development from, 10t  
 Pharyngeal artery, 251f, 252t, 411t  
 Pharyngeal branch of glossopharyngeal (IX) nerve, 414, 414t, 416f  
 Pharyngeal branch of vagus (X) nerve, 139t, 392t, 414, 414t, 416f  
 Pharyngeal canal, 34t, 35f, 249t, 250f, 251f  
 Pharyngeal clefts, 4, 7, 7t, 9t  
 Pharyngeal constrictor muscles, 410f, 410t  
 Pharyngeal glands, parasympathetics of, 525t, 526f  
 Pharyngeal membranes, 7, 7t, 9f, 9t  
 Pharyngeal nerve, 86t, 251f, 257t, 258f, 415t  
 Pharyngeal plexus  
   pharynx innervation by, 413f, 413t, 414, 414-415t, 416f  
   tongue innervation by, 392t  
   venous drainage from oral cavity and, 356t  
 Pharyngeal pouches  
   abnormalities related to, 19, 19f  
   embryotic development of, 4, 7, 7f, 7t, 8f, 9f  
 Pharyngeal raphe, 403f, 409f  
 Pharyngeal recess, 276f, 404t, 405f  
 Pharyngeal tonsil, 377, 404t, 405f  
 Pharyngeal tubercle, 30t, 31f, 403f, 409f  
 Pharyngeal vein, 136, 136t, 138f, 254t  
 Pharyngeal venous plexus, 174t, 215t, 230t  
 Pharyngoepiglottic fold, 403f  
 Pharyngotympanic tube  
   cartilaginous part of, 403f, 409f  
     with tube open vs. closed, 407f  
   inferior view of, 53t, 54f  
   middle ear's anterior wall and, 457t  
   nasal cavity and, 276f  
   pharyngeal opening of, 405f  
   soft palate and, 336-337f  
 Pharynx, 401-418  
   in anterior neck, 108  
   arterial supply to, 411t, 412f  
   clinical correlate for, 417, 418f  
   general information about, 402, 402-403f  
   innervation of, 414-415t, 416f  
   lymphatic drainage of, 636f  
   muscles of, 406t, 407-409f  
   parasympathetics of, 525t  
   parts of, 404t, 405f  
   pharyngeal plexus innervation of, 414, 414-415t  
   potential apertures in wall of, 410, 410f, 410t  
   spinal accessory nerve innervation of, 101f, 101t, 415t  
   venous drainage from, 413f, 413t  
 Philtrum, 268, 268f, 326f, 327f, 327t  
   embryotic development of, 13t, 14f, 16f  
 Phonation, 123  
 Phrenic nerve, 120t, 125t, 147f, 147t  
 Pia mater, 71f  
 Pineal gland, 69f  
 Piriform aperture, 276  
 Piriform fossa, 405f  
 Piriform recess, 404t  
 Pituitary gland, 34t, 69f, 314, 314f  
 Platysma muscle  
   deep fascia and, 442f  
   embryotic development of, 15f  
   facial expression and, 166t, 167f  
   superficial fascia and, 108, 109f, 440, 440f  
 Pleural cavity, 582, 582f  
 Plica fimbriata, 338t, 384t  
 Pons, 69, 69f, 92f  
 Posterior auricular artery  
   to external ear, 468f, 468t, 469f  
   to inner ear, 472t, 473f  
   to middle ear, 470t  
   to parotid space (bed), 190f, 190t  
   to scalp, 157t, 158f  
 Posterior auricular muscle, 166t, 167f  
 Posterior auricular nerve, 189f  
 Posterior auricular vein, 157t, 191f, 191t, 474t  
 Posterior ciliary arteries, 501f  
 Posterior cricoarytenoid muscle, 429f, 429t, 430f, 430t  
 Posterior deep temporal artery  
   to infratemporal fossa, 212t, 213-214f  
   to masticatory muscles, 228t, 229f  
   to temporal fossa, 206t, 206t  
 Posterior deep temporal vein, 207t, 230t  
 Posterior digastric muscle, 112f, 113, 115  
 Posterior division of auriculotemporal branch of mandibular nerve  
   course of, 89t  
   external ear, 463t, 464f  
   face, 178f, 178t  
   infratemporal fossa, 216t, 217f, 218f  
   parotid bed, 192f, 192t

# Index

- Posterior division of auriculotemporal branch of mandibular nerve (*Continued*)
  - scalp, 159t
  - temporal fossa, 208t, 209f
  - temporomandibular joint, 242f, 242t
- Gow-Gates block and, 542t
- Posterior division of inferior alveolar branch of mandibular nerve
  - course of, 89t
  - infratemporal fossa, 217f, 217t, 218f
  - teeth, 360t, 361f
- Posterior division of lingual branch of mandibular nerve, 89t, 216t, 217f, 218f, 221f
- Posterior division of mylohyoid branch of mandibular nerve, 89t, 217f, 217t
- Posterior ethmoidal artery
  - to ethmoid sinuses, 309f, 309t
  - to eye and orbit, 500t, 501f
  - to nasal cavity, 281t, 282f
  - to sphenoid sinus, 315f, 315t
- Posterior ethmoidal foramen, 51t, 52f, 55f, 55t, 482t
- Posterior ethmoidal nerve
  - course of
    - ethmoid sinuses, 310f, 310t
    - eye and orbit, 493f, 493t
    - sphenoid sinus, 316f, 316t
  - nasal branches of, 285f, 289f
  - in nasociliary branch of trigeminal nerve ophthalmic division, 84t, 85f
- Posterior inferior nasal branch of the greater palatine nerve, 87t, 88f, 287t, 288f
- Posterior lateral inferior nasal nerve, 292f, 310t
- Posterior lateral nasal artery branches, 309f, 309t, 310f, 315f, 315t
- Posterior lateral nasal branch of sphenopalatine artery, 271f, 283f
- Posterior lateral septal branch of sphenopalatine artery, 271f, 283f
- Posterior lateral superficial cervical lymph nodes, 635f
- Posterior lateral superior nasal nerve
  - course of, 86t
  - ethmoid sinuses, 310f, 310t
  - nasal cavity, 288f, 288t, 292f
- Posterior longitudinal ligament, 59t, 60f
- Posterior malleolar fold, 455t, 458f
- Posterior medial superior nasal nerve, 86t, 288t
- Posterior superior alveolar artery
  - to infratemporal fossa, 213f, 213t
  - to maxillary sinus, 312f, 312t
  - to nasal cavity, 283f
  - to teeth, 355t, 356f
- Posterior superior alveolar branch of maxillary nerve
  - course of, 86t, 88f
  - face, 176t
  - infratemporal fossa, 217t, 218f
  - pterygopalatine fossa, 251f, 255t, 256f
- Posterior superior alveolar nerve
  - intraoral injections and, 546, 547f
- Posterior superior alveolar nerve block, 548f, 548t
- Posterior superior alveolar nerve, course of
  - maxillary sinus, 313f, 313t
  - nasal cavity, 289f
  - teeth, 359t
- Posterior superior alveolar vein, 254t, 356t, 357f
- Posterior superior nasal nerve, 86t, 257t, 288f, 288t, 292f
- Posterior triangle, 108, 109f
  - anatomy of, 120, 120t, 121f
  - superficial fascia and, 440f
- Posterior wall, of middle ear, 457t
- Postganglionic neurons
  - autonomic nervous system, 512
  - course of
    - across pterygopalatine fossa, 261-262t
    - facial nerve correspondence, 527t
    - general anatomic pathway, 519t
    - glossopharyngeal nerve correspondence, 530t
    - greater palatine nerve, 505t
    - maxillary division distribution, 259t, 290t, 370t, 525t
    - nasal cavity and palate, 291t
- Postganglionic neurons (*Continued*)
  - oculomotor nerve correspondence, 521t, 522t
  - ophthalmic and maxillary division distribution, 370t, 525t
  - ophthalmic division distribution, 259t
  - parasympathetics of eye, 497t, 498f
  - parotid gland, 194t, 221t, 368t
  - sympathetics of eye, 498f, 499t
  - sympathetics of nasal cavity, 292t
  - in parasympathetic nervous system
    - glossopharyngeal nerve and, 531-532f
    - vagus nerve and, 533f, 533t
- Pouting, muscles for, 162t
- Preganglionic neurons
  - autonomic nervous system, 512
  - course of
    - across pterygopalatine fossa, 261t
    - chorda tympani nerve correspondence, 525t
    - facial nerve correspondence, 527t
    - general anatomic pathway, 519t
    - glossopharyngeal nerve correspondence, 530t, 531-532f
    - greater petrosal nerve correspondence, 259t, 505t, 525t
    - oculomotor nerve correspondence, 521t, 522t
    - ophthalmic and maxillary division distribution, 370t, 505t
    - ophthalmic division distribution, 370t
    - parasympathetics of eye, 497t, 498f
    - parasympathetics of parotid gland, 194t, 221t, 368t
    - sympathetics of eye, 498f, 499t
    - sympathetics of nasal cavity, 291t
    - sympathetics of parotid gland, 194t
    - in parasympathetic nervous system
      - glossopharyngeal nerve and, 531-532f
      - vagus nerve and, 533f, 533t
- Prelaryngeal ectopic thyroid, 19, 19f
- Premolars, 342f
  - mandibular, 350f, 350t
  - maxillary, 346f, 346t
  - nerve blocks to, 551t
- Pressure. *See* Touch
- Pretracheal fascial space, 446t, 447f
- Pretracheal layer of fascia, 441t, 442f
- Pretracheal lymph nodes, 635f
- Prevertebral deep layer of deep fascia, 108, 440f, 441t
- Prevertebral fascial space, 446t, 447f
- Primary cleft of lip and palate, 23, 24f
- Primary palate, 13t, 15, 15-16f
- Procerus muscle, 164t, 165f
- Promontory, 456f, 457t, 458f, 462f
- Pronator quadratus muscle, 572t, 573f
- Pronator teres muscle, 572t, 573f
- Proprioception, 82t, 90-91t, 92f
- Pseudomonas aeruginosa*, 476
- Psoas major muscle, 580t, 581f
- Pterion, 29f, 29t, 205f, 205t
- Pterygoid arteries, 212t, 213f, 228t, 229f
- Pterygoid canal
  - artery of, to pterygopalatine fossa, 251f, 252t, 253f
  - nerve of, to pterygopalatine fossa, 251f, 256f, 258f
  - pterygopalatine fossa and, 249t, 250f, 263f
  - sphenoid bone and, 34t, 35f
  - vein of, from pterygopalatine fossa, 254t
- Pterygoid fovea, 46f
- Pterygoid hamulus, 34t, 35f, 333f, 409f
- Pterygoid plexus
  - ears drained by, 474t
  - eye and orbit drained by, 502t, 503f
  - face drained by, 173, 173t, 174f, 174t
  - hematomas in, posterior superior alveolar nerve block and, 548t
  - infratemporal fossa drained by, 210, 215f, 215t
  - masticatory muscles drained by, 230f, 230t
  - nasal cavity drained by, 284f
  - pterygopalatine fossa drained by, 254f, 254t
- Pterygoid processes, 34t, 35f, 110f, 249t
- Pterygoid vein, 230t

- Pterygomandibular raphe**  
 hard palate and, 333f  
 inferior alveolar nerve block and, 539f  
 mandible and, 45t  
 in neck view, 110f  
 pharynx and, 408f, 409f  
 soft palate and, 337, 337f
- Pterygomandibular space**, 538t, 539f
- Pterygomaxillary fissure**, 110f, 249t, 251f
- Pterygopalatine fossa**, 247-263  
 arterial supply to, 252t  
 bordering structures of, 249t  
 branches within, 176t  
 general information about, 248, 248f  
 imaging of, 263f  
 maxillary division nerve block and, 553t  
 maxillary division nerve branches associated with, 86-87t, 255t, 256f  
 nasal cavity and, 276, 277t  
 openings for, 249t, 250-251f  
 palatine bone and, 41t  
 parasympathetics associated with, 259t, 260f  
 sympathetics associated with, 261-262t, 262f  
 venous drainage from, 254f, 254t
- Pterygopalatine ganglion**  
 branches of maxillary division of trigeminal nerve and, 86-87t, 88f, 257t, 258f  
 characteristics of  
   for lacrimal, nasal, palatine, pharyngeal, submandibular, and sublingual glands, 525t  
   for nasal cavity, 288f, 290t, 292f  
   for pterygopalatine fossa, 293f  
   for salivary glands, 370t, 371f  
 ethmoid sinuses and, 310t  
 orbital branch of, 316f, 316t  
 parasympathetics associated with, 259t  
 pterygopalatine fossa and, 251f
- Ptosis**, 80t, 103, 103f
- Pubis**, 566t, 567f
- Pulp cavity**, 343t
- Pupillary light reflexes**, ophthalmoplegia and, 183
- Pyramid**, middle ear's posterior wall and, 457t
- Pyramidal process**, 41t, 110f, 248f, 249t
- Q**
- Quadrangular membrane**, 428t
- Quadratus lumborum muscle**, 580t, 581f
- R**
- Radius**, 559t, 560f
- Rami communicantes**, 71f. *See also* Dorsal rami; Ventral rami  
   gray and white, 72f, 73f
- Rectum**, 593, 594, 594f
- Rectus abdominis muscle**, 580t, 581f
- Rectus capitis anterior muscle**, 129t, 130f
- Rectus capitis lateralis muscle**, 129t, 130f
- Rectus capitis posterior major**, 122, 122f, 122t, 131f, 131t
- Rectus capitis posterior minor**, 122f, 122t, 131f, 131t
- Recurrent laryngeal nerve** (branch of vagus)  
   to larynx, 104, 433t, 434f  
   to neck, 140t, 141f  
   to pharynx, 415t, 416f  
   in root of the neck, 125t
- Reissner's membrane**, 454f, 461f
- Respiratory epithelium**, 266, 300
- Retina**, 78t, 79f, 485f, 486
- Retinopathy**, diabetic, 509, 509f
- Retrodiscal pad**, of TMJ, 236f, 238t
- Retromandibular vein**, 114f, 191f, 191t, 284f
- Retromolar region**, 327t
- Retromolar trigone**, 540t
- Retropharyngeal fascial space**, 446t, 447f
- Retropharyngeal lymph nodes**, 307, 314, 636f
- Retropharyngeal space**, 409f
- Rhinitis**, 297, 297f
- Rhomboid major muscle**, 577t, 578f
- Rhomboid minor muscle**, 577t, 578f
- Rhytidectomy**, 154
- Ribosomes**, 66, 66f
- Ribs**, 564t, 565f  
   first, in root of the neck, 125, 126f
- Right lymphatic duct**, 125t, 634f
- Right recurrent laryngeal nerve**, 104f, 126f
- Rima glottidis**, 417, 430t
- Risorius muscle**, 162t, 163f
- Robin (Pierre) abnormalities**, 20, 20f
- Rods**, retinal, 78t, 79f, 490f
- Roof**, of middle ear, 457t
- Root canals**, of teeth, 343f
- Root of the neck**, 125, 125t, 126f
- Root of tongue**, 387f
- Roots**, of teeth, 342t, 343f
- Rotational movement**, in opening the mandible, 243, 243f
- Round window** (fenestra cochleae), 457t, 458f, 460f, 461f
- S**
- Saccule**, 459t, 460f, 461f  
   maculae of, 95-96f, 95t
- Sacral area**, of spinal cord, 70
- Sacral spinal nerves**, 70, 70f, 73f
- Sacrum**, 562t, 563f
- Salivary glands**, 368f  
   facial nerve in, 93t, 94f  
   features of, 367t  
   general information about, 186f, 366, 366f  
   oral cavity and, 326, 326f, 339f, 340f  
   parasympathetics of, 368t, 369f, 370t, 371f  
   parotid. *See* Parotid gland  
   sublingual. *See* Sublingual gland  
   submandibular. *See* Submandibular gland
- Salivation**  
   diminished, 234f  
   mastication and, 233, 234f, 367t, 368f
- Salpingopharyngeal fold**, 404t, 405f
- Salpingopharyngeus muscle**, 337f, 403f, 406t, 407f, 409f
- Satellite cells**, 66f, 67
- Scala tympani**, 454f, 460f, 461f
- Scala vestibuli**, 454f, 460f, 461f
- Scalene lymph nodes**, 635f
- Scalene muscles**  
   in neck, 109f  
   posterior triangle and, 120, 121f  
   prevertebral, 129t, 130f  
   venous drainage from, 157t
- Scalp**, 156-160. *See also* Facial expression, muscles of  
   arterial supply to, 157, 157t, 158f  
   general information about, 154, 156t  
   sensory nerves of, 159, 159t, 160f  
   venous drainage from, 157t, 158f
- Scalp group**, of muscles of facial expression, 166t, 167f
- Scaphoid fossa**, 455t, 456f
- Scapula**, 558f, 558t
- Scapular nerve**, 120t
- Scapular winging**, 105, 105f
- Scarpa's layer**, of abdominal wall, 556t, 557f
- Schlemm's canal**, 485f
- Schwann cells**, 66f, 67
- Sclera**, 484-485f, 486
- Scleral venous sinus**, 485f
- Secondary cleft of lip and palate**, 23, 24f
- Secondary palate**, 15, 15-16f
- Sella turcica**, 34t, 35f
- Semicircular canals**  
   cristae of, 95-96f, 95t  
   as inner ear boundaries, 459t, 460f, 461f
- Semicircular ducts**, 459t, 460f
- Semispinalis capitis muscle**, 120, 577t, 578f
- Sensory root of the ciliary ganglion**, 84t, 85f, 492t, 493f
- Septal artery**, 271t
- Septal cartilage**  
   anatomy of, 268, 269f  
   boundaries and relations of, 277f, 277t, 278f  
   development of, 15f, 36t  
   imaging of, 298f
- Serratus anterior muscle**, 568f, 568t
- Short ciliary nerves**, 84t, 85f, 490f, 493f
- Short posterior ciliary artery**, 500t



# Index

- Shoulder
  - muscles of, 569t, 570f
  - spinal accessory nerve lesions affecting, 105, 105f
- Sialoceles, of parotid gland, 202, 202f
- Sialoliths, 201
- Sigmoid colon, 593, 594, 594f
- Sigmoid sulcus, 29t
- Sinuses. *See* Paranasal sinuses
- Sinusitis, 317, 317-318f
- Sjögren's syndrome, 200
- Skin
  - Akinosi block and, 544t
  - Gow-Gates block and, 542t
  - of lower lip, mental nerve block and, 541t
  - over the scalp, 156f, 156t
- Skull
  - bones of, 28-46
    - articulations of, 27f, 27t
    - fractures of, 61, 61f, 62, 62f, 154
  - development of, 10t, 11f, 11t, 12t
  - general information about, 10, 26
  - major foramina and fissures in, 51-55
  - of newborn, 12f
  - views and sutures of, 47-50f, 47-50t
- SMAS (Superficial Muscular Aponeurotic System), 154
- Smell (sensation), 76t
- Soft palate
  - muscles of, 409f
  - as oral cavity border, 334, 334f, 335t, 336-337f
  - as oral cavity boundary, 326, 326f
  - pharynx and, 404t, 405f
  - swallowing and, 417, 418f
- Somatic general or special functional columns, of cranial nerves, 75. *See also* GSA function; GSE function; SSA function
- Somatic nervous system, 72
- Special functional columns, of cranial nerves, 75. *See also* SSA function; SVA function; SVE function
- Sphenoid bone
  - anatomy of, 34t, 35f
  - in facial skeleton, 155f
  - nasal cavity and, 277f, 277t, 278f
  - structures articulating with, 27f, 27t
- Sphenoid emissary foramen, 52f
- Sphenoid foramen, 51t
- Sphenoid sinus
  - arterial supply to, 315f, 315t
  - boundaries and relations of, 277f, 277t, 278f
  - conchae and, 279f
  - development of, 34t, 35f
  - drainage of, 303t
  - features of, 301t
  - general information about, 302f, 314
  - imaging of, 298f, 324f
  - nerve supply to, 316f, 316t
  - sinusitis in, 317
- Sphenomandibular ligament, 239f, 239t
- Sphenopalatine artery
  - to ethmoid sinuses, 309f, 309t
  - to nasal cavity, 281t, 283f
  - to palate, 352t, 353f
  - posterior lateral nasal and septal branches of, 271f, 283f
  - to pterygopalatine fossa, 251f, 252t, 253f
  - to sphenoid sinus, 315f, 315t
- Sphenopalatine foramen
  - nasal cavity and, 276, 278f, 283f
  - palatine bone and, 41f, 41t, 110f
  - pterygopalatine fossa and, 248f, 249t
    - diagram of, 251f
    - imaging of, 263f
  - infratemporal fossa and, 250f
  - vascular supply and, 253f
- Sphenopalatine vein, 254t, 284f, 284t, 356t
- Spinal accessory lymph nodes, 635f
- Spinal accessory (XI) nerve
  - carotid triangle and, 115t, 116f
  - fibers and functional column types of, 101f, 101t
  - lesions affecting, 105, 105f
  - neck innervation by, 140t
  - neck muscles and, 127t
  - in peripheral nervous system, 74, 74f
  - posterior triangle and, 120t, 121f
- Spinal cord, 70, 70-71f
- Spinal nerves, 70, 70f, 72, 73f
- Spinal part of spinal accessory nerve, 140t
- Spinalis cervicis muscle, 577t, 578f
- Spinalis thoracis muscle, 577t, 578f
- Spinous processes, 56f, 56t, 57f, 562t, 563f
- Spiral ganglion, 454f, 461f
- Spiral lamina, 461f
- Spiral ligament, 454f, 461f
- Splanchnic nerve, 72f
- Spleen, 598, 598f
- Splenius capitis muscle, 120, 577t, 578f
- Splenius cervicis muscle, 577t, 578f
- Squamous cell carcinoma, 399, 399f
- Squamous portion
  - of frontal bone, 28t
  - of temporal bone, 32t, 33f
    - development of, 11f
    - in newborn, 12f
  - temporal fossa and, 205f, 205t
  - temporomandibular joint and, 236, 237t
- SSA (special somatic afferent) function, 75, 78t, 95t
- Stapedius muscle, 93t, 458f, 462f, 462t
- Stapes, 457f, 458f, 460f
- Staphylococcus aureus*, 476
- Stensen's duct, 188t, 200f, 367t
- Stereocilia, 461f
- Sternocleidomastoid lymph nodes, 635f
- Sternocleidomastoid muscle
  - carotid triangle and, 115
  - investing layer of deep cervical fascia around, 108, 109f
  - muscular triangle and, 117
  - as neck triangles' border, 127t
  - parotid gland and, 187f, 187t
  - posterior triangle and, 120
  - spinal accessory nerve to, 101f, 101t
  - lesions affecting, 105, 105f
  - torticollis and, 149, 149f
- Sternohyoid muscle
  - carotid triangle and, 109f
  - in infrahyoid region, 111, 112f, 128t
  - muscular triangle and, 117, 117t, 118f
- Sternothyroid muscle
  - carotid triangle and, 109f
  - in infrahyoid region, 111, 128t
  - muscular triangle and, 117, 117t, 118f
- Sternum, 564t, 565f
- Stomach, 589, 589f
- Stomatitis, viral, 376
- Strabismus, 80t
- Strap muscles, 111, 117t
- Stratified squamous epithelium
  - of cheek, 337
  - nonkeratinized, 327t, 384t
  - oral cavity floor and, 338t
  - taste buds and, 383f
- Streptococcus pneumoniae*, 477
- Stripping wave, in swallowing, 417, 418f
- Styloglossus muscle
  - nerve supply to, 102f, 102t
  - pharynx and, 408f, 409f
  - tongue and, 385f, 385t
- Stylohyoid ligament, 110f, 408f, 409f
- Stylohyoid muscle
  - facial nerve and, 93t
  - parotid gland and, 187f, 187t
  - in suprahyoid region, 111, 112f, 128t
- Styloid process
  - infratemporal fossa and, 210f, 210t, 211f
  - of temporal bone, 32t, 33f, 110f
- Stylomandibular fascia, 187t

- Stylomandibular ligament, 110f, 239f, 239t  
 Stylomastoid foramen, 32t, 33f, 53t, 54f  
 Stylopharyngeus muscle, 97t, 337f, 406t, 408f, 418f  
 Subclavian artery  
   to neck, 132, 132t, 133f  
   posterior triangle and, 120t, 121f  
   in root of the neck, 125t, 126f  
 Subclavian lymph nodes, 635f  
 Subclavian vein  
   from neck, 136, 136t, 137f  
   posterior triangle and, 121f  
   in root of the neck, 125t, 126f  
 Subclavius muscle, 568f, 568t  
 Subcostal muscle, 579t  
 Subcostal plane, 556t, 557f  
 Sublingual caruncle, 326f, 340f, 366f, 384f  
 Sublingual ducts, 326f, 366f  
 Sublingual fascial space, 444t  
 Sublingual fold, 326f, 340f, 366f, 367t, 384f  
 Sublingual gland  
   facial nerve and, 93t, 94f  
   features of, 367t  
   general information about, 366, 366f  
   oral cavity floor and, 326f, 339f, 340f, 384f  
   parasympathetics of, 370t, 371f  
     anatomic pathway for, 525t, 526f  
     sympathetics of, anatomic pathway for, 527t, 528-529f  
 Sublingual papilla, 338t, 384t  
 Sublingual thyroid, 19, 19f  
 Submandibular duct  
   oral cavity and, 326f, 338t, 340f  
   salivary glands and, 366f, 367t  
   tongue and, 384f  
 Submandibular fascial spaces, 444t  
 Submandibular ganglion, 370t, 371f, 525t  
 Submandibular gland  
   facial nerve and, 93t, 94f  
   features of, 367t  
   general information about, 366, 366f  
   oral cavity floor and, 339f  
   parasympathetics of, 370t, 371f  
     anatomic pathway for, 525t, 526f  
     submandibular triangle and, 113t  
     sympathetics of, anatomic pathway for, 527t, 528-529f  
 Submandibular gland fascial space, 445t  
 Submandibular lymph nodes, 268, 304, 307, 311, 635f  
 Submandibular triangle, 109f, 111, 113, 113t, 114f  
 Submaxillary fascial space, 444t  
 Submental artery  
   to face, 170f  
   to oral cavity floor, 354t  
   submandibular triangle and, 113t, 114f  
   to tongue, 394t, 395f  
 Submental lymph nodes, 635f  
 Submental triangle, 109f, 111, 119, 119f, 119t  
 Submental vein, 113t, 114f, 396f, 396t  
 Suboccipital nerve, 58f, 122f, 122t, 160f  
 Suboccipital triangle, 122, 122f, 122t, 131f, 131t  
 Subparotid lymph nodes, 635f  
 Subscapularis muscle, 569t, 570f  
 Substernal ectopic thyroid, 19f  
 Subthalamus, 69  
 Succedaneous teeth, 341  
 Sulcus terminalis, 17f, 382t  
 Superficial cervical fascia, 438, 440, 440f  
 Superficial fascial space, 446t, 447f  
 Superficial layer of deep cervical fascia, 440f, 441t, 442f  
   general information about, 438, 439f  
   parotid gland and, 187f, 187t  
   trapezius muscle and, 108, 109f  
 Superficial Muscular Aponeurotic System (SMAS), 154  
 Superficial parotid lymph nodes, 635f  
 Superficial temporal artery  
   to external ear, 468f, 468t, 475f  
   to face, 169t, 170f  
   to parotid space (bed), 190f, 190t  
   to scalp, 157t, 158f  
   to temporal fossa, 206f, 206t  
   to temporomandibular joint, 240f, 240t  
 Superficial temporal vein  
   from ears, 474t, 475f  
   from face, 173t  
   from parotid bed, 191f, 191t  
   from scalp, 157t, 158f  
   from temporal fossa, 207f, 207t  
   from temporomandibular joint, 241f, 241t  
 Superior auricular muscle, 166t, 167f  
 Superior cervical ganglion  
   anatomic pathway for sympathetics of, 530t, 531-532f  
   characteristics of  
     for eye, 498f, 499t, 522t  
     general, 519t  
     for lacrimal, nasal, palatine, pharyngeal, submandibular, and sublingual glands, 527t  
     for nasal cavity, 291t, 292f  
     for parotid gland, 194t, 530t  
     for pterygopalatine fossa, 261t  
 Superior compartment, of temporomandibular joint, 236f, 238t, 239f  
 Superior constrictor muscle. *See* Superior pharyngeal constrictor muscle  
 Superior deep lateral cervical lymph nodes, 635f  
 Superior division of the oculomotor nerve, 495t, 496f  
 Superior horn of thyroid cartilage, 423t  
 Superior labial artery  
   to face, 169t, 170f  
   to lips and cheeks, 328t, 329f  
   to nasal cavity, 282t  
   nasal septal branch of, 271f  
   trauma to septal branch of, 269  
 Superior labial branch of infraorbital artery, 328t  
 Superior labial branch of infraorbital nerve, 87t, 331f, 331t  
 Superior labial vein, 173t, 174f, 272f, 329f, 329t  
 Superior lamina, of TMJ, 236f, 238t  
 Superior laryngeal artery, 412f, 431f, 431t  
 Superior laryngeal nerve  
   external branch of, 416f  
   internal branch of, 409f, 416f  
   to larynx, 433t, 434f  
   neck innervation, 139t, 141f  
 Superior laryngeal vein, 432f, 432t  
 Superior lateral palpebral artery, 501f  
 Superior lateral superficial cervical lymph nodes, 635f  
 Superior ligament of malleus, 456f  
 Superior longitudinal band, 59t, 60f  
 Superior longitudinal muscle, 386t, 387f  
 Superior macular arteriole and venule, 485f  
 Superior mediastinum, 584f, 584t  
 Superior mesenteric artery, 608, 608f  
 Superior nasal conchae, 279t  
 Superior nasal meatus, 41f, 279f, 279t, 303t, 307  
 Superior oblique muscle, 80f, 80t, 487t, 488-489f  
 Superior obliquus capitis muscle, 122, 122f, 122t, 131f, 131t  
 Superior omohyoid muscle, 115  
 Superior ophthalmic vein  
   from eye and orbit, 502t, 503f  
   from face, 174f, 174t  
   from nose, 272f, 272t  
 Superior orbital fissure, 51t, 52f, 55f, 55t, 482t  
 Superior palpebral artery, 500t  
 Superior petrosal sinus, 32t, 474t, 475f  
 Superior pharyngeal constrictor muscle  
   anatomy of, 403f, 406t, 408f, 409f  
   potential apertures in pharyngeal wall and, 410f, 410t  
   swallowing and, 418f  
 Superior rectus muscle, 487t, 488-489f  
 Superior salivatory nucleus  
   characteristics of, for lacrimal, nasal, palatine, pharyngeal, submandibular, and sublingual glands, 525t  
   nasal cavity innervation and, 290t, 293f  
   parasympathetic nervous system and, 370t, 371f  
     anatomic pathway for, 526f  
   in pterygopalatine fossa, 259t, 260f, 262f  
 Superior thyroid artery  
   muscular triangle and, 117t  
   to neck, 132, 132t, 134t, 135f  
   to pharynx, 411t

# Index

- Superior thyroid artery (*Continued*)
  - superior parathyroid glands and, 123, 124f
  - thyroid gland and, 123, 124f
- Superior thyroid lymph nodes, 635f
- Superior thyroid veins
  - carotid triangle and, 115t
  - from neck, 136, 136t, 137f, 138f
  - thyroid gland and, 123
- Superior tubercle, of thyroid cartilage, 423t
- Superior tympanic artery, 470t, 471f
- Superior wall of orbit, 482t
- Supinator muscle, 574t
- Supraclavicular lymph nodes, 635f
- Supraclavicular nerves, 120t, 145t, 146f
- Supraclavicular triangle, 120
- Suprahyoid fascial spaces, 443, 444-445t, 445f
- Suprahyoid lymph nodes, 635f
- Suprahyoid muscles, 128f, 128t
- Suprahyoid region of neck, 111
- Supraorbital artery
  - to eye and orbit, 500t, 501f
  - to face, 168f, 170f, 171t, 172f
  - to frontal sinuses, 305f, 305t
  - to scalp, 157t, 158f
- Supraorbital foramen, 482t
- Supraorbital nerve
  - as frontal branch of trigeminal nerve ophthalmic division, 84t, 85f
- Supraorbital nerve, course of
  - eye and orbit, 492t
  - face, 176t, 177f
  - frontal sinuses, 306f, 306t
  - scalp, 159t, 160f
- Supraorbital notch (foramen), 55f, 55t
- Supraorbital vein
  - from eye and orbit, 502t
  - from face, 168f, 173t, 174f
  - from scalp, 157t, 158f
- Suprarenal glands, 599, 600f
- Suprascapular artery, 120t, 121f, 412f
- Suprascapular nerve, 120t
- Suprascapular vein, 120t, 136t, 137f, 138f
- Supraspinatus muscle, 569t, 570f
- Suprasternal space, 440f, 442f
- Supratrochlear artery
  - to eye and orbit, 499t, 501f
  - to face, 170f, 171t, 172f, 173t
  - to frontal sinuses, 305f, 305t
  - to scalp, 157t, 158f
- Supratrochlear nerve
  - course of
    - eye and orbit, 492t, 493f
    - face, 176t, 177f
    - frontal sinuses, 306f, 306t
    - scalp, 159t, 160f
  - as frontal branch of trigeminal nerve ophthalmic division, 84t, 85f
- Supratrochlear vein, 157t, 158f, 174f, 502t, 503f
- Surgery
  - endoscopic, of paranasal sinuses, 323, 323f
  - of neck, voice effects from, 104f
- Suspensory ligament, 490f
- Sustentacular cells, 383f
- Sutural bones, 26
- Sutures
  - frontal, 28t
  - views of, 47-50f, 47-50t
- SVA (special visceral efferent) function
  - of cranial nerves, 75
  - facial nerve and, 93t
  - glossopharyngeal nerve and, 97t
  - olfactory nerve and, 76t
  - tongue and, 388t
  - vagus nerve and, 99t
- SVE (special visceral efferent) function
  - of cranial nerves, 75
  - facial nerve and, 93t
  - glossopharyngeal nerve and, 97t
  - spinal accessory nerve and, 101t
- SVE (special visceral efferent) function (*Continued*)
  - trigeminal nerve and, 82t
  - vagus nerve and, 99t
- Swallowing
  - mastication and, 224, 233, 234f
  - pharyngotympanic tube and, 407f
  - process of, 417, 418f
  - soft palate and, 334
- Swimmer's ear, 476, 476f
- Sympathetic nervous system, 512
  - functions of, 515t, 517f, 518f
  - general anatomic pathway, 519t, 520f
  - overview, 515t
  - T1-L2, 518f
- Sympathetic trunk, 115t, 125t, 148, 148f
- Symphysis, 57f, 63
- Synovial cavities, of cervical vertebrae, 60f
- Synovial fluid, 238t
- T**
- Taste (sensation), 97t, 98f, 388t
- Taste buds, 382t, 383f, 388f
- Tear formation and absorption, 504f, 504t
- Tectorial membrane, 59t, 60f, 454f, 461f
- Tectospinal tract, 81f
- Teeth, 341-351
  - age at eruption of, 341
  - anatomy of, 342-343t, 343f
  - arterial supply to, 355t
  - deciduous vs. permanent, 341, 342f
  - imaging of, 378f
  - mandibular, 45t, 46f
    - Akinosi block and, 544t
    - canines (cuspids), 348f, 348t
    - fractures of, 63f
    - Gow-Gates block and, 542t
    - incisors, 349f, 349t
    - inferior alveolar nerve block and, 538t
    - intraoral injections and, 537
    - molars, 351f, 351t
    - premolars, 350f, 350t
    - sensory innervation of, 360t, 361f
  - maxillary
    - alveolar process and, 43t
    - canines (cuspids), 344t, 345f
    - implants of, 322, 322f
    - incisors, 344t, 345f
    - intraoral injections and, 546, 552t
    - maxillary division nerve block, 553t
    - molars, 347f, 347t
    - permanent, 44f, 333f
    - premolars, 346f, 346t
    - sensory innervation of, 359t
  - permanent types of, 344t
  - surfaces of, 341t, 342f
  - venous drainage from, 356t
- Tegmen tympani, 456f, 458t
- Tegretol, 182
- Temperature (sensation)
  - facial nerve and, 93t
  - glossopharyngeal nerve and, 97t
  - tongue and, 388t
  - trigeminal nerve and, 82t, 90-91t, 92f
- Temporal bones
  - anatomy of, 32t, 33f
  - in facial skeleton, 155f
  - mastoid process, parotid gland and, 187f, 187t
  - structures articulating with, 27f, 27t
  - temporal fossa and, 205f, 205t
- Temporal branches of facial nerve
  - course of, 180t, 181f
  - within parotid bed, 189f
  - to temporal fossa, 208f, 208t, 209f
- Temporal fascial space, 444t
- Temporal fossa, 204-209
  - anatomy of, 204, 204f
  - arterial supply to, 206f, 206t
  - bordering structures of, 205f, 205t

- Temporal fossa (*Continued*)  
 nerve supply to, 208-209f, 208t  
 venous drainage from, 207f, 207t
- Temporal lobe, 68f, 69
- Temporalis muscle  
 infratemporal fossa and, 210  
 mastication and, 224f, 225t, 226f, 233  
 trigeminal nerve innervation of, 82f, 82t
- Temporomandibular joint (TMJ), 235-246  
 anatomic features of, 237-239t  
 arterial supply to, 240f, 240t  
 clinical correlates for, 243-244f, 243-245, 246f  
 dysfunction of, 236  
 general information about, 236, 236f  
 mandible and, 45t  
 mastication and, 233  
 sensory innervation of, 242f, 242t  
 venous drainage from, 241f, 241t
- Temporomandibular ligament, 238-239f, 239f
- Tensor tympani muscle  
 general information about, 462f, 462t  
 as middle ear boundary, 457t, 458f  
 trigeminal nerve innervation of, 82f, 82t  
 in tympanic cavity, 456f
- Tensor veli palatini muscle  
 external acoustic meatus and, 456f  
 mastication and, 227f  
 pharyngeal muscles and, 408f, 409f  
 pharyngotympanic tube and, 336-337f, 407f  
 of soft palate, 334, 334f, 335t  
 tendon of, 409f  
 trigeminal nerve innervation of, 82f, 82t
- Teres major muscle, 569t, 570f
- Teres minor muscle, 569t, 570f
- Terminal sulcus, 383f
- Thalamus, 69, 69f
- 3rd occipital nerve, 159t, 160f
- Thoracic area, of spinal cord, 70
- Thoracic cavity, root of the neck and, 125
- Thoracic duct, 125t, 634f
- Thoracic spinal nerves, 70, 70f, 73f
- Thoracic splanchnic nerves, 73f
- Thoracic vertebrae, 125, 562t, 563f
- Thoracolumbar fibers, 515t
- Thorax  
 bones of, 564t  
 heart in, 586-588f, 586-588t  
 inferior mediastinum in, 585f, 585t  
 lungs in, 583f, 583t  
 muscles of, 579f, 579t  
 overview of, 556t  
 pleural cavity in, 582, 582f  
 superior mediastinum in, 584f, 584t  
 vascular supply of, 606, 606f
- Thrombosis, cavernous sinus syndrome and, 183, 184f
- Thymus gland, 634f
- Thyroarytenoid muscle, 429f, 429t, 430f, 430t
- Thyrocervical artery, 132, 132t, 133f
- Thyroepiglottic ligament, 426f
- Thyroepiglottic muscle, 429f, 429t
- Thyroglossal duct remnant, ectopic thyroid and, 19, 19f
- Thyrohyoid membrane, 112f, 423f, 423t, 428f, 428t
- Thyrohyoid muscle, 109f  
 carotid triangle and, 115  
 in infrahyoid region, 111, 112f, 128t  
 muscular triangle and, 117t, 118f
- Thyroid cartilage  
 in anterior triangle of neck, 112f  
 embryotic development of, 15f  
 of larynx, 409f, 422f, 422t, 423f, 423t
- Thyroid cartilage lamina, 423f, 423t
- Thyroid gland  
 in anterior neck, 108, 112f, 124f  
 carotid triangle and, 115t, 116f  
 ectopic, 19, 19f  
 embryotic development of, 18, 18f  
 hyperthyroidism and, 152  
 hypothyroidism and, 151  
 inflammation of, voice effects from, 104, 104f
- Thyroid gland (*Continued*)  
 muscular triangle and, 117t, 118f  
 in suboccipital triangle, 123
- Thyroid lymph nodes, 635f
- Thyroid notch, 423t
- Thyroid tumors, voice effects from, 104, 104f
- Thyroiditis, 152
- Thyrototoxicosis, 152
- Thyroxine, 123
- Tic douloureux, 182, 182-183f
- TMJ. See Temporomandibular joint
- Tongue, 379-400  
 Akinosi block and, 544t  
 anatomy of, 380, 380-381f  
 arterial supply to, 394-395f, 394t  
 clinical correlates for, 397-400, 397-400f  
 dorsal surface structures of, 382t, 383f  
 embryotic development of, 15, 15f, 17f, 17t  
 frenulum of, 340f  
 glossopharyngeal nerve and, 97t, 98f  
 Gow-Gates block and, 542t  
 hypoglossal nerve lesions affecting, 106, 106f  
 hypoglossal nerve's GSE fibers and, 102t  
 lymphatic drainage of, 636f  
 mastication and, 224f  
 motor innervation of, 392t, 393f  
 muscles of, 385-386f, 385t, 386t, 387f  
 oral cavity and, 326  
 oral cavity floor and, 338t  
 sensory innervation of  
 general, 389-390t, 391f  
 special, 391-392f, 391t  
 types of, 388-389f, 388t  
 venous drainage from, 396f, 396t  
 ventral surface structures of, 384f, 384t
- Tongue-tie, 397, 397f
- Tonsillar artery, 411t, 412f
- Tonsillitis, 377, 377f
- Torticollis, 149, 149f, 150f
- Torus, 374, 374f
- Torus levatorius, 405f
- Torus tubarius, 404t, 405f
- Touch (sensation), 82t, 90-91t, 92f, 388t
- Trachea, 108, 110f, 112f, 117t, 125t
- Tractus solitarius, 93t
- Tragus, 455t, 456f
- Translational movement, in opening the mandible, 243, 243f
- Transpyloric plane, 556t, 557f
- Transverse arytenoid muscles, 430f, 430t
- Transverse cervical artery, 120t, 121f, 125t, 126f, 412f
- Transverse cervical chain of lymph nodes, 635f
- Transverse cervical nerves, 145t, 146f, 179f, 179t
- Transverse cervical vein, 120t, 136t, 137f, 138f
- Transverse colon, 593, 594f
- Transverse cricoarytenoid muscle, 429f, 429t
- Transverse facial artery  
 to face, 168f, 169t, 170f, 172f  
 to masticatory muscles, 228t, 229f  
 to nose, 270f  
 parotid gland and, 186  
 to parotid space (bed), 190f, 190t
- Transverse facial vein  
 from face, 168f, 173t  
 from masticatory muscles, 230f, 230t  
 from parotid bed, 191f, 191t
- Transverse foramen, 56f, 57f
- Transverse head of adductor pollicis muscle, 575t, 576f
- Transverse ligament of atlas, 59t, 60f
- Transverse muscle, of tongue, 386f, 387f
- Transverse processes, 56f, 56t, 57f, 563f
- Transverse rugae (plicae), 332
- Transverse sinus vein, 474t
- Transversus abdominis muscle, 580t, 581f
- Transversus thoracis muscle, 579f, 579t
- Trapezius muscle  
 anterior triangle of neck and, 112f  
 of back, 577t, 578f  
 investing layer of deep cervical fascia around, 108, 109f  
 as neck triangles' border, 127f, 127t

# Index

## Trapezius muscle (*Continued*)

- nerve supply to, 101f, 101t
- posterior triangle and, 120
- spinal accessory nerve lesions affecting, 105, 105f

## Trauma

- to septal branch of superior labial artery, 269
- surgical procedures on frontal sinus due to, 320, 320f

## Treacher Collins syndrome, 21, 21f

## Triangular fossa, 456f

## Triceps brachii muscle, 571t

## Trigeminal (V) nerve

- auriculotemporal branch of, 89t
- branches after infraorbital nerve emerges from infraorbital foramen of, 87t
- buccal branch of, 89t
- deep temporal branches of, 89t
- digastric muscle and, 127t
- fibers and functional column types of, 82-83f, 82t
- frontal branch of, 84t, 85f
- infraorbital canal branches of, 87t
- lacrimal branch of, 83t, 85f
- lingual branch of, 89t
- to lips and cheeks, 331t
- mandibular division (V<sub>3</sub>) of. *See* Mandibular division (V<sub>3</sub>) of trigeminal (V) nerve
- masseteric branch of, 89t
- maxillary division (V<sub>2</sub>) of. *See* Maxillary division (V<sub>2</sub>) of trigeminal (V) nerve
- middle cranial fossa branches of, 86t
- mylohyoid branch of, 89t
- mylohyoid muscle and, 128t
- nasociliary branch of, 84t, 85f
- ophthalmic division (V<sub>1</sub>) of. *See* Ophthalmic division (V<sub>1</sub>) of trigeminal (V) nerve
- ophthalmoplegia and, 103, 103f
- in peripheral nervous system, 74, 74f
- pharyngeal arches and, 5t
- proprioception of, 90-91t, 92f
- pterygoid branches of, 89t
- pterygopalatine fossa branches of, 86t
- pterygopalatine ganglia branches of, 86-87t
- sensory pathways of, 90-91t, 92f
- to tongue, 389f

## Trigeminal neuralgia, 182, 182-183f

## Trigeminothalamic lemniscus, 93t, 97t

## Triiodothyronine, 123

## Trismus, Akinosi block and, 544t

## Trochlear (IV) nerve

- eye and orbit innervation by, 495t, 496f
- eye muscles and, 488f
- fibers and functional column types of, 80f, 80t
- ophthalmoplegia and, 103, 103f, 183
- in peripheral nervous system, 74, 74f

## True pelvis, 566t

## True ribs, 564t, 565f

## Tubercle, of superior lip, 268f, 327f

## Tuberculosis, parotitis and, 200

## Tuberosity of maxilla, 110f

## Tympanic branch of glossopharyngeal nerve, 463t

## Tympanic canaliculus, 32t, 33f, 53t, 54f, 457t

## Tympanic cavity, 460f

## Tympanic cells, 458f

## Tympanic membrane, 9t, 455t, 456f

## Tympanic neurectomy, 198

## Tympanic part, of temporal bone, 32t, 33f

## Tympanic plexus, 456f, 458f, 466t

## Tympanomastoid fissure, 53t

## U

## Ulna, 559t, 560f

## Ultimobranchial body, development of, 18, 18f

## Umbo, 456f, 460f

## Uncinate process, 38t, 39f, 278f, 298f

## Unipolar neurons, 66, 66f

## Upper limbs

- arterial supply to
  - antebrachium, 602, 602f
  - axilla, 601, 601f
  - brachium, 602, 602f

## Upper limbs (*Continued*)

- bones of, 558f, 559t, 560-561f
- lymphatics of, 634f
- muscles of
  - brachium, 571f, 571t
  - extensor surface of antebrachium, 574f, 574t
  - flexor surface of antebrachium, 572t, 573f
  - hand, 575t, 576f
  - pectoral region, 568f, 568t
  - shoulder, 569t, 570f
- nerve supply to, 613, 613f, 614-616t, 616f
- overview of, 556t
- venous drainage from, 605, 605f

## Ureters, 599, 600f

## Utricle, 95-96f, 95t, 459t, 460f

## Utriculosaccular duct, 459t

## Uveal tract, 486

## Uvula, 16f, 17f, 326f, 334, 403f

## Uvular muscle, 333f, 334, 335t

## V

## Vagus (X) nerve

- in autonomic nervous system, 533f, 533t
- carotid triangle and, 115t, 116f
- fibers and functional column types of, 99t, 100f
- lesions affecting voice on, 104, 104f
- neck innervation, 139t
- in peripheral nervous system, 73f, 74, 74f
- pharyngeal arches and, 4f, 5t
- in root of the neck, 125t
- tongue innervation by, 389f
- Vallate papillae, 17f, 382t, 383f, 388f
- Ventral rami. *See also* Suboccipital nerve
  - cervical spinal nerves and, 121f
  - geniohyoid muscle and, 128t
  - of the neck, 147f, 147t
  - in peripheral nervous system, 72f
  - sensory innervation of neck by, 143, 143t

## Ventral root, of spinal cord, 71f, 72f

## Ventricular fold, 418f

## Vermilion zone, 327f, 327t

## Vertebral arteries

- to neck, 132, 132t, 133f
- in root of the neck, 125t, 126f
- suboccipital triangle and, 122, 122t

## Vertebral column, 3f, 562t, 563f

## Vertebral foramina, 56f, 56t, 57f, 563f

## Vertebral prominens, 56t

## Vertebral ribs, 564t, 565f

## Vertebral veins, 122t, 125t, 136, 136t

## Vertebrochondral ribs, 564t, 565f

## Vertebrosteral ribs, 564t, 565f

## Vertical muscle, of tongue, 386t, 387f

## Vesalius foramen, 52f

## Vestibular aqueduct, opening of, 51t, 52f

## Vestibular fold, 327t

## Vestibular ligament, 428f, 428t

## Vestibular membrane, 454f, 461f

## Vestibular nerve, 454f, 467f, 467t

## Vestibule

- of inner ear, 459t, 460f
- of larynx, 417, 418f
- of nose, 268, 276f, 277f
- of oral cavity, 326, 326f, 328f
- Vestibulocochlear (VIII) nerve, 454f
  - course of, to inner ear, 467f, 467t
  - fibers and functional column types of, 95-96t, 95t
  - in peripheral nervous system, 74, 74f

## Vibrissae, of nose, 268

## Vidian nerve, of pterygoid canal

- nasal cavity and, 292f, 293f
- to pterygopalatine fossa, 256f, 257t
- pterygopalatine ganglion and, 258f, 260f

## Viral infections, parotitis and, 200

- Visceral general or special functional columns, of cranial nerves, 75. *See also* GVA function; GVE function; SVA function; SVE function

Visceral region of cervical fascia, 440f, 441t  
 Viscerocranium, 10t, 11f  
 Vision, 78f, 78t, 491f, 491t  
 Vocal cords, muscles altering, 430t  
 Vocal function, 104, 104f, 123  
 Vocal ligaments, 428f, 428t, 430f  
 Vocal process of arytenoid cartilage, 425f, 425t  
 Vocalis, 430t  
 Voice, 104, 104f, 123

Vomer  
   anatomy of, 40f, 40t  
   in facial skeleton, 155f  
   nasal cavity and, 277f, 277t, 298f  
   structures articulating with, 27f, 27t

## W

Waldeyer's ring, 377  
 Wharton's duct, 367t  
 White matter, of spinal cord, 70, 71f  
 White ramus communicans, 72f, 73f, 81f  
 Wormian bones, 26  
 Wrist, arterial supply to, 604, 604f  
 Wryneck, 149, 149f, 150f

## X

Xerostomia, 201, 201f  
 Xiphoid process, 564t, 565f

## Z

Zonular fibers, 485f  
 Zygapophyseal joints, 57f  
 Zygomatic arch, 32t, 37f, 37t, 205f, 205t

Zygomatic bones (zygoma)  
   anatomy of, 37f, 37t  
   in facial skeleton, 154f, 155f  
   fractures of, 61, 61f, 154  
   orbital margin and, 482t, 483f  
   structures articulating with, 27f, 27t  
   temporal fossa and, 205f, 205t  
   Treacher Collins syndrome and, 21

Zygomatic branches of facial nerve, 180t, 181f, 186, 186f, 189f

Zygomatic foramen, 482t

Zygomatic nerve  
   course of, 86t, 88f  
   eye and orbit, 494f, 494t  
   face, 176t, 177f  
   pterygopalatine fossa, 251f, 255t, 256f

Zygomatic process  
   of frontal bone, 28t  
   maxilla and, 43t, 44f  
   in temporal bones, 32t, 33f  
   temporal fossa and, 205f, 205t  
   zygomatic bones and, 37t

Zygomaticofacial artery, 168f, 172f

Zygomaticofacial foramen, 27f, 37f, 55f, 55t

Zygomaticofacial nerve, 177f, 177t

Zygomaticofacial vein, 168f

Zygomaticoorbital artery, 168f

Zygomaticoorbital vein, 168f

Zygomaticotemporal artery, 168f

Zygomaticotemporal nerve, 159t, 160f, 176t, 177f

Zygomaticotemporal vein, 168f

Zygomaticus major muscle, 161t, 163f

Zygomaticus minor muscle, 161t, 163f