ATLAS OF ANATOMY

Sobotta

16th Edition

Edited by
Friedrich Paulsen and
Jens Waschke

English Version with
Latin Nomenclature

Head, Neck and Neuroanatomy

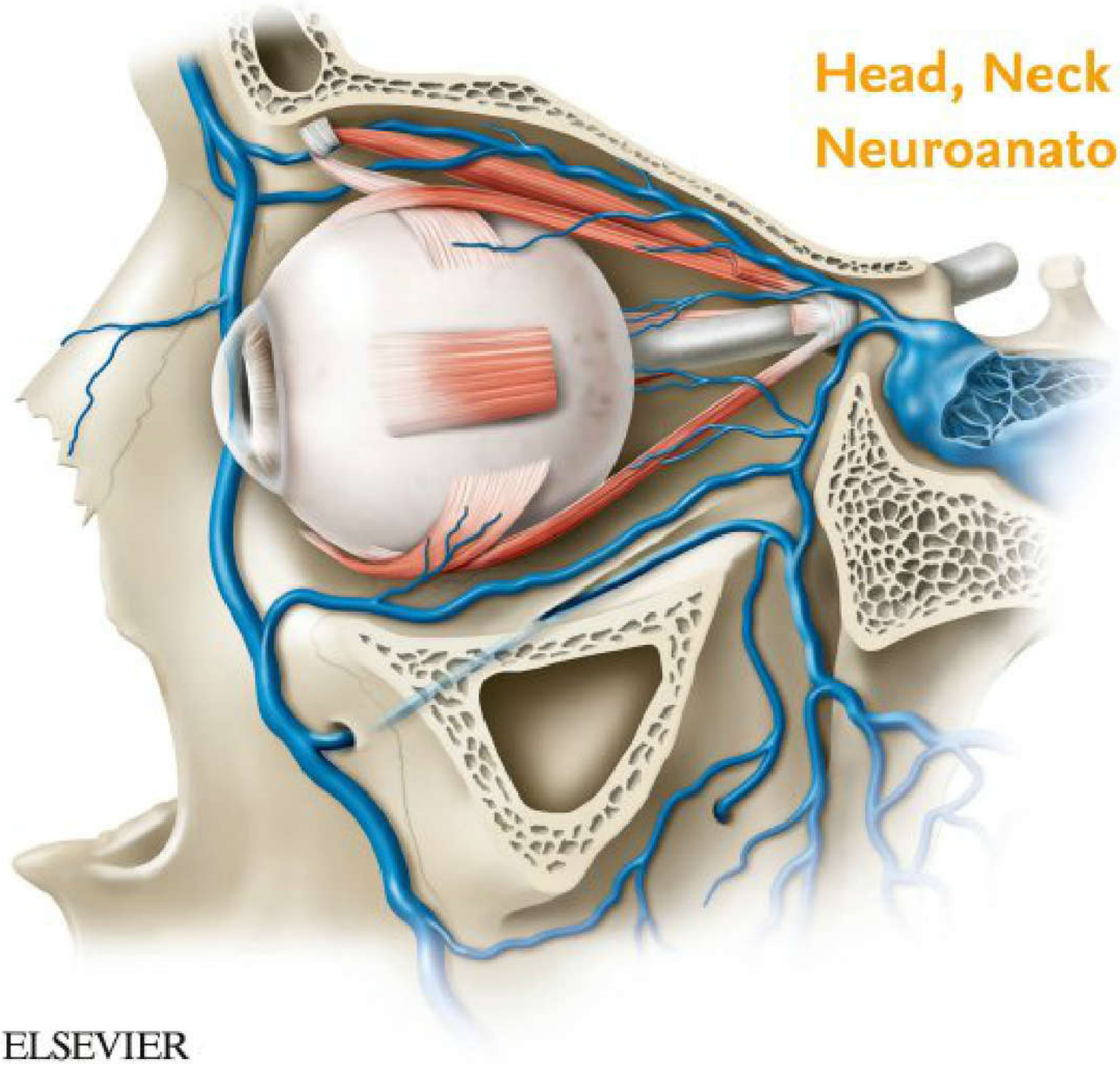

ELSEVIER

F. Paulsen, J. Waschke

Sobotta

Atlas of Anatomy

Friedrich Paulsen, Jens Waschke (Eds.)

Sobotta

Atlas of Anatomy

English Version with Latin Nomenclature

Head, Neck and Neuroanatomy

16th Edition

ELSEVIER

ELSEVIER
Hackerbrücke 6, 80335 Munich, Germany
All business correspondence should be made with:
books.cs.muc@elsevier.com

Original Publication
Sobotta Atlas der Anatomie
© Elsevier GmbH, 2017.
All rights reserved.
ISBN 978-3-437-44023-6

This translation of Sobotta Atlas der Anatomie, 24th edition by Friedrich Paulsen and Jens Waschke was undertaken by Elsevier GmbH.

ISBN 978-0-7020-5271-2

All rights reserved
16th edition 2018
© Elsevier GmbH, Munich, Germany

Notice
The translation has been undertaken by Elsevier GmbH at its sole responsibility.
Knowledge and best practice in this field are constantly changing. As new research an experience broaden our understanding, changes in research methods, professional practices, or medical treatment may become necessary.
Practitioners and researchers must always rely on their own experience and knowledge in evaluating and using any information, methods, compounds or experiments described herein.
Because of rapid advances in the medical sciences, in particular, independent verification of diagnoses and drug dosages should be made.
To the fullest extent of the law, no responsibility is assumed by Elsevier, authors, editors or contributors in relation to the translation or for any injury and/or damage to persons or property as a matter of products liability, negligence or otherwise, or from any use or operation of any methods, products, instructions, or ideas contained in the material herein.

Bibliographic Information published by the Deutsche Nationalbibliothek
The Deutsche Nationalbibliothek lists this publication in the Deutschen Nationalbibliografie; detailed bibliographic data is available on the Internet at http://www.d-nb.de/.

18 19 20 21 22 5 4 3 2 1

All rights, including translation, are reserved. No part of this publication may be reproduced or transmitted in any form or by any means, electronic or mechanical, including photocopying, recording, or any information storage and retrieval system, with our permission in writing by the publisher. Details on how to seek permission, further information about the Publisher's permissions policies and our arrangements with organizations such as the Copyright Clearance Center and the Copyright Licensing Agency, can be found at our website: www.elsevier.de/rechteundlizenzen/

Content Strategist: Dr Konstanze Knies, Susanne Szczepanek
Content Project Management: Dr Andrea Beilmann, Sibylle Hartl
Translation: Lingo24 Ltd., Edinburgh, United Kingdom
Production Management: Dr Andrea Beilmann, Sibylle Hartl
Layout: Nicola Kerber, Olching, Germany
Composed by: abavo GmbH, Buchloe, Germany
Printed and bound by: Drukarnia Dimograf Sp. z o. o., Bielsko-Biała, Poland
Cover Design: Stefan Hilden, hilden_design, München, Germany; Spiesz Design, Neu-Ulm, Germany

More Information at www.elsevier.de

This atlas was founded by Johannes Sobotta + ((Sterbekreuz)), former Professor of Anatomy and Director of the Anatomical Institute of the University in Bonn, Germany.

German Editions:
1st Edition: 1904–1907 J. F. Lehmanns Verlag, Munich, Germany
2nd–11th Edition: 1913–1944 J. F. Lehmanns Verlag, Munich, Germany
12th Edition: 1948 and following editions
Urban & Schwarzenberg, Munich, Germany
13th Edition: 1953, ed. H. Becher
14th Edition: 1956, ed. H. Becher
15th Edition: 1957, ed. H. Becher
16th Edition: 1967, ed. H. Becher
17th Edition: 1972, eds. H. Ferner and J. Staubesand
18th Edition: 1982, eds. H. Ferner and J. Staubesand
19th Edition: 1988, ed. J. Staubesand
20th Edition: 1993, eds. R. Putz and R. Pabst, Urban & Schwarzenberg, Munich, Germany
21st Edition: 2000, eds. R. Putz and R. Pabst, Urban & Fischer, Munich, Germany
22nd Edition: 2006, eds. R. Putz and R. Pabst, Urban & Fischer, Munich, Germany
23rd Edition: 2010, eds. F. Paulsen and J. Waschke, Urban & Fischer, Elsevier, Munich, Germany
24th Edition: 2017, eds. F. Paulsen and J. Waschke, Elsevier, Munich, Germany

Foreign Editions:
Arabic
Chinese
Croatian
Czech
English (nomenclature in English or Latin)
French
Greek
Hungarian
Indonesian
Italian
Japanese
Korean
Polish
Portuguese
Russian
Spanish
Turkish
Ukrainian

Prof. Friedrich Paulsen

Dissection course for students

In his teaching, Friedrich Paulsen puts great emphasis on ensuring that the students in his dissection classes can actually work on body donation cadavers. *'Carrying out dissection yourself is not only extremely important for gaining a three-dimensional understanding of anatomy, forming the fundamental basis of virtually any field of medical science. In dissection classes you will also experience for the first time the touch and feeling of the human body, the organs and individual tissues, but in most cases it will also be your first intensive encounter with issues around death and dying, and the clinical causes of death. You will not only study anatomy, but also learn how to deal with a quite unique and challenging situation as part of a team. Never again will you be in such close contact with your fellow students and teaching staff.'*
Friedrich Paulsen was born in Kiel in 1965 and, after completing his 'Abitur' in Brunswick, he initially trained as a nurse. He then studied medicine at the Christian Albrecht University (CAU) in Kiel. After his house officer training at the Oromaxillofacial Surgery Clinic and a period as resident physician at the ENT Clinic of CAU, in 1998 he moved to the Anatomical Institute of CAU where he graduated as medical doctor in 1997 and further qualified by performing his State doctorate in anatomy in 2001. In 2003 he was offered full professorship at the Anatomy Departments of the Ludwig Maximilians University (LMU) in Munich and the Martin Luther University (MLU) in Halle/Wittenberg. In Halle, he founded a clinical anatomy training centre. After declining yet another professorship, this time at the University of Saarland, he accepted a post at the Friedrich Alexander University (FAU) in Nürnberg as Professor of Anatomy and Head of its Anatomical Institute, a post he has held since 2010. He has continued to decline professorships offered by a number of other renowned universities.
Friedrich Paulsen is an honorary member of the Anatomical Society of Great Britain and Ireland as well as Romania and has been granted numerous scientific awards including the Dr Gerhard Mann Sicca research prize, the Sicca research prize of the German Federation of Ophthalmologists, and the Commemorative Medal of the Comenius University in Bratislava. Additionally, he received several teaching awards.
The key focus of his research is on the innate immune response of the eye surface, and on investigating the causes of dry eyes. Visiting research fellowships have taken him to Spain and the United Kingdom. He is the editor of the journal *Annals of Anatomy* and, as vice-president of Learning and Teaching (until 3/2018), and now People (since 4/2018) also a member of the FAU university administration since 2016.

Prof. Dr. Friedrich Paulsen
Institute of Anatomy, Department of Functional and Clinical Anatomy
Friedrich Alexander University Erlangen-Nürnberg
Universitätsstr. 19
91054 Erlangen
Germany

Prof. Jens Waschke

Making courses more clinically relevant

For Jens Waschke, one of the most important challenges in the teaching of modern anatomy is how to optimally adapt the courses to meet the requirements of clinical training and subsequent professional practice.
'The clinical aspects of the Atlas give students in the first semesters of medical school a grounding in anatomy and at the same time show them the importance of having a thorough understanding of human anatomy for their subsequent clinical practice, instead of just learning anatomical structures by rote. On the other hand, we prefer to avoid covering highly specialised details that are only needed by a few specialists for occasional diagnostic procedures or surgery, as is the case in other contemporary anatomy books. Since students at the beginning of their training are unable to distinguish between the necessary basics and specialised details, this can cause a mental overload and prevent them from focusing on the essentials.'
Jens Waschke (born in 1974 in Bayreuth) studied medicine at the University of Würzburg, achieving a doctorate in anatomy under Prof. Detlev Drenckhahn in the year 2000. After his intership training in the Anatomy and Internal Medicine Departments, he qualified as a professor of anatomy and cell biology in 2007. Jens Waschke spent nine months as a visiting scholar at the Davis campus of the University of California under Prof. Fitz-Roy Curry in 2003–2004. From 2008 onward he chaired the newly established Department III of the University of Würzburg before being appointed professor at the Ludwig Maximilians University in Munich, where he has been the head of Department I (Vegetative Anatomy) of the Anatomical Institute since 2011. Jens Waschke is heavily involved in the German Anatomical Society as an examiner in specialist anatomy and a member of its Study Commission, and he heads their working group on reducing formaldehyde exposure. He is a representative of the IFAA (International Federation of Associations of Anatomists) and an honorary member of the Anatomical Society of Ethiopia (ASE).
In his research he primarily investigates the biological mechanisms regulating cell adhesion and the external and internal barrier functions of the human body. His research predominantly focuses on the regulation of the endothelial barrier during inflammation, and also the mechanisms behind the impaired cell adhesion seen in diseases such as the blistering skin disorder pemphigus, Crohn's disease and arrhythmogenic cardiomyopathy. The aim is to better understand cell adhesion and to discover new treatment approaches.

Prof. Dr. Jens Waschke
Institute of Anatomy
Department I – Vegetative Anatomy
Ludwig Maximilians University (LMU)
Pettenkoferstr. 11
80336 Munich
Germany

Preface of the 24th German Edition

In the preface of the first edition of his atlas in May 1904, Johannes Sobotta writes: 'Long-standing experience in cadaver dissection classes has prompted the author to ensure that the illustrations of the peripheral nervous system and the blood vessels depict the relevant structures in the same way that the student is accustomed to seeing them on the cadaver, i.e. that they depict the vessels and nerves from the same region together. Furthermore, the atlas alternates between pages of text and full-page diagrams. The latter contain the key illustrations in the atlas, while the former – in addition to sketches and schematic drawings and legends – contain a brief, concise text to help the student find information quickly when using the book in the dissection hall.'

Just as fashions change on a regular basis, so do students' reading and studying habits. The ubiquitousness of multi-media and the ready availability of information and stimuli are surely the main reasons why these habits are changing at a much faster rate than ever before. Publishers and publishing houses must stay abreast of these developments and of students' changing expectations regarding atlases and textbooks they wish to use, as well as ensuring the digital availability of the contents. In addition to interviews with students and systematic surveys, a publisher can sometimes gauge students' expectations from the textbook market itself. Detailed textbooks claiming to be completely comprehensive are increasingly being abandoned in favour of textbooks that didactically meet students' educational needs and cover the contents of their courses and exams – whether they are studying medicine, dentistry or biomedical science. Likewise, although the images in atlases such as Sobotta have fascinated many generations of doctors and medical professionals around the world with their precise naturalistic representations of real dissections, they are sometimes perceived by students as being too complicated and too detailed. This realisation requires us to consider how we can build upon the obvious strengths of an atlas – which in the course of over 100 years of tradition and 23 German editions, has become a benchmark of accuracy and quality – to meet modern didactic concepts without the overall work losing its unique, exclusive characteristic and its originality.

For educational reasons, we have maintained the Sobotta's original concept and chosen to publish the atlas, as it has been since the first edition, in three volumes: General Anatomy and Musculoskeletal System (1); Internal Organs (2); and Head, Neck and Neuroanatomy (3). And while the concept mentioned in the preface of the first edition, i.e. linking the pictures in the Atlas with an explanatory text, may be old-fashioned, it has now come back into fashion – we have simply modernised the concept. Each picture is thus completed with a short explanatory text to introduce the students to the structure depicted and to explain why those particular dissection and depiction methods have been chosen for that particular region. The individual chapters have been systematically structured to follow today's methods of studying, while various illustrations have been updated or replaced. The majority of these new illustrations have been designed from the point of view of the learner, to make it easier to study the key pathways of blood supply and innervation. We have furthermore revised numerous existing illustrations and reduced the number of labels, using bold type to facilitate access to the anatomical content. The numerous clinical practice examples ('Clinical Remarks') show the somewhat 'dry' subject of anatomy at its most vibrant best, demonstrating to beginners how relevant anatomy is for their subsequent professional life and giving them a tantalising taste of their clinical training to come. Another revised feature is the introductory preface to the individual chapters, which sum up the content and the key issues, and include a real-life clinical case. In addition, each chapter ends with a summary of questions which would typically be asked in oral anatomy exams and exam tests. As in the 23rd edition, each chapter contains a brief introduction to the embryology of each body region.

Readers should please note two things:

1. The 24th edition of the Sobotta Atlas cannot replace an explanatory textbook.
2. No matter how good an educational concept is, students still have to put in many hours of intensive studying themselves – a good concept can but make that knowledge more accessible. Learning anatomy is not difficult, but it does take a lot of time; time that is well spent, since everybody – doctor and patient – will benefit from it in the long run. The aim of the 24th edition of the Sobotta Atlas is not only to facilitate your study, but also to make the time you spend studying engaging and interesting, so that the atlas is something you will repeatedly want to pick up and consult, both during your medical training and your subsequent professional career.

Erlangen and Munich, summer of 2017,
exactly 113 years after the first edition was published

Friedrich Paulsen and Jens Waschke

Acknowledgements of the 24th German Edition

The work on the 24th edition of the Sobotta Atlas has once again been a lot of fun, and this intensive involvement has continued to strengthen our sense of pride in the Sobotta.
Today, more than ever, an extensive anatomy atlas of the calibre of the Sobotta requires a lot of teamwork with the coordination of the publishing house. The cornerstone of the 24th edition has been laid by Dr Katja Weimann, who extensively coordinated the project. We are very grateful for her hard work. Also, without the long-standing experience of Dr Andrea Beilmann, who has worked on several previous editions of the Sobotta and has been a true pillar of strength for the Sobotta team, many things would not have been possible. We would like to thank her again most profusely for all her help and support. Benjamin Rempe, another member of the four-person team behind the 24th edition of the Sobotta, has contributed to Sobotta for the first time, approaching the task with real passion and enthusiasm. His unique way of motivating the team served as a continual source of encouragement and motivation for the editors. Benjamin: thank you very much. We fondly recall the monthly conference calls in which Benjamin Rempe and Dr Andrea Beilmann helped us carefully craft the Sobotta Atlas and, despite their different approaches, showing a remarkable gift for intuitively adopting a uniform working style. Sibylle Hartl coordinated the project in collaboration with Dr Andrea Beilmann and was responsible for the entire print production. We are truly grateful to her. Without the tenacity and the protective hand of Dr Dorothea Hennessen and Rainer Simader, who were both in charge of the overall management of the 'Sobotta 24th edition' project and who never lost faith in their Sobotta team or the tight schedule, this edition in its present form would not have been possible. Others whom we are similarly grateful to for their involvement in the project and their share of its success are: Dr Antje Kronenberg (editing), the abavo GmbH team (technical image processing and typesetting) and Nicola Kerber (layout design). We would very much like to thank Dr Ursula Osterkamp-Baust for exhaustively compiling the index.

Special thanks to our team of illustrators Dr Katja Dalkowski, Marie Davidis, Johannes Habla, Anne-Kathrin Hermanns, Martin Hoffmann, Sonja Klebe, Jörg Mair and Stephan Winkler, who in addition to updating the existing images also helped us develop a large number of new illustrations.
For their help in producing the clinical images, we would also like to thank Dr Frank Berger, Institute of Clinical Radiology of Ludwig Maximilians University, Munich; Prof. Christopher Bohr, Phoniatrics and Paediatric Audiology, ENT Clinic at Friedrich Alexander University, Erlangen/Nürnberg; Dr Eva Louise Bramann, Ophthalmology Clinic at Heinrich Heine University, Düsseldorf; Prof. Andreas Dietz, Director of the ENT Clinic and Outpatients' Clinic at the University of Leipzig; Prof. Gerd Geerling, Ophthalmology Clinic at Heinrich Heine University, Düsseldorf; Dr Berit Jordan, University Clinic and Outpatients' Clinic for Neurology, Martin Luther University, Halle/Wittenberg; Dr Axel Kleespies, Surgical Clinic, Ludwig Maximilians University, Munich; Prof. Norbert Kleinsasser, University Clinic for Illnesses of the Ear, Nose and Throat, Julius Maximilians University, Würzburg; Dr Hannes Kutta, ENT practice, Hamburg-Altona/Ottensen; Dr Christian Markus, Anaesthesiology Clinic, Julius Maximilians University, Würzburg; Jörg Pekarsky, Institute for Anatomy II, Friedrich Alexander University, Erlangen/Nürnberg; Dr Dietrich Stövesandt, Clinic for Diagnostic Radiology, Martin Luther University, Halle/Wittenberg; Prof. Jens Werner, Surgical Clinic, Ludwig Maximilians University, Munich; Dr Tobias Wicklein, Erlangen, and Prof. Stephan Zierz, Director of the University Clinic and Outpatients' Clinic for Neurology, Martin Luther University Halle/Wittenberg.
Last but not least, we would like to thank our families, who not only were very gracious and understanding of all the time we devoted to the 24th edition of the Sobotta, but who also gave us very helpful suggestions whenever we needed feedback. You have been a true support.

Erlangen and Munich, summer of 2017
Friedrich Paulsen and Jens Waschke

1. List of Abbreviations

Singular:			Plural:					
A.	=	Arteria	Aa.	=	Arteriae	♀	=	female
Lig.	=	Ligamentum	Ligg.	=	Ligamenta	♂	=	male
M.	=	Musculus	Mm.	=	Musculi			
N.	=	Nervus	Nn.	=	Nervi			
Proc.	=	Processus	Procc.	=	Processus			
R.	=	Ramus	Rr.	=	Rami			
V.	=	Vena	Vv.	=	Venae			
Var.	=	Variation						

Percentages:
In the light of the large variation in individual body measurements, the percentages indicating size should only be taken as approximate values.

2. General Terms of Direction and Position

The following terms indicate the position of organs and parts of the body in relation to each other, irrespective of the position of the body (e.g. supine or upright) or direction and position of the limbs. These terms are relevant not only for human anatomy but also for clinical medicine and comparative anatomy.

General terms

anterior – posterior = in front – behind (e.g. Arteriae tibiales anterior et posterior)
ventralis – dorsalis = towards the belly – towards the back
superior – inferior = above – below (e.g. Conchae nasales superior et inferior)
cranialis – caudalis = towards the head – towards the tail
dexter – sinister = right – left (e.g. Arteriae iliacae communes dextra et sinistra)
internus – externus = internal – external
superficialis – profundus = superficial – deep (e.g. Musculi flexores digitorum superficialis et profundus)
medius, intermedius = located between two other structures (e.g. the Concha nasalis media is located between the Conchae nasales superior and inferior)
medianus = located in the midline (Fissura mediana anterior of the spinal cord). The median plane is a sagittal plane which divides the body into right and left halves.
medialis – lateralis = located near to the midline – located away from the midline of the body (e.g. Fossae inguinales medialis et lateralis)
frontalis = located in a frontal plane, but also towards the front (e.g. Processus frontalis of the maxilla)
longitudinalis = parallel to the longitudinal axis (e.g. Musculus longitudinalis superior of the tongue)
sagittalis = located in a sagittal plane
transversalis = located in a transverse plane
transversus = transverse direction (e.g. Processus transversus of a thoracic vertebra)

Terms of direction and position for the limbs

proximalis – distalis = located towards or away from the attached end of a limb or the origin of a structure (e.g. Articulationes radioulnares proximalis et distalis)

for the upper limb:
radialis – ulnaris = on the radial side – on the ulnar side (e.g. Arteriae radialis et ulnaris)

for the hand:
palmaris – dorsalis = towards the palm of the hand – towards the back of the hand (e.g. Aponeurosis palmaris, Musculus interosseus dorsalis)

for the lower limb:
tibialis – fibularis = on the tibial side – on the fibular side (e.g. Arteria tibialis anterior)

for the foot:
plantaris – dorsalis = towards the sole of the foot – towards the back of the foot (e.g. Arteriae plantares lateralis et medialis, Arteria dorsalis pedis)

3. Use of Brackets

[ ]: Latin terms in square brackets refer to alternative terms as given in the Terminologia Anatomica (1998), e.g. Ren [Nephros]. To keep the legends short, only those alternative terms have been added that differ in the root of the word and are necessary to understand clinical terms, e.g. nephrology. They are primarily used in figures in which the particular organ or structure plays a central role.

( ): Round brackets are used in different ways:
– for terms also listed in round brackets in the Terminologia Anatomica, e.g. (M. psoas minor)
– for terms not included in the official nomenclature but which the editors consider important and clinically relevant, e.g. (Crista zygomaticoalveolaris)
– to indicate the origin of a given structure, e.g. R. spinalis (A. vertebralis).

Colour Chart

Concha nasalis inferior
Mandibula
Maxilla
Os ethmoidale
Os frontale
Os lacrimale
Os nasale
Os occipitale
Os palatinum
Os parietale
Os sphenoidale
Os temporale
Os zygomaticum
Vomer

In the newborn the following cranial bones are indicated by only one colour:

Os nasale, Os temporale, Mandibula
Maxilla, Os incisivum
Os occipitale, Os palatinum

Table of Content

Head

Overview 4
Skeleton and Joints 9
Muscles 47
Topography 56
Neurovascular Pathways 62
Nose 68
Mouth and Oral Cavity 82
Salivary Glands 110

Eye

Development 124
Skeleton 126
Eyelids 128
Lacrimal Apparatus 135
Muscles of the Eye 141
Topography 145
Eyeball 154
Visual Pathway 160

Ear

Overview 166
Outer Ear 172
Middle Ear 174
Auditory Tube 182
Inner Ear 186
Hearing and Equilibrium 192

Neck

Muscles 202
Pharynx 213
Larynx 221
Thyroid Gland 234
Topography 240

Brain and Spinal Cord

Development 260
General Principles 270
Brain 272
Meninges and Blood Supply 295
Cerebral Areas 317
Cranial Nerves 345
Spinal Cord 392
Sections 425

Head

Overview 4

Skeleton and Joints 9

Muscles 47

Topography 56

Neurovascular Pathways 62

Nose 68

Mouth and Oral Cavity 82

Salivary Glands 110

8

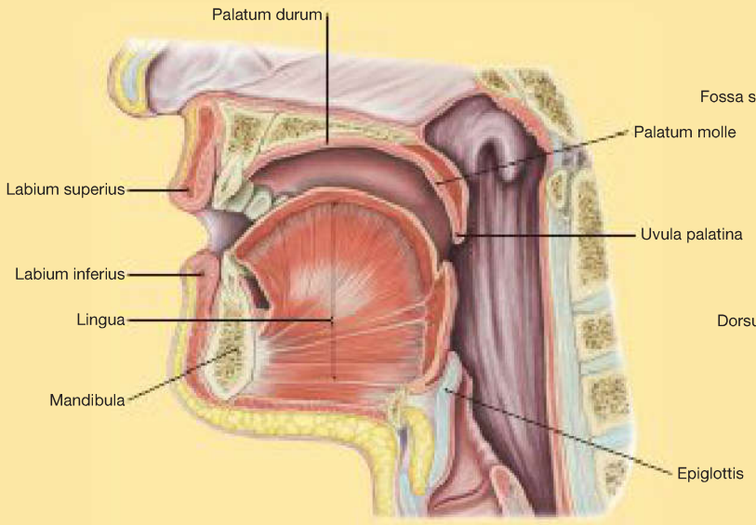

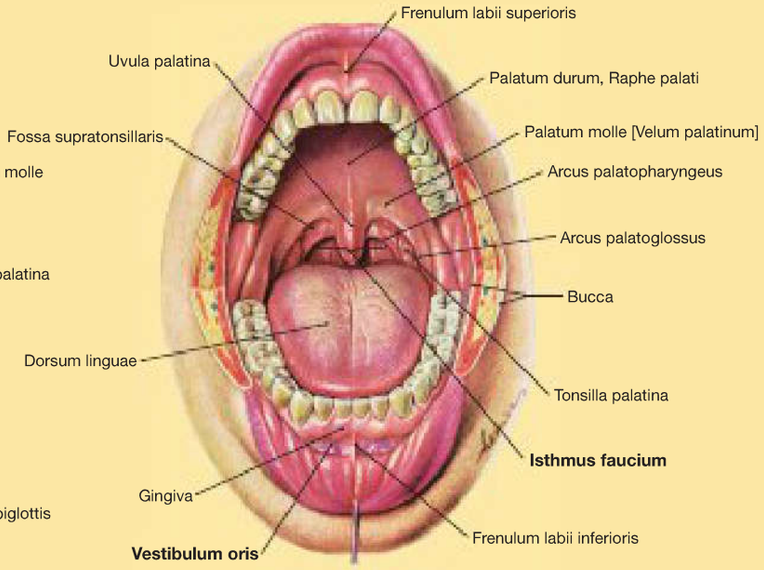

Overview

The **head (Caput)** is flexibly connected to the torso (trunk, Truncus) via the neck area. This allows us to direct the sensory organs of our head towards environmental stimuli without having to move our whole body. The bony skeleton of the head is the **skull (Cranium).** Its posterior section, called the neurocranium, encloses essential parts of the central nervous system (brain), while its front section, the viscerocranium, encloses the various major, highly specialised organs of sensory perception: the **eye** (organ of sight), the **ear** (organ of hearing and balance), the **nose** (organ of smell) and the **oral cavity** and **pharynx** (organs of taste). The respiratory tract starts in the nasal cavity and upper part of the pharynx, while the oral cavity and middle section of the pharynx mark the beginning of the digestive tract. Thus, we use our heads both for the **food intake and spatial orientation.** Together with our nose and sinuses, our mouth, pharynx and masticatory apparatus significantly contribute to the shape of our face. We humans additionally use the oral cavity and its organs for **articulation, enabling speech and singing.** The **mimetic muscles,** which do not have their own fascia, insert directly into the skin of the head, thus enabling unique facial expressions to aid our communication with the rest of the world. The Protuberantia occipitalis externa at the back of the skull, the base of the ears and the Mandibula (in order from the back to the front) mark the boundary between the head and neck area.

Main Topics

After studying this chapter, you should be able to:

- describe the cranial bones and cranial development;
- name sutures and fontanelles, including closure;
- describe the basic structure of the skull, its bones and their positional relationship to each other;
- identify the neurocranium, viscerocranium, internal surface of the cranial base and cranial fossae, and be able to explain their structure;
- name the major passageways and structures, foramina, fissures and impressions on the inner and outer surfaces of the cranial base;
- describe the insertion, origin, function and innervation of the muscles of facial expression;
- describe the structure, blood supply, lymphatic drainage and innervation of the scalp;
- name and locate key landmarks in the different areas (face, lateral facial region), systematically identify them and be able to describe the topographic route of neurovascular pathways in the areas, as well as name and visualise in three dimensions the anatomical structures deep within the lateral facial region that are not visible from the outside;
- name major topographic features and explain their clinical relevance;
- outline the origin, route and fibre quality, and the innervation areas of the twelve cranial nerves (→ chapter 12);
- describe the general embryological development of the nose and sinuses;
- describe the external structure of the nose, the bony and cartilaginous structure of the nasal skeleton, and the boundaries of the nasal cavities and their distension;
- describe the blood supply and innervation of the entire nose with respect to its clinical relevance;
- demonstrate the olfactory epithelium and how it is connected to the anterior cranial fossa;
- describe the location, bony structures and openings of the sinuses, and their topographical relationship to other structures;
- explain the embryological development of the oral cavity, masticatory apparatus, tongue, palate and salivary glands;
- describe all structures of the oral cavity, their neurovascular supply, and the routes of nerves and vessels;
- describe the topography and the interrelationship of the structures and organs to each other and to the neighbouring regions, and their functions;
- explain the dental development and the detailed structure of the different teeth, including the different stages of dentition;
- describe the structure and function of the Articulatio temporomandibularis, and the location, function, blood supply and innervation of the masticatory muscles;
- outline the structure, location, function, innervation, vascular supply and lymphatic drainage of the tongue, palate and salivary glands;
- provide an exact explanation of the blood supply to the Tonsilla palatina;
- outline the topography of the floor of the mouth including its compartments, the muscles involved, and the blood supply, innervation and lymphatic drainage.

Clinical Relevance

In order not to lose reference to future everyday clinical life with so many anatomical details, the following describes a typical case that shows why the content of this chapter is so important.

Facial Paralysis

Case Study

In the summer, a 22-year-old trainee visits his GP stating that for several days now he has had increasing problems moving the right side of his face and has had problems when trying to drink. In addition, saliva has been constantly dripping from the corner of his mouth. He also has the feeling that he hears more loudly on the right side. Otherwise, the patient appears to be healthy. He did not have any recent fever, headaches, painful limbs, a bout of flu or a tick bite. His medical history is normal. The young man is not on any medication and does not take drugs. He only drinks alcohol occasionally and in moderate limits; he does not smoke. His family medical history is also normal.

Result of Examination

The first impression of the patient's face as he comes into the examination room immediately indicates facial paralysis as a diagnosis. The right side of his face is visibly 'drooping' (→ Fig. a). The nasolabial fold on the right side has disappeared. When requested, the patient cannot frown, smile or whistle a tune, nor blow out his cheek on the right side. His attempts to close his eyes result in lagophthalmos (his right eye remains open) and in BELL's phenomenon.

BELL's phenomenon: the eyeball automatically turns upwards when closing the eyelid. As the lid cannot be closed, only the white sclera of the eye remains visible.

The doctor tests the facial nerve sensitivity by brushing the patient's cheek; however, this is intact. Because the patient cannot frown on the affected side, the doctor comes to a preliminary diagnosis: idiopathic (no identified cause) peripheral (infranuclear) facial paralysis.

People with central facial paralysis can still wrinkle their foreheads.

The GP refers the patient to an ENT specialist.

The ENT specialist also notes a complete right-sided peripheral facial paralysis. The patient's auricle and facial soft tissue are normal, and his ear canal and eardrum show no signs of irritation on either side. His parotid saliva shows no signs of irritation. The palpation of neck and face gives no indication of any tumour or infection.

Diagnostic Procedure

The ENT specialist conducts an audiometry, which shows no evidence of hearing loss. To exclude other more serious causes (e. g. a tumour), he orders a cranial MRI, blood tests, an electroneurography (ENoG) and an electromyography (EMG). The blood test results are all normal; therefore zoster oticus, a herpes simplex infection and borreliosis can all be ruled out. The ENoG and EMG reveal no signs of major nerve damage. After examination by a neurologist, neurological symptoms can also be ruled out. The MRI shows a slight swelling of the N. facialis [VII] inside the bony canal.

Diagnosis

Idiopathic, right-sided peripheral facial paralysis.

In up to 70% of all cases a peripheral facial paralysis is idiopathic.

Treatment

An outpatient treatment with cortisone infusion quickly shows results; the facial movements have already begun to return to normal by the third day. The forehead branch is the only part of the nerve still not working at this stage.

Further Development

An outpatient follow-up examination four weeks later confirms that his facial movements are perfectly symmetrical again.

Dissection Lab

Look out for the following branches of the N. facialis: N. petrosus major, Chorda tympani and N. stapedius.

Back in the Clinic

Although the patient's facial (mimetic) muscles are becoming increasingly mobile during his cortisone treatment, he has noticed that his right eye always waters when he is eating, so he goes to visit his GP again. The doctor tells him that this so-called crocodile tears syndrome is also referred to as gustatory hyperlacrimation. This harmless irritation syndrome occasionally occurs in the regenerative processes after a facial paralysis. Affected patients experience increased lacrimation (shedding of tears) on one side when eating. Because the regenerating parasympathetic gustatory nerve fibres are growing into the lacrimal gland (Glandula lacrimalis), this results in faulty misconnection and misrouting of the nerve fibres. If the patient suffers with strong subjective symptoms, Botox injections can be attempted as a treatment option.

Fig. a Left: patient as seen during examination; centre: patient when asked to wrinkle his forehead; right: patient when asked to close an eye. [T887]

Overview

Regions of the Head and Neck

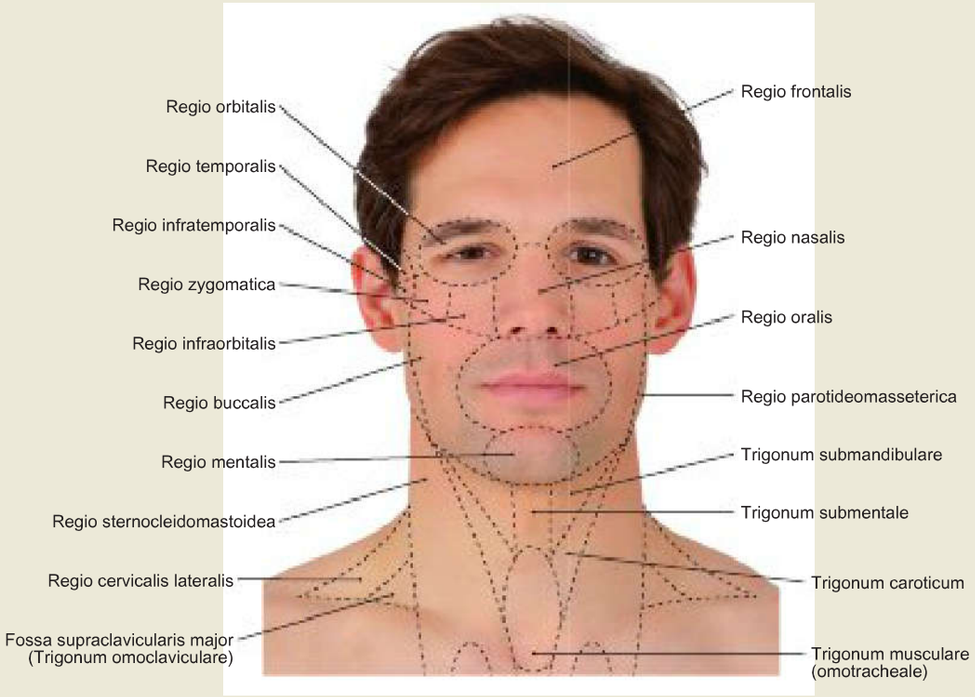

Fig. 8.1 Regions of the head and neck, Regiones capitis et colli; frontal view. [J803]
The **head** is conventionally subdivided into the following topographic regions:

- Regio frontalis
- Regio temporalis
- Regio orbitalis
- Regio nasalis
- Regio infraorbitalis
- Regio zygomatica
- Regio oralis
- Regio buccalis
- Regio mentalis
- Regio parietalis
- Regio occipitalis
- Regio parotideomasseterica

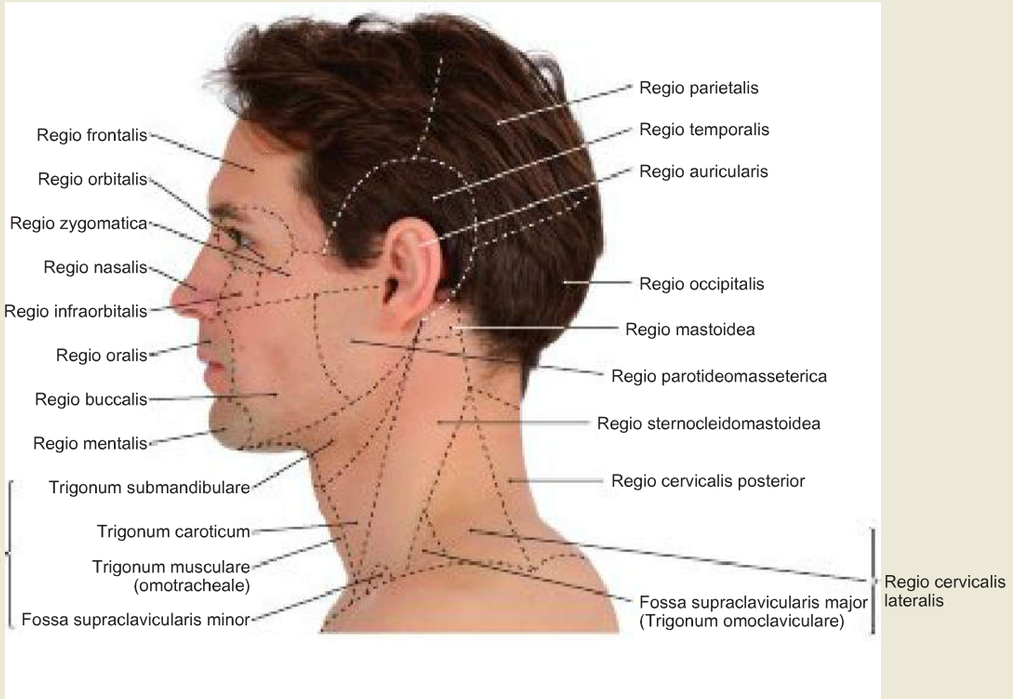

Fig. 8.2 Regions of the head and neck, Regiones capitis et colli; lateral view. [J803]
The **neck** is conventionally subdivided into the following topographic regions:

- Regio cervicalis anterior, consisting of the Trigonum submandibulare, Trigonum caroticum and Trigonum musculare (omotracheale)
- Regio sternocleidomastoidea with Fossa supraclavicularis minor
- Regio cervicalis lateralis with Trigonum omoclaviculare
- Regio cervicalis posterior

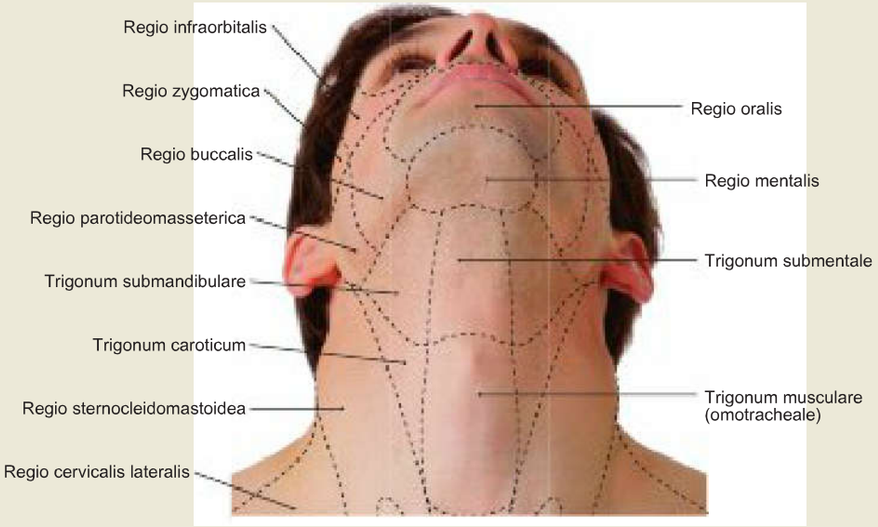

Fig. 8.3 Regions of the head and neck, Regiones capitis et colli; anterolateral view. [J803]

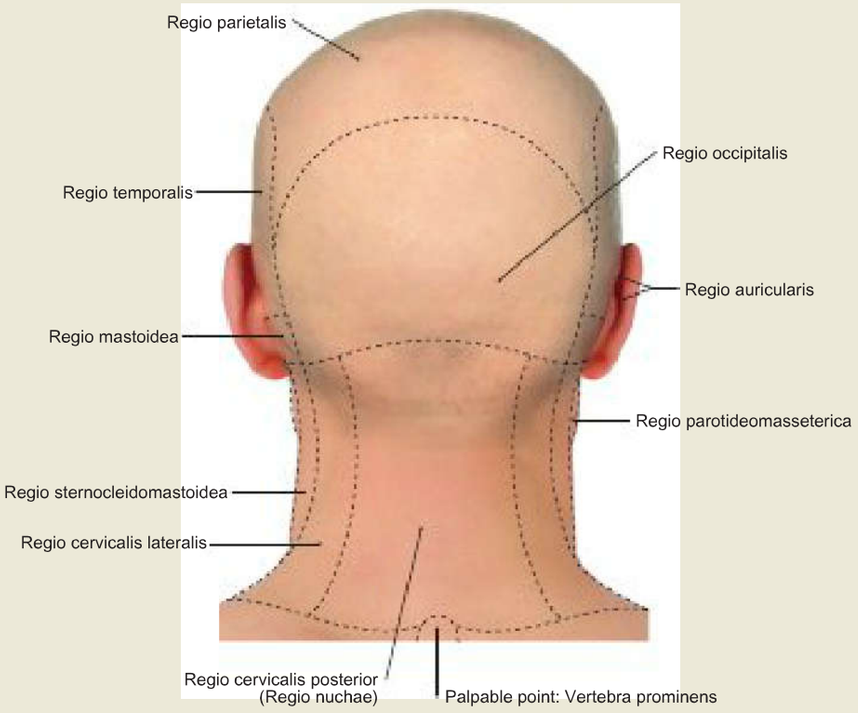

Fig. 8.4 Regions of the head and neck; posterior view. [J803] The posterior region of the neck is often also referred to as the nuchal region.

Facial Morphometry and Proportions

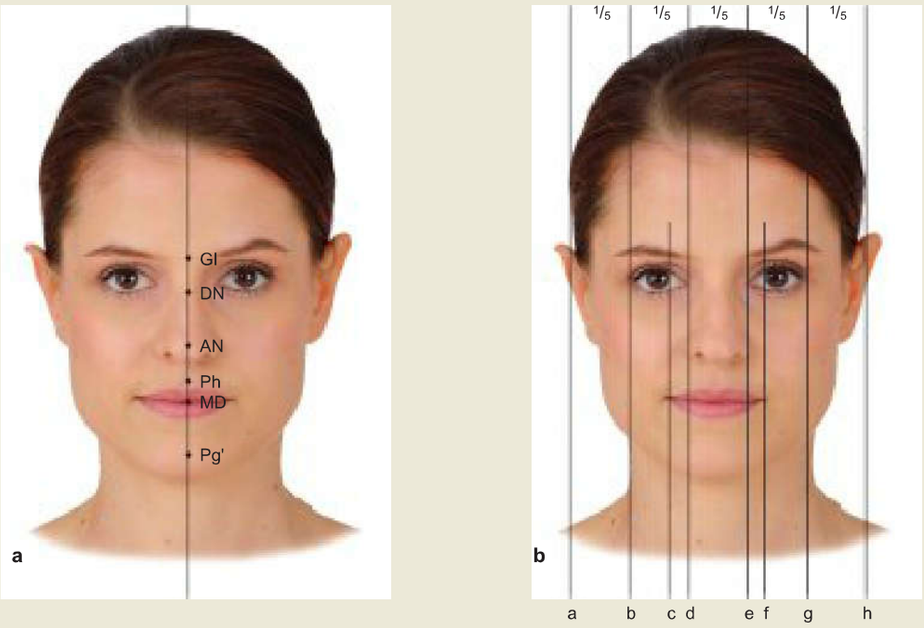

Fig. 8.5a and b Facial morphometry and proportions; frontal view; vertical proportions. [J803]

a In ideally proportioned faces, the midline of the face runs directly through the glabella (Gl), the bridge of the nose (Dorsum nasi, DN), the tip of the nose (Apex nasi, AN), the philtrum (Ph) and the soft tissue of the pogonion (Pg'). The centre of the dental arch (Medietas dentium, MD) also aligns with this midline.

b If perfectly symmetrical, the face can be divided by vertical lines into five equal parts. These lines run along the outer edge of the auricles (a, h), and pass through the lateral (b, g) and medial (d, e) corners of the eyes. The corners of the mouth (c, f) generally align vertically with the medial rim of the iris.

Based on: Radlanski, R. J./Wesker, K. H.: Das Gesicht. Bildatlas klinische Anatomie. 2. Auflage. KVM, 2012

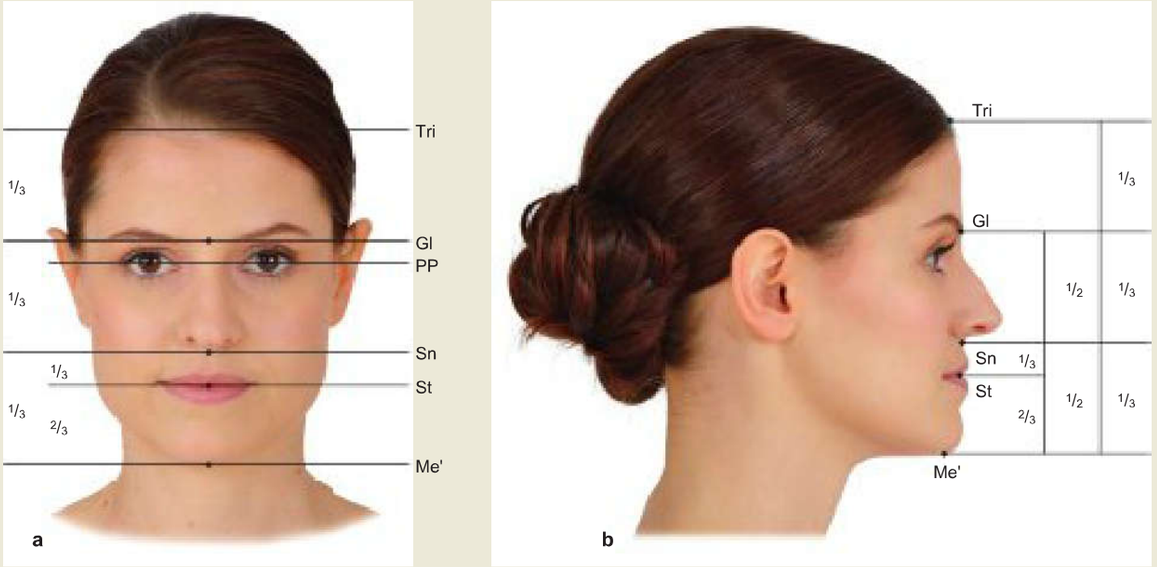

Fig. 8.6a and b Facial morphometry and proportions; frontal view **(a)** and lateral view **(b);** transverse proportions. [J803]

If perfectly symmetrical, the face can be divided by horizontal lines into three equal parts. Equal distances between the hairline (trichion, Tri) and the glabella (Gl), between the glabella and the subnasion (Sn), and between the subnasion and the chin (Menton, Me') allow the division into the upper face, midface and lower face. The lower face is further divided into thirds by the line where the upper lip and lower lip meet (St). One third is located above the line between the two lips, while the chin region takes up the lower two thirds. The transverse mid-pupillary line (PP) can also be used for orientation if both eyes are exactly at the same height.

Based on: Radlanski, R. J./Wesker, K. H.: Das Gesicht. Bildatlas klinische Anatomie. 2. Auflage. KVM, 2012

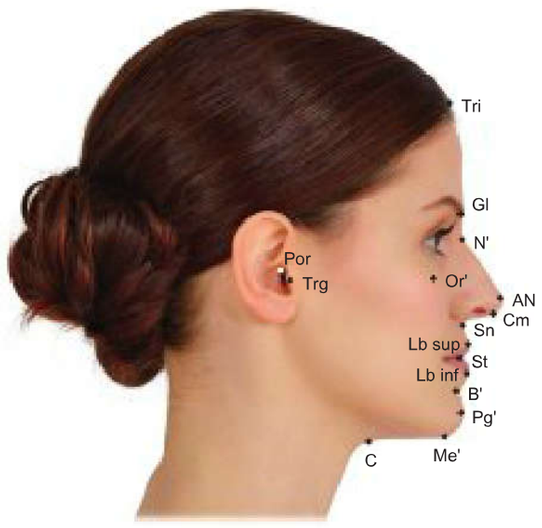

Fig. 8.7 Most common measuring points of the face; lateral view. [J803]
Based on: Radlanski, R. J./Wesker, K. H.: Das Gesicht. Bildatlas klinische Anatomie. 2. Auflage. KVM, 2012

Abbreviation	Measuring Point	Explanation
Tri	trichion	hairline
Gl	glabella	raised area of the Os frontale between the eyebrows
N'	soft tissue nasion	lowest point between the nose and forehead
Or'	soft tissue orbital point	lowest point of the curved edge of the orbit
AN	Apex nasi	tip of nose
Cm	columella	bridge of tissue that separates the nostrils
Sn	subnasale	
Lb sup	Labrale superius	foremost point of the upper lip
St	stomium	contact area between the two lips
Lb Inf	Labrale inferius	foremost point of the lower lip
B'	soft tissue labiomental point	lowest point of the labiomental fold
Pg'	soft tissue pogonion	
Me'	soft tissue chin	furthest caudal point of the soft tissue of the chin contour
C	cervical point	in the area where the submental contour meets the contour of the neck
Por	porion	opening of the ear canal
Trg	tragion	protruding edge of the tragus

Fig. 8.8 Tension lines of the skin of the face; frontal view from the right side. [J803]
Any facial surgical operations involving incisions in the skin must pay attention to the tension lines, which are created by the direction of the collagen fibrils and the position of the mimetic muscles. Incisions along these lines and wrinkles are the best option as they reduce the tension in the skin to a minimum, and thus minimise the scar formation.
Based on: Radlanski, R. J./Wesker, K. H.: Das Gesicht. Bildatlas klinische Anatomie. 2. Auflage. KVM, 2012

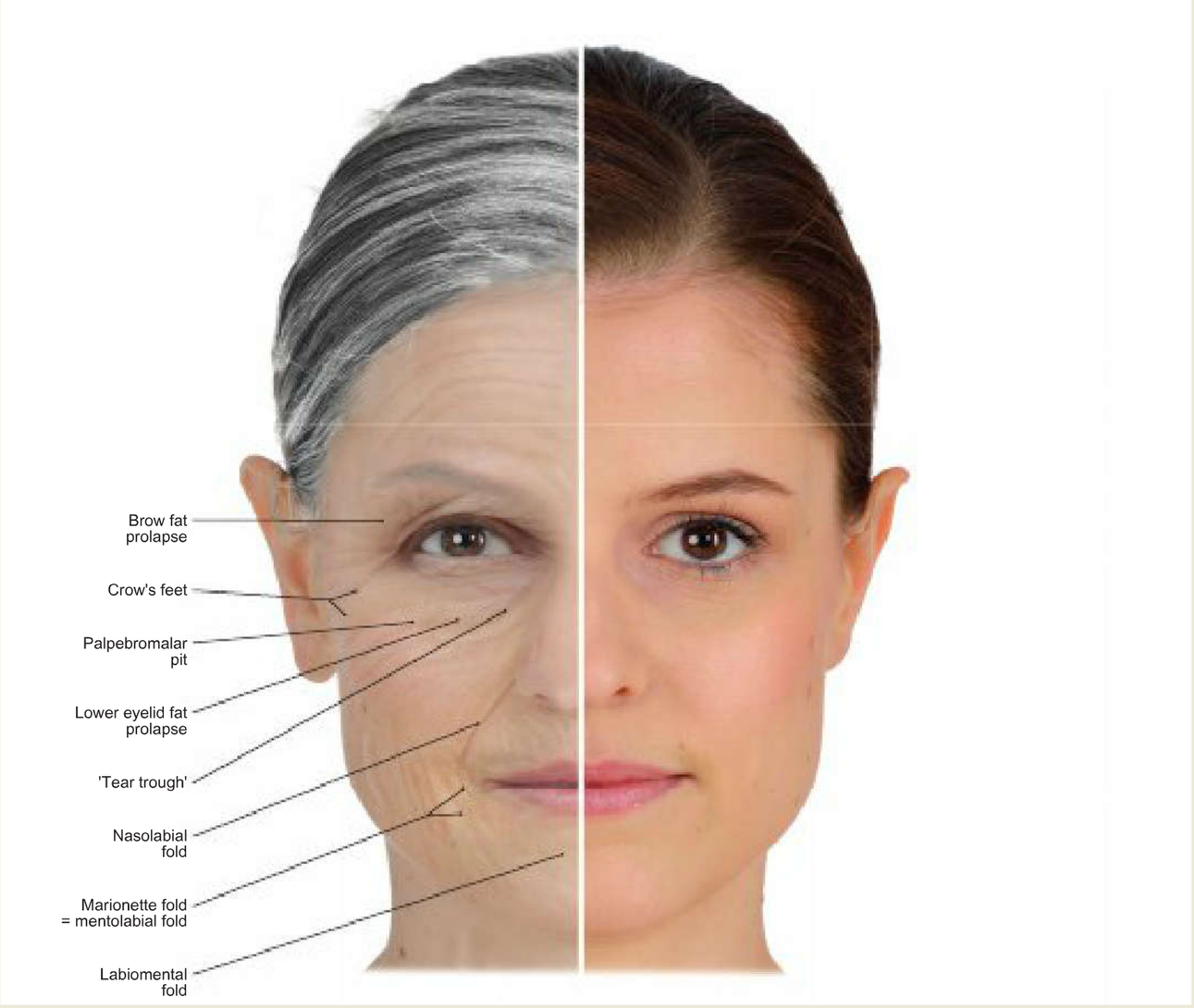

Fig. 8.9 Ageing of the face; frontal view. [J803]
Increasing age brings complex changes not only to the skin of the face, but to all other tissues such as bone, muscle or subcutaneous fat deposits (subcutaneous fat compartments) as well. This is due to ageing processes that are specific to each region of the face, and progress at very different rates depending on the individual. They can be influenced by many environmental factors (e.g. UV radiation, smoking). The ageing process, which is slow but inexorable, has a visible effect on the skin: more and more wrinkles are formed, and gravity forces make the skin and the subcutaneous connective tissue sag. This is particularly evident on the eyelids and at the corners of the mouth.
Based on: Radlanski, R. J./Wesker, K. H.: Das Gesicht. Bildatlas klinische Anatomie. 2. Auflage. KVM, 2012

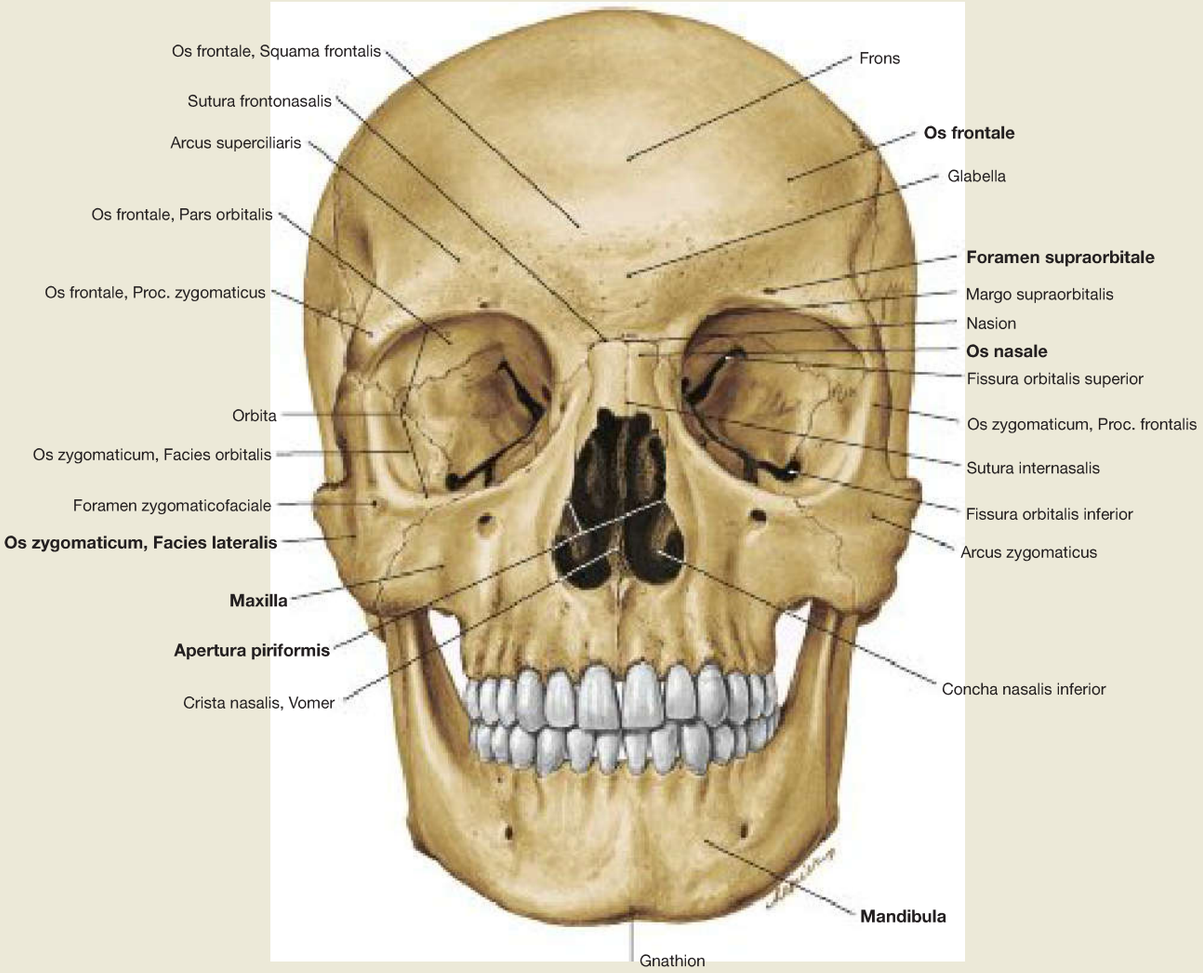

Fig. 8.10 Skull, Cranium; frontal view.
From bottom to top: the lower jaw (Mandibula), the two halves of the upper jaw (Maxillae), the nasal bones (Ossa nasalia) between the upper jaw and orbit (Orbita) and, above the Orbita, the Os frontale.
The Os frontale consists of four parts (→ Fig. 8.29). Above the upper margin of each orbit (Margo supraorbitalis) the protruding Arcus superciliaris (superciliary arch) can be felt. A continuation of the Os frontale extends medially downwards to form in part the medial margin of the orbit. Laterally, the Proc. zygomaticus meets the Proc. frontalis of the Os zygomaticum. Both form the lateral margin of the orbit.
The Os zygomaticum constitutes the major part of the lateral and lower margins of the orbit.
The nasal bone (Os nasale) connects with the Os frontale at the fronto-nasal suture on both sides, while the internasal suture connects the two nose bones themselves.

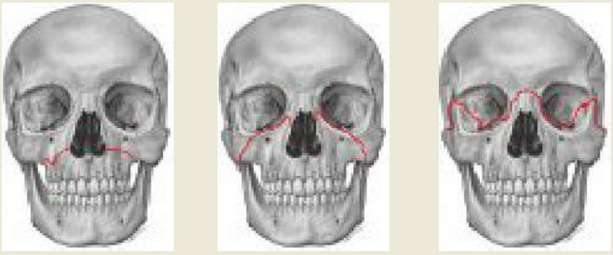

Fig. 8.11 LE FORT fractures.

Clinical Remarks

Central midface fractures occur most frequently as a result of traffic accidents. They are categorised according to LE FORT (→ Fig. 8.11) as:

- **LE FORT I:** isolated disjunction fracture of the Proc. alveolaris
- **LE FORT II:** disjunction fracture of the maxilla in the area of the mid-orbital floor, possibly involving the Os ethmoidale, the anterior cranial base and/or the Os nasale
- **LE FORT III:** complete disjunction fracture of the facial skeleton from the neurocranium

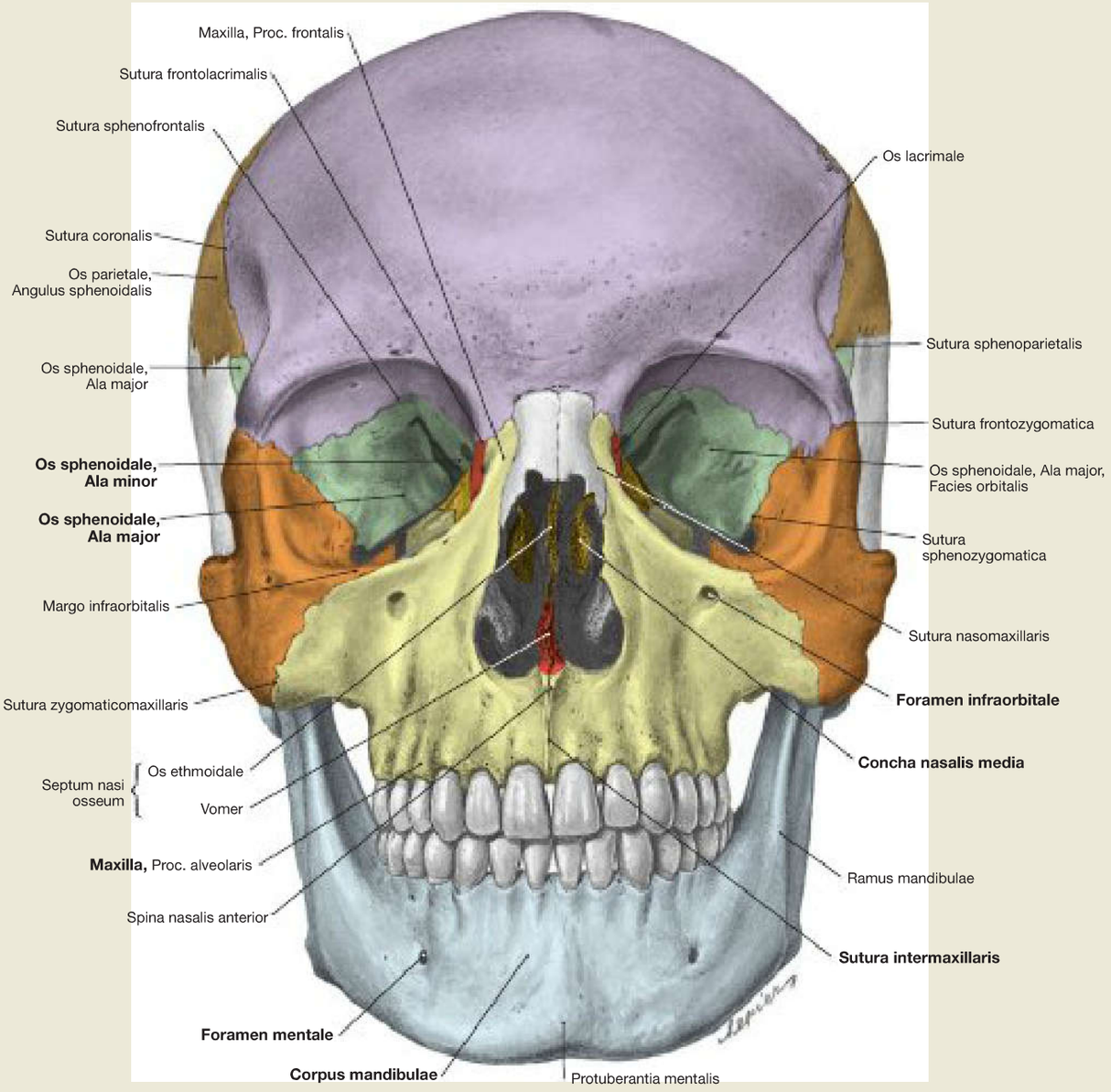

Fig. 8.12 Cranial bones, Ossa cranii; frontal view; for colour chart see p. VIII.
The upper jaw or maxillary bone **(Maxilla)** is located between the orbit and the oral cavity. The maxilla forms part of the lower and the medial margins of the orbit and borders laterally on the Os zygomaticum. The Proc. frontalis of the maxilla connects with the Os frontale. In the body of the maxilla, below the lower orbital margin, is the Foramen infraorbitale. There is a bony projection in the midline, the Spina nasalis anterior. Below this is the Proc. alveolaris, which forms the lower edge of the upper jaw and holds the teeth.
The lower jaw oder mandible **(Mandibula)** consists of the Corpus and Rami mandibulae, both of which converge at the Angulus mandibulae. The Corpus mandibulae holds the teeth. Underneath that is the Basis mandibulae, the protrusion at the midline of the Protuberantia mentalis. Please note the Foramen mentale as well.

Clinical Remarks

Fractures of the Os nasale or other bone/cartilage of the nose are among the most common fractures in the facial area. We distinguish between closed and open nasal fractures; in the latter, the bone is exposed as a result of injury to the skin and soft tissue. The nasal septum and Conchae nasales can also be fractured as a result. Fractures of the bone/cartilage of the nose are typical injuries resulting from violent physical disputes, car accidents, martial arts such as karate and boxing, and a variety of team sports.

Os temporale, Pars squamosa
Sutura squamosa
Sutura coronalis
Sutura sphenofrontalis
Sutura sphenosquamosa
Linea temporalis
Sutura sphenozygomatica
Sutura frontozygomatica
Sutura frontolacrimalis
Sutura lacrimomaxillaris
Sutura nasomaxillaris
Fossa sacci lacrimalis
Spina nasalis anterior
Sutura zygomaticomaxillaris
Sutura temporozygomatica
Protuberantia mentalis
Foramen mentale
Arcus zygomaticus
Linea temporalis superior
Linea temporalis inferior
Tuber parietale
Sutura squamosa
Sutura lambdoidea
Sutura parietomastoidea
Sutura occipitomastoidea
Os temporale, Proc. mastoideus
Porus acusticus externus
Condylus occipitalis
Proc. styloideus
Articulatio temporomandibularis

Fig. 8.13 Cranial bones, Ossa cranii; lateral view; for colour chart see p. VIII
The lateral view displays parts of the Ossa frontale, parietale, occipitale, sphenoidale and temporale, parts of the viscerocranium (Os nasale, Os lacrimale, Maxilla and Os zygomaticum) and the lateral aspect of the lower jaw (Mandibula).
Within the viscerocranium, the **Os nasale** borders the Os frontale cranially and the maxilla posteriorly. The upper part of the Os lacrimale forms the Fossa sacci lacrimalis between the maxilla and the Os ethmoidale. The Proc. alveolaris of the maxilla contains the upper teeth. Medially, the **maxilla** connects with the Os frontale and laterally with the Os zygomaticum. At the front there is a bony projection, the Spina nasalis anterior. The **Os zygomaticum** gives the cheek area its contour.
The head of the Mandibula (Caput mandibulae) articulates with the temporal bone in the Articulatio temporomandibularis.
The upper frontal aspect of the **Os frontale** connects with the parietal bone (Os parietale) and the sphenoidal bone (Os sphenoidale) along the Sutura coronalis. The Os parietale borders the occipital bone (Os occipitale) along the Sutura lambdoidea. The Pars squamosa of the Os temporale forms the major part of the lateral wall of the skull.
The Os temporale and Os zygomaticum form the Arcus zygomaticus, which bridges the Fossa temporalis.

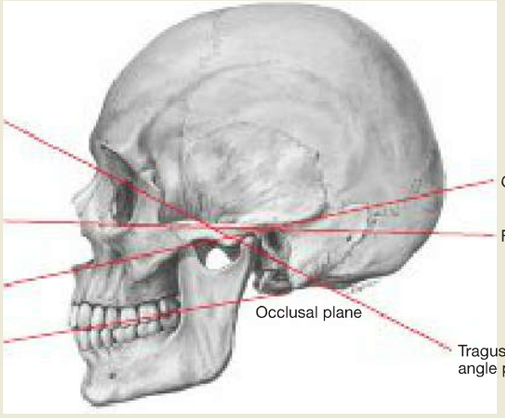

Fig. 8.14 Planes of reference of the jaw.
FRANKFORT horizontal plane (line): between the lower edge of the orbit and the upper edge of the Meatus acusticus externus
CAMPER's plane: between the lowest point of the Spina nasalis anterior and the highest point of the Meatus acusticus externus
Occlusal plane: runs parallel to the CAMPER's plane
Tragus plane: between the medial angle of the eye and the tragus

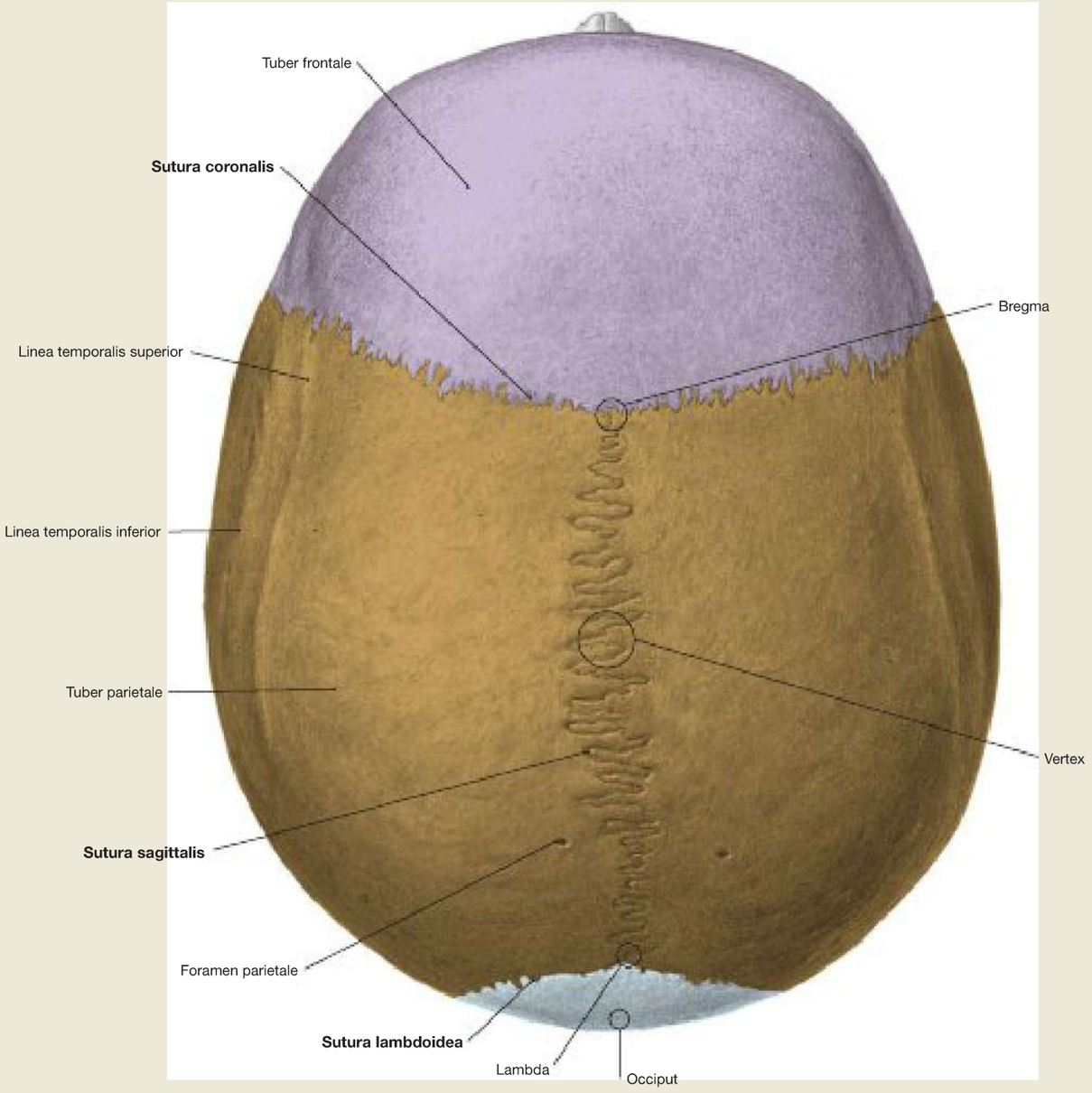

Fig. 8.15 Cranial bones, Ossa cranii; view from above; for colour chart see p. VIII.
A view on the upper part of the skull (skull cap, Calvaria) reveals the Os frontale, the Ossa parietalia, and the Os occipitale. The Os frontale and Ossa parietalia are bordered by the **Sutura coronalis.** The two Ossa parietalia are bordered by the **Sutura sagittalis.** The Os occipitale is connected, along with the two Ossa parietalia, to the **Sutura lambdoidea.** The point of contact of the Sutura coronalis and the Sutura sagittalis is called the **bregma,** and the point at which the Suturae sagittalis and lambdoidea meet, is called the **lambda.** In the dorsal part of the Ossa parietalia, directly adjacent to the Sutura sagittalis, are pairs of Foramina parietalia for the passage of the Vv. emissariae.

Clinical Remarks

Due to great external forces, **skull fractures** can often occur. It is possible to differentiate between the following: **linear fractures** with a clear fracture line, **split skull fractures** with multiple bony fragments (impression fracture with inward pointing bony parts that can cause a compression or tear of the dura mater as well as an injury to brain tissue), **diastases** (widening of sutures) and **fractures of the base of the skull.** Any fracture associated with a rupture/laceration of the scalp or linked to the sinuses or the middle ear, is regarded as an open fracture requiring surgical treatment due to the potential risk of infection.

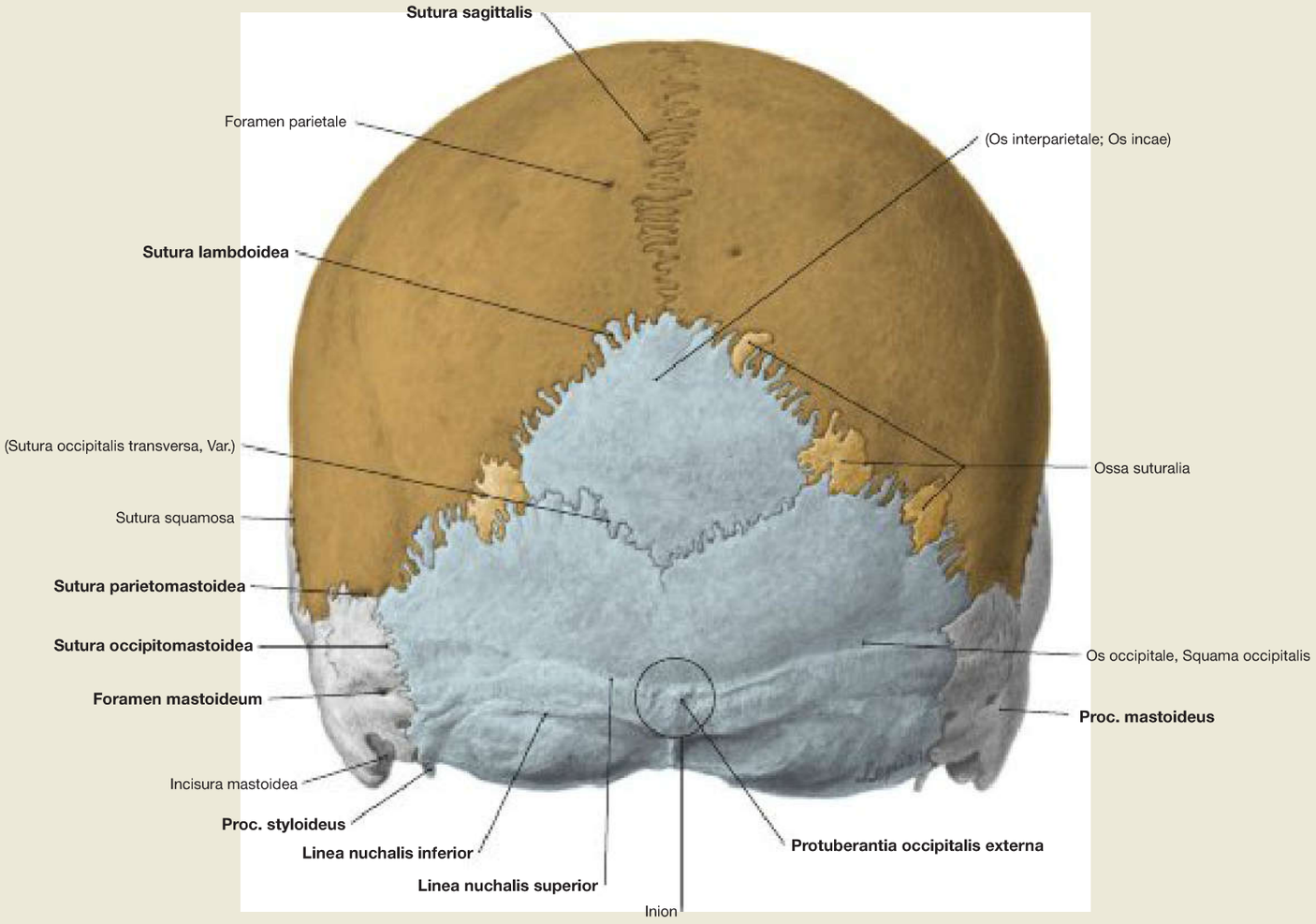

Fig. 8.16 Cranial bones, Ossa cranii; posterior view; for colour chart see p. VIII.
This view from the posterior aspect shows the Os temporale, Os parietale and Os occipitale. Laterally, you can see the **Os temporale** with the Proc. mastoideus on both sides. At the lower medial edge of the Proc. mastoideus is the Incisura mastoidea, a notch where the Venter posterior of the M. digastricus inserts.
In this posterior view, you can see the two **Ossa parietalia,** which meet in the midline via the Sutura sagittalis, and posteriorly are bordering the Os occipitale via the Sutura lambdoidea, and laterally and externally are bordering the temporal bones via the Suturae parietomastoideae.

A large portion of the posterior skull is formed by the **Os occipitale.** Its central structure is the Squama occipitalis. Frequently, structural variants called sutural bones (Ossa suturalia) can be found in the area of the Sutura lambdoidea. The Os occipitale has a bony landmark, the Protuberantia occipitalis externa, which is usually easily palpable. Its furthest protruding point is called the inion. Laterally, the protuberance continues on both sides in the arch-shaped Linea nuchalis superior, a bony ridge for the attachment of the autochthonous back muscles. Approximately 2–2.5 cm below the Protuberantia occipitalis externa are the arch-shaped ridges of the Linea nuchalis inferior, serving as attachment sites for further muscles.

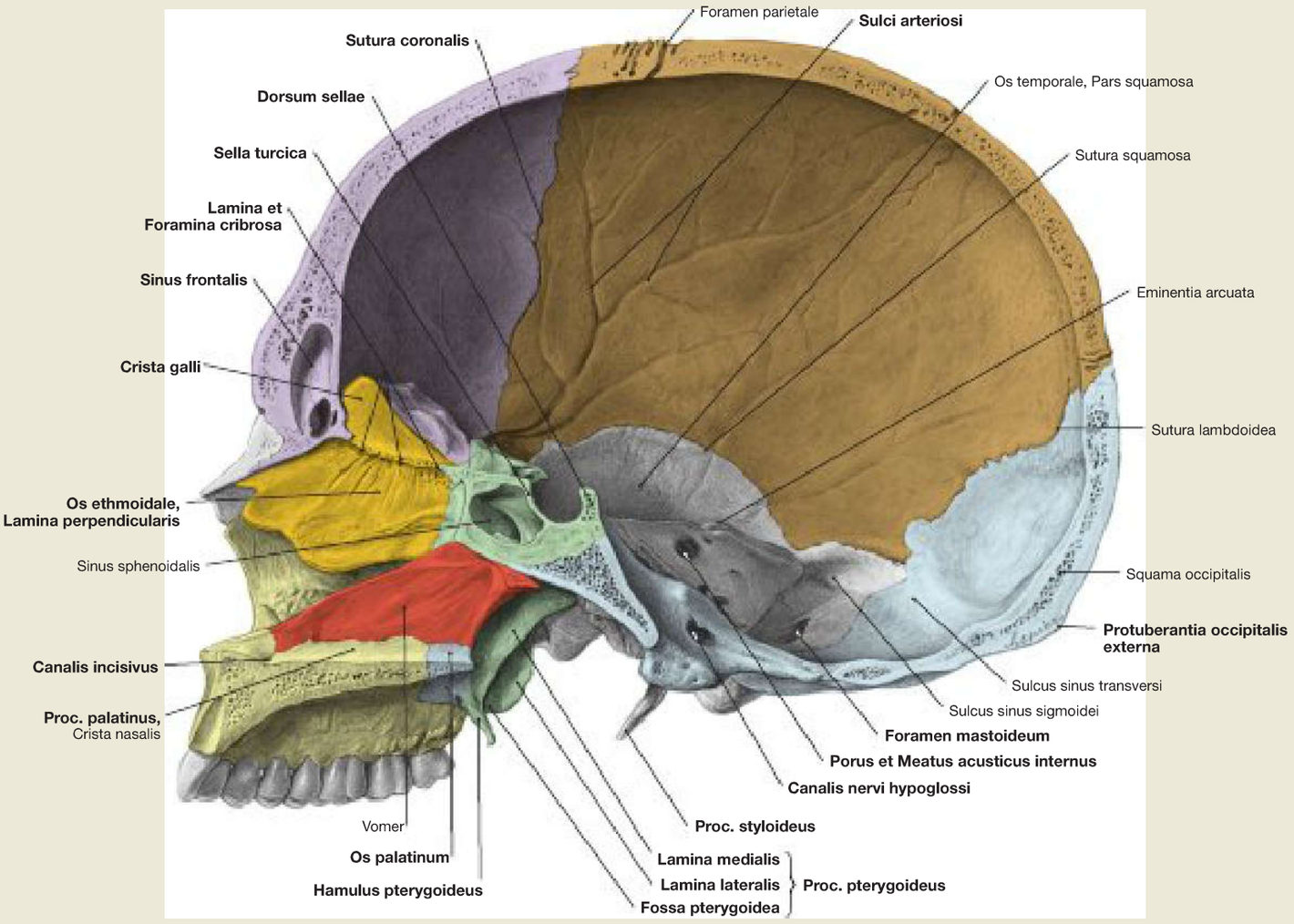

Fig. 8.17 Cranial bones, Ossa cranii, right side; medial view; for colour chart see p. VIII.
The cranial cavity comprises the calvaria, as well as the base of skull formed by the anterior, middle and posterior cranial fossae. The cranial cavity surrounds the brain with its meninges and encloses the proximal portion of the cranial nerves, including the blood vessels and the venous sinuses. On the internal surface of the cranium, you can see the arterial grooves (Sulci arteriosi) carved by the pulsations of the A. meningea media. At the transition to the viscerocranium, the Lamina perpendicularis of the Os ethmoidale and the Vomer connect to the bony nasal septum. The hard palate is formed by the Proc. palatinus of the Maxilla and by the Os palatinum.

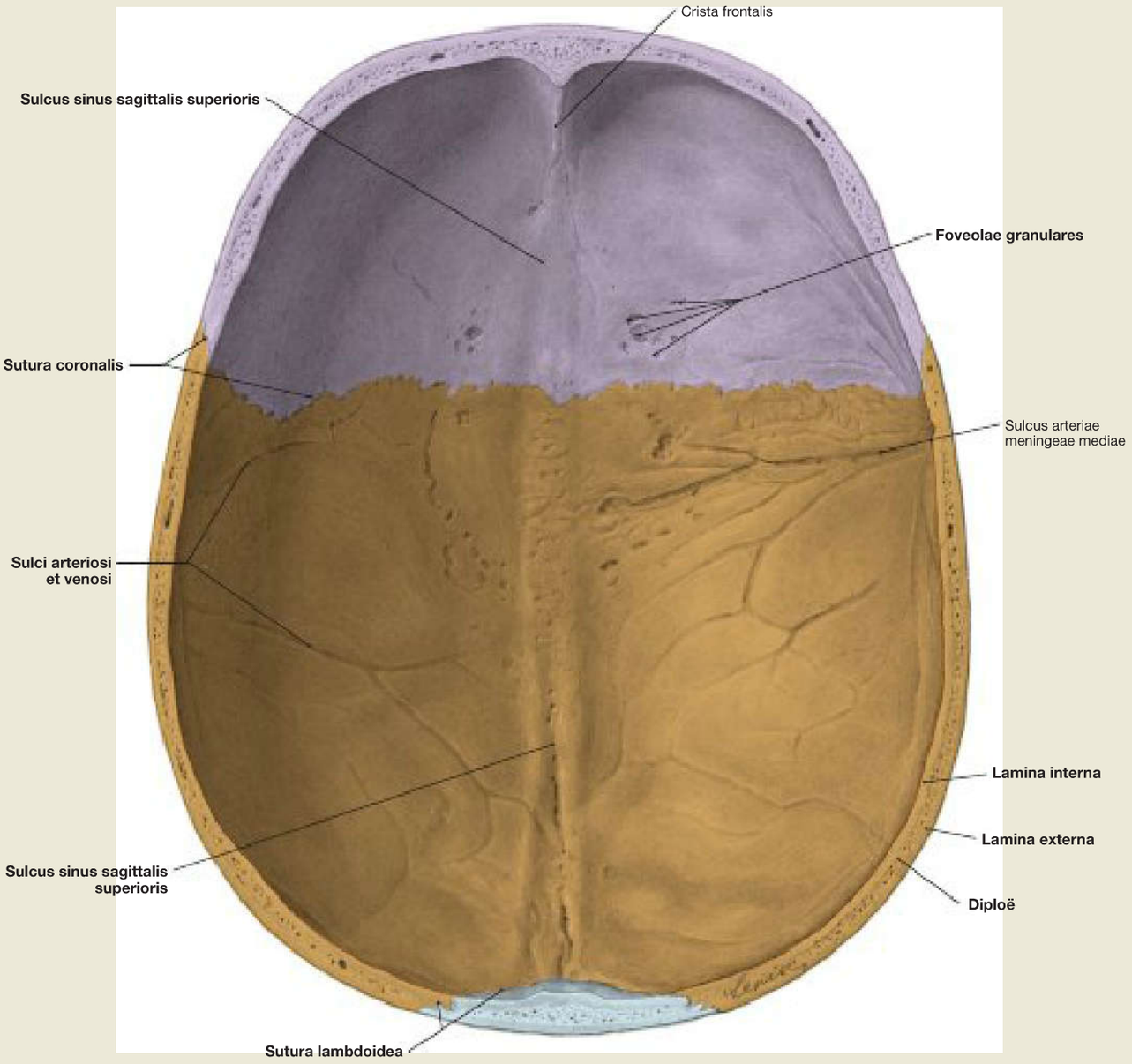

Fig. 8.18 Calvaria; view from the inside; for colour chart see p. VIII.
On the inside of the calvaria, you can see the Suturae coronalis between the Os frontale and Ossa parietalia, and the Sutura lambdoidea between the Ossa parietalia and the Os occipitale. Furthermore, the Crista frontalis is visible on the inside of the Os frontale, which serves to connect the Falx cerebri (duplicature of tight connective tissue; separates the two cerebral hemispheres). The Crista frontalis transitions into the Sulcus sinus sagittalis superioris (groove of the Sinus sagittalis superior) which becomes wider and deeper towards the posterior part. It extends across the Sutura lambdoidea to the Os occipitale.
Bilaterally and along the entire length of the Sulcus sinus sagittalis superioris, there are irregularly grouped small depressions (Foveolae granulares), in which the cauliflower-like Granulationes arachnoideae (PACCHIONIAN granulations) are found. In the lateral parts of the cranial bones, numerous grooves can be seen (Sulci arteriosi et venosi).
The **bones** of the **calvaria** possess a special **structure.** They consist of a thick outer and a thin inner compact layer, the Lamina externa and Lamina interna (Lamina vitrea), and a thin layer of spongiosa, known as Diploë.

Clinical Remarks

Since the lamina interna of the skull bone is very thin, this is very often injured in the context of **bend fractures**. If, in the Sulcus arteriae meningeae mediae of the lamina interna, A.meningea media are injured, an **epidural haematoma** may occur (→ Fig. 12.77).

Internal Surface of the Cranial Base

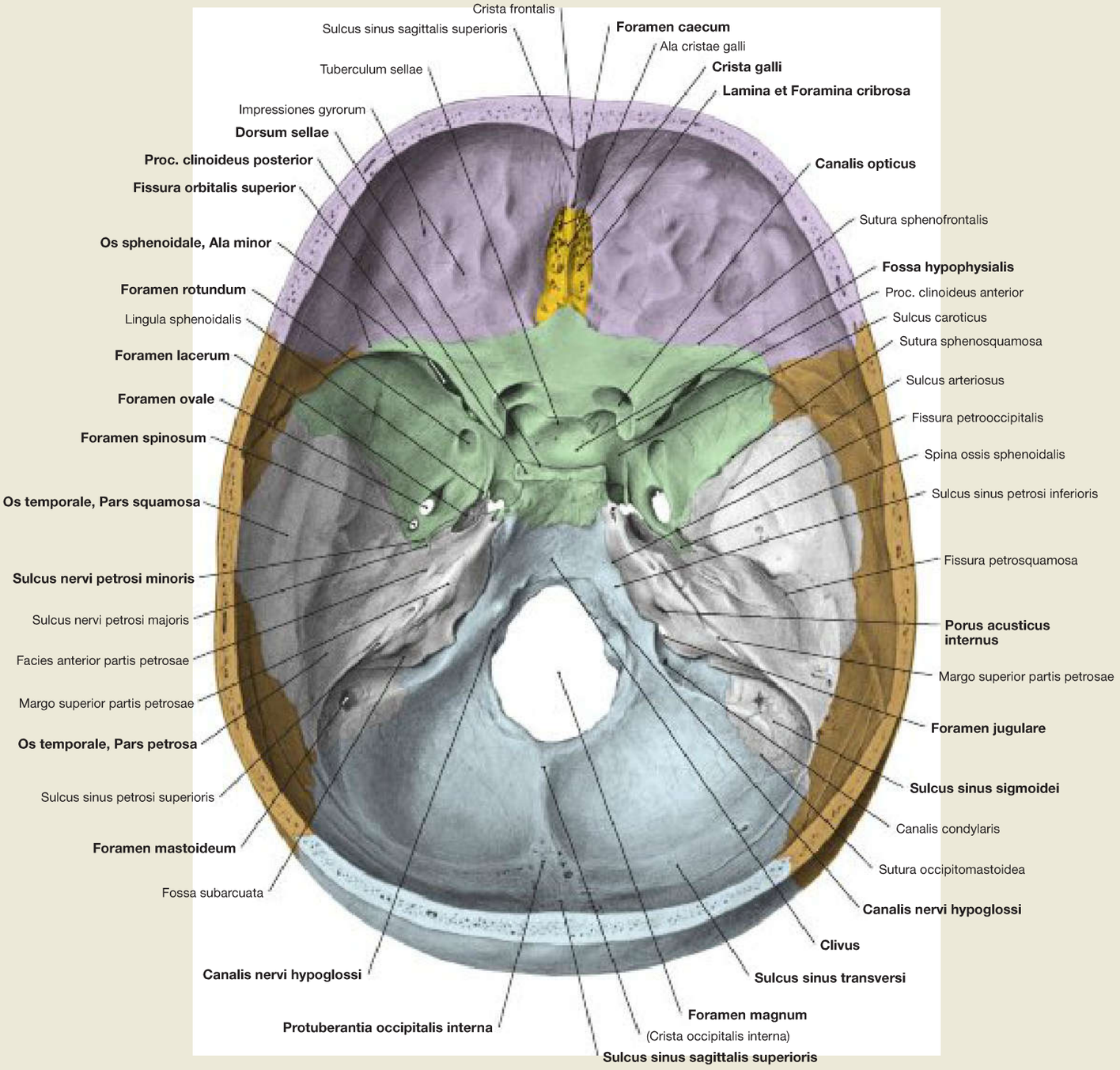

Fig. 8.19 Internal surface of the cranial base, Basis cranii interna; view from above; for colour chart see p. VIII.
The anterior (Fossa cranii anterior), middle (Fossa cranii media) and posterior cranial fossae (Fossa cranii posterior) form the internal surface of the cranial base.
The Ossa frontale, ethmoidalia and sphenoidale make up the floor of the **anterior cranial fossa,** which lies above the nasal cavity and the eye sockets. In the anterior cranial fossa are the Foramen caecum, the Crista galli (attachment point of the Falx cerebri) and on both sides the Lamina cribrosa. Posterior to the Ossa frontale and ethmoidalia, the Corpus and the Alae minores of the Os sphenoidale form the base of the anterior cranial fossa. The Corpus also forms the border to the middle cranial fossa.

The **middle cranial fossa** is formed by the Ossa sphenoidale and temporalia. Its floor is elevated in the midline, where it continues into the Corpus of the Os sphenoidale. The lateral portion form fossae and are all part of the Ala major of the Os sphenoidale and the Pars squamosa of the Os temporale. Located in the middle cranial fossa are, on both sides of the saddle-shaped Sella turcica with the Fossa hypophysialis, the Canalis opticus, the Fissura orbitalis superior, and the Foramina rotundum, ovale, spinosum and lacerum. The posterior aspect of the middle cranial fossa is formed by the Facies anterior partis petrosae.

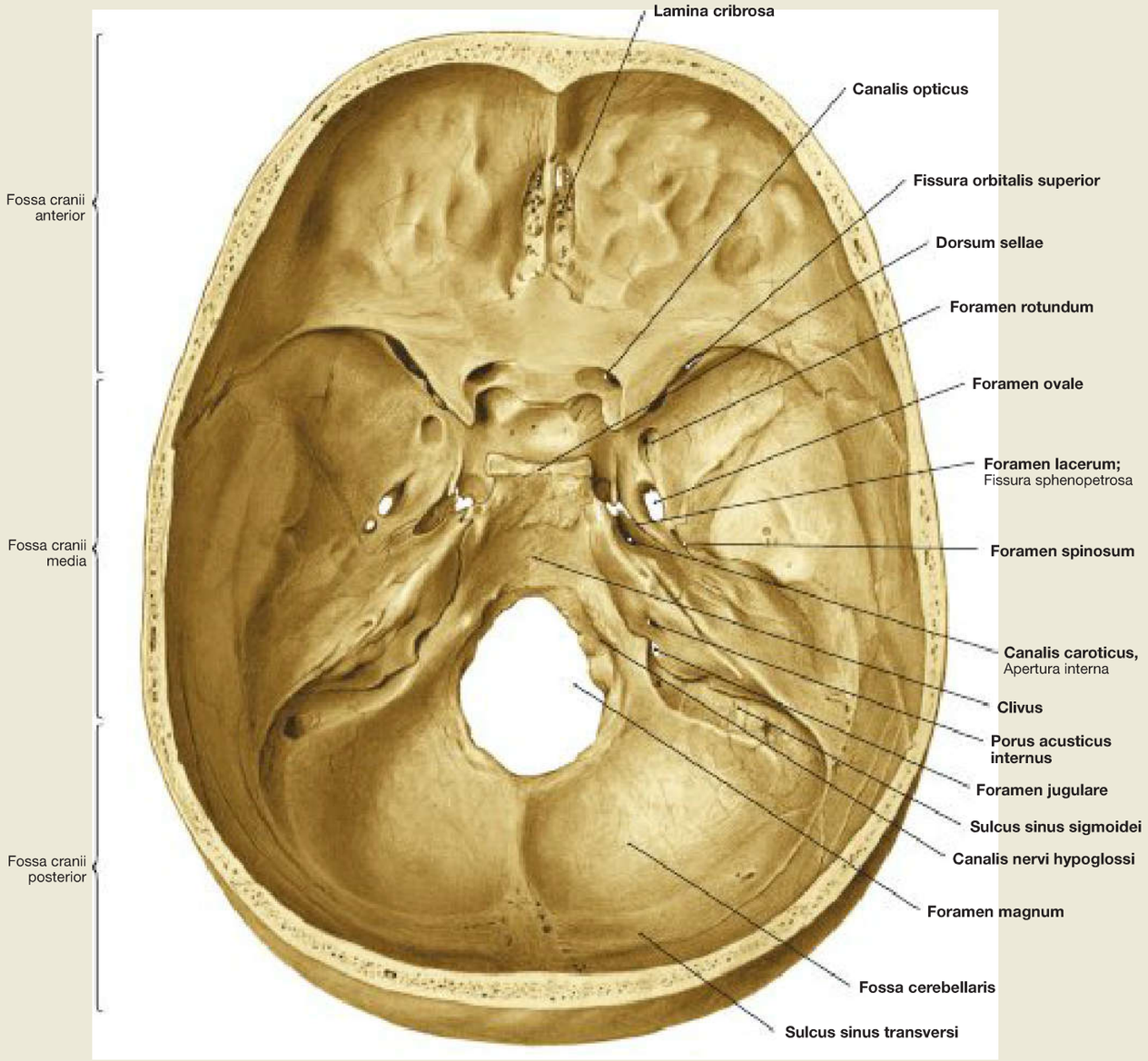

Fig. 8.20 Internal surface of the cranial base, Basis cranii interna; view from above.
Of the three cranial fossae, the **posterior cranial fossa** is the biggest. It is mainly formed by the Ossa temporalia and the Os occipitale and to a lesser extent by the Os sphenoidale and the Ossa parietalia.
In the midline, its anterior margin is formed by the Dorsum sellae and the Clivus. The Clivus is a bone surface sloping from the Dorsum sellae to the Foramen magnum. It consists of parts of the Corpus of the Os sphenoidale and the Pars basilaris of the Os occipitale. Dorsally, the posterior cranial fossa is mainly confined by the Sulcus sinus transversi. The Foramen magnum is the largest opening of the posterior cranial fossa.
Additional structures of the posterior cranial fossa include the Canalis nervi hypoglossi, the Porus acusticus internus and the Foramen jugulare. The Sulcus sinus sigmoidei leads laterally to the Foramen jugulare. The central depression of the posterior cranial fossa is the Fossa cerebellaris.

External Surface of the Cranial Base

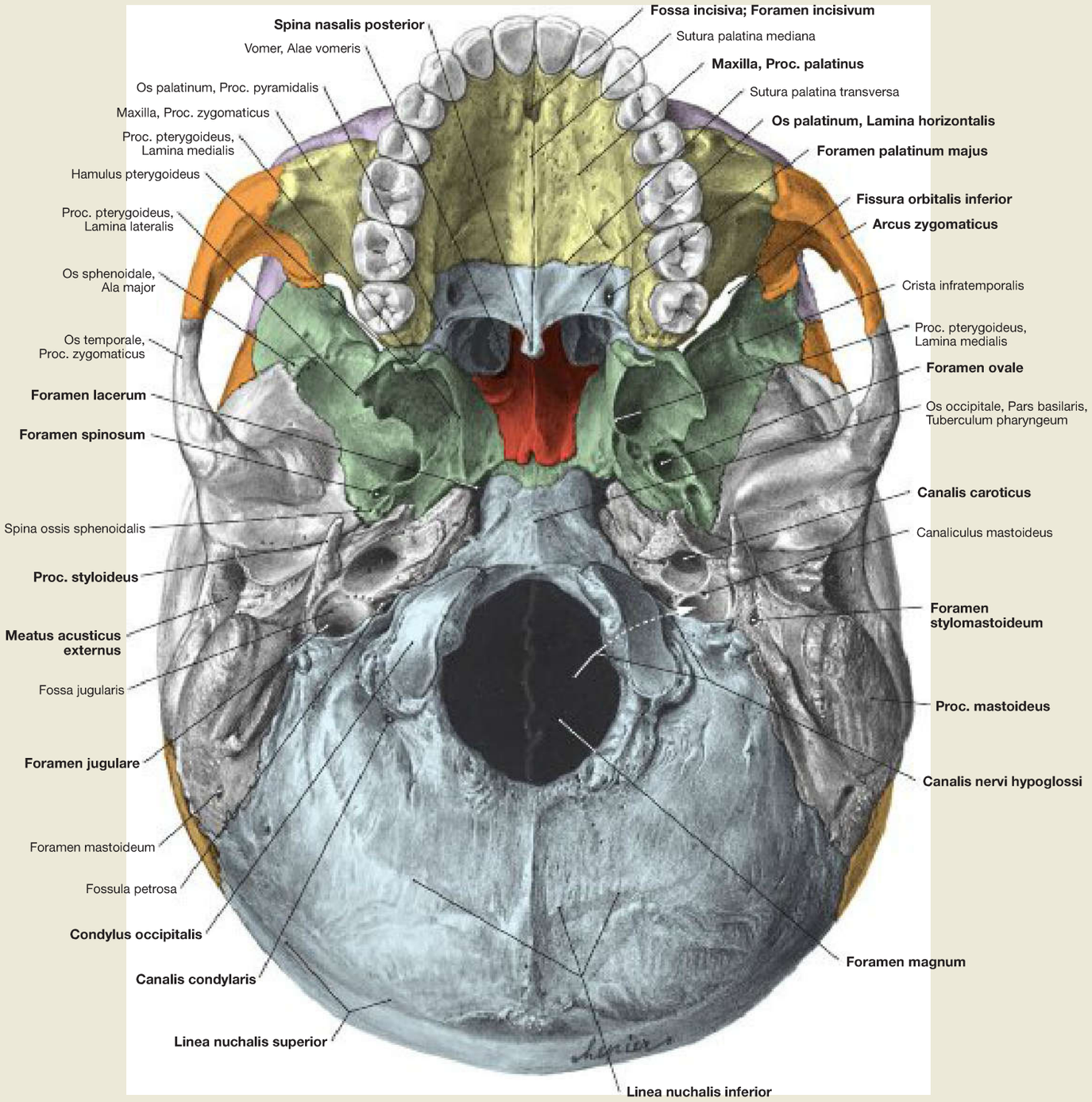

Fig. 8.21 External surface of the cranial base, Basis cranii externa; view from below; for colour chart see p. VIII

The cranial base extends at the front up to the middle incisors, laterally to the Proc. mastoideus and Arcus zygomaticus, respectively, and backwards to the Lineae nuchales superiores. The cranial base is divided into three compartments:

- anterior compartement, with maxillary teeth and palate
- middle compartment, posterior to the palate up to the anterior margin of the foramen magnum
- posterior compartment, from the anterior margin of the Foramen magnum to the Lineae nuchales superiores

Anterior cranial base: encompasses the hard palate (→ Fig. 8.32).

Middle cranial base: the anterior part of the middle compartment consists of the Vomer and Os sphenoidale; the posterior part is formed by the Ossa temporalia and Os occipitale. The Os sphenoidale, which is above the Vomer in the front of the midline, contributes to the Pars posterior of the bony nasal septum.

The Os sphenoidale is composed of a central Corpus and the paired Alae majores and Alae minores (not visible from below).

Immediately behind the Corpus of the Os sphenoidale, the Pars basilaris of the Os occipitale represents the beginning of the posterior part of the middle cranial base. The Pars basilaris extends up to the Foramen magnum. At this point, the Tuberculum pharyngeum protrudes as a projection on which parts of the pharynx are attached to the base of the skull (continuation → Fig. 8.22).

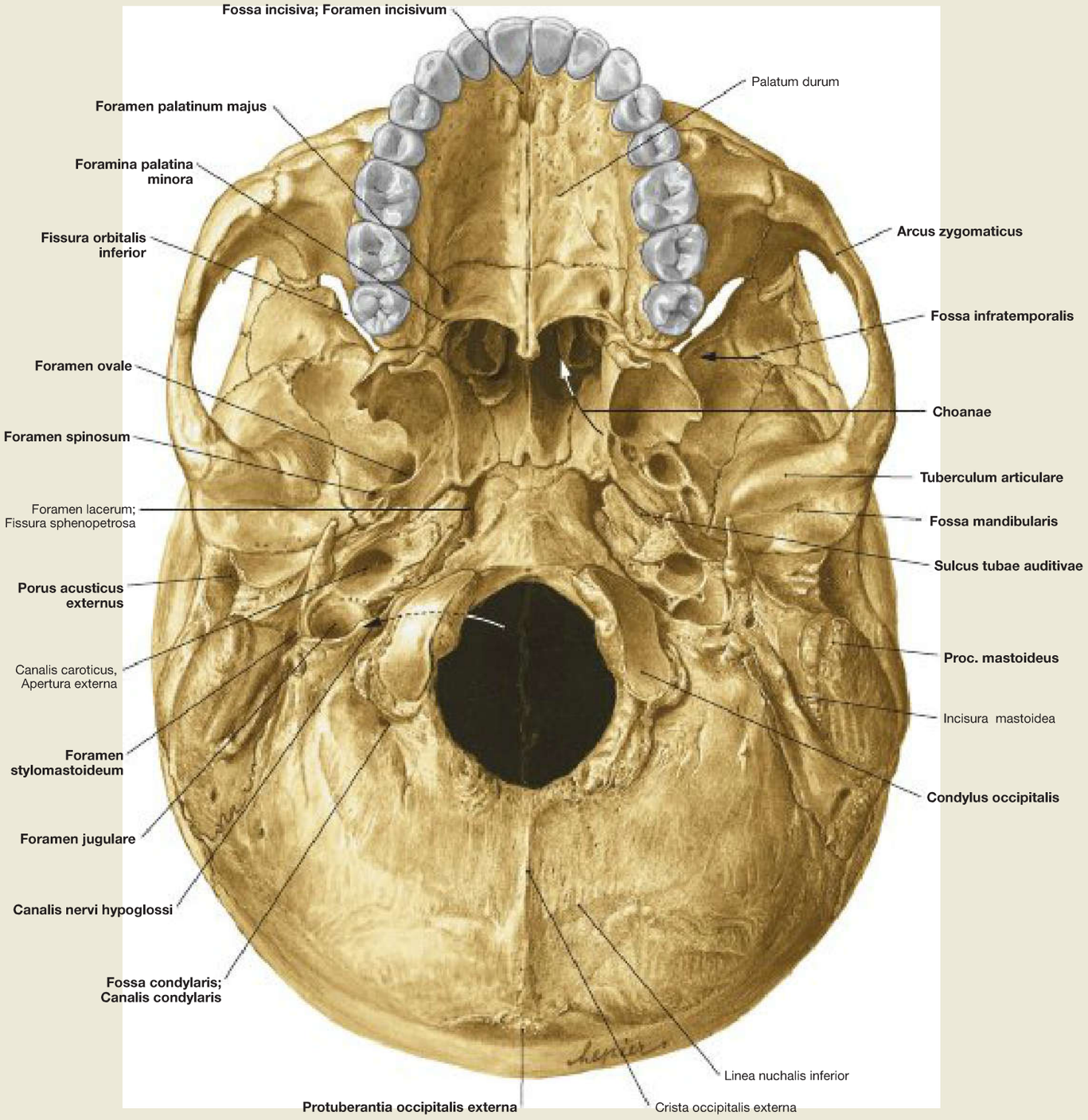

Fig. 8.22 External surface of the cranial base, Basis cranii externa; view from below.
Middle cranial base (continuation of → Fig. 8.21): the Sulcus tubae auditivae is positioned at the border between the Ala major of the Os sphenoidale and the Pars petrosa of the Os temporale and forms the entrance into the bony part of the Tuba auditiva (→ p. 175). The bony canal continues through the Pars petrosa of the Os temporale to the tympanic cavity. Located laterally is the Pars squamosa of the Os temporale which is involved in the formation of the Articulatio temporomandibularis. The Fossa mandibularis is part of the Facies articularis of the Articulatio temporomandibularis (→ pp. 41–45). The Tuberculum articulare is located at the anterior margin of the Fossa mandibularis.

Posterior cranial base: the posterior compartment extends from the anterior margin of the Foramen magnum to the Lineae nuchales superiores and consists of parts of the Os occipitale and the Ossa temporalia. The paired Pars lateralis has on either side a Condylus occipitalis to articulate with the atlas. Located behind each condyle is the Fossa condylaris, which contains the Canalis condylaris; above the condyle runs the Canalis nervi hypoglossi. Immediately lateral thereof is the Foramen jugulare.

Passageways of the External Surface of the Cranial Base

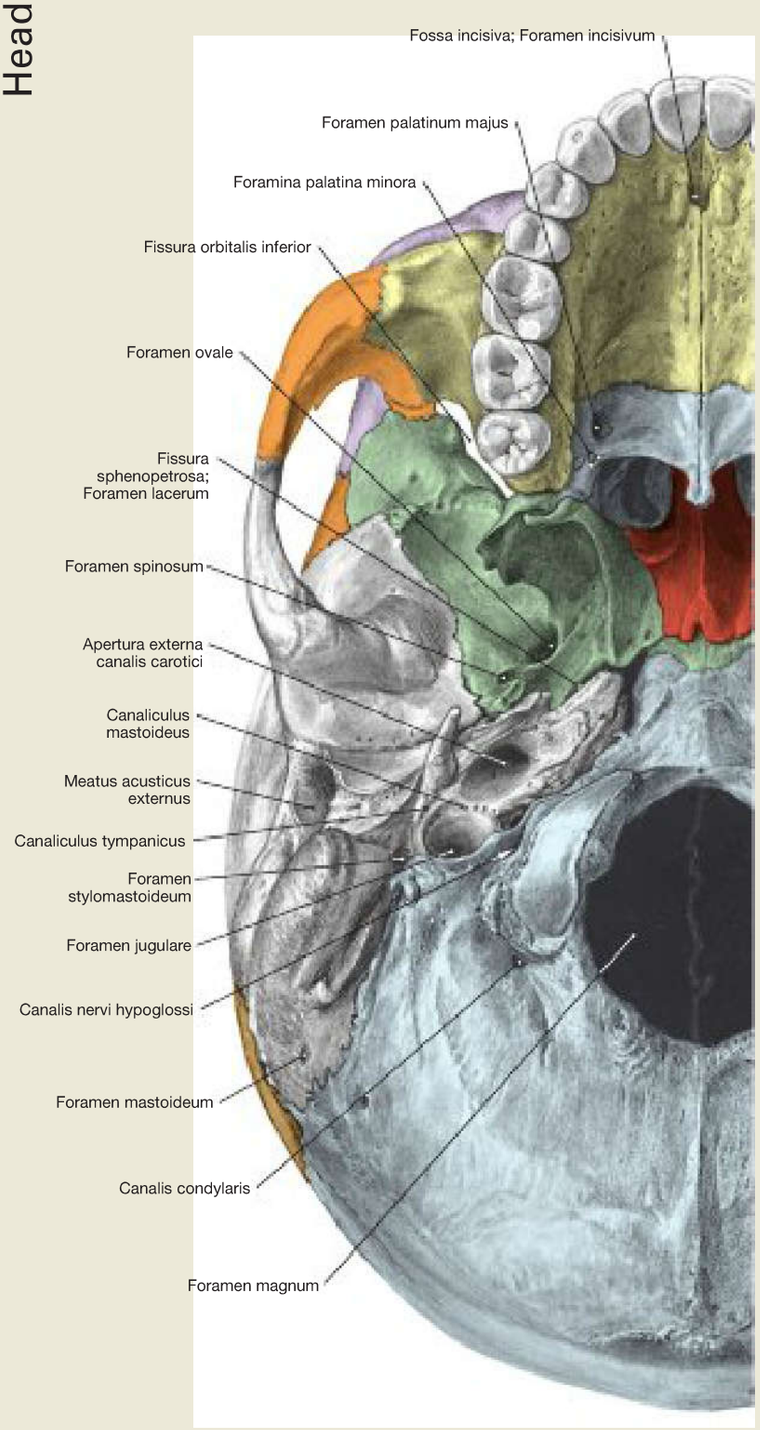

Fig. 8.23 External surface of the cranial base, Basis cranii externa; with foramina; view from below; for colour chart see p. VIII

Clinical Remarks

In the case of **fractures of the cranial base,** the fracture lines often run through the openings of the cranial base. The penetrating nerves and blood vessels can thereby be injured. Nerve lesions and bleeding therefore frequently occur. Similarly, fractures of the frontal and sphenoidal sinuses, as well as of the ethmoidal cells are possible (leakage of cerebrospinal fluid from the nose). With lateral fractures, the Os temporale is often affected (leakage of cerebrospinal fluid from the ear).

Foramina of the External Surface of the Cranial Base and their Content

Foramen	Content
Foramen incisivum	• N. nasopalatinus (N. maxillaris [V/2])
Foramen palatinum majus	• N. palatinus major (N. maxillaris [V/2]) • A. palatina major (A. palatina descendens)
Foramina palatina minora	• Nn. palatini minores (N. maxillaris [V/2]) • Aa. palatinae minores (A. palatina descendens)
Fissura orbitalis inferior	• A. infraorbitalis (A. maxillaris) • V. ophthalmica inferior • N. infraorbitalis (N. maxillaris [V/2]) • N. zygomaticus (N. maxillaris [V/2])
Foramen rotundum (→ p. 16)	• N. maxillaris [V/2]
Foramen ovale	• N. mandibularis [V/3] • Plexus venosus foraminis ovalis
Foramen spinosum	• R. meningeus (N. mandibularis [V/3]) • A. meningea media (A. maxillaris)
Fissura spheno-petrosa, Foramen lacerum	• N. petrosus minor (N. glossopharyngeus [IX]) • N. petrosus major (N. facialis [VII]) • N. petrosus profundus (Plexus caroticus internus)
Apertura externa canalis carotici and Canalis caroticus	• A. carotis interna, Pars petrosa • Plexus venosus caroticus internus • Plexus caroticus internus (Truncus sympathicus, Ganglion cervicale superius)
Foramen stylomastoideum	• N. facialis [VII]
Foramen jugulare	Anterior area: • Sinus petrosus inferior • N. glossopharyngeus [IX] Posterior area: • A. meningea posterior (A. pharyngea ascendens) • Sinus sigmoideus (Bulbus superior venae jugularis) • N. vagus [X] • R. meningeus (N. vagus [X]) • N. accessorius [XI]
Canaliculus mastoideus	• R. auricularis nervi vagi (N. vagus [X])
Canaliculus tympanicus	• N. tympanicus • A. tympanica inferior
Canalis nervi hypoglossi	• N. hypoglossus [XII] • Plexus venosus canalis nervi hypoglossi
Canalis condylaris	• V. emissaria condylaris
Foramen magnum	• Meninges • Plexus venosus vertebralis internus (Sinus marginalis) • Aa. vertebrales (Aa. subclaviae) • A. spinalis anterior (Aa. vertebrales) • Medulla oblongata/Medulla spinalis • Radices spinales (N. accessorius [XI])

Foramina of the Internal Surface of the Cranial Base and their Content	
Foramen	**Content**
Lamina cribrosa	• Nn. olfactorii [I] • A. ethmoidalis anterior (A. ophthalmica)
Canalis opticus	• N. opticus [II] • A. ophthalmica (A. carotis interna) • Meninges; Vaginae nervi optici
Fissura orbitalis superior	Medial area: • N. nasociliaris (N. ophthalmicus [V/1]) • N. oculomotorius [III] • N. abducens [VI] Lateral area: • N. trochlearis [IV] common trunk of: – N. frontalis (N. ophthalmicus [V/1]) – N. lacrimalis (N. ophthalmicus [V/1]) • R. orbitalis (A. meningea media) • V. ophthalmica superior
Foramen rotundum	• N. maxillaris [V/2]
Foramen ovale	• N. mandibularis [V/3] • Plexus venosus foraminis ovalis
Foramen spinosum	• R. meningeus (N. mandibularis [V/3]) • A. meningea media (A. maxillaris)
Fissura spheno-petrosa, Foramen lacerum	• N. petrosus minor (N. glossopharyngeus [IX]) • N. petrosus major (N. facialis [VII]) • N. petrosus profundus (Plexus caroticus internus)
Apertura interna canalis carotici and Canalis caroticus	• A. carotis interna, Pars petrosa • Plexus venosus caroticus internus • Plexus caroticus internus (Truncus sympathicus, Ganglion cervicale superius)
Porus and Meatus acusticus internus	• N. facialis [VII] • N. vestibulocochlearis [VIII] • A. labyrinthi (A. basilaris) • Vv. labyrinthi
Foramen jugulare	Anterior area: • Sinus petrosus inferior • N. glossopharyngeus [IX] Posterior area: • A. meningea posterior (A. pharyngea ascendens) • Sinus sigmoideus (Bulbus superior venae jugularis) • N. vagus [X] • N. accessorius [XI] • R. meningeus (N. vagus [X])
Canalis nervi hypoglossi	• N. hypoglossus [XII] • Plexus venosus canalis nervi hypoglossi
Canalis condylaris	• V. emissaria condylaris
Foramen magnum	• Meninges • Plexus venosus vertebralis internus (Sinus marginalis) • Aa. vertebrales (Aa. subclaviae) • A. spinalis anterior (Aa. vertebrales) • Medulla oblongata/Medulla spinalis • Radices spinales (N. accessorius [XI])

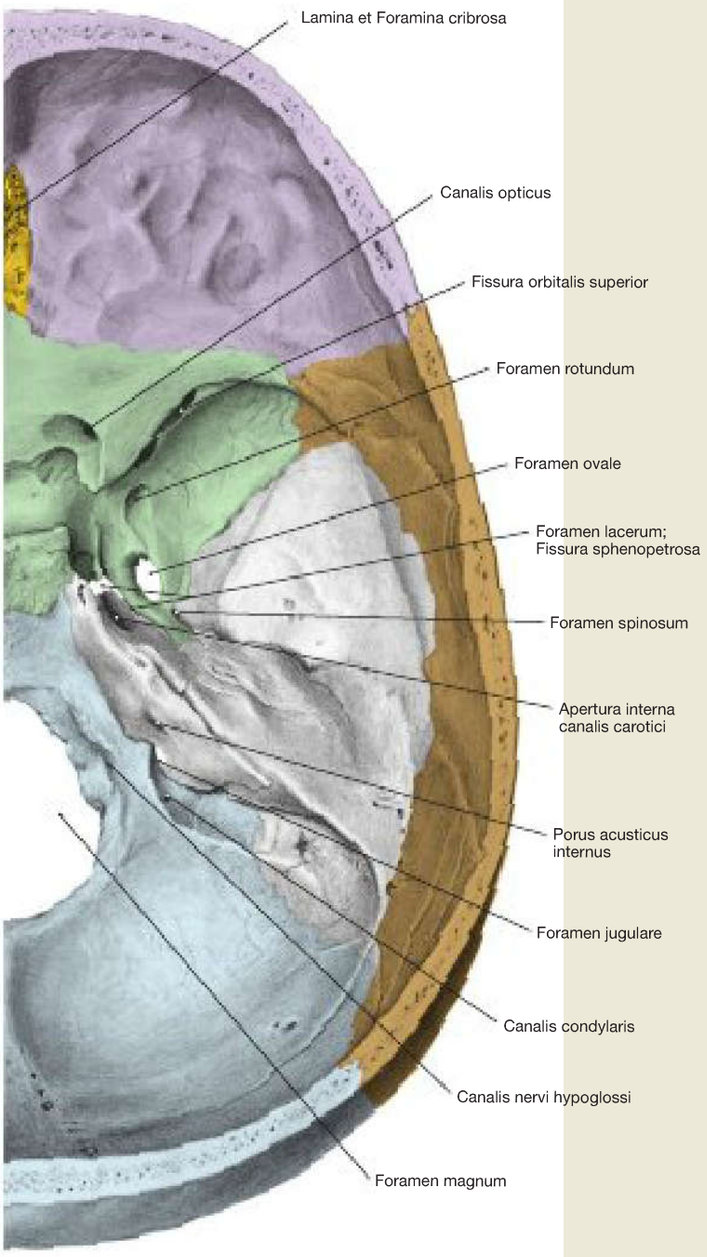

Fig. 8.24 Internal surface of the cranial base, Basis cranii interna; with foramina; view from above; for colour chart see p. VIII

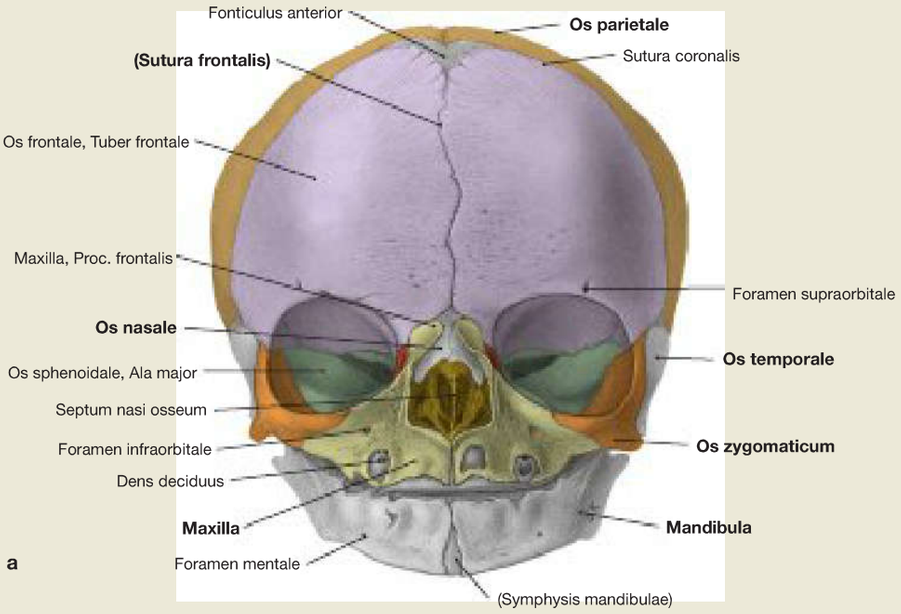

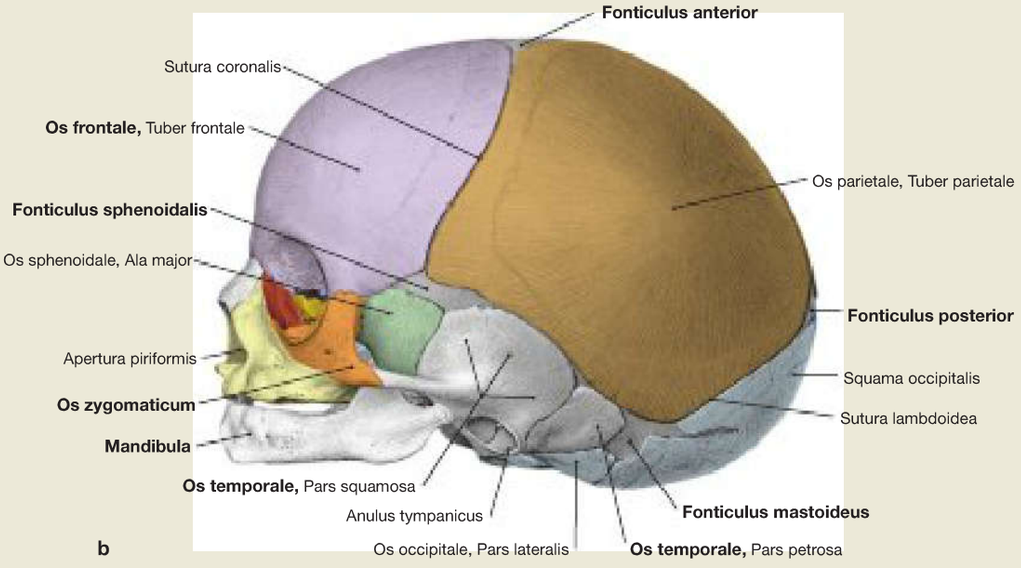

Fig. 8.25a and b Cranium of a newborn; frontal view (→ Fig. 8.25a) and lateral view (→ Fig. 8.25b); for colour chart see p. VIII. a [L238]
At birth, the newborn has six fontanelles, two unpaired (Fonticuli anterior and posterior) and two paired (Fonticuli sphenoidales and mastoidei). During **birth process,** the cranial sutures and fontanelles serve as reference structures for assessing the position and presentation of the child's head. The posterior fontanelle is the leading part of the head in a normal presentation of the foetus.
Together with the cranial sutures, the fontanelles ensure a limited skull deformation during the birth process. The acceleration of growth after birth results in a rapid reduction of the fontanelles, which will be closed by the third year of life.

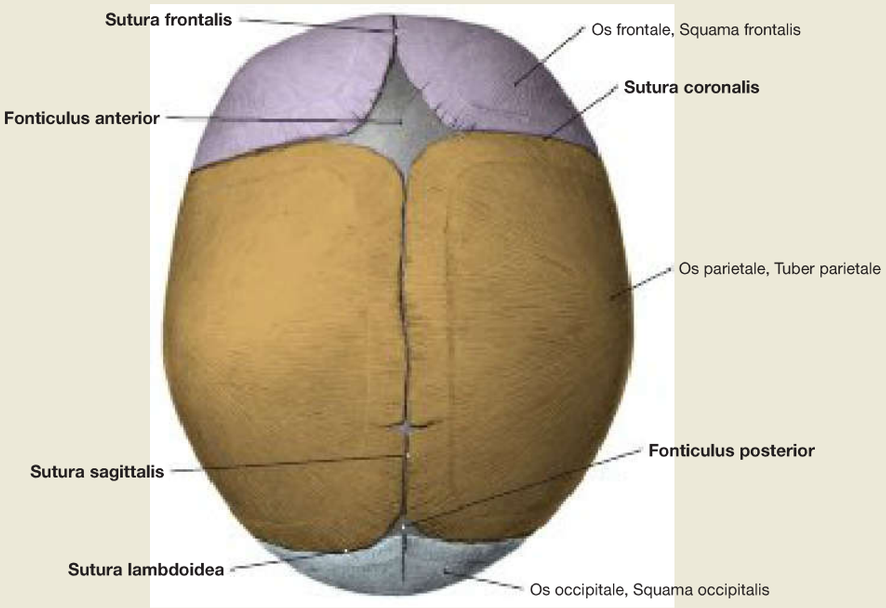

Fig. 8.26 Cranium of a newborn; view from above; for colour chart see p. VIII.
At birth, the bony plates of the skull cap (calvaria) are still separated by the interstitial tissue located in the cranial sutures (Suturae). The sutures are widened to fontanelles (Fonticuli) in regions where more than two bones meet. Over the course of life, most sutures, fonticuli and synchondroses ossify. Important sutures are the Suturae lambdoidea **(lambdoid suture),** frontalis **(frontal suture),** sagittalis **(sagittal suture)** and coronalis **(coronal suture)** which continue closing up to the age of 50; the frontal suture already between the first and second years of life).

Fontanelles		
Fontanelle	**Number**	**Closure [LM = month of life]**
Fonticulus anterior (large fontanelle)	1	approx. 36 LM
Fonticulus posterior (small fontanelle)	1	approx. 3 LM
Fonticulus sphenoidalis (anterior lateral fontanelle)	paired	approx. 6 LM
Fonticulus mastoideus (posterior lateral fontanelle)	paired	approx. 18 LM

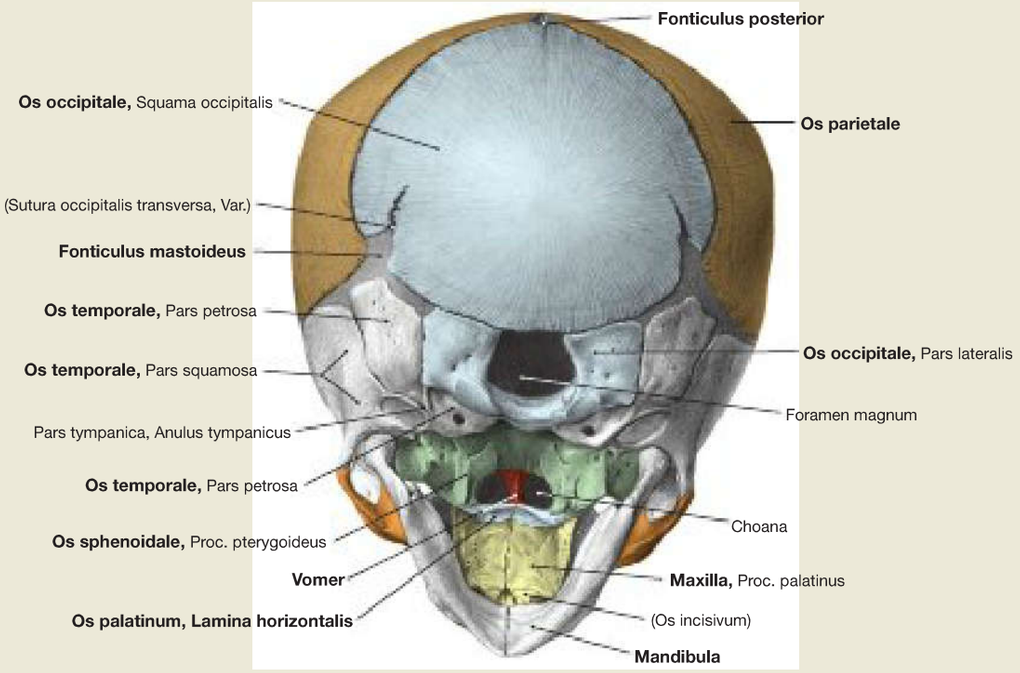

Fig. 8.27 Cranium of a newborn; anterior view from below; for colour chart see p. VIII.
The development of the skull follows a partly intramembranous (desmal), partly endochondral mode of osteogenesis (→ table). The primordial substance is the mesenchyme derived from the paraxial cranial mesenchyme, the prechordal mesoderm, the occipital somites and the neural crest. At the time of birth, some cranial bones are linked by cartilaginous joints (Articulationes cartilagineae; Synchondroses cranii).

Ossification Mode of the Cranial Bones

	Viscerocranium	Neurocranium	Auditory Ossicles
Desmal	Mandibula except Proc. condylaris, Maxilla, Os zygomaticum, Os palatinum, Os nasale, Vomer, Os lacrimale	Lamina medialis of the Proc. pterygoideus of the Os sphenoidale, Pars squamosa of the Os temporale, Squama occipitalis, Os frontale, Os parietale	
Endochondral	Proc. condylaris of the Mandibula, Os ethmoidale, Concha nasalis inferior	Os sphenoidale except the Lamina medialis of the Proc. pterygoideus, Pars petrosa and Pars tympanica of the Os temporale, Pars lateralis and Pars basilaris of the Os occipitale	
MECKEL's cartilage			Malleus, Incus
REICHERT's cartilage		Proc. styloideus of the Os temporale	Stapes

a

b

Fig. 8.28a and b Craniostenosis; child with scaphocephaly.
[E347-09]
This malformation results of the premature closure of the Sutura sagittalis. The skull cap is overly long.
a View from above
b View from the right

Clinical Remarks

Disturbances of bone growth are referred to as dysostoses. **Craniosynostoses** are malformations as a result of the premature closure of one or more sutures. The premature closure of the Sutura sagittalis results in the extension of the skull in the frontal and occipital regions. The skull becomes longer and narrower **(scaphocephaly).** The premature closure of the Sutura coronalis leads to the formation of a 'tower'-shaped skull **(turricephaly).** If the premature closure of the Suturae coronalis and lambdoidea occurs on one side only, this results in an asymmetrical craniosynostosis **(plagiocephaly). Microcephaly** results of a failed brain growth. Because the skull growth adapts to the brain growth, the entire neurocranium remains small. Children with microcephaly are mentally retarded.

Frontal Bone and Ethmoidal Bone

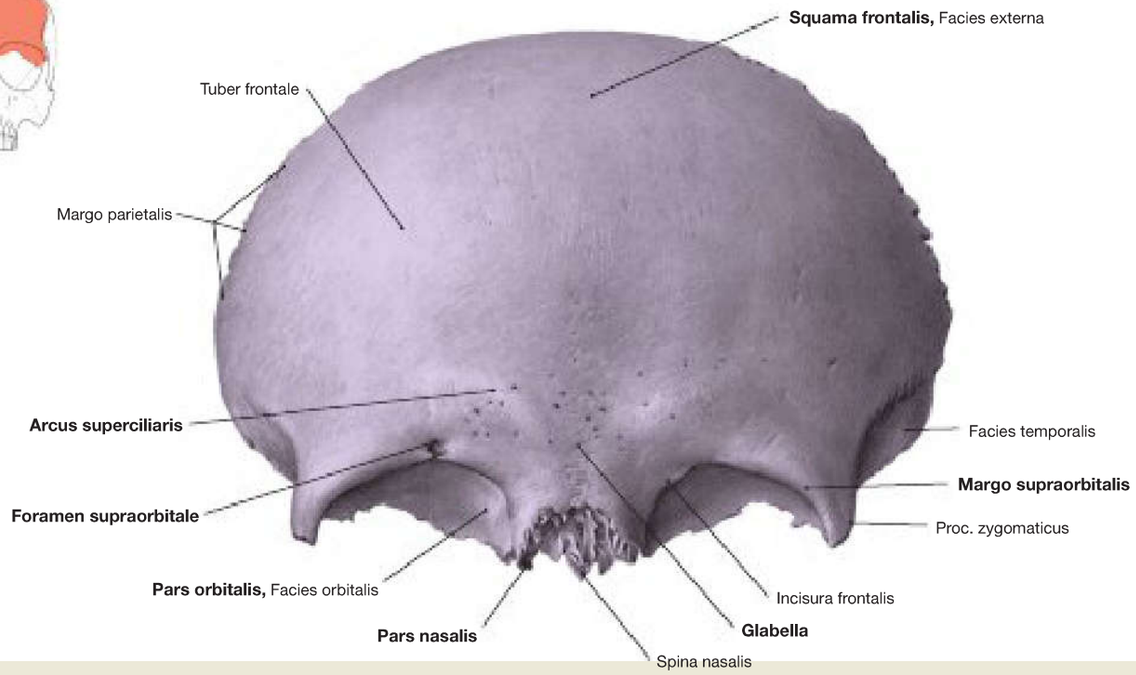

Fig. 8.29 Frontal bone, Os frontale; frontal view; for colour chart see p. VIII.
The Os frontale is the foremost bone of the calvaria. It forms part of the walls of the orbital and nasal cavities. The unpaired Os frontale is divided into **four parts:**

- the Pars squamosa (Squama frontalis)
- the paired Pars orbitalis and
- the unpaired Pars nasalis

Above the upper margin of the orbit (Margo supraorbitalis) bulges a prominent Arcus superciliaris, which is usually stronger in men than in women. In the midline between the two arches, the bone is flat and creates the glabella (area between the eyebrows). At the medial upper margin of the orbit is usually a Foramen supraorbitale, and very occasionally an Incisura frontalis.

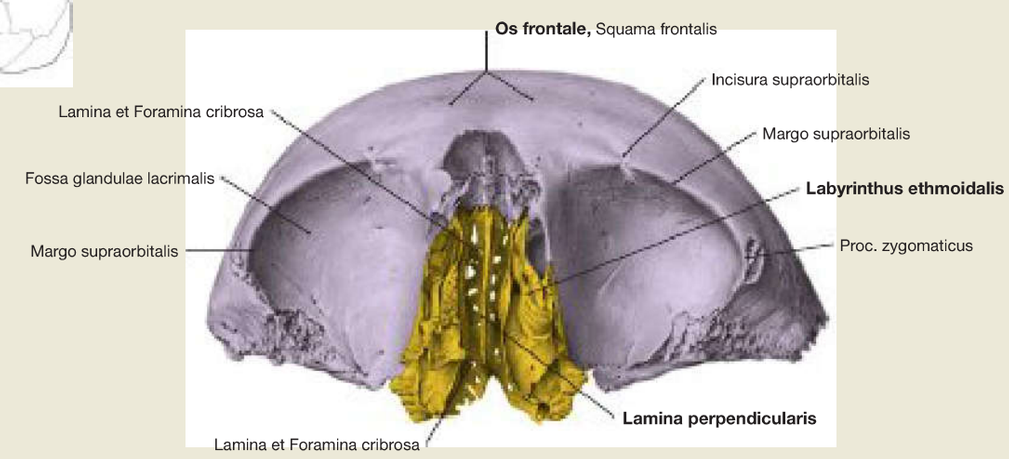

Fig. 8.30 Frontal bone, Os frontale, ethmoidal bone, Os ethmoidale, and nasal bones, Ossa nasalia; view from below; for colour chart see p. VIII.

Medially in front and below, the Os ethmoidale and Ossa nasalia, which are connected to the Os frontale, form parts of the nasal skeleton. The Sinus frontalis is located in the Os frontale.

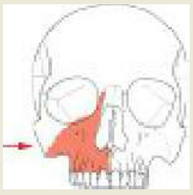

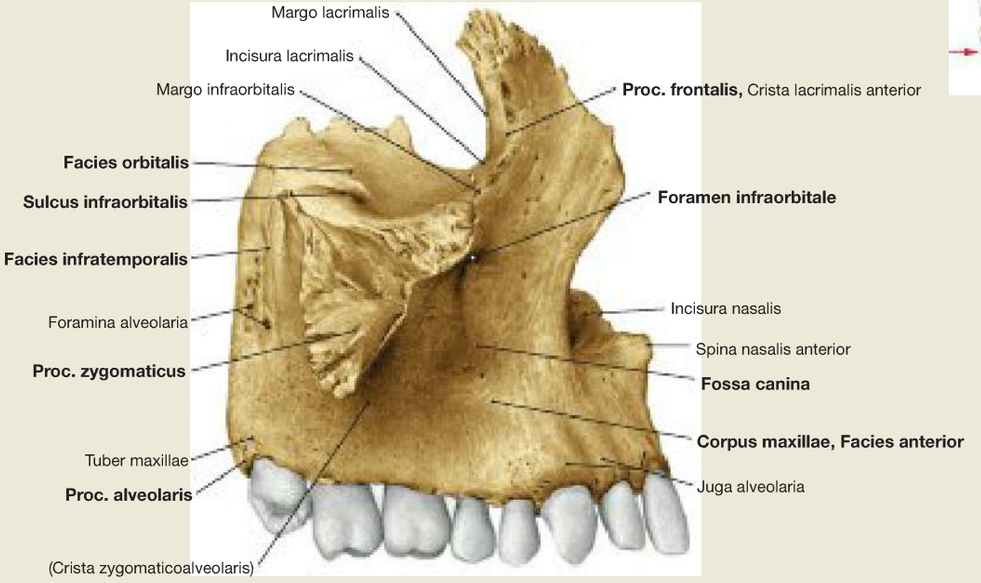

Fig. 8.31 Maxilla, right side; lateral view.
The upper jaw can be divided into the body of the maxilla (Corpus maxillae), the frontal process (Proc. frontalis, connected to the Os frontale), the zygomatic process (Proc. zygomaticus, forms together with the Os zygomaticum the Arcus zygomaticus), the palate process (Proc. palatinus, anterior portion of the bony palate, → Fig. 8.32) and the Proc. alveolaris. The latter forms the lower margin of the maxilla and contains tooth sockets (Alveoli dentales) for the roots of the teeth. The prominent anterior rims of the dental alveoli are known as Juga alveolaria. In the Corpus maxillae, just below the lower orbital margin, is the Foramen infraorbitale.

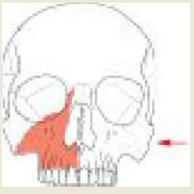

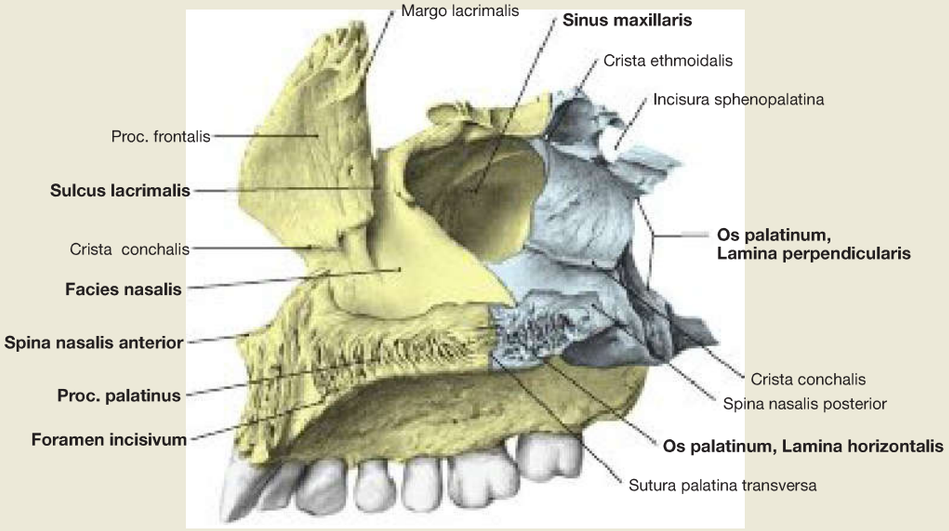

Fig. 8.32 Maxilla and palatine bone, Os palatinum, right side; medial view with regard to the Sinus maxillaris; for colour chart see p. VIII.
Posterior to the maxilla lies the Os palatinum which is composed of two plates: The **Lamina horizontalis** creates the Pars posterior of the palate (Palatum osseum), and the **Lamina perpendicularis** extends vertically upright (perpendicular to the Lamina horizontalis) and is the posterior medial margin of the Sinus maxillaris.

Nasal Cavity

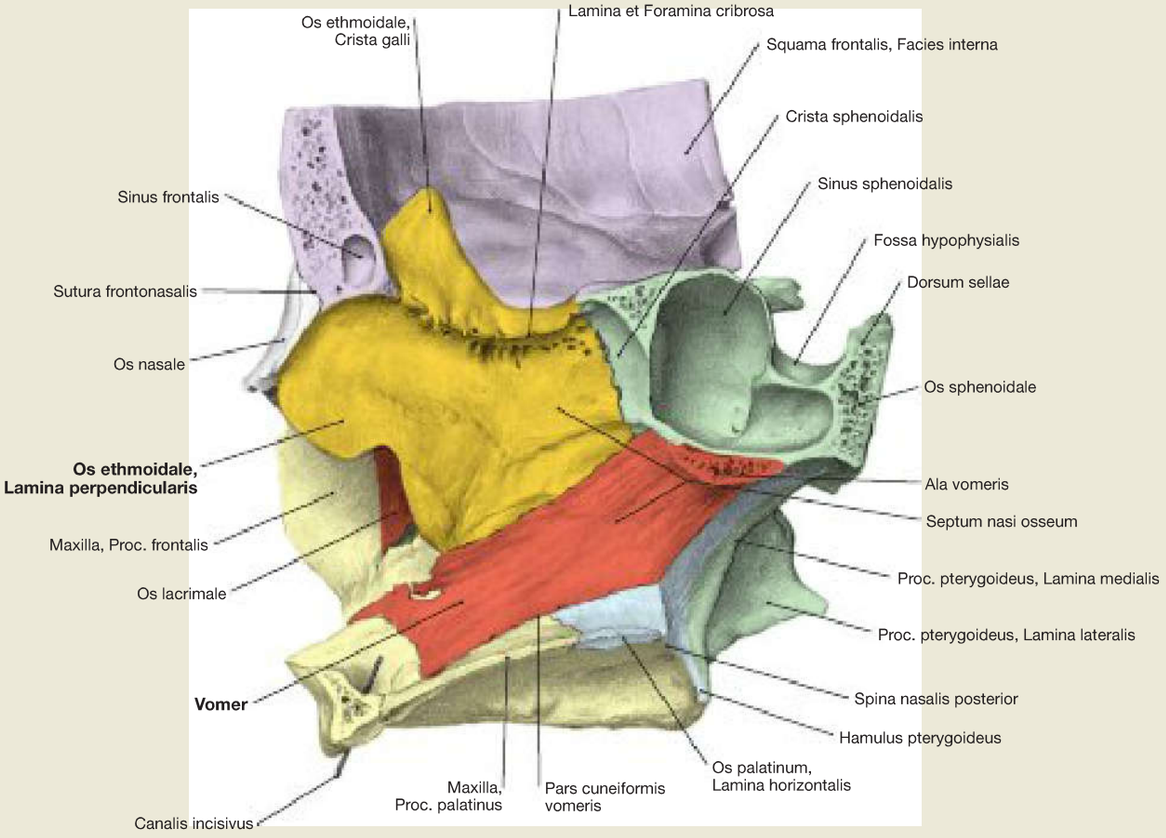

Fig. 8.33 Bony nasal septum; lateral view; for colour chart see p. VIII. The bony nasal septum is formed by the Lamina perpendicularis of the Os ethmoidale and by the Vomer.
The **Os ethmoidale** sits between the Os frontale and the maxilla and is also connected to the Ossa nasalia, lacrimalia, sphenoidale and palatina. It forms the Crista galli above. Perforated with multiple holes, the Lamina cribrosa is the roof of the nasal cavity and part of the floor of the anterior cranial fossa. The Lamina perpendicularis of the Os ethmoidale is located below the Crista galli, it divides the bony labyrinth of the Os ethmoidale into a right and left part, and constitutes the upper part of the bony nasal septum.
The **Vomer** forms the largest part of the bony nasal septum. The flat trapezoid bone is connected above with the Lamina perpendicularis of the Os ethmoidale and posteriorly via the Ala vomeris with the Os sphenoidale. Below, the Pars cuneiformis vomeris borders the Proc. palatinus of the maxilla, and the Lamina horizontalis of the Os palatinum.

Clinical Remarks

A **nasal septum deviation** can be the result of a traumatic puncture or a blow to the nose, or is caused by a developmental deformity of the facial bones. More than 60% of the population has at least a mild septum deviation. Nasal septum deviations primarily hinder the nasal breathing. If this is the case, the inspired air cannot be heated, cleaned and moistened. The nasal breathing obstruction leads to increased mouth breathing with snoring and/or increased risk of inflammation. Since the paranasal sinuses are no longer sufficiently ventilated, this can lead to sinusitis with post-nasal drip of secretions and descending inflammation of the larynx and bronchi. Later in life, cardiovascular diseases can result from the lack of oxygen.

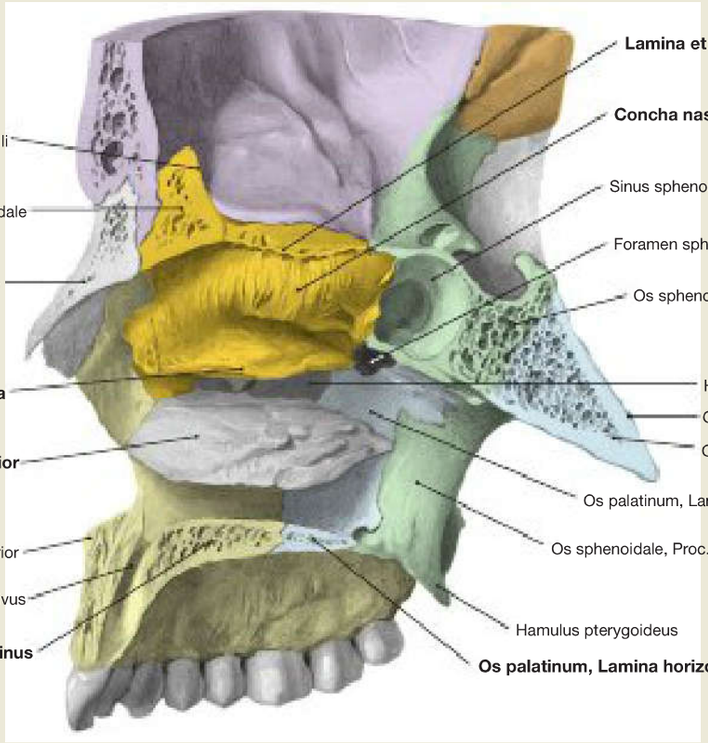

Fig. 8.34 Lateral wall of the nasal cavity, Cavitas nasi, right side; view from the left; for colour chart see p. VIII.
The view of the lateral nasal wall shows that the Lamina cribrosa of the Os ethmoidale is the roof on top, and also forms the superior nasal concha (Concha nasalis superior) and the middle nasal concha (Concha nasalis media). The upper nasal passage (Meatus nasi superior) is located between the two nasal conchae. Below sits the Concha nasalis inferior as an independent bone.

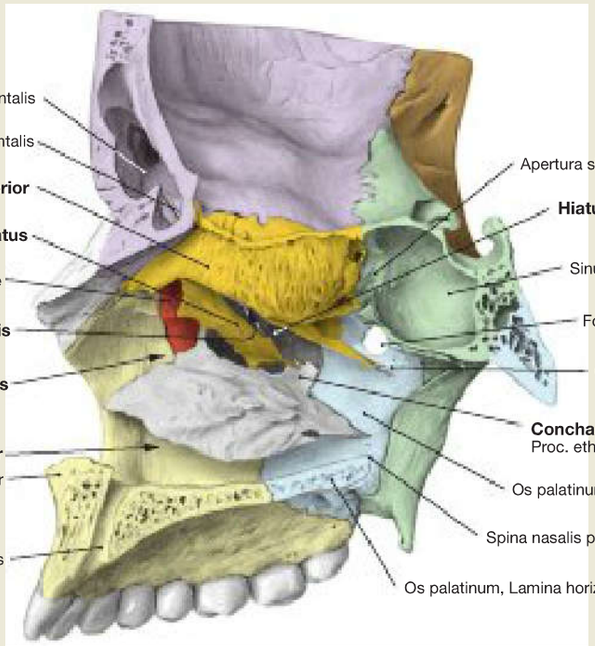

Fig. 8.35 Lateral wall of the nasal cavity, Cavitas nasi, right side; medial view after removal of the middle nasal concha; for colour chart see p. VIII.
Beneath the middle nasal concha is a thin lamellar bone, the **Proc. uncinatus,** which forms part of the Os ethmoidale, but does not completely close the medial wall of the Sinus maxillaris. There are numerous openings above and below the Proc. uncinatus. One of these is the Hiatus maxillaris.
The **maxilla** and the **Os palatinum** create the floor and parts of the lateral wall (floor: Lamina horizontalis; lateral wall: Lamina perpendicularis). The **Os lacrimale** is also part of the lateral wall and forms part of the anterior margin of the Sinus maxillaris. The Concha nasalis inferior is attached to the three latter bones. It divides the lateral nasal wall into an overlying middle nasal passage (Meatus nasi medius) and an underlying lower nasal passage (Meatus nasi inferior).

Hard Palate

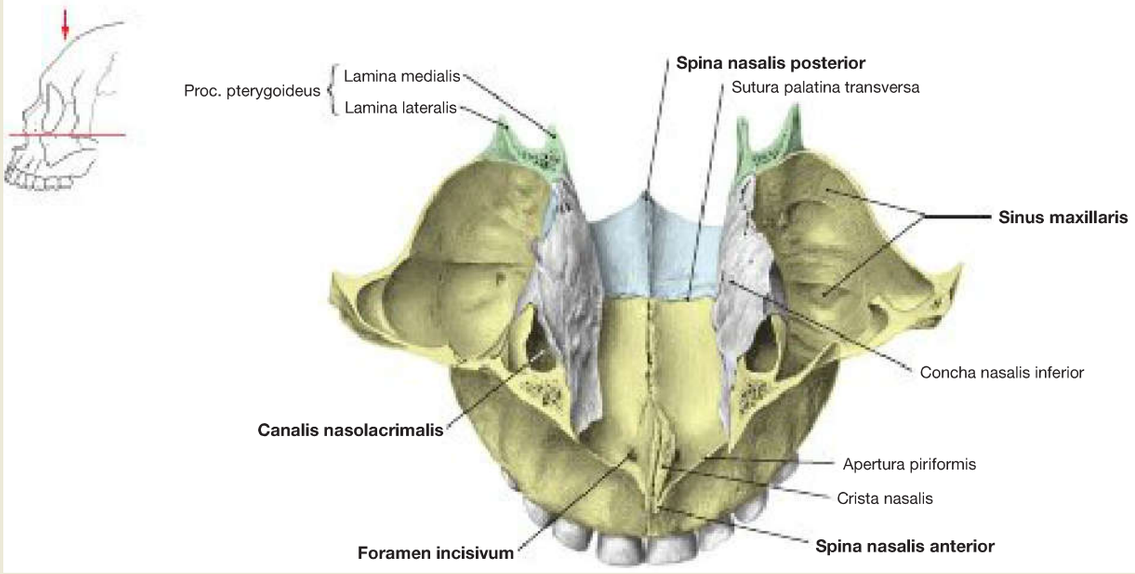

Fig. 8.36 Hard palate, Palatum durum; maxillary sinus, Sinus maxillaris, and inferior nasal concha, Concha nasalis inferior; view from above; for colour chart see p. VIII.
The hard palate represents a horizontal bony plate created by the maxilla and the Os palatinum. It separates the oral and nasal cavities from each other. A connection exists via the Foramina incisiva. This illustration shows the floor of the nasal cavity. The Sinus maxillares can be found laterally.

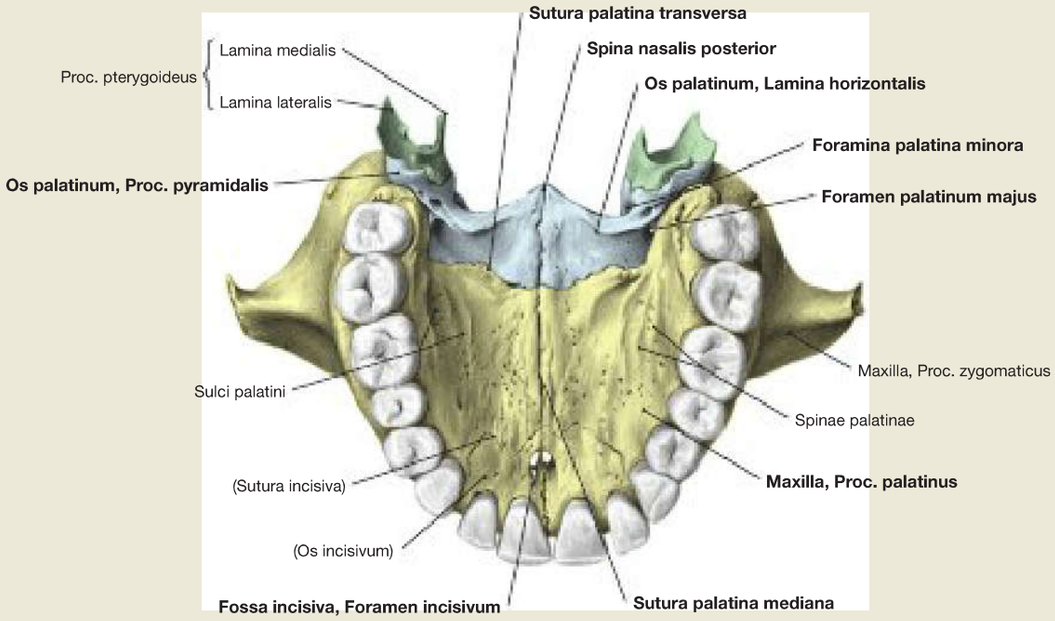

Fig. 8.37 Hard palate, Palatum durum; view from below; for colour chart see p. VIII.
The hard palate is part of the **anterior cranial base.** The teeth are attached to the two maxillary alveolar arches, which enclose the hard palate at the front and both sides. It consists rostrally of the Procc. palatini of the Maxillae and posteriorly of the Laminae horizontales of the Ossa palatina. The **Procc. palatini** are connected in the midline via the Sutura palatina mediana, and posteriorly they border the two Ossa palatina via the Sutura palatina transversa. The **Laminae horizontales** of the Ossa palatina make contact with each other in the midline via the Sutura interpalatina (continuation of the Sutura palatina mediana).
Behind the incisors, in the frontal part of the midline, is the **Fossa incisiva,** which transitions into the Foramen incisivum and the Canales incisivi. Close to the lateral posterior margin of the hard palate, on both sides, is a **Foramen palatinum majus,** which transitions into the Canalis palatinus majus, as well as the **Foramina palatina minora.** They are located in the Proc. pyramidalis of the Os palatinum and transition into the Canales palatini minores. In the midline, the **Spina nasalis posterior** protrudes backwards as a pointed process of the hard palate.

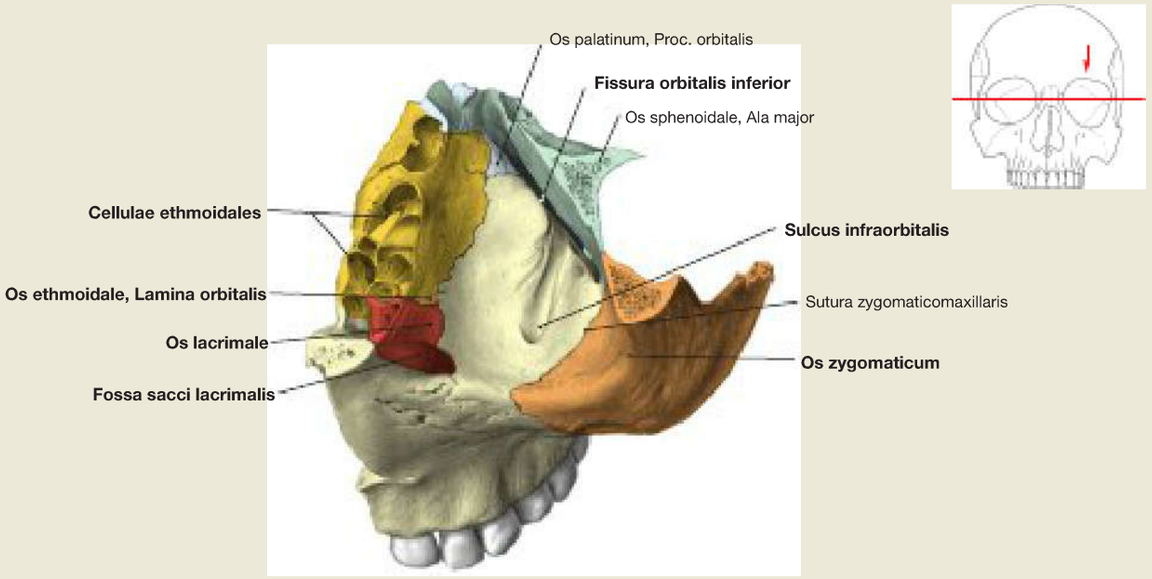

Fig. 8.38 Floor of the orbit, Paries inferior orbitae, left side; view from above; for colour chart see p. VIII.
The floor of the orbit is the roof of the Sinus maxillaris. In it is the Sulcus infraorbitalis, which becomes a bony canal passing anteriorly below the floor of the orbit and opens into the Foramen infraorbitale. It contains the N. infraorbitalis and the infraorbital vessels. Laterally, the floor of the orbit is formed by the Os zygomaticum, with medial participation of the Proc. orbitalis of the Os palatinum, the Lamina orbitalis of the Os ethmoidale and the Os lacrimale. The latter, along with the maxilla, forms the Fossa sacci lacrimalis in which the lacrimal sac can be found. For the orbital cavity → Figs. 9.9 to 9.13.

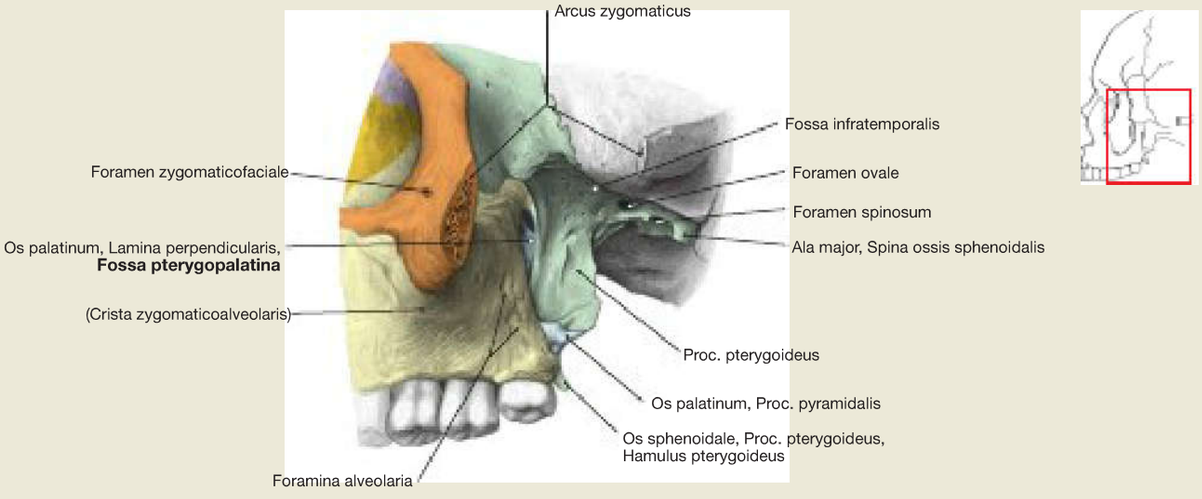

Fig. 8.39 Pterygopalatine fossa, Fossa pterygopalatina, left side; lateral view; for colour chart see p. VIII.
The Fossa pterygopalatina is the medial continuation of the Fossa infratemporalis and is bordered by the maxilla, Os palatinum and Os sphenoidale. It forms a **relais station** between the middle cranial fossa and the orbit and nose. It serves as a conduit for many nerves and blood vessels which supply the structures in these cavities (→ pp. 96–97).
Access to the pterygopalatine fossa within the context of tumour surgery in this region is generally achieved laterally, e.g. in the case of a nasopharyngeal fibroma.

Orbit

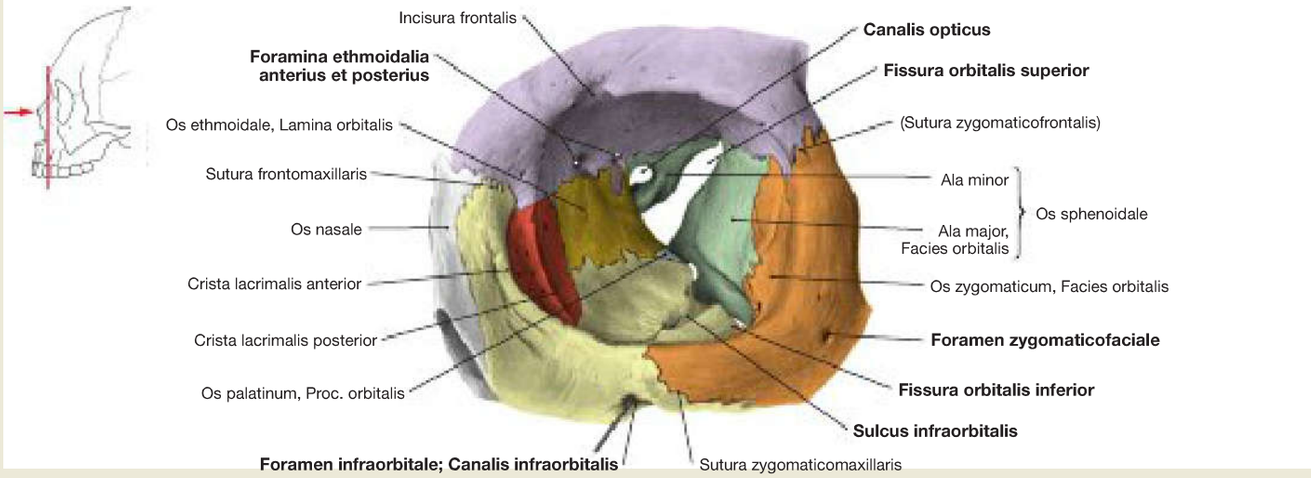

Fig. 8.40 Orbit, Orbita, left side; frontal view; probe in the Canalis infraorbitalis; for colour chart see p. VIII.
The Orbita is bordered by the Ossa frontale, ethmoidale, lacrimale, palatinum, sphenoidale, zygomaticum and the Maxilla. As openings into the Orbita serve the Fissurae orbitales superior and inferior, the Canalis opticus and the Foramina ethmoidalia anterius and posterius. In the posterior part of the floor of the Orbita, the Sulcus infraorbitalis is located, which continues anteriorly as Canalis infraorbitalis and opens into the Foramen infraorbitale below the inferior orbital margin. Laterally, the Foramen zygomaticofaciale is regularly found in the Os zygomaticum. For the orbital cavity → Figs. 9.9 to 9.13.

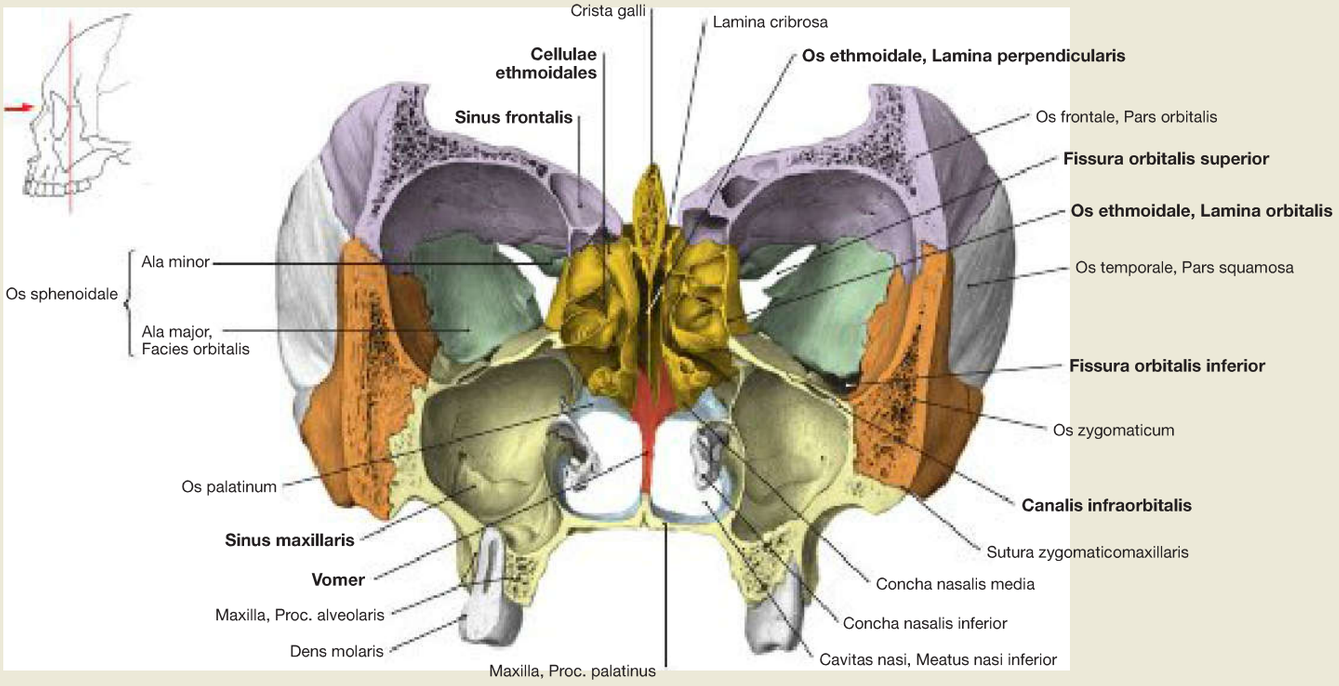

Fig. 8.41 Viscerocranium; frontal section at the level of the orbits; frontal view; for colour chart see p. VIII.
The unpaired Os ethmoidale harbours the anterior and posterior ethmoidal cells. The Lamina perpendicularis of the Os ethmoidale lies immediately beneath the Crista galli, separates the bony labyrinth of the Os ethmoidale into a right and a left half, and forms the upper part of the bony nasal septum. The Vomer joins its posterior aspect. The thin **Lamina orbitalis** forms the lateral walls of the Cellulae ethmoidales as well as the major part of the medial wall of the orbit, which is known as **Lamina papyracea.** Directly below the Orbita is the Sinus maxillaris. In its roof, which is also the floor of the Orbita, the Canalis infraorbitalis can be found. The level of the Lamina cribrosa is significantly lower than the roof of the Orbita. For the orbital cavity → Figs. 9.9 to 9.13.

Clinical Remarks

Due to the paper thin Lamina orbitalis (Lamina papyracea) of the Os ethmoidale between the orbit and the **ethmoidal cells, inflammation** of the latter can easily spread to the orbit and cause an orbital phlegmon. In → Fig. 8.41, the close proximity of the root of a molar tooth to the Sinus maxillaris can be seen. Inflammations of the second premolars and/or the first molars can lead to an odontogenic inflammation of the Sinus maxillaris (Sinusitis maxillaris).

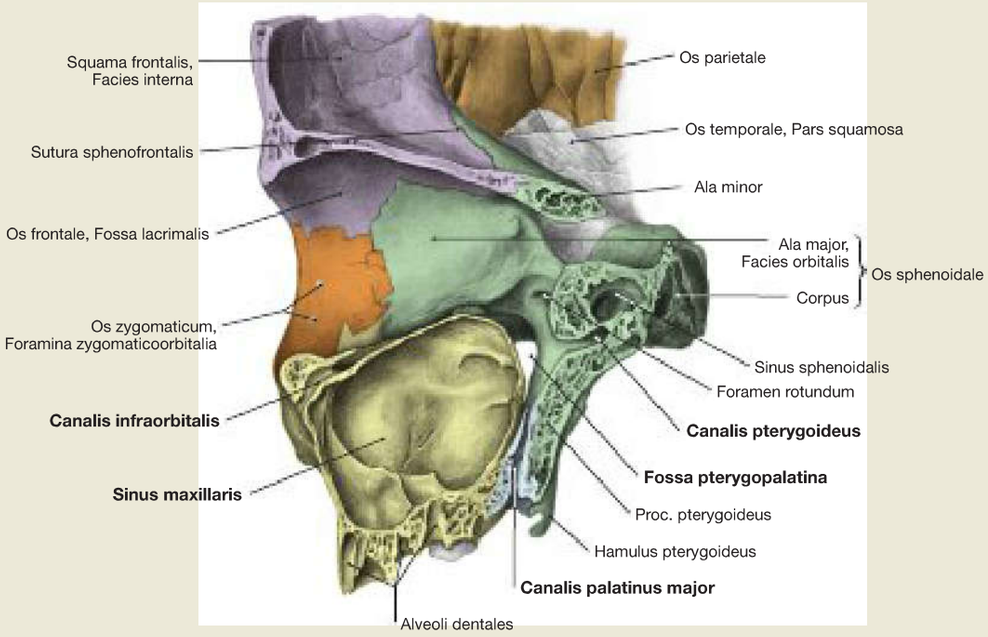

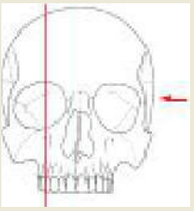

Fig. 8.42 Lateral wall of the orbit, Paries lateralis orbitae, right side; medial view; for colour chart see p. VIII.
The lateral wall of the orbit is formed by the Ossa zygomaticum, frontale, sphenoidale and the maxilla. The Canalis infraorbitalis is depicted clearly in the anterior third of the orbital floor, as well as the very thin bony layer separating the orbit from the Sinus maxillaris. Posteriorly, the Fossa pterygopalatina closes the Sinus maxillaris, which has a lateral connection to the Fossa infratemporalis, a superior connection to the Orbita, and an inferior connection via the Canalis palatinus majus to the oral cavity. From a posterior cranial position, the Canalis pterygoideus exits into the Fossa pterygopalatina.

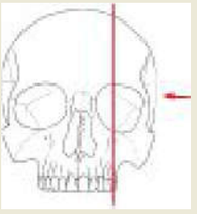

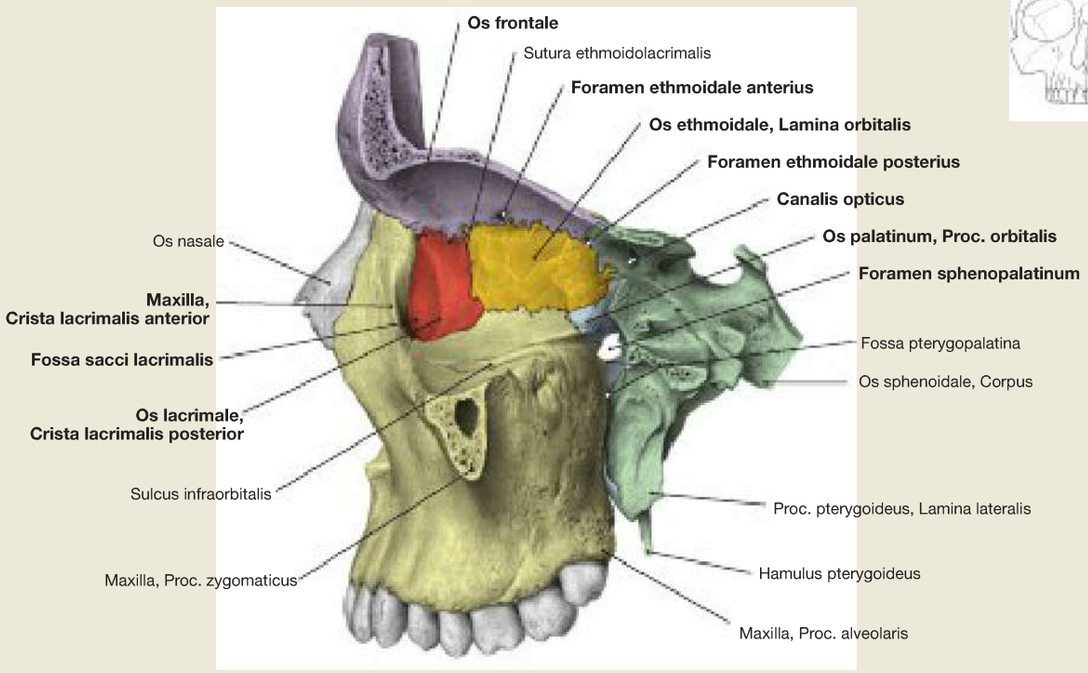

Fig. 8.43 Medial wall of the orbit, Paries medialis orbitae, left side; lateral view; for colour chart see p. VIII.
The Os lacrimale, the maxilla, and the Os frontale form the anterior part of the medial wall of the orbit, whereas in the posterior part the Lamina orbitalis of the Os ethmoidale (Lamina papyracea), the Proc. orbitalis of the Os palatinum, and the Os sphenoidale are placed between the Os frontale and the maxilla. Both, the anterior Crista lacrimalis of the maxilla and the posterior Crista lacrimalis of the Os lacrimale confine a depression (Fossa sacci lacrimalis) for the lacrimal sac. Located in the medial wall of the orbit are the Foramina ethmoidalia anterius and posterius and the Canalis opticus. Just above the Fossa pterygopalatina is the Foramen sphenopalatinum.

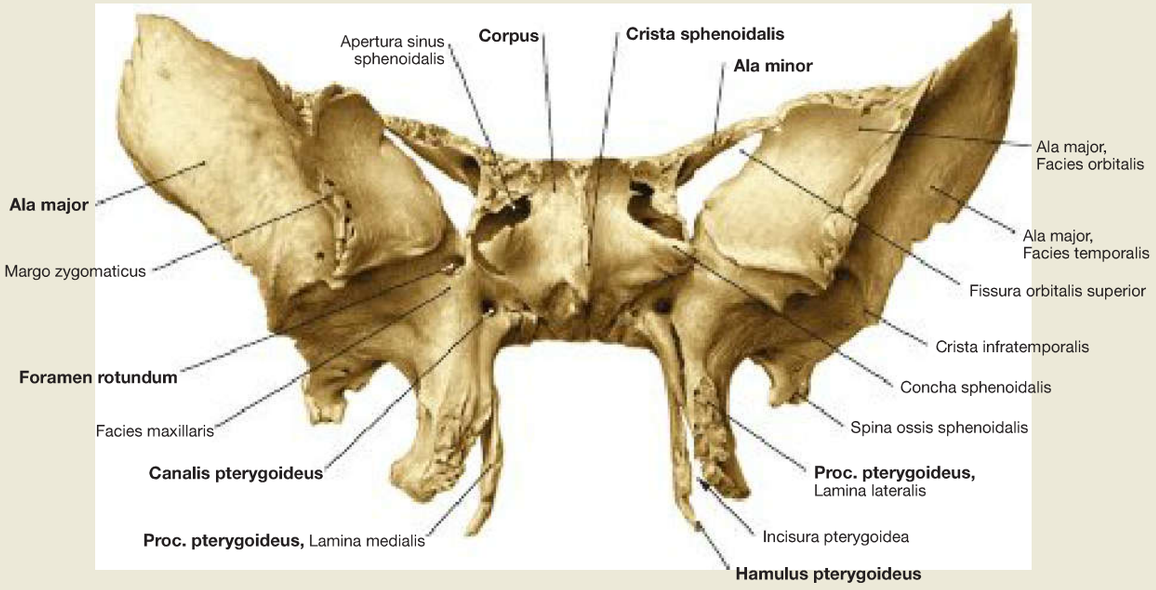

Fig. 8.44 Sphenoidal bone, Os sphenoidale; frontal view.
The unpaired Os sphenoidale is a bone connecting the viscerocranium and the neurocranium. From the Corpus of the Os sphenoidale, two pairs of wings (Alae) extend outwards laterally. At the top are the **Alae minores,** and below are the **Alae majores.** Extending downwards are the **pterygoid processes (Procc. pterygoidei)**. In the centre of the Os sphenoidale are the sphenoidal sinuses (Sinus sphenoidales)**.** The Crista sphenoidalis subdivides the anterior part of the Corpus into two halves.

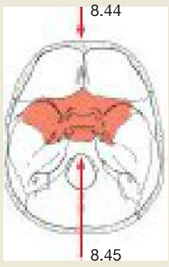

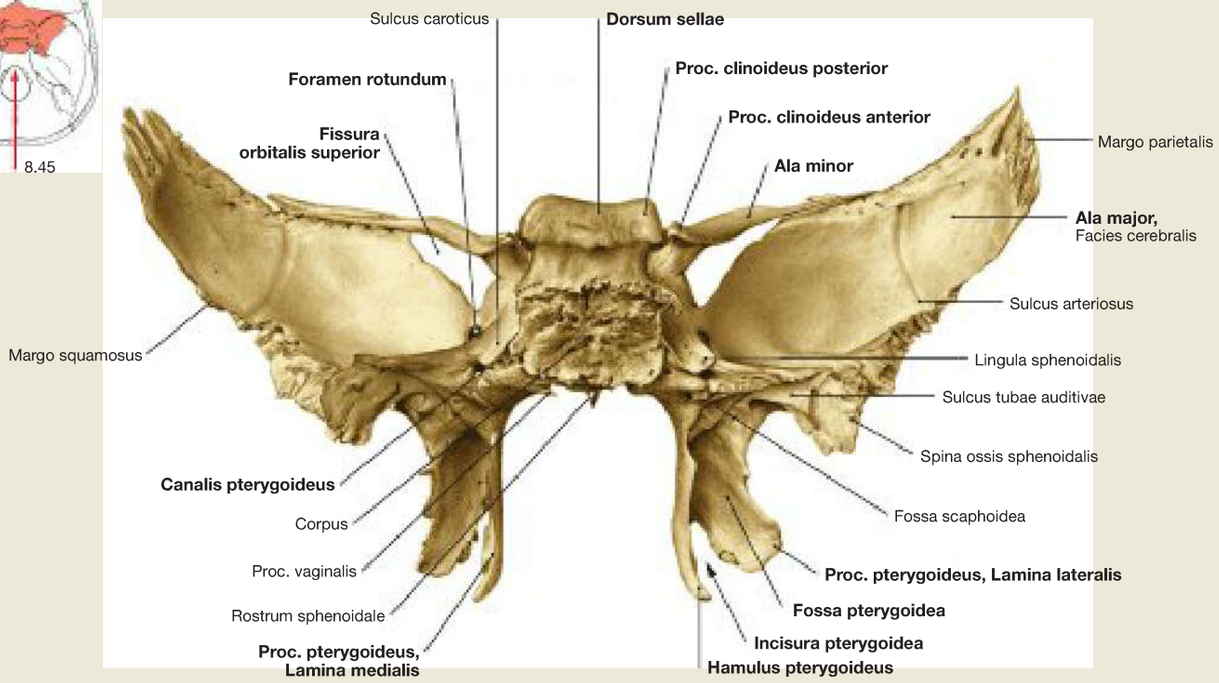

Fig. 8.45 Sphenoidal bone, Os sphenoidale; posterior view.
The Ala minor and Ala major of the Os sphenoidale border the **Fissura orbitalis superior.** The Proc. pterygoideus is divided on each side into a smaller Lamina medialis and a larger Lamina lateralis, which between them enclose the Fossa pterygoidea and are separated by the **Incisura (Fissura) pterygoidea.** The Lamina medialis continues caudally into the **Hamulus pterygoideus.** At its base, the Canalis pterygoideus pierces the Os sphenoidale and opens into the Fossa pterygopalatina.

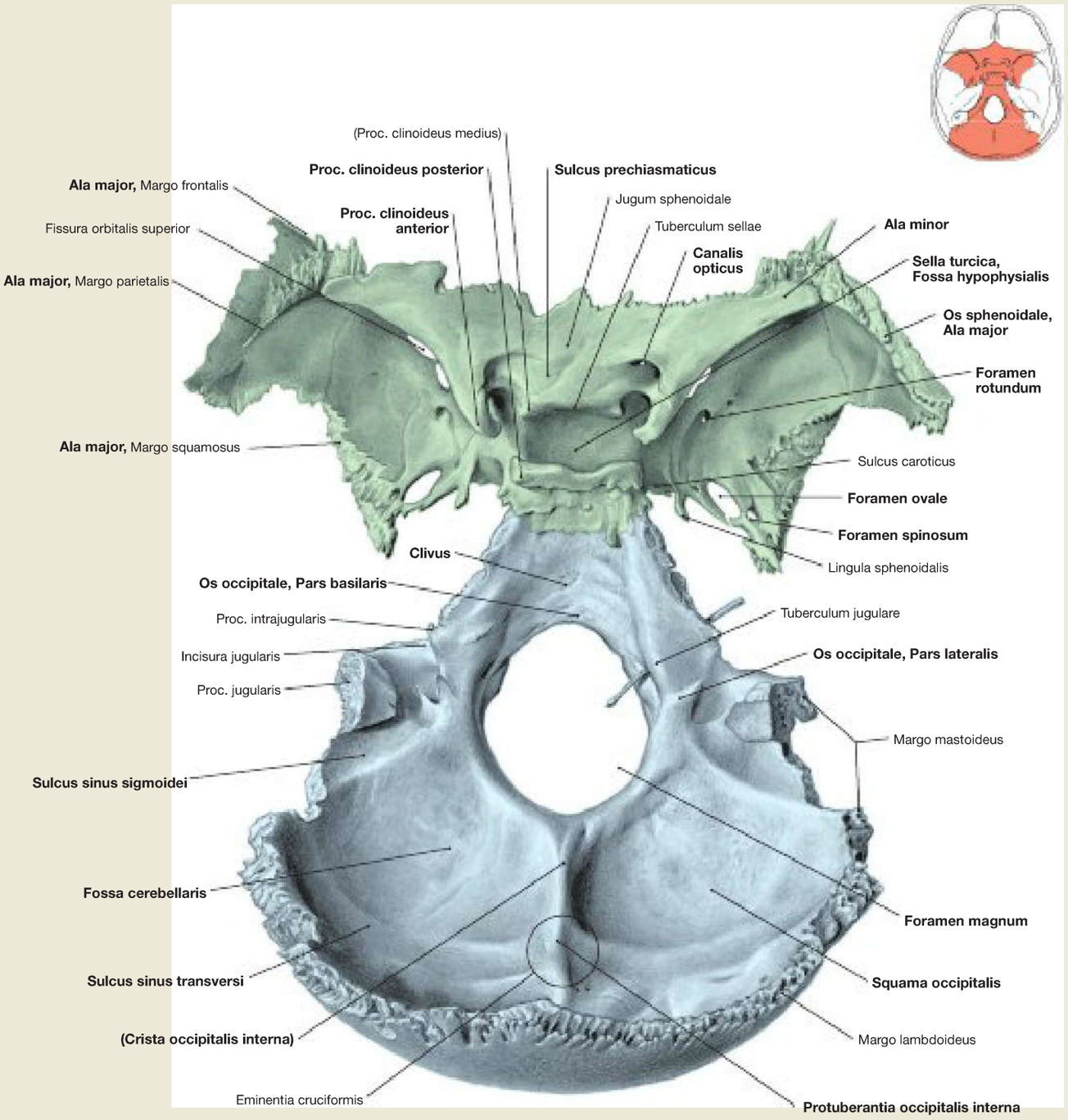

Fig. 8.46 Sphenoidal bone, Os sphenoidale, and occipital bone, Os occipitale; view from above; for colour chart see p. VIII.
The centre of the **Os sphenoidale** is composed of the Sella turcica with the Fossa hypophysialis. The Tuberculum sellae, which laterally continues the middle clinoid process on each side, forms the anterior margin of the Fossa hypophysialis. The Sulcus prechiasmaticus and the Jugum sphenoidale are located in front of the Tuberculum sellae. The clivus forms the posterior portion of the Sella turcica, of which the upper edge is laterally raised to the Proc. clinoideus posterior. The Ala minor is pierced at its anterior margin by the Canalis opticus in the area of the Sella turcica. The Foramina rotundum, ovale, and spinosum pierce the Ala major bilaterally in an anterior cranial to posterior caudal direction.

The unpaired **Os occipitale** consists of the Squama occipitalis with two Partes laterales and a Pars basilaris. These four parts delimit the **Foramen magnum.** On the inner surface of the Squama occipitalis, the Sulcus sinus sagittalis superioris and the grooves of the Sinus transversi meet at the Protuberantia occipitalis interna. In addition, the Sulcus sinus sigmoidei and the Sulcus sinus occipitalis can also be seen on the inner surface on the right and left. Above and below the Protuberantia occipitalis, the inner surface of the Squama occipitalis forms the Fossa cerebralis and the Fossa cerebrellaris, respectively. Together with the Corpus of the Os sphenoidale, the Pars basilaris of the Os occipitale generates the Clivus.

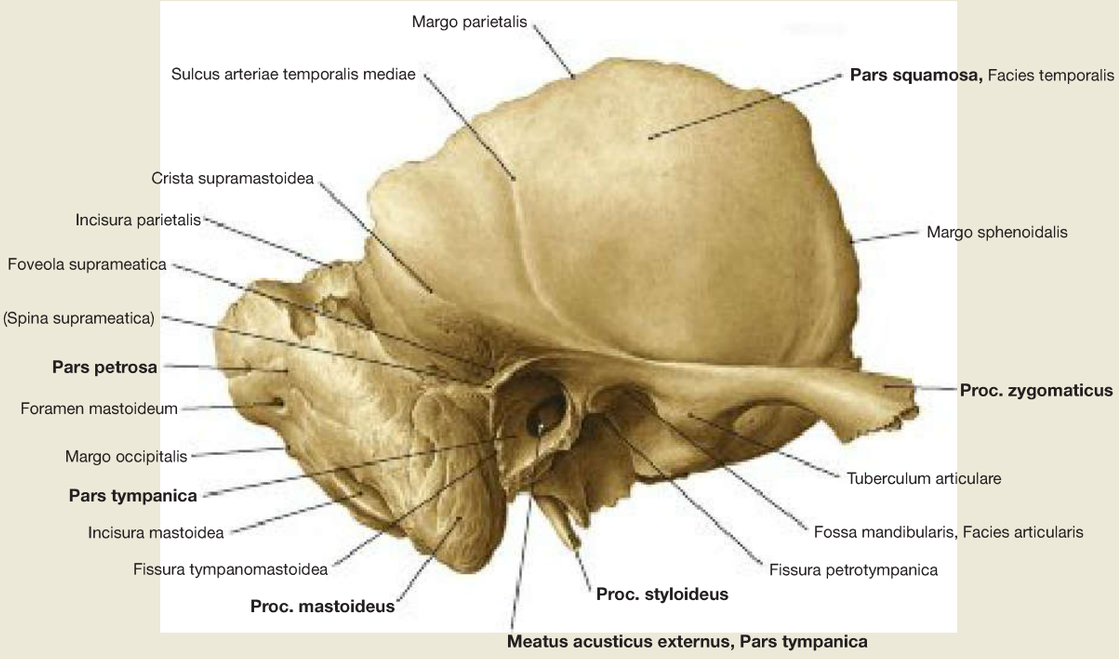

Fig. 8.47 Temporal bone, Os temporale, right side; lateral view.
The paired Os temporale belongs to both the neurocranium and the viscerocranium. It is part of the lateral wall and the base of the cranium. A distinction is made between the Pars squamosa, the Pars tympanica and the Pars petrosa.
The **Pars squamosa,** which is scale-like, borders the Os parietale on the Margo parietalis. In front and above the meatus, the Proc. zygomaticus protrudes and is directed forward.
The **Pars petrosa** borders the Ossa parietale and occipitale. Its central outer opening is the Meatus acusticus externus. Located at its posterior caudal aspect is the Proc. mastoideus. Middle and inner ear are located within the Pars petrosa (not visible). Access routes are the internal acoustic meatus (Meatus acusticus internus, → p. 20), the Foramen stylomastoideum (→ p. 21) and the Canalis musculotubarius (→ Fig. 10.29 and → Fig. 10.40).
The **Pars tympanica** forms the bony wall of the external acoustic meatus. It is a ring-shaped structure lying on the Partes squamosa and petrosa. The Pars tympanica borders the Meatus acusticus externus at its frontal, caudal, and posterior sides and extends to the tympanic membrane (→ Fig. 10.15 and → Fig. 10.23).

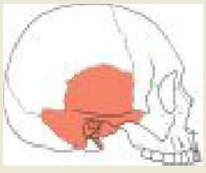

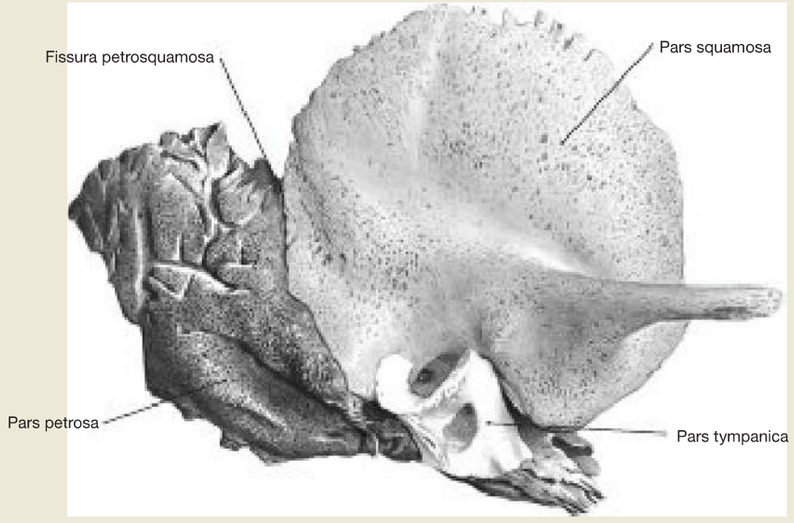

Fig. 8.48 Temporal bone, Os temporale, of a newborn, right side; lateral view; schematic representation; for colour chart see p. VIII.
The illustration shows the different parts of the Os temporale: Pars squamosa, Pars petrosa and Pars tympanica.

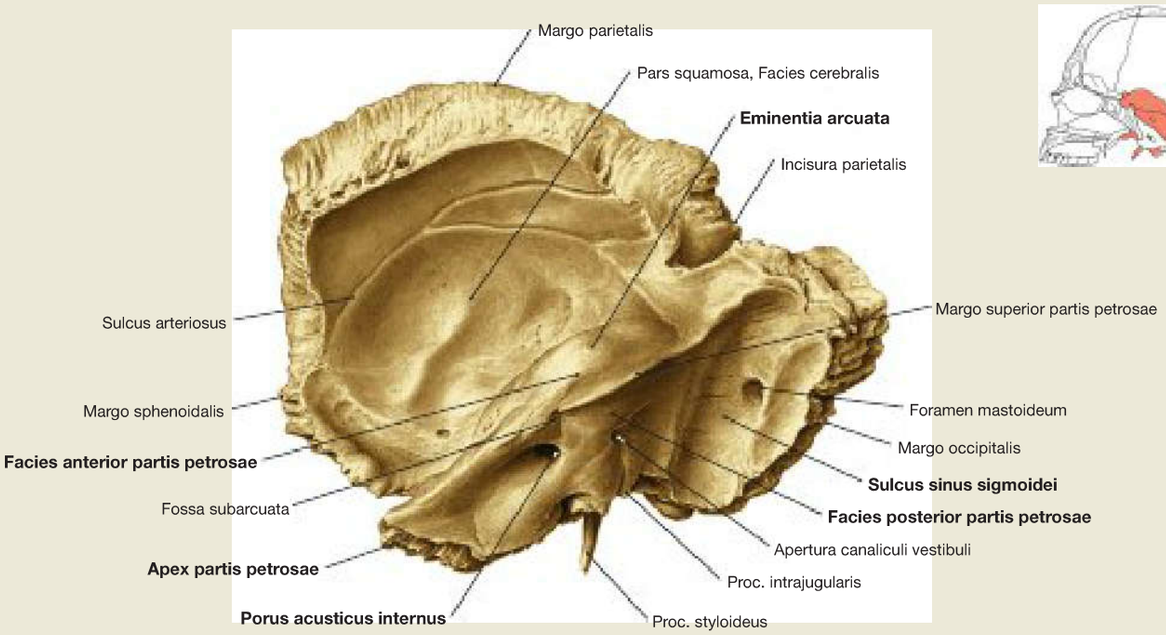

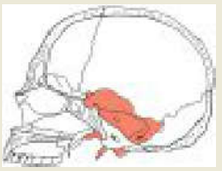

Fig. 8.49 Temporal bone, Os temporale, right side; inner aspect. The Pars petrosa is shaped like a pyramid, the tip of which (Apex partis petrosae) is aligned medially forwards and the base of which is facing the Proc. mastoideus. The Facies anterior is directed towards the middle cranial fossa, and protrudes as Eminentia arcuata; in the Facies posterior, the **Porus acusticus internus** is the entrance to the Meatus acusticus internus. The Facies posterior of the Pars petrosa is deepened by the Sulcus sinus sigmoidei. This is also where the **Foramen mastoideum** is found. On the inside (Facies cerebralis) of the Pars squamosa, you can see the Sulci arteriosi of the A. meningea media.

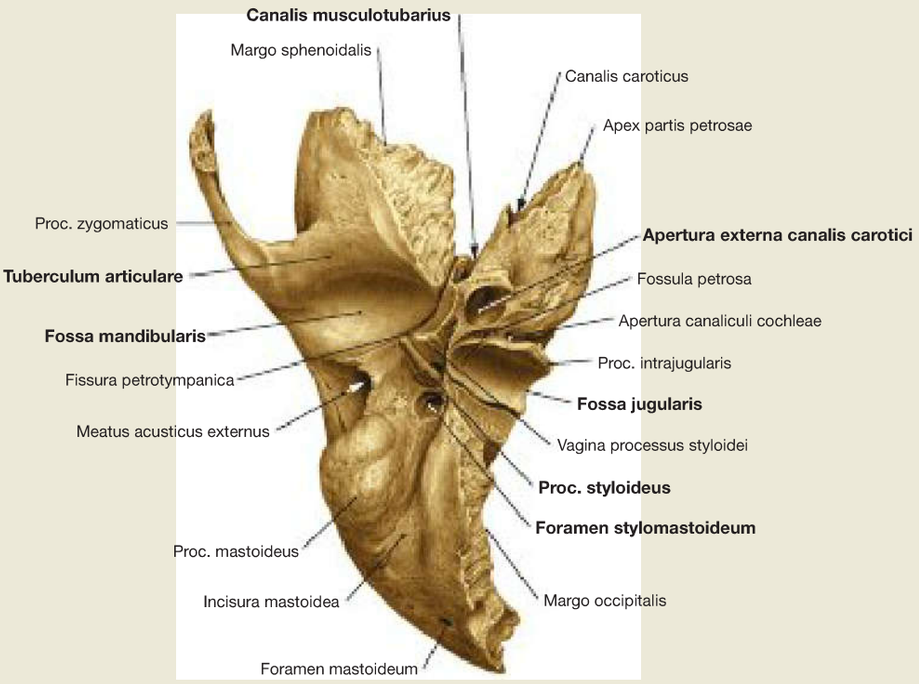

Fig. 8.50 Temporal bone, Os temporale, right side; inferior view. The Facies inferior of the Os temporale deepens towards the **Fossa jugularis,** which borders the Foramen jugulare together with the Os occipitale. At the notch (Incisura) between the Pars squamosa and the Pars petrosa, the Canalis musculotubarius begins. In addition, you can see the Apertura externa canalis carotici and the Proc. styloideus. The **Foramen stylomastoideum** opens to the lateral posterior side. Just before the external ear canal, the Pars squamosa forms the **Fossa mandibularis,** which is rostrally surrounded by the Tuberculum articulare.

Mandible

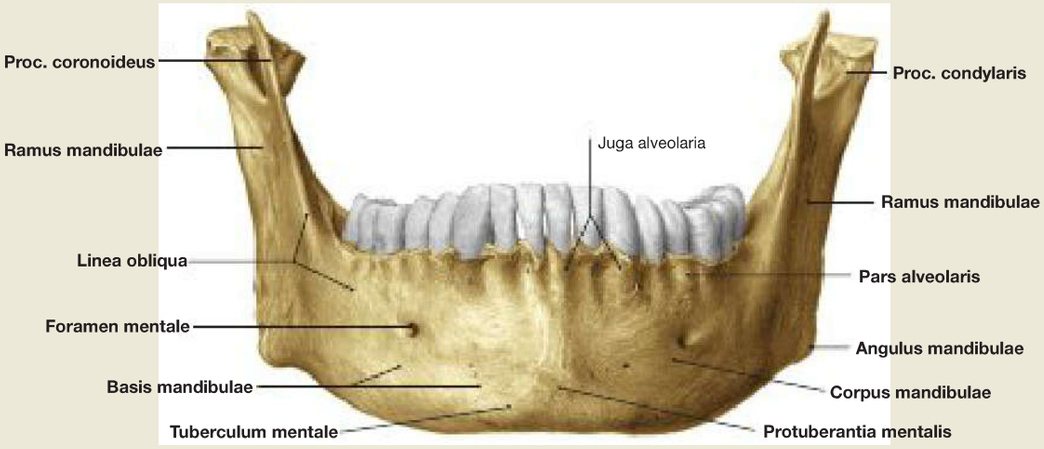

Fig. 8.51 Mandible, Mandibula; frontal view.
The unpaired Mandibula consists of a body (Corpus mandibulae) and two rami (Rami mandibulae). Each ramus divides into a **Proc. coronoideus** and a **Proc. condylaris.** The Corpus mandibulae consists of the Basis and the Pars alveolaris, which are separated from the Proc. coronoideus by the Linea obliqua descending obliquely towards the front. At the front of the Pars alveolaris is the chin (Menta) with the Protuberantia mentalis, the bilateral tubercles of the chin (Tubercula mentalia) and the Foramina mentalia.

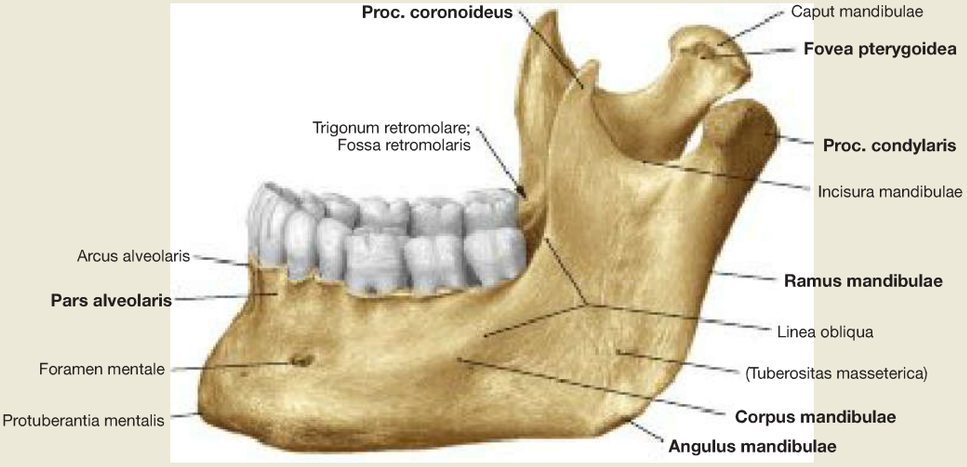

Fig. 8.52 Mandible, Mandibula; lateral view. Corpus mandibulae and Ramus mandibulae merge at the Angulus mandibulae.
The Proc. condylaris carries the **Caput mandibulae.**

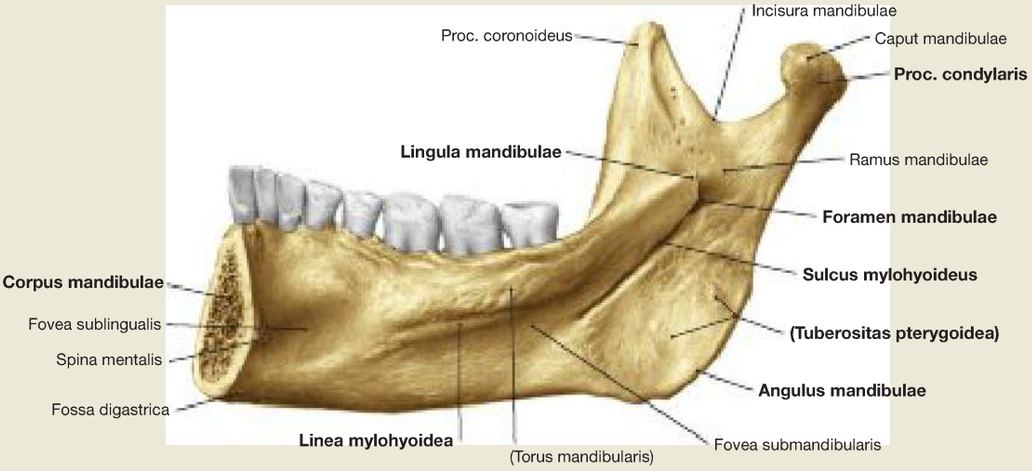

Fig. 8.53 Mandible, Mandibula; inner aspect of the mandibular arch.
The **Foramen mandibulae** is located on the inner surface of the Ramus mandibulae. In front of the foramen, the **Linea mylohyoidea** forms a 'terraced' ledge, which serves as the point of attachment for the M. mylohyoideus and which marks the level of the floor of the mouth.

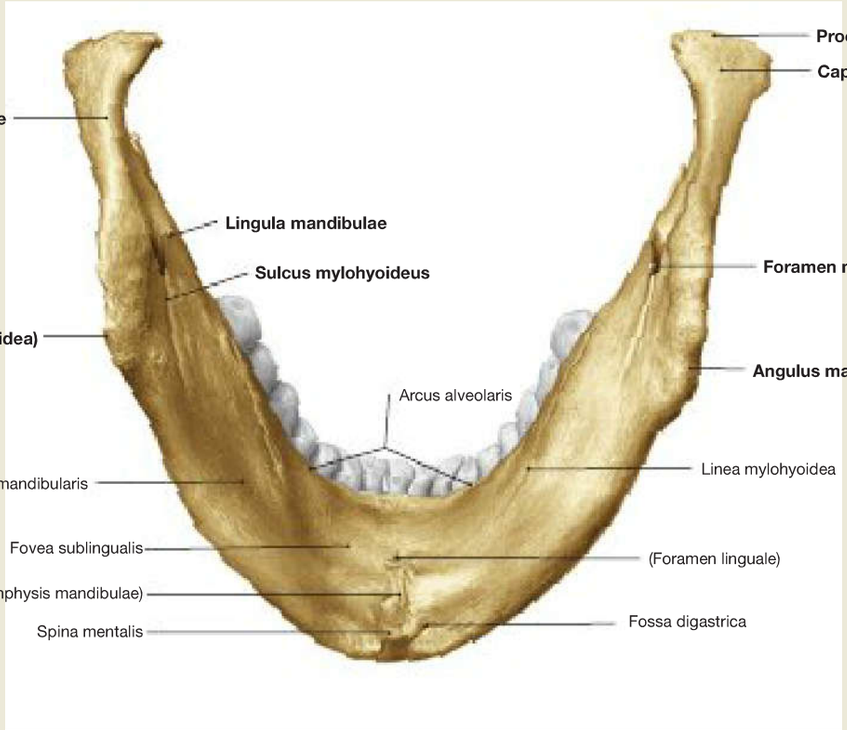

Fig. 8.54 Mandible, Mandibula; inferior view.
The Spina mentalis is located at the inside of the Mandibula close to the midline. Laterally and below this, the bone deepens into the Fossa digastrica, and above the Spina mentalis into the Fovea sublingualis and the Fovea submandibularis on each side. On the inside of the Angulus mandibulae the **Tuberositas pterygoidea** is found.

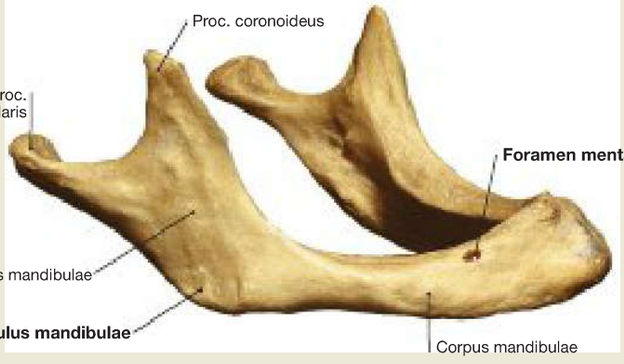

Fig. 8.55 Mandible, Mandibula, of an old man.
Loss of teeth – particularly in an advanced age – results in a **regression of the Pars alveolaris** of the Mandibula. This can progress until the Foramen mentale becomes located at the upper edge of the toothless Mandibula. The **Angulus mandibulae** of a toothless jaw is much wider than with dentition.

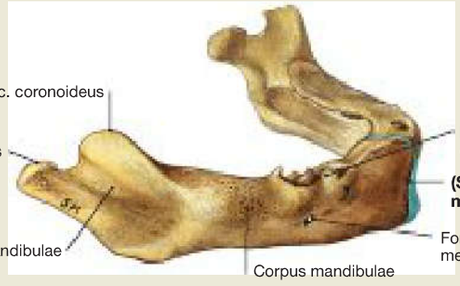

Fig. 8.56 Mandible, Mandibula, of a newborn. [L238]
In newborns, the two mandibular segments are still connected via the **Symphysis mandibulae.** The angle between the Corpus and Ramus mandibulae is still very large.

Clinical Remarks

After fractures of the nose, also fractures of the mandible frequently occur due to its exposed position. The U-shaped form explains why various types of mandibular fractures can happen, in particular at the level of the canines and the third molar teeth. Extravasated blood from the Mandibula collects in the loose tissue of the floor of the mouth, resulting in small spotted bleeding under the skin (ekchymoses), which is a typical sign of a mandibular fracture.

Without any replacement of lost teeth, the **tooth loss** will lead to degeneration of the Pars alveolaris mandibulae in the affected area. Adjustment of a dental prosthesis is very challenging in the case of a largely regressed Pars alveolaris and often only successful after reconstructing the bone structure.

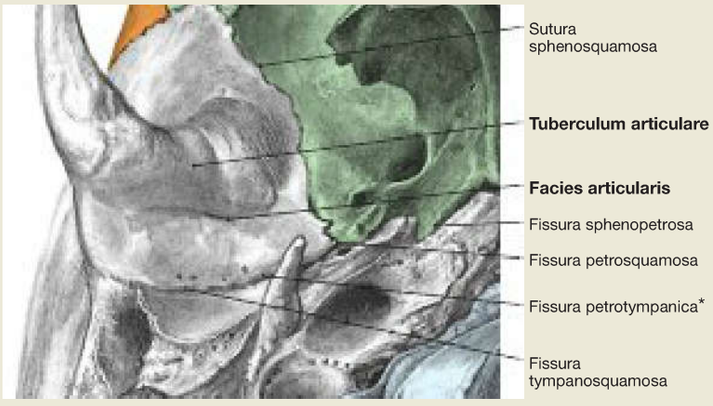

Fig. 8.57 Glenoid fossa and articular protrusion of the temporomandibular joint, Articulatio temporomandibularis, right side; inferior view. For colour chart see p. VIII.
The illustration shows the Facies articularis of the Fossa mandibularis, which is normally coated with hyaline articular cartilage. At the front is the Tuberculum articulare, which is likewise coated with hyaline cartilage (tubercle slope). In the posterior third of the Fossa mandibularis, the Pars squamosa is connected with the Pars petrosa of the Os temporale, and the Os temporale is medially adjacent to the Os sphenoidale. **Three fissures** exist in this area:

- Laterally and externally, the Fissura tympanosquamosa can be seen.
- In the middle lies the Fissura petrotympanica (* GLASERIAN fissure).
- Medially runs the Fissura sphenopetrosa, from which the Chorda tympani leaves the cranial base.

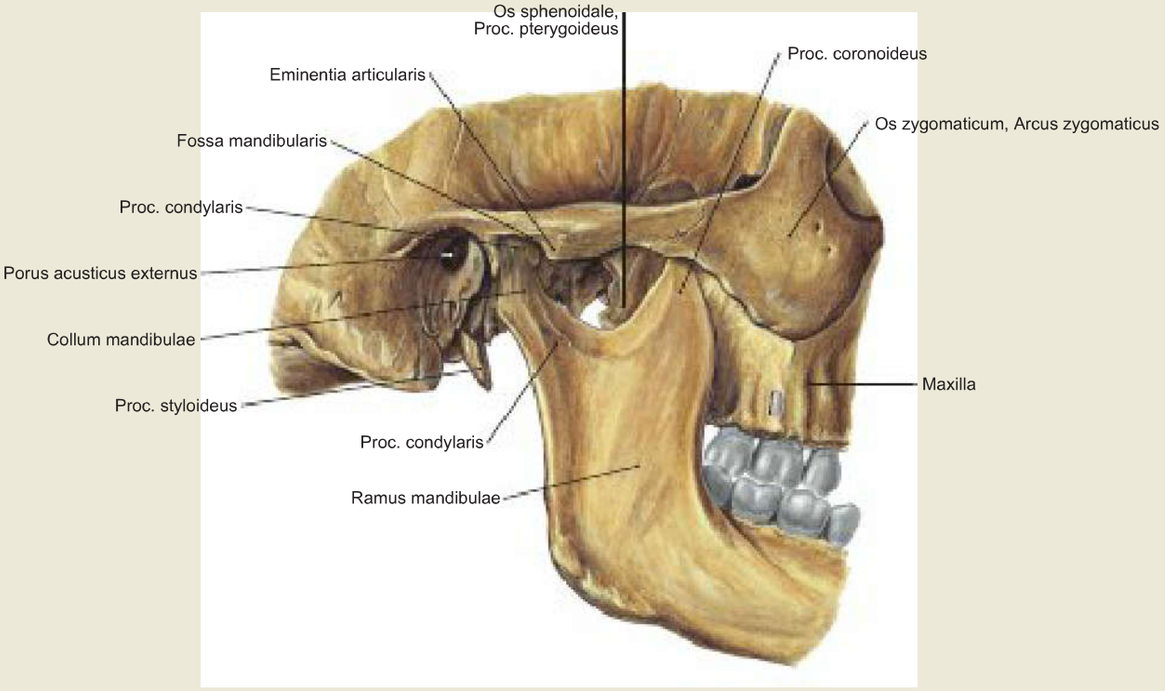

Fig. 8.58 Temporomandibular joint, Articulatio temporomandibularis, right side; lateral view.
The Proc. condylaris of the Mandibula is located in the Fossa mandibularis of the Os temporale. In front of the condyle is the Eminentia articularis, and behind it, the bony part of the Meatus acusticus externus. Above the Fossa mandibularis is the middle cranial fossa.

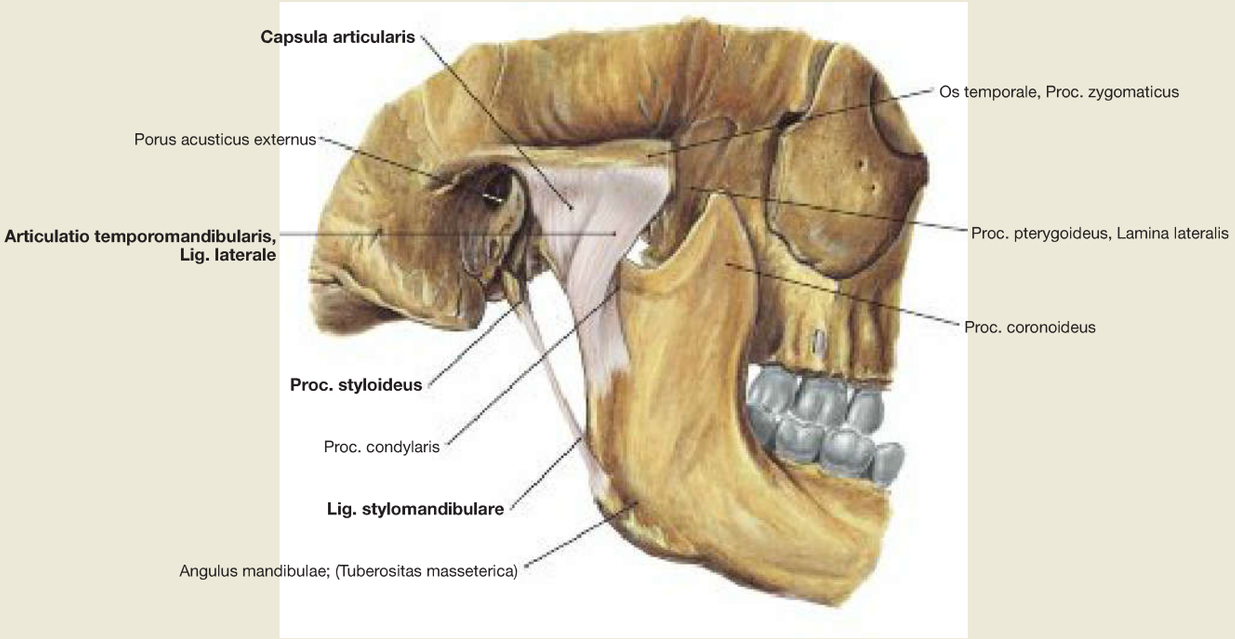

Fig. 8.59 Temporomandibular joint, Articulatio temporomandibularis, right side; lateral view.
The temporomandibular joint is enclosed by a wide joint capsule (Capsula articularis), that extends in a funnel-shaped manner from the Os temporale to the Proc. condylaris. The joint capsule is reinforced laterally and anterior by the Lig. laterale, which runs obliquely downwards from the Arcus zygomaticus to the Collum mandibulae. At the inside of the joint (not shown), connective tissue generates the variable Lig. mediale. The Lig. laterale and Lig. mediale (insofar as they are formed) are involved in the articulation and inhibit marginal movements, particularly backwards. The Lig. laterale also stabilises the condyle on the working side. From the Proc. styloideus, the **Lig. stylomandibulare** runs to the posterior rim of the Ramus mandibulae. It is usually weak and, together with the **Lig. sphenomandibulare,** resists further movements of the lower jaw at a position close to the maximal opening of the mouth (→ Fig. 8.60).

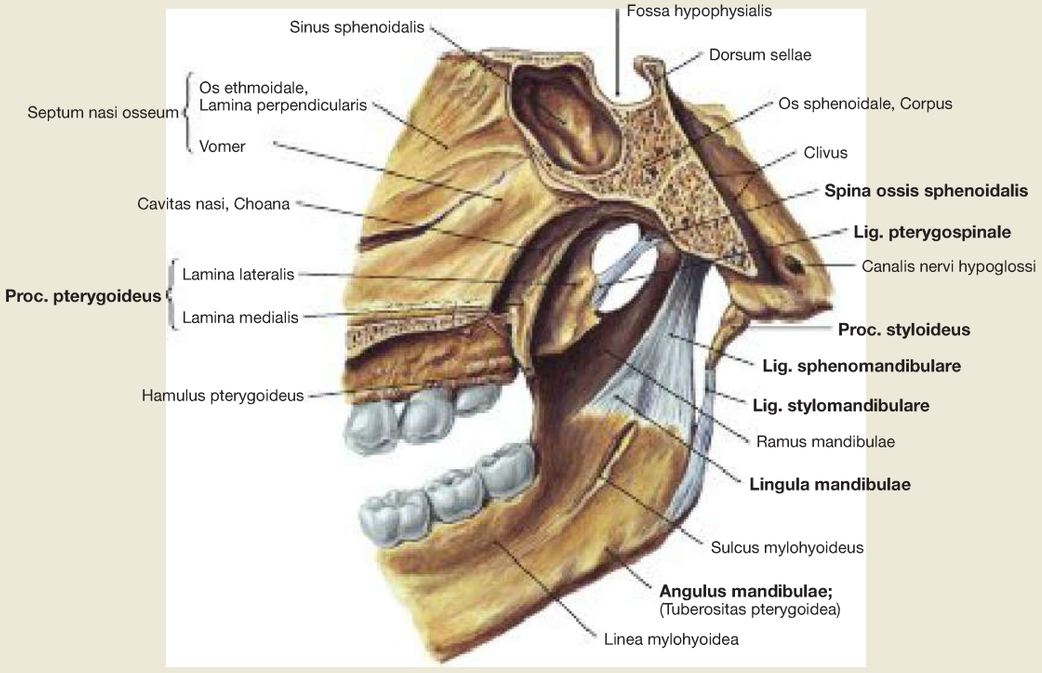

Fig. 8.60 Lig. stylomandibulare and Lig. sphenomandibulare, right side; medial view.
Both ligaments affect the **kinematics** of the Articulatio temporomandibularis but are not associated with the joint capsule.
The powerful **Lig. sphenomandibulare** originates at the Spina ossis sphenoidalis and runs between the Mm. pterygoidei lateralis and medialis to the Lingula mandibulae. Here it inserts in a fan-shaped manner above the Foramen mandibulae. The **Lig. stylomandibulare** coming from the Proc. styloideus inserts at the Angulus mandibulae. Together, both ligaments inhibit **movements** of the lower jaw close to the end or maximal opening position of the mouth.
Without a connection to the temporomandibular joint and without any impact on its kinematics, the **Lig. pterygospinale** runs from the Spina ossis sphenoidalis to the Lamina lateralis of the Proc. pterygoideus. This ligament has a **stabilising** function.

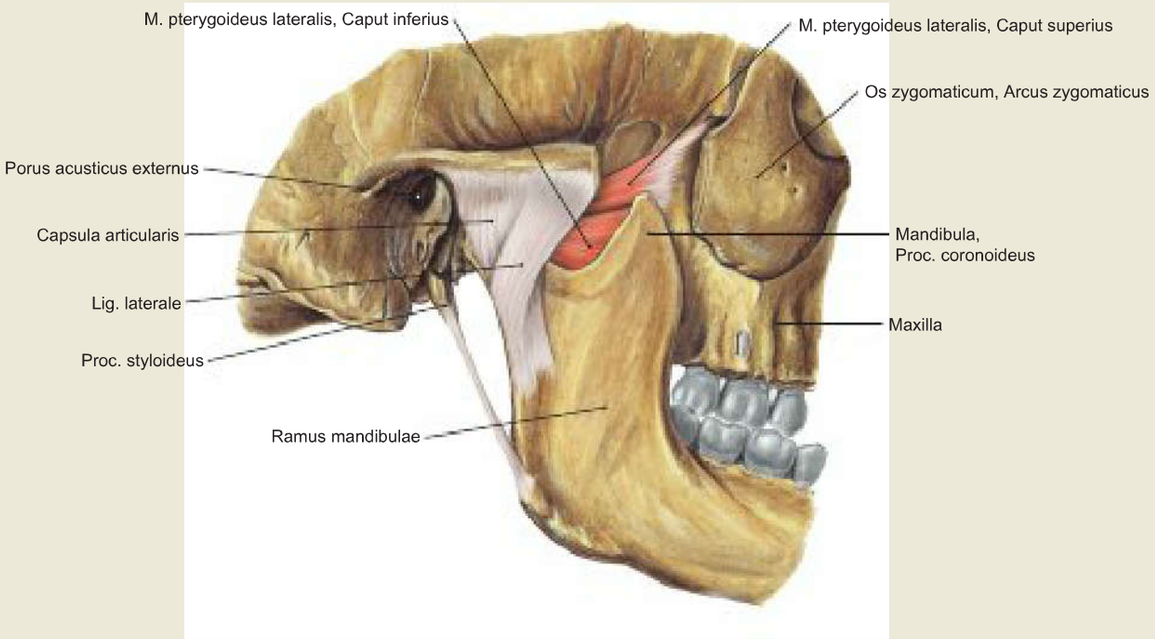

Fig. 8.61 Temporomandibular joint, Articulatio temporomandibularis, right side; lateral view.
The M. pterygoideus lateralis is connected directly to the temporomandibular joint. Its two muscular parts run towards the anterior portion of the joint capsule. They are located medially behind the Lig. laterale.

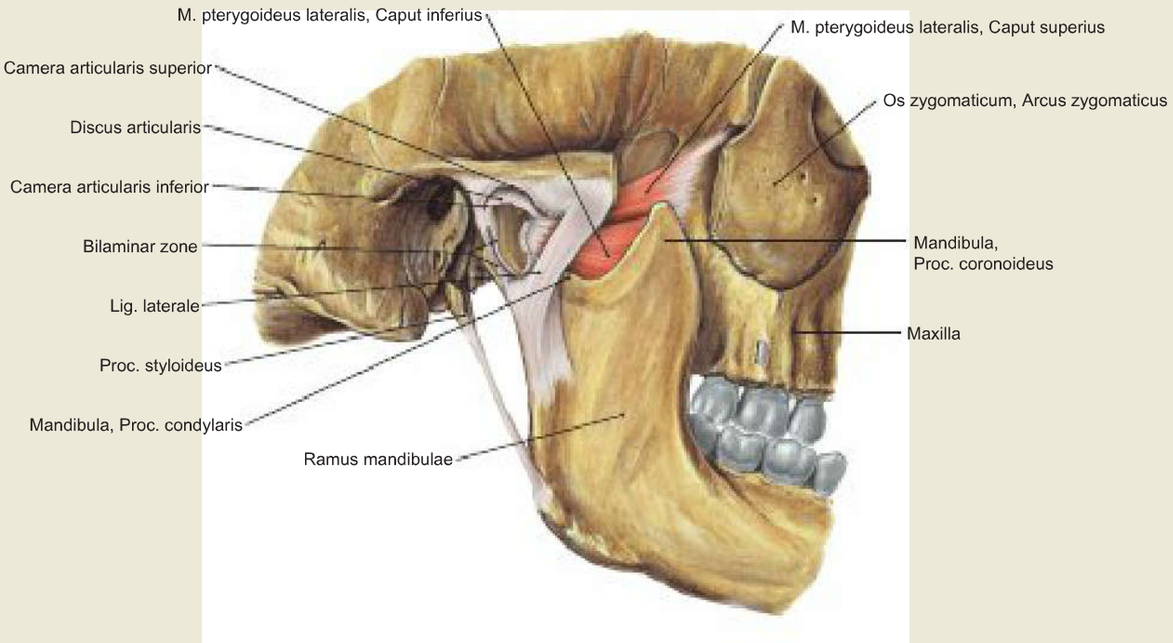

Fig. 8.62 Temporomandibular joint, Articulatio temporomandibularis, right side; lateral view; after partial removal of the lateral part of the capsule, as well as parts of the Lig. laterale.
The Caput superius of the M. pterygoideus lateralis, which originates from the Ala major of the Os sphenoidale, penetrates the anterior part of the joint capsule of the Articulatio temporomandibularis above the Pars inferior. It inserts into the Discus articularis of the Articulatio temporomandibularis, as well as into the Proc. condylaris. The Caput inferius of the M. pterygoideus lateralis originates at the outer surface of the Lamina lateralis of the Proc. pterygoideus of the Os sphenoidale, and penetrates the joint capsule from the front beneath the tendon of the Caput superius of the M. pterygoideus lateralis, and inserts completely into the Proc. condylaris.

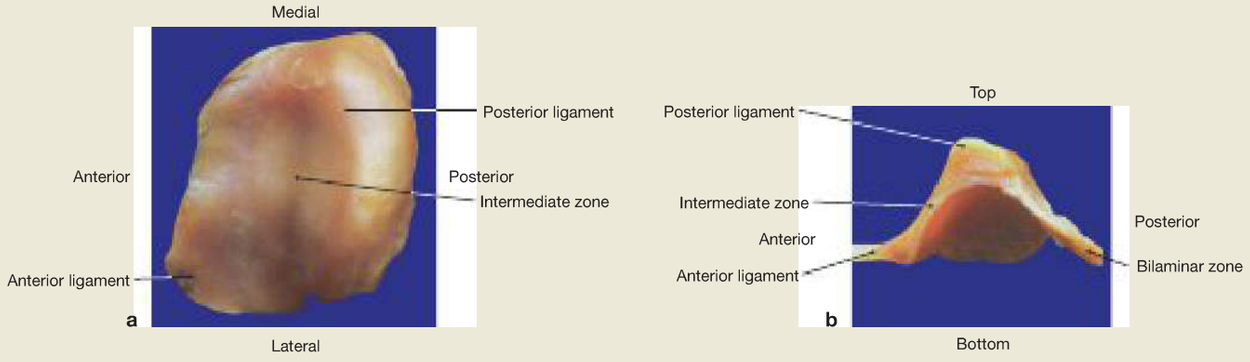

Fig. 8.63a and b Articular disc, Discus articularis, of the Articulatio temporomandibularis.
a View from above
b Lateral view

From front to back, the Discus articularis consists of an anterior ligament (connective tissue), an intermediate zone (fibrous cartilage), a posterior ligament (connective tissue), and a bilaminar zone (connective tissue). The intermediate zone is particularly thin in the lateral portion. The Discus articularis is fused on all sides with the joint capsule.

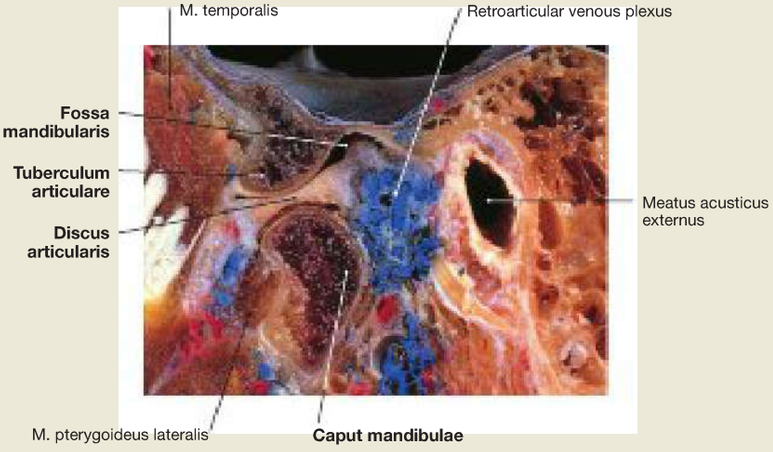

Fig. 8.64 Temporomandibular joint, Articulatio temporomandibularis; sagittal section through the joint area with injected veins; lateral view. [S010-1-17]
You can recognise the bilaminar zone between the Tuberculum articulare and Caput mandibulae. The bone between the middle cranial fossa and the Fossa mandibularis is thin. Between the tracts of connective tissue in the bilaminar zone lies a distinct **retroarticular venous plexus.** There is a close relationship to the external acoustic meatus (Meatus acusticus externus).

Clinical Remarks

A violent impact on the Mandibula often leads to **fractures of the Collum mandibulae.** These intra- or extracapsular fractures can occur, with or without dislocation. In addition, bleeding from the retroarticular venous plexus (→ Fig. 8.64) can occur, leading to painful sensations from the Meatus acusticus externus.

Since the Articulatio temporomandibularis is a diarthrosis, the same conditions as those found in the large joints of the limbs can occur, e.g. osteoarthritis or rheumatoid arthritis. An **osteoarthritis of the Articulatio temporomandibularis** will result preferably in defects in the lateral part of the Discus articularis.

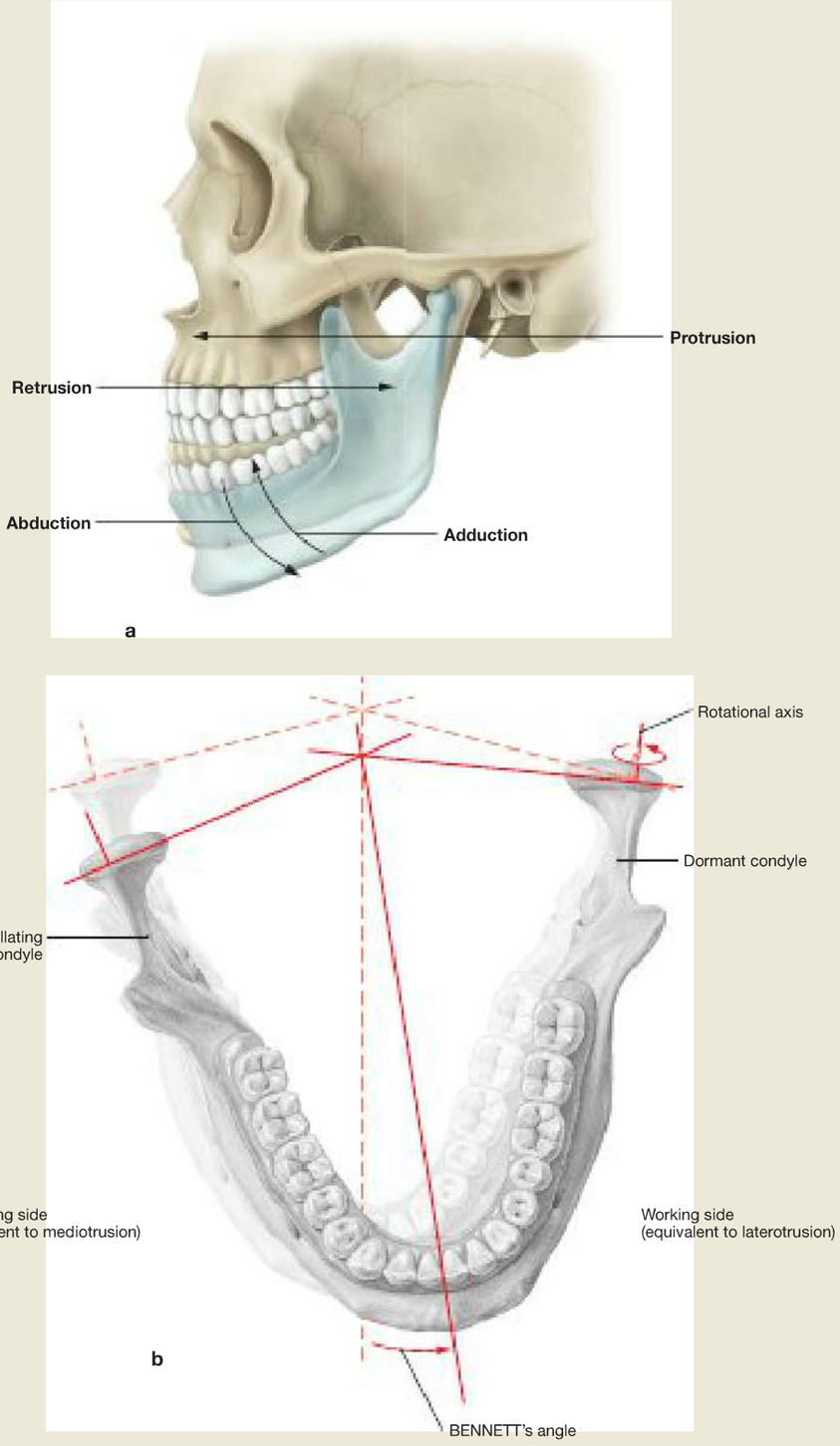

Fig. 8.65a and b Movements of the temporomandibular joint, Articulatio temporomandibularis; lateral view from the left **(a); grinding movements of the Mandibula in the left temporomandibular joint;** view from above **(b).** a [L275], b [L127]

a Independent movements in one of the joints are not possible because both temporomandibular joints are linked via the Mandibula. The temporomandibular joints permit two main functions during chewing: elevation **(adduction)** and depression **(abduction)** of the lower jaw as well as grinding movements. In addition to abduction and adduction, the forward **(protrusion)** and backward movement **(retrusion)** as well as grinding movements (sideways sliding **– laterotrusion and mediotrusion)** constitute the movement patterns of the Articulatio temporomandibularis. The masticatory muscles are involved differently in the movements.

b The Articulatio temporomandibularis is a bicondylar joint; movements on one side always affect the other side. In the case of grinding movements, the dormant **condyle** (shown here on the left = the **working side**) rotates around an almost vertical axis through the Caput mandibulae, while the **oscillating condyle** (shown here on the right = the **balancing side**) oscillates forwards and medially at the same time (translation movement). The **BENNETT's angle** describes the extent (amplitude) of the mandibular oscillation. On the working side, the Mandibula performs a laterotrusion, and on the balancing side, a mediotrusion.

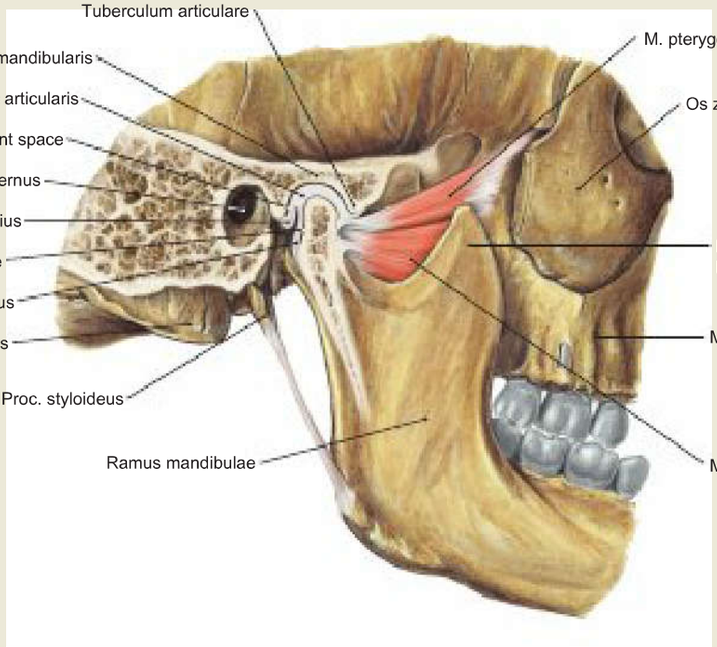

Fig. 8.66 Temporomandibular joint, Articulatio temporomandibularis, right side; sagittal section, lateral view.
When the mouth is closed with intercuspidating rows of teeth (resting position), the Proc. condylaris with the Discus articularis is located in the Fossa mandibularis. Since the Discus articularis is fused on all sides with the joint capsule, a larger superior joint chamber (between Fossa mandibularis and Discus), and a smaller inferior joint chamber (between Discus and Proc. condylaris) form. Therefore, it is called a bithalamic joint (consisting of two chambers). At the posterior aspect, you can recognise the superior (Stratum superius) and the inferior (Stratum inferius) ligaments of the bilaminar zone of the Discus articularis. The Stratum superius is short and stretchy. It runs to the Fissurae petrotympanica and tympanosquamosa and has a close relationship with the Chorda tympani of the N. facialis [VII] (→ Fig. 8.94). The tighter Stratum inferius inserts much further below and behind between the Caput and Collum mandibulae.

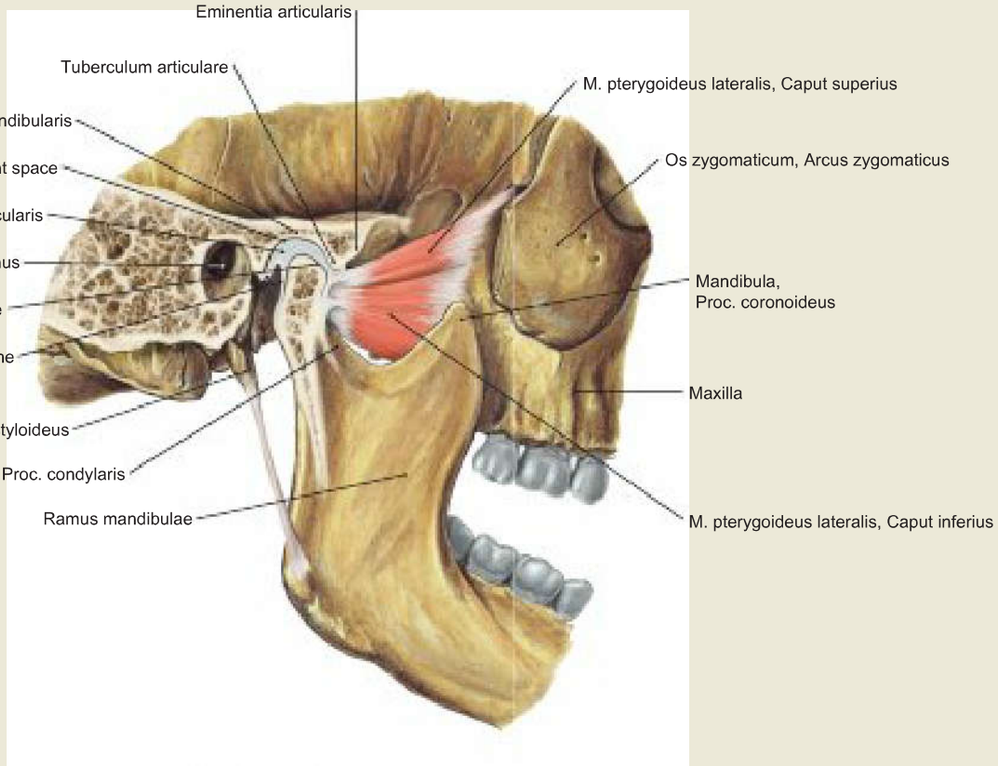

Fig. 8.67 Temporomandibular joint, Articulatio temporomandibularis, right side; sagittal section, lateral view.
With the mouth opening up to 15°, rotation of the condyle occurs around its transverse axis. Through the tension of the Lig. laterale, and the traction of the Caput superius of the M. pterygoideus lateralis, the condyle is also drawn forwards onto the Tuberculum articulare (tubercle slope) when the mouth is opened more than 15°.

Temporomandibular Joint, X-Ray Images

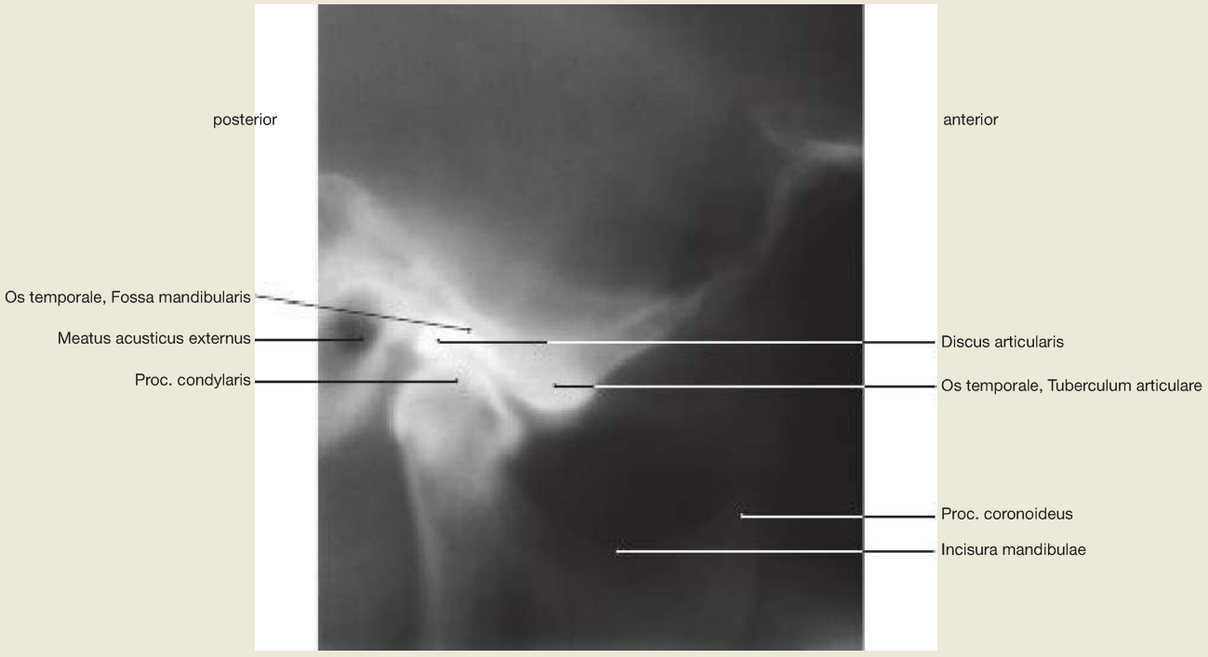

Fig. 8.68 Temporomandibular joint, Articulatio temporomandibularis; X-ray in lateral beam projection; mouth closed. [T905]

With a closed mouth and relaxed masticatory muscles, the Proc. condylaris lies in the Fossa mandibularis.

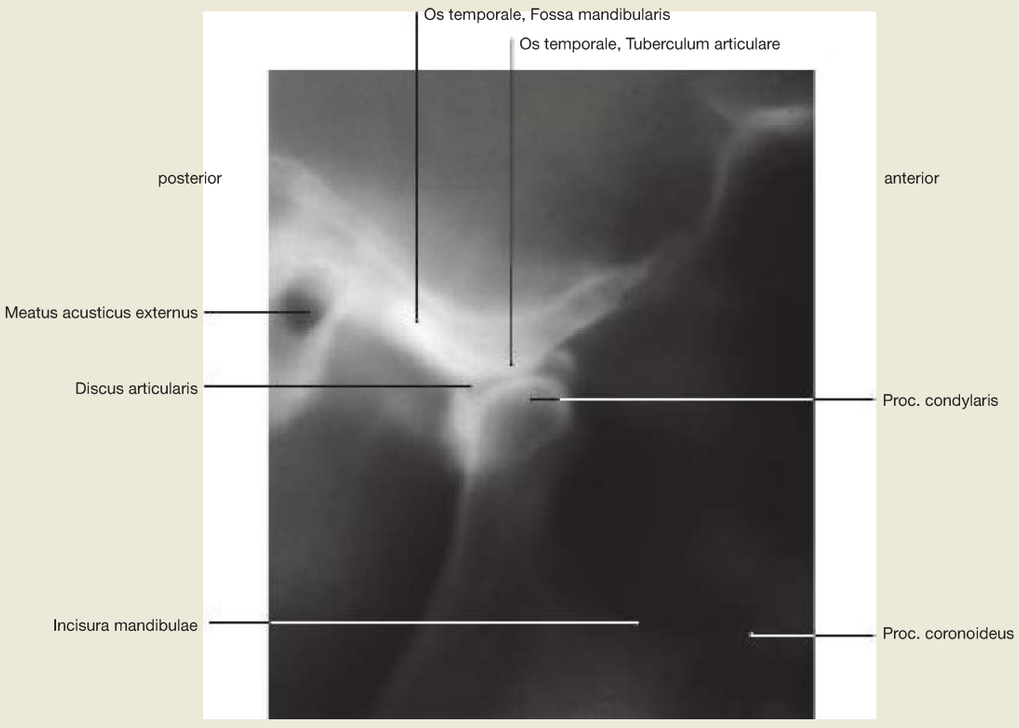

Fig. 8.69 Temporomandibular joint, Articulatio temporomandibularis; X-ray in lateral beam projection; mouth open. [T905]

With an open mouth, the Discus articularis and the Proc. condylaris will slide forward onto the Tuberculum articulare.

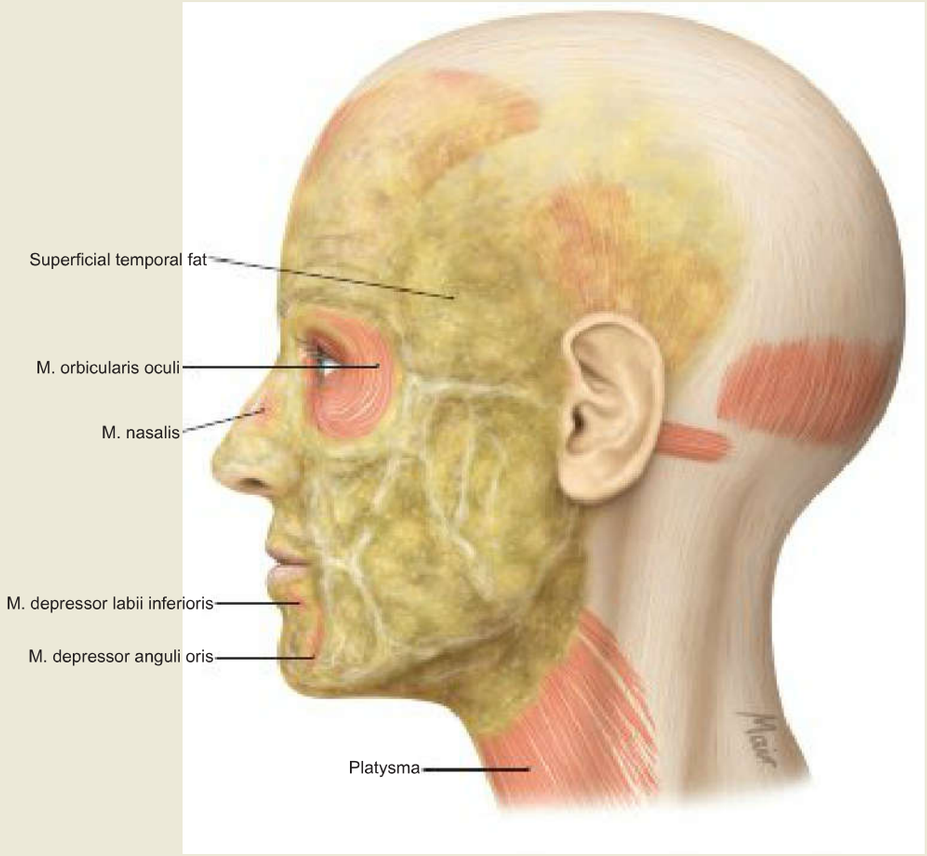

Fig. 8.70 Subcutaneous fat layer of the face; lateral view. [L127]
After removal of the facial skin, the distribution of the superficial subcutaneous fat layer can be seen. The shaping of the adipose tissue varies greatly in each individual and depends highly on the nutritional status; it adds to the individuality of the face. Only on the M. orbicularis oculi and in the region of the nose there is barely any subcutaneous fat. The adipose tissue is divided by connective tissue septa into compartments (→ Fig. 8.71). The connective tissue septa are stretched out between the skin, the loose connective tissue, the mimetic muscles and the 'superficial muscular aponeurotic system' (SMAS), which consists of the fasciae of the Glandula parotidea (Fascia parotidea), of the M. masseter (Fascia masseterica), of the M. buccinator (Fascia buccopharyngea) and of the M. temporalis (Fascia temporalis), forming a layer of remarkable tensile strength. The SMAS extends up to the scalp.
Based on: Radlanski, R. J./Wesker, K. H.: Das Gesicht. Bildatlas klinische Anatomie. 2. Auflage. KVM, 2012

Compartments

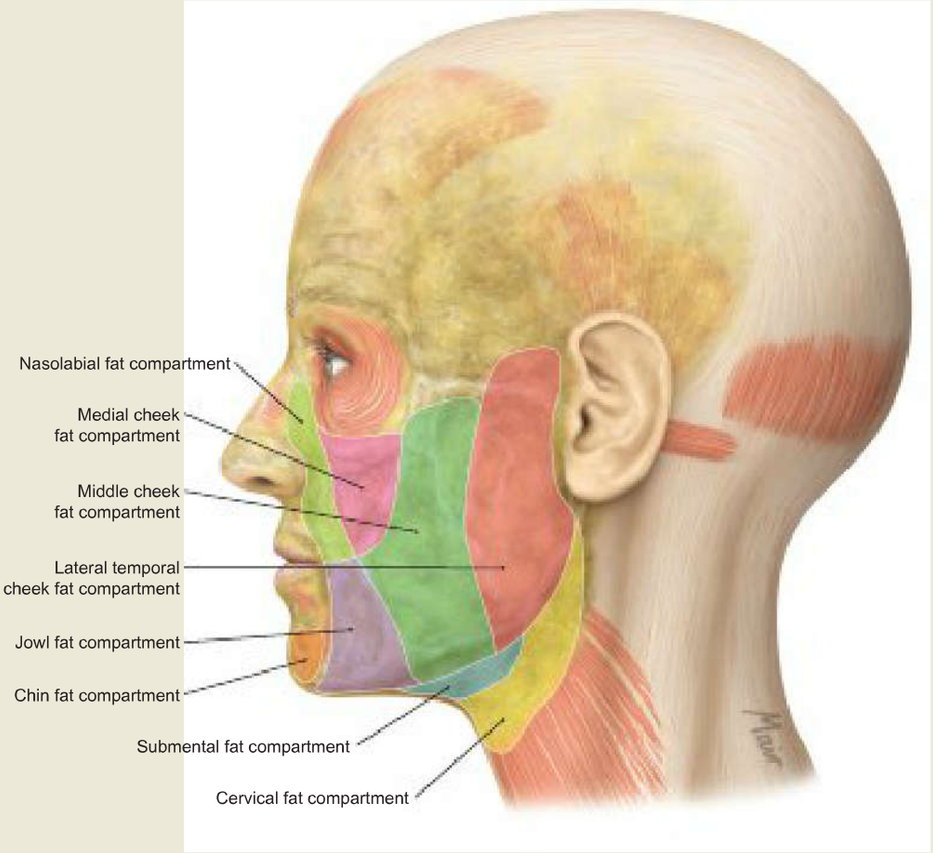

Fig. 8.71 Subcutaneous fat compartments; lateral view. [L127]
Presentation of the topography of the connective tissue septa of the 'superficial muscular aponeurotic system' (SMAS) as well as coloured representation of the various subcutaneous fat compartments underneath the Arcus zygomaticus.

Based on: Radlanski, R. J./Wesker, K. H.: Das Gesicht. Bildatlas klinische Anatomie. 2. Auflage. KVM, 2012

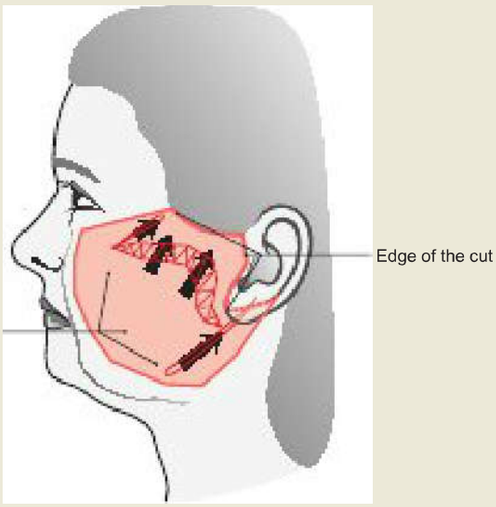

Fig. 8.72 Face lift. [L126]

Clinical Remarks

The **SMAS (superficial muscular aponeurotic system)** is crucial in plastic surgery for **face lifts** (rhytidectomy). Via an arc-shaped incision in front of the auricle, the SMAS can be dissected and detached from the surrounding structures. A customised cut of the part close to the ear can be made to reduce it, and the edge of the cut can be sewn up again by pulling it towards the auricle. In this way the facial skin is tightened (→ Fig. 8.72).

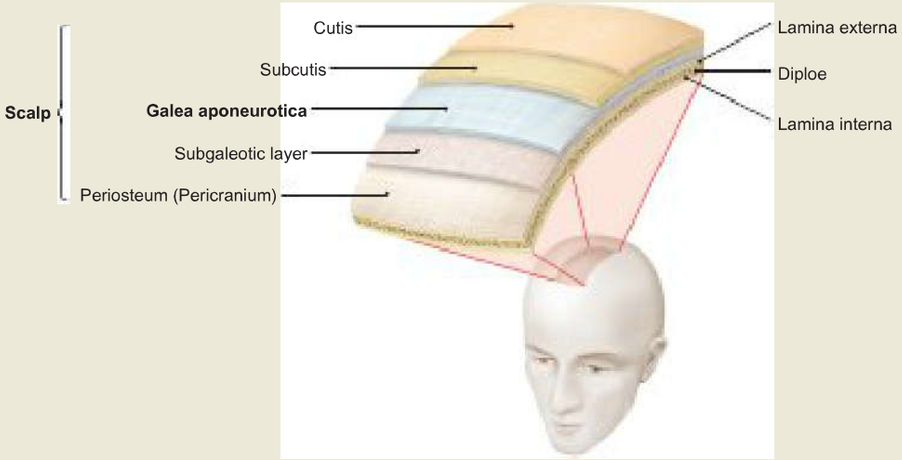

Fig. 8.73 Structure of the scalp; frontal and cranial oblique view. [L127]
The functional unit of skin, subcutis and tendinous epicranial aponeurosis (Galea aponeurotica), lying above the calvaria, is referred to as the scalp. It consists of five layers that you can remember using the term SCALP.

- S = skin (Cutis)
- C = connective tissue (Subcutis)
- A = aponeurosis (Aponeurosis epicranialis, Galea aponeurotica with M. epicranius)
- L = loose connective tissue (subgaleotic layer)
- P = pericranium (periosteum of the cranium)

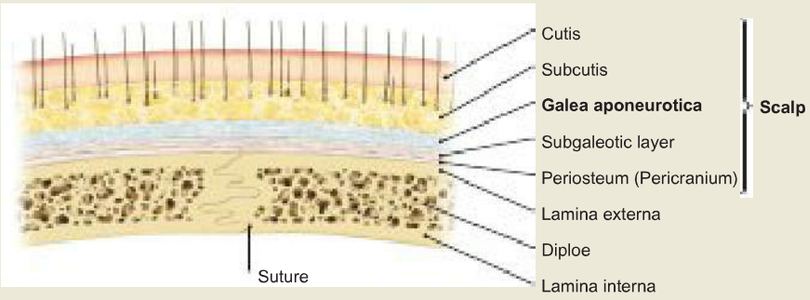

Fig. 8.74 Structure of the scalp; sagittal section. [L127]
The total thickness of the scalp is approximately 5 mm. The cutis is rough in the area of the hair-covered scalp and contains many hair shafts, sebaceous glands and sweat glands. In the subcutis are the corresponding papillae, hair follicles and hair roots. It consists for the most part of dense connective tissue, which anchors the skin in the Galea aponeurotica. In addition, blood vessels and nerves run here. In bald areas, the cutis and subcutis are thinner. The Galea aponeurotica is an extensive tendon to which the paired Venter frontalis and Venter occipitalis of the M. epicranius (M. occipitofrontalis) are attached, as well as the variably occurring M. temporoparietalis on each side. The Galea aponeurotica and subcutis are firmly connected by retinacula. The loose connective tissue (subgaleotic layer) connects the Galea aponeurotica with the pericranium. The pericranium of the calvaria is firmly fused with the external lamina of the facial bones and the connective tissue of the cranial sutures.

Clinical Remarks

At birth, the stress on the child's skull through the birth canal is high. It can lead especially in the occipital and parietal areas to bloody-serous oedema, which is known as **scalp swelling (Caput succedaneum).** Bleeding under the periosteum (subperiostal bleeding) remains limited to individual bones of the calvaria **(cephalic haematoma),** since the periosteum is very strongly adherent in the area of the cranial sutures.
If long hair is caught in a rotating machine, it could be torn off together with the scalp **(scalping injury).** Therefore, health and safety prescribes the use of headwear in the proximity of such machines. The easily detachable nature of the scalp is useful in surgical procedures carried out on the brain where the scalp, by means of a 'temple cut' (from one auricle to the other) can be removed forwards and backwards from the periosteum. After the surgery, the scalp is moved back into place and sewn on. Due to the strong connective tissue, injured blood vessels in the subcutis remain open with only poor retraction. **Bleeding** after injury is therefore often extensive.

Facial Muscles

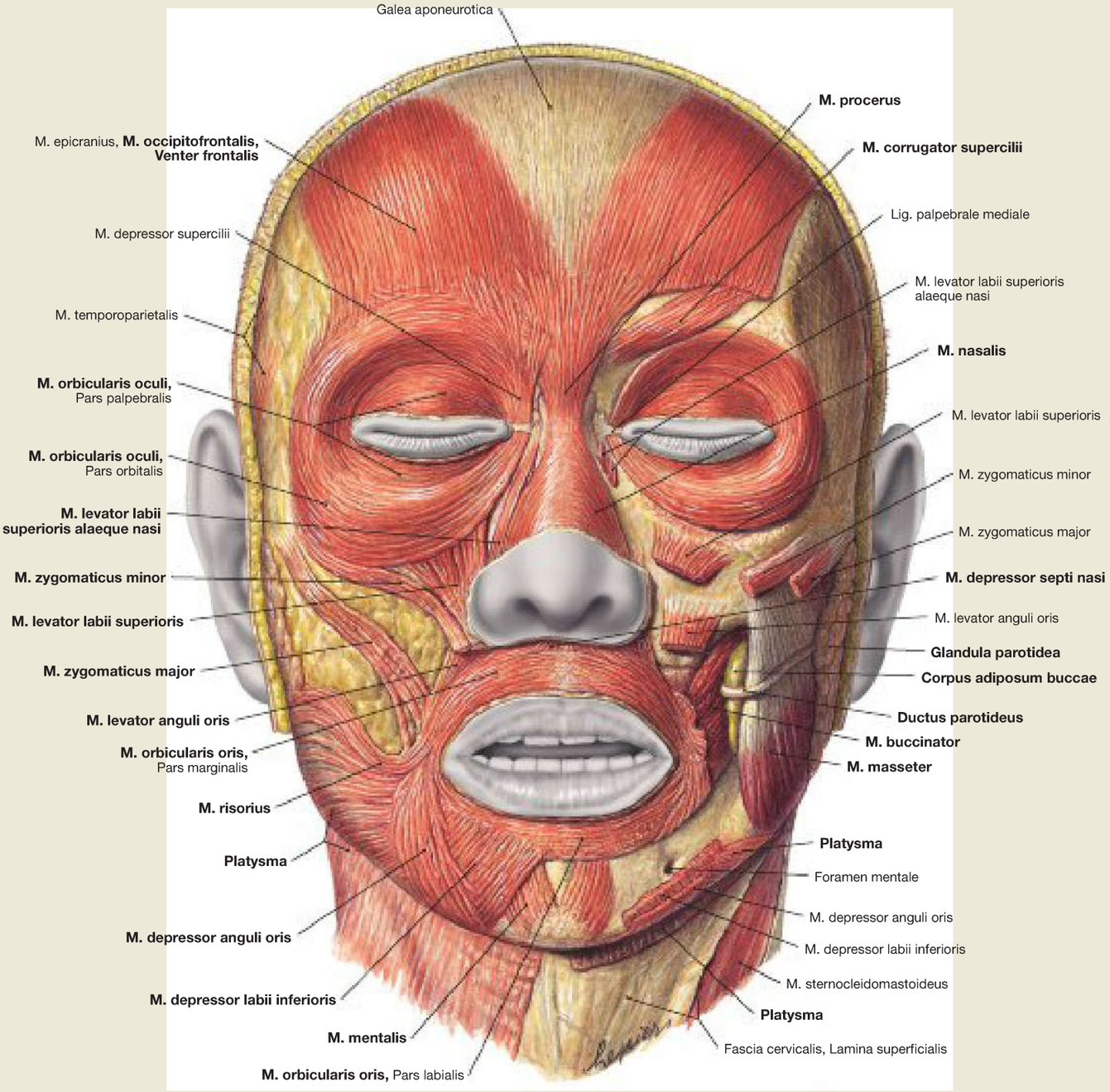

Fig. 8.75 Facial muscles, Mm. faciei, and masticatory muscles, Mm. masticatorii; frontal view.
The mimetic muscles are, as the name indicates, responsible for facial expressions, as well as creating the individual facial physiognomy of a person. The muscles in the region of the eyes have important protective functions, while the muscles in the region of the mouth serve the food uptake and articulation.
Visible on both sides of the face are the Venter frontalis of the M. occipitofrontalis (M. epicranius), the Partes orbitalis and palpebralis of the M. orbicularis oculi (Pars lacrimalis, → Fig. 8.64), the M. corrugator supercilii, M. procerus, Mm. nasalis, depressor septi nasi, levator labii superioris alaeque nasi, the M. orbicularis oris with the Pars labialis and Pars marginalis, the M. buccinator, the Mm. zygomatici major and minor, the Mm. risorius, levator labii superioris, levator anguli oris, depressor anguli oris, depressor labii inferioris and mentalis, as well as the platysma projecting into the neck area.
Of the masticatory muscles, the only one to be seen in the left half of the face is the M. masseter, which is crossed by the Ductus parotideus (STENSEN's duct). The duct runs from the Glandula parotidea anteriorly and bends around the frontal edge of the M. masseter in an almost right angle, in order to enter into the M. buccinator.
A buccal fat pad (Corpus adiposum buccae, BICHAT's fat pad) is located between the M. masseter and M. buccinator and contributes to the contour of the cheek area. With the exception of the M. buccinator, the facial muscles do not possess a fascia. The fascia of the M. buccinator, the M. masseter and the Glandula parotidea have been removed.

→ T 1a, c–f, 4

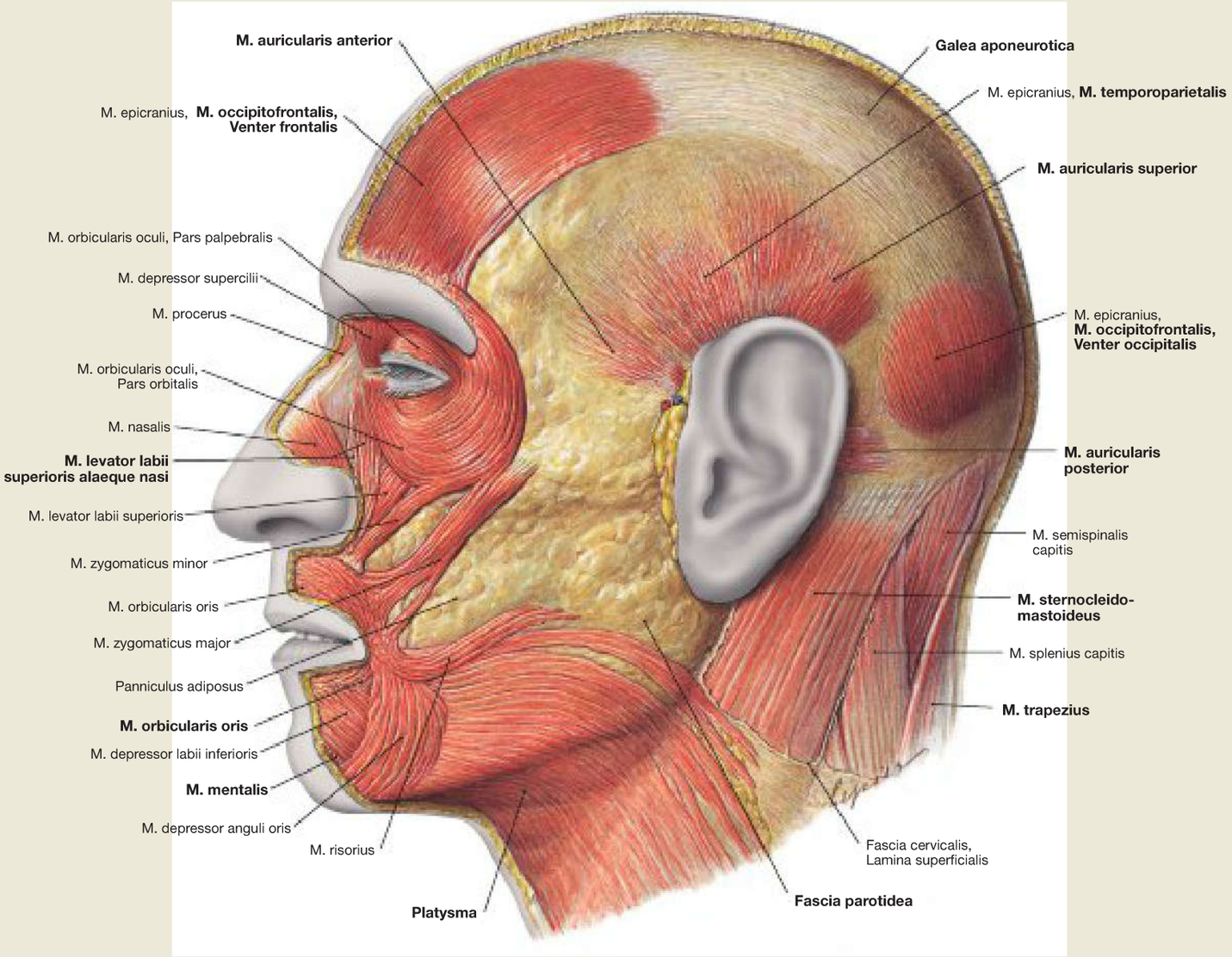

Fig. 8.76 Facial muscles, Mm. faciei, left side; lateral view.
In addition to the muscles labelled in → Figure 8.75, the view from the side shows the Venter occipitalis of the M. occipitofrontalis (M. epicranius) and the **Galea aponeurotica** extending between the Venter frontalis and Venter occipitalis. Located above the ear and also projecting into the Galea aponeurotica is the M. temporoparietalis (also a part of the M. epicranius) which originates from the Fascia temporalis. In addition, you can see further mimetic muscles such as the Mm. auriculares anterior, superior and posterior. On the back of the neck area, parts of the M. sternocleidomastoideus, the M. trapezius and some intrinsic muscles are visible.

→ T 1

Clinical Remarks

Paralysis of the M. orbicularis oculi associated with a paresis of the N. facialis [VII] (facial paralysis), results in inability to voluntarily close the eyelid, causing it to stay open during sleep (paralytic **lagophthalmos,** → Fig. 12.155). The lower eyelid has no tension and hangs down limply **(paralytic ectropion).** The lacrimal fluid can no longer be discharged via the Canaliculus inferior and runs over the everted lower eyelid (constant tearing, **epiphora**). The inability to blink leads to the drying out of the cornea with inflammation **(keratitis)** and opacity of the cornea.

The age-related flaccid weakness of the lower eyelid is described as a **senile ectropion**.
Paralysis of the M. orbicularis oris (also in the context of facial paralysis) results in speech disabilities. The corner of the mouth hangs down so that saliva involuntarily flows from the mouth.

Facial and Masticatory Muscles

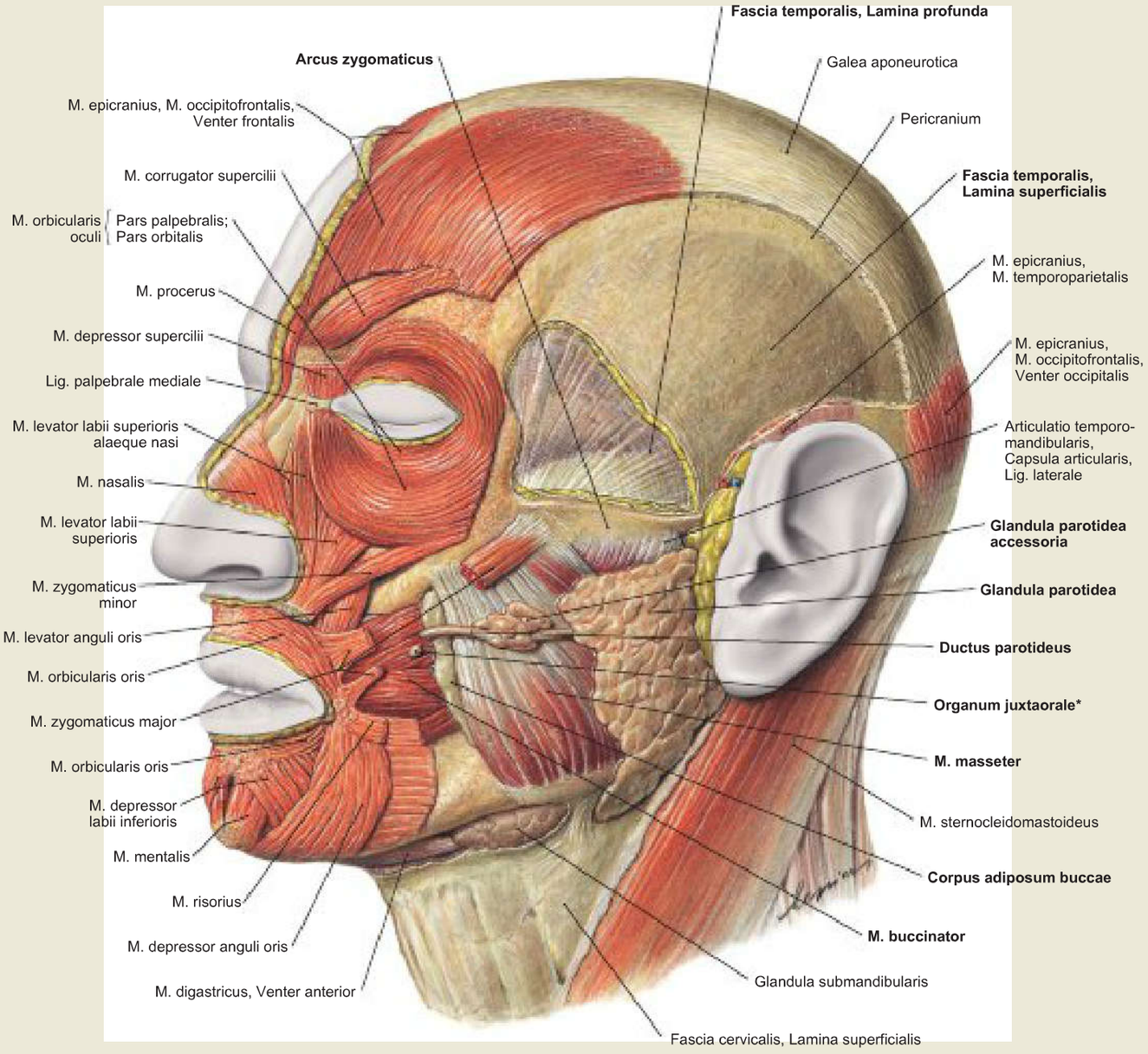

Fig. 8.77 Facial muscles, Mm. faciei, and masticatory muscles, Mm. masticatorii; oblique lateral view.
The fascia of the M. buccinator and the M. masseter, as well as the Fascia parotidea and, in some cases, the Lamina superficialis of the Fascia cervicalis, are removed. As a result, the corresponding muscles, the Glandula parotidea extending to the neck area, and the Glandula submandibularis become visible.
The main excretory duct of the Glandula parotidea, the Ductus parotideus (STENON's duct, STENSEN's duct), emerges from the gland at the anterior pole and runs horizontally from the posterior side of the **M. masseter** forwards and then bends inwards in an almost right angle to the anterior margin of the M. masseter in order to penetrate the **M. buccinator.** Between the M. buccinator and M. masseter lies the Corpus adiposum buccae (BICHAT's fat pad). Associated with the Ductus parotideus is accessory glandular tissue (Glandula parotidea accessoria). Near to the site where the Ductus parotideus penetrates the M. buccinator, lies the juxtaoral organ (*Organ of CHIEVITZ) on the M. buccinator. It is approximately 5×3 mm and is an epithelial organ in the cheek, embedded in connective tissue rich in nerves and cells, and surrounded by a perineural sheath. Its function is not conclusively established; it is assumed, however, that it effects dynamic changes when chewing, swallowing, sucking and speaking, and among other things, helps prevent you from biting your cheek when chewing.
In the temporal region, the M. parietoparietalis of the M. epicranius has been removed. This reveals the Lamina superficialis of the Fascia temporalis.
Above the Arcus zygomaticus, a part of the Lamina superficialis together with the underlying temporal fat pad (Corpus adiposum temporale) is removed so that the deep layer (Lamina profunda) of the Fascia temporalis can be seen together with the M. temporalis gleaming through it.

→T 1, 4

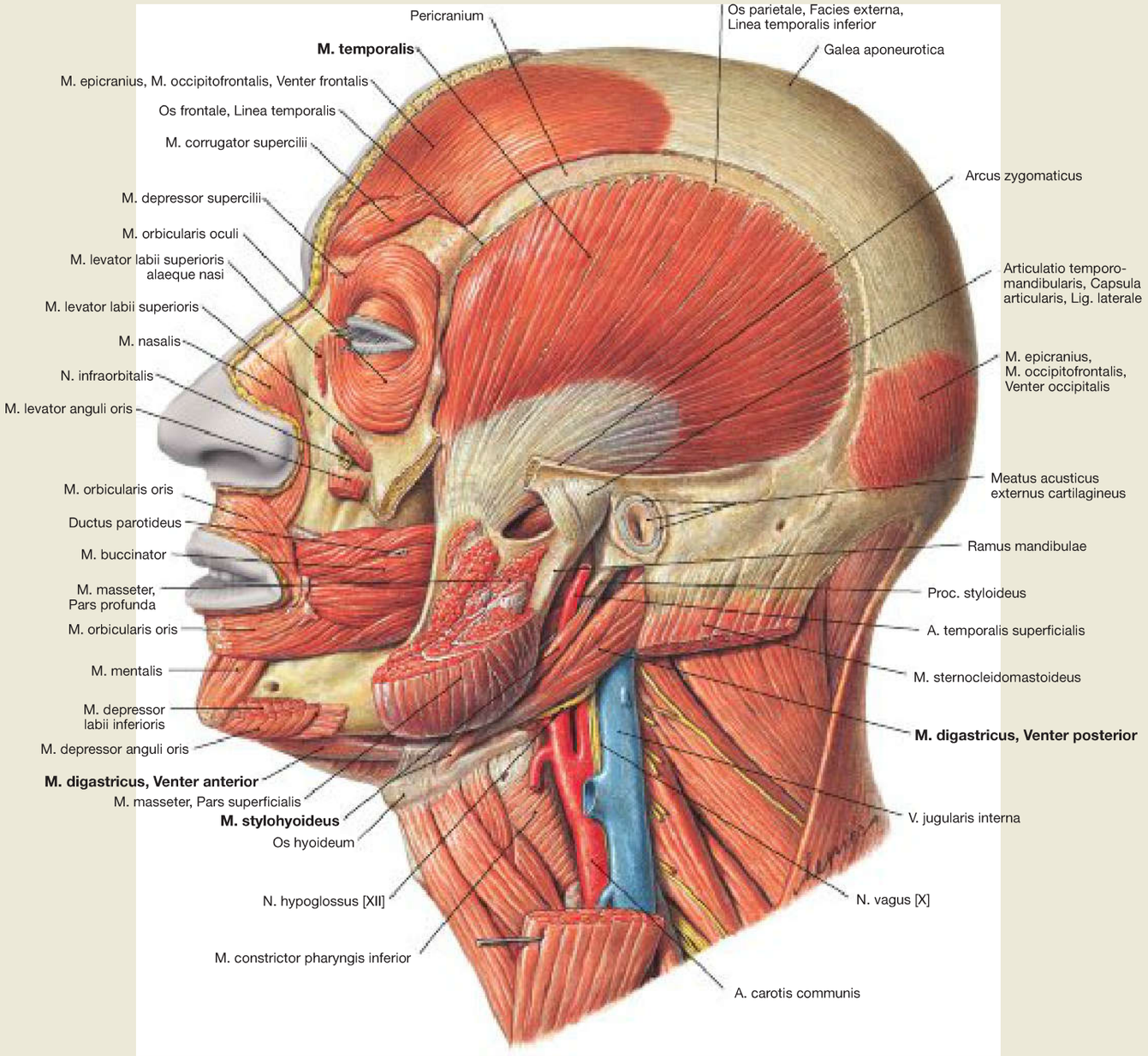

Fig. 8.78 Facial muscles, Mm. faciei, and masticatory muscles, Mm. masticatorii, left side; oblique lateral view.
Upon removal of the superficial and deep laminae of the Fascia temporalis and the partial removal of the Arcus zygomaticus and parts of the M. masseter, the **M. temporalis** becomes visible.
The origin of the M. temporalis is shown along the Linea temporalis inferior of the Facies externa of the Os parietale, and the Facies temporalis of the Os frontale. The muscle fibres converge into a flat tendon, which disappears behind the Arcus zygomaticus into the Fossa infratemporalis and extends to the Proc. coronoideus.

Origins of the M. temporalis:
- Linea temporalis inferior of the Facies externa of the Os parietale
- Facies temporalis of the Os frontale
- Facies temporalis, Pars squamosa of the Os temporale
- Facies temporalis of the Os zygomaticum
- Facies temporalis of the Os sphenoidale to the Crista infratemporalis

The illustration also shows some of the Mm. suprahyoidei (M. digastricus with Venter anterior and Venter posterior, M. stylohyoideus).

→ T 1, 4

Clinical Remarks

Swelling of the Glandula parotidea (e.g. in the case of an epidemic parotitis [mumps], → p. 110) is often very painful when chewing due to the close proximity to the masticatory muscles and because it shares a common fascia (Fascia parotideomasseterica) with the M. masseter. The pain is often referred into the external acoustic meatus (pain from pressure onto the tragus).

In the case of a severe emaciation, e.g. in the final stages of malignant tumour diseases **(cancer cachexia)** or in an advanced stage of HIV, the BICHAT's fat pad of the cheek wastes away; the patient then has sunken cheeks.

Masticatory Muscles

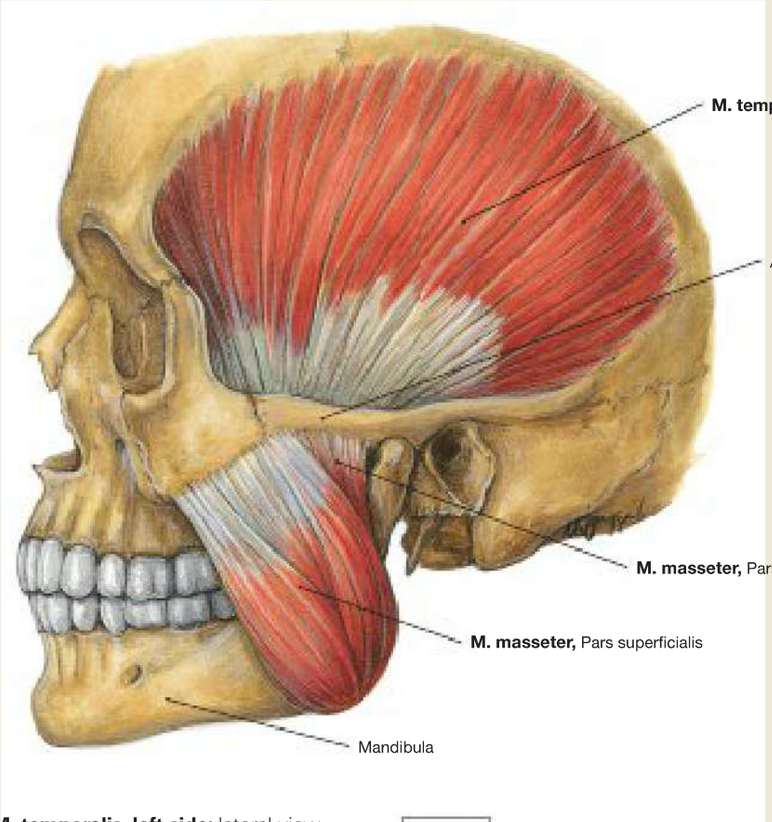

Fig. 8.79 M. masseter and M. temporalis, left side; lateral view.
The **M. masseter** consists of a Pars superficialis and a Pars profunda.

→T 4

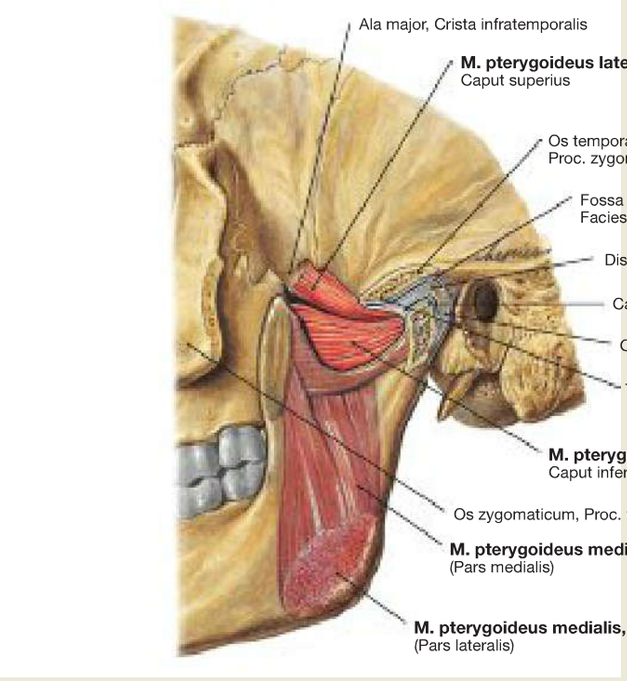

Fig. 8.80 Temporomandibular joint, Articulatio temporomandibularis, M. pterygoideus medialis and M. pterygoideus lateralis, left side; lateral view.
The M. pterygoideus medialis consists of a Pars medialis and a Pars lateralis.

→T 4

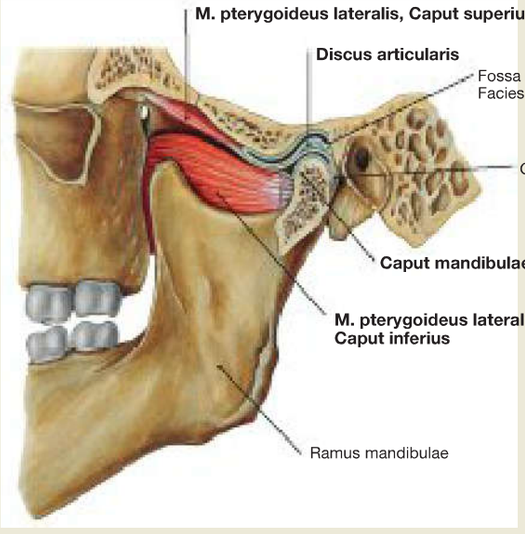

Fig. 8.81 Temporomandibular joint, Articulatio temporomandibularis, and relationship with the M. pterygoideus lateralis, left side; lateral view.
The M. pterygoideus lateralis has a Caput superius and a Caput inferius (→ Fig. 8.80).

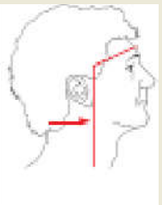

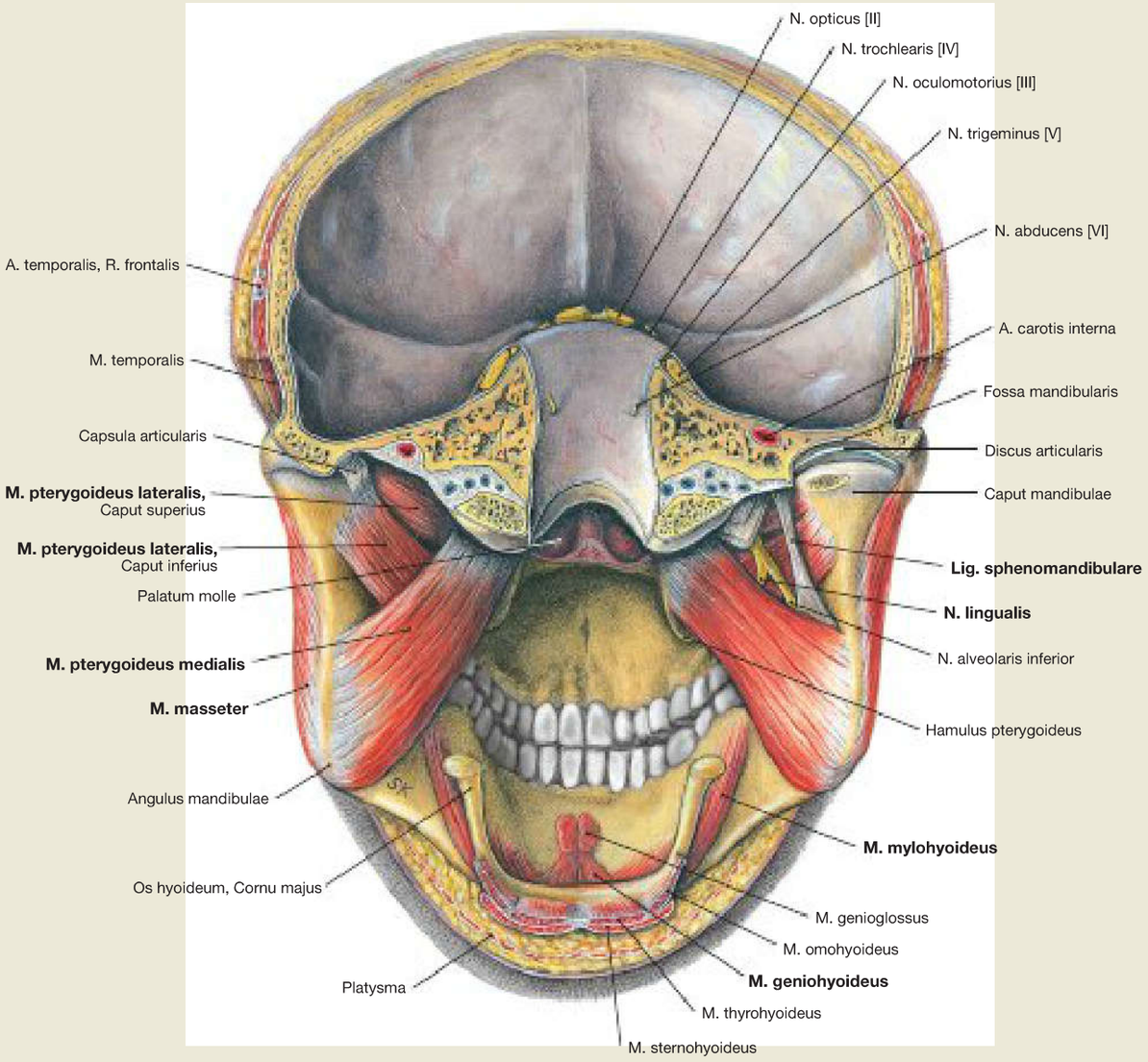

Fig. 8.82 Masticatory muscles, Mm. masticatorii; frontal section in the area of the Articulatio temporomandibularis and horizontal section of the calvaria; posterior view. [L238]
You can see the respective insertions of the M. masseter and M. pterygoideus medialis on both sides of the Angulus mandibulae. The Mandibula is suspended by these muscles like in a swing. Furthermore on the right side, the Lig. sphenomandibulare can be recognised between the M. pterygoideus lateralis and the M. pterygoideus medialis and, among others, the N. lingualis.

→T 4

Clinical Remarks

Trismus manifests itself as an inability to open your mouth. It is caused by abscesses in the fascial compartments of the masticatory muscles. **Lock jaw** is differentiated from trismus (inability to close the mouth), and is usually triggered by a very strong yawn or extreme opening of the mouth, although it can also be the result of an accident.

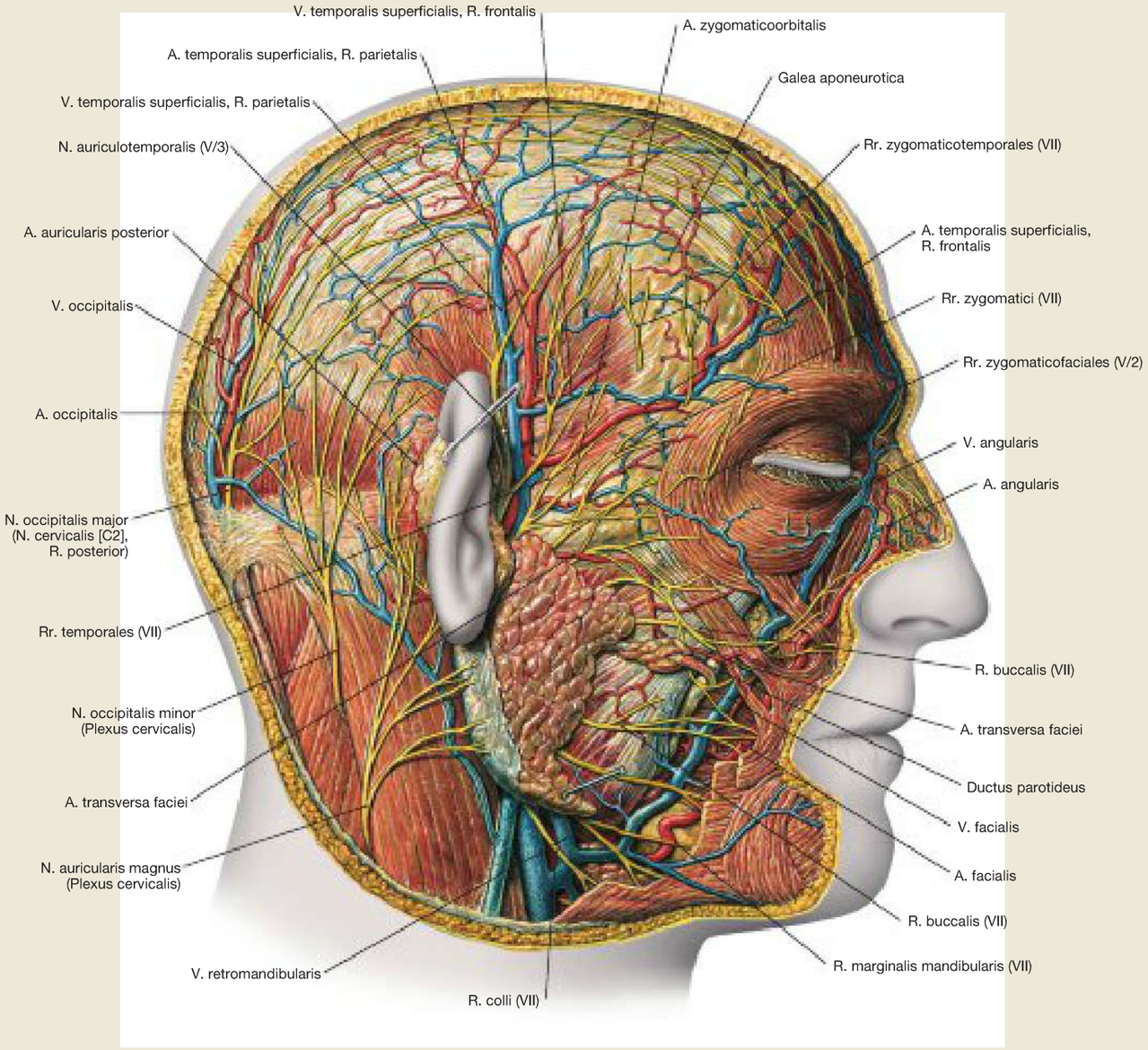

Fig. 8.83 Vessels and nerves of the head and neck, superficial lateral regions, right side; lateral view.
In the facial area, the superficial arteries are the **A. facialis** and their branches. In the lateral head region, the **A. temporalis superficialis** is arising from the A. carotis externa with a R. parietalis and a R. frontalis. The blood is drained from here via identically named veins into the **V. jugularis externa**.
Superficial nerves are the terminal branches of the **N. facialis [VII],** which arise from the Plexus intraparotideus located in the parotid gland (Rr. temporales, Rr. zygomatici, Rr. buccales, Rr. marginales mandibulares, R. colli n. facialis). In front of the outer ear emerges the **N. auriculotemporalis,** which originates from the N. trigeminus [V]. The **N. supraorbitalis**, also a branch of the N. trigeminus [V], leaves the Orbita and pierces the M. orbicularis oculi.
The neck and occipital regions receive sensory innervation by branches of the **Plexus cervicalis**, most of which originate from the Punctum nervosum (ERB's point) on the back of the M. sternocleidomastoideus: N. transversus colli (not visible), N. auricularis magnus, N. occipitalis minor and Nn. supraclaviculares (not visible).

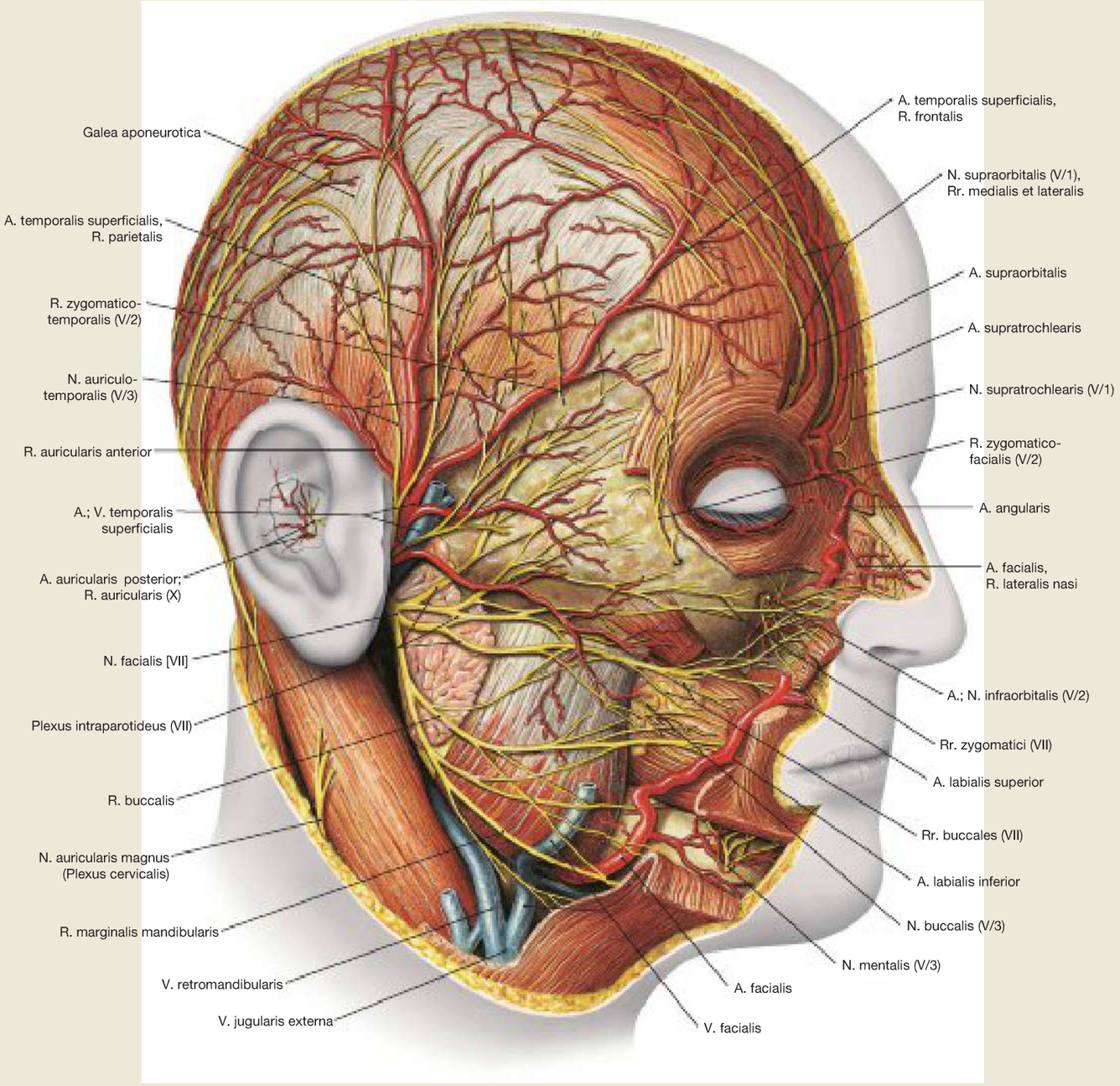

Fig. 8.84 Vessels and nerves of the head and neck, deep lateral regions, right side; lateral view.
Upon removal of the facial muscles and the superficial parts of the Glandula parotidea, the route of the **A. facialis** as well as the origin of the terminal branches of the N. facialis, provided by the **Plexus intraparotideus,** become visible. Also shown are the **terminal sensory branches of the N. trigeminus [V]** which originate from its three parts:

- Nn. supraorbitalis and supratrochlearis (from N. ophthalmicus [V/1])
- N. infraorbitalis (from N. maxillaris [V/2])
- N. mentalis (from N. mandibularis [V/3])

Clinical Remarks

Operations or incision injuries of the Glandula parotidea can lead to a **disruption of the intraparotid branches of the N. facialis [VII]** with partial paralysis of mimetic muscles (peripheral facial paralysis or partial paralysis).

Vessels and Nerves of the Lateral Facial Region

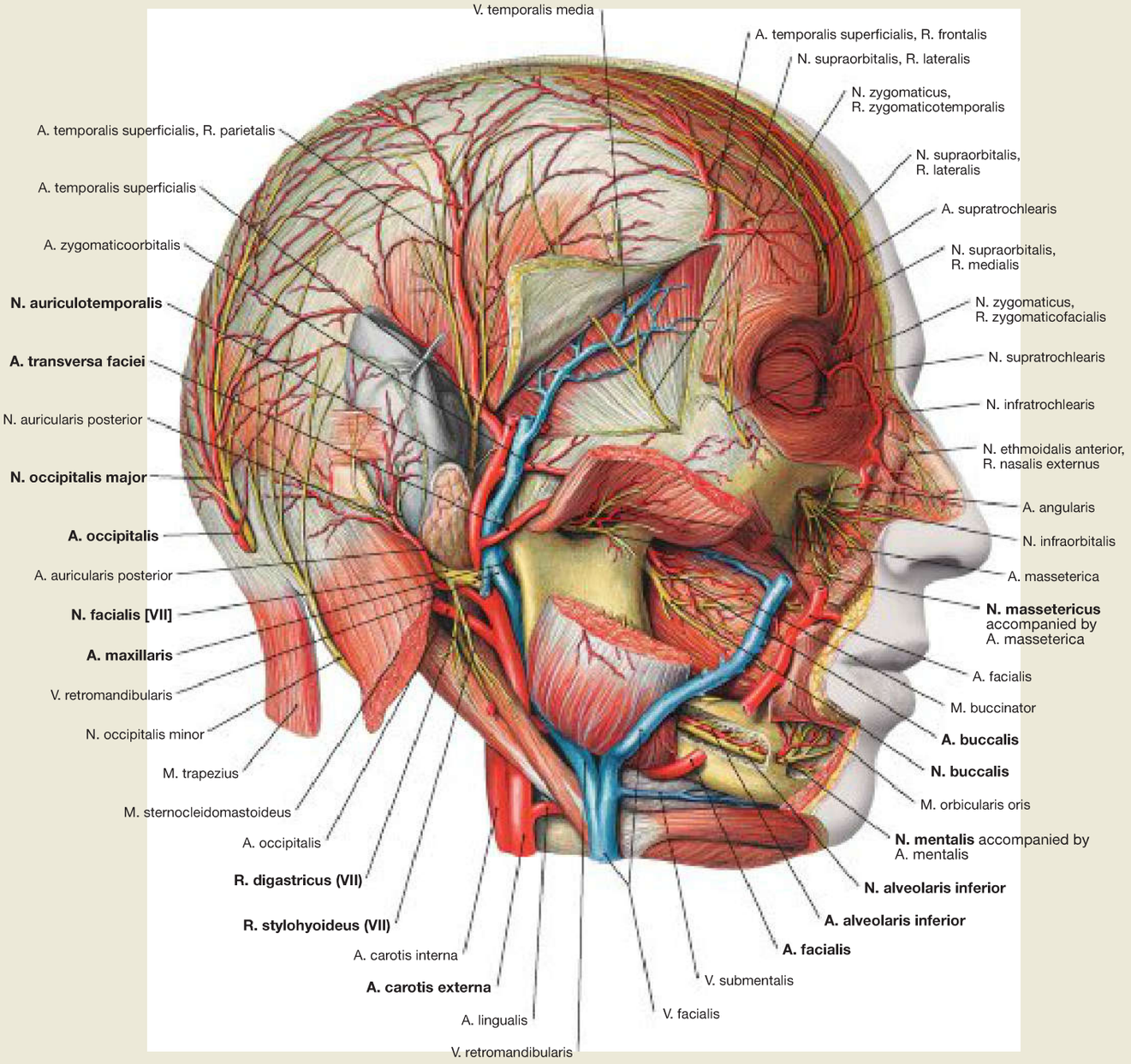

Fig. 8.85 Vessels and nerves of the head, deep lateral regions, right side; lateral view.
Upon removal of large parts of the Glandula parotidea, the structures of the **Fossa retromandibularis** in the deep lateral head region become visible.
Below the auricle, the undivided stem of the **N. facialis [VII]** is visible. Shortly after leaving the Foramen stylomastoideum, it sends branches to the M. digastricus, Venter posterior (R. digastricus), and to the M. stylohyoideus (R. stylohyoideus), as well as to the mimetic ear muscles (N. auricularis posterior).
Below the Mm. digastricus and stylohyoideus, the Aa. carotides interna and externa ascend. The **A. carotis externa** runs with the V. retromandibularis and the N. auriculotemporalis in the retromandibular fossa and divides into the Aa. occipitalis, auricularis posterior, maxillaris and temporalis superficialis, as well as numerous small branches. The M. masseter was cut and folded back to demonstrate its supplying structures located on the back of this muscle (N. massetericus – branch of the N. mandibularis [V/3]; A. masseterica – branch of the A. maxillaris). The supplying structures reach this muscle through the Incisura mandibulae. In the lower part of the face, all mimetic muscles on the Mandibula have been removed. The Canalis mandibularis, which runs intraosseously from the Foramen mandibulae to the Foramen mentale, is opened to expose the **N. alveolaris inferior** and the artery of the same name. At the Foramen mentale, the nerve becomes the **N. mentalis.**
Below the orbit, a part of the A. facialis is removed. Just below the eye it continues as A. angularis, which anastomoses with the branches of the A. ophthalmica in the Orbita. On top of the **M. buccinator**, the N. buccalis, a sensory branch of the N. mandibularis [V/3], is visible.

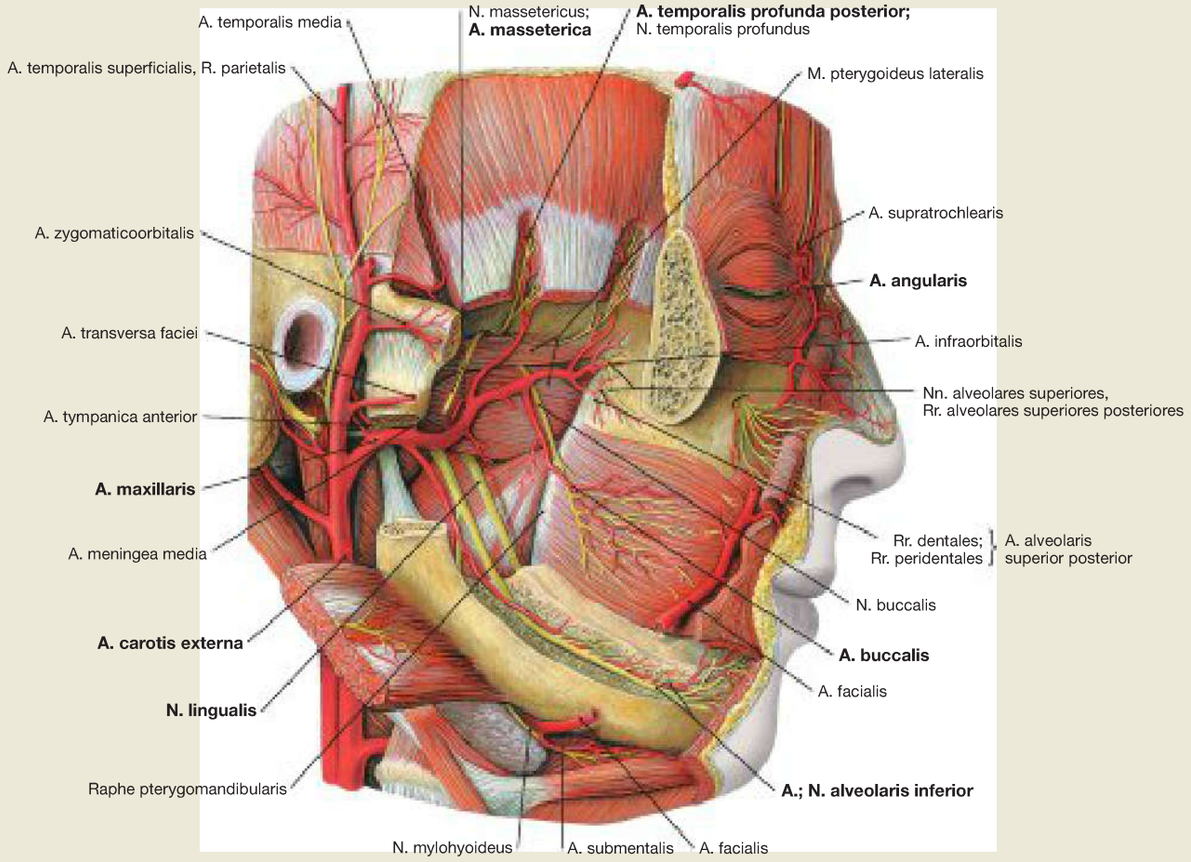

Fig. 8.86 Arteries and nerves of the head, deep lateral regions, right side; lateral view.
The **A. maxillaris** rus in the majority of cases behind the Ramus mandibulae and only rarely laterally thereof. It continues between the masticatory muscles, which it provides with blood, sends branches to the M. buccinator and the Mandibula, and its terminal branches reach the orbit, nose, maxilla and palate. The **A. carotis externa** passes through the Fossa retromandibularis, together with the branches emerging from it. The A. facialis above the opened Corpus mandibulae was removed. At the point where it bends around the edge of the Mandibula, you can usually feel its pulses.

Branches of the A. maxillaris	
Pars retromandibularis	• A. auricularis profunda • A. tympanica anterior • A. alveolaris inferior – Rr. dentales – Rr. peridentales – R. mentalis – R. mylohyoideus • A. meningea media • A. pterygomeningea
Pars intermuscularis	• A. masseterica • A. temporalis profunda anterior • A. temporalis profunda posterior • Rr. pterygoidei • A. buccalis
Pars sphenopalatina	• A. alveolaris superior posterior – Rr. dentales – Rr. peridentales • A. infraorbitalis – Aa. alveolares superiores anteriores – Rr. dentales – Rr. peridentales • A. canalis pterygoidei • A. palatina descendens • A. sphenopalatina

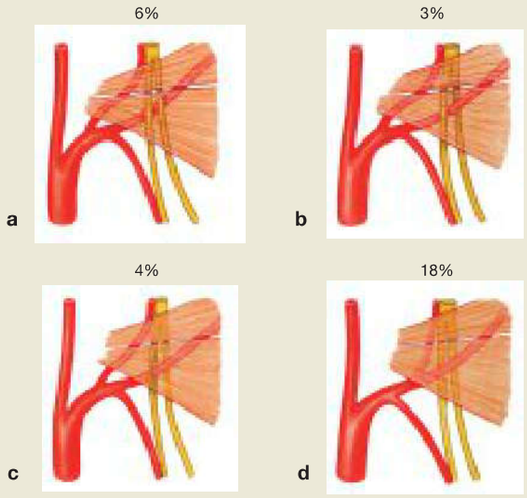

Fig. 8.87a to d Variations of the course of the A. maxillaris.
a Course of the A. maxillaris medially of the M. pterygoideus lateralis and of the N. lingualis and the N. alveolaris inferior
b Course of the A. maxillaris between the N. lingualis and N. alveolaris inferior
c Course of the A. maxillaris through a loop of the N. alveolaris inferior
d A. meningea media, branching off distally to the outlet of the A. alveolaris inferior

Plexus pterygoideus, N. mandibularis [V/3]

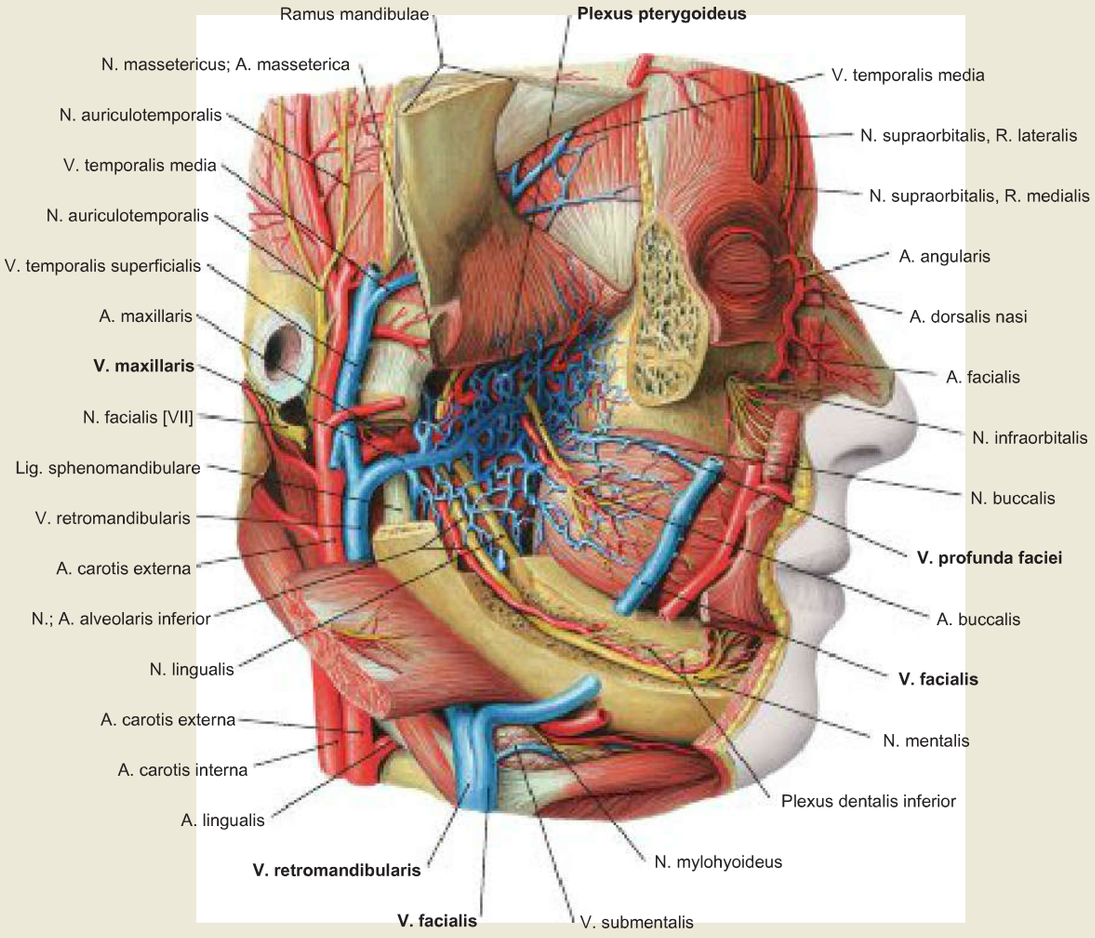

Fig. 8.88 Vessels and nerves of the head, deeper lateral regions, right side; lateral view.
Venous blood from the area of the masticatory muscles is drained via the **Plexus pterygoideus** and is mostly directed into the V. maxillaris. The Plexus pterygoideus is also connected via the V. profunda faciei to the V. facialis, and via the V. ophthalmica inferior to the Sinus cavernosus.

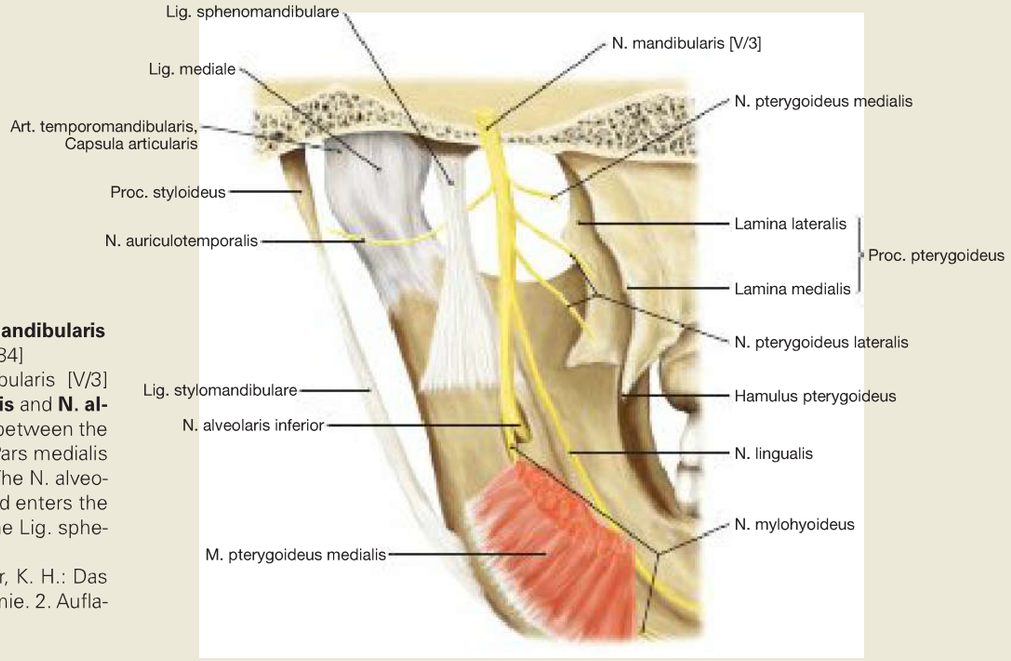

Fig. 8.89 Branching of the N. mandibularis [V/3], right side; medial view. [L284]
The branching of the N. mandibularis [V/3] (→ Fig. 12.143) into the **N. lingualis** and **N. alveolaris inferior** normally occurs between the Lig. sphenomandibulare and the Pars medialis of the M. pterygoideus medialis. The N. alveolaris inferior then turns laterally and enters the Canalis mandibularis laterally of the Lig. sphenomandibulare.
Based on: Radlanski, R. J./Wesker, K. H.: Das Gesicht. Bildatlas klinische Anatomie. 2. Auflage. KVM, 2012

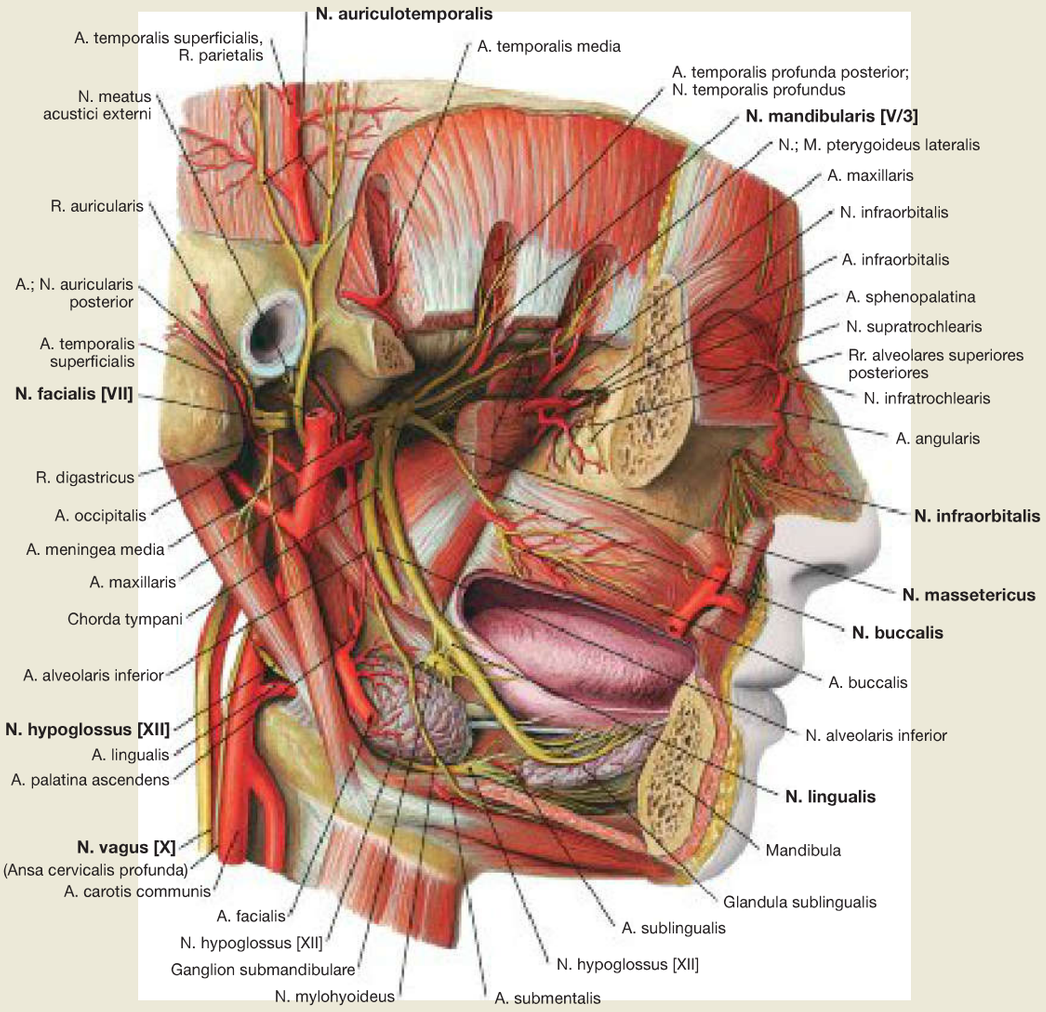

Fig. 8.90 Arteries and nerves of the head, deepest lateral regions, right side; lateral view.

Upon exiting the Foramen ovale, the N. mandibularis [V/3] divides into the **N. lingualis, N. alveolaris inferior,** N. buccalis, and the N. auriculotemporalis and sends branches to the masticatory muscles.

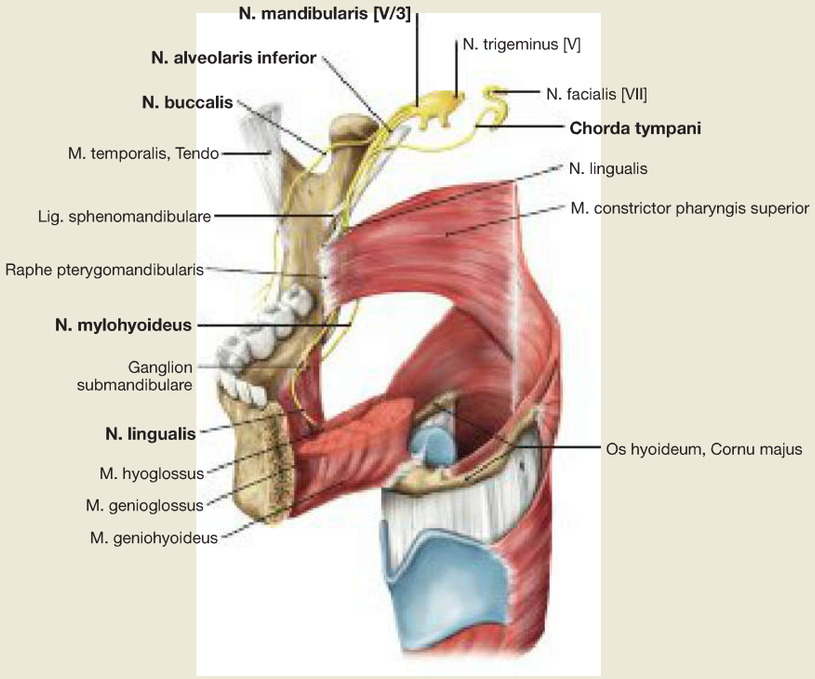

Fig. 8.91 Branching of the N. mandibularis [V/3], right side; frontal view from the left. [L266]
Branching off the N. mandibularis [V/3], the **N. lingualis** enters the tongue from the lateral side. Shortly after leaving the N. mandibularis [V/3] it joins the Chorda tympani, which branches off the N. facialis [VII] in the Canalis facialis. The Chorda tympani leads parasympathetic fibres to the Ganglion submandibulare and gustatory fibres supplying the anterior two-thirds of the tongue.

Arteries of the Head

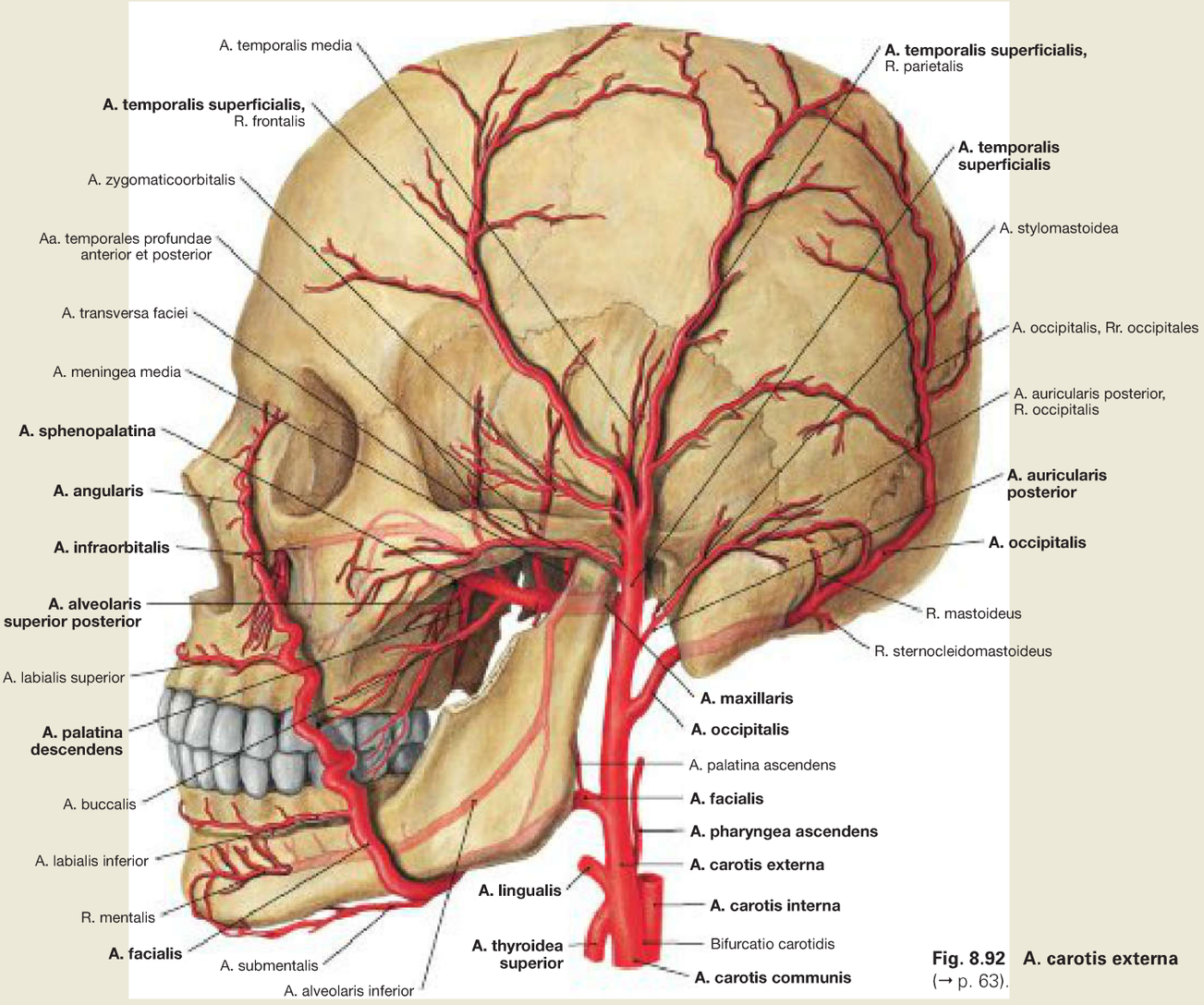

Fig. 8.92 A. carotis externa (→ p. 63).

Branches of the A. carotis externa

1. A. thyroidea superior
- R. infrahyoideus
- A. laryngea superior
- R. cricothyroideus
- R. sternocleidomastoideus
- Rr. glandulares

2. A. pharyngea ascendens
- Rr. tonsillares
- Rr. pharyngeales
- A. tympanica inferior
- A. meningea posterior

3. A. lingualis
- Rr. dorsales linguae
- A. sublingualis
- A. profunda linguae

4. A. facialis
- A. palatina ascendens
- R. tonsillaris
- A. submentalis
- Rr. glandulares
- A. labialis inferior
- A. labialis superior
  - R. septi nasi
- R. lateralis nasi
- A. angularis

5. A. occipitalis
- R. mastoideus
- R. auricularis
- Rr. sternocleidomastoidei
- Rr. occipitales
- R. meningeus (var.)
- R. descendens

6. A. auricularis posterior
- A. stylomastoidea
  - A. tympanica posterior
- R. auricularis
- R. occipitalis
- R. parotideus

7. A. temporalis superficialis
- R. parotideus
- A. transversa faciei
- Rr. auriculares anteriores
- A. zygomaticoorbitalis
- A. temporalis media
- R. frontalis
- R. parietalis

8. A. maxillaris
- A. alveolaris inferior
  - R. mentalis
- A. meningea media
  - A. tympanica superior
  - A. auricularis profunda
  - A. tympanica anterior

} Pars mandibularis

- A. masseterica
- Aa. temporales profundae posterior et anterior
- Rr. pterygoidei
- A. buccalis

} Pars pterygoidea

8. A. maxillaris *(continuation)*
- A. alveolaris superior posterior
  - Rr. dentales
  - Rr. peridentales
- A. infraorbitalis
  - Aa. alveolares superiores anteriores
- A. palatina descendens
  - A. palatina major
  - Aa. palatinae minores
    - R. pharyngeus
- A. sphenopalatina
  - Aa. nasales posteriores laterales
  - Rr. septales posteriores
  - A. nasopalatina

} Pars pterygopalatina

The terminal branches of the A. maxillaris are the A. infraorbitalis, A. sphenopalatina, A. alveolaris superior posterior and the A. palatina descendens.

Veins of the Head

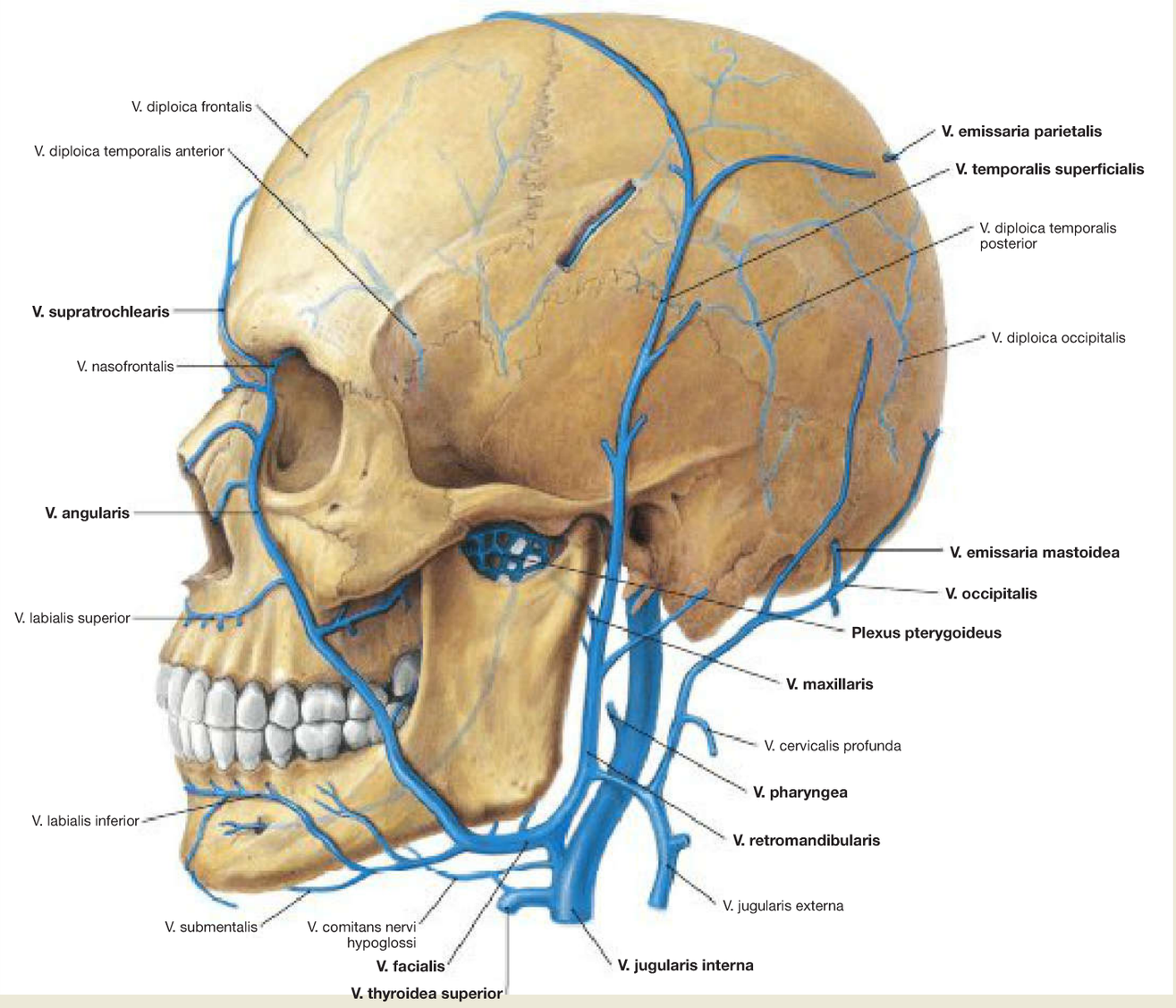

Fig. 8.92 External carotid artery, A. carotis externa, left side; lateral view (→ p. 62).
The A. carotis externa, after leaving the A. carotis communis, divides into **branches** according to order noted in the table (→ p. 62).

Fig. 8.93 Internal jugular vein, V. jugularis interna, left side; lateral view.
The V. jugularis interna begins as an extended continuation of the Sinus sigmoideus at the base of the skull. This vein drains the blood from the regions of the skull, brain, face, and parts of the neck. It receives inflows from the superficial head region via the Vv. facialis, lingualis, pharyngea, occipitalis, thyroidea superior, thyroidea media and via Vv. emissariae.

Clinical Remarks

The pulse of the V. jugularis **(jugular pulse)** provides useful information on the venous blood pressure, and the wave-like characteristic of the jugular pulse reflects the function of the right heart.

Inflammation in the facial area may, in rare cases, extend via the valveless V. angularis into the intraorbital veins (V. ophthalmica superior) and further into the Sinus cavernosus. This could result in a life-threatening phlebitis or even a venous sinus thrombosis.

N. facialis [VII]

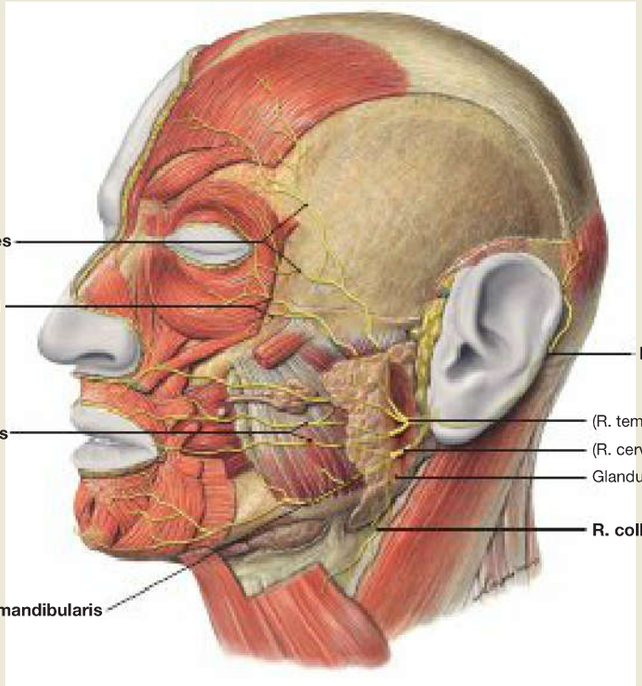

Fig. 8.94 Terminal branches of the N. facialis [VII] in the face, left side; lateral view.
Within the Glandula parotidea, the N. facialis [VII] (→ Fig. 12.152) forms the parotid plexus, which for practical clinical reasons is divided into a R. temporofacialis (Pars temporofacialis) and a R. cervicofacialis (Pars cervicofacialis). These two parts generate the terminal branches of the N. facialis [VII]: the Rr. temporales, zygomatici, buccales, marginales mandibulares and colli. The outgoing N. auricularis posterior, also seen as a terminal branch of the N. facialis [VII], runs dorsally behind the auricle.

a

b

Fig. 8.95a and b Peripheral paralysis of the N. facialis [VII], right side. [T887]
a When the patient is asked to raise his eyebrows, only the left side of the forehead displays wrinkles (loss of function of the M. occipitofrontalis as sign of a peripheral facial paralysis).
b When the patient is asked to shut both eyes, it does not work on the side with the damaged N. facialis (lagophthalmus). The eyeball automatically turns upwards when closing the eyes. Because the eyelid on the affected side fails to close properly, the white sclera becomes visible (BELL's phenomenon).

Clinical Remarks

In the case of a **peripheral facial paralysis** (→ Fig. 12.155) the second motor neuron of this nerve pathway is affected; the lesion can be located anywhere between the Nucleus nervi facialis and its peripheral branches. In particular, viral infections or a nerve injury during surgery on the Glandula parotidea can be the causes. The so-called central (supranuclear) damage of the N. facialis [VII] **(central facial paralysis)** is a result of lesions of the first motor neurons. The cause is usually bleeding or infarction in the region of the corticonuclear tract of the inner capsule of the contralateral side. Since the central area for the temporal branches of the N. facialis [VII] receives contralateral as well as ipsilateral influxes, the muscles of the forehead and the M. orbicularis oculi can still be contracted on both sides in the upper eyelid area. However, on the contralateral side the muscles innervated by the Rr. zygomatici, buccales, marginales mandibulares and colli are paralysed (so-called lower facial paralysis).

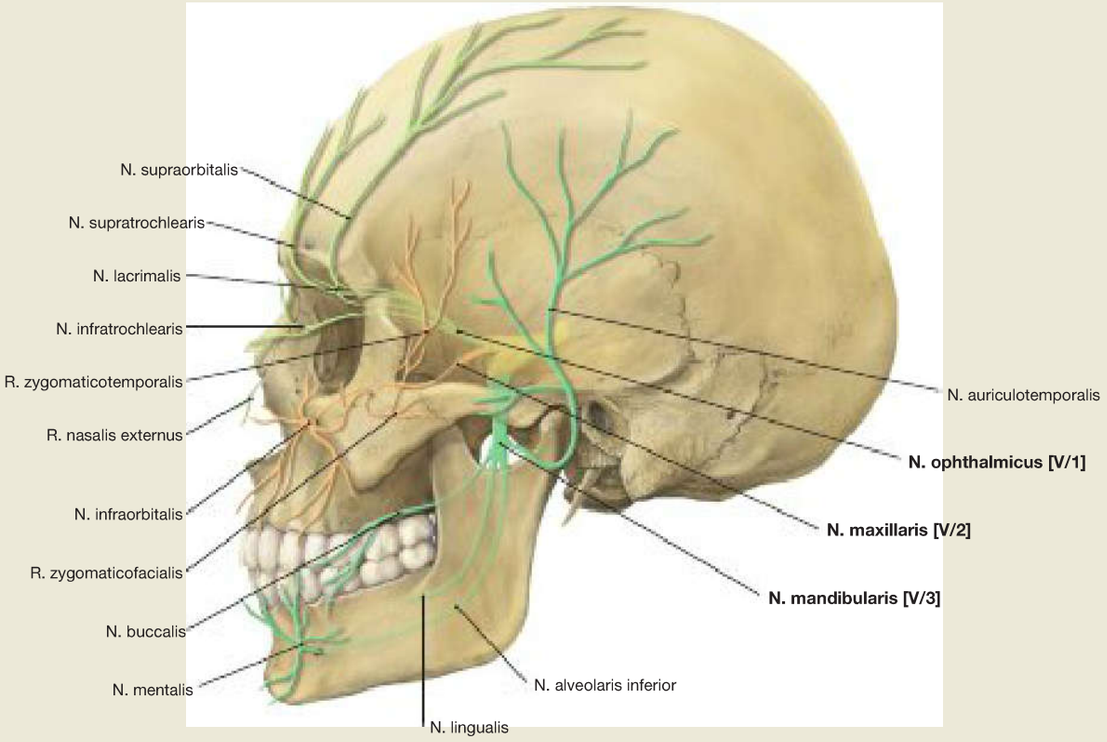

Fig. 8.96 Branches of the N. trigeminus [V], left side; lateral view. [L284]
Upon exiting the cranium, the three major branches of the N. trigeminus [V] – N. ophthalmicus [V/1], N. maxillaris [V/2], and N. mandibularis [V/3] – subdivide into smaller branches in a specific topographic order. Visible branches of the **N. ophthalmicus [V/1]** are the Nn. supraorbitalis, supratrochlearis, lacrimalis, infratrochlearis and the R. nasalis externus. In this illustration, branches of the N. infraorbitalis and the N. zygomaticus (with its Rr. zygomaticotemporalis and zygomaticofacialis) can be seen emerging from the **N. maxillaris [V/2].** From the **N. mandibularis [V/3],** the Nn. buccalis, lingualis, alveolaris inferior and auriculotemporalis branch off. After leaving the Canalis mandibularis, the terminal branch of the N. alveolaris inferior is the N. mentalis.

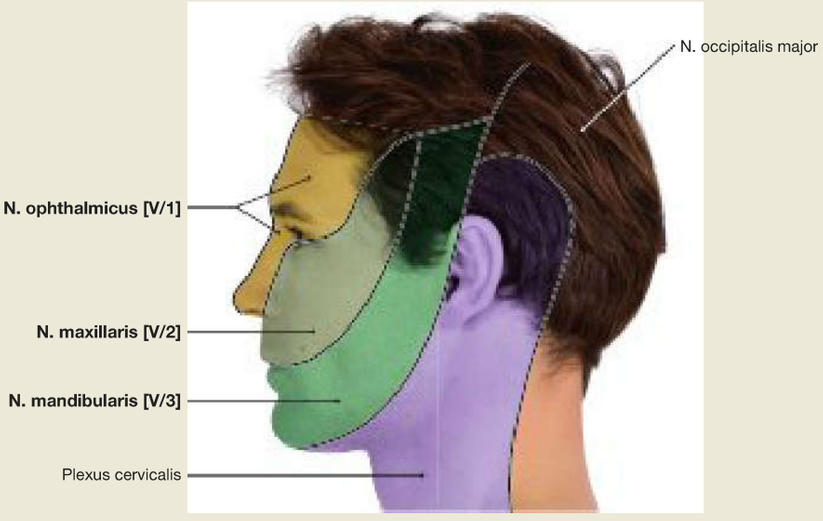

Fig. 8.97 Skin innervation of the head and neck, right side; lateral view. [J803]
The view from the ventral side is depicted in → Fig. 12.146.

Clinical Remarks

In the course of a clinical examination of the cranial nerves, the N. trigeminus [V] is checked by exerting manual pressure on its three exit points **(trigeminal pressure points),** which should normally not be painful: it is checked at the Foramen supraorbitale/Incisura supraorbitalis, the Foramen infraorbitale and the Foramen mentale.

Trigeminal neuralgia (tic douloureux) is a complex and painful dysfunction of the sensory trigeminal root. Typically located in the innervation areas of the N. mandibularis [V/3] and the N. maxillaris [V/2], the facial pain can be intense and occur quite suddenly. It can often be triggered by touching the corresponding area of the face.

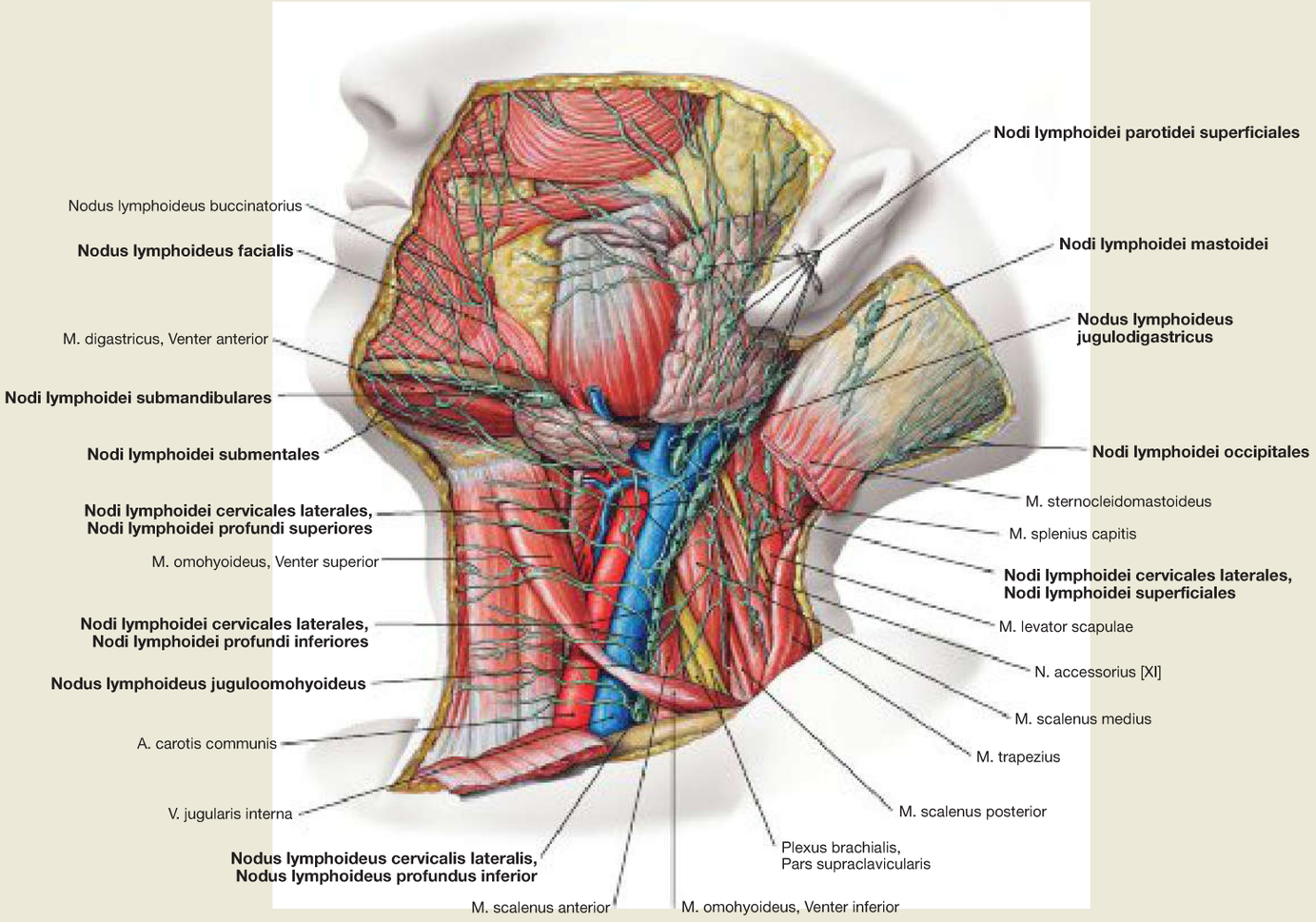

Fig. 8.98 Superficial lymphatic vessels, Vasa lymphatica superficialia, and lymph nodes, Nodi lymphoidei, of the head and neck of a child, left side; lateral view.

The lymph of the face, scalp and occiput region is drained **regionally** to the Nodi lymphoidei submentales, submandibulares, parotidei, mastoidei and occipitales. From here, the lymphatic drainage continues into the superficial **(Nodi lymphoidei cervicales laterales superficiales)** and the deep **(Nodi lymphoidei cervicales laterales profundi superiores and inferiores,** → Fig. 11.84) lateral cervical lymph nodes.

An important deep cervical lymph node is the Nodus lymphoideus jugulodigastricus between the anterior margin of the M. sternocleidomastoideus and the mandibular angle at the lower edge of the Glandula parotidea.

The Nodi lymphoidei parotidei are divided into the superficial **(Nodi lymphoidei parotidei superficiales)** and deep lymph nodes **(Nodi lymphoidei parotidei profundi).** The latter include the Nodi lymphoidei preauriculares, infraauriculares and intraglandulares. In addition, there are single facial lymph nodes **(Nodi lymphoidei faciales)** (Nodi lymphoidei buccinatorius, nasolabialis, malaris, mandibularis) and lymph nodes of the tongue (Nodi lymphoidei linguales).

Lymph Nodes of the Head (Nodi lymphoidei capitis)
• Nodi lymphoidei occipitales
• Nodi lymphoidei mastoidei
• Nodi lymphoidei parotidei superficiales
• Nodi lymphoidei parotidei profundi – Nodi lymphoidei preauriculares – Nodi lymphoidei infraauriculares – Nodi lymphoidei intraglandulares
• Nodi lymphoidei faciales – Nodus lymphoideus buccinatorius – Nodus lymphoideus nasolabialis – Nodus lymphoideus malaris – Nodus lymphoideus mandibularis
• Nodi lymphoidei submentales
• Nodi lymphoidei submandibulares
• Nodi lymphoidei linguales

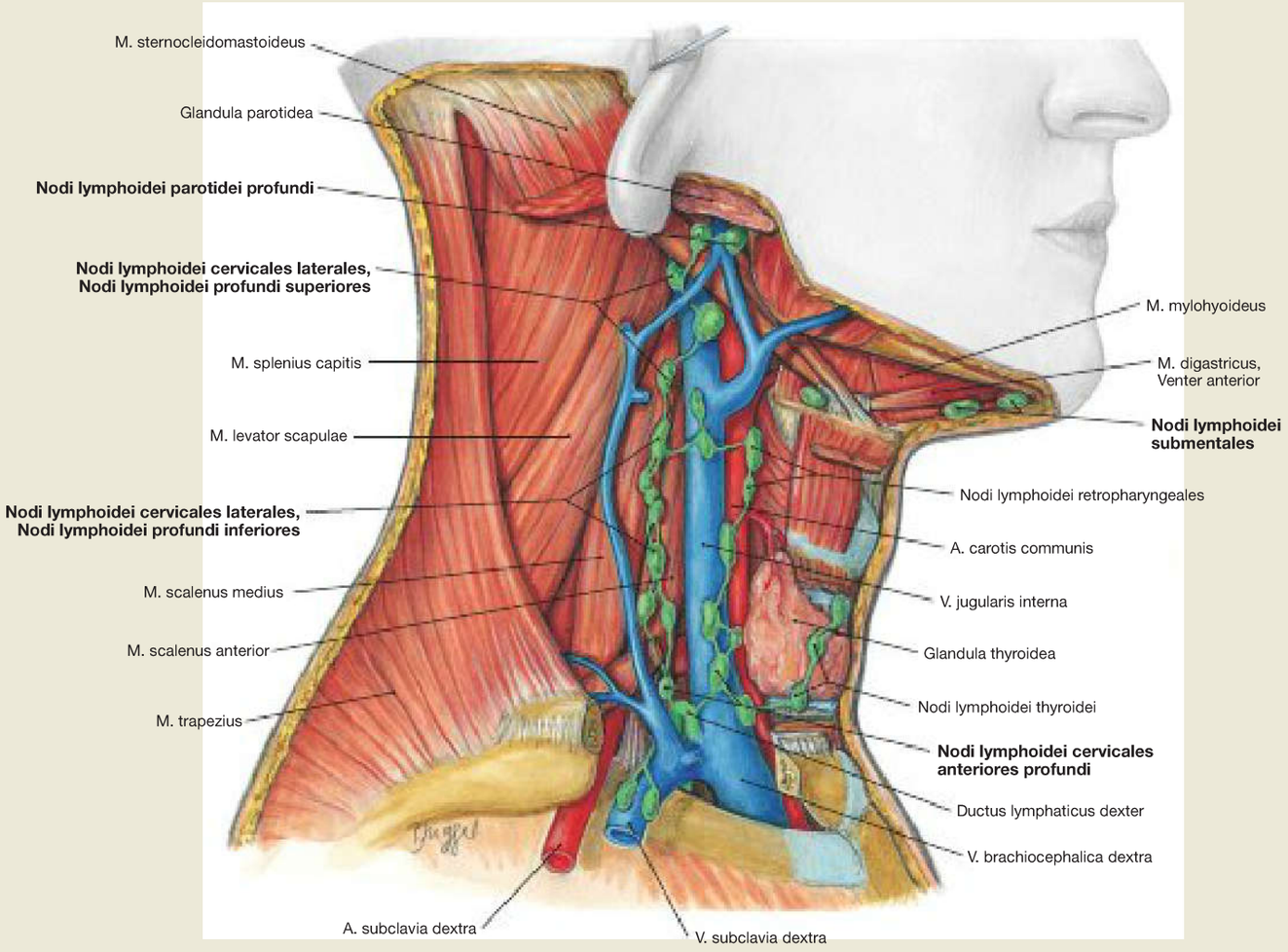

Fig. 8.99 Deep cervical lymph nodes, Nodi lymphoidei cervicales profundi, right side; lateral view.
Both the anterior cervical lymph nodes (Nodi lymphoidei cervicales anteriores) and the lateral cervical lymph nodes (Nodi lymphoidei cervicales laterales) are divided into superficial and deep lymph nodes.
The deep **anterior** cervical lymph nodes (Nodi lymphoidei cervicales anteriores profundi) include the Nodi lymphoidei infrahyoidei with the Nodi lymphoidei prelaryngei, the Nodi lymphoidei thyroidei, Nodi lymphoidei pretracheales, Nodi lymphoidei paratracheales and Nodi lymphoidei retropharyngeales.
The deep **lateral** cervical lymph nodes (Nodi lymphoidei cervicales laterales profundi) include a **superior group** (Nodi lymphoidei profundi superiores) consisting of the Nodus lymphoideus jugulodigastricus, Nodus lymphoideus lateralis and Nodus lymphoideus anterior, as well as an **inferior group** consisting of the Nodus lymphoideus juguloomohyoideus, Nodus lymphoideus lateralis and Nodi lymphoidei anteriores. There are also Nodi lymphoidei supraclaviculares and Nodi lymphoidei accessorii (along the N. accessorius [XI]) with Nodi lymphoidei retropharyngeales.

Nasal Skeleton

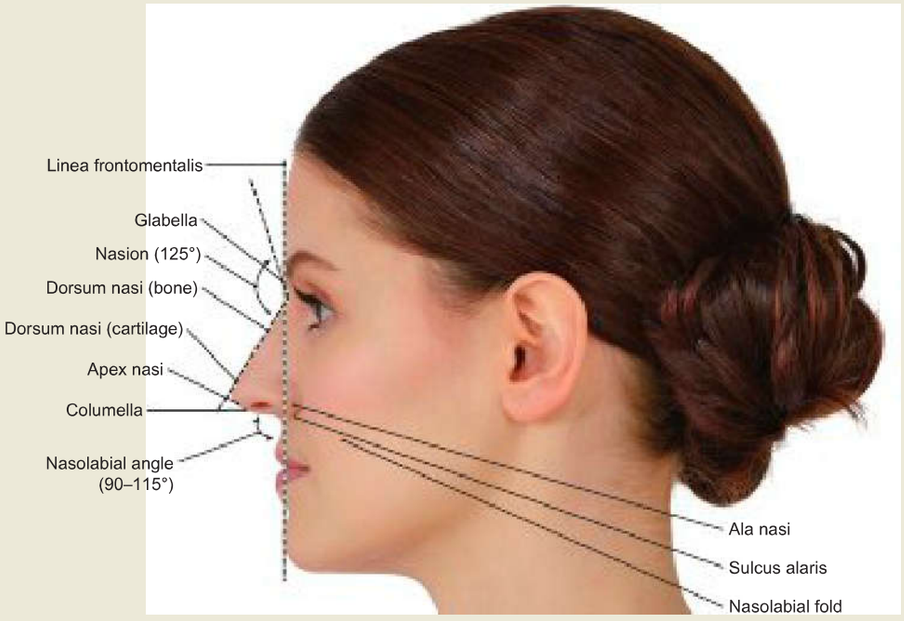

Fig. 8.100 Outer nose with aesthetic angles and orientation points; view from the left side. [J803]
The outer nose has a great impact on the shape of the face. A distinction is made between:

- Base (or root) of nose (Radix nasi) above the philtrum (Sulcus nasolabialis)
- Dorsum of nose (Dorsum nasi)
- Left and right alae of nose (Alae nasi dextra and sinistra)
- Tip of nose (Apex nasi)
- Membranous part of the nasal septum (Pars membranacea septi nasi, Columella, Pars mobilis septi)
- Nostril (Naris, paired)

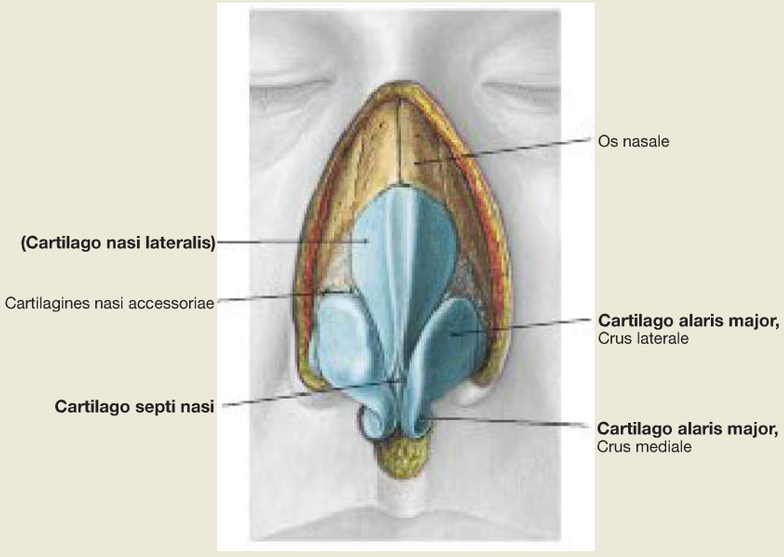

Fig. 8.101 Nasal skeleton; frontal view.
The nasal skeleton consists of a bony and a cartilaginous portion. The cartilaginous portion is attached to the Apertura piriformis between the Os nasale and maxilla via the associated connective tissues. The individual elements consist of hyaline cartilage and are linked via connective tissue. The roof is formed by the **upper lateral or triangular cartilage** (Cartilago nasi lateralis, Cartilago triangularis), and the ala is formed by **cartilage** from the **tip of nose or major alar cartilage** (Cartilago alaris major) with a Crus laterale and a Crus mediale. On each side there are often two smaller **alar cartilages** (Cartilagines alares minores). Below and centrally, the nasal skeleton is supported by the cartilaginous portion of the nasal septum (Cartilago septi nasi).

Nasal Skeleton and Nasal Septum

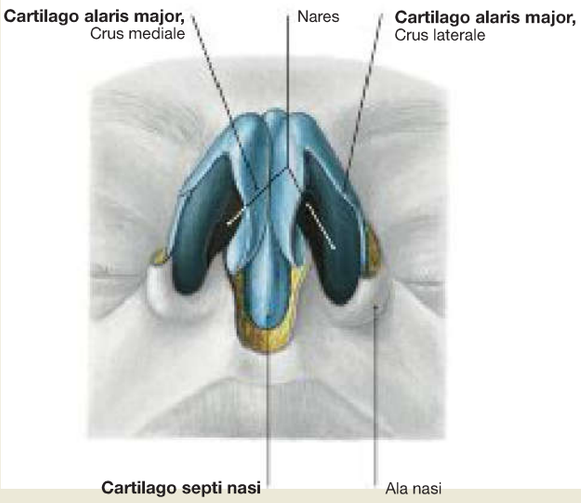

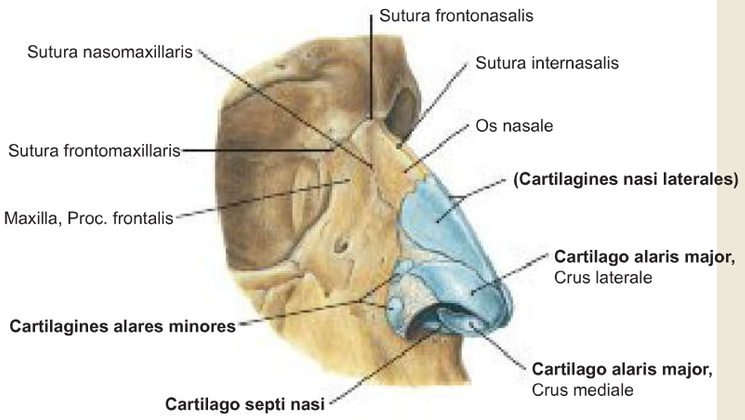

Fig. 8.102 Nasal cartilages, Cartilagines nasi; view from below.
The view from below shows the nasal orifices (Nares) which are delineated by the two crura (Crus mediale and Crus laterale) of the Cartilago alaris major. At the bottom in the centre, you can see the Cartilago septi nasi.

Fig. 8.103 Nasal skeleton; frontal view from the right.
The cartilaginous nasal skeleton is fixed at the Apertura piriformis by connective tissue. You can see the Cartilagines nasi laterales, alares majores, alares minores and the Cartilago septi nasi. Connective tissue is found in cartilage-free areas.

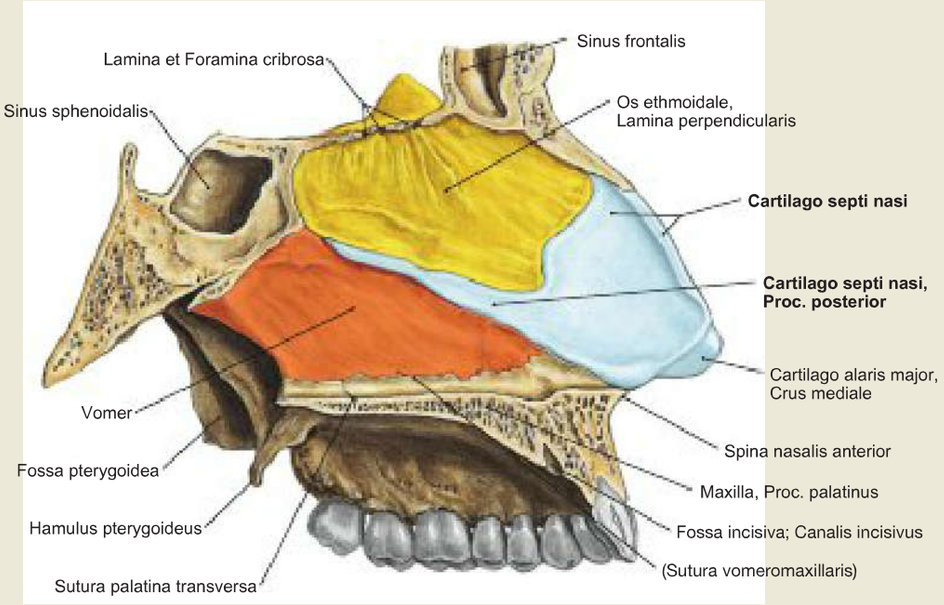

Fig. 8.104 Nasal septum, Septum nasi; view from the right side; for colour chart see p. VIII.
The nasal septum is formed at the front by the Cartilago septi nasi which extends with a long Proc. posterior between the bony nasal septum (above), consisting of the Lamina perpendicularis of the Os ethmoidale, and the Vomer (below).

Clinical Remarks

Some specific clinical terms are often used: **columella** (Pars anterior of the nasal septum between the tip of nose and the philtrum), **keystone area** (where the Os nasale overlaps the lateral cartilages), **soft triangle** (skin area at the upper rim of the nostril, close to the point where the Crus mediale bends to become the Crus laterale; this **cartilage-free area** is composed exclusively of a skin duplicature), **supratip area** (on the bridge of nose just above the tip), and **weak triangle** (similar to the supratip area since here the bridge of nose is exclusively formed by the septum). These areas are considered as 'critical' points for plastic surgery.
In the case of a **nasal septal haematoma** (e. g. after a nasal fracture), immediate relief is required in the form of a puncture and, if necessary, with an incision and nasal tamponade, otherwise the septum cartilage is at risk of being destroyed.

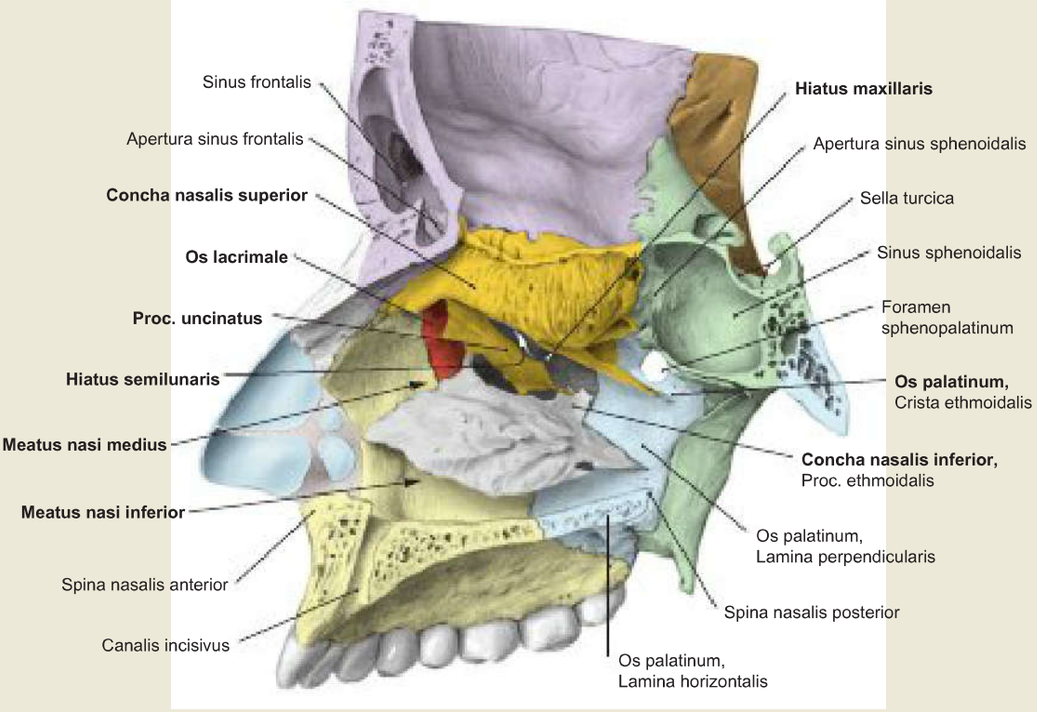

Fig. 8.105 Bony structures of the lateral wall of the nose, Cavitas nasi, without middle nasal concha; view from the left side; for colour chart see p. VIII.
The lateral wall of the nasal cavity has a complex and variable structure. The most prevalent topography is shown. The bony elements are:

- Frontal:
  - Os nasale
  - Facies nasalis maxillae
  - Os lacrimale
- In the middle:
  - Corpus maxillae with Hiatus maxillaris
  - Os ethmoidale with Proc. uncinatus (a thin lamellar bone), the bony wall to the anterior and posterior ethmoidal cells (Cellulae ethmoidales anteriores and posteriores) and the superior and middle nasal conchae (Conchae nasales superior and media). The middle nasal concha is not shown (→ Fig. 8.106)
  - Concha nasalis inferior
- Posterior:
  - Lamina perpendicularis of the Os palatinum
  - Lamina medialis of the Proc. pterygoideus ossis sphenoidalis

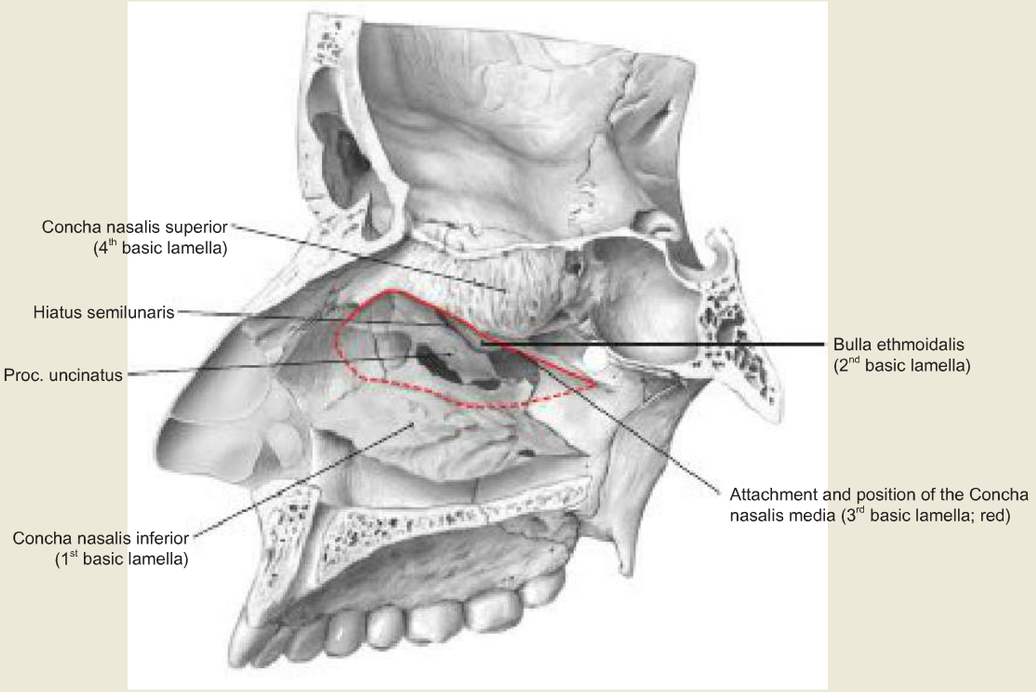

Fig. 8.106 Bony structures of the lateral wall of the nose, Cavitas nasi, without middle nasal concha; view from the left side.

The relatively complex anatomy of the Hiatus semilunaris and the area surrounding it below the middle nasal concha, is described by the term **osteomeatal complex.** In doing so, the access to the Sinus maxillaris (via the Hiatus maxillaris) is usually only partially closed by three structures:

- **Proc. uncinatus** – a thin lamellar bone of the Os ethmoidale, which closes the Hiatus maxillaris partially. It forms part of the medial wall of the Sinus maxillaris. At the superior edge of the Proc. uncinatus remains a crescent-shaped smooth cleft called the **Hiatus semilunaris.** Below the Proc. uncinatus there are usually also some openings that are normally covered by the nasal mucosa, but can also remain as openings. They are referred to as the anterior and posterior fontanelles.
- In front of and below the Proc. uncinatus it is bordered by the Os lacrimale and the Concha nasalis inferior.
- From behind and above, an often enlarged or pronounced anterior ethmoidal cell protrudes into and in front of the Hiatus maxillaris, which is called the **Bulla ethmoidalis.** It confines the Hiatus semilunaris from behind and above.

Clinical Remarks

From a surgical perspective, a distinction is made between the four **basic lamellae (BL)** of the lateral nasal wall. This relates to bony lamellae, which are found within the Os ethmoidale as embryological residues. 1st BL – Proc. uncinatus; 2nd BL – Bulla ethmoidalis; 3rd BL – Concha nasalis media; 4th BL – Concha nasalis superior. The structures of the **osteomeatal complex** are extraordinarily important in clinical terms, not only with regard to ventilation, but also for the drainage of the paranasal sinuses. In **endonasal sinus surgery,** this is the central surgical access route, e. g. in the treatment of chronic sinusitis or polyposis nasi.

Nasal Cavity

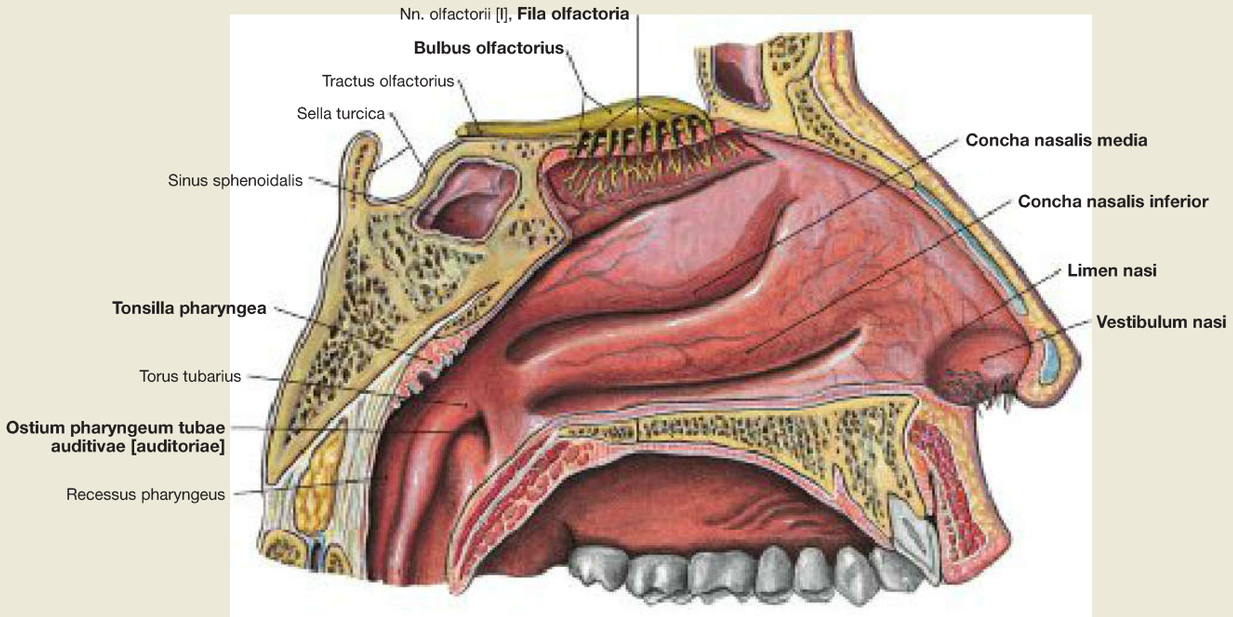

Fig. 8.107 Lateral wall of the nasal cavity, Cavitas nasi, left side; view from the right side.
The lateral nasal wall is largely occupied by the inferior nasal concha **(Concha nasalis inferior)** and the middle nasal concha **(Concha nasalis media).** The superior nasal concha (Concha nasalis superior) is small. It is related to the olfactory epithelium of the roof of nose. Here, the Fila olfactoria of the Bulbus olfactorius pass through the Lamina cribrosa and extend into the neighbouring mucosa, including the mucosa of the upper nasal concha.
The **Vestibulum nasi** is lined by keratinised squamous epithelium. At the Limen nasi, the epithelial layer transforms into nonkreatinised stratified squamous epithelium and then into ciliated pseudostratified columnar epithelium. The Concha nasalis inferior projects to the Ostium pharyngeum of the Tuba auditivas. Above it, the Tonsilla pharyngea sits at the roof of the pharynx.

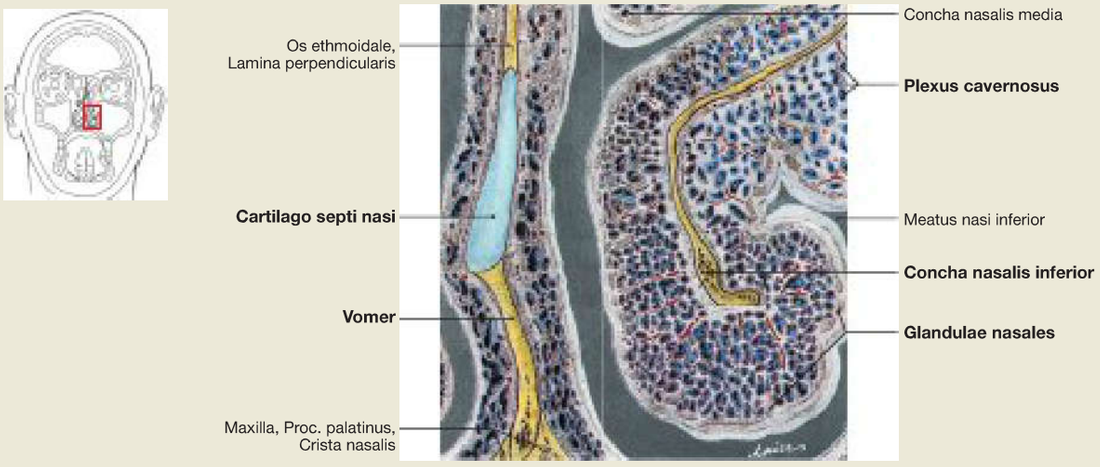

Fig. 8.108 Inferior nasal concha, Concha nasalis inferior, left side; frontal section at the level of the initial part of the Proc. posterior of the Cartilago septi nasi; frontal view.
This section demonstrates the thin bony skeleton of the Concha nasalis inferior, which is covered by a vascular plexus (Plexus cavernosus) composed of a network of specialised arteries and veins. Located on the surface of the nasal concha is the ciliated epithelium with embedded serous glands (Glandulae nasales).

Clinical Remarks

A characteristic feature of the nasal mucosa is a dense subepithelial plexus of venous sinusoids. Depending on the particular state of swelling, approximately 35% of the nasal mucosa is composed of vascular plexuses. The highest density of venous sinusoids is found in the lower and middle nasal conchae, as well as in the KIESSELBACH's area of the nasal septum.

In approximately 80% of people, a so-called **nasal cycle** can be detected. The nasal mucosa of both nasal passages swells and subsides for two to seven hours with alternating airway resistance during nasal breathing in a ratio of 1:3, but with unchanged overall resistance.

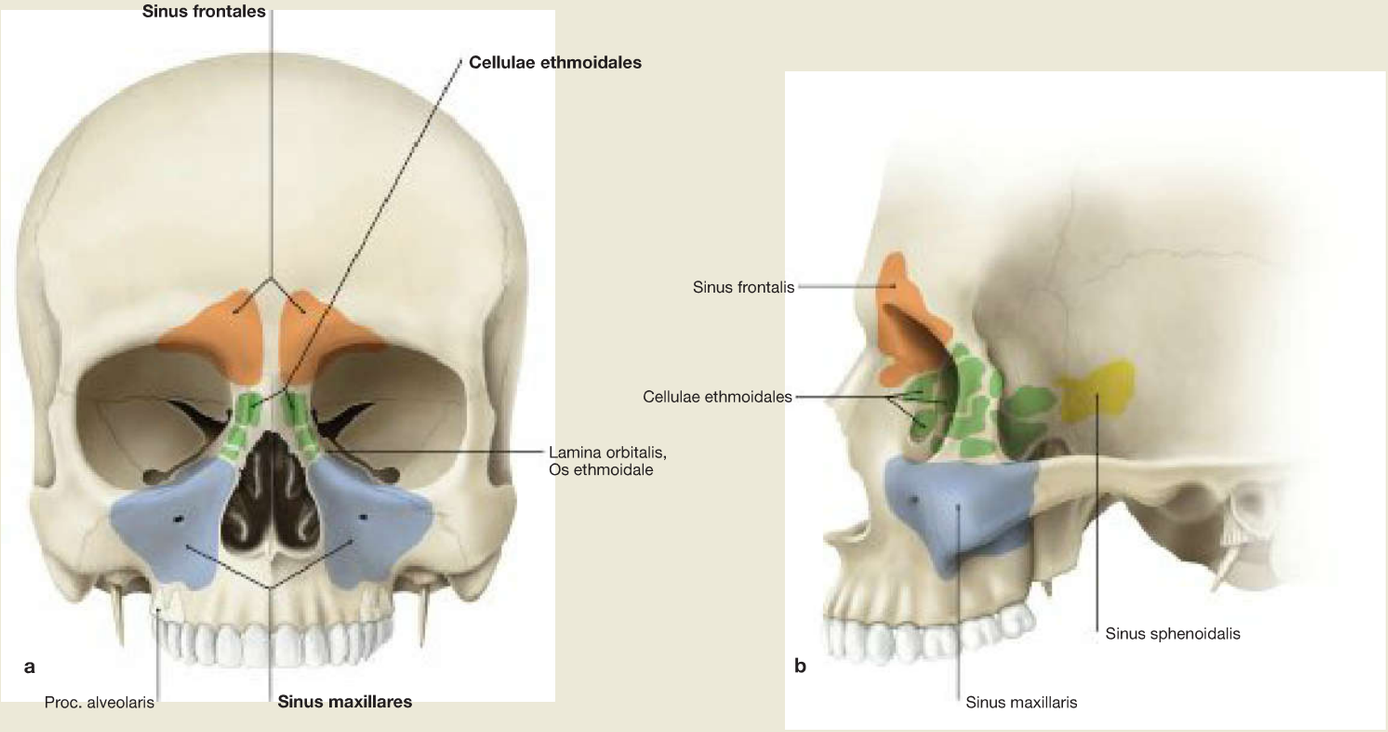

Fig. 8.109a and b Projection of the sinuses onto the skull; frontal view **(a),** lateral view **(b).** [L275]

As the formation of the sinuses is extremely variable, individual cavities can be missing.

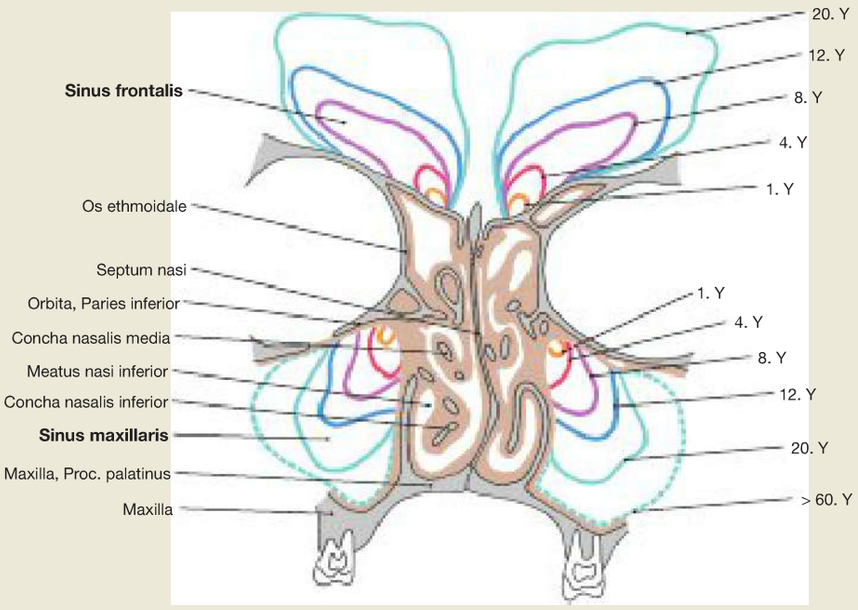

Fig. 8.110 Development of the maxillary and frontal sinuses. [L238] Y: year of life.

The Sinus frontalis forms and reaches the rim of the Orbita by approximately the age of five.

Orifices of the Sinuses

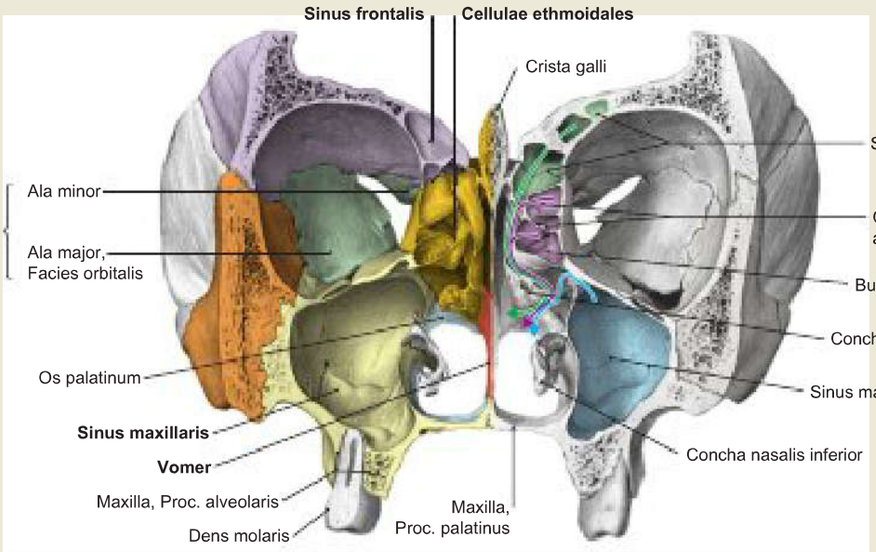

Fig. 8.111 Bony topography (right calvaria) and orifices of the paranasal sinuses (left calvaria); frontal section through the viscerocra-nium; for colour chart see p. VIII.
The Sinus frontalis (green), the anterior ethmoidal cells (Cellulae ethmoidales anteriores, purple) and the Sinus maxillaris (blue) open via the Hiatus semilunaris into the middle nasal passage. On the left side of the skull, the close relationship between the tooth root and the Sinus maxillaris can be seen in the section through the maxilla.

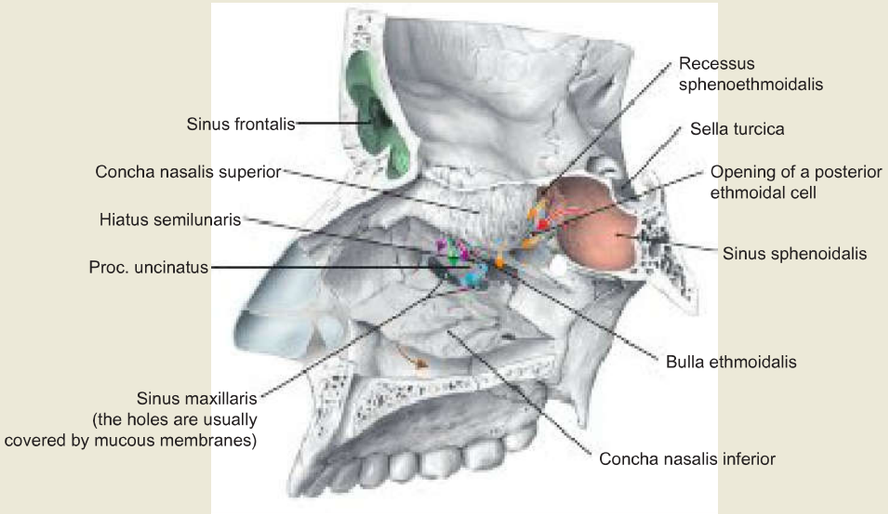

Fig. 8.112 Orifices of the paranasal sinuses and the Ductus nasolacrimalis in the lateral nasal wall. View from the left side.
Arrows: brown = Ductus nasolacrimalis; green = Sinus frontalis; purple = anterior ethmoidal cells; blue = Sinus maxillaris; orange = posterior ethmoidal cells; red = Sinus sphenoidalis. The Sinus sphenoidalis has a close topographical relationship to the Sella turcica, in which the pituitary gland (Glandula pituitaria) is located. The Ductus nasolacrimalis opens into the lower nasal passage via the Plica lacrimalis (HASNER's valve). The middle nasal concha is not shown. As a result, the Hiatus semilunaris is visible. The Bulla ethmoidalis lies above it and the Proc. uncinatus lies below it. Behind the upper nasal concha, the Recessus sphenoethmoidalis is located at the orifice of the Sinus sphenoidalis (Apertura sinus sphenoidalis, red arrow).

Orifice Points of the Paranasal Sinuses and the Nasolacrimal Ducts

Structure	Lower nasal passage	Medium nasal passage	Upper nasal passage
Ductus nasofrontalis	X		
Sinus frontalis		X	
Cellulae ethmoidales anteriores		X	
Cellulae ethmoidales posteriores			X
Sinus maxillaris		X	
Sinus sphenoidalis			X

Clinical Remarks

The **Sinus sphenoidalis** may extend into large parts of the sphenoidal bone. In the case of surgical interventions, the extensive pneumatisation of the Sinus sphenoidalis can endanger the A. carotis interna (Tuberculum arteriae carotidis internae) and the N. opticus [II] because of their close relationship to the lateral sinus wall.

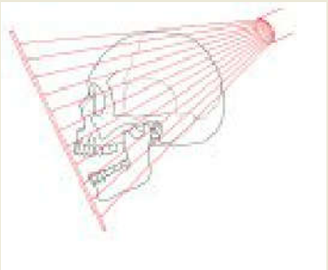

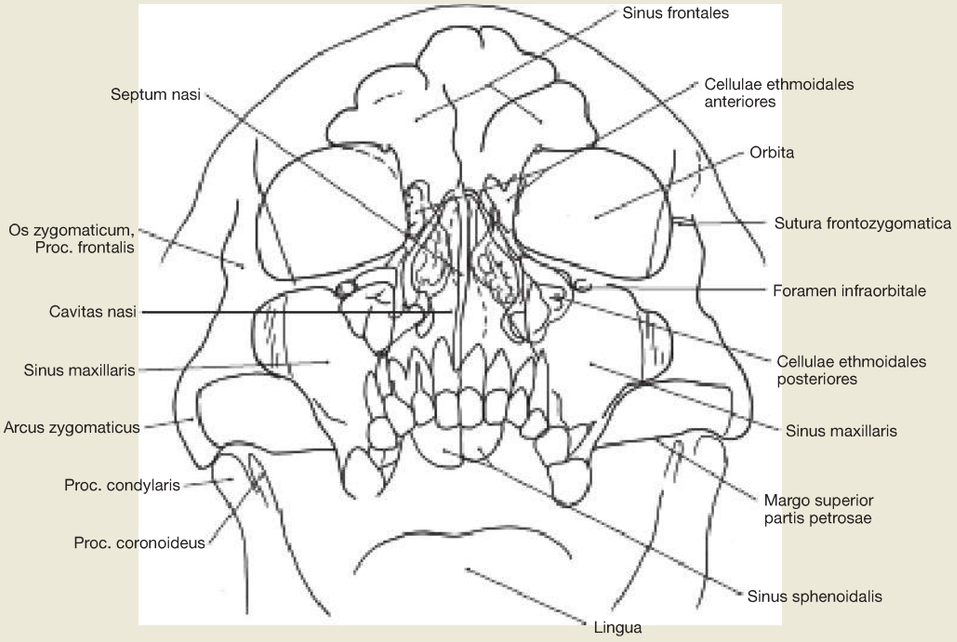

Fig. 8.113 Paranasal sinuses, Sinus paranasales; X-ray of the skull with opened mouth in posterior-anterior (PA) beam projection [T895].

Clinical Remarks

Conventional X-ray images are useful for rapid orientation on the sinus system, but are increasingly rarely carried out. They have been replaced by computed tomography and magnetic resonance imaging for establishing surgical indications.
Sinusitis is a common disease. In children, it is most often due to an inflammation of the ethmoidal cells, while in adults the Sinus maxillaris is most frequently affected. Inflammation of the ethmoidal cells can penetrate the thin Lamina orbitalis (papyracea) of the Os ethmoidale into the Orbita, or can spread in the posterior region of the ethmoidal cells or the Sinus maxillaris into the Canalis opticus and damage the optic nerve.

Sinuses

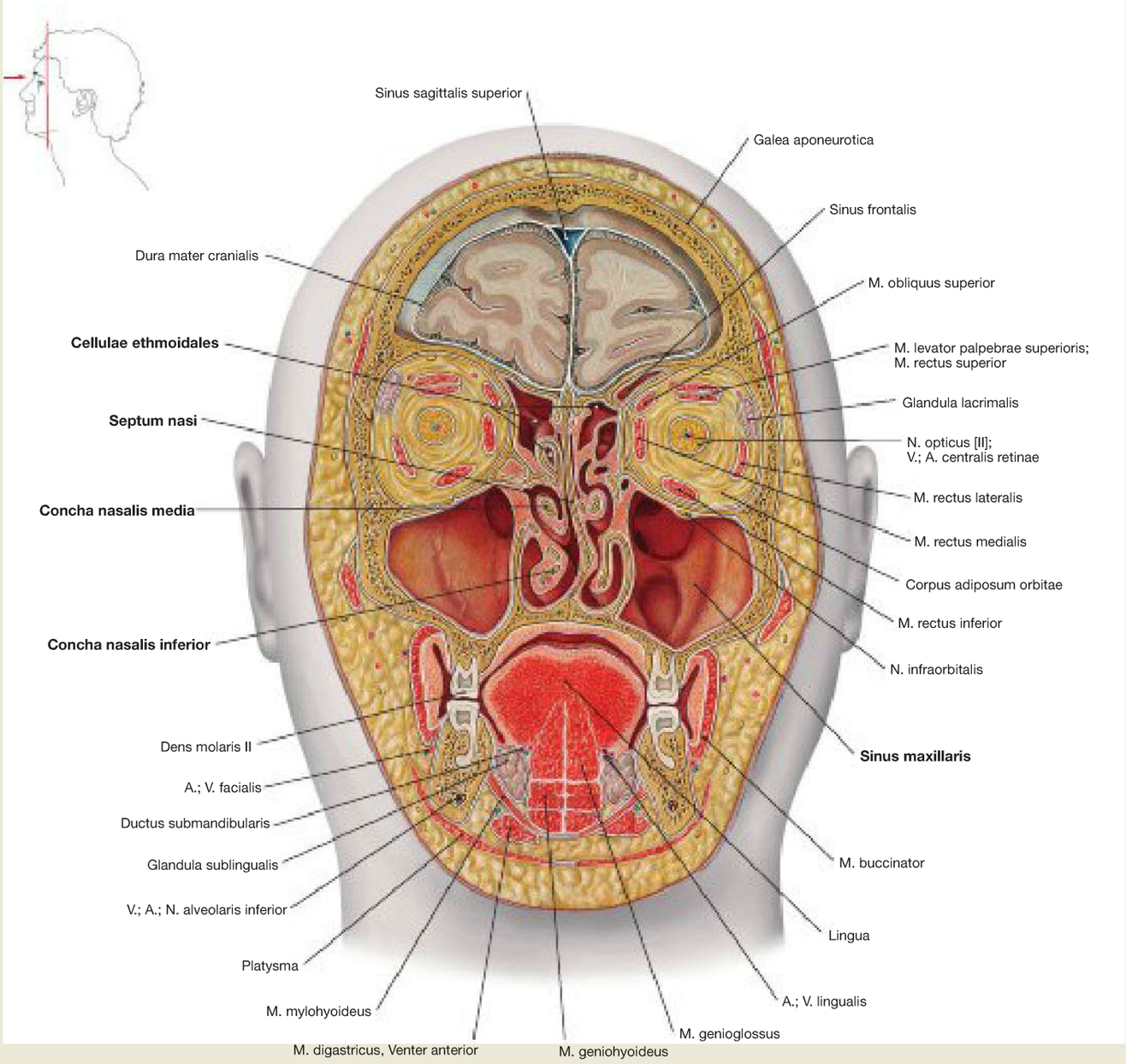

Fig. 8.114 Frontal section through the head at the level of the second upper molars; frontal view. [L238]
This section emphasises the individual bilateral differences in the formation of the paranasal sinuses. The Sinus maxillares are formed differently on both sides and have variable chambers. The nasal septum is shifted to the left (nasal septum deviation). As a result, the lower and middle nasal conchae are developed more strongly on the right than on the left. The ethmoidal cells are also formed differently on the right and left. On the left side, in the supraorbital region, parts of the Sinus frontalis are visible.

Clinical Remarks

In the case of **nasal septum deviation** nasal breathing may be so severely restricted that headaches, hyposmia or even anosmia may occur. Formation of the paranasal sinuses is extremely variable. This accounts for interindividual and lateral differences to the point that individual sinuses are completely lacking **(aplasia).**

However, individual sinuses can reach extreme sizes. If the Sinus frontalis extends in an occipital direction well beyond the orbital roof **(Recesses supraorbitalis),** the clinician refers to it as a dangerous frontal sinus. An inflammatory process of the frontal sinus can overcome the thin bony barrier and can spread into the anterior cranial fossa and lead to meningitis, epidural abscesses, or even brain abscesses.

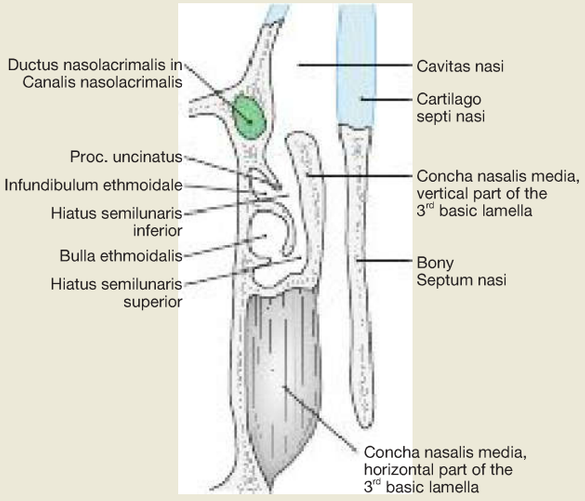

Fig. 8.115 Topography of the sinuses. Horizontal section through the nasal septum and osteomeatal complex of the left side of the nose just above the Concha nasalis inferior. [L126]
The Ductus nasolacrimalis has close topographical relationships to the Sinus maxillaris laterally, and to the sinuses medially. Just behind the head of the middle turbinate, from front to back, can be found the Proc. uncinatus, Hiatus semilunaris and Bulla ethmoidalis.

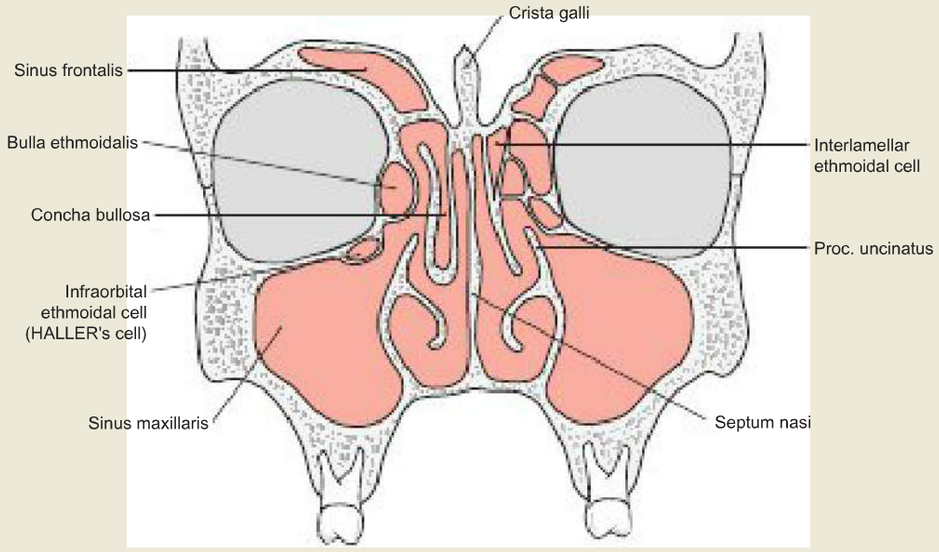

Fig. 8.116 Topography and variants of the ethmoidal cells, Cellulae ethmoidales; frontal section through the viscerocranium. [L126]
Anatomical variants occur regularly in the anterior ethmoidal bone. An infraorbital ethmoidal cell (HALLER's cell) pneumatises the orbital wall; a Concha bullosa pneumatises the bone of a nasal concha (usually the middle nasal concha is affected).

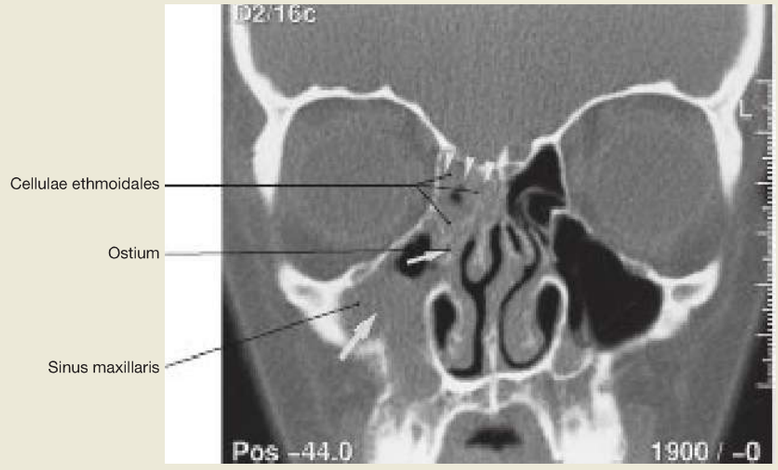

Fig. 8.117 Chronic sinusitis; coronal computed tomography (CT) scan of the paranasal sinuses. White arrows indicate a swelling of the inflamed mucosa in the right Sinus maxillaris and the ostium, while white arrow heads point to a swelling of the ethmoidal cells. [17] [T720]

Clinical Remarks

The Meatus nasi medius is the endonasal access route in paranasal surgery for the treatment of a chronic inflammation of the frontal or maxillary sinus and anterior ethmoidal cells. One-sided **inflammation of the Sinus maxillaris** is often odontogenic (maxillary odontogenic sinusitis). Commonly, the cause is an inflammation of the second premolar or the first molar (→ Fig. 8.41).

Topography of the Sinuses

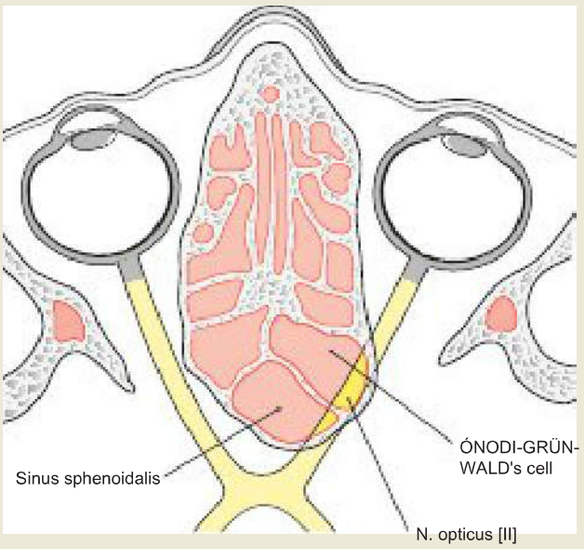

Fig. 8.118 Topography and variants of the ethmoidal cells, Cellulae ethmoidales; horizontal section through the Os ethmoidale at the level of the Canalis opticus. [L126]

If an ÓNODI-GRÜNWALD´s cell develops, the Sinus sphenoidalis lies partially below this posterior sphenoidal cell. It often has a close relationship with the N. opticus [II].

Sinuses – Commonly Used Clinical Terms	
Agger nasi	An anterior ethmoidal cell in front of and above the attachment of the middle nasal concha
Atrium meatus medii	Region in front of the middle nasal passage above the head of the Concha nasalis inferior
Bulla ethmoidalis	An anterior ethmoidal cell above the Hiatus semilunaris, which very regularly develops, but can also be missing
Fontanelle	Accessory opening in the medial wall of the Sinus maxillaris that is covered by mucous membrane
Basic lamellae	Lamellae within the Os ethmoidale as embryological residues. **Four basic lamellae** (BL) can be distinguished: • 1st BL: Proc. uncinatus • 2nd BL: Bulla ethmoidalis • 3rd BL: Concha nasalis media • 4th BL: Concha nasalis superior
HALLER's cell	An ethmoidal cell pneumatising the lower orbital wall (infraorbital cell)
Hiatus maxillaris	A large opening of the Sinus maxillaris into the nasal cavity, which is partially closed by the Proc. uncinatus of the Os ethmoidale, as well as by the mucous membrane
Hiatus semilunaris	A crescent-shaped and up to 3 cm wide cleft between the Bulla ethmoidalis and the upper free margin of the Proc. uncinatus; the Hiatus semilunaris provides access to the Infundibulum ethmoidale
Infundibulum ethmoidale	Space delineated by the Proc. uncinatus, the Lamina papyracea and the Bulla ethmoidalis
ÓNODI-GRÜNWALD's cell	A posterior ethmoidal cell which protrudes backwards over the Sinus sphenoidalis
Osteomeatal complex	General term for the complicated anatomy of the Hiatus semilunaris and its surroundings
Proc. uncinatus	A thin lamellar bone of the Os ethmoidale participating in the formation of the medial wall of the Sinus maxillaris and confining the Hiatus semilunaris at its anteroposterior aspect
Recessus frontalis	Cleavage space or gap connecting the frontal sinus and nasal cavity (Ductus nasofrontalis, Canalis nasofrontalis)
Sulcus olfactorius	A groove or canal between the anterior attachment of the Concha nasalis media at the cranial base and the roof of nose

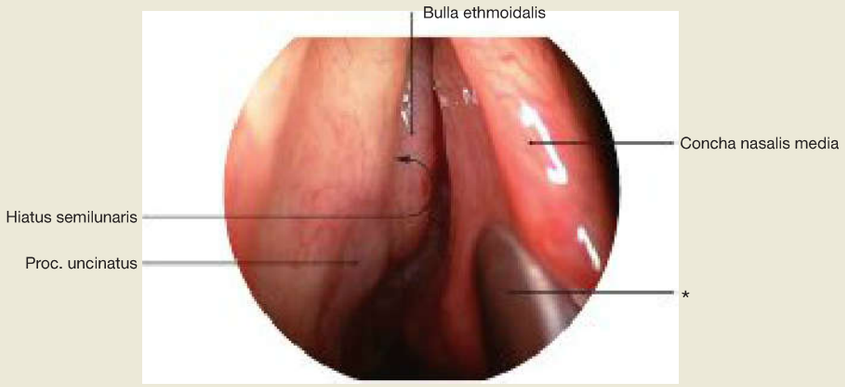

Fig. 8.119 Nasal cavity, Cavitas nasi, left side; transnasal endoscopy with a 30° endoscope. [T720]

The examiner views the head of the middle nasal concha (Concha nasalis media).

* Antrum curette

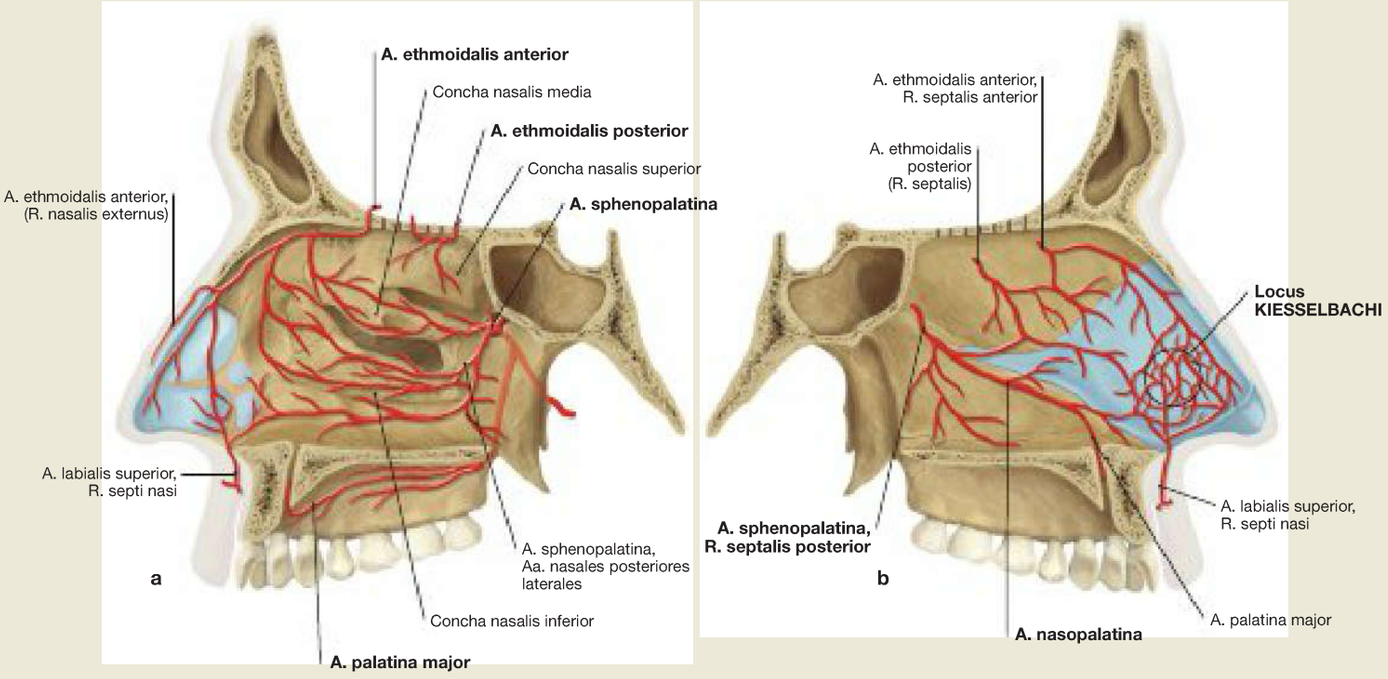

Fig. 8.120a and b Arteries of the nasal cavity. [L284]
a Lateral wall of the right nasal cavity
b Nasal septum of the right nasal cavity
The A. carotis externa and A. carotis interna provide the arterial supply of the nose.
A. carotis interna: the **Aa. ethmoidales anterior** and **posterior** run from the ophthalmic artery through the anterior and posterior Os ethmoidale to reach the lateral nasal wall and the nasal septum.
A. carotis externa: as a terminal branch of the A. maxillaris, the **A. sphenopalatina** enters the nasal cavity via the Foramen sphenopalatinum. There are anastomoses between the blood vessels of the lip and the facial artery. On the nasal septum, the **A. nasopalatina** branches off the A. sphenopalatina, which enters the oral cavity via the Canalis incisivus and anastomoses with the A. palatina major. Together with the Aa. ethmoidales anterior and posterior, the A. nasopalatina feeds KIESSELBACH's plexus, which is an arteriovenous plexus.

Clinical Remarks

The most frequent location for **nasal bleeding** (epistaxis) is the KIESSELBACH's plexus at the nasal septum.
Fractures of the base of skull in the area of the Lamina cribrosa can cause ruptures of the Aa. ethmoidales anterior and/or posterior with consecutive nosebleeds.

If, in the event of life-threatening bleeding, a nasal tamponade is not successful, the A. sphenopalatina must be ligated.

Veins of the Nasal Cavity

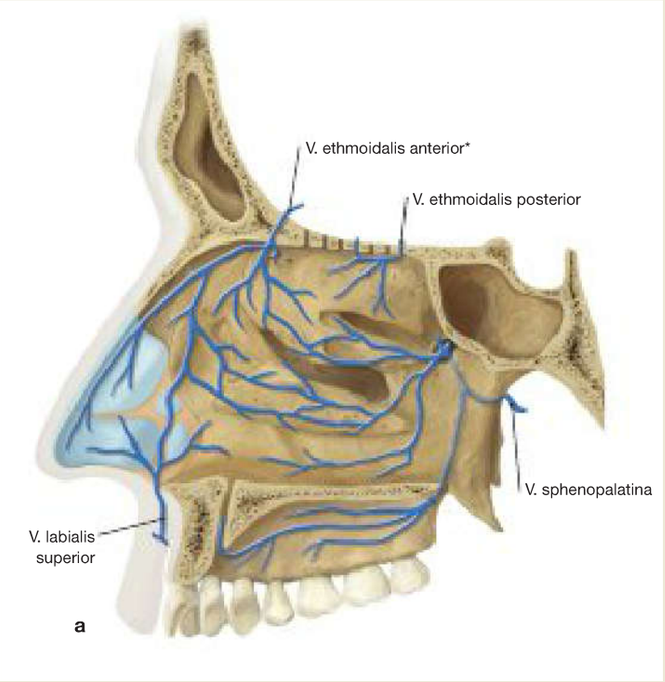

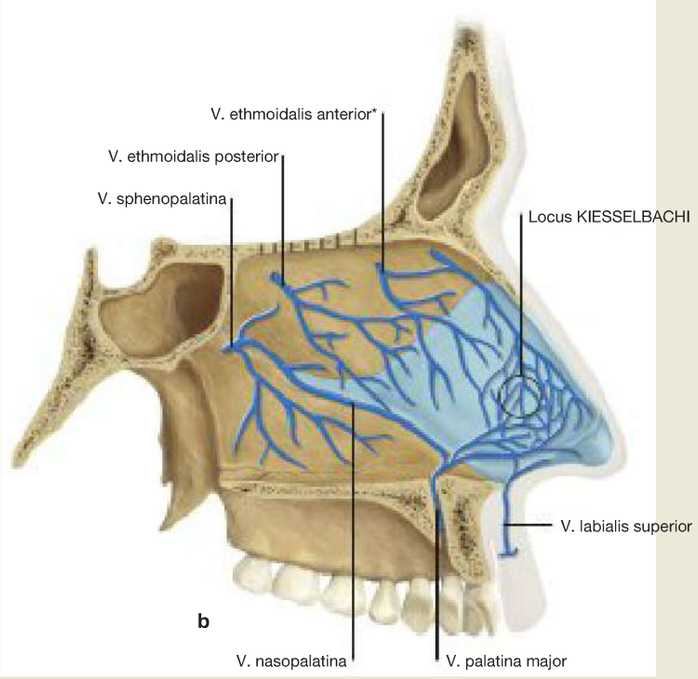

Fig. 8.121a and b Veins of the nasal cavity. [L284]
a Lateral wall of the right nasal cavity
b Nasal septum of the right nasal cavity
The blood is drained via the **Vv. ethmoidales anterior** and **posterior** to the Sinus cavernosus at the base of the skull, via the **V. sphenopalatina** to the Plexus pterygoideus in the Fossa infratemporalis, and via the connection to the **Vv. labiales** into the V. facialis.

* connecting vein to the Sinus sagittalis superior via the Foramen caecum (only present during childhood)

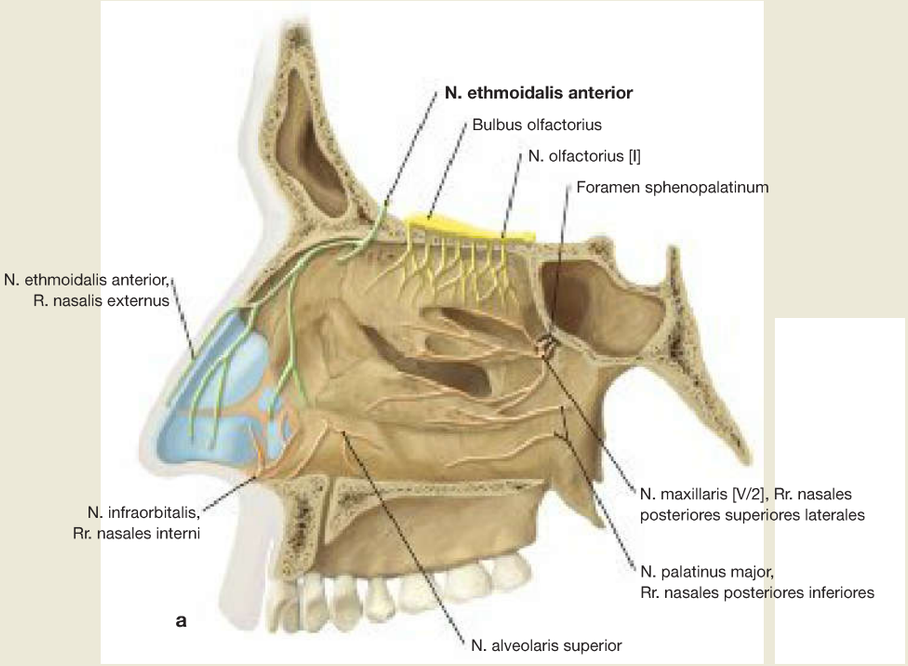

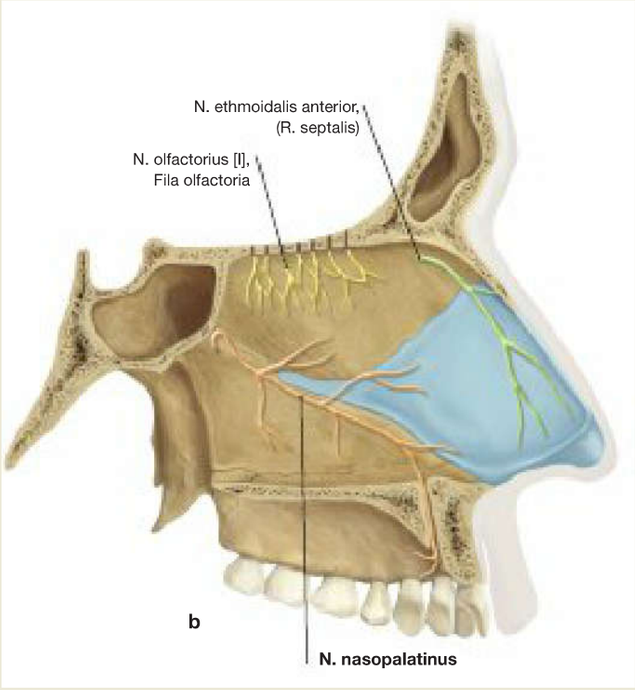

Fig. 8.122a and b Innervation of the nasal cavity. [L284]
a Lateral wall of the right nasal cavity
b Nasal septum of the right nasal cavity
The sensory innervation of the nasal mucosa is provided by branches of the N. trigeminus [V]: N. ophthalmicus [V/1] → N. ethmoidalis anterior, and N. maxillaris [V/2] → Rr. nasales, N. nasopalatinus. The olfactory epithelium is innervated by the **N. olfactorius [I].** Along the nasal septum runs the **N. nasopalatinus,** which passes through the Canalis incisivus and innervates the mucosa of the hard palate in the area on the backside of the incisors as far as to the canine.

Clinical Remarks

The sensory innervation of the nasal mucosa is extremely good. Each manipulation in the nose can therefore be very painful.
Damage (rupture) of the Fila olfactoria within the context of a traumatic brain injury, may result in **anosmia** (the patient can no longer smell).

Tearing (rupture) of the dura mater can cause a **rhinorrhoea of cerebrospinal fluid.** A clear transparent fluid (= CSF, cerebrospinal fluid) drops from the nose of the patient. The diagnosis can be confirmed by the detection of glucose, using glucose test strips. Due to the risk of infection, surgical care is mandatory.

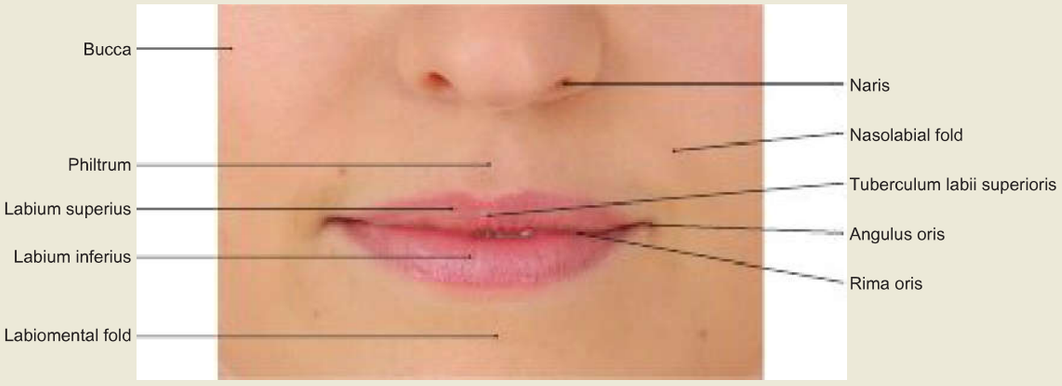

Fig. 8.123 Oral fissure, Rima oris; frontal view.
The entrance to the mouth is closed by the lips. Since the epithelium of the lips is thin and not pigmented, and the connective tissue papillae that are richly vascularised with capillaries are located close to the free surface, the blood in the papillae shimmers through the skin and causes the red colour of the lips (vermilion). The margin of the upper lip has a depression lying below the columella of the nose, the philtrum, which ends as a lip protuberance or torus, the Tuberculum labii superioris.

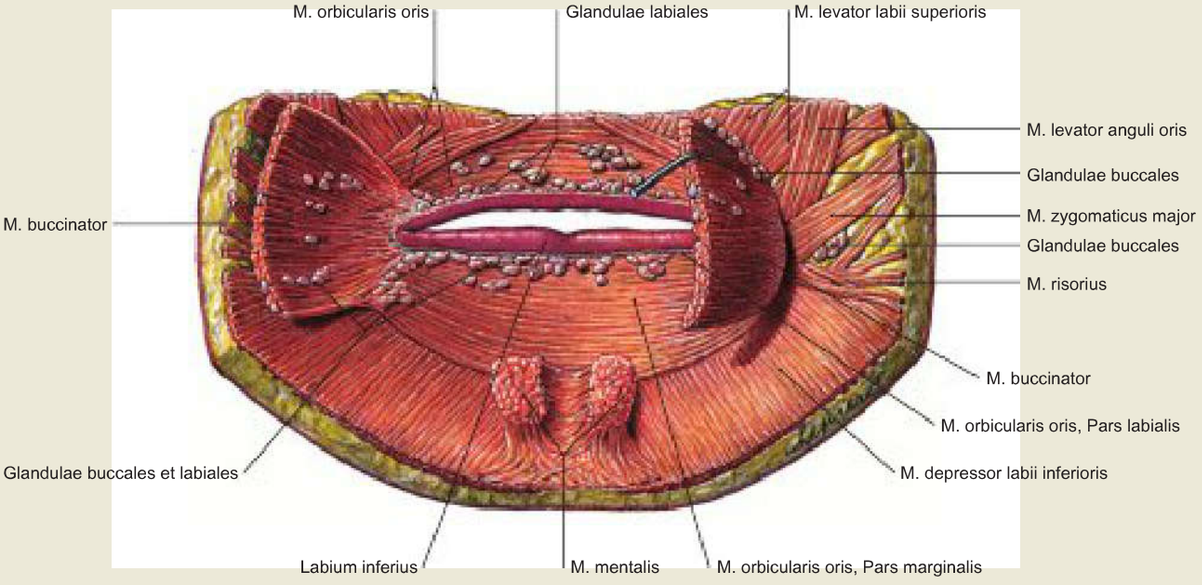

Fig. 8.124 Muscles of the oral region, Regio oralis; intraoral view.
The mucosa is removed; small salivary glands are partially preserved. The base of the lips is the Pars labialis of the transversely striated M. orbicularis oris. Its Pars marginalis bends outwards below the prolabium and under the skin, and fans out into other mimetic muscles. In the submucosa, below the M. orbicularis oris, are lots of small, mixed seromucous salivary glands (Glandulae labiales). In contrast, the small Glandulae buccales around the M. buccinator produce a mucoserous secretion.

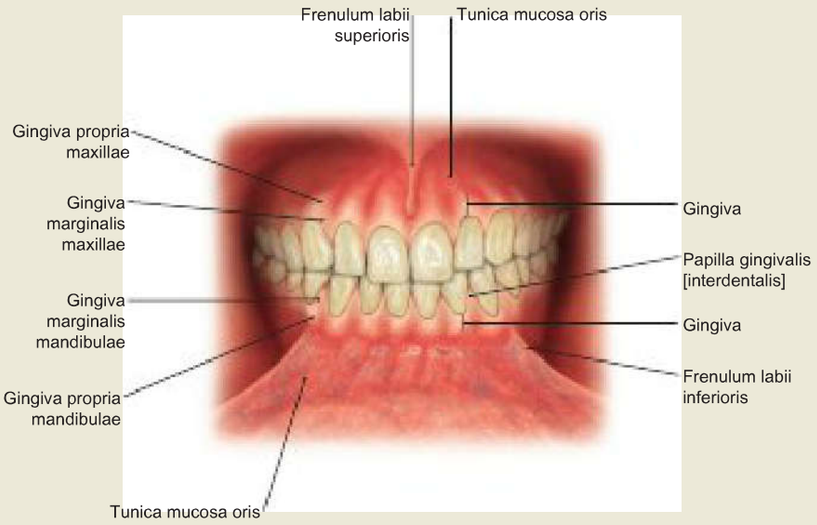

Fig. 8.125 Oral vestibule, Vestibulum oris, with gums, Gingiva, and oral mucosa; frontal view. [L127]
The lips are fixed by connective tissue. The upper lip is fixed via the Frenulum labii superioris that runs in the midline, the lower lip is fixed via the paired Frenulum labii inferioris, which passes on both sides to the oral mucosa, usually between the canines and first premolars. The gums extend up to the cervix of the teeth as the Gingiva marginalis, which is movable and forms the Sulcus gingivalis between the teeth. The non-movable Gingiva propria connects to the Gingiva marginalis and covers the Proc. alveolaris of the Maxilla and Mandibula, respectively. It continues into the oral mucosa.

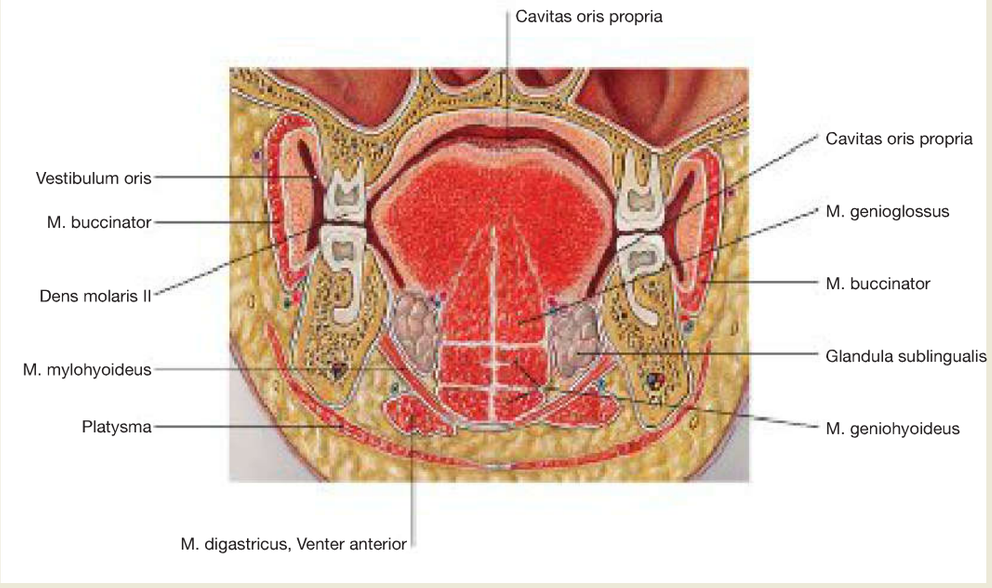

Fig. 8.126 Frontal section through the oral cavity at the level of the second molars; frontal view. [L238]
The oral vestibule (Vestibulum oris) is bordered at the front by the lips, on both sides by the cheeks, as well as inside and outside by the Procc. alveolares and the teeth. The mouth cavity is the Cavitas oris propria. With a closed mouth, it is almost completely filled by the tongue. Its roof is formed by the palate, and its floor is the floor of the mouth.

Clinical Remarks

To create a genetic fingerprint, e.g. in the context of analysing relationships (paternity test) or to detect criminal offences, a **mouth smear** is taken. For this purpose, sterile buccal swab is used to obtain mucosal cells from the inside of the cheek, from which DNA is then extracted and analysed.
Keratinisation disorders with cellular and epithelial atypia of the usually pink oral mucosa lead to white mucosal changes **(leukoplakia).** If they cannot be wiped off, they are referred to as **precarcinoma,** which are classified as premalignant diseases of the oral mucosa and require immediate histopathological evaluation and, if necessary, surgical removal. If, on the other hand, the white plaques can be wiped away, they are usually due to **fungal infections** (most commonly *candida albicans*), which can be treated with medication.

Oral Cavity

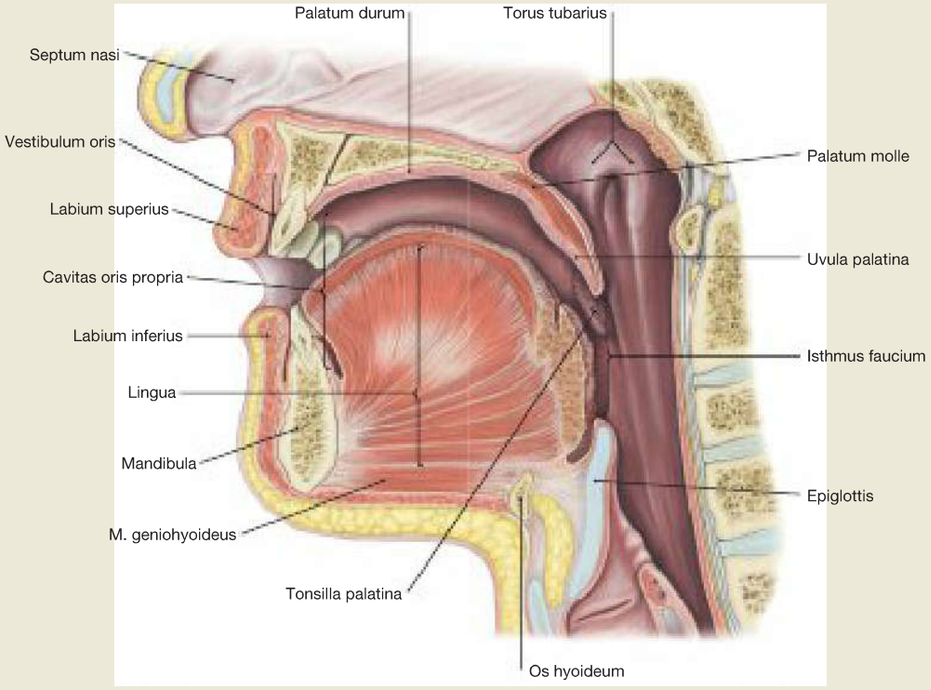

Fig. 8.127 Oral cavity, Cavitas oris, right side; view from the left side. Median sagittal section. [L285]
The Cavitas oris propria is filled by the body of the tongue. It is bordered by the teeth at the front and on both sides, and above by the hard and soft palate. Below, the tongue lies on the floor of the mouth. Anterior parts of the tongue muscles are fixed at the Mandibula.

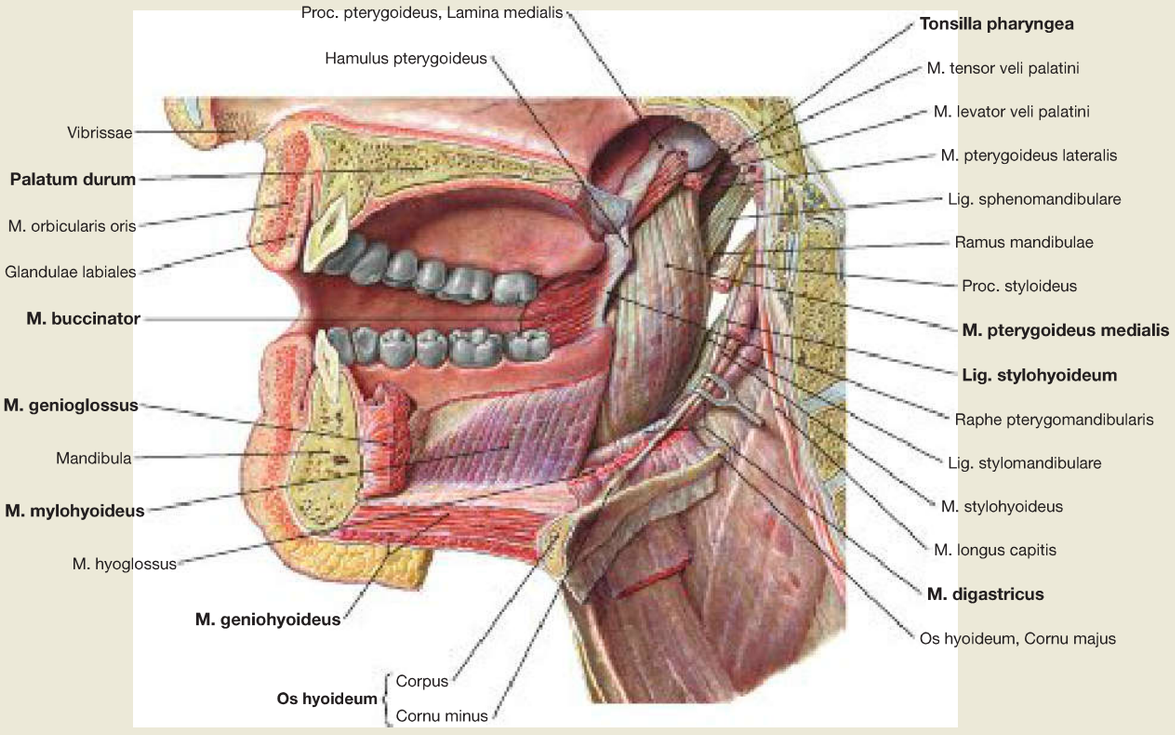

Fig. 8.128 Oral cavity, Cavitas oris, right side; view from the left side. The sagittal section is at the level of the first incisors.

On the side, the oral cavity is bordered by the cheek, on the top by the palate, and at the bottom by the muscles of the floor of the mouth.

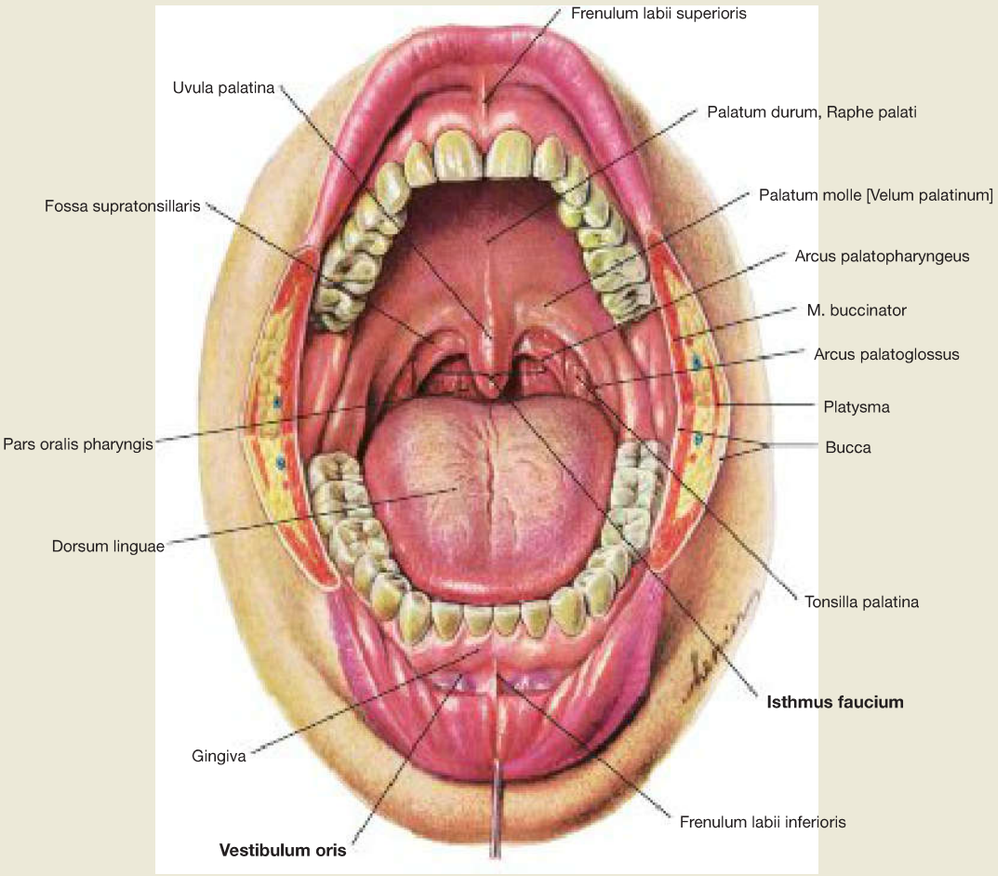

Fig. 8.129 Oral cavity, Cavitas oris; frontal view; mouth open.
The oral opening (Rima oris) represents the entrance to the digestive tract and the oral cavity. This is divided into the oral vestibule (Vestibulum oris), and the actual mouth called the Cavitas oris propria. The **Vestibulum oris** is bordered externally by the lips and cheeks and internally by the Procc. alveolares and the teeth. When the row of teeth is closed, there is a connection to the oral cavity behind the last tooth (Spatium retromolare). In the region of the oropharyngeal isthmus **(Isthmus faucium),** the oral cavity becomes the Pars oralis of the pharynx (oropharynx). Opening into the Vestibulum oris and the Cavitas oris propria are numerous (500–1,000) small excretory ducts and three paired large salivary glands. The inside of the oral cavity is filled for the most part by the tongue (Corpus linguae).

Dental Arches

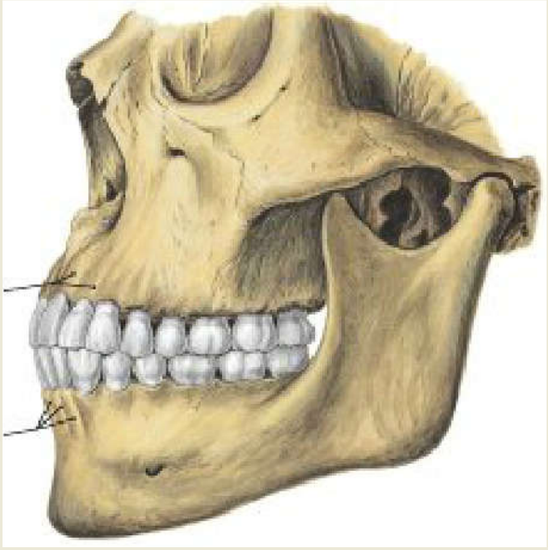

Fig. 8.130 Arcus dentales superior et inferior; in the viscerocranium of a 28-year-old; teeth in occlusion position; lateral view.
In the Proc. alveolaris, the roots of the teeth produce burr-shaped, vertically extending protrusions (Juga alveolaria). The teeth of the upper jaw are in the **occlusion position** above those of the lower jaw. They are arranged and displaced relative to each other so that the cusps of a tooth come to rest in the fissures of the two opposite teeth (cusp-fissures interlocking). In the upper jaw, each quadrant consists of a central incisor and a smaller lateral incisor, which often have pronounced marginal edges. The canine has the longest root and only one cusp. The two premolars have two cusps; the (distal) second premolar is usually a little bit smaller. The largest tooth is the first molar. It is marked by a mesiopalatinal cusp. The second molar is similar to the first, but is smaller. The third molar (wisdom tooth, Dens serotinus) is designed very differently and can also be missing (either not developed or not erupted). In the lower jaw, incisors and canine teeth are smaller. There are also two premolars. The first molar usually has five cusps, the second molar has four, and the third molar (wisdom tooth, Dens serotinus), as in the upper jaw, is very variable in terms of formation and can also be missing.

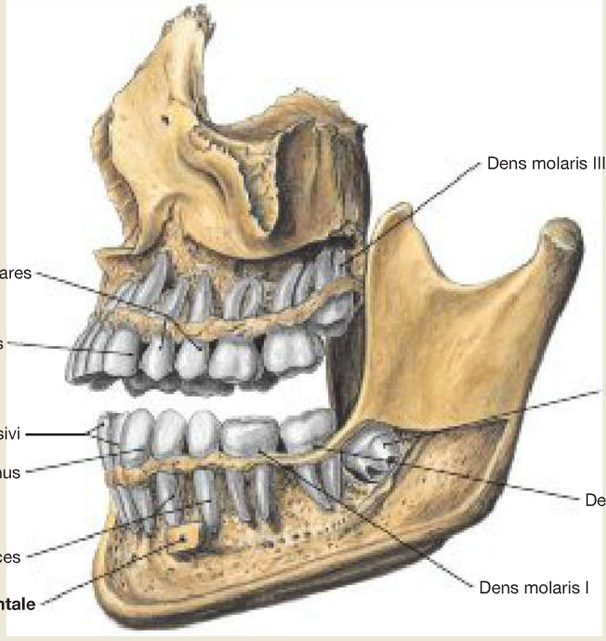

Fig. 8.131 Maxilla, and mandible, Mandibula, of a 20-year-old person.
Completion of the permanent dentition results in up to 32 permanent teeth (Dentes permanentes). The third molar (Dens molaris tertius, wisdom tooth, Dens serotinus) has not yet erupted in the Mandibula. It can be regressed or has not been developed at all (aplasia). Usually, the molar teeth erupt approximately seven months earlier in girls than in boys. In both sexes, the molar teeth in the lower jaw erupt earlier than molar teeth in the maxilla. The roots of the deciduous teeth require another 16 to 26 months to develop; the roots of the permanent teeth are fully developed only after another 1.7 to 3.5 years.

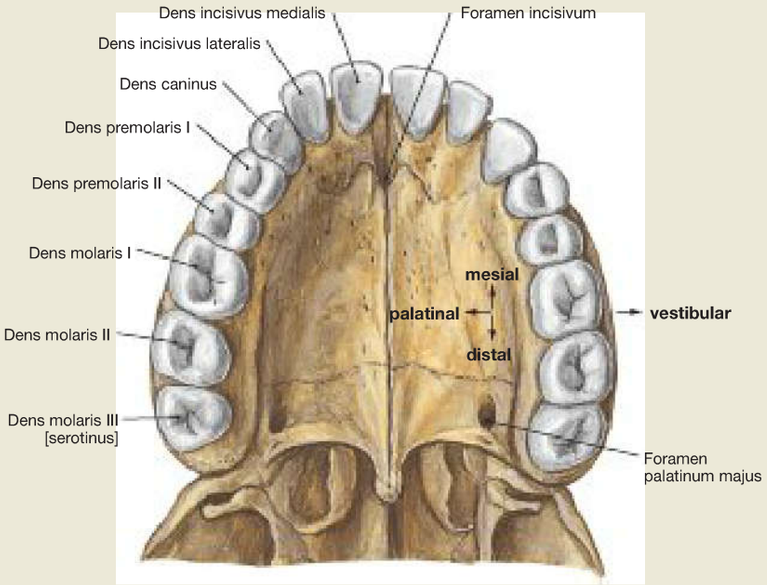

Fig. 8.132 Maxillary dental arch, Arcus dentalis maxillaris [superior].
The teeth (Dentes) are arranged in two dental arches, the upper (Arcus dentalis maxillaris or superior) and the lower dental arch (Arcus dentalis mandibularis or inferior), and are anchored in the upper and lower jaw. The dentition is **heterodontic** in humans; the teeth are shaped differently with distinct features, and thereby are categorised as incisors (Incisivi), canines (Canini), premolars (Premolares) and molars (Molares). Incisors and canine teeth are also called front teeth, whereas premolars and molars are lateral teeth.

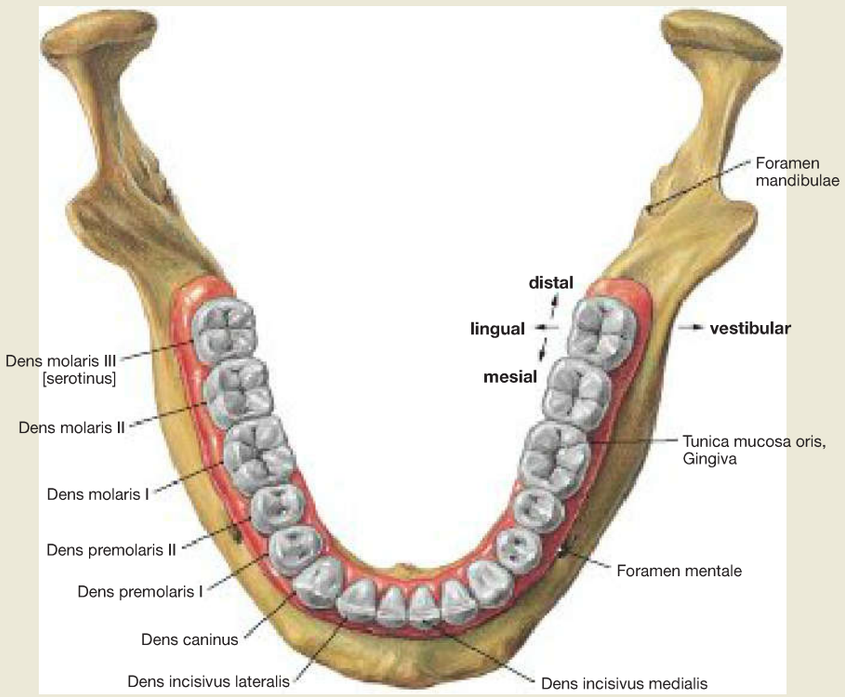

Fig. 8.133 Mandibular dental arch, Arcus dentalis mandibularis [inferior].
With one exception, the arrangement of teeth in the lower dental arch is similar to that in the upper dental arch. For a precise indication of the 'oral' topographical relationships, 'palatinal' is the term used in the upper jaw and 'lingual' in the lower jaw. The **Gingiva** is part of the oral mucosa, covers the Proc. alveolaris and also covers the alveolar bone as well as the interdental bony septa. Furthermore, it wraps around the cervix of the tooth and continues at the Margo gingivalis into the oral mucosa. The Gingiva supports the anchorage of the teeth and stabilises their position in the alveolar bone (Pars fixa gingivae); as part of the oral mucosa, the Gingiva marginalis forms the junctional epithelium attached to the dental surfaces.

Fig. 8.134 Incisor tooth, Dens incisivus. On each tooth, a distinction is made between the crown (Corona dentis), the neck or cervix (Cervix dentis) and the root (Radix dentis). The **dental crown** is the visible part of the tooth. It sticks out above the gums (Gingiva) and is covered by enamel (Enamelum). [L126]
The **root of the tooth** is placed in the tooth socket (Alveolus dentalis), which is the root compartment, a depression in the Proc. alveolaris of the maxilla or mandible; the root is covered by cement (Cementum). Periodontal fibres (periodontium, desmodontium) anchor the root of the tooth in the alveolar bone. The **dental cervix** is the area where the enamel and cement are adjacent to each other. This is where the gingiva is attached to the tooth.
The lowest point of the root is the **root apex** (Apex radicis dentis). The dental papilla (Papilla dentis) is perforated in the Foramen apicis by the root canal (Canalis radicis dentis) through which vessels and nerves enter the Cavitas dentis, consisting of the Cavitas pulparis and the Cavitas coronae.
The dental pulp (Pulpa dentis) consists of connective tissue, containing blood vessels, lymphatic vessels, and nerves, and thus nourishes the tooth. Here, too, a distinction is made between the root pulp (Pulpa radicularis) and the crown pulp (Pulpa coronalis). Collectively, the cement, desmodontium, alveolar bone, and parts of the gingiva are referred to as the parodontium.

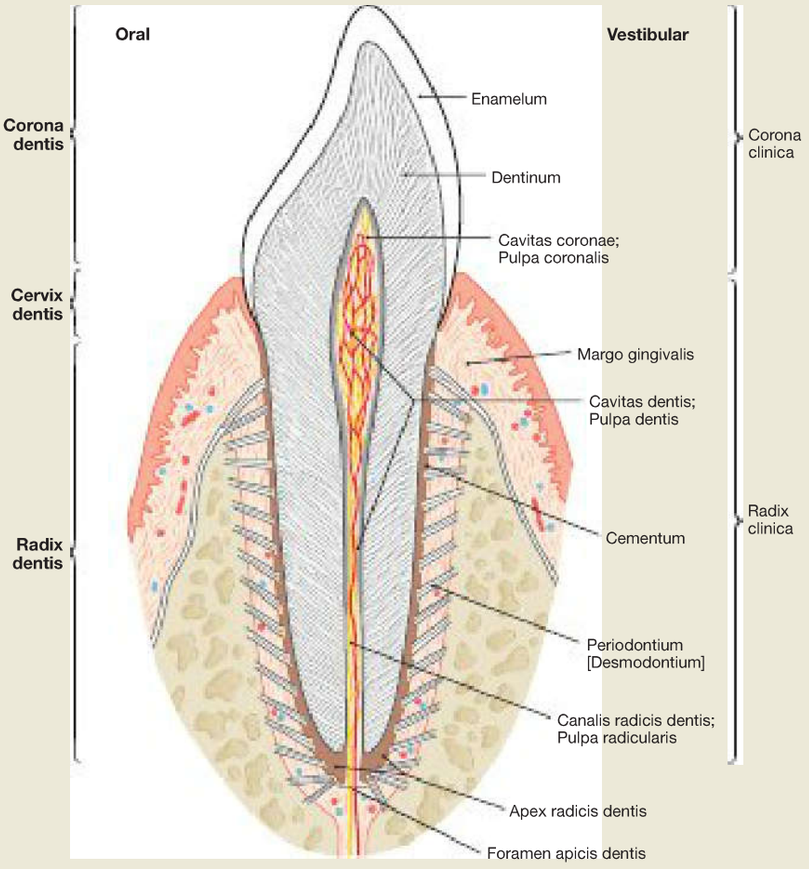

Fig. 8.135 Permanent canine tooth, Dens caninus permanens; example of a tooth with one root.

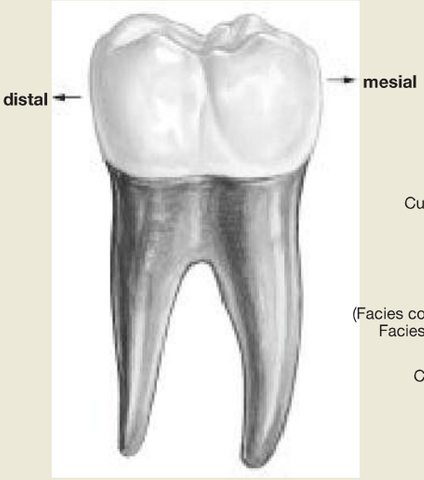

Fig. 8.136 Second deciduous molar tooth, Dens molaris deciduus; example of a tooth with two roots.

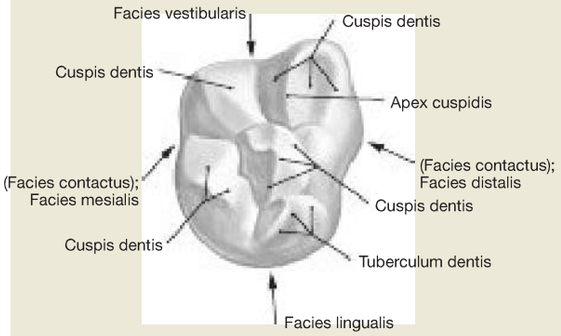

Fig. 8.137 First molar tooth, Dens molaris primus; occlusal surface of a molar tooth with the individual parts labelled.

Clinical Remarks

Form, arrangement and orientation rules
The **labelling of the surfaces** of the teeth is from the midline outwards. The part closest to the midline is referred to as mesial, and the part furthest away as distal. The contact areas of the teeth to neighbouring structures are defined as **surfaces** (Facies). Number, dimension, and form of the roots (Radices) are functionally adapted to the dental crown. The morphology of the roots of individual teeth in deciduous and permanent dentition is different and variable. Teeth with a single root are the incisors, canines and premolars. Teeth with two roots are the first upper premolars and the lower molars. Teeth with three roots are the upper molars.

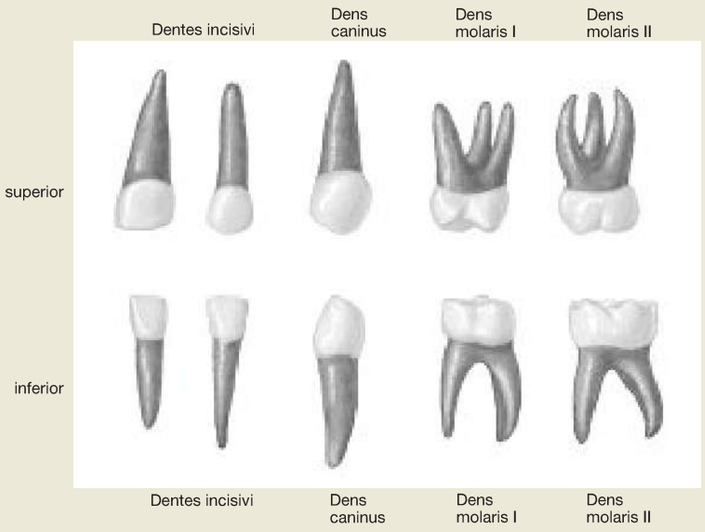

Fig. 8.138 Deciduous teeth, Dentes decidui, of a three-year-old child; view from vestibular.
A complete set of milk teeth is usually present by the age of 30 months.

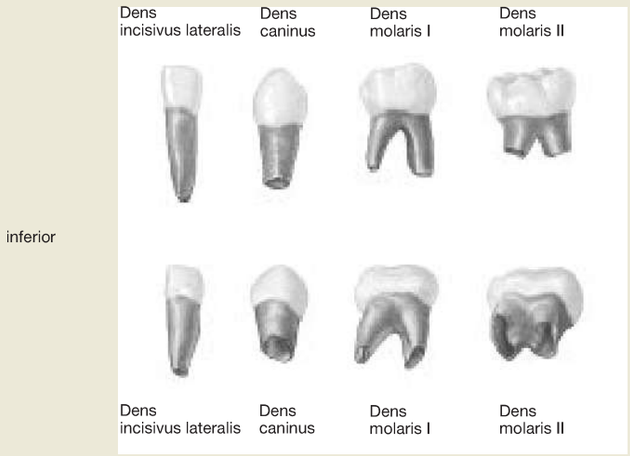

Fig. 8.139 Deciduous teeth, Dentes decidui, of a two-year-old child; upper row, view from vestibular; lower row, view from below in an oblique angle.

The medial incisors are not presented here. You can see that in a two-year-old child the root formation has not yet been completed in many teeth. This process is only complete after dental eruption.

Clinical Remarks

Dental formula

There is an internationally accepted dental formula which is applied by all disciplines of dental medicine. In doing so, each half of a jaw **(quadrant)** is given a number. Starting from the midline, **teeth** of the permanent and deciduous dentition are numbered consecutively from one to eight (permanent dentition) and from one to five (deciduous dentition), respectively. The number of the quadrant is followed by the number of the tooth. For example, the digits 11 (called: 'one-one') describe the first incisor in the right upper jaw of the permanent dentition; the digits 52 (called: 'five-two') describe the second incisor in the right upper jaw of the deciduous dentition.

Dental Formula of the Adult

Upper jaw

right	18	17	16	15	14	13	12	11	21	22	23	24	25	26	27	28	left
	48	47	46	45	44	43	42	41	31	32	33	34	35	36	37	38	

Lower jaw

Dental Formula of the Deciduous Dentition

Upper jaw

right	55	54	53	52	51	61	62	63	64	65	left
	85	84	83	82	81	71	72	73	74	75	

Lower jaw

Permanent Teeth

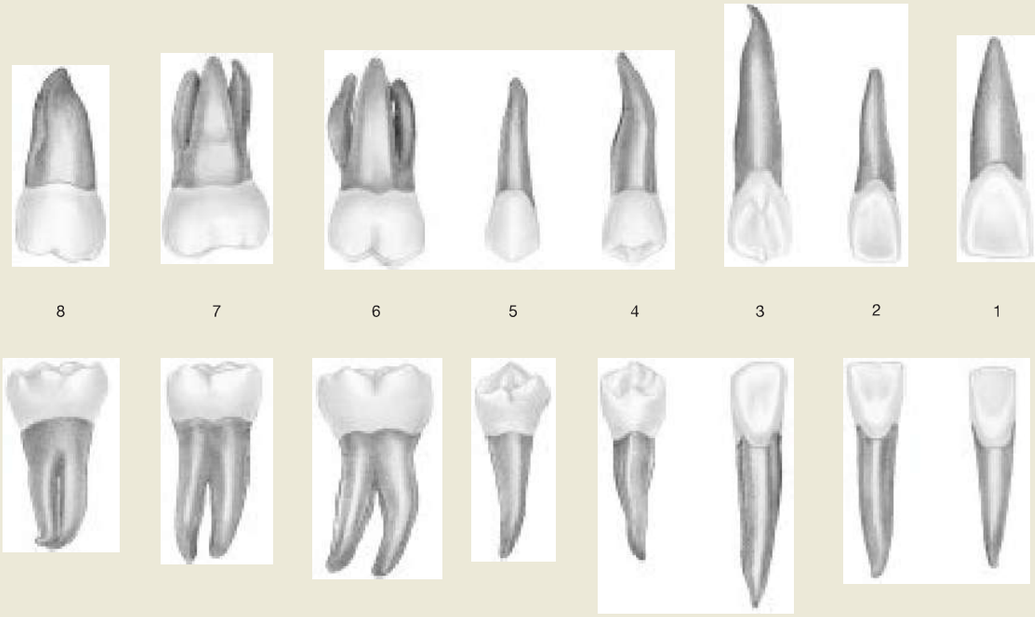

Fig. 8.140 Permanent teeth, Dentes permanentes; oral view.

1 Dens incisivus I
2 Dens incisivus II
3 Dens caninus
4 Dens premolaris I
5 Dens premolaris II
6 Dens molaris I
7 Dens molaris II
8 Dens molaris III (serotinus)

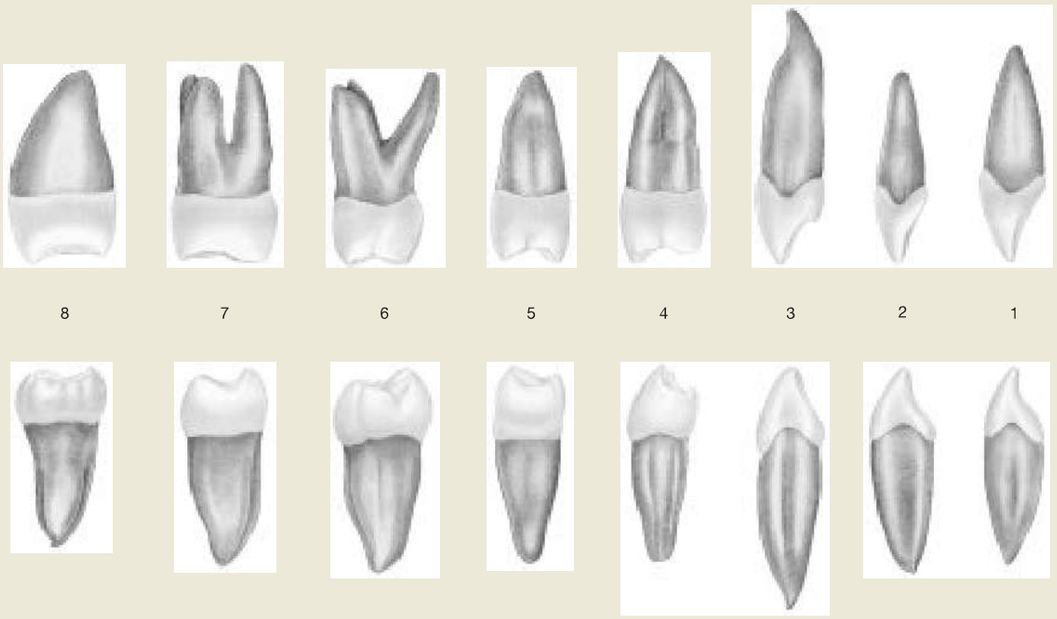

Fig. 8.141 Permanent teeth, Dentes permanentes; distal view.

1 Dens incisivus I
2 Dens incisivus II
3 Dens caninus
4 Dens premolaris I
5 Dens premolaris II
6 Dens molaris I
7 Dens molaris II
8 Dens molaris III (serotinus)

Clinical Remarks

In clinical terms, the back teeth are referred to as molars and those in front of them as premolars. Since the teeth are the most imperishable organs of the body and therefore particularly durable, they play an important role in **forensic medicine** in the identification of victims.

Permanent Teeth

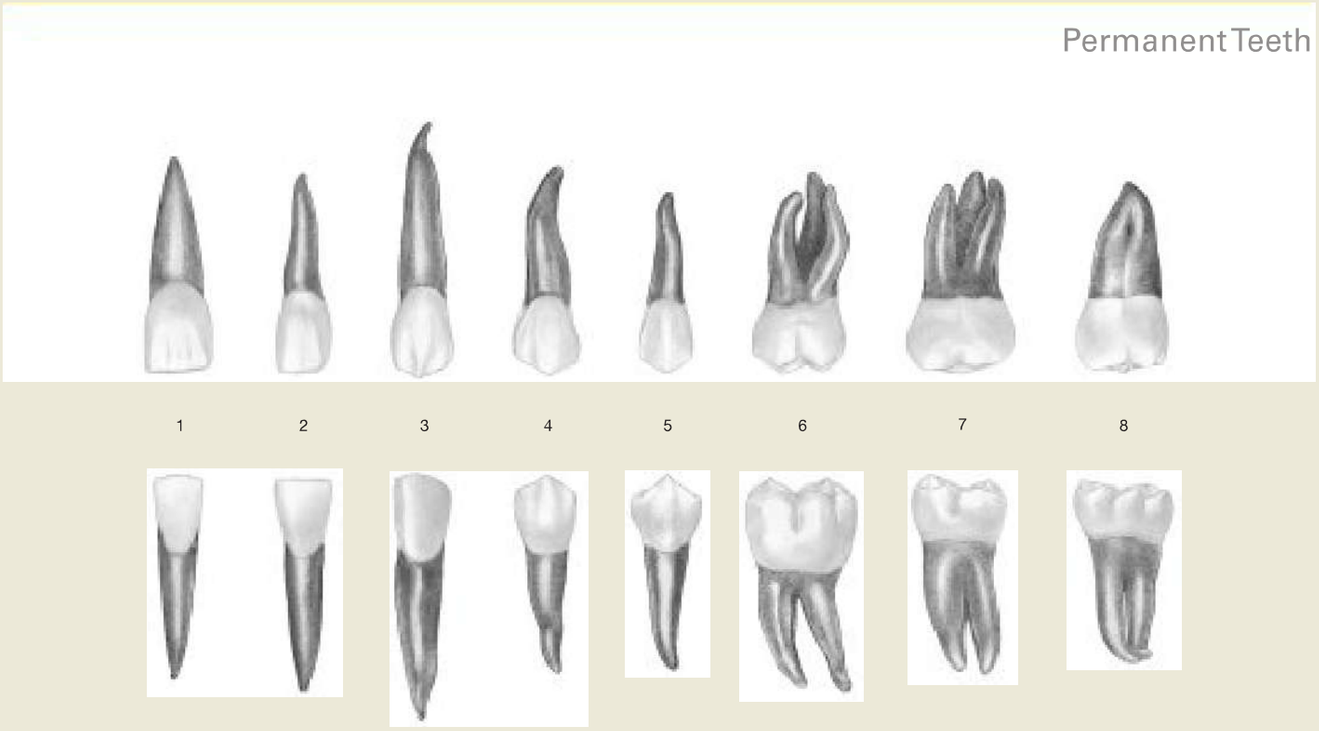

Fig. 8.142 Permanent teeth, Dentes permanentes; view from vestibular.

1 Dens incisivus I
2 Dens incisivus II
3 Dens caninus
4 Dens premolaris I
5 Dens premolaris II
6 Dens molaris I
7 Dens molaris II
8 Dens molaris III (serotinus)

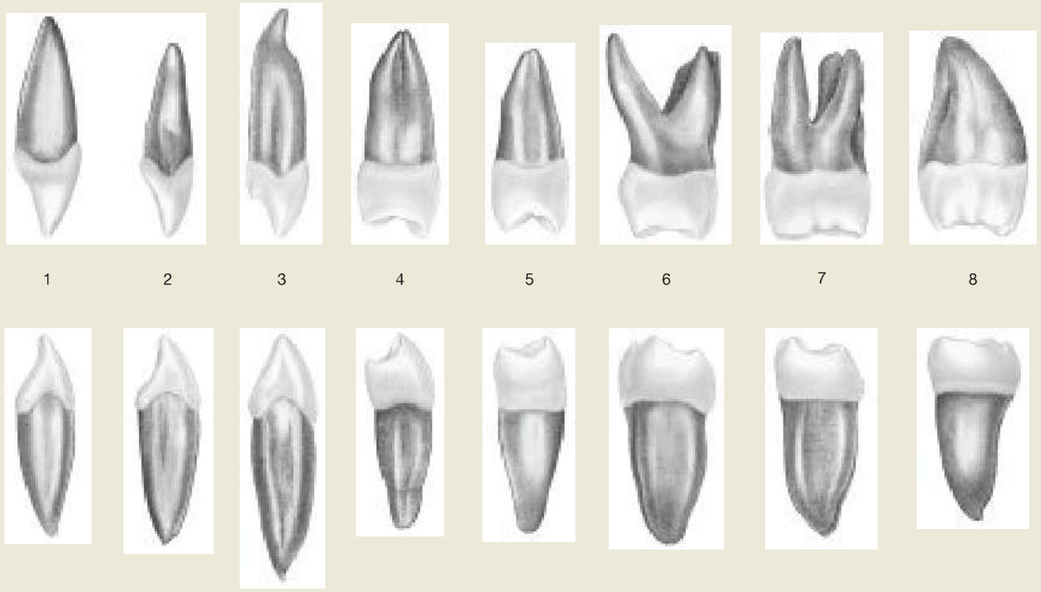

Fig. 8.143 Permanent teeth, Dentes permanentes; view from mesial.

1 Dens incisivus I
2 Dens incisivus II
3 Dens caninus
4 Dens premolaris I
5 Dens premolaris II
6 Dens molaris I
7 Dens molaris II
8 Dens molaris III (serotinus)

Clinical Remarks

- Environmental and genetic factors can influence the **development of the teeth**. Resulting dental anomalies can affect the size, shape and number of teeth.
- The administration of **tetracyclines** (a member of the family of antibiotics) during the phase of dental development can result in discolouration of teeth and enamel defects.
- Also important are discolourations of teeth and enamel defects caused by high doses of fluorides in the form of tablets **(dental fluorosis).**
- Enamel defects can also be caused by a vitamin D deficiency **(rickets).**
- Remnants of the dental lamina can be preserved as SERRE's bodies, and remnants of the epithelial root sheath as so-called epithelial cell rests of MALASSEZ, and both can generate cysts.

Times of Tooth Eruption

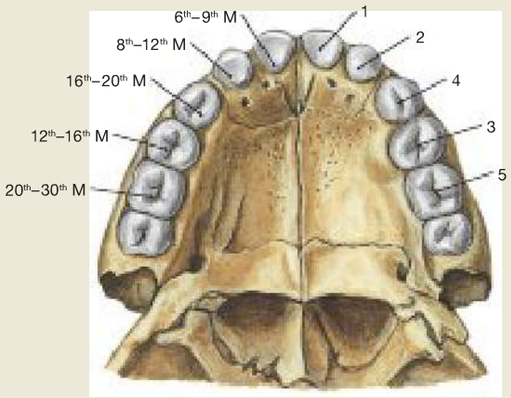

Fig. 8.144 Upper jaw, Maxilla, with deciduous teeth, Dentes decidui, and first permanent teeth; left: average time of eruption in months (M); right: sequence of tooth eruption.
The development of permanent teeth (replacement teeth) and deciduous (milk) teeth is similar but happens at different times. The time of eruption and the sequence at which milk teeth appear in the oral cavity is subject to significant interindividual differences. By 30 months, the milk teeth have usually all appeared.

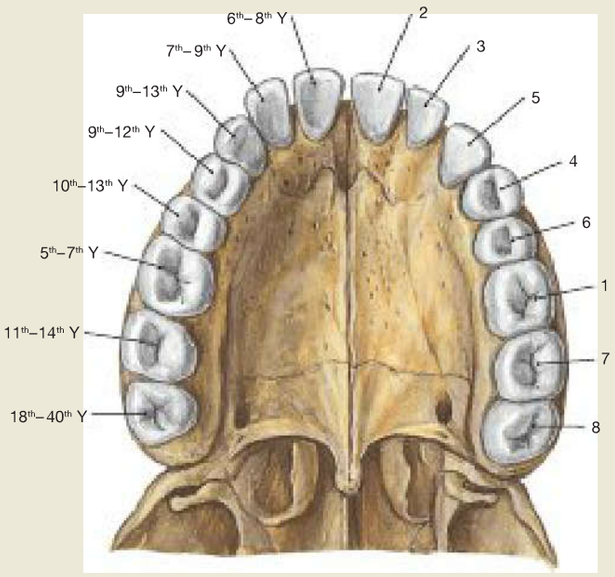

Fig. 8.145 Upper jaw, Maxilla, with permanent teeth, Dentes permanentes; left: average time of eruption in years (Y); right: sequence of tooth eruption.
With the exception of the molar teeth, the deciduous dentition (first dentition with 20 teeth) is similar to the permanent dentition (second dentition with 32 teeth). The sequence of eruption of the permanent molars is always the same: first molars at the age of six years **(6-year molars),** second molars with 12 years, and third molars with 18 years or later.

Clinical Remarks

The term **parodontopathies** refers to diseases of the periodontium. Parodontosis is a chronic degenerative form of periodontal disease and results in an increased tooth mobility and tooth loss with subsequent atrophy of the Proc. alveolaris caused by the decline of the **periodontal support system.** The systemic administration of fluoride ions during the formation of the hard substance in permanent teeth sometimes leads to the formation of **fluorapatite** instead of hydroxyapatite. Fluorapatite is lesser acid-soluble and thus increases resistance to caries.

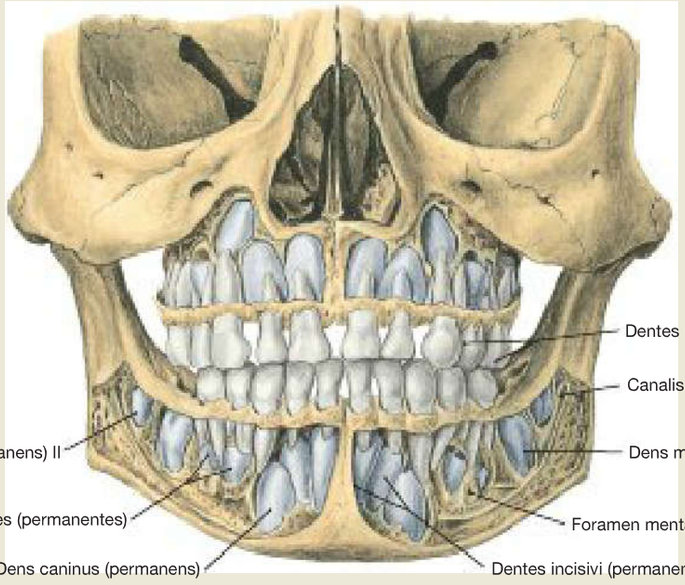

Fig. 8.146 Upper jaw, Maxilla, and lower jaw, Mandibula, of a five-year-old child, with milk teeth and primordium of permanent teeth, frontal view.
Human dentition is diphyodont; there are two successive sets of teeth, known as the deciduous and permanent dentitions. First, the 20 milk teeth (Dentes decidui) develop in children. Development and eruption of the first and second dentitions and the body growth are synchronised in a chronological manner. Resorption of the roots of the milk teeth occurs at different points in time.

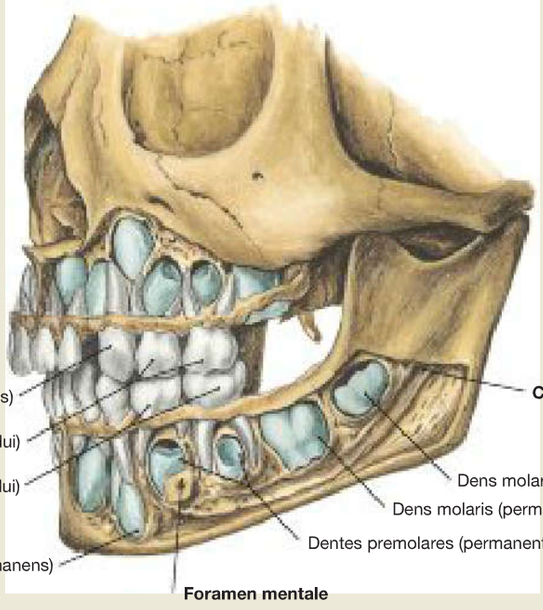

Fig. 8.147 Upper jaw, Maxilla, and lower jaw, Mandibula, of a five-year-old child, with milk teeth and primordium of permanent teeth, lateral view.
The primordium of the third molar (Dens molaris permanens III) is not visible.

Clinical Remarks

Because of the variances and differences in the shape of the third molar (**wisdom tooth,** Dens serotinus, Dens molaris permanens III) and of the Mandibula, an individual decision must be taken for each patient as to whether the wisdom teeth must be extracted or not.

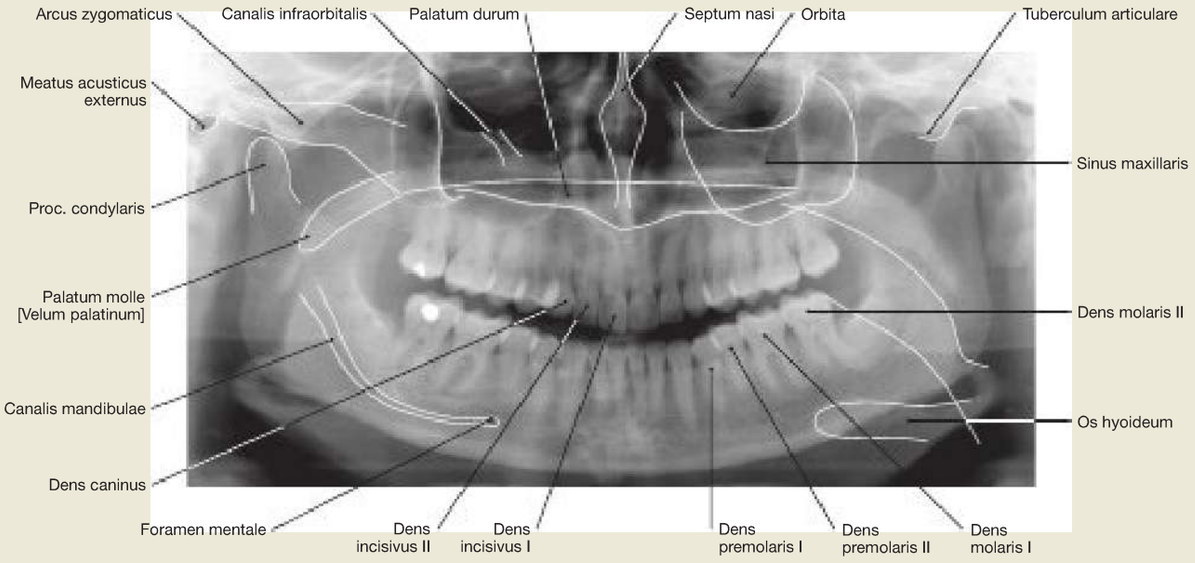

Fig. 8.148 Upper jaw, Maxilla, and lower jaw, Mandibula, without wisdom teeth; panoramic X-ray image.

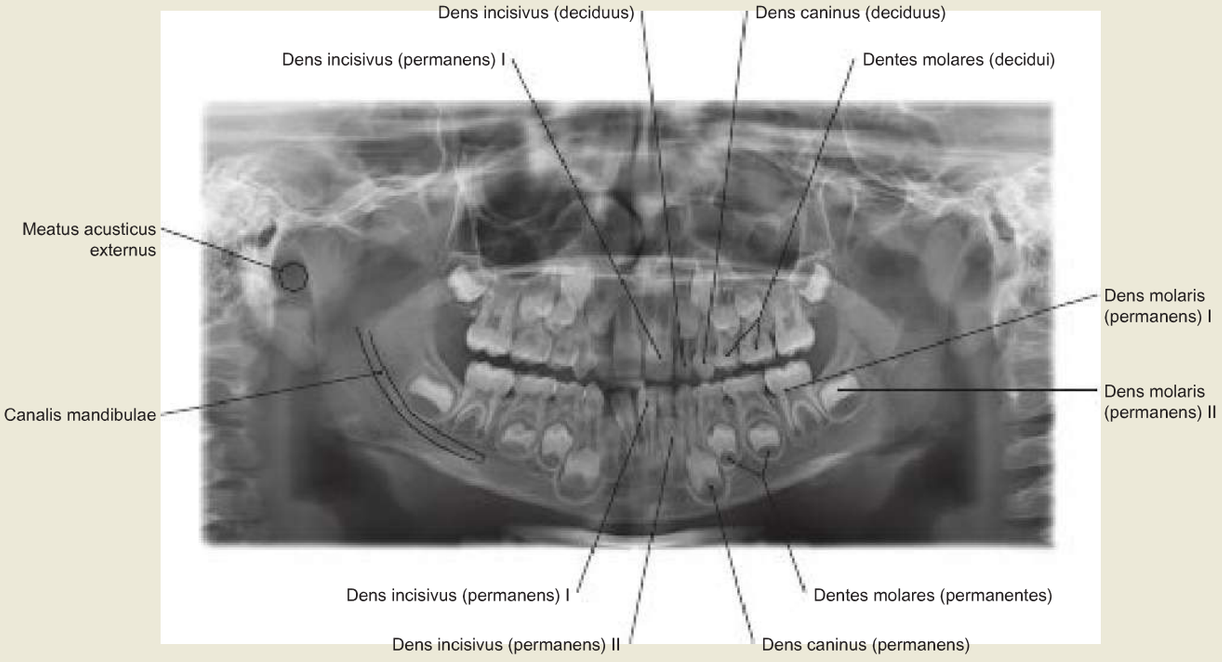

Fig. 8.149 Upper jaw, Maxilla, and lower jaw, Mandibula, of a five-year-old child; panoramic X-ray image. [T884]

Blood Supply and Innervation of the Teeth

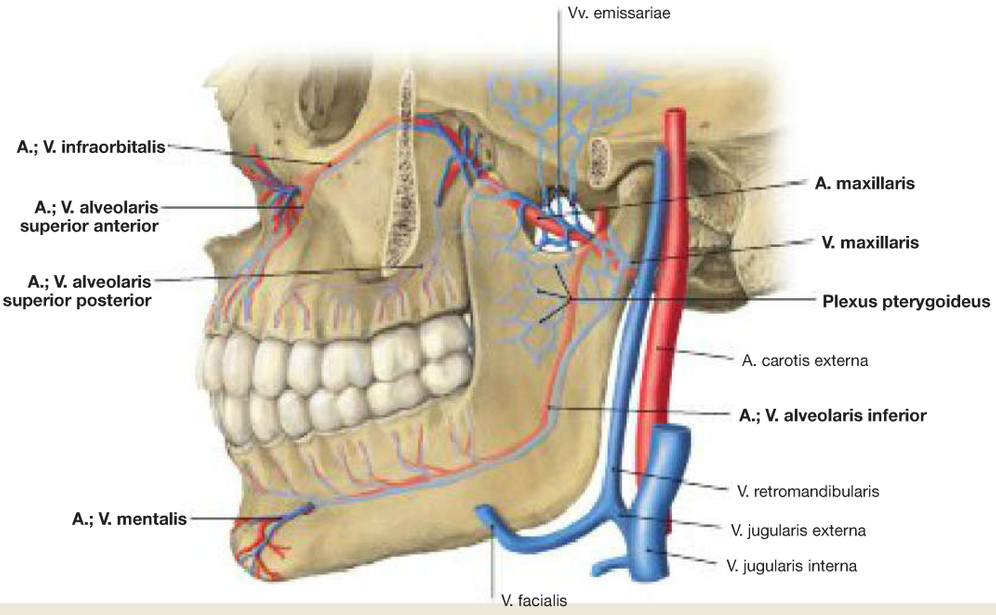

Fig. 8.150 Blood supply to the teeth. [L284]
The upper lateral teeth are supplied by the A. maxillaris via the **A. alveolaris superior posterior,** and the upper front teeth by the **A. infraorbitalis.** Teeth and gingiva of the lower jaw are supplied by the **A. alveolaris inferior,** which runs in the Canalis mandibularis. The veins accompanying the arteries drain the blood into the **Plexus pterygoideus.**

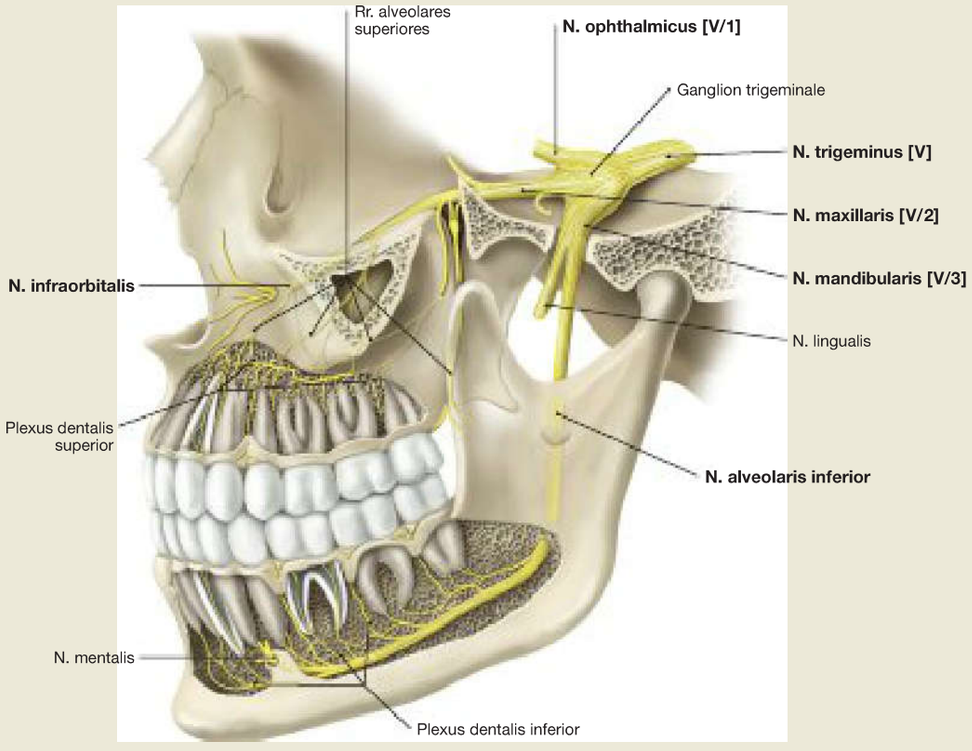

Fig. 8.151 Innervation of the teeth, left side; lateral view.
[L275]
The N. maxillaris [V/2] and N. mandibularis [V/3] of the N. trigeminus [V] provide the sensory innervation for the teeth. The **maxillary teeth** are innervated by the Plexus dentalis superior, which is composed of the Rr. alveolares superiores posteriores, medii and anteriores of the Nn. alveolares superiores of the N. infraorbitalis. The **teeth of the mandible** are innervated by the Plexus dentalis inferior, which is formed from the N. alveolaris inferior and divides into Rr. dentales inferiores. In addition, the anterior teeth of the Mandibula are reached by the N. mentalis. The innervation of the gingiva is even more complex than the sensory innervation of the teeth (→ Fig. 8.161).

Clinical Remarks

Because the teeth and gingiva of the maxilla are innervated by different nerve branches, a **local infiltrative anaesthesia,** has to be applied tooth-by-tooth. For the teeth of the Mandibula, a **block anaesthesia** is used. In doing so, the N. alveolaris inferior is anaesthetised shortly before it enters the Canalis mandibularis. Because the N. lingualis is also anaesthetised, this leads to a sensory block in the ipsilateral half of the tongue with the exception of the tip of the tongue. The chin and parts of the lower lip are also numb since the terminal branch of the N. alveolaris inferior is also anaesthetised.

Fossa pterygopalatina and Ganglion pterygopalatinum

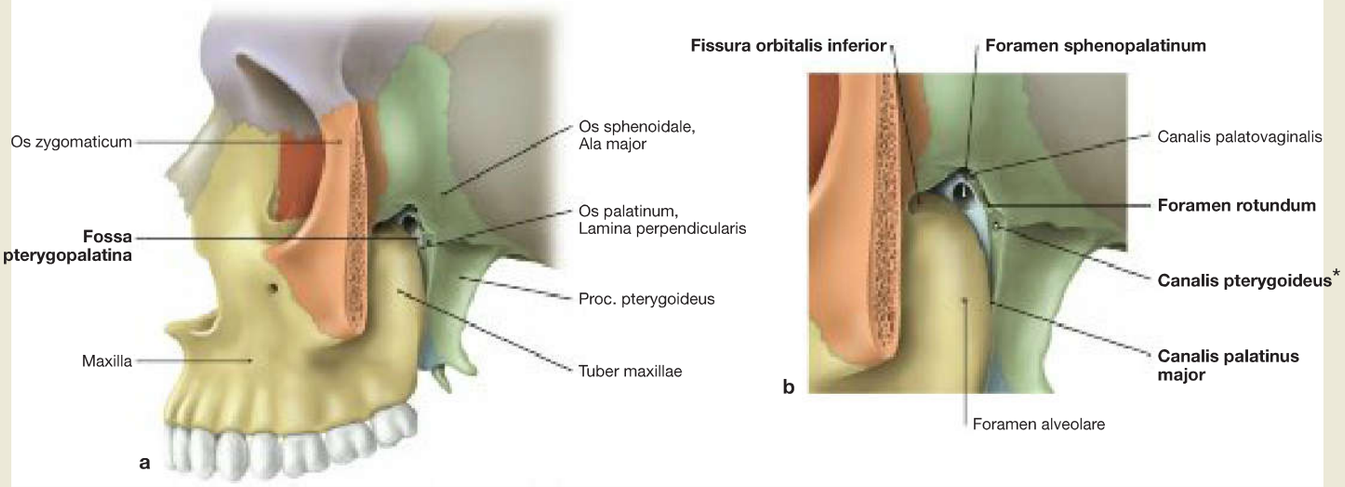

Fig. 8.152a and b Fossa pterygopalatina, left side; lateral view; for colour chart see p. VIII. [L275]
a Overview
b Detail in magnification
The Fossa pterygopalatina is a neural switching area between the middle cranial fossa, the orbit and the nose. The maxilla, Os palatinum and Os sphenoidale also define the margins of this fossa. It is bordered at the front by the Tuber maxillae, at the back by the Proc. pterygoideus, medially by the Lamina perpendicularis of the Os palatinum and above by the Ala major of the Os sphenoidale. The fossa continues into the Fissura orbitalis inferior above. At the back, the fossa opens into the retropharyngeal space; laterally it opens widely into the Fossa infratemporalis.

* VIDIAN canal

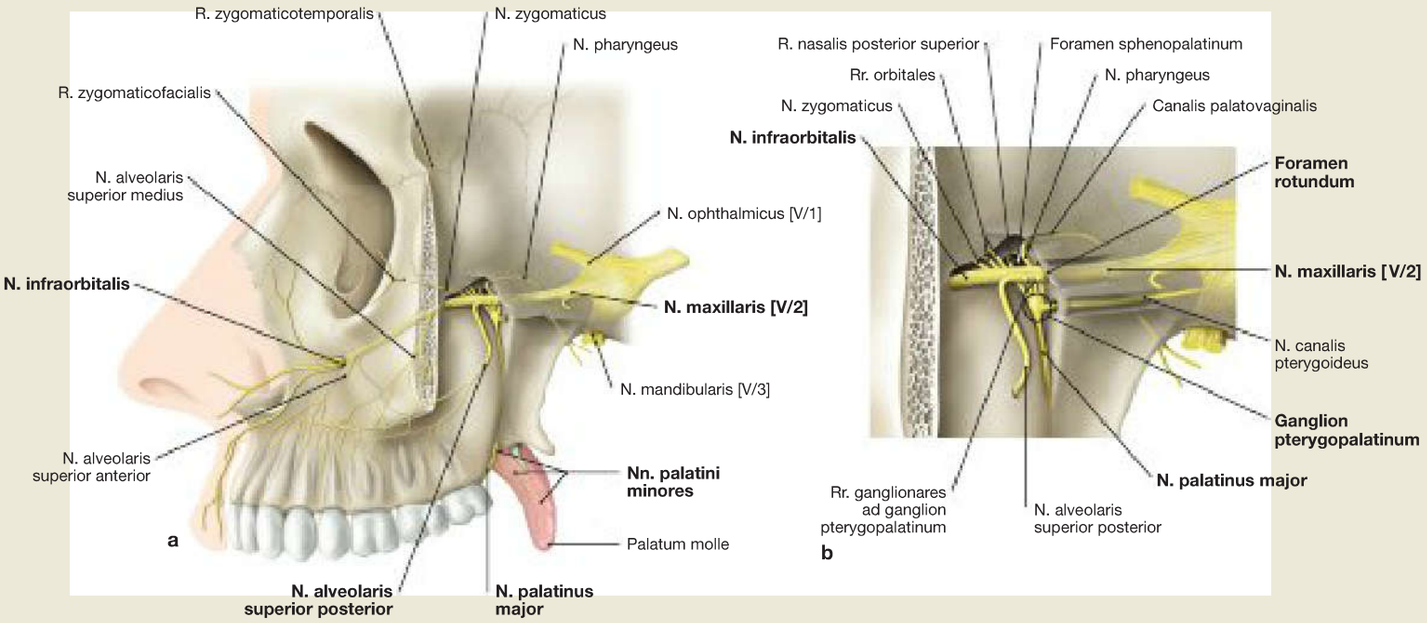

Fig. 8.153a and b N. maxillaris [V/2], left side; lateral view. [L275]
a Terminal branches
b Topographical relationship to the Ganglion pterygopalatinum
The N. maxillaris [V/2] exits the base of the skull through the **Foramen rotundum** to enter the Fossa pterygopalatina, and exits this fossa through the **Fissura infraorbitalis.** In the Fossa pterygopalatina, the orbital branches, the N. zygomaticus, the N. alveolaris superior posterior and the Rr. ganglionares to the Ganglion pterygopalatinum branch off. Sensory nerve fibres run within the Rr. ganglionares of the N. maxillaris [V/2] via the Ganglion pterygopalatinum to reach the soft and hard palate. Parasympathetic fibres from the Nucleus salivatorius superior reach the Ganglion pterygopalatinum via the N. facialis [VII] (N. intermedius), the N. petrosus major and the N. canalis pterygoidei, and are switched here from preganglionic to postganglionic. The postganglionic parasymphathetic fibres innervate the lacrimal, nasal and palatine glands. Postganglionic sympathetic fibres which originate from the N. caroticus internus (Plexus caroticus internus), assemble as the N. petrosus profundus and pass through the Ganglion pterygopalatinum to the lacrimal, nasal and palatine glands.

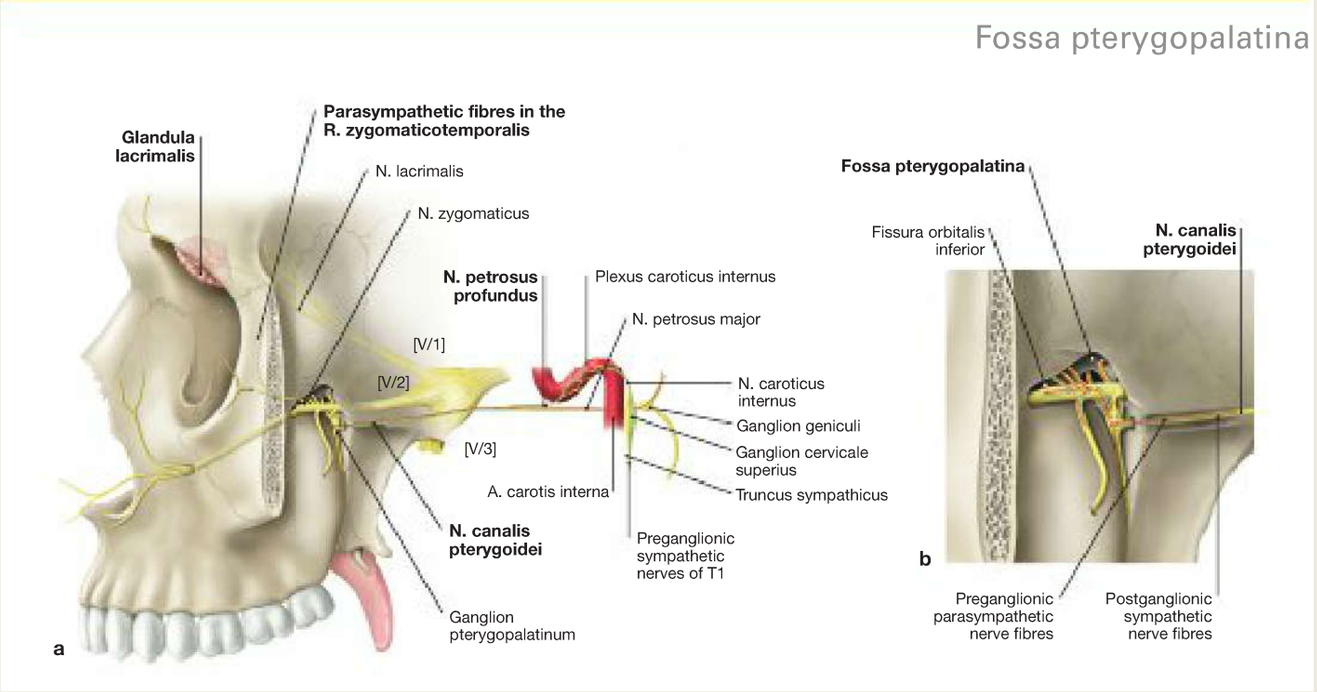

Fig. 8.154a and b N. canalis pterygoidei, left side; lateral view. [L275]
a Overview
b Nerves in the Fossa pterygopalatina
Parasympathetic fibres of the N. facialis [VII], which form the N. petrosus major, reach the Ganglion pterygopalatinum and are switched here from pre- to postganglionic fibres which then run downwards to the lacrimal, nasal and palatine glands. **Postganglionic sympathetic** fibres originating from the Plexus caroticus internus, assemble to the N. petrosus profundus and pass through the Ganglion pterygopalatinum without switching. They also reach the lacrimal, nasal and palatine glands.

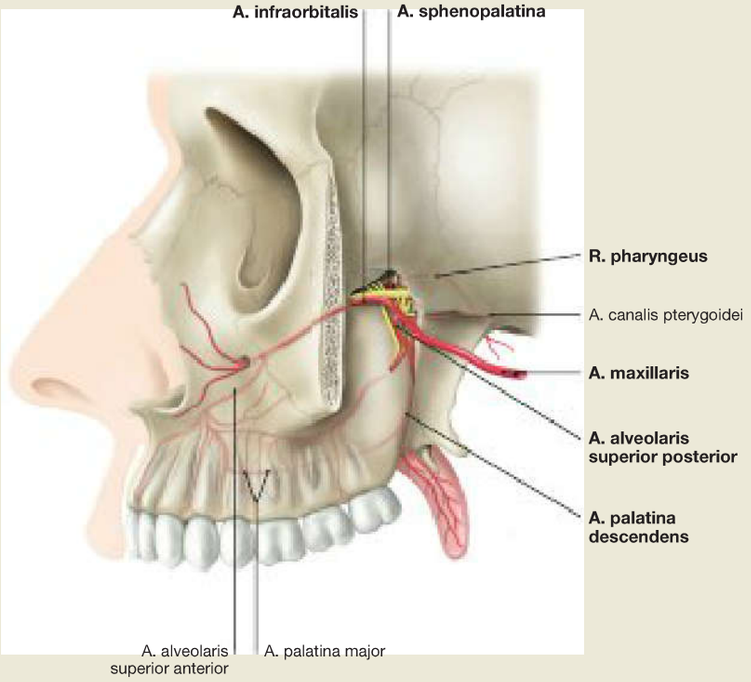

Fig. 8.155 A. maxillaris in the Fossa pterygopalatina, left side; lateral view. [L275]
In the Fossa pterygopalatina, the A. maxillaris divides into its **terminal branches:** Aa. infraorbitalis, sphenopalatina, alveolaris superior posterior, palatina descendens and R. pharyngeus.

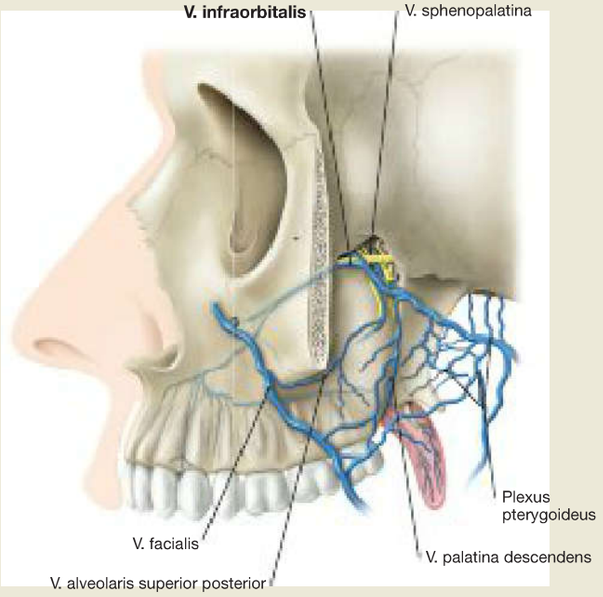

Fig. 8.156 Veins in the Fossa pterygopalatina, left side; lateral view. [L275]
The Vv. infraorbitalis, sphenopalatina,alveolaris superior posterior, and palatina descendens drain into the **Plexus pterygoideus,** which lies in the Fossa infratemporalis.

Clinical Remarks

A lesion of the parasympathetic fibres exiting the brain in association with the N. facialis [VII] which finally reach the lacrimal gland via branches of the N. ophthalmicus [V/I] can result in a reduced production of lacrimal fluid by the lacrimal gland, leading to a **dry eye syndrome** ('sicca' syndrome).

Palate and Palatine Muscles

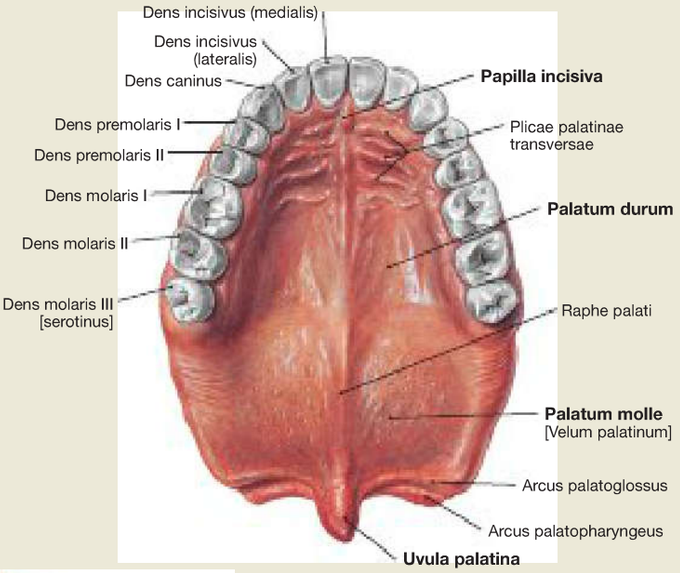

Fig. 8.157 Hard palate, Palatum durum, and soft palate, Palatum molle; view from below.
The palate (Palatum) forms the roof of the oral cavity and the floor of the nasal cavity. It therefore forms a border between the oral and nasal cavities. At the front it consists of the hard palate (Palatum durum) and at the back of the soft palate (Palatum molle).
The **hard palate** contributes to the phonation of consonants and serves as an abutment for the tongue when crushing food. Here, located on both sides of the midline, are several shallow, corrugated, mucosal ridges (Plicae palatinae transversae, Rugae palatinae). They serve to grind and hold ingested food.
The **soft palate** is flexible and, during swallowing, blocks off the nasopharynx by folding back onto the posterior pharyngeal wall.

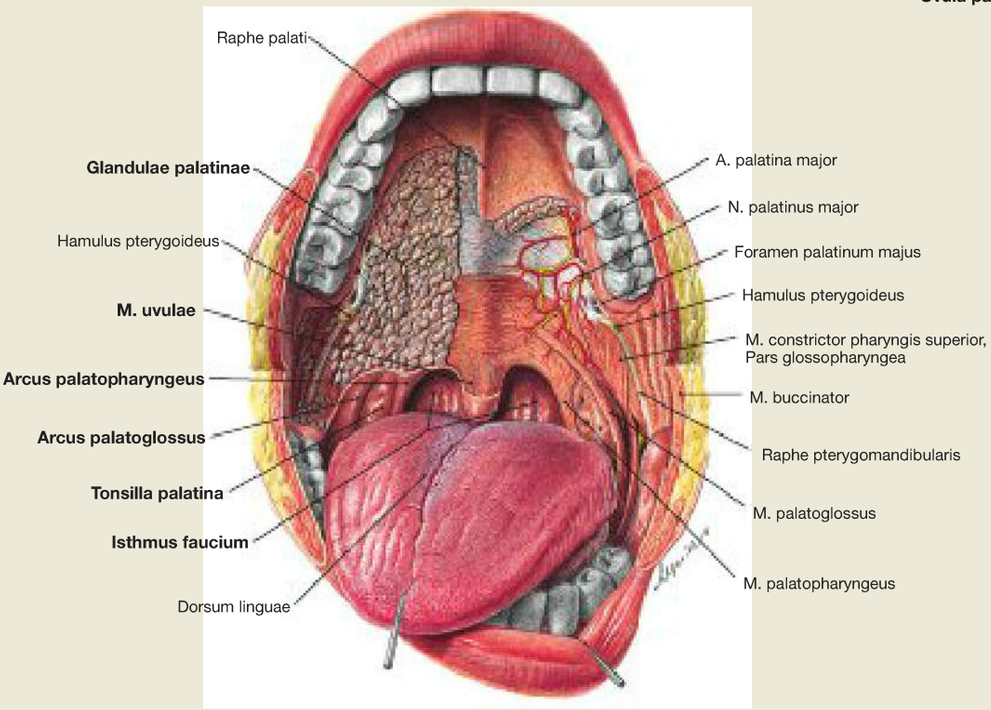

Fig. 8.158 Oral cavity, Cavitas oris, and palatine muscles, Mm. palati; frontal view.
The palate is covered by a thick mucosal layer firmly attached to the periosteum. In its subepithelial layers, 'clusters' of small salivary glands (Glandulae palatinae) are found. The movable soft palate follows towards the back and at its end, forms the uvula. The latter consists of a muscle (M. uvulae) and mucosal glands.

Laterally, the **palatine arches** (Arcus palatoglossus and Arcus palatopharyngeus), which at their base have muscles of the same name (Mm. palatoglossus and palatopharyngeus), are inserted in the soft palate and the uvula. The palatine arches on one side frame the Tonsilla palatina (Tonsilla palatina). The palatine arches create the **pharyngeal isthmus** (Isthmus faucium), the muscle-controlled entrance to the pharynx.

→T 3

Clinical Remarks

Cleft formations of the palate, jaw and face can vary greatly. They are attributable to an insufficient mesenchymal proliferation, as a result of which the jaw and nasal crests fail to fuse. The uni- or bilateral clefting of the upper lip is colloquially known as a 'harelip'. In severe forms, the clefting continues backwards in the palate as **lip-jaw-palate fissures** which occur at a rate of 1:2,500 births, and affect girls more frequently than boys. An **isolated cleft palate** occurs when the two halves of the secondary palate do not fuse with each other or do not fuse with the primary palate. The mildest form is a cleft uvula **(Uvula bifida).** These clefts are not genetic malformations, but can be attributed to a folic acid deficiency in the mother's diet during pregnancy (→ clinical remarks p.104).

Fig. 8.159a to c Development of the palate, separation of the nasal and oropharyngeal cavities. [E838]
From the medial nasal prominences, the intermaxillary segment emerges in the depth, from which the philtrum of the upper lip, part of the maxilla (with the four incisors), and part of the palate (forms the primary palate) develop. The primary palate extends into the anterior part of the oronasal cavity. The main part of the definitive bony palate is formed by the palatine processes which develop from the maxillary processes. In the seventh week, the tongue moves into a caudal position, the palatine processes are aligned horizontally and grow towards each another between the nasal cavity and the oral cavity, and merge in the midline into the secondary palate. In the anterior part, these palatine processes fuse with the primary palate.

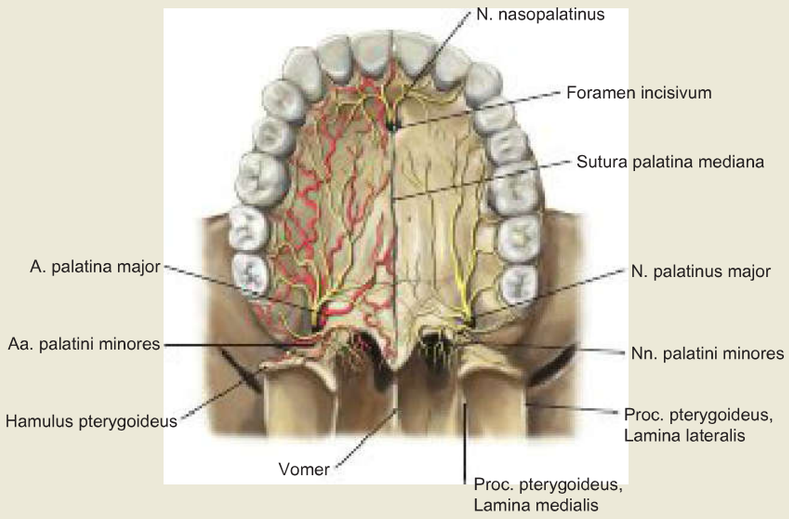

Fig. 8.160 Arterial blood supply and nerves of the palate; view from below. [L266]
Blood vessels and nerves reach the palate from cranially via the Foramen incisivum and the Foramina palatina majora and minora. The nerves are derived from the N. maxillaris [V/2].

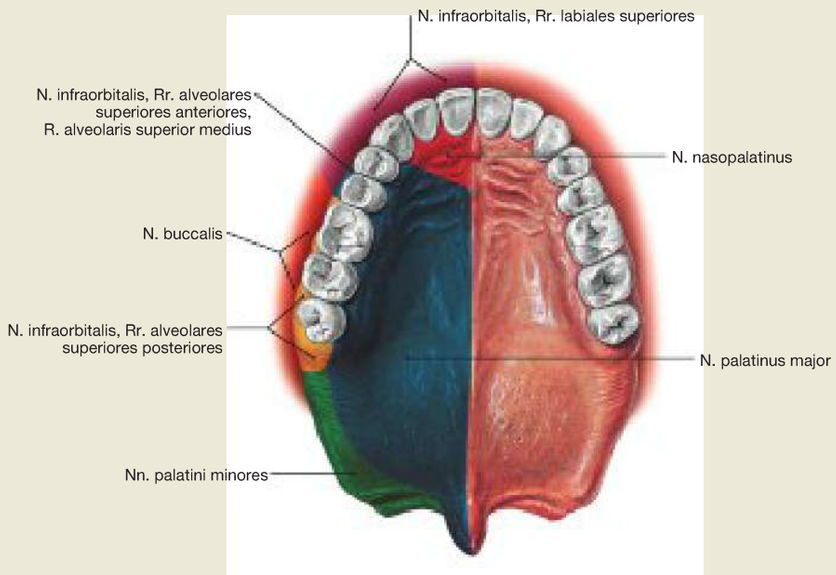

Fig. 8.161 Sensory innervation of the mucous membrane of the hard palate, Palatum durum, the soft palate, Palatum molle, as well as of the Gingiva and the Vestibulum oris; view from below. [L127]
The sensory innervation of the palatine mucosa, upper lip, cheeks and gums is provided by various branches of the N. trigeminus [V]: N. maxillaris [V/3] and N. buccalis of the N. mandibularis [V/2].

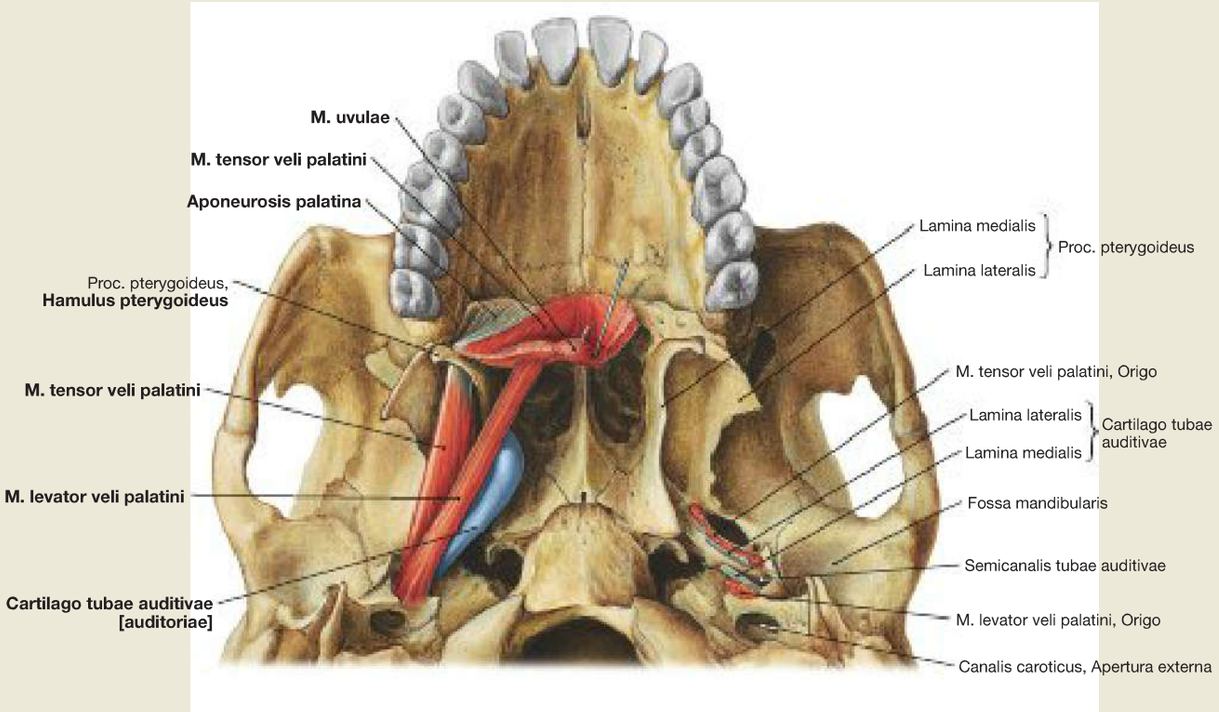

Fig. 8.162 M. levator veli palatini, M. tensor veli palatini and cartilage of the auditory tube, Cartilago tubae auditivae; view from below.
The M. tensor veli palatini and M. levator veli palatini provide tension to the **Aponeurosis palatina.** Both muscles are attached at the base of the skull. The Hamulus pterygoideus serves as a hypomochlion (centre of rotation of a joint) for the M. tensor veli palatini. The muscles pull the soft palate backwards and upwards upon contraction, which during the swallowing process functions as a **closure between the nasopharynx and oropharynx.** In addition, these muscles participate in the opening of the Tuba auditiva [auditoria] (→ p. 183).

→T 3

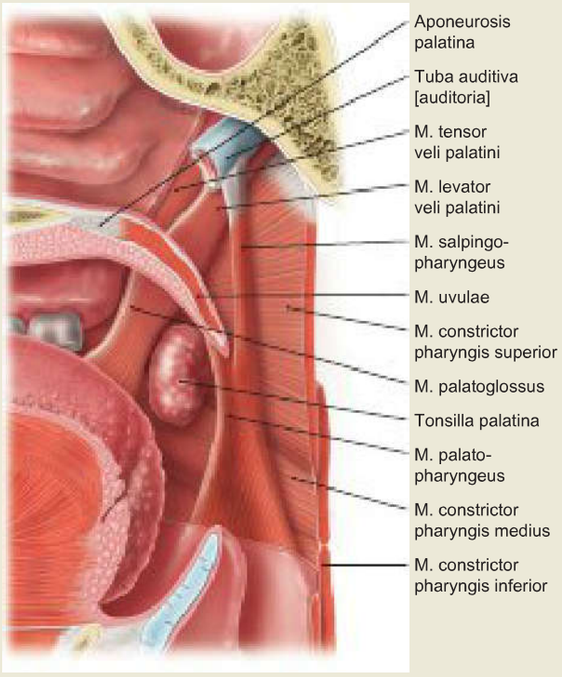

Fig. 8.163 Muscles of the soft palate, Palatum molle, right side; view from the left side. [L238]
In addition to the M. tensor veli palatini and M. levator veli palatini depicted in → Fig. 8.162, which serve to raise the soft palate and to open the Tuba auditiva, the M. uvulae, which serves to squeeze out the mucous glands of the uvula, the M. palatoglossus and the M. palatopharyngeus radiate into the **Aponeurosis palatina.** The last two muscles pull the soft palate downwards upon contraction which reopens the passage **between the nasopharynx and oropharynx** after swallowing.

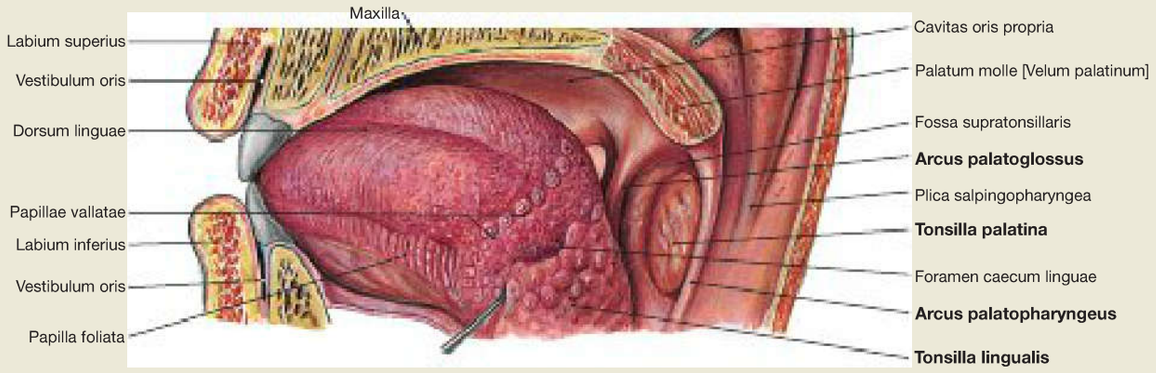

Fig. 8.164 Tongue, Lingua, in the oral cavity; posterior lateral view. Behind the Sulcus terminalis, the base of the tongue and the lingual tonsil (Tonsilla lingualis) are connected. The Tonsilla lingualis is part of the WALDEYER's tonsillar ring, which also includes the Tonsilla palatina located between the two palatine arches (Arcus palatoglossus and Arcus palatopharyngeus).

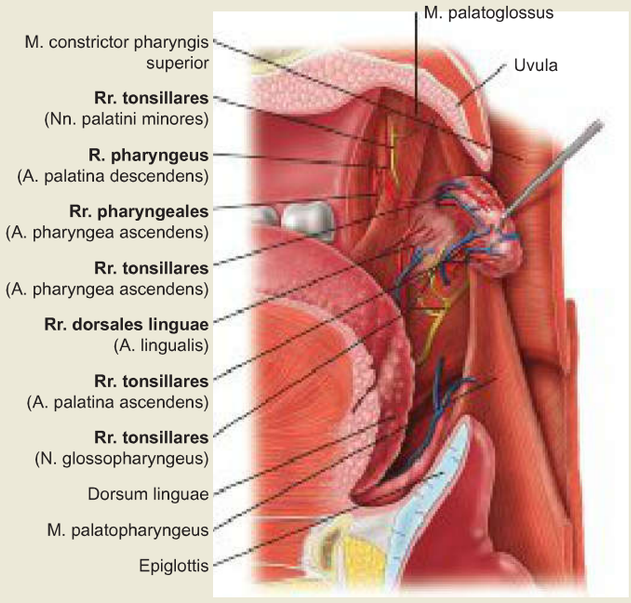

Fig. 8.165 Blood supply and innervation of the Tonsilla palatina, right side; medial view. [L238]
Involved in the blood supply of the Tonsilla palatina are the **Rr. tonsillares** of the A. palatina ascendens, the R. pharyngeus of the A. palatina descendens and the Rr. pharyngeales of the A. pharyngea ascendens, as well as the Rr. dorsales linguae of the A. lingualis. The innervation of the tonsillar bed is provided by the **Rr. tonsillares** of the Nn. palatini minores and the N. glossopharyngeus [IX].

Pharyngeal Lymphoid Ring (WALDEYER's Tonsillar Ring)		
Definition	It is a group of lymphoepithelial tissues that are located at the transition from the oral cavity and the nasal cavity to the pharynx. They form a ring in their entirety. The pharyngeal lymphoid ring serves in immune responses and is part of the mucosa-associated lymphoid tissue (MALT).	
Components	• pharyngeal tonsil (Tonsilla pharyngea) • tubal tonsils (Tonsillae tubariae) • palatine tonsils (Tonsillae palatinae) • lingual tonsil (Tonsilla lingualis) • so-called lateral assortment of MALT	→ pp. 72, 85 → p. 98 → p. 98

Clinical Remarks

Frequently recurrent infection of the palatine tonsils is an indication for their surgical removal **(tonsillectomy),** one of the most common surgical ENT procedures. Postoperative bleeding can occur up to three weeks (in rare cases even longer) after the operation, and is feared as a serious complication.

Tongue

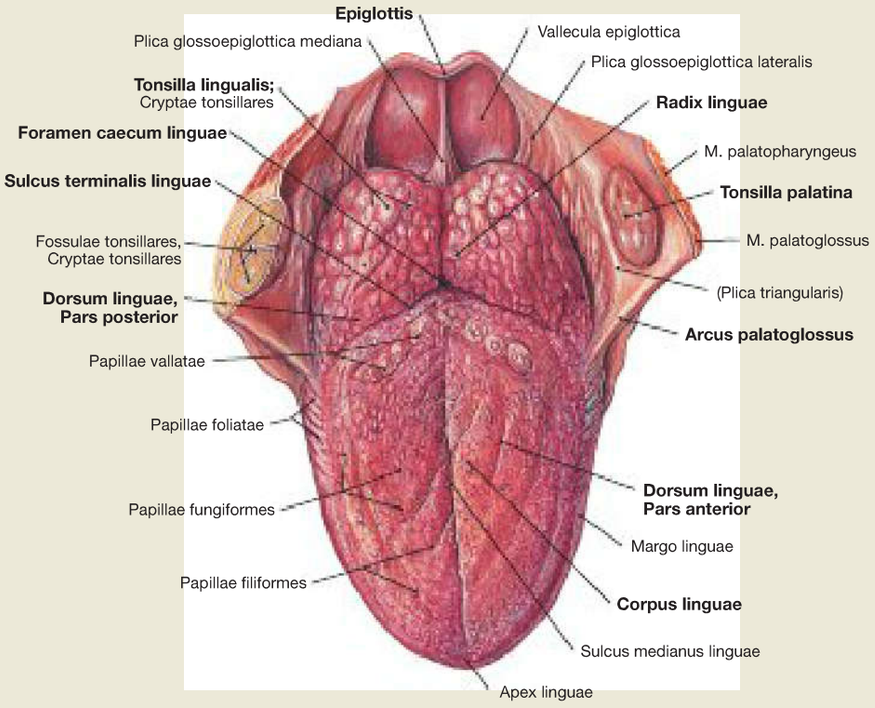

Fig. 8.166 Tongue, Lingua; view from above.
On the **dorsum of the tongue** (Dorsum linguae), the Sulcus medianus linguae divides the tongue into a right and a left half. The Sulcus terminalis linguae (a V-shaped furrow) forms the border between the Corpus linguae and the base of the tongue, and divides the tongue into a Pars anterior as well as a Pars posterior. At the tip of the Sulcus terminalis linguae, the surface epithelium sinks into the **Foramen caecum linguae.** This foramen is the place where the thyroid gland started its descent from the ectoderm of the floor of the mouth to its final destination in front of the larynx (origin of the Ductus thyroglossalis).

The mucosa of the Pars anterior is rough since it contains multiple small, partially macroscopically visible papillae (Papillae linguales, filiformes, foliatae, fungiformes and vallatae), which play a role in the perception of touch and taste sensations.
The **base of the tongue** (Radix linguae) is covered by the lingual tonsil, which is framed on the sides by the two palatine arches, Arcus palatoglossus and Arcus palatopharyngeus, and at the back by the epiglottis. From the base of the tongue, the unpaired Plica glossoepiglottica mediana and the paired Plicae glossoepiglotticae laterales extend to the epiglottis and delineate the Valleculae epiglotticae.

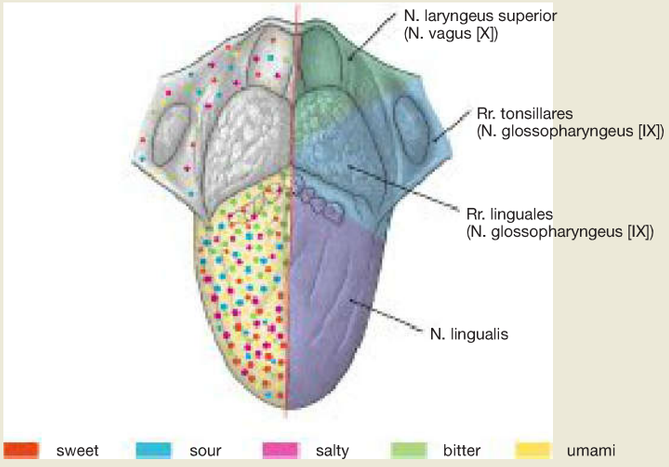

Fig. 8.167 Innervation and taste qualities at the base of the tongue.
The N. lingualis, a branch of the N. mandibularis [V/3], provides the sensory innervation of the Pars anterior of the tongue, Rr. linguales of the N. glossopharyngeus [IX] supply the region of the Sulcus terminalis linguae, and the N. laryngeus superior, a branch of the N. vagus [X], innervates the base of the tongue.
Taste sensations from the **anterior two-thirds** of the tongue are conveyed by branches of the N. facialis [VII] (Chorda tympani, N. intermedius) to the upper part of the Tractus solitarius in the brain stem; the perikarya of these sensory fibres are located in the Ganglion geniculi. Taste sensations from the **posterior third** of the tongue are projected to the lower part of the Tractus solitarius in the brain stem by sensory fibres of the N. glossopharyngeus [IX] and N. vagus [X]. The perikarya of these nerve fibres reside in the Ganglion inferius of the N. glossopharyngeus [IX] or the N. vagus [X].
All regions in the anterior two-thirds of the tongue are capable of perceiving all five basic qualities of taste, albeit with different intensity. You therefore taste sweeter things on the tip of the tongue and more bitter things towards the base of the tongue.

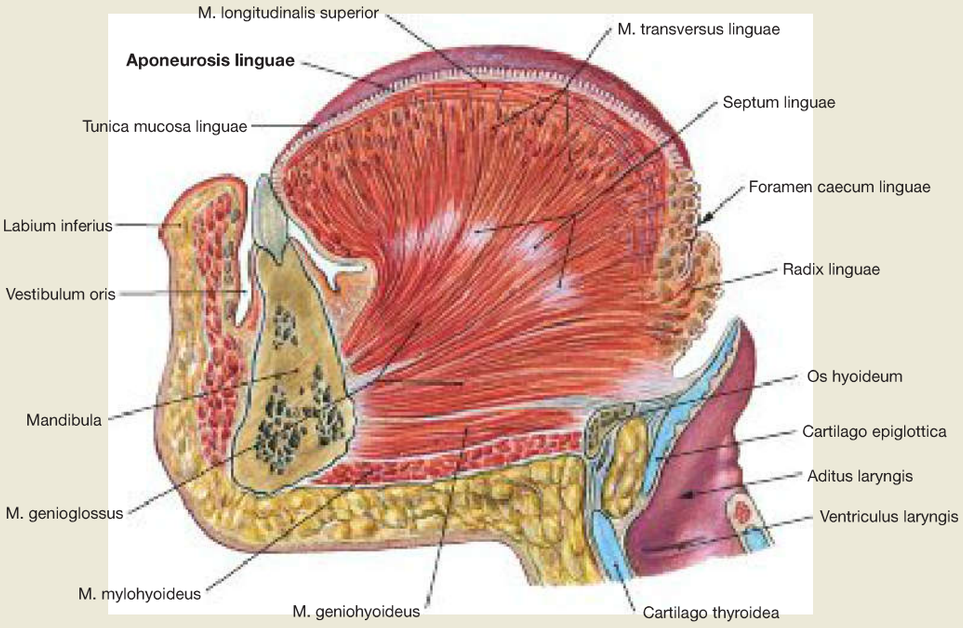

Fig. 8.168 Tongue, Lingua, and muscles of the tongue, Mm. linguae; median section.
The tongue is a highly flexible muscular body. It plays a significant role in chewing and swallowing and makes sucking and speaking possible. It is also an important instrument of taste and houses the taste organ. A distinction is made between internal and external muscles which originate from the skeleton and radiate into the body of the tongue. The external muscles change the position of the tongue, the internal muscles of the tongue modify its shape. The majority of these muscles insert at the largest part of the **Aponeurosis linguae,** a tough plate of connective tissue beneath the mucosa of the dorsum of the tongue.

→ T 2a

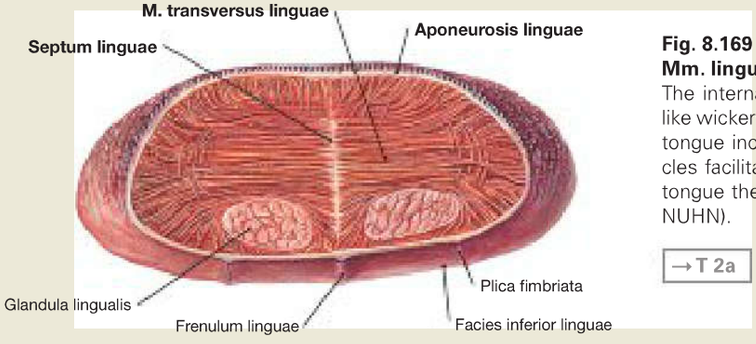

Fig. 8.169 Tongue, Lingua, and internal muscles of the tongue, Mm. linguae interni; cross-section through the tip of the tongue.
The internal muscles of the tongue weave through the spatial planes like wickerwork. In the median plane, the Septum linguae intersects the tongue incompletely into two halves. Agonistic and antagonistic muscles facilitate the flexibility of the tongue. In the area of the tip of the tongue there is a salivary gland (Glandula lingualis, gland of BLANDIN-NUHN).

→ T 2a

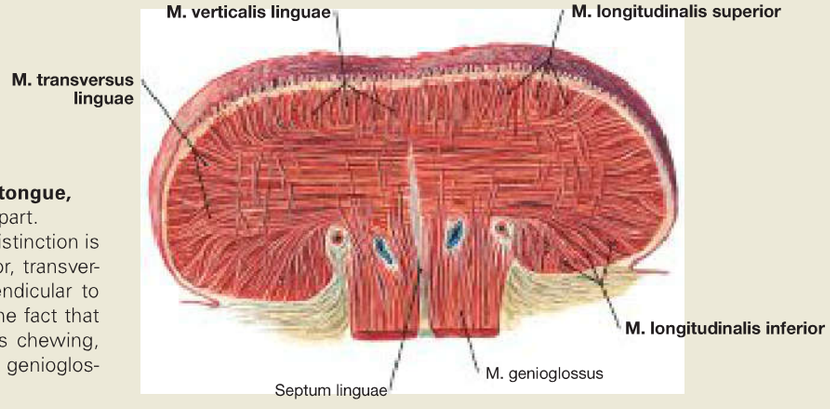

Fig. 8.170 Tongue, Lingua, and internal muscles of the tongue, M. linguae interni; cross-section at the level of the middle part.
The internal muscles originate and insert in the tongue. A distinction is made between the Mm. longitudinales superior and inferior, transversus linguae and verticalis linguae. The muscles are perpendicular to each other in the three spatial planes and they interlace. The fact that the tongue is so malleable means, that functions such as chewing, sucking, singing, talking and whistling are possible. The M. genioglossus belongs to the external muscles of the tongue.

→ T 2a

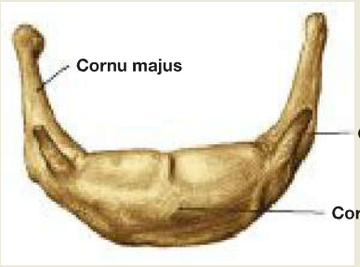

Fig. 8.171 Hyoid bone, Os hyoideum; frontal view from above. The horseshoe-shaped hyoid consists of a body (Corpus) and the paired greater and lesser horns (Cornua majora and minora).

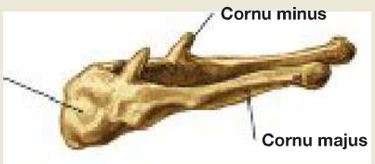

Fig. 8.172 Hyoid bone, Os hyoideum; lateral view.

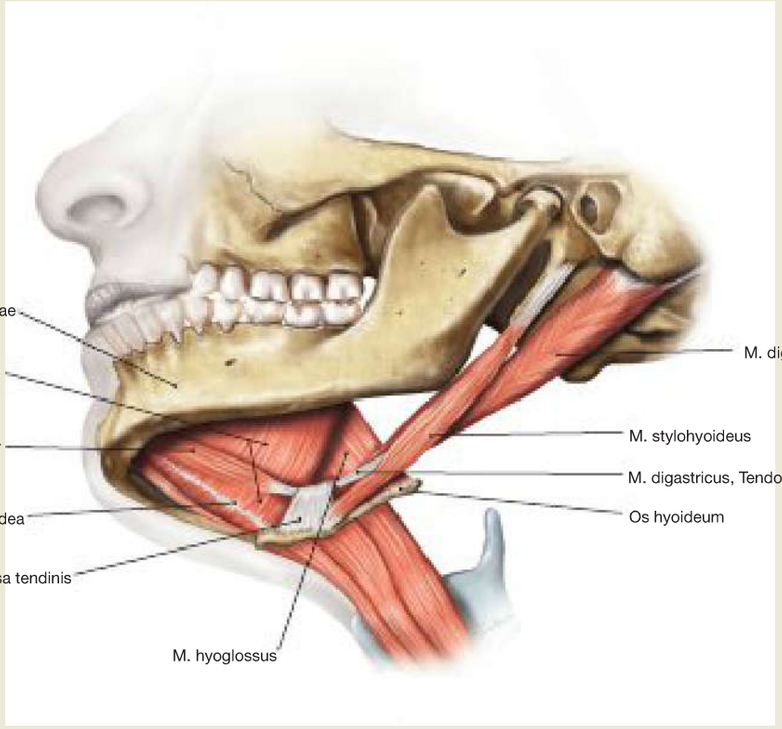

Fig. 8.173 Oral region; lateral view from below. [L266]
The muscular oral diaphragm, **Diaphragma oris,** consists of the two Mm. mylohyoidei and forms the floor of the oral cavity. In addition, the Mm. geniohyoidei (not shown) and digastrici are part of the structure of the floor of the mouth. Since all muscles are directly or indirectly linked to the hyoid, they are treated together with the Mm. stylohyoidei as **Mm. suprahyoidei** (suprahyoid muscles). Functionally, the floor of the mouth represents an adjustable abutment for the tongue.

→T 2b, 9

Clinical Remarks

Touching the base of the tongue, the palatine arches or the posterior wall of the pharynx triggers a **swallowing** or **gag reflex.** The muscles of the tongue, pharynx, larynx, and oesophagus are part of these reflexes.
Allergic reactions can result in a life-threatening swelling of the mucosal lining of the soft palate.
Inflammation of the palatine mucosa, in particular of the soft palate, typically leads to severe difficulty in swallowing.
Circulatory disorders of the brain stem are often associated with paralysis of the palatine muscles, resulting in difficulties swallowing and tube ventilation disorders. In affected patients, there may be a paralysis of the soft palate (lesion of the nuclear areas of the N. glossopharyngeus [IX] and N. vagus [X]). Due to paralysis of the M. levator veli palatini, the soft palate may hang down on the affected side. The uvula moves to the healthy side.
Often, the tongue is the first to be injured by **chemical burns and scalding.** At the margin of the tongue, potential **precancerous** conditions may occur in the form of hyperkeratoses or leukoplakias.

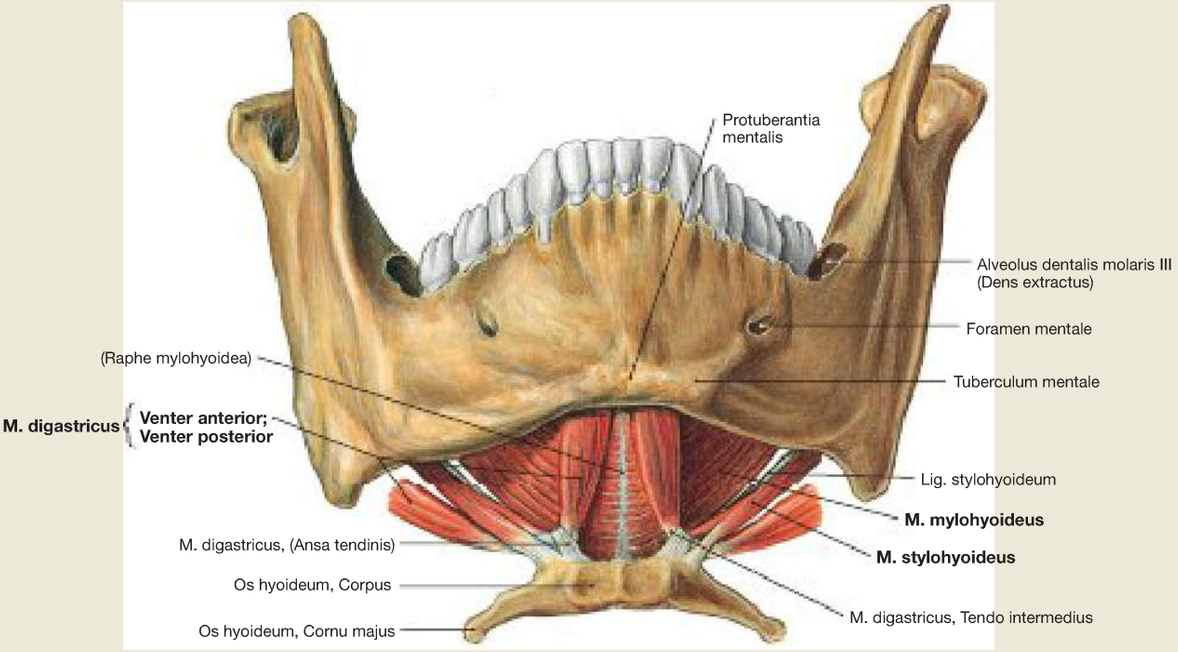

Fig. 8.174 Lower jaw, Mandibula, and muscles of the floor of the mouth, Mm. suprahyoidei; frontal view.
The oral diaphragm (Diaphragma oris) is formed by muscles that belong to the suprahyoid muscles. The central muscle of the floor of the mouth is the **M. mylohyoideus,** which extends between the two Rami mandibulae on both sides to the front; both parts of the muscle join in the midline at the Raphe mylohyoidea. Underneath that is the paired Venter anterior of the **M. digastricus,** which is connected via an intermediate tendon to the Venter posterior of the M. digastricus. The intermediate tendon is fixed to the hyoid bone by means of a connective tissue loop. As the third suprahyoid muscle, you can see the **M. stylohyoideus** coming from the hyoid.

→T 9

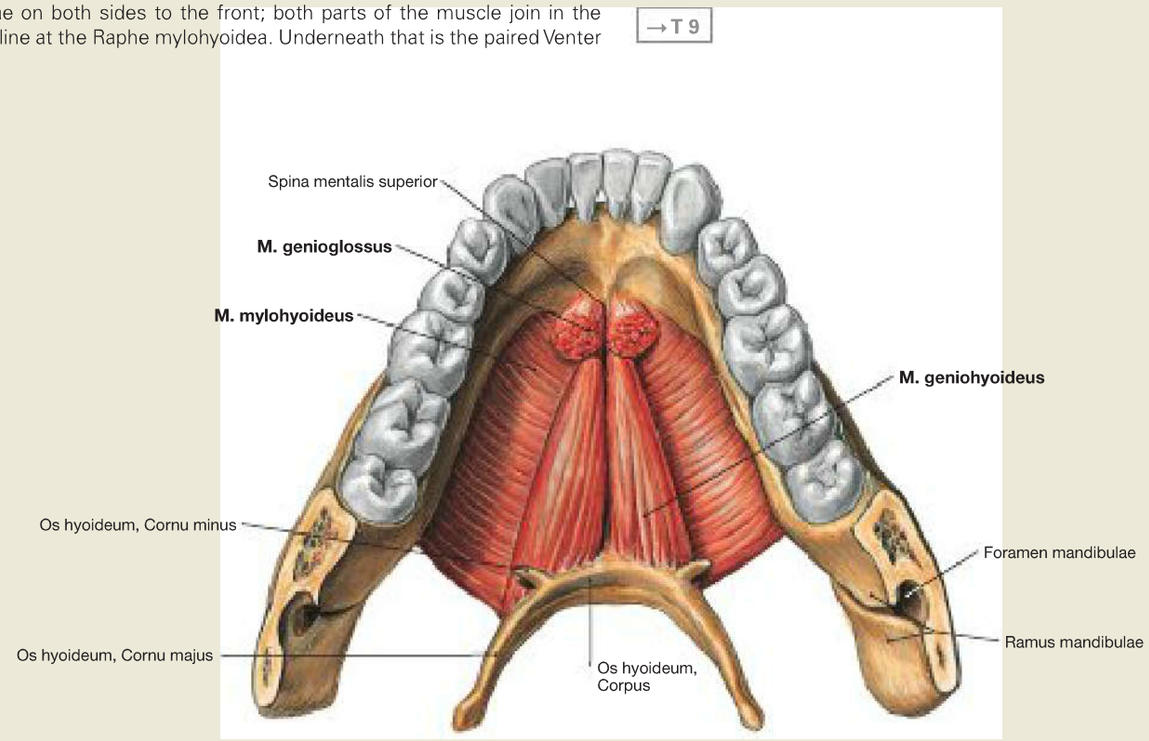

Fig. 8.175 Lower jaw, Mandibula, muscles of the floor of the mouth, Mm. suprahyoidei, and hyoid bone, Os hyoideum; view from above.
You can see here the Diaphragma oris formed by both Mm. mylohyoidei, on which the paired **Mm. geniohyoidei,** belonging to the suprahyoid muscles, run from the inner surface of the Mandibula to the hyoid bone. The overlying M. genioglossus, which is part of the external muscles of the tongue, has been cut just behind its origin at the Spina mentalis superior of the Mandibula.

→T 9

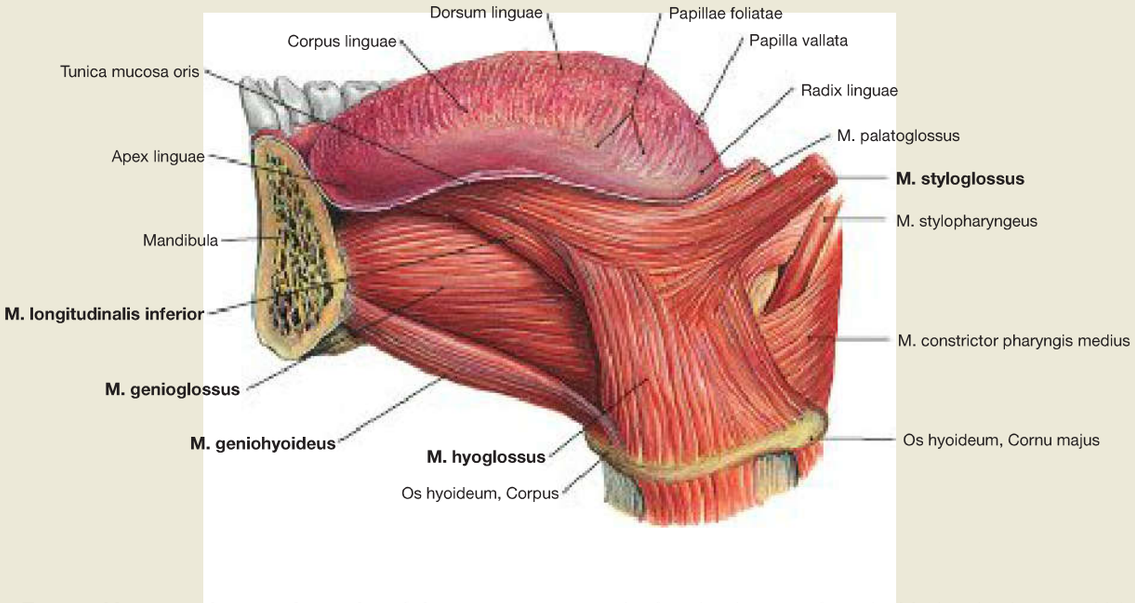

Fig. 8.176 Tongue, Lingua, and external muscles of the tongue, Mm. linguae externi; view from the left side.
The external muscles radiate into the tongue. They consist of the **Mm. genioglossus, hyoglossus and styloglossus.** The M. palatoglossus is also part of the external muscles of the tongue. The M. hyoglossus can receive functional support from the M. chondroglossus, which originates from the lesser horn of the Os hyoideum (→ Fig. 8.177 and → Fig. 8.178).

→ T 2b

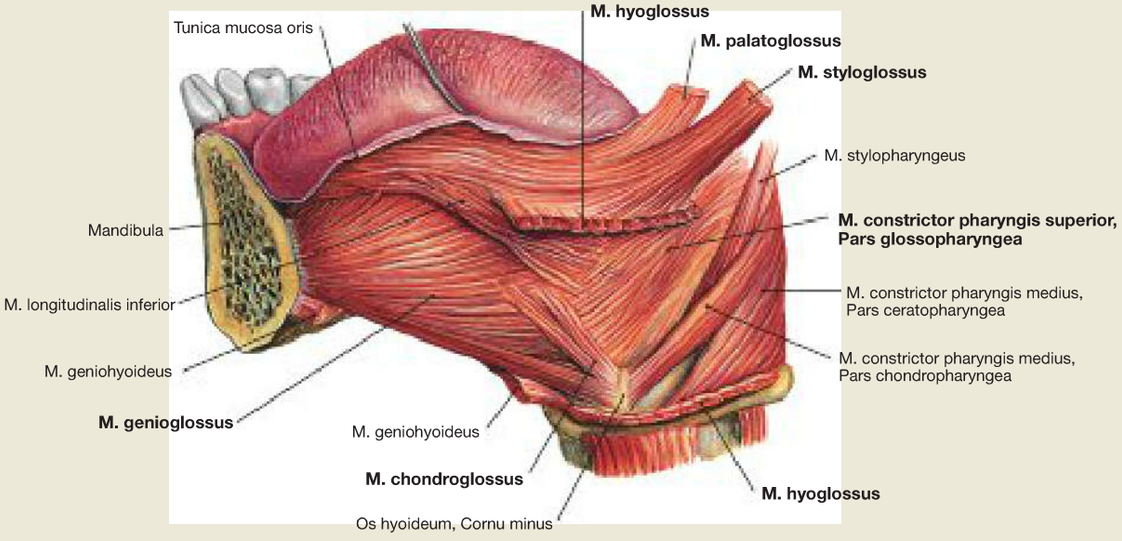

Fig. 8.177 Tongue, Lingua, and external muscles of the tongue, Mm. linguae externi; view from the left side.
With the M. hyoglossus removed, you can see the small **M. chondroglossus,** which originates from the lesser horn of the Os hyoideum and functionally supports the M. hyoglossus. At the posterior aspect, in addition to the external muscles of the tongue, the M. palatoglossus and the Pars glossopharyngea of the M. constrictor pharyngis superior radiate into the tongue.

→ T 2b

Clinical Remarks

The tongue can only be fully protruded when the M. genioglossus is intact. In a deep coma the M. genioglossus slackens. In the supine position, the tongue slips into the pharynx and can block the airway. This is why unconscious people must always be placed in a stable position on their side as a precaution.

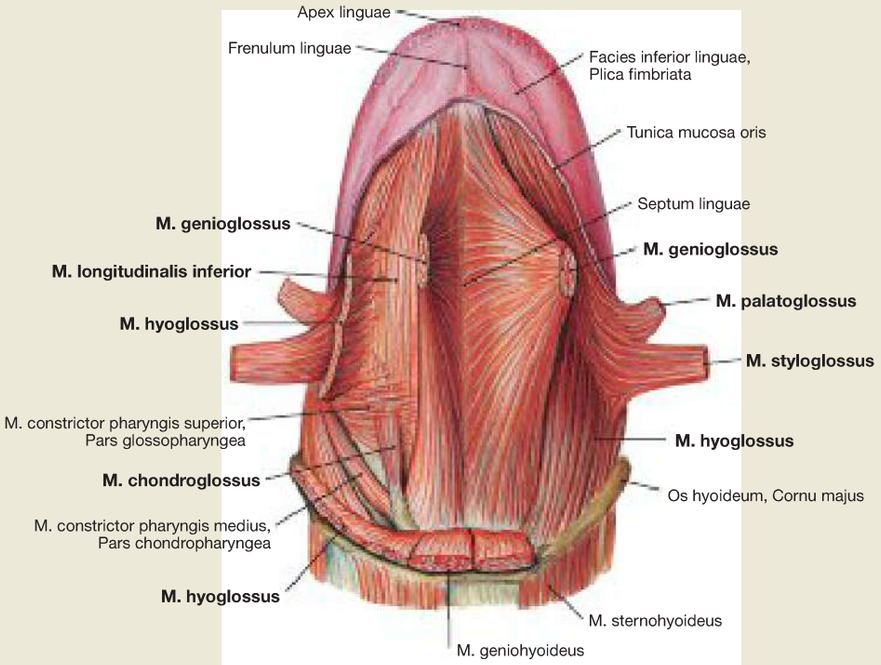

Fig. 8.178 Muscles of the tongue, Mm. linguae; inferior view.
The M. genioglossus was removed at its mandibular origin. Also, the Mm. styloglossus and palatoglossus were removed. Laterally, the M. hyoglossus (cut at the right side of the tongue) and M. chondroglossus are shown, which are external muscles of the tongue. At the bottom of the tongue runs the M. longitudinalis inferior (internal muscle of the tongue).

→T 2b

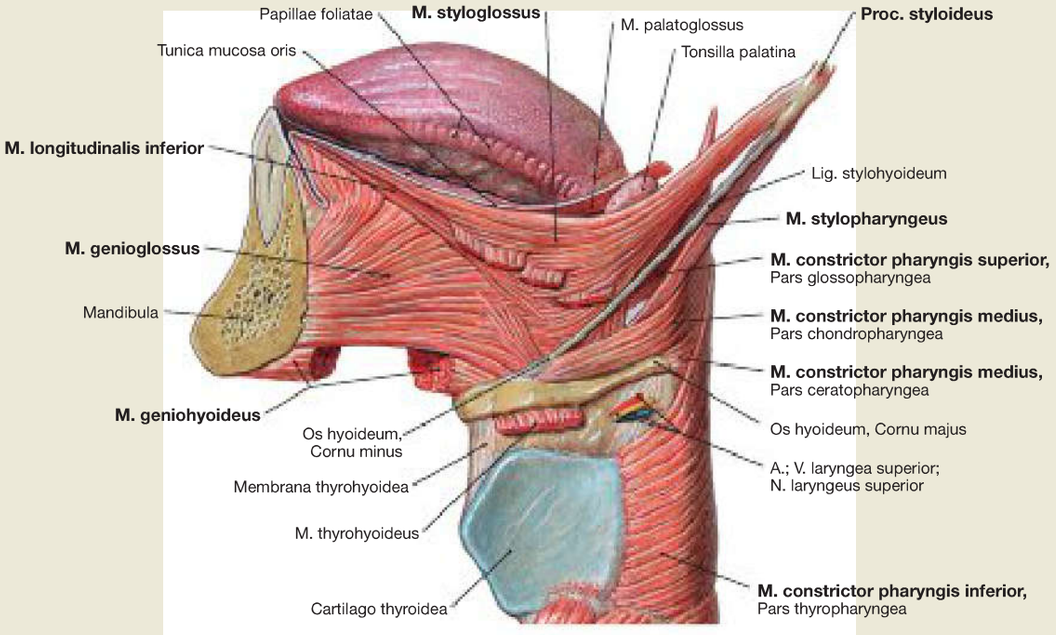

Fig. 8.179 External muscles of the tongue, Mm. linguae externi, and pharyngeal muscles, Mm. constrictores pharyngis; lateral view; mandibular arch removed.
The Lig. stylohyoideum extends between the M. styloglossus and M. stylopharyngeus. Located below this ligament are the pharyngeal muscles, the M. constrictor pharyngis superior with the Pars glossopharyngea, and the M. constrictor pharyngis medius with the Partes chondropharyngea and ceratopharyngea. Below the hyoid bone is the M. constrictor pharyngis inferior with the Pars thyropharyngea.

→T 2b, 5

Compartments of the Floor of the Mouth, Vessels and Nerves of the Tongue

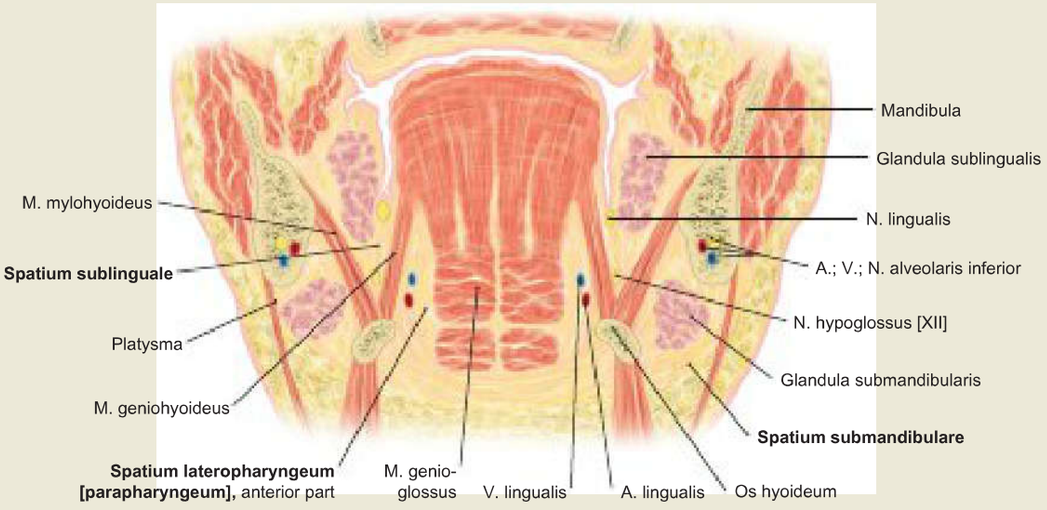

Fig. 8.180 Compartments of the floor of the mouth, Diaphragma oris; horizontal section in the area of the Os hyoideum. [L127]
The muscles of the oral diaphragm are separated from each other by loose connective tissue spaces. These spaces, which are so-called compartments of the oral diaphragm, are the **Spatium parapharyngeum,** in which the A. and V. lingualis run, the **Spatium sublinguale,** in which the N. lingualis runs, and the **Spatium submandibulare** with the Glandula submandibularis. All compartments of the oral diaphragm are posteriorly connected to the neurovascular structures of the neck.

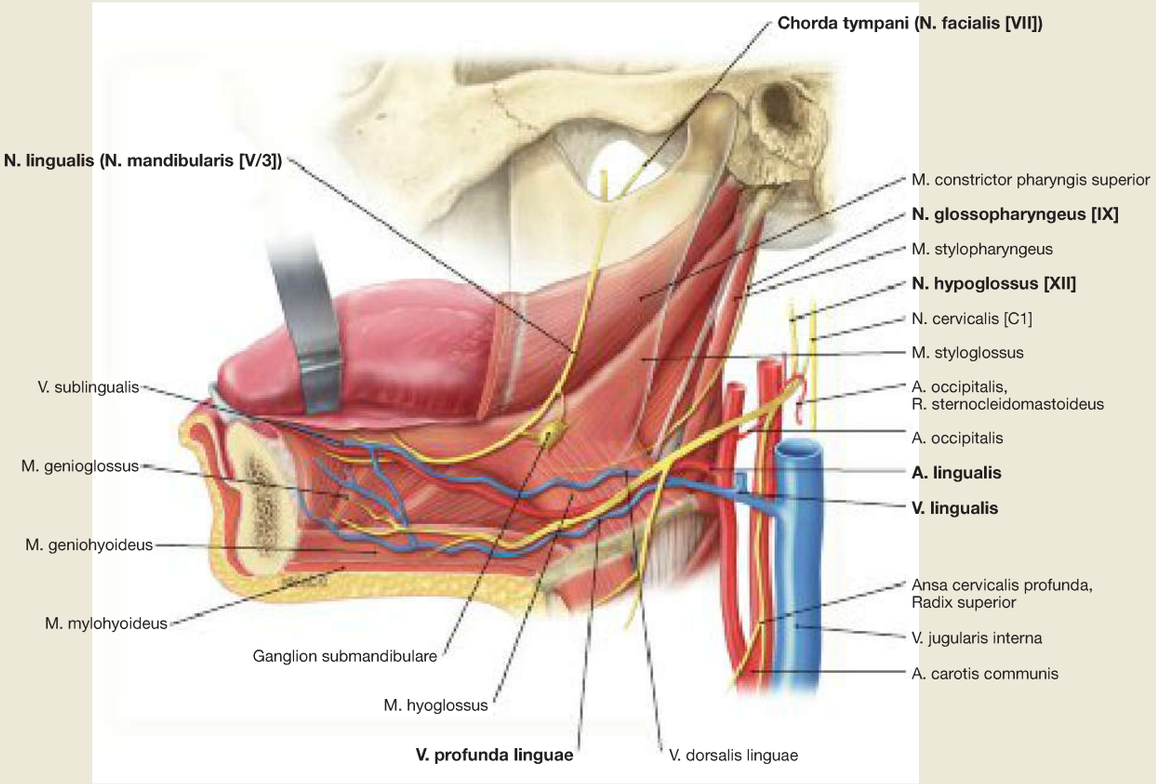

Fig. 8.181 Vessels and nerves of the tongue, Lingua; lateral view; mandibular arch removed. [L238]

Clinical Remarks

If abscesses in the floor of the mouth spread dorsally and caudally and via the neurovascular structures of the neck into the mediastinum, this may give rise to life-threatening conditions. Inflammations in the soft tissue of the lower jaw are usually associated with a swelling of the submental and submandibular lymph nodes, which are palpable under the chin or in the submandibular triangle.

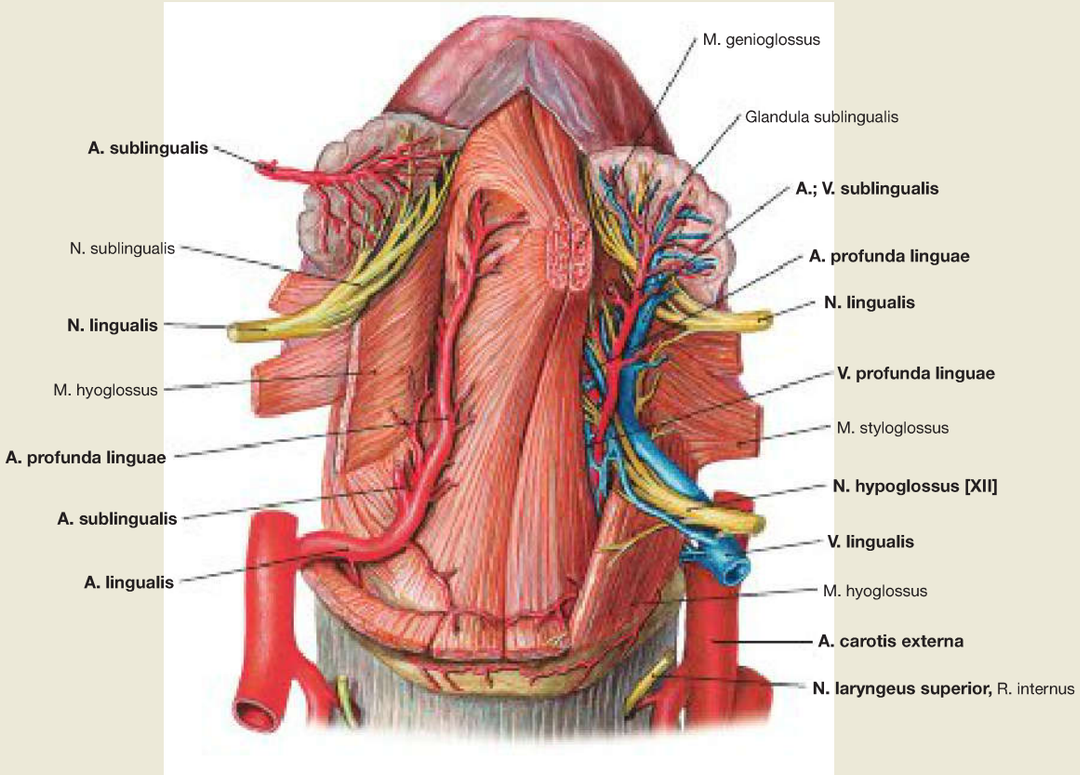

Fig. 8.182 Vessels and nerves of the tongue, Lingua; frontal view from below.

The **arterial** supply of the tongue is provided by the A. lingualis from the A. carotis externa. Branches of the A. lingualis are the A. profunda linguae, mainly supplying the muscles of the middle and anterior parts of the tongue, and the A. sublingualis, passing to the Glandula sublingualis and to the floor of the mouth. Projecting backwards, the Rr. dorsales linguae can communicate with each other, whereas all other branches are separated by the Septum linguae and therefore can only provide arterial blood to one half of the tongue.

The **venous** blood is drained via the V. lingualis. It is laterally adjacent to the M. hyoglossus and drains the blood of the tongue into the V. jugularis interna. The V. lingualis collects blood from the Vv. sublingualis, profunda linguae and dorsales linguae as well as from the V. comitans nervi hypoglossi.

With the exception of the M. palatoglossus which is innervated by the Plexus pharyngeus, the **motor innervation** of the tongue is via the N. hypoglossus [XII]. Sensory innervation in the anterior two-thirds of the tongue is provided by the N. lingualis, a branch of the N. mandibularis [V/3], in the region of the Sulcus terminalis by the N. glossopharyngeus [IX], and at the base of the tongue by the N. laryngeus superior (branch of the N. vagus [X]).

Branches of the A. lingualis:
- (R. hyoideus)
- Rr. dorsales linguae
- R. suprahyoideus
- A. sublingualis
- A. profunda linguae

Innervation of the Tongue

Nerve	Quality	Areas innervated
N. lingualis (branch of [V/3])	sensitive	anterior $^{2}/_{3}$ of the tongue
N. glossopharyngeus [IX]	sensitive, sensory	posterior $^{1}/_{3}$ of the tongue
N. vagus [X], N. laryngeus superior (branch of [X])	sensitive, sensory	transition to the epiglottis
Chorda tympani (branch of the N. intermedius as part of [VII])	sensory parasympathetic	• Papillae fungiformes • Glandula submandibularis, Glandula sublingualis, small salivary glands in the oral mucosa
N. hypoglossus [XII]	motor	all muscles of the tongue with the exception of the M. palatoglossus
Plexus pharyngeus (branches of [IX and X])	motor	M. palatoglossus

Clinical Remarks

In the mucosa under the tongue is a **subepithelial venosus plexus.** Therefore, medications administered sublingually are rapidly absorbed.

In the case of **injury to the N. hypoglossus [XII]** on one side, the tongue moves to the affected side upon extension; muscle atrophy can occur on the paralysed side.

Glandula parotidea

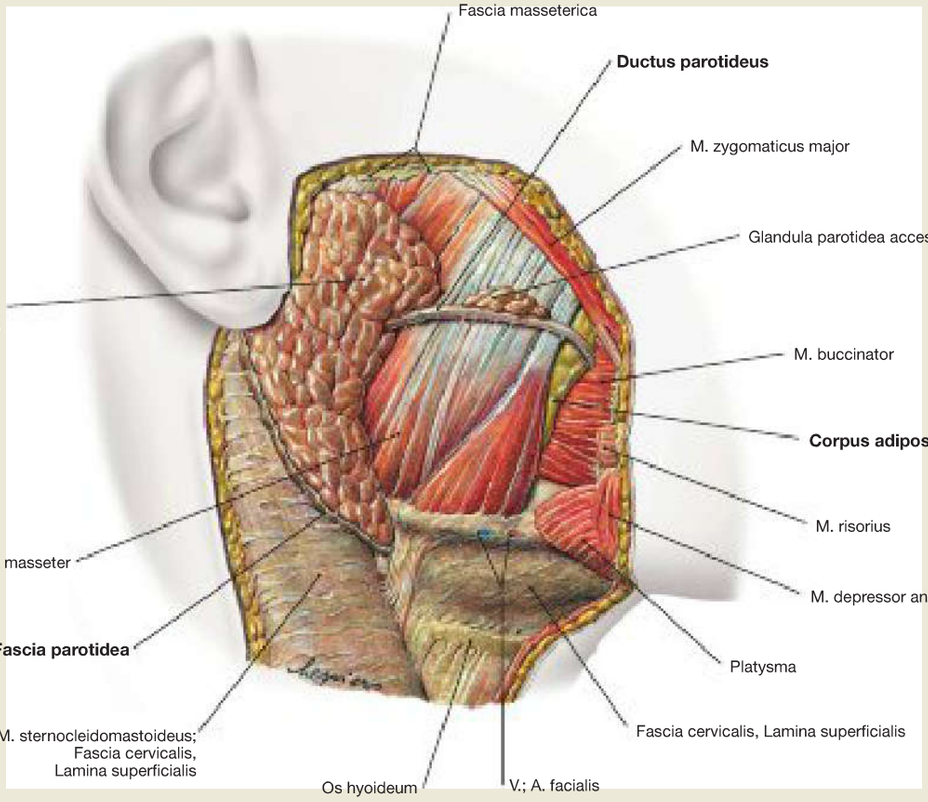

Fig. 8.183 Parotid gland, Glandula parotidea, right side; lateral view.
The purely serous Glandula parotidea is the largest oral salivary gland. Its size and dimensions are quite variable. The Pars superficialis of the gland is located immediately in front of the outer ear. It is surrounded by a fascia of dense connective tissue (Fascia parotidea) (edges of the cut shown).

The Fascia parotidea is the continuation of the Lamina superficialis of the Fascia cervicalis. At the anterior margin of the gland, the Ductus parotideus exits and runs horizontally across the upper half of the M. masseter to the M. buccinator, piercing it, and, in the Papilla ductus parotideus, opens into the Vestibulum oris opposite the second upper molar tooth. Around the excretory duct often accessory glandular tissue (Glandula parotidea accessoria) can be found.

Clinical Remarks

Surgical removal of tumours in the Glandula parotidea can result in **gustatory sweating (FREY's syndrome).** During the surgery, damage occurs to the sympathetic and parasympathetic nerve fibres innervating the glandular parenchyma. With postoperative regeneration, parasympathetic fibres occasionally synapse with formerly sympathetic innervated sweat glands of the skin. Since the neurotransmitter for the sympathetic innervation of the sweat glands is acetylcholine (as with the parasympathetic nervous system), former sympathetically innervated sweat glands are now parasympathetically innervated. In the case of parasympathetic activation (e.g. if a person is hungry and sees something delicious to eat), also the sweat glands are activated. Beads of sweat form on the cheek (gustatory sweating).
Parotitis epidemica, or mumps, is very painful, since the glandular tissue cannot expand when swelling occurs within the organ fascia.
Malignant **tumours** of the Glandula parotidea can lead to peripheral facial nerve lesions; in contrast, benign tumours of the Glandula parotidea usually do not destroy the N. facialis [VII].

Glandula parotidea, Horizontal Section

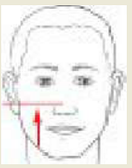

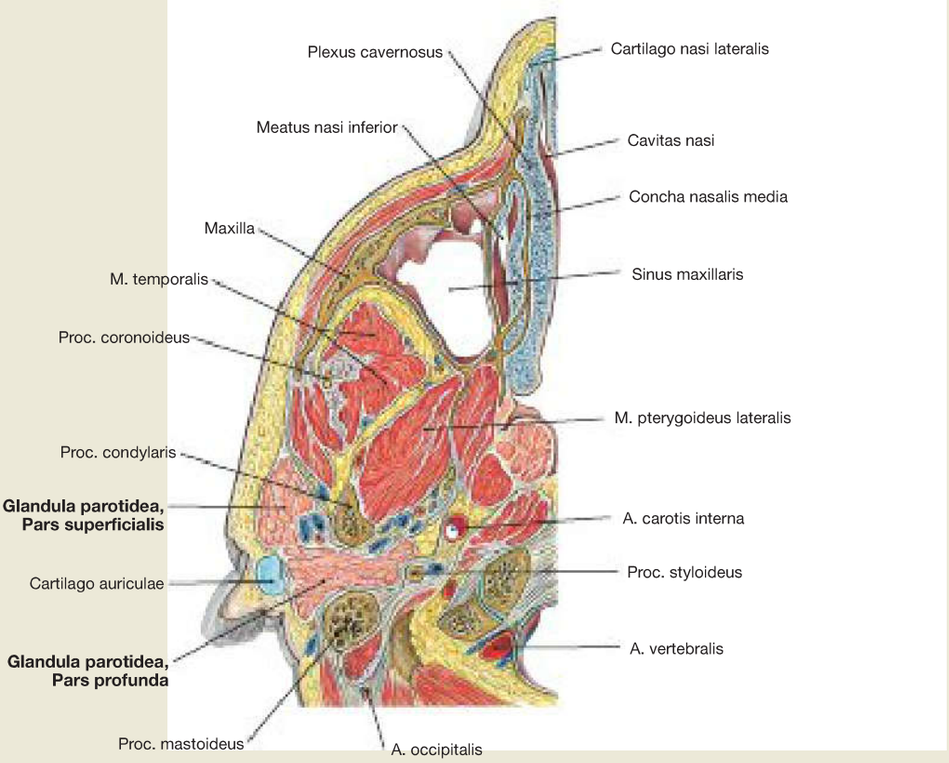

Fig. 8.184 Parotid gland, Glandula parotidea, and masticatory muscles, Mm. masticatorii; horizontal section; view from below. The Glandula parotidea consists of two parts. The upper **Pars superficialis** is located immediately in front of the outer ear. Projecting deep into the retromandibular fossa, the larger part of the gland **(Pars profunda)** is free of fascia. In this section, you can see parts of the Mm. temporalis and pterygoideus lateralis between the Glandula parotidea and Sinus maxillaris.

Salivary Glands (Glandulae salivariae oris)		
In the oral cavity, there are three large salivary glands (Glandulae salivariae majores) and numerous small salivary glands (Glandulae salivariae minores).		
Large Salivary Glands	• parotid gland (Glandula parotidea) • submandibular gland (Glandula submandibularis) • sublingual gland (Glandula sublingualis)	→ pp. 50, 52, 65, 110, 116 → pp. 52, 112–116 → pp. 76, 109, 113–116
Small Salivary Glands	• labial glands (Glandulae labiales) • cheek (Glandulae buccales) • tongue (Glandulae linguales) • palatine glands (Glandulae palatinae) • molar glands (Glandulae molares)	→ p. 84 → pp. 103, 115, 116 → pp. 98, 110

Openings of the Salivary Glands

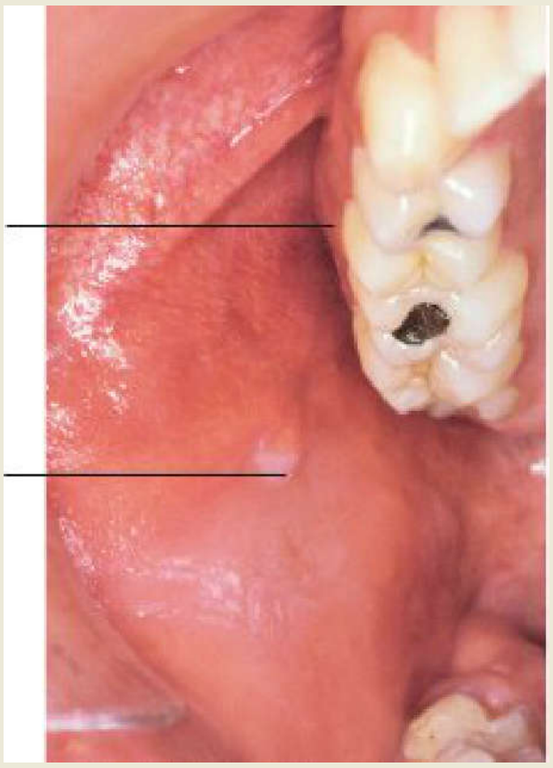

Fig. 8.185 Papilla of the parotid duct, Papilla ductus parotidei, right side; inferior view from an oblique angle. [T910]
The excretory duct of the Glandula parotidea (Ductus parotideus, STENON's duct) opens opposite the second upper molars at the Papilla ductus parotidei into the oral vestibule.

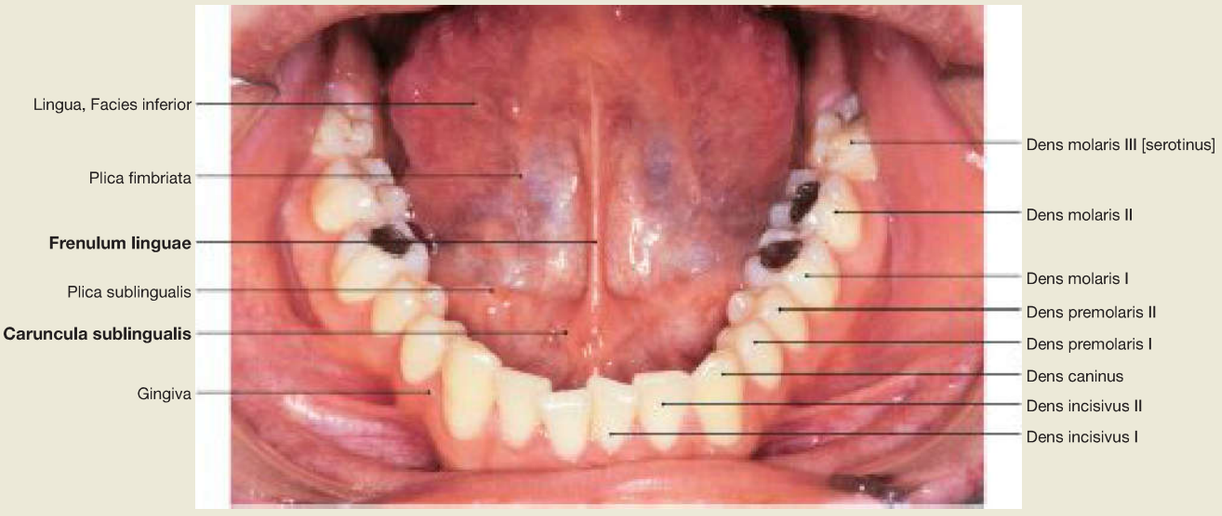

Fig. 8.186 Sublingual caruncle, Caruncula sublingualis; frontal superior view. [T910]
The excretory duct of the Glandula submandibularis (Ductus submandibularis, WHARTON's duct) runs along the floor of the mouth (→ Fig. 8.189 and → Fig. 8.190), merges with the main excretory duct of the Glandula sublingualis (Ductus sublingualis major), and at the Caruncula sublingualis on both sides of the Frenulum linguae and behind the incisors, it opens into the Cavitas oris propria.

Clinical Remarks

Malformations in the excretory duct system, especially of the Ductus submandibularis, can lead to the formation of a **ranula** (with saliva-filled retention cysts).
In kidney disease, increased levels of renally cleared substances can be detected in the saliva. Lime deposits from the saliva can lead to the formation of tartar, especially at the lingual side of the lower incisors, or to salivary stones **(sialoliths)** in the excretory ducts of the salivary glands with associated salivary colic, obstructions of the Ductus parotideus, and swelling of the gland, known as salivary tumours.
Therapeutic radiation in the treatment of tumours of the head and neck or radioactive radiation can result in a **'dry mouth' syndrome** with swallowing and speech difficulties. **Inflammation** of the salivary glands can be acute or chronic.

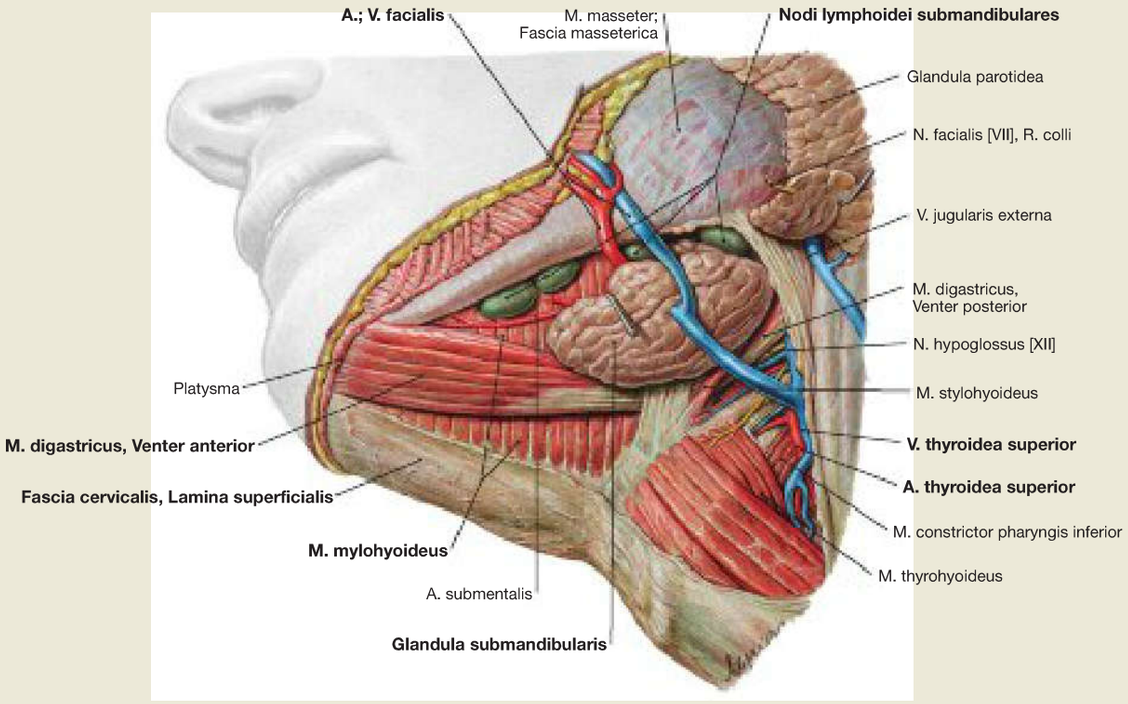

Fig. 8.187 Submandibular gland, Glandula submandibularis, left side; inferior view from an lateral oblique angle.
The Glandula submandibularis lies in the Trigonum submandibulare. The gland has its own fascia, enclosed in the superficial cervical compartment, which is delineated by the Lamina superficialis of the Fascia cervicalis (→ p. 207). The gland has a direct topographical relationship to the A. and V. facialis.

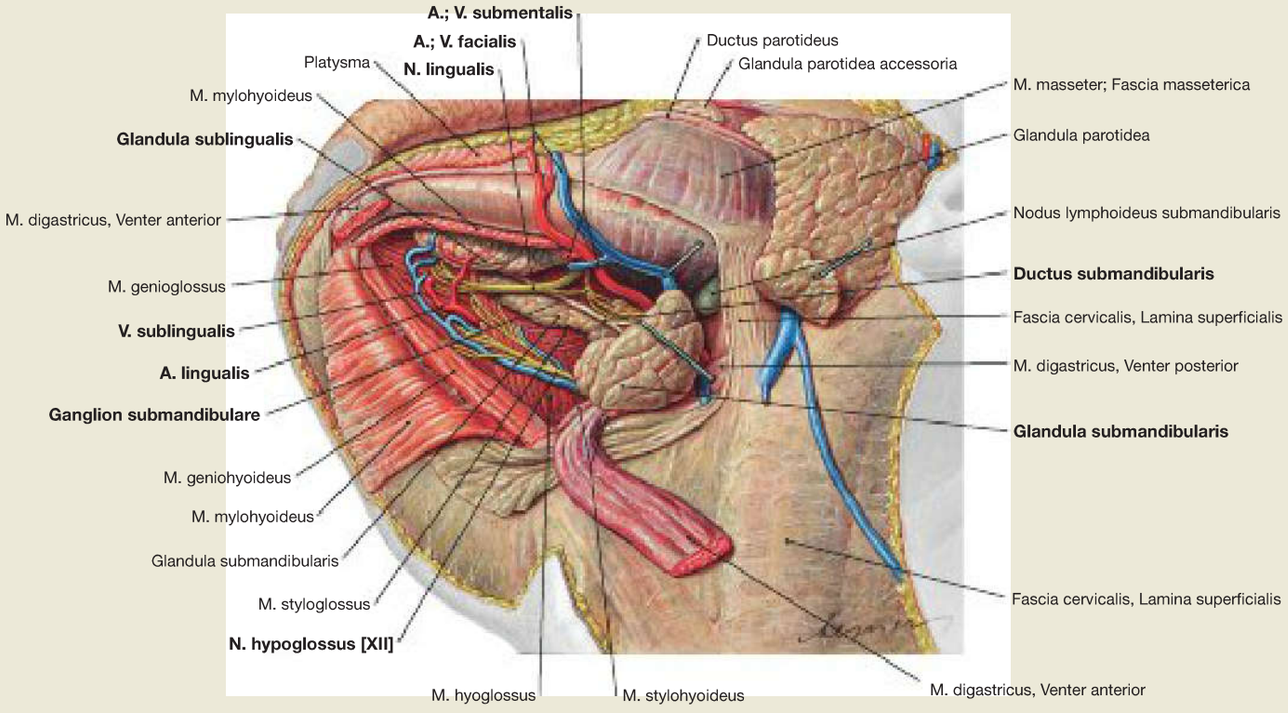

Fig. 8.188 Submandibular gland, Glandula submandibularis, and sublingual gland, Glandula sublingualis, left side; lateral inferior view.
The superficial portion of the Glandula submandibularis is folded back, the M. mylohyoideus is separated from the Mandibula and folded back medially. Under the removed muscle, the deep portion of the Glandula submandibularis and the Glandula sublingualis can be seen. The sublingual gland lies parallel to the Corpus mandibulae.

The **arterial** supply of the glands is via the Aa. facialis, submentalis and lingualis. The **venous** blood flows via the V. sublingualis and the V. submentalis into the V. facialis or directly into the V. jugularis interna.
Regional lymph nodes are the Nodi lymphoidei submentales and submandibulares.

Submandibular and Sublingual Glands

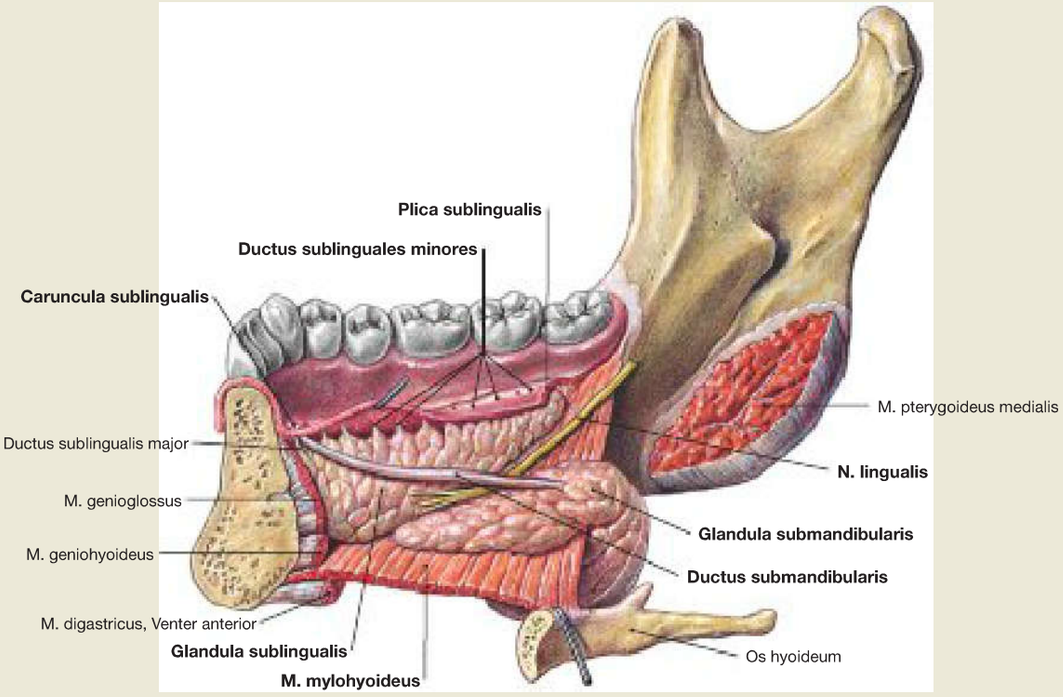

Fig. 8.189 Submandibular gland, Glandula submandibularis, and sublingual gland, Glandula sublingualis, right side; medial view.
The Glandula sublingualis lies on the M. mylohyoideus, lateral to the M. genioglossus. Sometimes it pierces the floor of the mouth. The glandular body bulges the mucosa at the floor of the mouth, creating the Plica sublingualis which contains multiple openings of smaller excretory ducts (Ductus sublinguales minores) from the posterior part of the gland. The lower portion of the Glandula submandibularis embraces the posterior margin of the M. mylohyoideus, and continues above the muscle into the Ductus submandibularis. The N. lingualis runs between the Glandula submandibularis and the Glandula sublingualis below the Ductus submandibularis to the tongue.

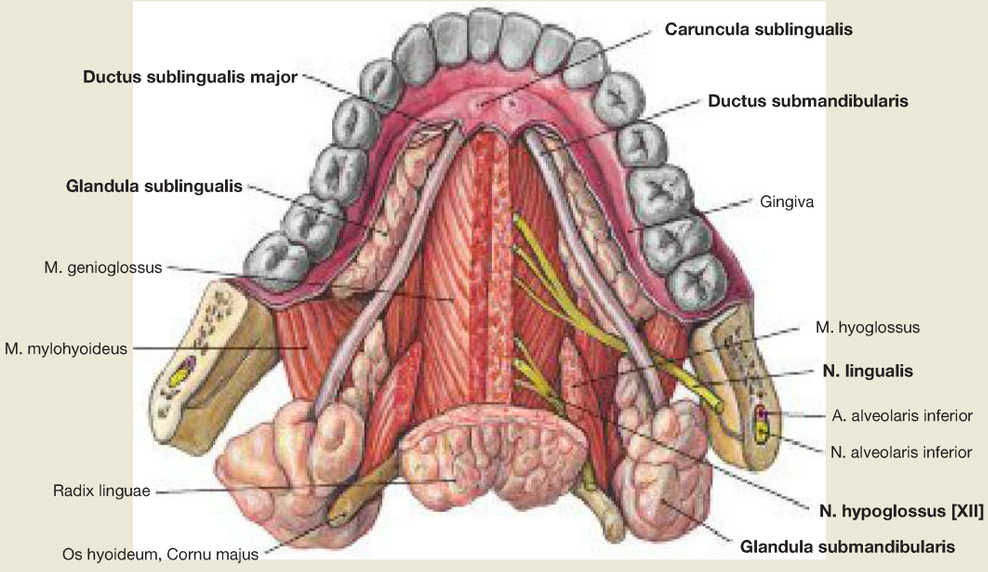

Fig. 8.190 Submandibular gland, Glandula submandibularis, and sublingual gland, Glandula sublingualis; superior view.
The anterior portion of the Glandula sublingualis has a single greater excretory duct **(Ductus sublingualis major),** which joins the Ductus submandibularis on the M. hyoglossus, where they open together at the Caruncula sublingualis. The N. hypoglossus [XII] reaches the tongue between the M. hyoglossus and the M. genioglossus.

Clinical Remarks

The excretory duct system of the Glandula submandibularis is most commonly affected by salivary stones **(sialoliths).** Salts are stored in the thickened saliva form crystalline structures, which can then be deposited as sialoliths and block the excretory duct of the salivary gland. When eating, the gland swells rapidly and hurts (→ p. 112).

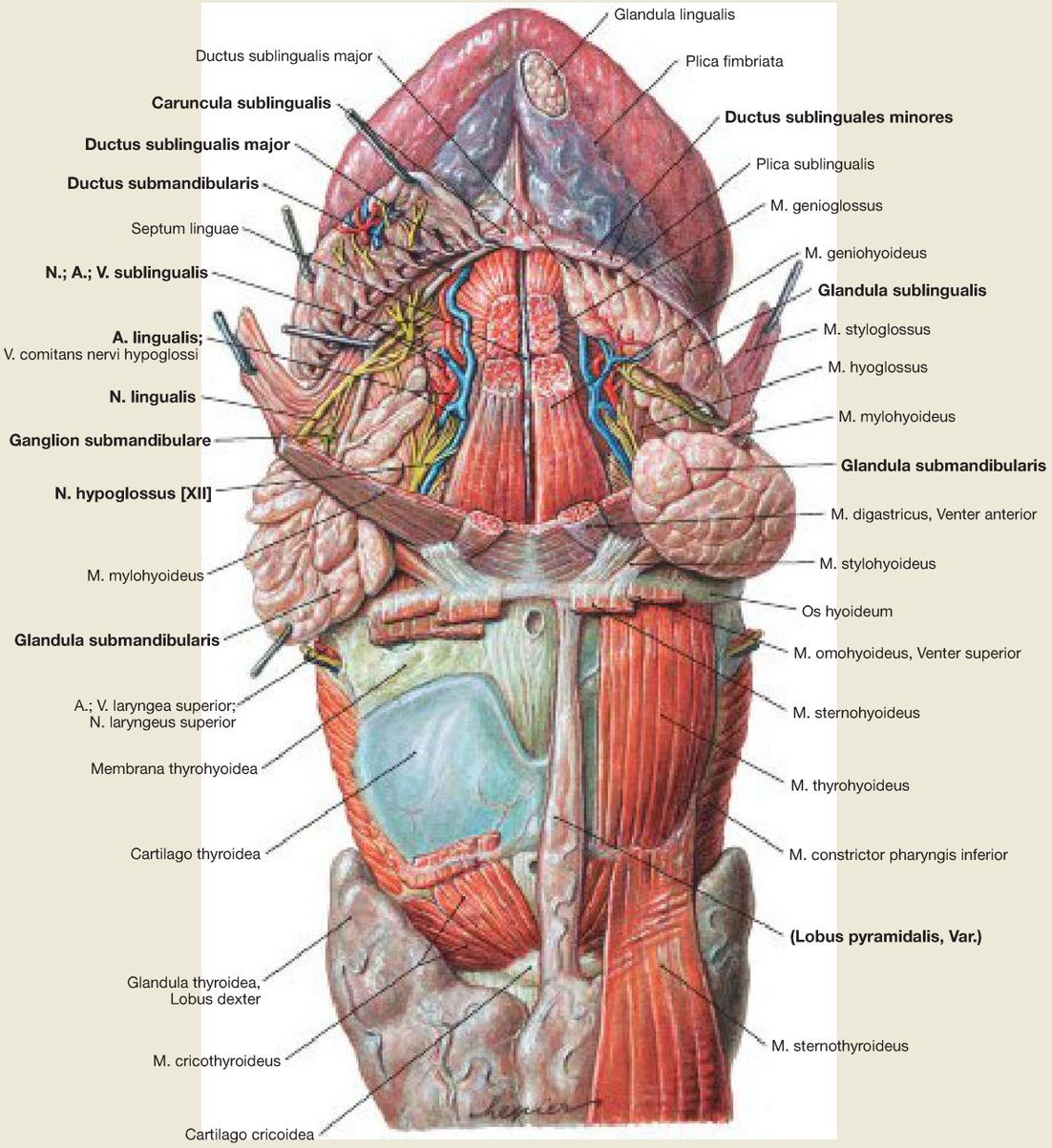

Fig. 8.191 Vessels and nerves of the tongue, Lingua, and large salivary glands, Glandulae salivariae majores; frontal inferior view. The frontal view of the elevated tongue shows a subepithelial venous plexus on the underside of the tongue. On the right, the Glandula sublingualis has been folded upwards, which gives a clear view of the underlying N. lingualis and the Ductus submandibularis (WHARTON's duct). The N. hypoglossus [XII] enters the tongue slightly deeper. As a remnant of the thyroid development, frequently a Lobus pyramidalis can be located in front of the larynx, and extend up to the hyoid bone.

Parasympathetic Innervation of the Glands of the Head

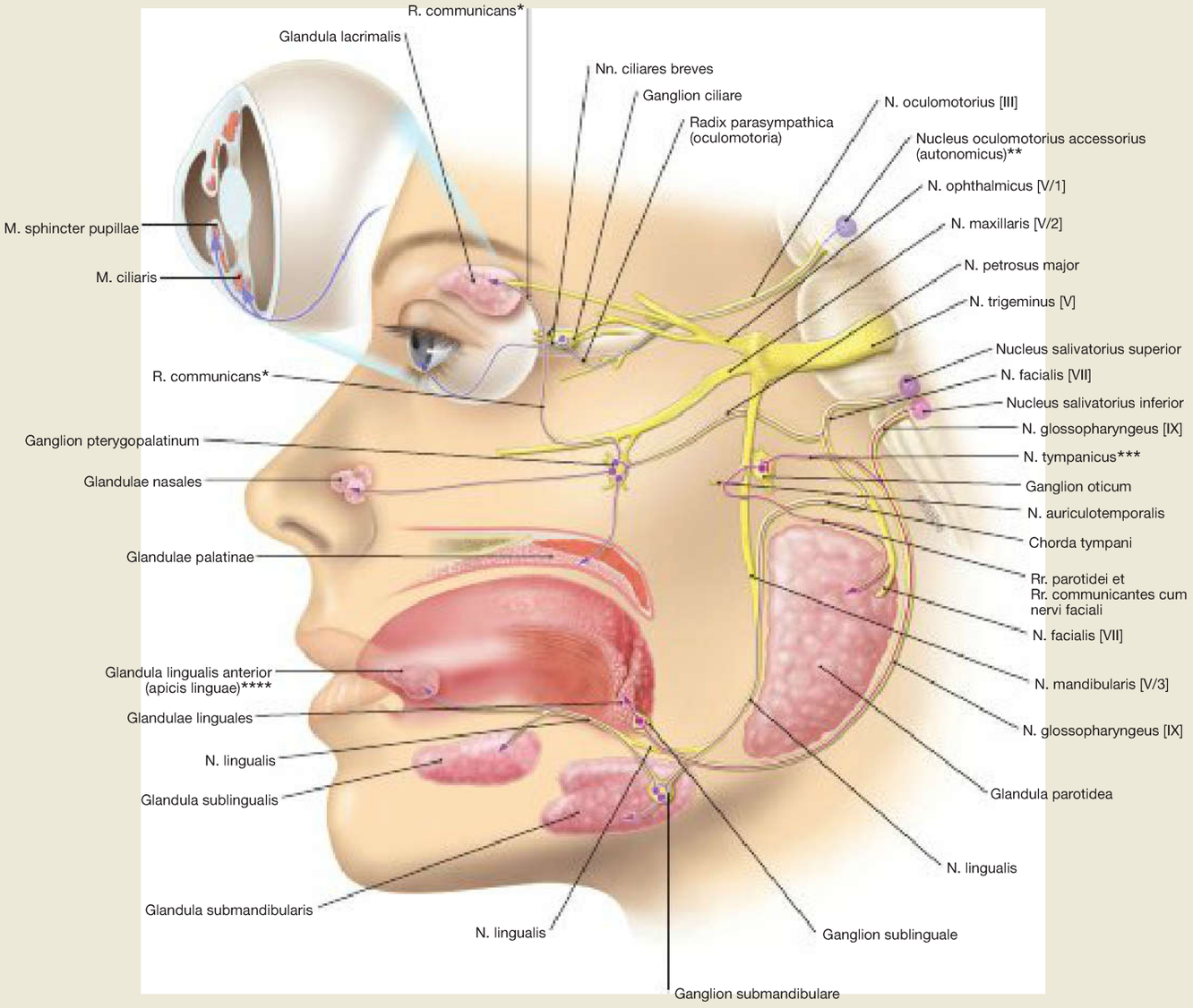

Fig. 8.192 Innervation of the glands of the head with autonomic ganglia; schematic drawing. [L238]
Parasympathetic fibres originate from the lower and upper salivatory nuclei (Nucleus salivatorius superior and Nucleus salivatorius inferior). **Preganglionic parasympathetic** fibres run to the ganglia of the head (Ganglia oticum, submandibulare, sublinguale, pterygopalatinum, ciliare) with various nerves. Here, these fibres synapse and, as short postganglionic fibres, reach their target structures (glands). **Preganglionic sympathetic** fibres for the head originate from the lateral horn of the spinal cord and are mostly switched in the Ganglion cervicale superius (upper ganglion of the sympathetic chain) to postganglionic fibres. The **postganglionic** fibres form sympathetic plexuses around the arteries (e.g. A. carotis interna) and reach their target structures together with the blood vessels or by joining local nerves.

* anastomosis of the lacrimal gland
** EDINGER-WESTPHAL nucleus
*** JACOBSON's nerve
**** glands of BLANDIN-NUHN

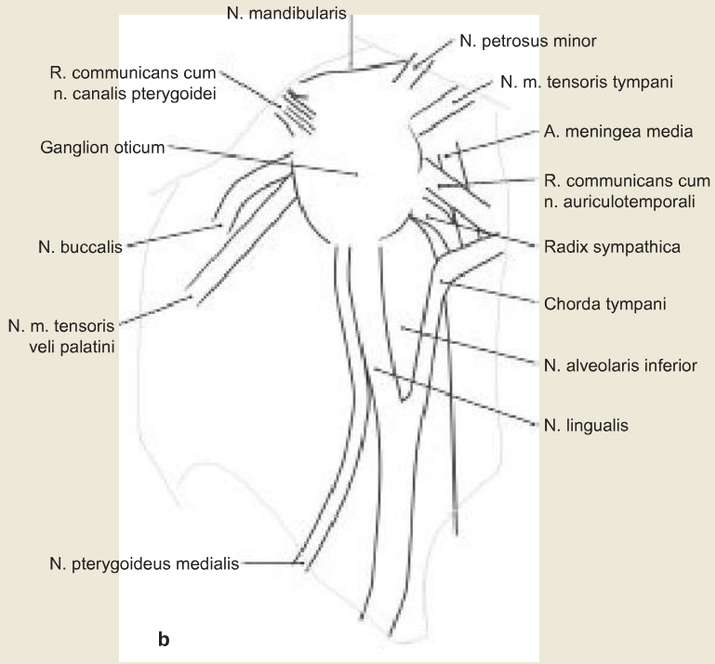

Fig. 8.193a and b Overview photograph (a) and corresponding schematic drawing of a left Ganglion oticum with its branches (b); view from the right side. [F885]

The parasympathetic Ganglion oticum is located immediately below the Foramen ovale in the Fossa infratemporalis under the cranial base. It has a close topographical relationship with the N. mandibularis [V/3], A. meningea media, M. tensor veli palatini and Pars cartilaginea of the Tuba auditiva. Through the ganglion there are running motor, sympathetic and parasympathetic fibres. The motor and sympathetic fibres run all the way without switching, while the parasympathetic fibres are switched from pre- to postganglionic. They reach the ganglion via the N. petrosus minor and leave it after switching via the R. communicans cum n. auriculotemporali, a branch of the N. mandibularis [V/3]. After a short passage with the N. auriculotemporalis, the nerve fibres within the Glandula parotidea join up with fibres of the N. facialis [VII] for a short distance, then they reach the glandular parenchyma (Rr. communicantes cum n. faciali). The parasympathetic fibres are not only responsible for the secretory innervation of the Glandula parotidea, but also innervate the Glandulae buccales. The continuous motor fibres originate from the N. pterygoideus medialis (from [V/3]) and having passed through the Ganglion oticum, innervate as N. musculi tensoris tympani the M. tensor tympani, and as the R. musculi tensoris veli palatini also the M. tensor veli palatini. The sympathetic fibres are postganglionic fibres, which have already been switched in the Ganglion cervicale superius and have reached the Ganglion oticum via the Plexus caroticus externus. After passing through the Ganglion oticum, they reach the Glandula parotidea and the Glandulae buccales.

Ganglion pterygopalatinum

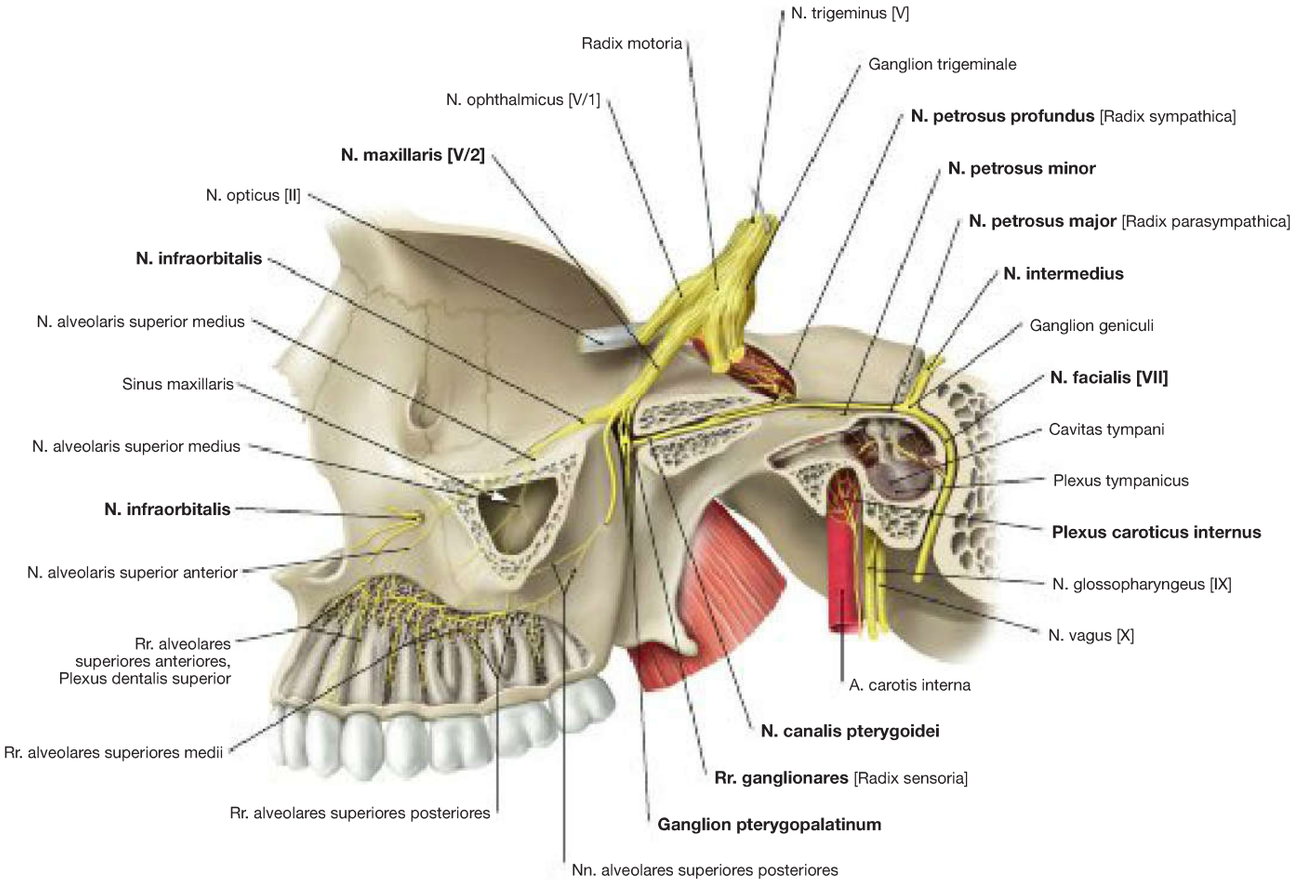

Fig. 8.194 Ganglion pterygopalatinum. [L275]
Sensory nerve fibres run within the Rr. ganglionares of the N. maxillaris [V/2] via the Ganglion pterygopalatinum to reach the soft and hard palate. Parasympathetic fibres from the superior salivatory nucleus reach the Ganglion pterygopalatinum via the N. facialis [VII] (N. intermedius), the N. petrosus major and the N. canalis pterygoidei, and are switched here from preganglionic to postganglionic. The postganglionic parasympathetic fibres innervate the lacrimal, nasal and palatine glands. The postganglionic sympathetic fibres originate from the N. caroticus internus (Plexus caroticus internus), assemble to form the N. petrosus profundus and pass through the Ganglion pterygopalatinum to innervate the lacrimal, nasal and palatine glands.

Practice Exam Questions

To check that you are completely familiar with the content of this chapter, practice questions from an oral anatomy exam are listed here.

Explain the structure of the skull:

- Which bones border the orbit, which entry and exit points does the Orbita have, and what enters and exits?
- Which bones confine the nasal cavity?
- Do you know which spaces hold air in the skull? How will these be ventilated?
- How are the cranial bones structured?
- What is meant by fontanelles, and when do they close?
- Explain the structure of the Articulatio temporomandibularis.
- How many and which teeth form part of the primary dentition?
- What are the special features of the Os temporale?

Describe the structure of the face:

- Which parts does the M. orbicularis oculi share? What are they used for?
- Which muscles in the face have a fascia, which do not? Describe their functions.
- Describe the route of the N. facialis [VII] after exiting the Foramen stylomastoideum.
- Which masticatory muscles do you know, how are they supplied with blood and how are they innervated? Which nerve innervates the masticatory muscles?
- Describe the inflow and outflow/anastomosis of the V. facialis.
- How is the Galea aponeurotica structured?
- Which structure is at risk in the context of diseases of the Glandula parotidea?
- What is the juxtaoral organ, where is it, and how should it function?
- Into which lymph nodes does the lymph of the facial area drain?

Describe the structure of the nose:

- How are the bone and cartilage of the nose structured?
- How is the nose supplied with blood? How do arteries reach the nose?
- What is the Hiatus semilunaris, how is it confined and what usually drains or ends here?
- What is the KIESSELBACH's plexus?

Explain the structure of the oral cavity:

- Which structures open into the oral cavity?
- How is the oral cavity confined?
- Describe the innervation of the tongue.
- Which papillae occur on the tongue?
- Which muscles of the tongue do you know? How are they innervated?
- What is between the anterior and the posterior palatine arches?
- How is the Tonsilla palatina supplied arterially?
- How are the teeth innervated? Where should the dentist inject a local anaesthetic to numb the teeth of the maxilla and the mandible?
- What happens if the mandibular teeth are anaesthetised by a local injection before the Foramen mandibulae has been anaesthetised?
- How does the palate develop?
- Which muscles are involved in the movement of the soft palate?
- What is the problem with a cleft palate?

Explain the structure of the Fossa pterygopalatina:

- Which structures pass through the Fossa pterygopalatina?
- What is switched in the Ganglion pterygopalatinum?
- Which bones limit the Fossa pterygopalatina?
- Name the topographic relationships of the Fossa pterygopalatina.

Describe the structure of the floor of the mouth:

- Which muscles belong to the floor of the mouth?
- How are the muscles innervated?
- Which muscles of the floor of the mouth are involved in opening the jaw?

Explain the position and the structure of the salivary glands:

- What are the parts of the Glandula parotidea?
- To what does the Glandula parotidea have a topographic relationship?
- Describe the route of the Ductus parotideus.
- Where does it enter the Glandula sublingualis?
- Illustrate the orifice of the Ductus submandibularis.
- Where are the sympathetic and parasympathetic fibres for the innervation of the large salivary glands?
- Name the small salivary glands, describe their locations.
- How are the salivary glands supplied with blood?

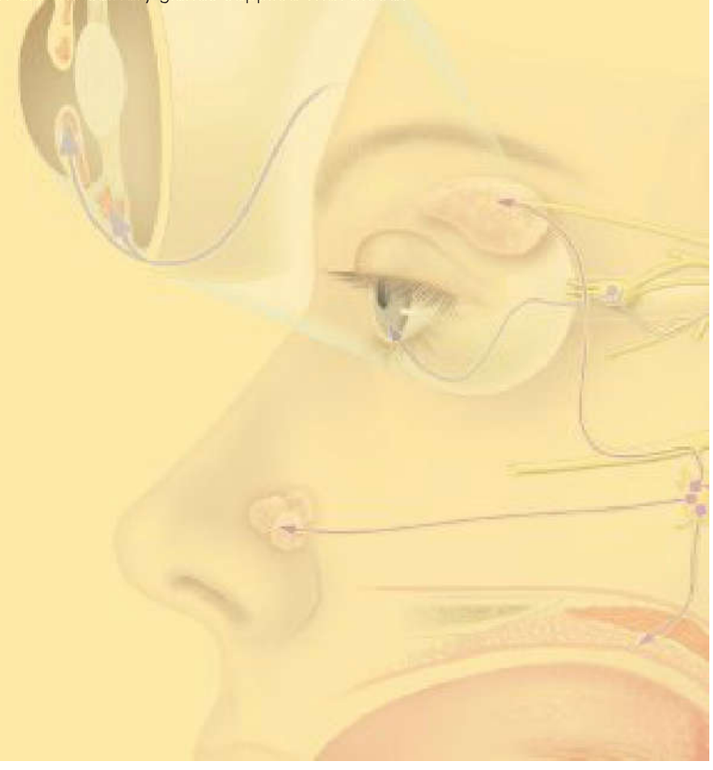

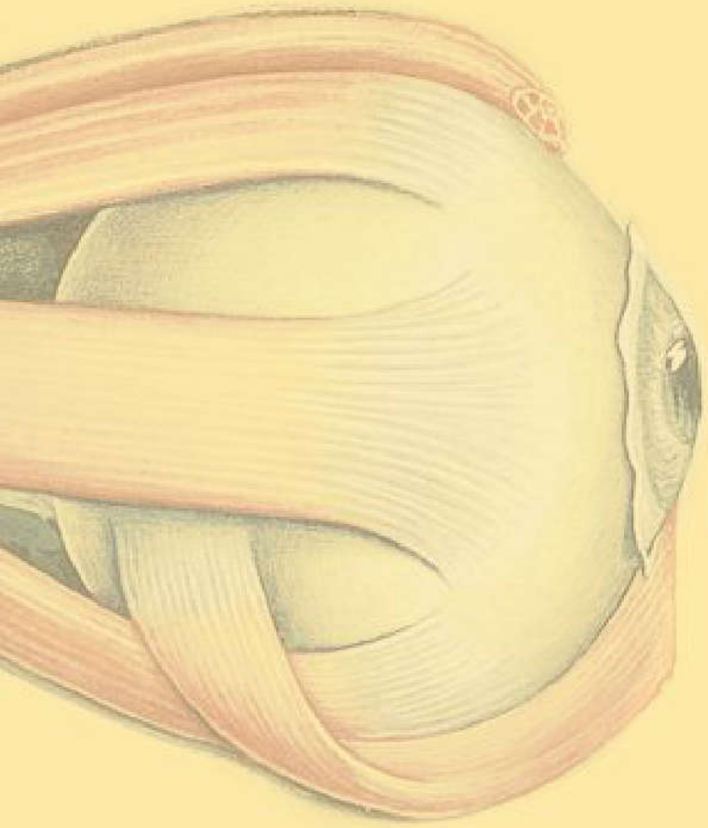

Eye

Development 124

Skeleton 126

Eyelids 128

Lacrimal Apparatus 135

Muscles of the Eye 141

Topography 145

Eyeball 154

Visual Pathway 160

9

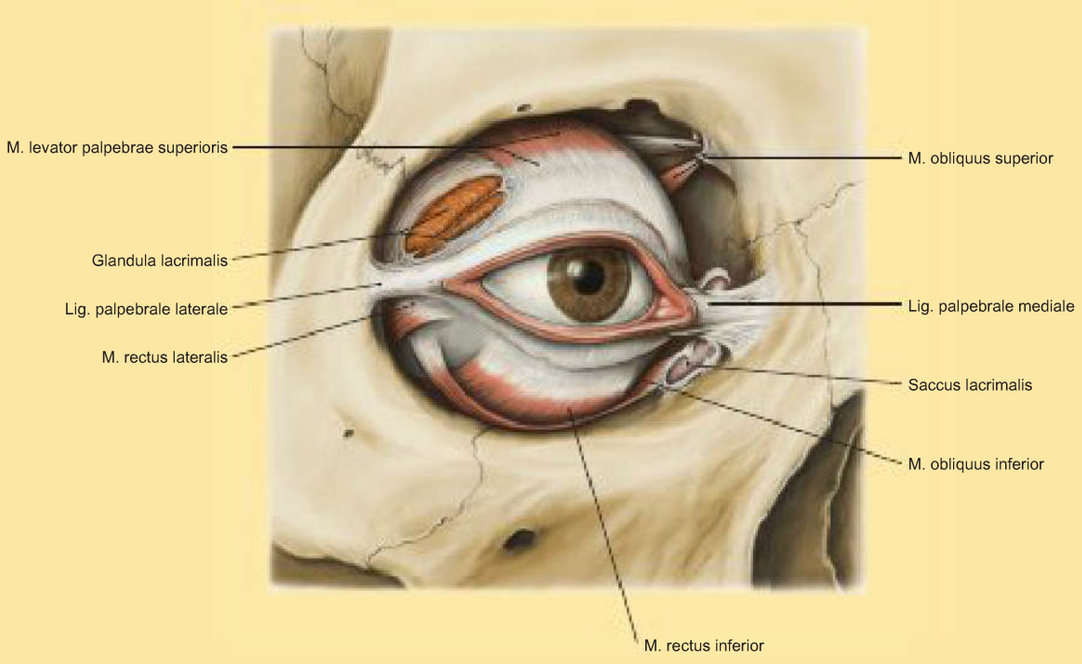

Overview

The eye or sight organ (Organum visus) is often referred to as the 'gateway to the soul' and is considered by many people to be the body's most important sensory organ. It includes the **eyeball** (Bulbus oculi), the optical apparatus and the auxiliary structures (Structurae oculi accessoriae) such as **extraocular muscles** (Mm. externi bulbi oculi), **eyelids** (Palpebrae), **conjunctiva** (Tunica conjunctiva) and **lacrimal apparatus** (Apparatus lacrimalis). The Bulbus oculi has a diameter of approximately 24 mm and is encased in a **connective tissue capsule** (Vagina bulbi) and embedded in a **adipose body** (Corpus adiposum orbitae), together with the auxiliary structures (with the exception of the eyelids) in the bony **eye socket** (Orbita). The position of the Bulbus oculi can be adjusted to see in all directions with the help of six external (or extraocular) muscles; four rectus and two oblique. The Bulbus oculi itself consists of three layers. The outer layer is made up of the **outer (fibrous) layer of the eyeball** (Tunica fibrosa), the sclera and cornea (Stratum corneum). The cornea is clear and forms the window to the outside world, through which anything, which is to be seen, enters the inner eye. Directly below the surface is the **middle (fibrous) layer of the eyeball** (Tunica vasculosa) consisting of the iris and the choroid (Corpus ciliare and Choroidea). Inside the **inner layer of the eyeball** (Tunica interna) joins as the retina. This is where the receptors are situated which register the visual impression and then pass it on. The interior of the Bulbus oculi is separated in an **anterior** and a **posterior chamber** (Camera anterior and Camera posterior). The border between the two spaces forms the ocular lens (Lens oculi). The anterior chamber of the eye contains intraocular fluid, the posterior chamber is filled with the **vitreous humour** (Corpus vitreum).

Main Topics

After studying this chapter, you should be able to:

- understand the development of the eye from the three original tissue layers of the neuroectoderm of the diencephalon, the surface ectoderm of the head and the mesenchyme, and the resulting structure of the eye;
- name the structure of the Orbita and the structures involved in its development, as well as name the entering and exiting structures;
- explain the content of the Orbita and to differentiate between its different segments;
- describe the topographic relationships of the Orbita to neighbouring structures;
- explain the structure and the function of the auxiliary structures such as eyelids, conjunctiva, lacrimal apparatus with lacrimal gland and the lacrimal drainage system from the point of view of functional aspects;
- describe and distinguish between the structure and function of the extraocular muscles, their fixation in the Orbita and the blood supply and innervation of the Bulbus oculi and the Orbita;
- explain the individual parts of the Bulbus oculi and describe their functions

Clinical Relevance

In order not to lose reference to future everyday clinical life with so many anatomical details, the following describes a typical case that shows why the content of this chapter is so important.

Orbital Blow-out Fracture

Case Study

A 24-year-old student was playing squash on the first day of his semester vacation. During the game, a ball bounced off the wall and he could not get out of the way quickly enough. The squash ball hit him in the centre of his right eye (→ Fig. a). He clutched his right eye in pain. Using his mobile phone, his friend immediately called the emergency services, after which he obtained a cool pack from the squash court restaurant to cool the right eye.

Result of Examination

During the initial examination, the emergency physician noticed that the right Bulbus oculi seemed to be withdrawn into its socket (enophthalmos). The right eyelid structures are not only swollen, but there are also signs of bleeding into the soft tissue of the eye (monocular haematoma of the right side). Although the student could still see with this eye, he was almost completely unable to follow the doctor's finger moving in all directions. The student also complained of double vision. When the emergency physician brushed the skin below his right eye he felt no sensation.

Diagnostic Procedure

The student was taken to the university eye hospital. A skull CT was performed. The CT shows a fracture of the orbital floor with a shift of the eye socket content towards the right maxillary sinus (Fig. b). The N. infraorbitalis, the M. orbicularis inferior and the M. rectus inferior have shifted. Otherwise, the paranasal sinuses and the viscerocranium are intact. Other routine examinations of the eye reveal no evidence of retinal detachment or other damage within the Bulbus oculi. The patient has 100% vision.

Diagnosis

Blow-out fracture to the right, with the participation of the N. infraorbitalis and entrapment of the lower extraocular muscles.

Treatment

The student is prepared for an operational orbital floor reconstruction procedure for the next morning. This is necessary, since each orbital floor fracture, with symptoms such as double vision, sensory disturbances and enophthalmos, must be operated on as soon as possible in order to prevent an ascending infection from the bacteria populated maxillary sinus into the sterile Orbita. Furthermore, the pressure on the N. opticus could lead to loss of vision or permanent double vision due to an atrophy of the eye muscles. Within the framework of the operation, the soft tissue will first of all be shifted back and the bone fragments replaced, as far as possible, in the correct position. Then follows the orbital floor reconstruction with homologous material (e.g. lyophilised dura). Alternatively, the reconstruction could be performed using alloplastic materials (e.g. plastic or metallic osteosynthesis material).

Further Developements

The postoperative recovery is satisfactory. After one week there are hardly any problems with double vision. The soft tissue shell of the external eye is only slightly swollen and now has a yellow-green colour.

Dissection Lab

Isolated orbital floor fracture (blow-out fractures) are rare in relation to the total number of central facial fractures.

Sports, traffic and work accidents, as well as brutal are the most common causes of isolated orbital floor fractures.

It is far more common to encounter an orbital floor fracture in combination with other fractures. It is important to consider the complexity of the bony structures of the viscerocranium and the passage of the neurovascular pathways, particularly during the physical examination, in order to be able to determine the true extent of the damage. It is recommended that the persons involved in the reconstruction of the eye socket and the surrounding bone structures invest an appropriate amount of time in the study of the facial skull, in the dissection lab.

Note the thin bony walls when dissecting the eye socket.

One must always remind oneself of just how many structures there are in such close proximity.

Back in the Clinic

Due to the impact of the squash ball, the Bulbus oculi was pushed back in the funnel-shaped Orbita. Generally speaking; injuries of the blood vessels in the soft tissue shell of the eye and the eyelids are more common than nerve injury. Sometimes the N. opticus can also be compressed into its bony canal (Canalis nervi optici). The N. infraorbitalis is often affected because it extends into the cheek via the Fissura orbitalis inferior and the Foramen infraorbitale. That is why sensitivity testing (lightly brushing against the skin), especially of the lower eyelid, cheeks and upper lip, is so important.
Three of the four orbital walls border on the sinuses. In the case of this student, the contusion of the Bulbus oculi broke the orbital floor.

The orbital floor is also the roof of the maxillary sinus. Therein lies the N. infraorbitalis.

As a result, the M. rectus inferior and the M. orbitalis inferior are squeezed into the gap resulting from the fracture. This explains the double vision in the initial examination. With a fracture of the Paries medialis, which to a large extent is structured from the lamina papyracea of

The Lamina papyraceais is aptly named. It is transparent and can almost be seen through.

the Os ethmoidale, the air from the ethmoidal cells can penetrate into the orbital adipose tissue or under the skin of the eyelid (air emphysema). This results in a quiet crackling sound in the palpation of the eyelid. Until such time as the injury is completely healed, the patient must not wipe his nose. Nose drops can be prescribed to allay inflammation or congestion. After any mid-facial fractures, a check for a liquor fistula must be made. If this is the case then a clear secretion (liquor) could trickle out of the nose. Due to the risk of infection where there is an open connection between the Orbita and the paranasal sinuses, treatment with an antibiotic is imperative.

a

b

Fig. a Incident report: the ball hits the Bulbus oculi, which causes an orbital floor fracture, leading to a shift of the eye socket content into the maxillary sinus. [L126]
Fig. b Coronary skull CT: fracture of the orbital floor of the left eye with a shift of the orbital structures into the maxillary sinus. [R349]

Development

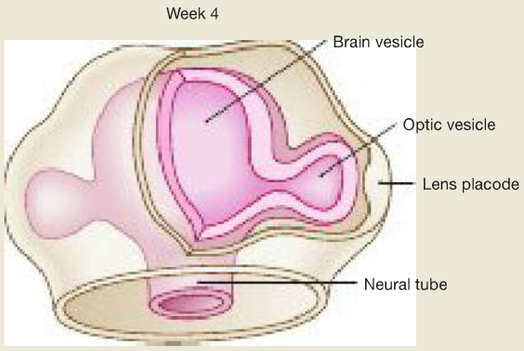

Fig. 9.1 Eye development, 4th week. [E838]
In the fourth week the optic vesicles (Vesicula optica) bulges out of the diencephalon area of the prosencephalon. The optic vesicles (Vesicula optica) make their way further towards the surface and induce the formation of a lens placode in the surrounding surface ectoderm.

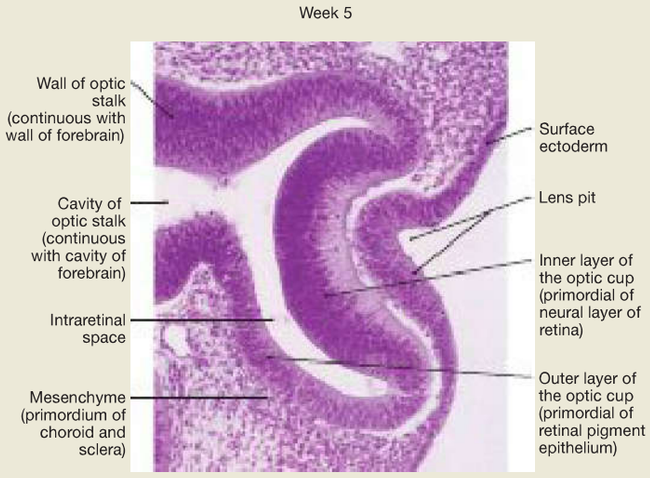

Fig. 9.2 Eye development, 5th week; photomicrograph of a sagittal section. [E347-09]
The image shows the optic vesicles which have slipped into the optic cup (or ophthalmic cup) and have already formed a close connection with the lens placode. Located between the two layers of the optic cup (primordium of the retina) and in the optic stalk (primordium of the N. opticus [II]), the intraretinal space is still relatively wide.

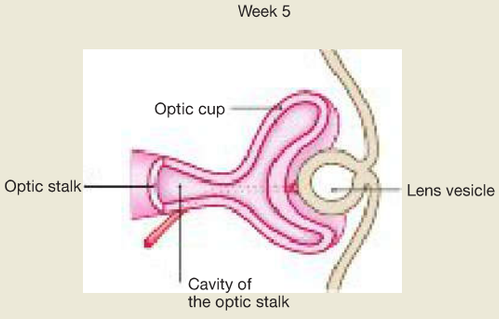

Fig. 9.3 Eye development, 5th week. [E838]
The spherical lens vesicle separates from the surface ectoderm and the rim of the optic cup infolds on the lens vesicle. The optic cup is still connected with the diencephalon by a small optic stalk, the former Sulcus opticus.

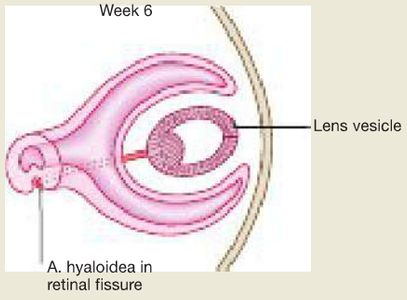

Fig. 9.4 Eye development, 6th week. [E838]
At the deepest point of the optic cup, a longitudinal groove, the optic fissure becomes visible. This optic fissure contains blood vessels and the first nerve fibres of the later N. opticus [II]. During the development stage, the blood vessels supply the inside of the optic cup via the A. and V. hyaloidea. During the seventh month of pregnancy, the blood vessels in the optic cup disappear; in the N. opticus [II], the vessels remain as the A. and V. centralis retinae.

Development of the Eye

The development of the eye starts at the beginning of the fourth week when the optic vesicles slip out of the diencephalon area of the prosencephalon. After a short time, the anterior pole folds inwards to form a primitive optic cup. The retinal pigment epithelium derives from the posterior section of the outer layer of the optic cup, whereas its anterior section gives rise to the Corpus ciliare and iris. The inner layer of the optic cup forms the retina. At the contact zone between the optic cup and the surface epithelium the lens vesicle releases itself and sinks. The epithelial tissues of cornea and conjunctiva also have their origins in the ectoderm. Most of the other components of the middle and outer eye are of mesenchymal origin. In the beginning, the lens system is made up of a blood vessel network (with contribution by the A. hyaloidea), which regresses later. The proximal stump of the A. hyaloidea becomes the A. centralis retinae.

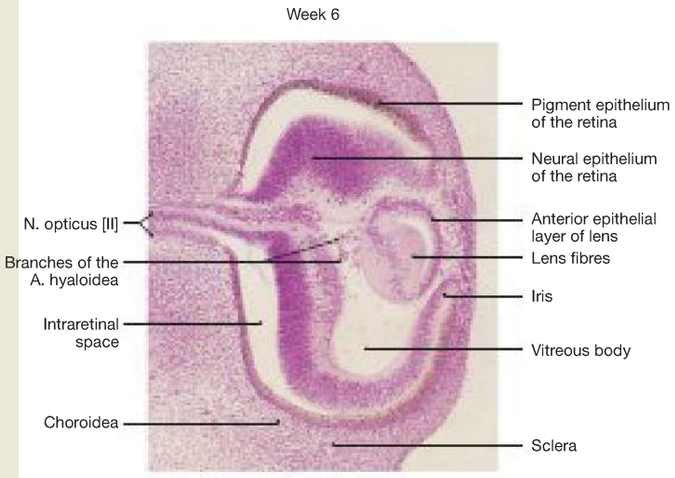

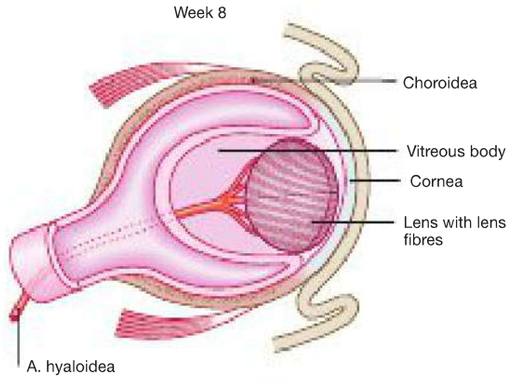

Fig. 9.5 Eye development, 6th week; photomicrograph of a sagittal section. [E347-09]
In the sixth week the epithelial cells in the posterior wall of the lens vesicle elongate and form the lens fibres.

Fig. 9.6 Eye development, 8th week. [E838]
Mesenchyme cells migrate into the optic cup and form the vitreous body (Corpus vitreum) that is composed of vitreous humour, a gelatinous substance with tiny fibres embedded. The vitreous body gives the eyeball its firm shape.

Fig. 9.7 Male newborn with cyclopia. [E347-09]
Cyclopia is a malformation of the face and eye associated with a proboscis-shaped nasal appendage above a single medially located eye.

Fig. 9.8 Newborn male with anophthalmia. [E347-09]
Congenital abscence of all components of the eye and a single right nostril, with left nostril not formed. The eyelids have formed but they have almost entirely fused together.

Clinical Remarks

Developmental defects of the eye are relatively rare. Inherited blindness has an incidence of 20 per 100,000 live births and in most cases, coincides with other (mental) disabilities. In certain rare cases, remnants of the A. hyaloidea make their way from the N. opticus into the vitreous body or even into the lens and can cause a clouding of the lens. In most cases, the **persistence of the A. hyaloidea** is without clinical significance. The term **cyclopia** refers to the partial or complete merging of both eyes in the middle of the face (→ Fig. 9.7). This congenital abnormality or absence of ocular tissue from the Orbita is known as **anophthalmia** (→ Fig. 9.8).

Bony Eye Socket

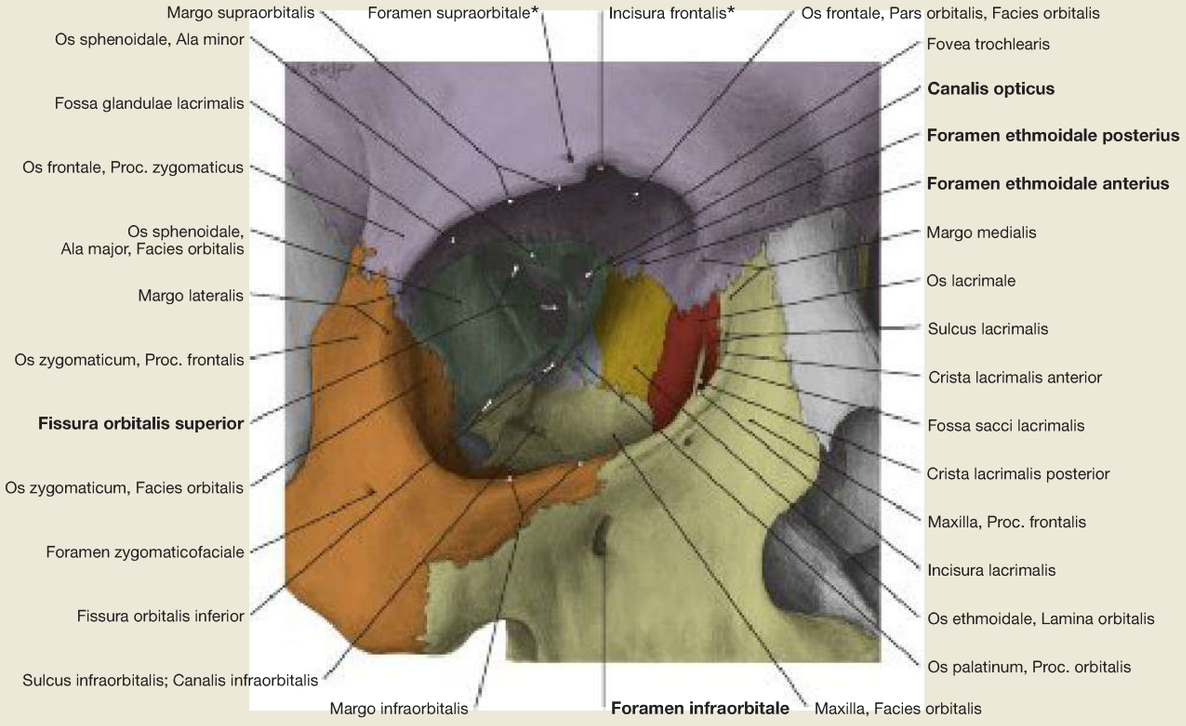

Fig. 9.9 Eye socket, Orbita, right side; frontal view from an oblique angle; for colour chart see p. VIII.
The orbital walls are formed from seven bones (Os frontale, Os ethmoidale, Os lacrimale, Os palatinum, Maxilla, Os sphenoidale and Os zygomaticum). The Paries lateralis borders on the Fossa temporalis, the Paries medialis is located close to the ethmoidal cells and the nasal cavity. In the posterior aspect are close topographical relationships to the middle cranial fossa, Canalis opticus and the Fossa pterygopalatina.

*These structures can be formed as Foramina or Incisurae.

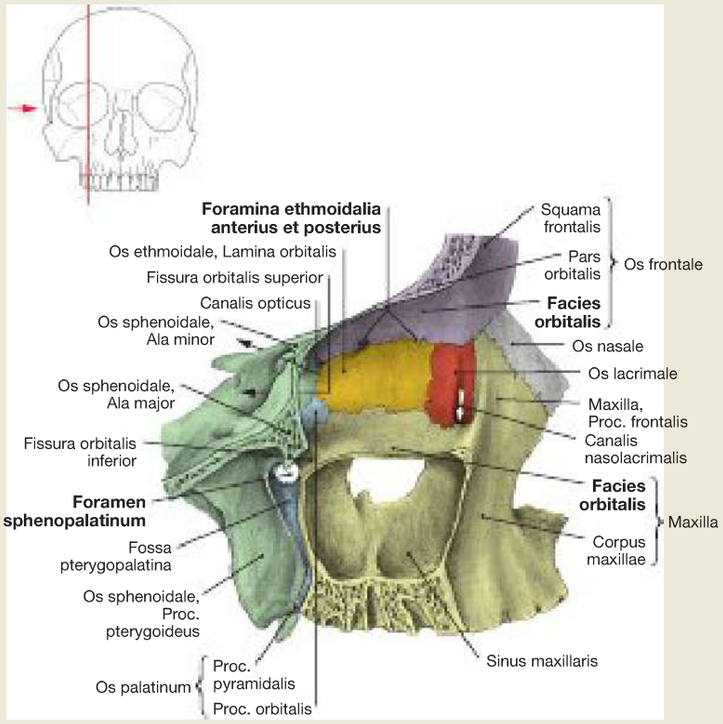

Fig. 9.10 Medial wall of the eye socket, Paries medialis orbitae, right side; lateral view; for colour chart see p. VIII.

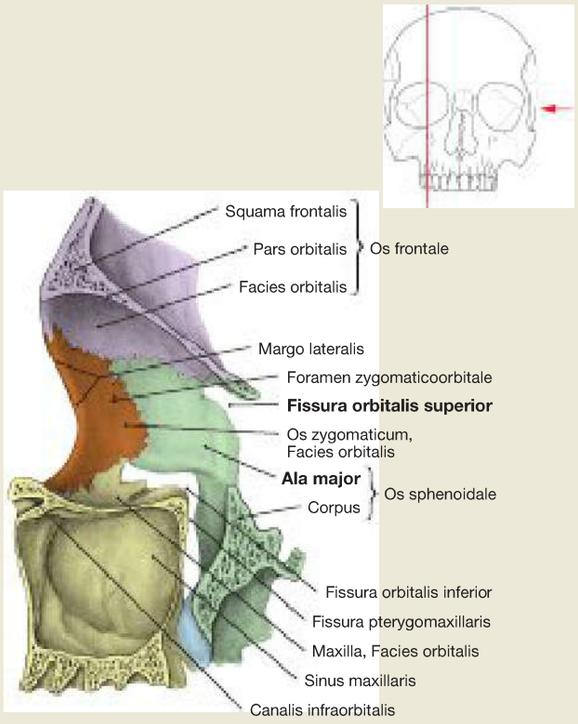

Fig. 9.11 Lateral wall of the eye socket, Paries lateralis orbitae, right side; medial view; for colour chart see p. VIII.

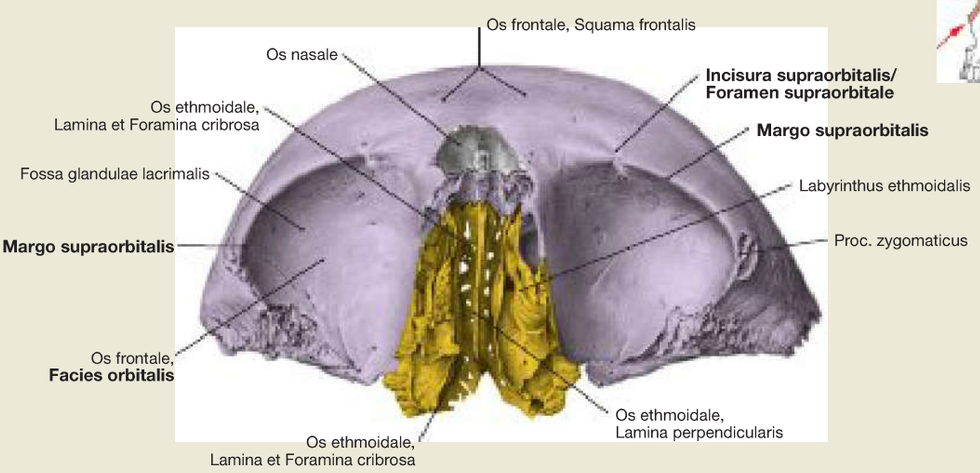

Fig. 9.12 Roof of the eye socket, Paries superior orbitae; inferior view; for colour chart see p. VIII.
The roof of the Orbita is also the floor of the anterior cranial fossa and of parts of the Sinus frontalis. All bones of the Labyrinthus ethmoidalis are extremely thin and can be easily fractured during surgical procedures.

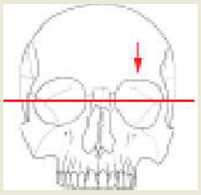

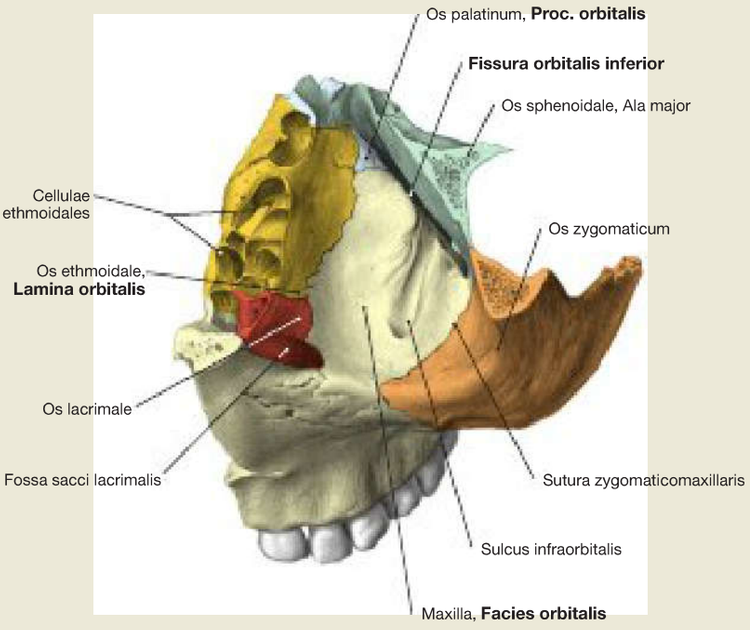

Fig. 9.13 Floor of the eye socket, Paries inferior orbitae, left side; superior view; for colour chart see p. VIII.
The floor of the Orbita is also the roof of the Sinus maxillaris. In its posterior aspect is the Sulcus infraorbitalis, the anterior aspect of which goes through a bony canal through the maxilla and comes out as an Foramen infraorbitale (not visible) below the Orbita.

Clinical Remarks

Although the medial bony wall is paper thin (hence the name Lamina papyracea), in the event of a blunt trauma against the Bulbus oculi (e.g. if a tennis ball hits the centre of the eye) the result is usually a fracture of the orbital floor (so-called **blow-out fracture**). As a result, intraorbital structures (M. rectus inferior and M. obliquus inferior) can be trapped in the fracture gap or be translocated into the Sinus maxillaris **(orbital hernia).** Reduced mobility of the eyeball can cause double vision, an enophthalmos and/or the inability of this eye to look upwards. Involvement of the N. infraorbitalis, which runs in the orbital floor, is likely if **sensory dysfunction** in the dermal region of the upper jaw occurs.

Eyelids

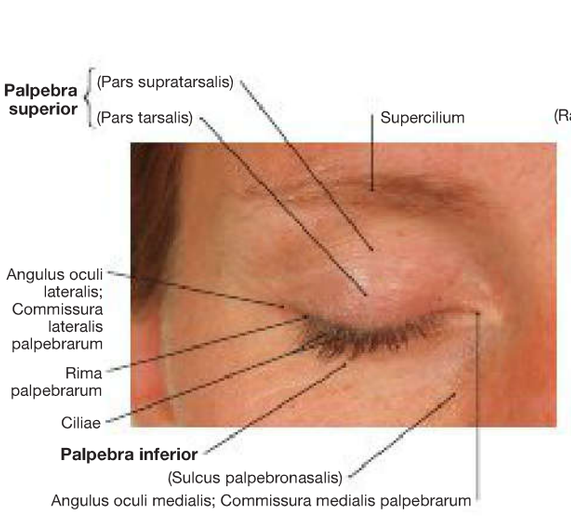

Fig. 9.14 Eye, Oculus, right side, with eyelids closed.
On average, a human eye blinks 20 to 30 times per minute. Each eyelid movement distributes a tear film across the surface of the eye. Blinking involves a consecutive contraction of the M. orbicularis oculi from temporal to nasal and results in a wiping motion in the direction of the medial angle of the eye. Mechanical irritations (e.g. sudden draft, dust particles, flies) activate the blink reflex (also known as corneal reflex) which serves to protect the surface of the eye.

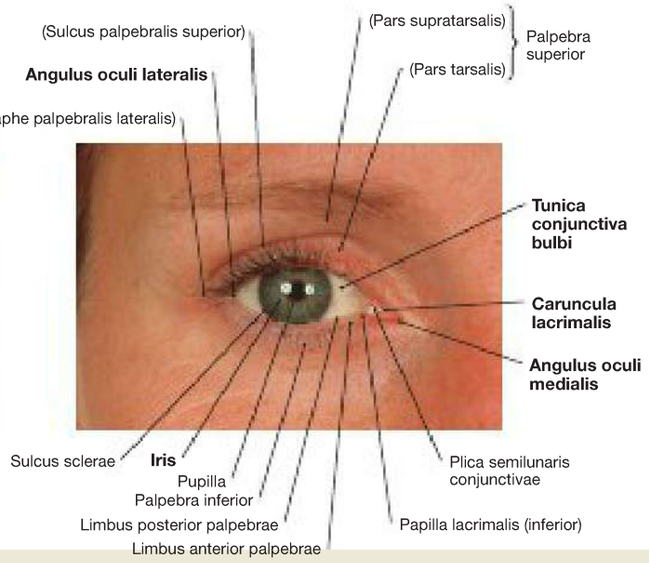

Fig. 9.15 Eye, Oculus, right side, with eyelids open.
In an adult with open eyelids, the width between the upper and lower eyelid ranges between 6 und 10 mm, and the distance between the temporal and medial angle of the eye is 28–30 mm.

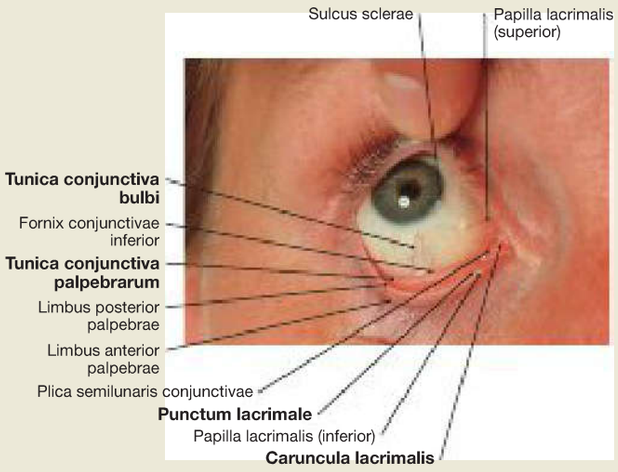

Fig. 9.16 Eye, Oculus, right side, with upper and lower eyelid everted.
With the exception of the cornea, the conjunctiva (a translucent thin mucous layer with blood vessels) covers the part of the Bulbus oculi creating the eye surface, and the side of the eyelids in contact with the eye surface.

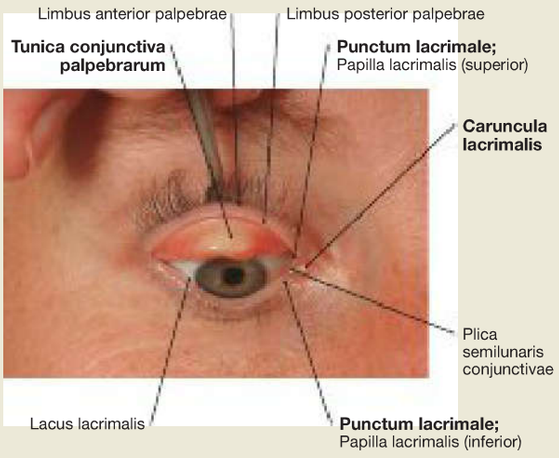

Fig. 9.17 Eye, Oculus, right side, with ectropionised upper eyelid.
The Conjunctiva palpebrae and the Conjunctiva bulbi cover the rear side of the eyelid and the eyeball, respectively. Both conjunctival parts merge at the upper and lower Conjunctiva fornicis. The latter is also referred to as the conjunctival sac. It is possible to apply eyedrop medication here.

Clinical Remarks

A number of diseases involve the **tightening** or the **widening of the eyelids.** Damage to the sympathetic fibres leads to a paralysis of the M. tarsalis superior and thus to a narrowing of the eyelids. Paralysis of the N. oculomotorius causes ptosis of the upper eyelid (which hangs down) due to the paralysis of the elevating muscle of the upper eyelid (M. levator palpebrae superioris). In contrast, a facial nerve palsy due to the paralysis of the muscle that closes the eyelids (M. orbicularis oculi) leads to a widening of the eyelids. An **inflammation** of the conjunctiva (conjunctivitis) is encountered frequently in individuals wearing contact lenses. In patients with anaemia the conjunctiva appears to be off-white and pale since, due to the lack of erythrocytes, the normal blood vessel pattern is missing. This condition can be diagnosed using a simple method. The examining physician pushes the lower eyelid down and examines the conjunctival sac.

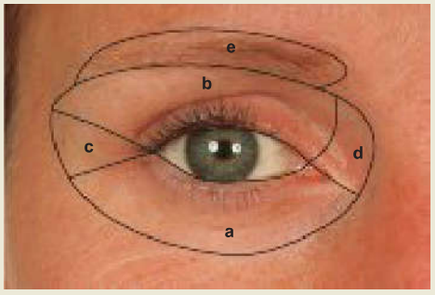

Fig. 9.18 Skin regions of the eye, Occulus, right side.
The eyelid and eye region are central elements of the face. They are a major factor in determining the appearance of a person. Loss of elasticity of the thin eyelid skin in old age (→ Fig. 9.31) and increased life expectancy in the industrialised nations result in more and more people seeking corrective eyelid surgery (blepharoplasty). The latter differs due to the structural peculiarities of different eye regions:
a lower lid region
b normal region
c temporal canthal region
d nasal canthal region
e eyebrow region
Based on: Radlanski, R. J./Wesker, K. H.: Das Gesicht. Bildatlas klinische Anatomie. 2. Aufl. KVM, 2012

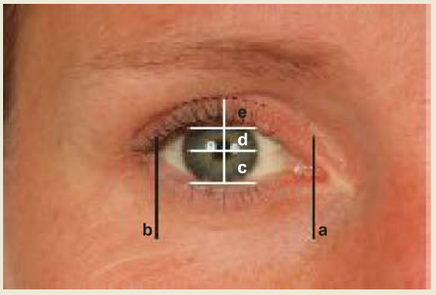

Fig. 9.19 Palpebral fissure width and eyelid width of the eye, Occulus, right side.
The palpebral fissure width is the distance between the two vertical lines through the nasal (**a**) and temporal (**b**) eyelid corners. On average, it is between 28 and 30 mm. The distances of the bottom (**c**) and the top (**e**) edges of the eyelids from the centre of the pupil (**d**) are referred to as 'middle reflex routes'. The results from these two distances gives the palpebral fissure height or 'eyelid opening width', which is normally between 10–12 mm. The distance between the upper eyelid border and the upper eyelid fold is on average 9–12 mm (women) and 7–9 mm (men), but can vary greatly and is often covered by the eyebrows.
Based on: Radlanski, R. J./Wesker, K. H.: Das Gesicht. Bildatlas klinische Anatomie. 2. Aufl. KVM, 2012

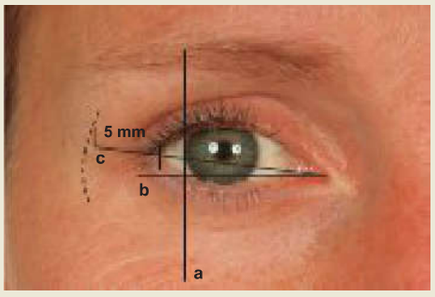

Fig. 9.20 Proportions of the eye, Occulus, right side.
The nasal canthus is slightly lower than the temporal canthus. This is indicated by the angle between a horizontal (**b**) and the connection line (**c**) between the nasal canthus and the temporal canthus. The distance between the temporal canthus and outer boarder of the Orbita is approximately 5 mm. The highest point of the eyebrow curve is normally in the lateral third of the eye and is shown by the vertical line (**a**).
Based on: Radlanski, R. J./Wesker, K. H.: Das Gesicht. Bildatlas klinische Anatomie. 2. Aufl. KVM, 2012

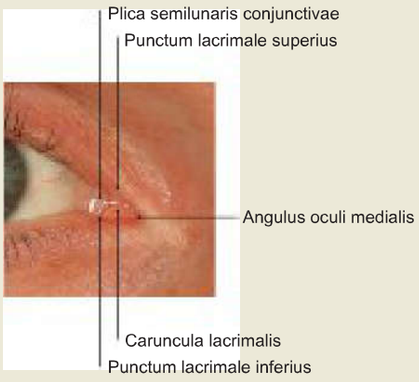

Fig. 9.21 Medial angle of eye, Angulus oculi medialis, right side.
At the nasal canthus, Angulus oculi medialis (Epicanthus medialis, Commissura medialis palpebrarum), there is a small, crescent shaped fold of skin (Plica semilunaris conjunctivae), which is known as the third eyelid. In humans, and in the majority of primates, vestigial remnants of the nictitating membrane (Membrana nicitans) still remain in the corner of the eye (nasal canthus). Animals with an intact nictitating membrane can draw a transparent or translucent third eyelid across the eye for protection and to moisten it while maintaining vision. Furthermore, the lacrimal caruncle (Caruncula lacrimalis), is the small, pink, globular nodule at the inner corner (nasal canthus) of the eye. This could also be regarded as a modified part of the conjunctiva which is sometimes present in adipose tissue. In the covering mucous membrane are goblet cells and intraepithelial mucosal glands. A few millimeters away from the medial canthus, are the openings to the upper (Punctum lacrimale superius) and the lower (Punctum lacrimale inferius) lacrimal points. They are the entrance to the lacrimal drainage system (→ p. 138 ff.). The Punctum lacrimale inferius in adults is approx. 6.5 mm away from the lacrimal point, and the Punctum lacrimale superius is approximately 6 mm away. When the eyelid is closed the two lacrimal points do not come into contact with each other. The opening of the lacrimal point has a slight inclination toward the rear.
Based on: Radlanski, R. J./Wesker, K. H.: Das Gesicht. Bildatlas klinische Anatomie. 2. Aufl. KVM, 2012

Facial Muscles

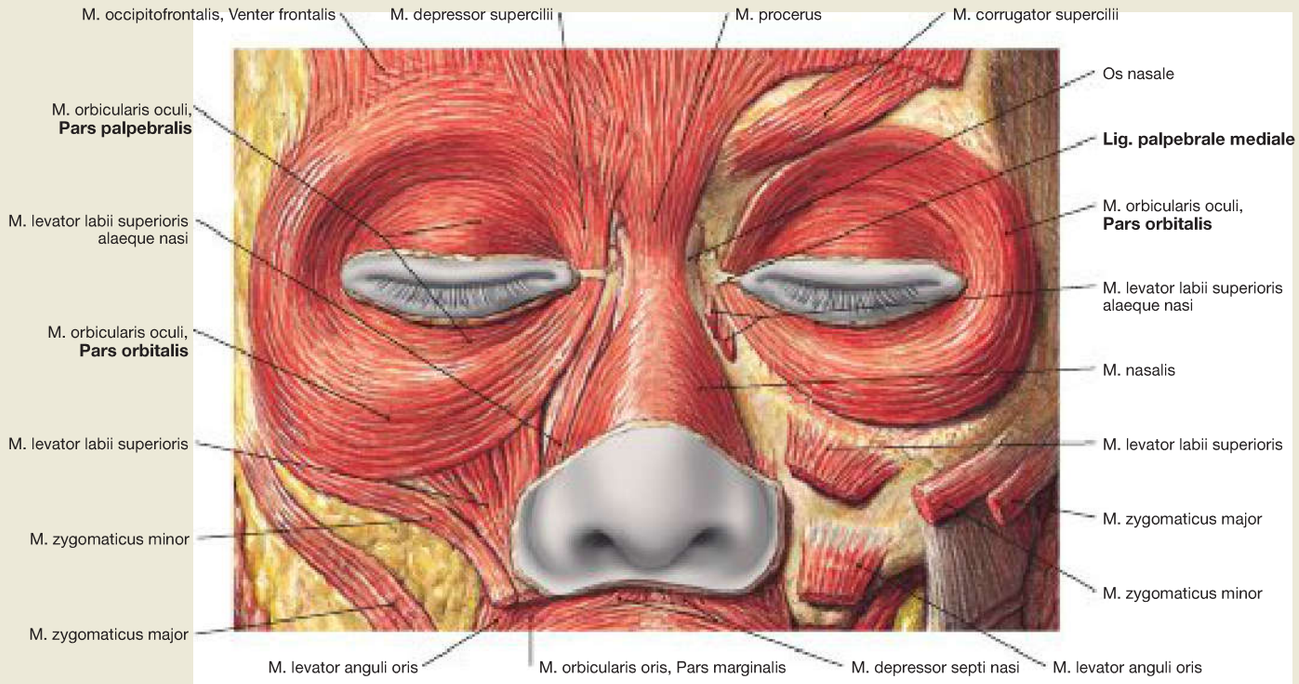

Fig. 9.22 Facial muscles, Mm. faciei, in the orbital region; frontal view.

The orbital opening is surrounded by the Pars orbitalis of the M. orbicularis oculi. The Pars palpebralis of this muscle projects into the eyelids.

→ T 1a, c, d, e

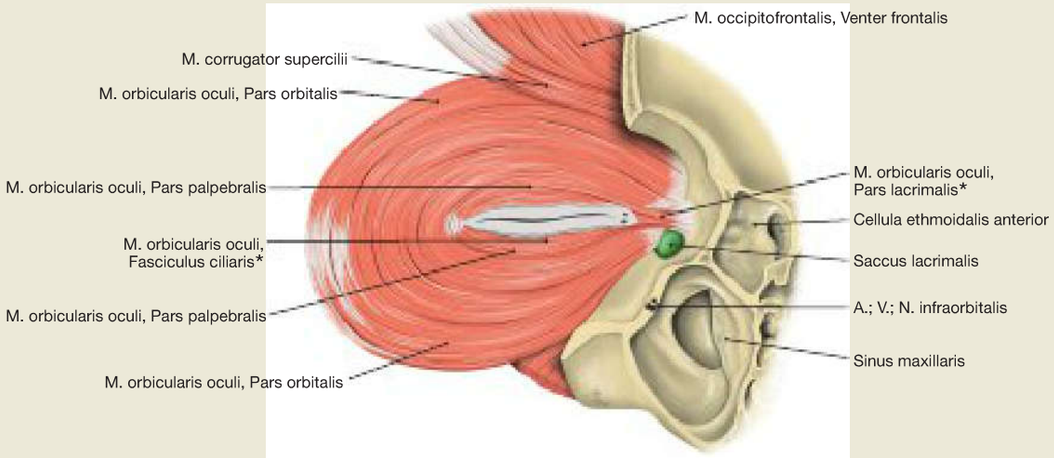

Fig. 9.23 M. orbicularis oculi, left side; posterior view. [L127]
At the nasal canthus the Pars lacrimalis of this muscle (HORNER's muscle) can be seen, which is important for the drainage of the lacrimal fluid (tears).
The M. orbicularis oculi consists of three parts. The **Pars orbitalis** is responsible for the voluntary firm occlusion of the eyelids. A contraction of the **Pars palpebralis** triggers the eyelid movement (blinking), which can be carried out randomly, but usually involuntarily. The **Pars lacrimalis** (HORNER's muscle) is situated around the lacrimal canal and is important for the drainage of lacrimal fluid (tears). When the eye is closed the two **lacrimal points** (Puncta lacrimalia: Punctum lacrimale superius and Punctum lacrimale inferius) are immersed in the lacrimal lake (Lacus lacrimalis) in the nasal third of the medial canthus. It is assumed that the contraction of the Pars lacrimalis results in a suction effect (pressure-suction pump mechanism). The tear fluid is sucked via the lacrimal points through the upper and lower lacrimal canaliculus (Canaliculi lacrimales superior and inferior) into the lacrimal sac (Saccus lacrimalis). The lower lacrimal canaliculus transports most of the tear fluid.
Based on: Tillmann, B. N.: Atlas der Anatomie. 2nd ed. Springer, 2010

→ T 1c

* RIOLAN's muscle
** HORNER's muscle

Clinical Remarks

Injuries to the N. facialis can result in the paralysis of the M. orbicularis oculi with the inability to close the eye **(lagophthalmus).** If the patient closes the eye, the Bulbus oculi rolls upward in the normal manner (the outer eye muscles are intact), so that one only sees the white of the eye (sclera) (**BELL's phenomenon;** → Fig. 12.155). If the eye cannot close, the film of lacrimal fluid can no longer keep the eye moist. The cornea dries out after a short time and takes on a milky appearance. The patient is unable to see with this eye. In the case of a facial paralysis, not being able to close the eyes presents the greatest challenge in the treatment of patients.

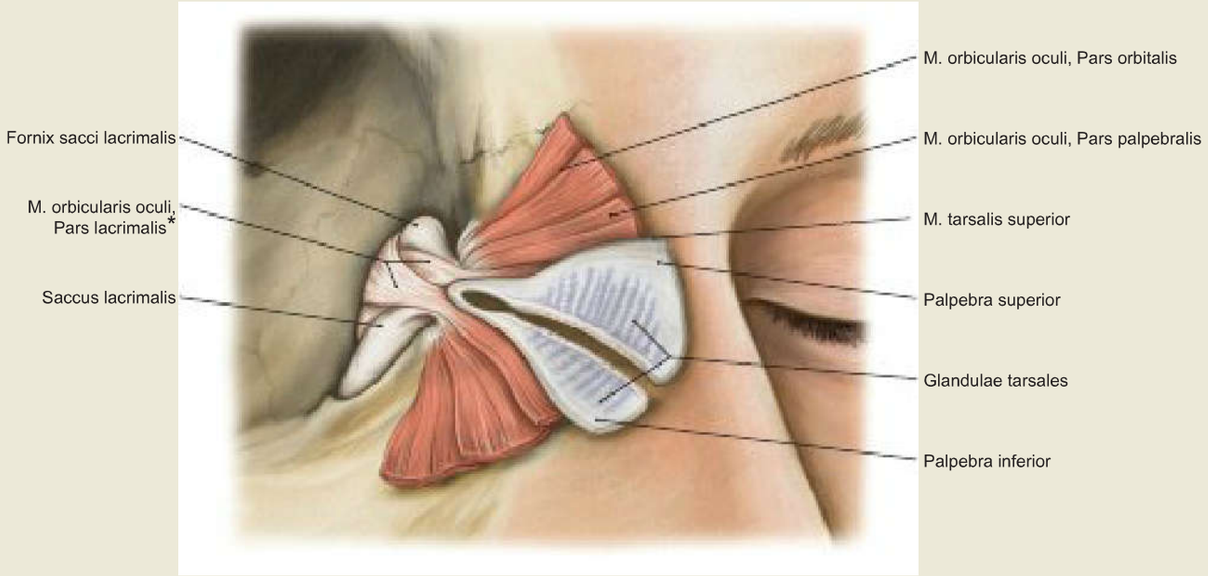

Fig. 9.24 M. orbicularis oculi and eyelids, Palpebrae; detached and folded over to the outside, right side. [L285]
The Pars lacrimalis (HORNER's muscle) of the M. orbicularis oculi encloses the Canaliculi lacrimales (not visible because they are surrounded by the muscle, → Fig. 9.25) from behind and runs to the back of the lacrimal sac (Saccus lacrimalis; → Fig. 9.23 and → Fig. 9.44). The fibres of the Pars lacrimalis in the upper eyelid, Palpebra superior, are interlaced with those of the lower eyelid, Palpebra inferior. The Pars lacrimalis of the M. orbicularis oculi (HORNER's muscle) is essential for the drainage of the lacrimal fluid (tears) through the lacrimal canaliculi. This so-called 'tear pump' function is not yet fully understood. It is thought that the lacrimal muscle fibres surrounding the canaliculi create a 'pressure-suction effect'. The muscle fibres influence the Septum lacrimale of the posterior lacrimal sac wall via small tendons so that their contractions expand the lumen of the lacrimal sac. On the back of the eyelids we can see the shimmer of the Glandulae tarsales (also called MEIBOM's glands).
Based on: Radlanski, R. J./Wesker, K. H.: Das Gesicht. Bildatlas klinische Anatomie. 2. Aufl. KVM, 2012

* HORNER's muscle

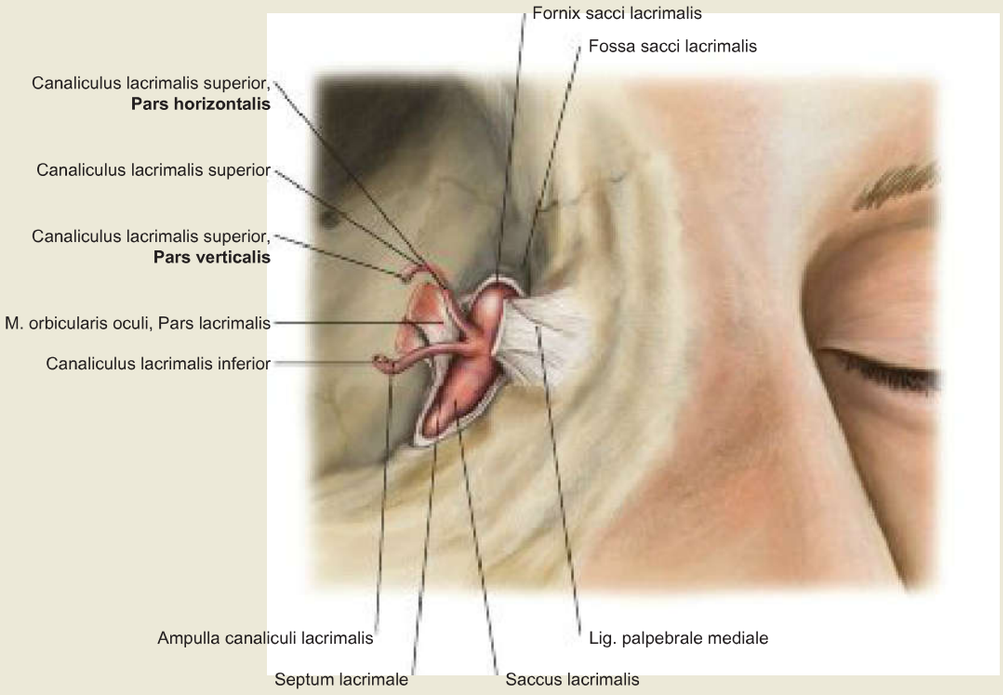

Fig. 9.25 M. orbicularis oculi, Pars lacrimalis, lacrimal canaliculi, Canaliculi lacrimales, lacrimal sac, Saccus lacrimalis, and medial palpebral ligament, Lig. palpebrale mediale, right side. [L285]
In the nasal canthus, one can see the detached Pars lacrimalis of the M. orbicularis oculi (HORNER's muscle), which is important for the drainage of lacrimal fluid (tears). It surrounds the upper (Canaliculus lacrimalis superior) and lower lacrimal canaliculi (Canaliculus lacrimalis inferior) but it has been shortened so that we can see how the Pars lacrimalis runs behind the lacrimal sac (Saccus lacrimalis) and inserts here. At posterior aspect of the lacrimal sac is the Lig. palpebrale mediale, which is attached to the bone shortly before the front margin of the Fossa lacrimalis (→ Fig. 9.44).
Based on: Radlanski, R. J./Wesker, K. H.: Das Gesicht. Bildatlas klinische Anatomie. 2. Aufl. KVM, 2012

Fig. 9.26 Upper eyelid, Palpebra superior; photograph of a microscopic specimen; azan stain; sagittal section, magnified. [R252]
The eyelid can be divided into an outer and inner lamina. The outer lamina is composed of the striated M. orbicularis oculi with its Pars palpebralis. The inner lamina consists of the palpebral conjunctiva (Tunica conjunctiva palpebrarum), the tarsal plate (Tarsus) with the integrated MEIBOM's glands (Glandulae tarsales, modified sebaceous glands) and, close to the rim of the eyelid, muscle fibres of the Pars palpebralis of the M. orbicularis oculi (muscle of RIOLAN, Fasciculi ciliares) radiating into the tarsal plate.

* MEIBOM's glands
** RIOLAN's muscle

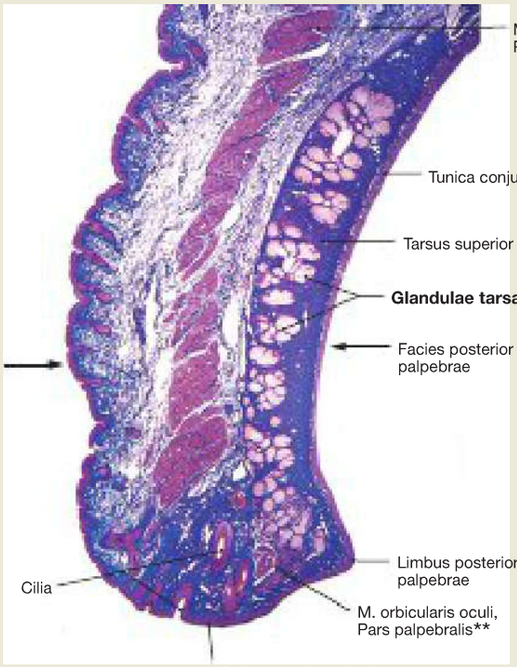

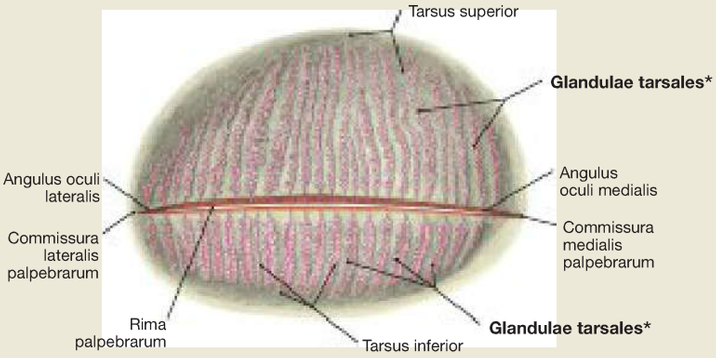

Fig. 9.27 Eyelids, Palpebrae, right side; posterior view; excretory ductules of the Glandulae tarsales in translucent specimen.
Each eyelid contains approximately 25 to 30 individual glands, each with its own excretory ductules into the rim of the eyelid (Rima palpebralis).

*MEIBOM's glands

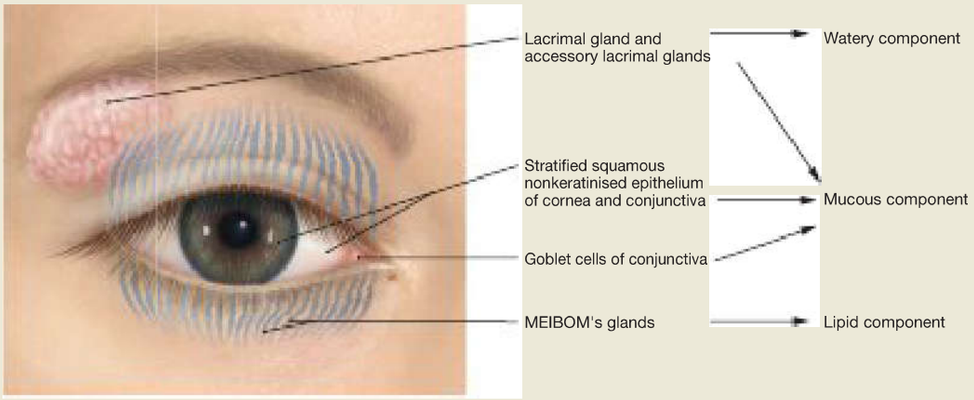

Fig. 9.28 Structures of the eye surface involved in the formation of the three components of the tear film; schematic drawing. [L238]

Fig. 9.29 Stye, chalazion on the upper eyelid, Palpebra superior. [T867]

Fig. 9.30 Inflammation of the rims of the eyelids, seborrhoeic blepharitis. [T867]

Clinical Remarks

A stye (**chalazion,** → Fig. 9.29) is referred to as a granulomatous inflammation, outgoing granulomatous inflammation, usually caused by an occlusion of the excretory duct of the MEIBOM's gland. An unmovable, painless protrusion with a size between a grape seed and a hazelnut can be palpated just below the rim of the eyelid. A **hordeolum** is a painful, mostly purulent inflammation of individual glands of the eyelids (usually caused by bacteria). Inflammations of the rim of the eyelid often result in **blepharitis** (→ Fig. 9.30) with the typical signs of dry eyes, such as a burning sensation, the feeling of having sand in one's eye, a mild form of photophobia and redness of the eyelid rims.

Fig. 9.31 Senile ectropion of the lower eyelid, right side. [T867]

Fig. 9.32 SCHIRMER's tear test is performed on a healthy person. [T912]
After two minutes, the two yellow SCHIRMER's paper strips already display a clear purple coloration. Within five minutes, the paper strips are completely purple.

Clinical Remarks

When the eyelid sags or turns away from the eye, this condition is called an **ectropion.** In most cases, the lower eyelid is affected. The most common form is **senile ectropion** (Ectropium atonicum; → Fig. 9.31) which results in weakening of the muscles in the elderly. This means that the eye cannot be fully closed (lagophthalmos); or that there is a constant slow flow of tears (epiphora) and lacrimal fluid flows over the rims of the eyelids, because the lacrimal points are no longer in contact with the Bulbus oculi. Furthermore, a dry eye is vulnerable for recurrent conjunctivitis or corneal ulceration. The treatment of choice is surgical correction.

When dysfunction of a lacrimal gland is suspected, e.g. in the context of a facial paralysis, a **SCHIRMER's tear test** is carried out. For this purpose, a standardised long filter paper strip is clipped to the conjunctival sac to absorb the tear fluid and become discoloured (→ Fig. 9.32). At a normal rate of tear production, more than two thirds of the paper strip should be coloured within five minutes. A lower amount of the coloured portion is indicative of a reduced production of lacrimal fluid (tears).
Another test for the tear film is the measurement of the **tear film breakup time** (tear scope test), which helps to determine if the tear ducts can maintain a continuous protective film across the entire surface of the eye. A normal breakup time is 20–30 seconds. A breakup time of under 10 seconds is an indication of a dysfunction.

Orbital Opening with Blood Supply and Innervation

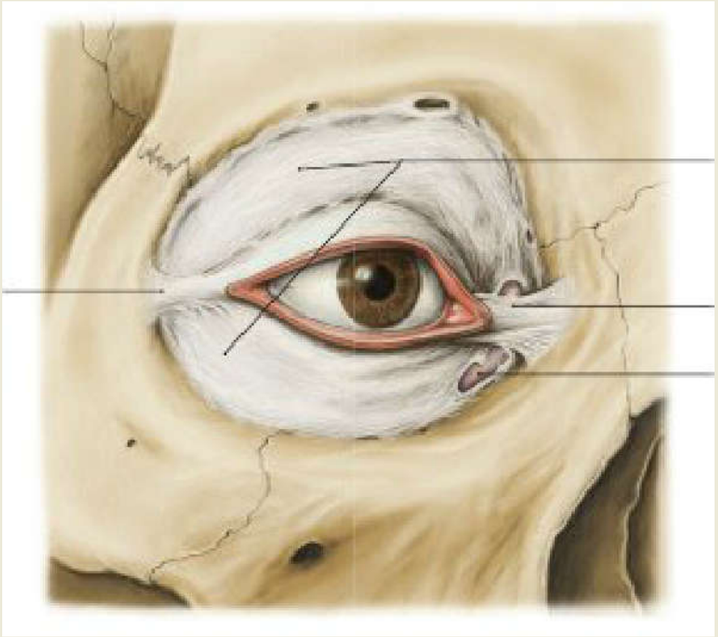

Fig. 9.33 Orbital opening, Aditus orbitalis, right side, with Septum orbitale, eyelid lamina and palpebral ligaments; frontal view on the side. [L285]
The Septum orbitale is a lamina of connective tissue that partially closes the orbital opening (Aditus orbitae). It is attached to the walls of the Orbita on the periorbita (periost). The Septum orbitale extends to the eyelid lamina, Tarsus superior and Tarsus inferior, and is laterally strengthened by the Ligg. palpebralia laterale and mediale.
Based on: Radlanski, R. J./Wesker, K. H.: Das Gesicht. Bildatlas klinische Anatomie. 2. Aufl. KVM, 2012

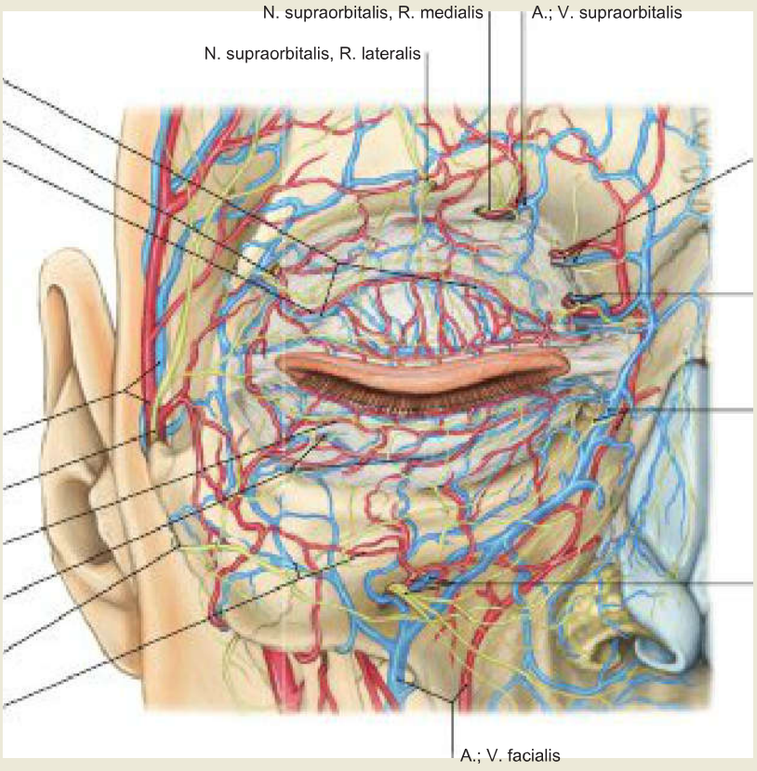

Fig. 9.34 Arteries, veins, and nerves at the orbital opening, Aditus orbitalis, and in the periorbital region, right side; frontal view. [L285]
The Arcus palpebrales superior and inferior create an arterial circle located above the Septum orbitale and surrounding the Orbita. The arterial circle is supplied by numerous arteries derived from the **supply area of the A. carotis interna** (A. supraorbitalis, Aa. palpebrales laterales of the A. lacrimalis, Aa. palpebrales mediales) and the **A. carotis externa** (A. facialis, A. angularis, A. infraorbitalis, A. temporalis superficialis, A. zygomaticoorbitalis. The Nn. supra- and infraorbitalis are branches of the N. ophthalmicus [V/1] and N. maxillaris [V/2], respectively, and exit the Orbita through the identically named foramina (the N. supraorbitalis may exit the Orbita through the Incisura supraorbitalis). The sensory perception of the N. ophthalmicus [V/1] and N. maxillaris [V/2] can be tested at both nerve exit points.
Based on: Radlanski, R. J./Wesker, K. H.: Das Gesicht. Bildatlas klinische Anatomie. 2. Aufl. KVM, 2012

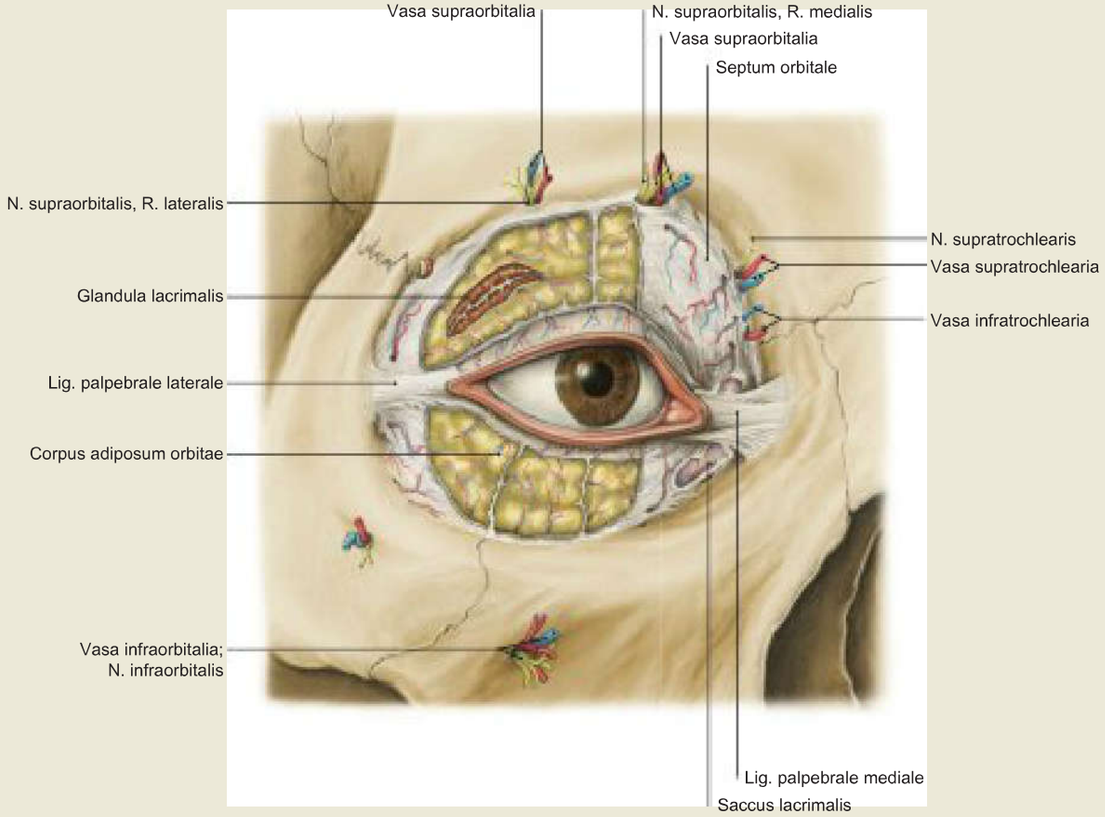

Fig. 9.35 Orbital opening, Aditus orbitalis, Septum orbitale (partially removed), eyelid lamina and eyelid ligaments, right side; frontal view on the side. [L285]
Orbital adipose tissue, which is below the Septum orbitale, is here known as post-septal, preaponeurotic fat (situated before the tendon of the M. levator palpebrae superioris). In the outer upper quadrant is the anterior part of the lacrimal gland (Glandula lacrimalis), directly behind the Septum orbitale.
Based on: Radlanski, R. J./Wesker, K. H.: Das Gesicht. Bildatlas klinische Anatomie. 2. Aufl. KVM, 2012

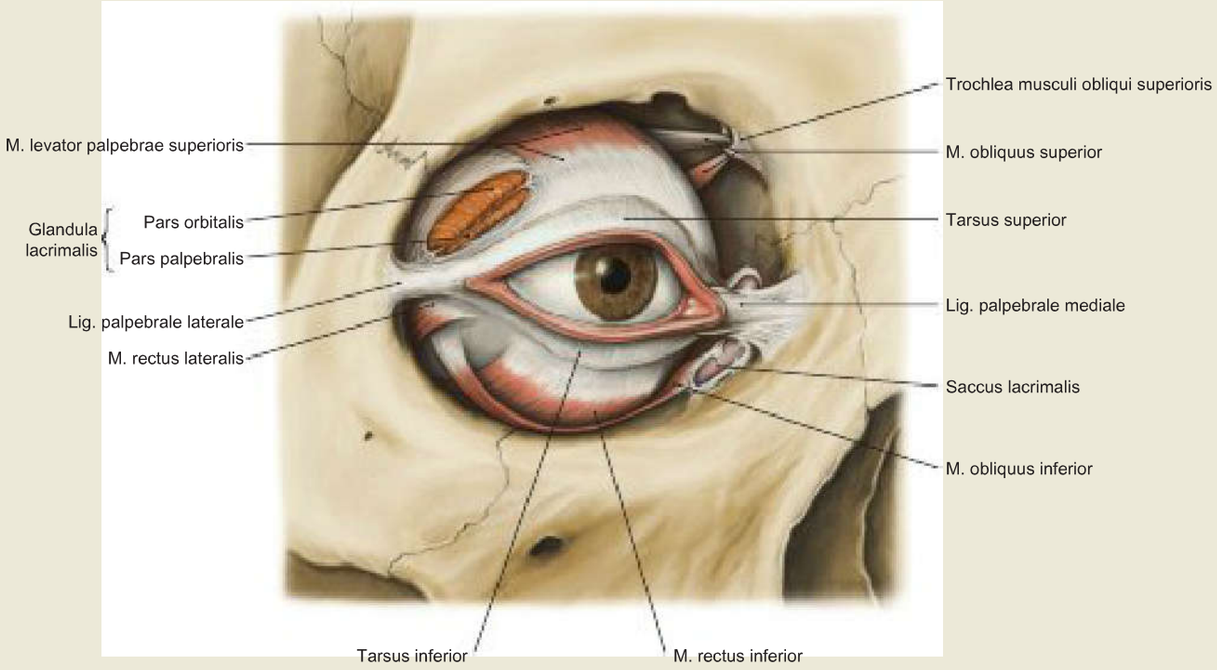

Fig. 9.36 Lacrimal glands, Glandula lacrimalis, in their connective tissue capsules on the eyeball, Bulbus oculi, right side; frontal view on the side. [L285]
After removal of the postseptal fat (Corpus adiposum orbitae), and the Septum orbitale, the lacrimal glands (Glandula lacrimalis) are visible in their connective tissue capsule. The capsule has been removed in the front section. The lacrimal gland is divided by the tendon of the M. levator palpebrae superioris into a larger upper part (Pars orbitalis), and a smaller lower palpebral part (Pars palpebralis).
Based on: Radlanski, R. J./Wesker, K. H.: Das Gesicht. Bildatlas klinische Anatomie. 2. Aufl. KVM, 2012

Lacrimal Gland, Blood Supply and Innervation

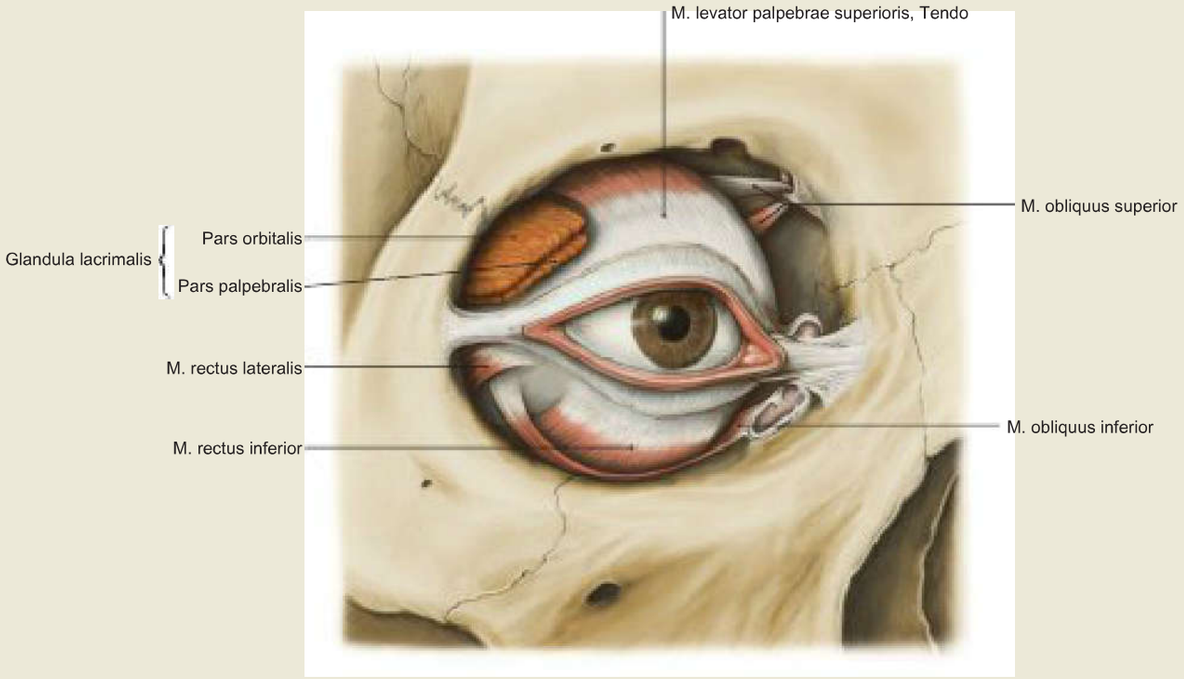

Fig. 9.37 Lacrimal gland, Glandula lacrimalis, on the eyeball, Bulbus oculi, right side; frontal view on the side. [L285]

After removal of the connective tissue capsules of the lacrimal gland (Glandula lacrimalis), you can see their expansion in the upper lateral quadrant on the Bulbus oculi in relation to the course of the tendon of the M. levator palpebrae superioris.
Based on: Radlanski, R. J./Wesker, K. H.: Das Gesicht. Bildatlas klinische Anatomie. 2. Aufl. KVM, 2012

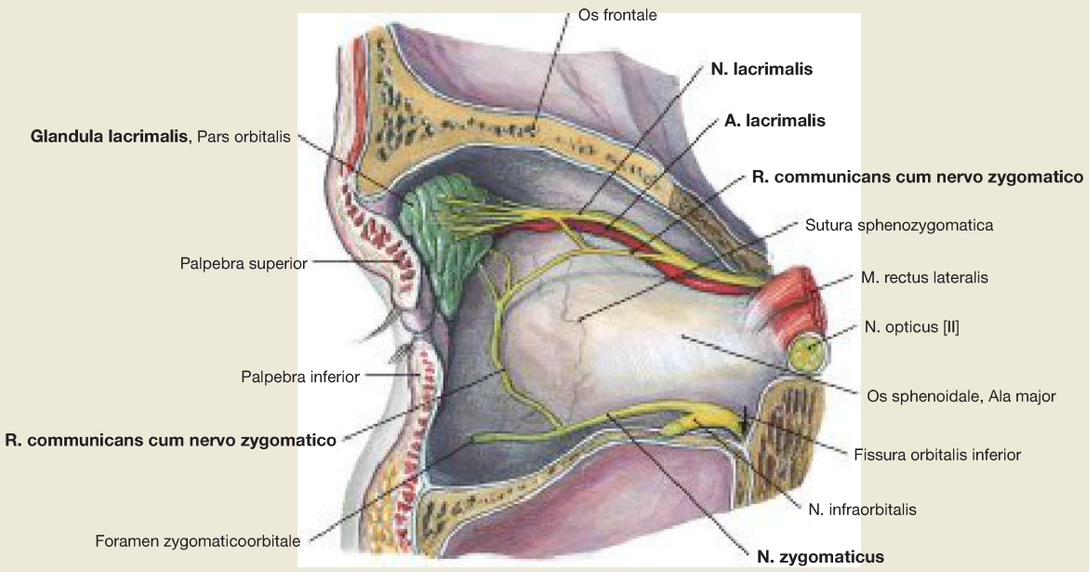

Fig. 9.38 Innervation of the lacrimal gland, Glandula lacrimalis, right side; medial view on the lateral wall of the Orbita.
The lacrimal gland and the N. lacrimalis are both visible as well as the connection between the N. zygomaticus with N. lacrimalis via the R. communicans cum nervo zygomatico.

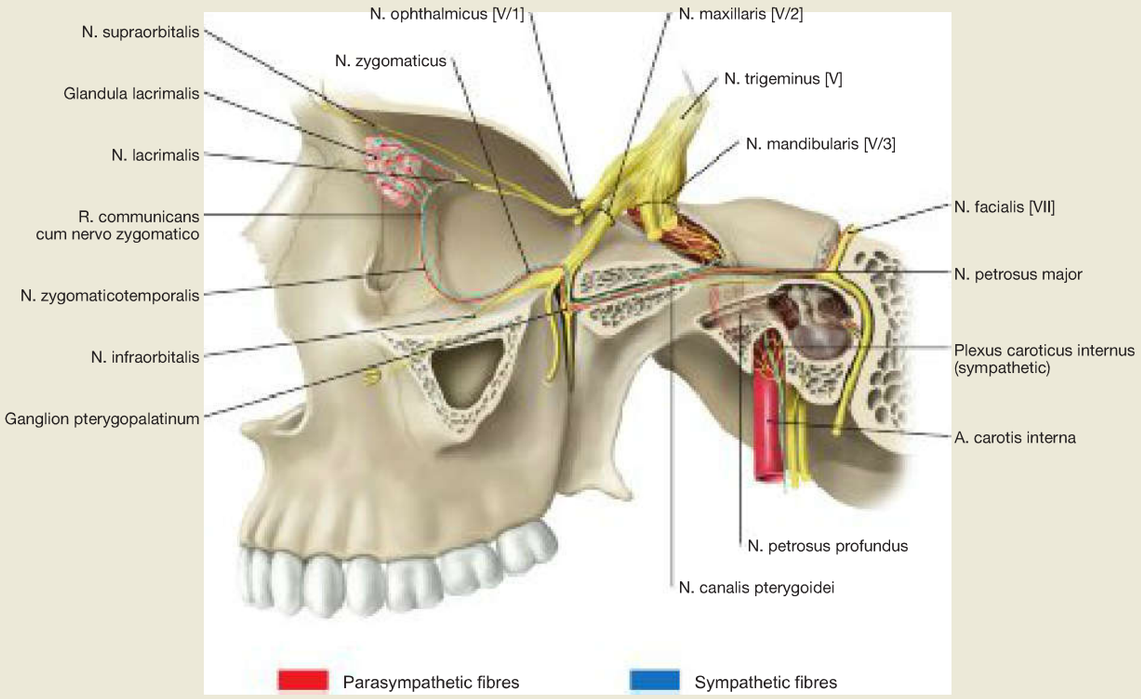

Fig. 9.39 Sympathetic and parasympathetic innervation of the lacrimal gland, Glandula lacrimalis; schematic drawing. [L275]
In the Ganglion cervicale superius, preganglionic sympathetic nerve fibres are synapsed to postganglionic nerve fibres, which reach the lacrimal gland by accompanying the A. carotis interna, A. ophthalmica and A. lacrimalis, or by parting already from the A. carotis interna at the Foramen lacerum and run from here together with the parasympathetic nerve fibres to the lacrimal gland. Preganglionic parasympathetic nerve fibres run via the intermedius portion of the N. facialis without synapsing through the geniculate ganglion (Ganglion geniculi) via the N. petrosus major and N. canalis pterygoidei to the Ganglion pterygopalatinum. Here, the synapsing to postganglionic nerve fibres takes place with the N. zygomaticus via the R. communicans cum nervo zygomatico of the N. lacrimalis and thereby reach the lacrimal gland.

Fig. 9.40 Narrowed eyelids in acute dacryoadenitis (inflammation of the lacrimal gland); right side. [T867]

Clinical Remarks

Inflammation of the lacrimal gland, Glandula lacrimalis (dacryoadenitis; → Fig. 9.40) causes protrusion of the Septum orbitale and a narrowing of the palpebral fissure.

Lacrimal Apparatus

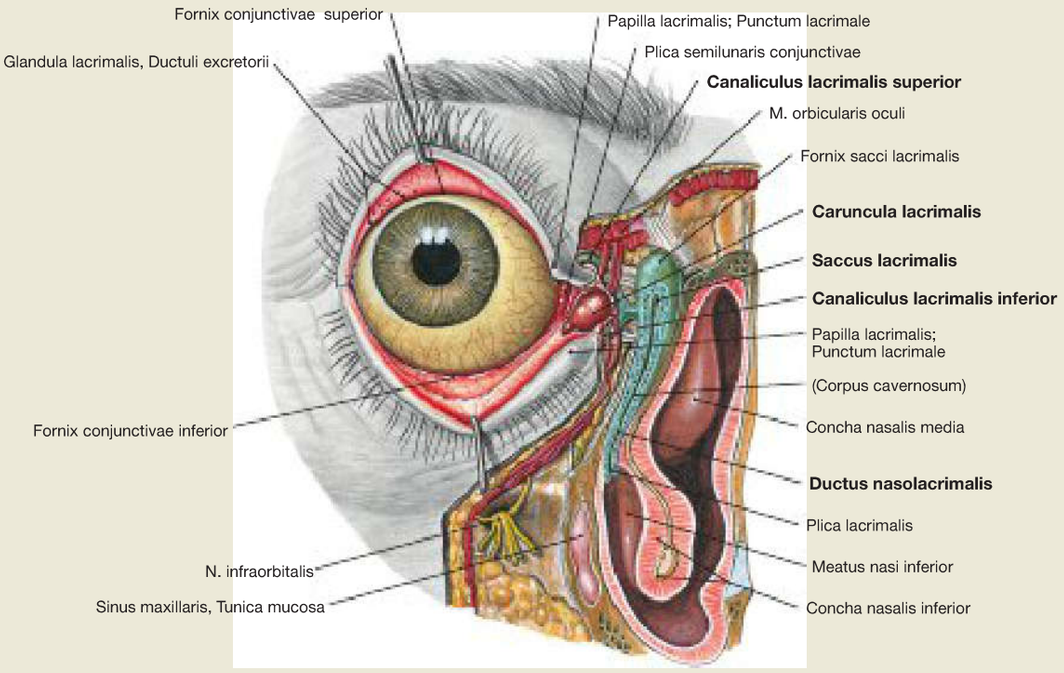

Fig. 9.41 Lacrimal apparatus, Apparatus lacrimalis, right side; frontal view; the eyelids have been pulled away from the Bulbus oculi, thereby making visible into the upper and lower conjunctival sac; the nasolacrimal duct has been opened up to the Meatus nasi inferior.

The draining nasolacrimal duct is composed of the upper and lower lacrimal canaliculi (Canaliculi lacrimales superior and inferior), the lacrimal sac (Saccus lacrimalis) and the nasolacrimal duct (Ductus nasolacrimalis). The Ductus nasolacrimalis exits into the lower nasal meatus (Meatus nasi inferior) beneath the lower nasal concha (Concha nasalis inferior).

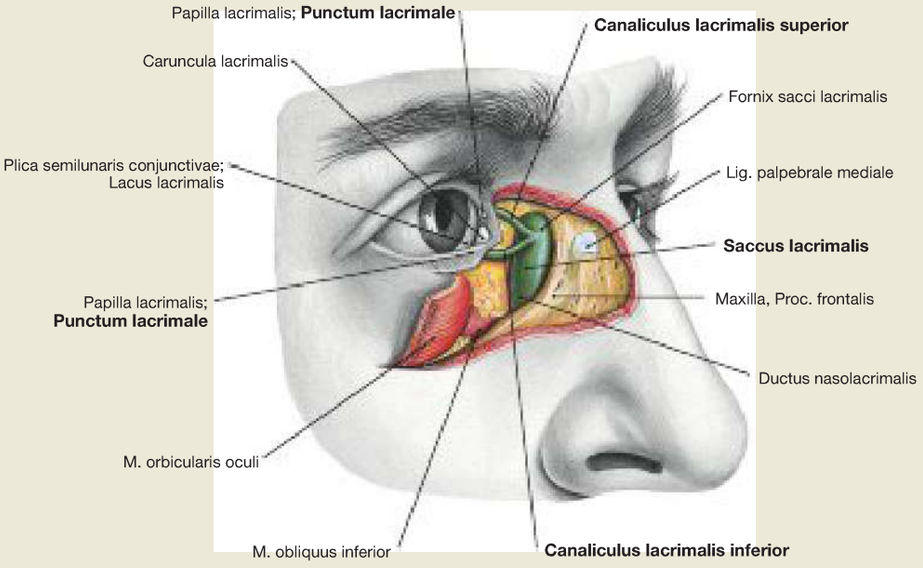

Fig. 9.42 Lacrimal apparatus, Apparatus lacrimalis, right side; frontolateral view; after removal skin, muscles and Septum orbitale in the medial canthus.
The lacrimal sac (Saccus lacrimalis) is located in the Fossa sacci lacrimalis and continues caudally as the Ductus nasolacrimalis in a bony enclosure, bordered at anterior by the maxilla and at the posterior by the Os lacrimale. Each Canaliculus lacrimalis originates as a 0.25 mm (upper) to 0.3 mm (lower) wide, round, oval or slit-shaped Punctum lacrimale which continues as an approximately 2 mm long vertical tube which then bends almost at a right angle and proceeds as a approximately 8 mm horizontal segment. In the majority of cases (65–70%) both canaliculi merge to form a common tube approximately 1–2 mm long that opens into the lacrimal sac about 2–3 mm below the Fornix sacci lacrimalis.

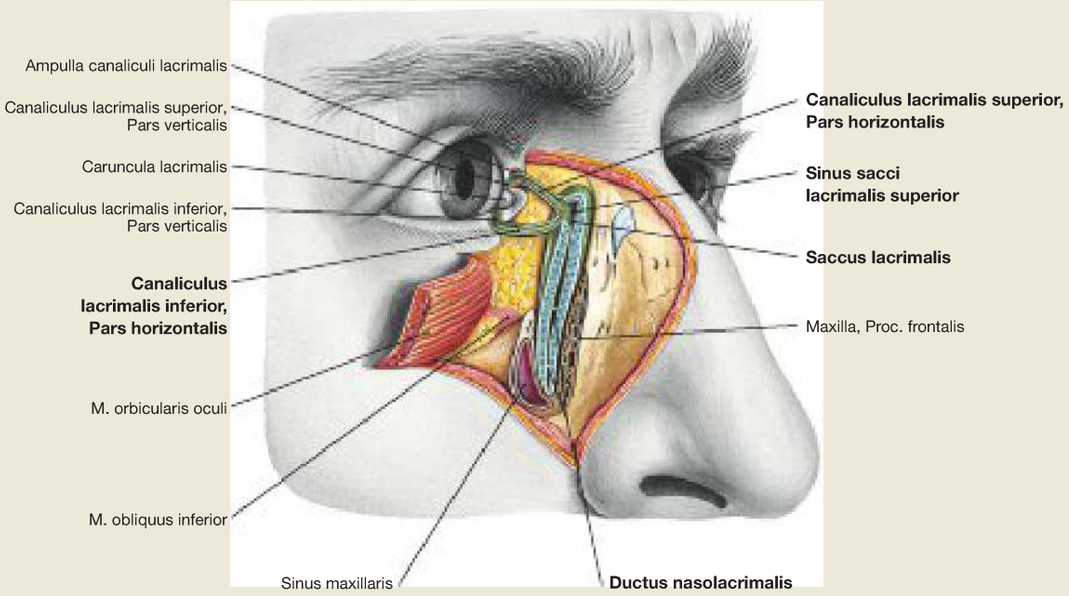

Fig. 9.43 Lacrimal apparatus, Apparatus lacrimalis, right side; horizontal section at the level of the lacrimal sac.
A cavernous body of tissue functionally supporting the transport of the lacrimal fluid surrounds the lumen of the lacrimal sac. Swelling of this cavernous tissue reduces or blocks the transport of lacrimal fluid and the tears (lacrimal fluid) run down the cheek (crying). The blood vessels of the cavernous tissue dilate when a foreign particle enters the conjunctival sac or when experiencing strong emotions (e.g. intense happiness or sadness). The Canaliculus lacrimalis consist of short Pars verticalis and then bends into the Pars horizontalis which is about four times as long, to the bony Fossa sacci lacrimalis in the Orbita in which the lacrimal sac lies. Between the Pars verticalis and Pars horizontalis, each canaliculus of the Ampulla Canaliculi lacrimalis is enlarged. With increasing age, the first right-angled bending point becomes more rounded. The diameter of the Pars horizontalis located close to the rim of the eyelid can easily expand from 0.3–0.6 mm up to 1.5 mm. In more than 95% of cases, the Pars verticalis of the upper and lower Canaliculus lacrimalis merge together to form one duct. After passing through the Septum lacrimale (covered from the Fossa sacci lacrimalis; → Fig. 9.44) the duct penetrates the wall of the lacrimal sac approximately 2.5–4 mm below the Fundus sacci lacrimalis and merges in the lumen of the lacrimal sac (Sinus sacci lacrimalis superior, MAIER's sinus).

Dimensions of the Draining Lacrimal Ducts

Structure			Dimensions
Punctum lacrimale	superius		Ø 0.25 mm
	inferius		Ø 0.3 mm
Canaliculus lacrimalis	superior	Pars verticalis	Length: 1.8–2.25 mm, ø 0.08–0.1 mm
		Pars horizontalis	Length: 7–9 mm, always approx. 0.5 mm shorter than the Canaliculus inferior, ø 0.3–0.6 mm
	inferior	Pars verticalis	Length: 1.8–2.25 mm, ø 0.08–0.1 mm
		Pars horizontalis	Length: 7–9 mm, always approx. 0.5 mm longer than the Canaliculus superior, ø 0.3–0.6 mm
Saccus lacrimalis	Ø vertically		12 mm
	Ø sagittally		5–6 mm
	Ø transversely		4–5 mm
Ductus nasolacrimalis	total		Length: 12.4 mm
	bony cavity		Length: 10 mm
			Ø 4.6 mm

Lacrimal Apparatus

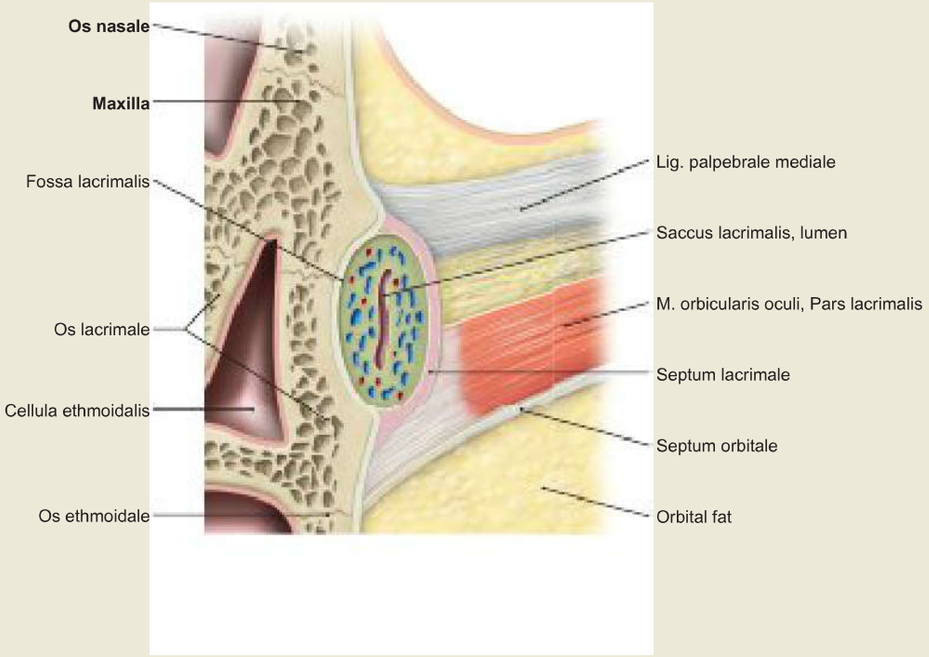

Fig. 9.44 Lacrimal apparatus, Apparatus lacrimalis, right side; horizontal section at the level of the lacrimal sac, Saccus lacrimalis. [L275] The Lig. palpebrale mediale inserts on the anterior margin of the Fossa lacrimalis. The Pars lacrimalis of the M. orbicularis oculi passes laterally of the Septum orbitale and at the posterior aspect of the lacrimal sac. One should also note the close proximity to the ethmoidal cells (Cellulae ethmoidales).

Fig. 9.45 Inflammation of the lacrimal sac (dacryocystitis) in an infant, left side. [T867]

Clinical Remarks

The most common diseases of the lacrimal drainage system are inflammation (**dacryocystitis;** → Fig. 9.45), narrowing **(dacryostenosis)** and stone formation **(dakryolithiasis).** This mainly leads to tear overflow **(epiphora).** Dacryostenosis can also be hereditary. In most cases a congenital stenosis is based on a persistent membrane of HASNER, a thin connective tissue membrane at the transition to the lower nasal passage, which ruptures shortly after birth in most cases. However, if persistent, it must be pierced by the doctor.

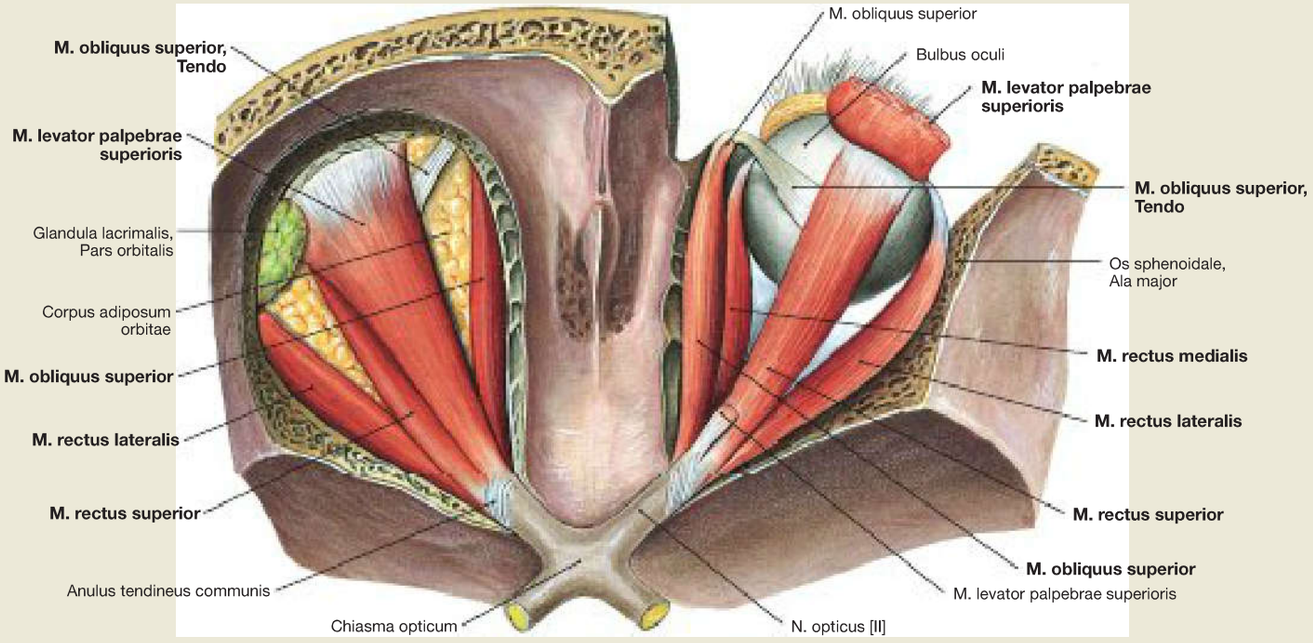

Fig. 9.46 Extraocular muscles, Mm. bulbi; superior view; after removal of the roof of the Orbita on both sides and removal of most of the M. levator palpebrae superioris as well as the orbital fat body on the right side.

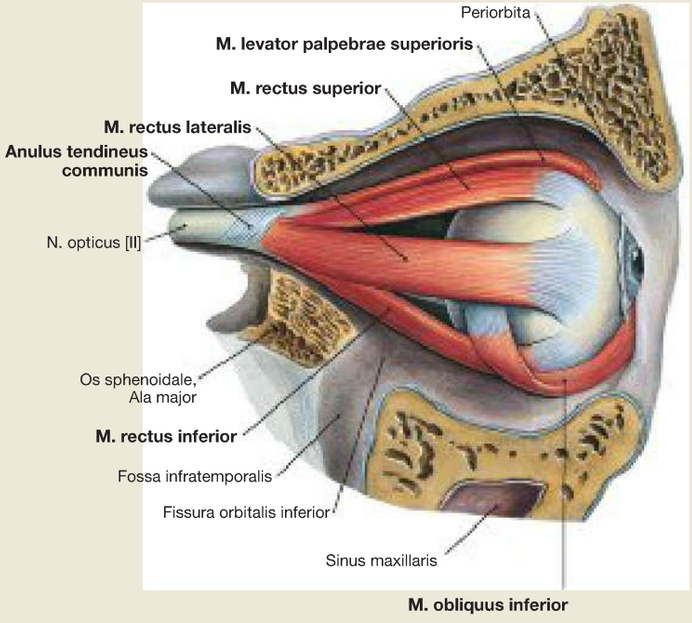

Fig. 9.47 Extraocular muscles, Mm. bulbi, right side; lateral view; after removal of the lateral wall of the Orbita.
The Bulbus oculi is controlled by six extraocular muscles (four rectus muscles: Mm. recti superior, inferior, medialis and lateralis; two oblique muscles: Mm. obliqui superior and inferior). With the exception of the M. obliquus inferior (origin at the Facies orbitalis of the lateral maxilla of the Incisura lacrimalis in the anterior medial region of the Orbita) and the M. obliquus superior (origin at the Corpus ossis sphenoidalis medial of the Anulus tendineus communis and the dural sheath of the N. opticus), all other extraocular muscles originate from the **tendinous anulus of ZINN (Anulus tendineus communis).**
All six muscles insert at the sclera. The four extra ocular rectus muscles insert anterior to the equator of the Bulbus oculi, while the two oblique muscles insert posterior to the equator. A tendinous pulley-like structure (Trochlea), which attaches to the anterior upper area of the Os frontale and acts as a hypomochlion for the M. obliquus superior, redirects this muscle backwards to its insertion area at the top of the eyeball posterior to its equator. The tendinous anulus of ZINN is also the origin of the elevating muscle of the upper eyelid (M. levator palpebrae superioris) which projects into the upper eyelid (Palpebra superior).

Clinical Remarks

A **paralysis of the M. levator palpebrae superioris** (resulting from damage to the N. oculomotorius [III]) leads to **ptosis** (drooping of the eyelid). The patient does not usually suffer from double vision (diplopia), since the affected eyelid is above the pupil. Raising the drooping eyelid, however, causes double vision, because the Mm. recti superior, inferior and medialis are also paralysed. Even in the case of damage to the N. abducens [VI] and the N. trochlearis [IV] there will be a paralytic squint, resulting in diplopia.

Extraocular Muscles

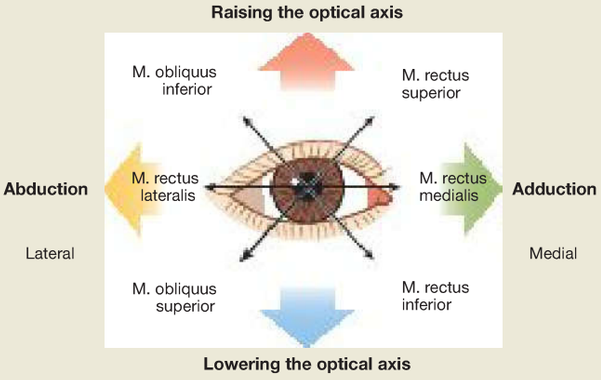

Fig. 9.48 Function of the extraocular muscles, Mm. bulbi. [L126]
The clinical evaluation of ocular motility is carried out by **testing the nine main viewing directions** (straight ahead, right, left, top, below, top left, top right, bottom left, bottom right). The muscles activated for each direction are shown for both eyes. The synchronised movement of both eyeballs is a very complex issue since the innervated muscle of the different cranial nerves (Nn. oculomotorius, trochlearis and abducens) must be coordinated synergistically. The extraocular muscles are very finely innervated and their fine structure distinguish them from the normal striated muscles.

Muscle	Function	Innervation
right eye lateral medial M. rectus superior	Elevation of the optical axis Adduction and medial rotation of the eyeball	N. oculomotorius [III], R. superior
M. rectus inferior	Depression of the optical axis Adduction and lateral rotation of the eyeball	N. oculomotorius [III], R. inferior
M. rectus lateralis	Abduction of the eyeball	N. abducens [VI]
M. rectus medialis	Adduction of the eyeball	N. oculomotorius [III], R. inferior
M. obliquus inferior	Elevation of the optical axis Abduction and external rotation of the eyeball	N. oculomotorius [III], R. inferior
M. obliquus superior	Depression of the optical axis Abduction and medial rotation of the eyeball	N. trochlearis [IV]

Fig. 9.49 Function and innervation of the extraocular muscles entering at the Bulbus oculi. [L285]
The respective muscle is shown in dark red.

Clinical Remarks

In the case of **N. oculomotorius palsy**, with the exception of the M. rectus lateralis (N. abducens) and the M. obliquus superior (N. trochlearis) all extraocular muscles cease to function. Because of the two unaffected muscles predominate, the gaze of the eye is directed downwards. Since the M. levator palpebrae superioris has failed, the patient has a ptosis. The patient cannot see with the affected eye and therefore does not experience double vision. Only when the drooping eyelid is manually raised, the patient complains of diplopia.

Extraocular Muscles

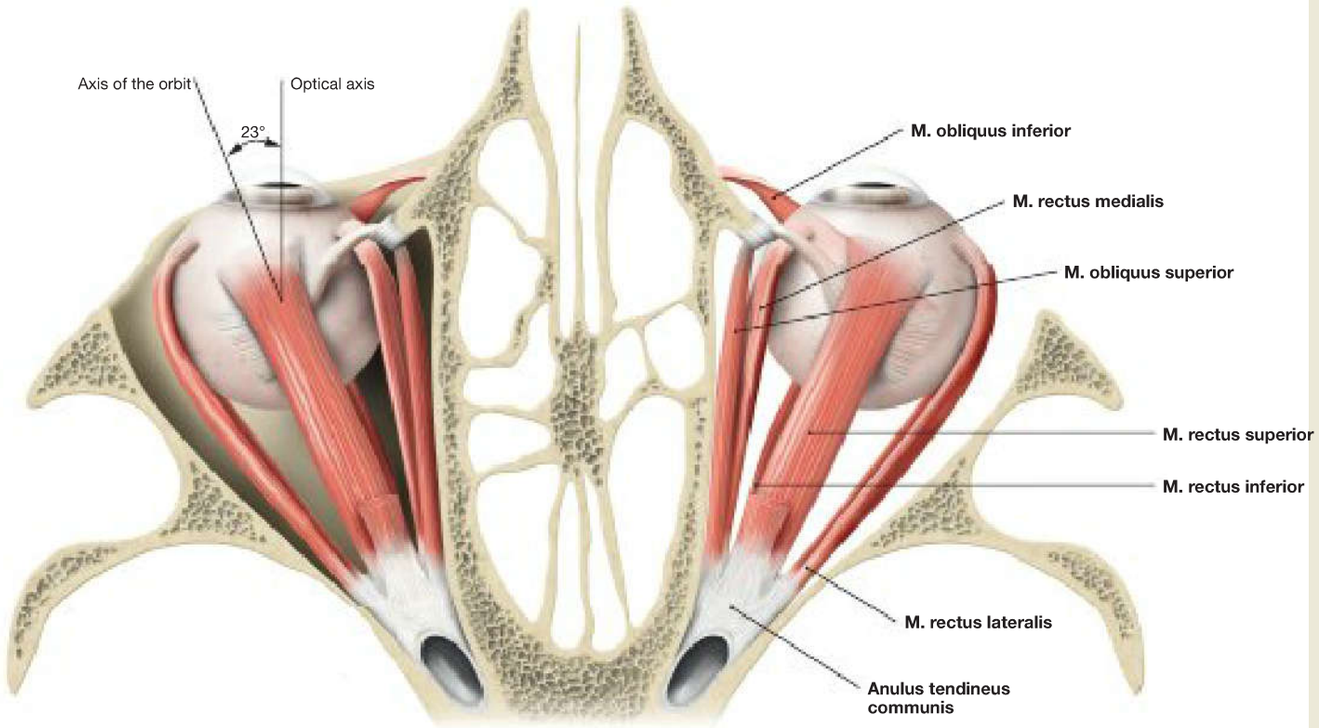

Fig. 9.50 Extraocular muscles, Mm. bulbi; superior view. [L275] Shown are the tendinous anulus of ZINN (Anulus tendineus communis) and the insertion sites of the muscles at the Bulbus oculi.

The optical axis and the axis of the Orbita differ by an angle of 23°. This is the reason why the Fovea centralis (the area of most acute vision) is located lateral to the Papilla nervi optici (blind spot).

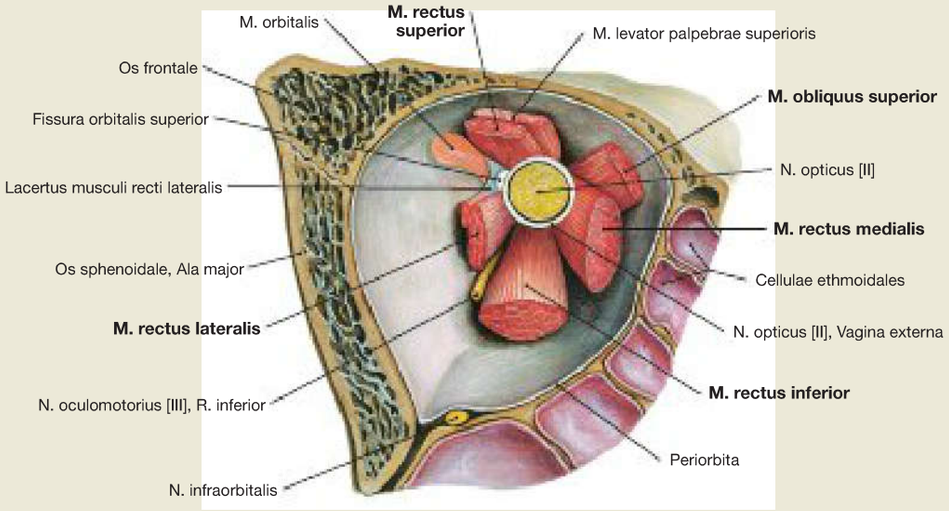

Fig. 9.51 Extraocular muscles, Mm. bulbi, right side; frontal view onto the posterior wall of the Orbita. The periorbital space near the Fissura orbitalis superior contains smooth muscle fibres innervated by the Sympathicus; collectively, these form the M. orbitalis.

Clinical Remarks

Damage to the N. trochlearis [IV] can cause **palsy of the trochlear nerve.** Paralysis of the M. obliquus superior causes the visual axis to point medially (nasal) and upward because the normal abduction and downward movement of the eyeball by the superior oblique muscle is absent. **Abducens nerve palsies** are the most frequent palsies of the extraocular muscles (in part, because the N. abducens [VI] [→ Fig. 9.52] runs through the centre of the Sinus cavernosus and can be damaged more easily here than in the peripheral zone of the sinus where the N. oculomotorius [III] and N. trochlearis [IV] are located). Paralysis of the M. rectus lateralis shifts the visual axis medially (nasally).

Muscles of the Eye

Extraocular Muscles, Neurovascular Pathways

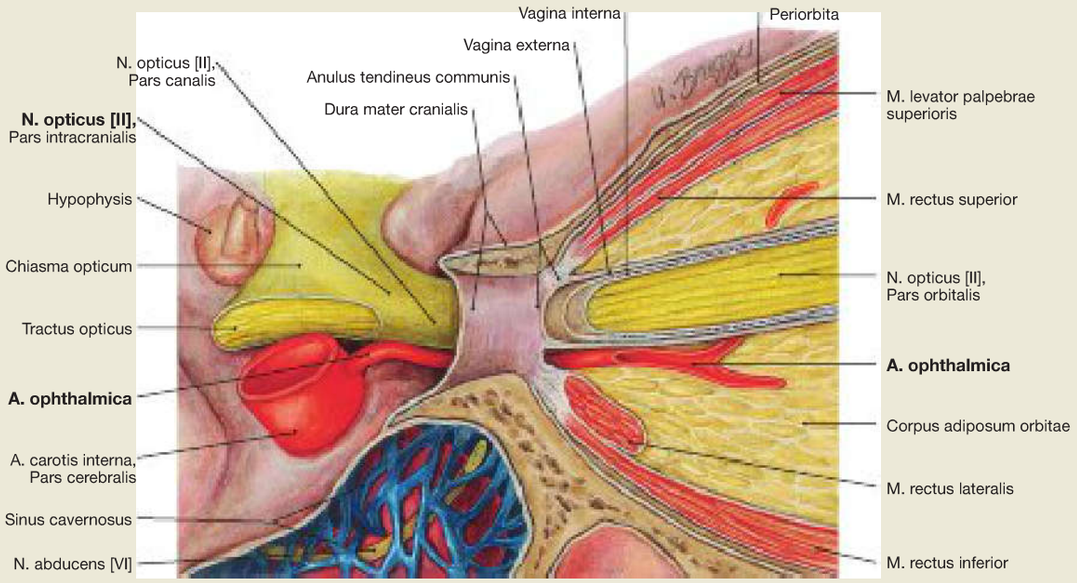

Fig. 9.52 Optic nerve, N. opticus [II], right side; lateral view; after the opening of the Canalis opticus.

The N. opticus [II] runs together with the A. ophthalmica (branch of the A. carotis interna) through the Canalis opticus and the Anulus tendineus communis (tendinous anulus of ZINN) into the Orbita.

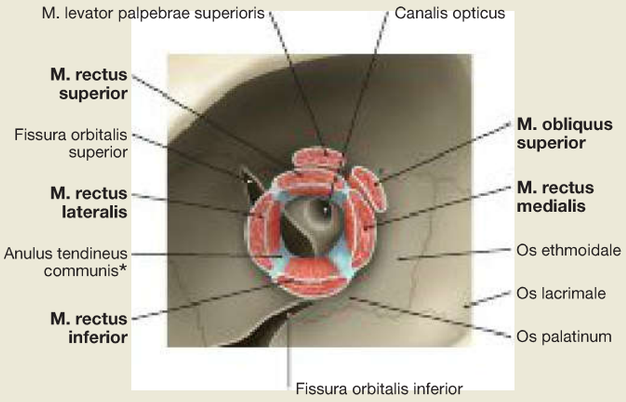

Fig. 9.53 Musclar origins at the Anulus tendineus communis (tendinous anulus of ZINN), right side; frontal view. [L275]
The Mm. rectus superior, rectus medialis, rectus inferior and rectus lateralis originate from the Anulus tendineus communis. The neurovascular bundle passes through the anulus are not shown in this illustration (→ Fig. 9.54). The M. levator palpebrae superioris, which is shown originates from the Ala minor ossis sphenoidalis in the tip of the Orbita and outside of the Anulus tendineus communis. The M. obliquus superior comes from the Corpus ossis sphenoidalis, medial of the Anulus tendineus communis, at the dural sheath. Connective tissue fibres of its fascia radiate into the Anulus tendineus communis.

* tendinous anulus of ZINN

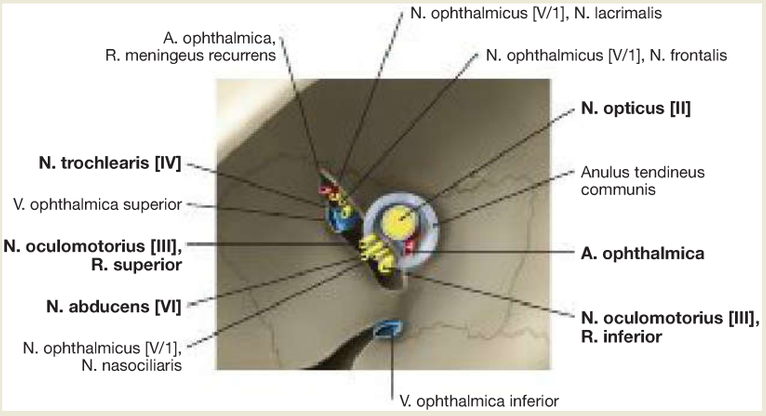

Fig. 9.54 Neurovascular pathways passing through the Canalis opticus and the Fissura orbitalis superior, right side; frontal view. [L275]
The N. oculomotorius [III], N. nasociliaris, N. abducens [VI] and Radix sympathica ganglii ciliaris run via the Fissura orbitalis superior and through the Anulus tendineus communis (tendinous Anulus of ZINN). The V. ophthalmica superior, the N. lacrimalis, the N. frontalis and the N. trochlearis [IV], also run via the Fissura orbitalis superior in the Orbita. But these neurovascular structures run outside of the Anulus tendineus communis (tendinous anulus of ZINN). Not shown are V. ophthalmica inferior, A. infraorbitalis, N. infraorbitalis and N. zygomaticus which enter the Orbita through the Fissura orbitalis inferior. Within the N. opticus [II] courses centrally the A. centralis retinae as the first branch of the A. ophthalmica.

Clinical Remarks

The **orbital apex syndrome** may cause incomplete or complete paralysis of one or more extraocular muscles (ophthalmoplegia). The causes are usually chronic inflammation or tumours in the area of the tip of the Orbita. An **embolic occlusion of the A. centralis retinae** is a frequent vascular cause of acute blindness.

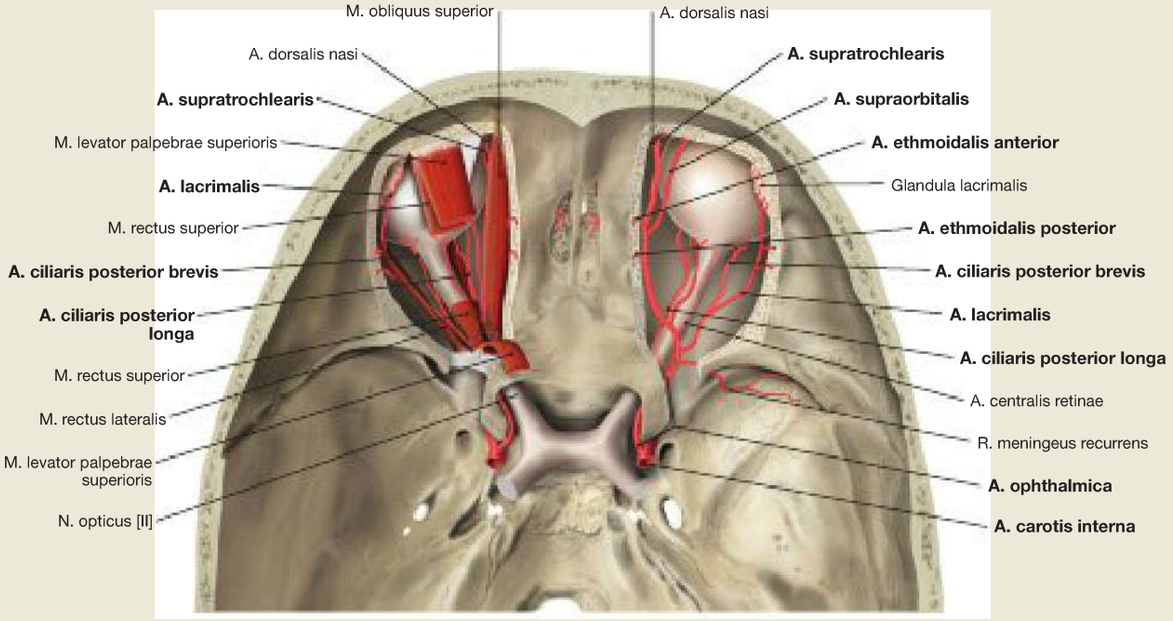

Fig. 9.55 Arteries of the eye, Oculus, and the eye socket, Orbita; superior view on the opened orbits; left side: orbital contents with extraocular muscles, right side: without extraocular muscles. [L280]
The A. ophthalmica is the main artery of the Orbita. It originates from the Pars cerebralis of the A. carotis interna and normally runs below the N. opticus [II] through the Canalis opticus into the Orbita. Here, the artery divides into many branches which supply the Bulbus oculi and the structures of the Orbita with blood. Anastomoses exist via a R. orbitalis to the A. meningea media, via the Aa. ethmoidales anterior and posterior to the blood vessels in the nose and via blood vessels penetrating the Septum orbitale or the bone to the facial arteries (Aa. supraorbitalis, supratrochlearis, palpebralis medialis and lateralis, dorsalis nasi).

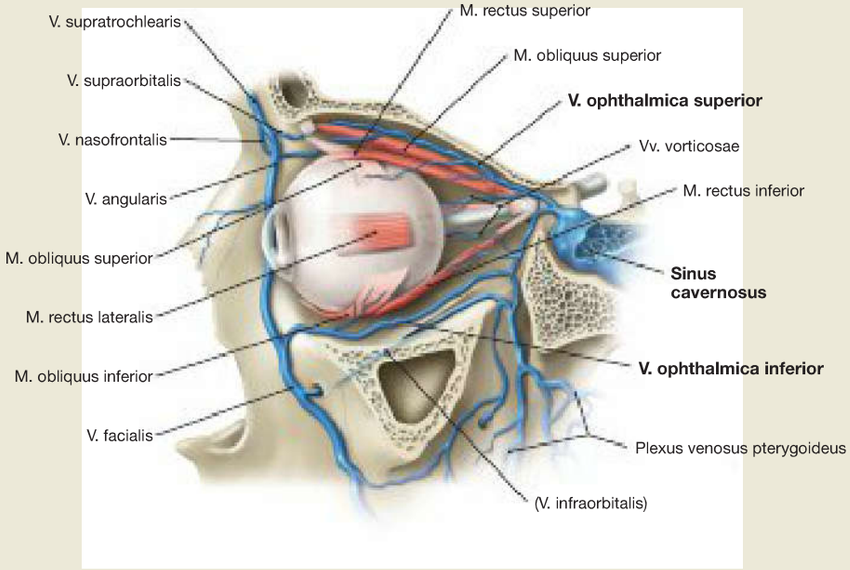

Fig. 9.56 Veins of the eye, Oculus, and the eye socket, Orbita, right side; lateral view into the Orbita; after removal of the lateral wall of the Orbita. [L275]
The venous drainage occurs via the Vv. ophthalmicae superior and inferior. The latter is usually smaller than the A. ophthalmica superior. Venous anastomoses are present on the superficial and deep facial regions (Plexus pterygoideus) and the Sinus cavernosus.

Clinical Remarks

Via the V. angularis running in the medial canthus and the intraorbitally running V. ophthalmica, there is a connection between the face (V. facialis) and the Sinus cavernosus. In the case of infections of the outer face regions (e.g. after squeezing out a pimple on the cheek) there could be a **spread of germs** into the Sinus cavernosus with a subsequent **thrombosis** of the Sinus cavernosus (→ p. 312). At the first sign of an infection, the A. angularis must be treated in order to prevent a sinus thrombosis.

Arteries and Nerves of the Eye Socket

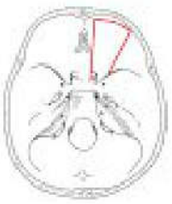

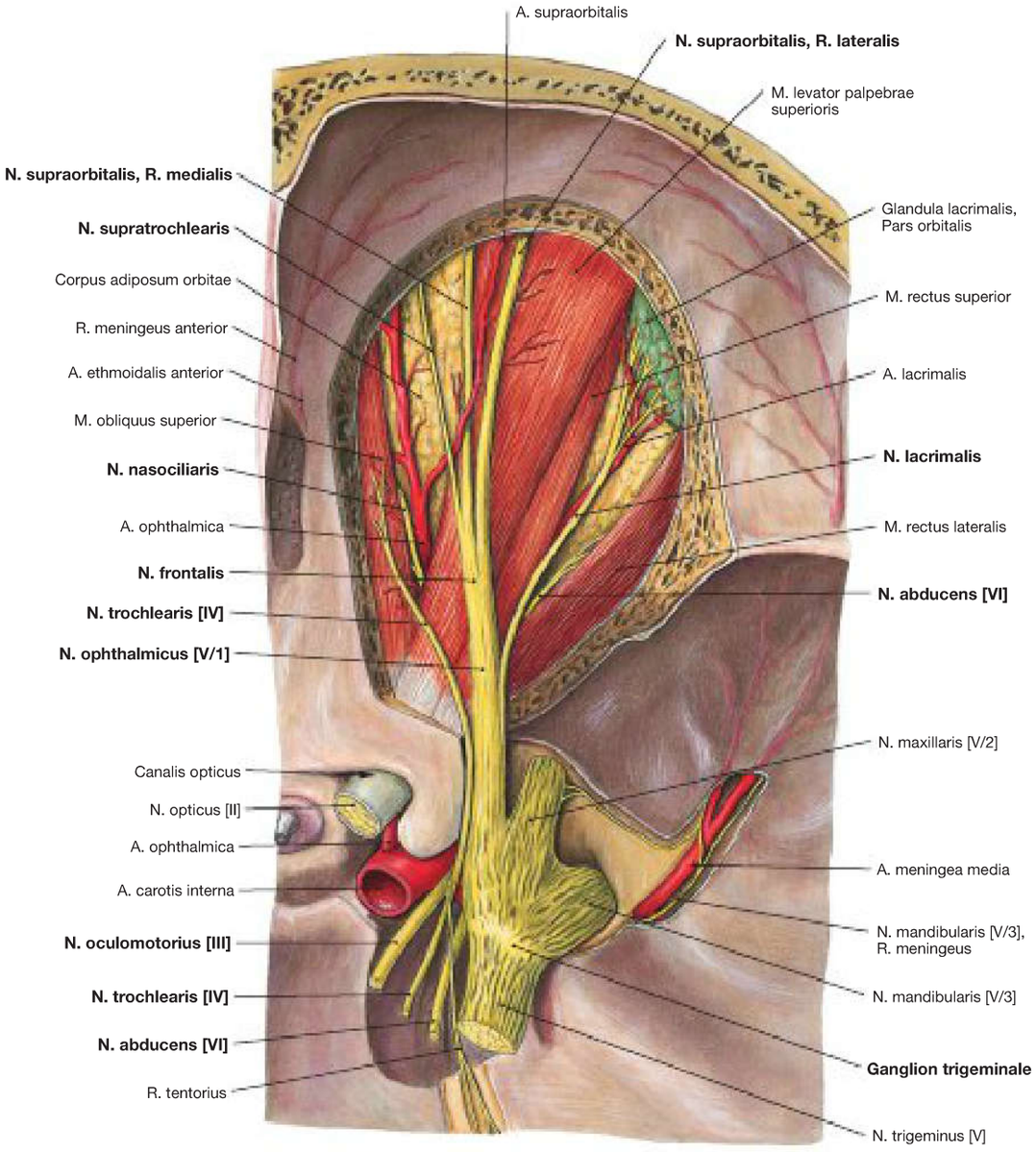

Fig. 9.57 Arteries and nerves of the eye socket, Orbita, right side; superior view on the opened orbita **(upper level of the orbita);** illustration of the Ganglion trigeminale (Ganglion semilunare, Ganglion GASSERI); bony roof of the Orbita, Periorbita and Corpus adiposum orbitae partially removed.

Depicted are the **course of the N. ophthalmicus** [V/1], superior view of the opened Fissura orbitalis superior and its further branching into the Nn. lacrimalis and frontalis (including consecutive branching) as well as the running more deeply N. nasociliaris. It is also possible to see the gracile N. trochlearis [IV], supplying the motor innervation of the M. obliquus superior, and the more deeply located N. abducens [VI] which innervates the M. rectus lateralis.

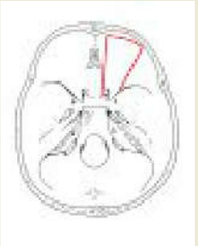

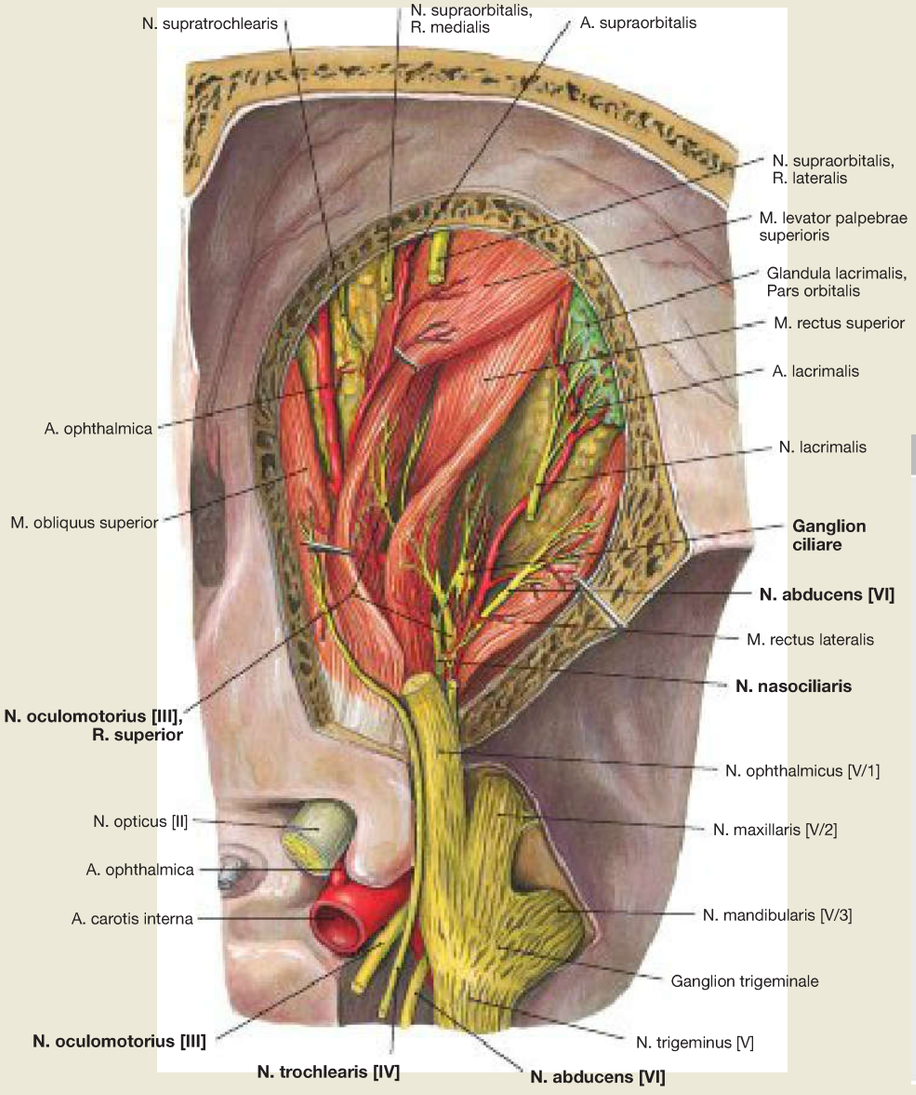

Branches of the A. ophthalmica

- A. centralis retinae
- A. lacrimalis
  - R. anastomoticus cum a. meningea media
  - Aa. palpebrales laterales
- R. meningeus recurrens
- Aa. ciliares posteriores longae
- Aa. musculares
  - Aa. ciliares anteriores
  - Aa. conjunctivales anteriores
  - Aa. episclerales
- A. supraorbitalis
  - R. diploicus
- A. ethmoidalis anterior
  - R. meningeus anterior
  - Rr. septales anteriores
  - Rr. nasales anteriores laterales
- A. ethmoidalis posterior
- Aa. palpebrales mediales
  - Aa. conjunctivales posteriores
  - Arcus palpebralis superior
  - Arcus palpebralis inferior
- A. supratrochlearis
- A. dorsalis nasi

Fig. 9.58 Arteries and nerves of the eye socket, Orbita, right side; superior view; after removal of the roof of the Orbita; illustration of the Ganglion ciliare; the M. levator palpebrae superioris and the M. rectus superior have been folded back.
Depicted are the nerve branches of the N. oculomotorius [III] entering beneath the muscles. After removal of the fat body beneath the muscles, the **Ganglion ciliare,** approximately 2 mm in size becomes visible. Positioned approximately 2 cm lateral of the N. opticus [II] behind the Bulbus oculi, the Ganglion ciliare is embedded in the Corpus adiposum orbitae. The Ganglion ciliare contains perikarya of the postganglionic parasympathetic neurons, which synapse with the axons of preganglionic parasympathetic neurons located in the Nucleus oculomotorius accessorius (autonomicus, EDINGER-WESTPHAL nucleus). These parasympathetic fibres innervate the inner muscles of the eye (M. ciliaris and M. sphincter pupillae, →Fig. 8.192). Postganglionic sympathetic neurons for the M. dilatator pupillae pass through the Ganglion ciliare without switching. They were already switched from preganglionic to postganglionic in the Ganglion cervicale superius.

Arteries and Nerves of the Eye Socket

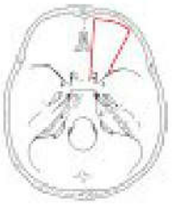

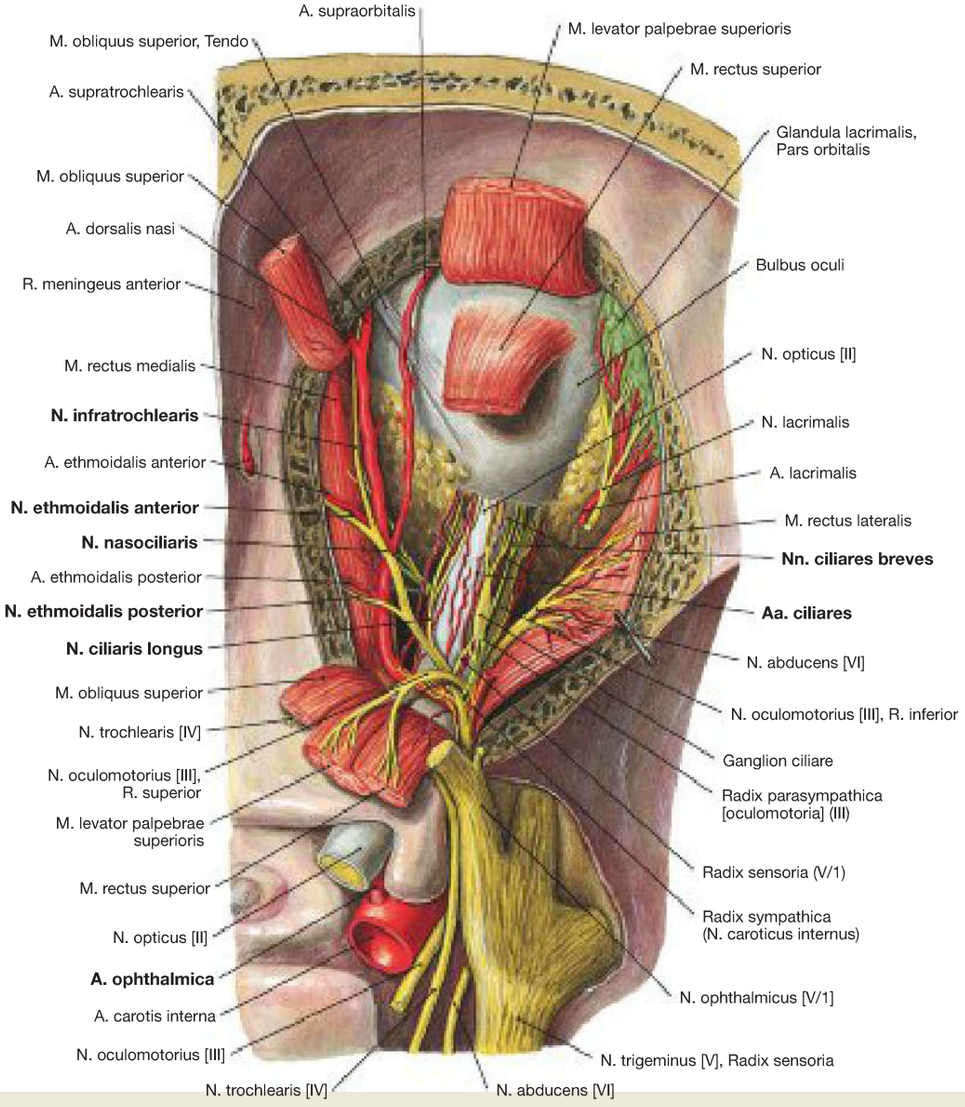

Fig. 9.59 Arteries and nerves of the eye socket, Orbita, right side; superior view; the partial removal of Mm. levator palpebrae superioris, rectus superior and obliquus superior.

The illustration shows the content of the **middle level of the Orbita.** One can recognise the network of arteries (Aa. ciliares) that supply the N. opticus [II] branching off the A. ophthalmica which runs through the Orbita, as well as the Nn. ciliares longi and breves, the Ganglion ciliare and the terminal branching of the N. nasociliaris.

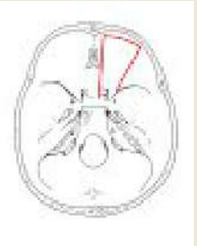

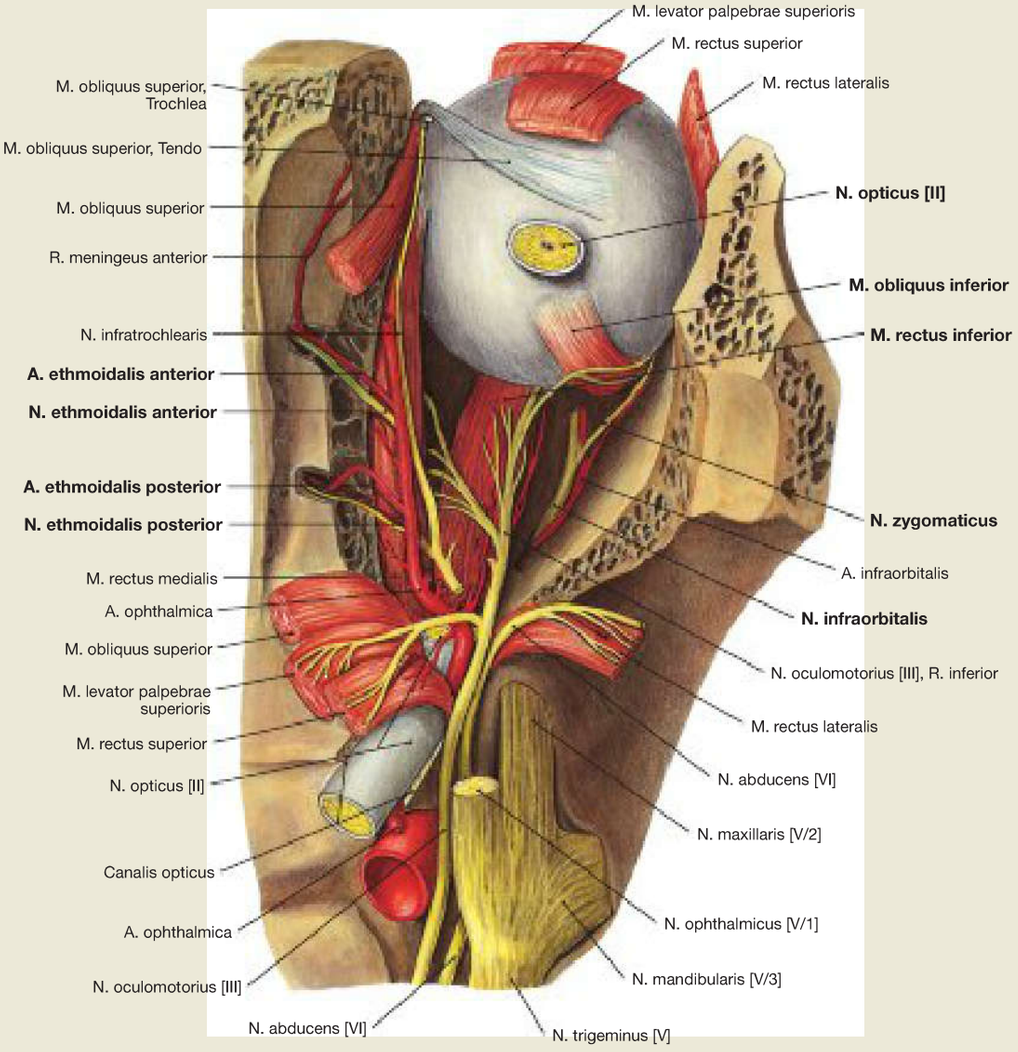

Fig. 9.60 Arteries and nerves of the eye socket, Orbita, right side; superior view; the N. opticus [II] has been cut.
After removal additional structures and upon removal of the entire orbital fat body, the M. inferior rectus and the **lower level of the Orbita** are visible. The Bulbus oculi is rotated in such a way that the insertion site of the M. obliquus inferior, close to the entry site of the cut N. opticus [II], can be seen. On the medial side, the ethmoidal cells (Cellulae ethmoidales) are opened up in order to show the course of the Nn. ethmoidales anterior and posterior as well as the Aa. ethmoidales anterior and posterior from the orbita into the ethmoid bone. At the lower level, the lateral A. and N. infraorbitalis are visible. The N. zygomaticus which contains sensory fibres, branches off the N. infraorbitalis and innervates the lacrimal gland via postganglionic parasympathetic fibres.

Clinical Remarks

The N. opticus [II] has a topographical connection to the sphenoidal sinus (Sinus sphenoidalis), with the consequence that **disease processes within the Sinus sphenoidalis** (sinusitis, tumours) can affect the N. opticus [III] because the bony wall which separates it from the sphenoidal sinus is so thin. Sometimes, this bony wall is missing. During operations in the sphenoidal sinus, great care is required not to damage the N. opticus.

Nerves of the Eye Socket

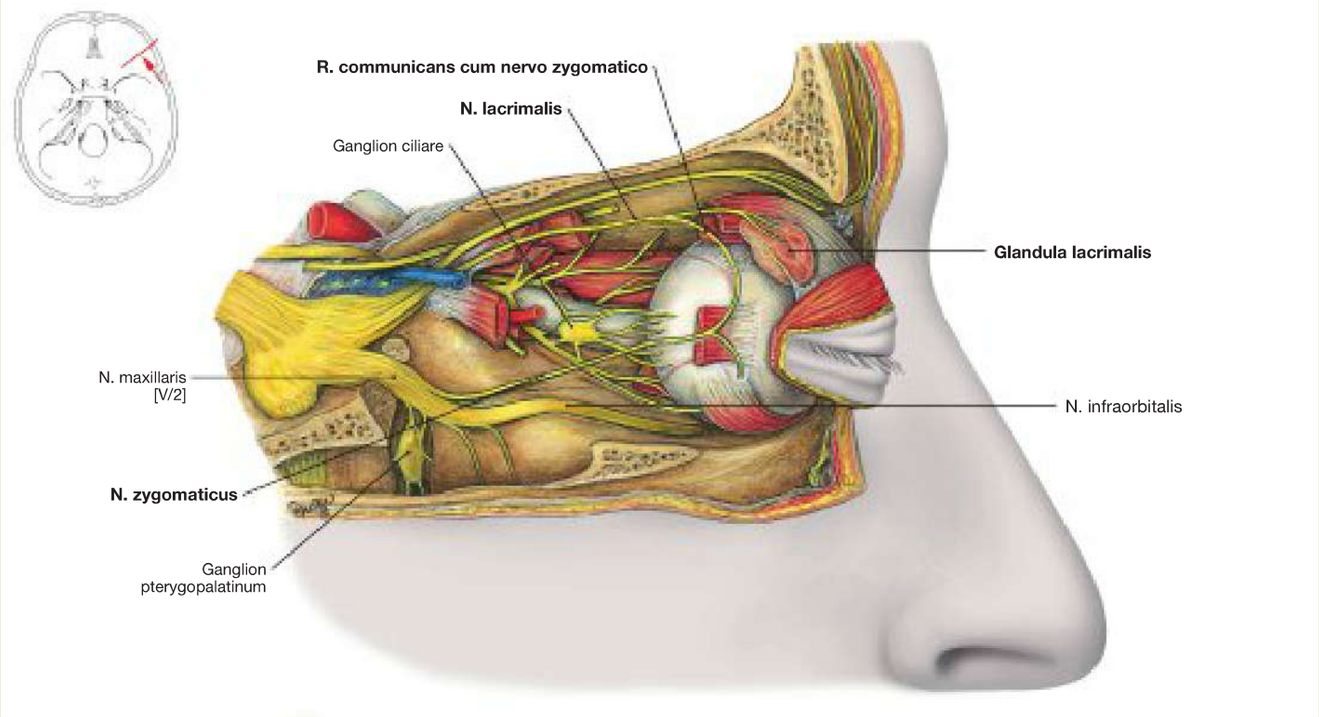

Fig. 9.61 Nerves of the eye socket, Orbita, and the eye, Oculus, innervation of the lacrimal gland, Glandula lacrimalis, and illustration of the Ganglion ciliare, right side; lateral view; after removal of the temporal wall and the orbital fat body.
The lacrimal gland is innervated via sympathetic, parasympathetic and somatosensory fibres. **Postganglionic parasympathetic fibres** originate from the Ganglion pterygopalatinum and stimulate glandular excretion. The fibres leave the Ganglion pterygopalatinum, associate with the N. zygomaticus (a branch of the N. maxillaris [V/2]), and separate as a R. communicans cum nervo zygomatico (→ Fig. 8.192 and → Fig. 9.39) to anastomose with the N. lacrimalis and reach the lacrimal gland. The N. lacrimalis (a branch of the N. ophthalmicus [V/1]) provides the **sensory** innervation. The sympathetic fibres inhibit glandular secretion. **Postganglionic sympathetic fibres** derive from the Ganglion cervicale superius. Without synapsing, the fibres pass through the Ganglion pterygopalatinum and take the same route to the lacrimal gland as the parasympathetic fibres (→ Fig. 9.39).

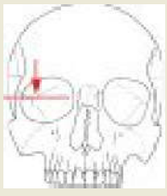

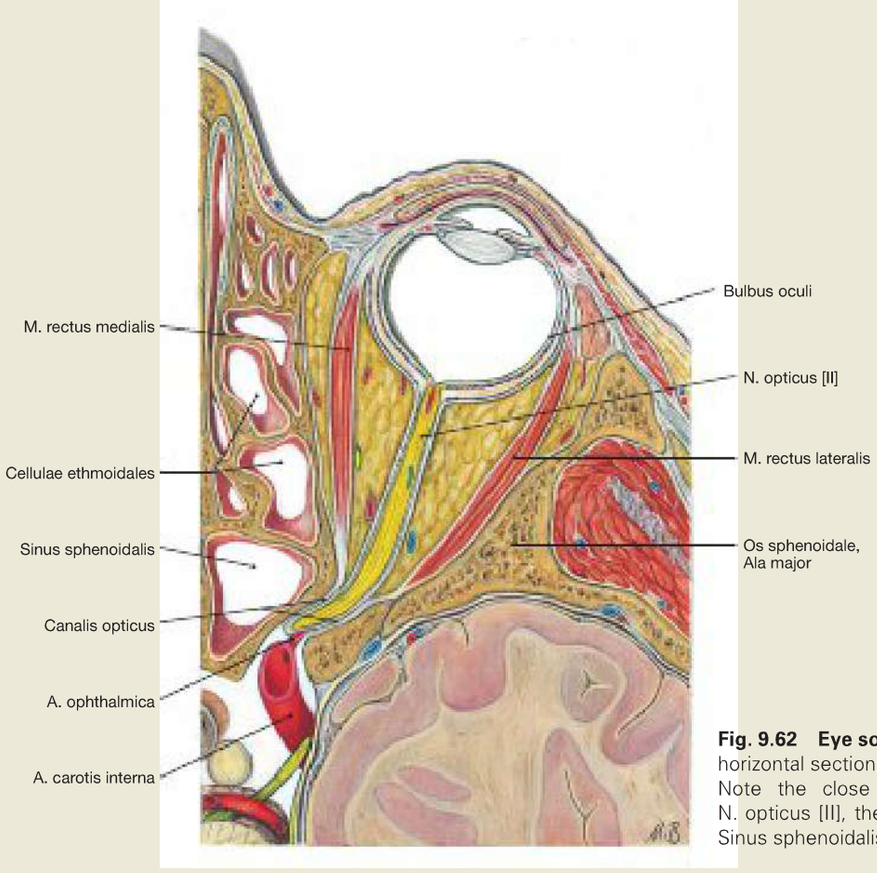

Fig. 9.62 Eye socket, Orbita, right side; horizontal section; superior view.
Note the close relationship between the N. opticus [II], the A. carotis interna, and the Sinus sphenoidalis.

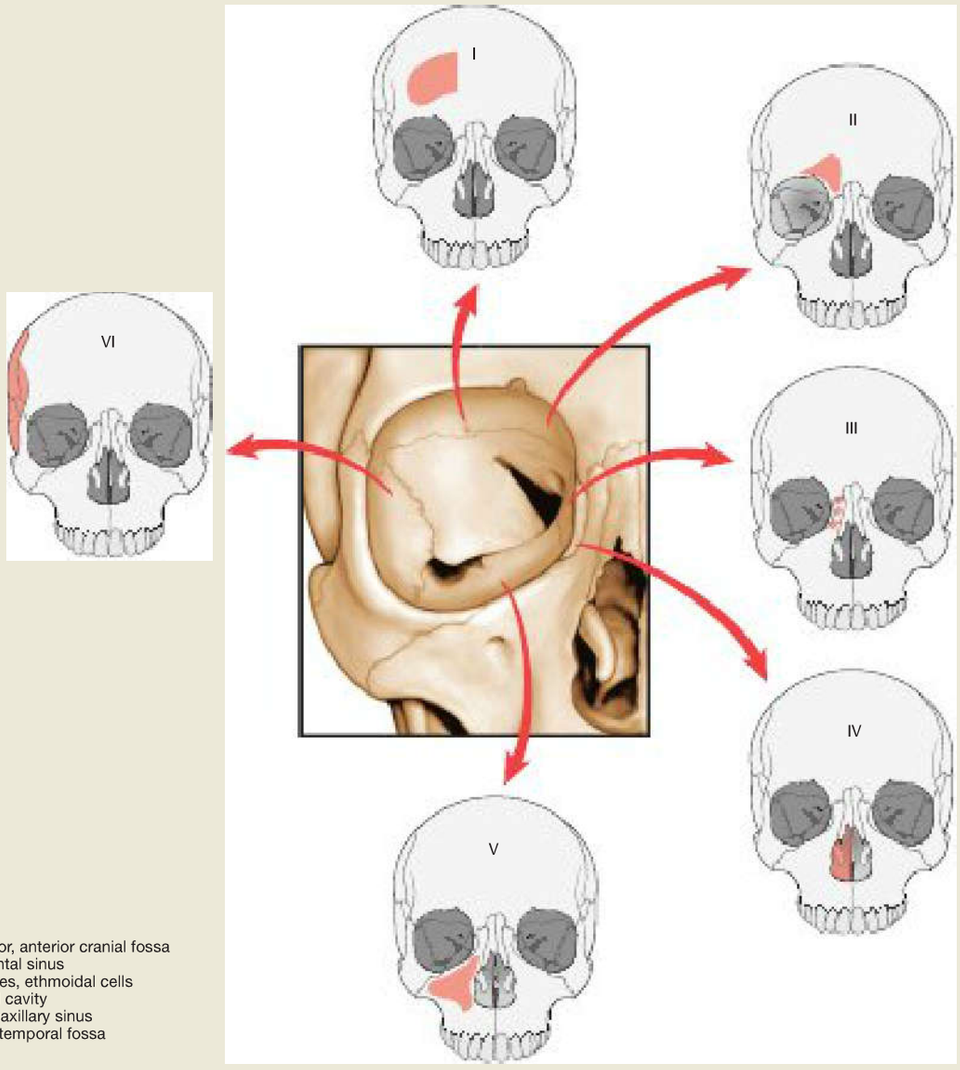

I Fossa cranii anterior, anterior cranial fossa
II Sinus frontalis, frontal sinus
III Cellulae ethmoidales, ethmoidal cells
IV Cavitas nasi, nasal cavity
V Sinus maxillaris, maxillary sinus
VI Fossa temporalis, temporal fossa

Fig. 9.63 Topographical relationship between the eye socket, Orbita, and neighbouring regions, right side; frontal view. [L126]
The Orbita has a close topographical relationship with neighbouring regions. These regions include the anterior cranial fossa (Fossa cranii anterior), the frontal sinus (Sinus frontalis), the ethmoidal cells (Cellulae ethmoidales), the nasal cavity (Cavitas nasi), the maxillary sinus (Sinus maxillaris) and the temporal fossa (Fossa temporalis).

Clinical Remarks

The treatment of diseases, particularly these affecting facial structures, requires the interdisciplinary collaboration of numerous specialist fields. Besides the ophthalmologist, otolaryngologists, oromaxillofacial surgeons, neurosurgeons, radiologists and neurologists also participate in the treatment, as well as specialists of other disciplines (e.g. paediatricians, anaesthetists, nuclear medicine specialists, etc.). Inflammation and tumours of the Orbita can spread to the neighbouring regions (and vice versa) and require interdisciplinary therapy.

Eye Socket, Topography

Clinical Remarks

Endocrine orbitopathy is an inflammation of the Orbita as part of GRAVES' disease. The latter is an autoimmune disease, whereby it is assumed that the immune system erroneously produces antibodies which attack the tissues of the patient's own thyroid gland and eye sockets (e.g. extraocular muscle and orbital fat body). The details of this disease mechanism are not yet fully understood. The disease phenotype are, however, a combination of a hyperfunction of the thyroid gland (hyperthyroidism) and exophthalmos (bulging out of the eyes, → Fig. 9.64). Exophthalmos coincides with widening of the palpebral fissure, retraction of the eyelid, and distorted eye movements.

Fig. 9.64 Patient with GRAVES' orbitopathy. [T127]
One can see the pronounced exophthalmos

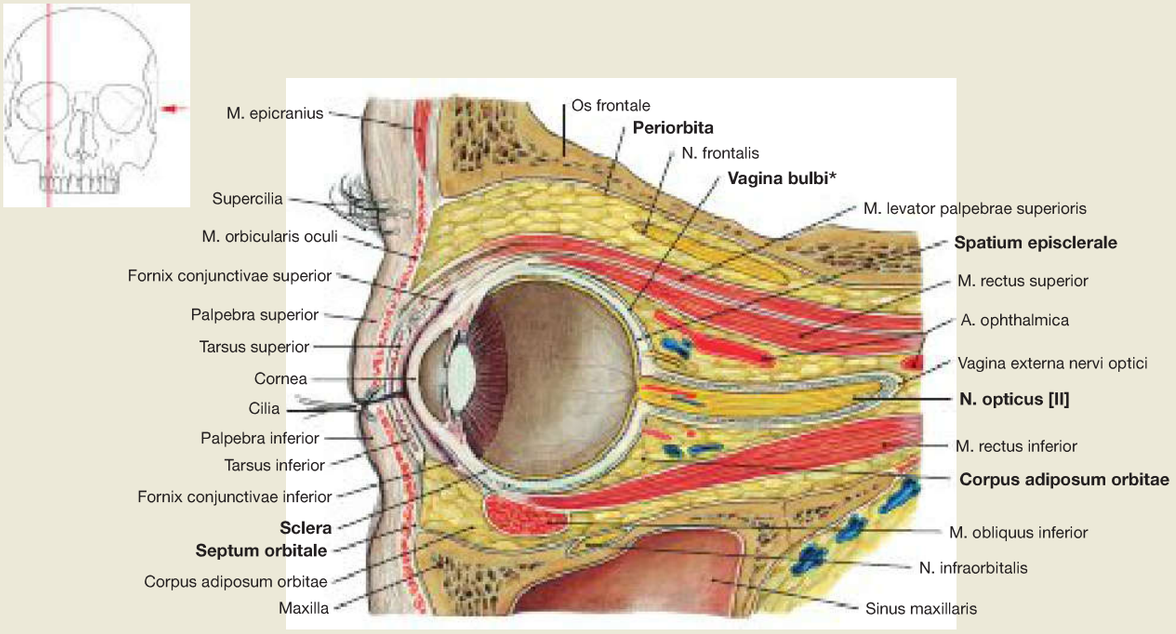

Fig. 9.65 Eye socket, Orbita, right side; medial view; vertical midline section.
The inside of the eye socket is coated with periosteum. All structures of the Orbita are embedded in adipose tissue (Corpus adiposum orbitae). The entrance to the Orbita is restricted by the Septum orbitale. A thin layer of connective tissue sheath (Vagina bulbi, TENON's capsule) surrounds the eyeball. Between the Vagina bulbi and the sclera of the Bulbus oculi is a narrow gap called Spatium episclerale.

* TENON's capsule

Clinical Remarks

For the choice of an appropriate surgical access route the Orbita is divided into parts according to different clinical criteria:

- bulbar part – retrobulbar part
- central or intraconal (delineated by the cone-shaped arrangement of the extraocular rectus muscles) part – peripheral or extraconal part
- upper level – middle level – lower level of the Orbita:
  - The **upper level** is located between the roof of the Orbita and the M. levator palpebrae superioris. It contains: N. frontalis, N. trochlearis, N. lacrimalis, A. supraorbitalis, A. supratrochlearis, A. and V. lacrimalis and V. ophthalmica superior (→ Fig. 9.57).
  - The **middle level** is located between the extraocular rectus muscles and includes the intraconal space (→ Fig. 9.59). It contains: N. oculomotorius, N. nasociliaris, N. abducens, N. zygomaticus, Ganglion ciliare, A. ophthalmica, V. ophthalmica superior, Aa. ciliares posteriores breves and longae.
  - The **lower level** extends from the M. rectus inferior and the M. obliquus oculi inferior to the orbital floor (→ Fig. 9.60). It contains: N. infraorbitalis, A. infraorbitalis and V. ophthalmica inferior.

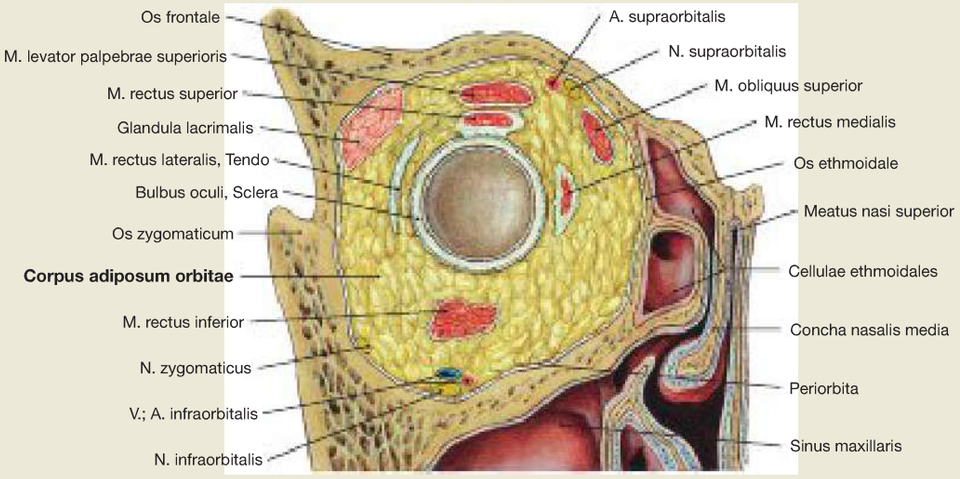

Fig. 9.66 Eye socket, Orbita, right side; frontal section through the Orbita at the level of the posterior aspect of the Bulbus oculi; frontal view.

All structures of the Orbita are embedded in orbital fat body (Corpus adiposum orbitae); this structural fat forms a protective coat around the Orbita.

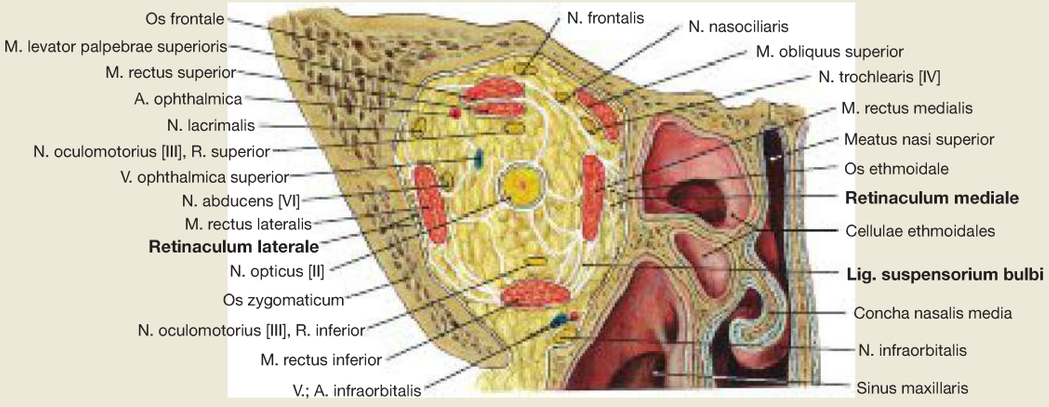

Fig. 9.67 Eye socket, Orbita, right side; frontal section through the retrobulbar region of the Orbita; frontal view.
The Bulbus oculi and the structures of the retrobulbar space connect to the Periorbita and to each other via thin ligaments. The stronger ligaments are called Retinaculum mediale (between the M. rectus medialis and Periorbita) and Retinaculum laterale (between M. rectus lateralis and Periorbita) as well as a Lig. suspensorium bulbi (LOCKWOOD's ligament, between the M. rectus medialis and M. rectus inferior and Periorbita).

Fig. 9.68 Central venous occlusion, left side. [T867]
Bleeding is apparent in all quadrants of the retina.

Clinical Remarks

After **diabetic retinopathy,** retinal vein occlusions (in cases of diabetes mellitus) are the second most common vascular retinal diseases. Very often, the vein occlusions result from local resulting thrombi (thrombosis of the V. centralis retinae = **central venous thrombosis;** → Fig. 9.68). They are accompanied by significant loss of vision. Changes often occur in the retinal vessels of diabetic patients, which can lead to vitreous bleeding, resulting in a loss of vision. If the bleeding into the vitreous body does not resolve spontaneously after two to three months, a removal of the vitreous body (vitrectomy) is recommended in the case of poor vision.

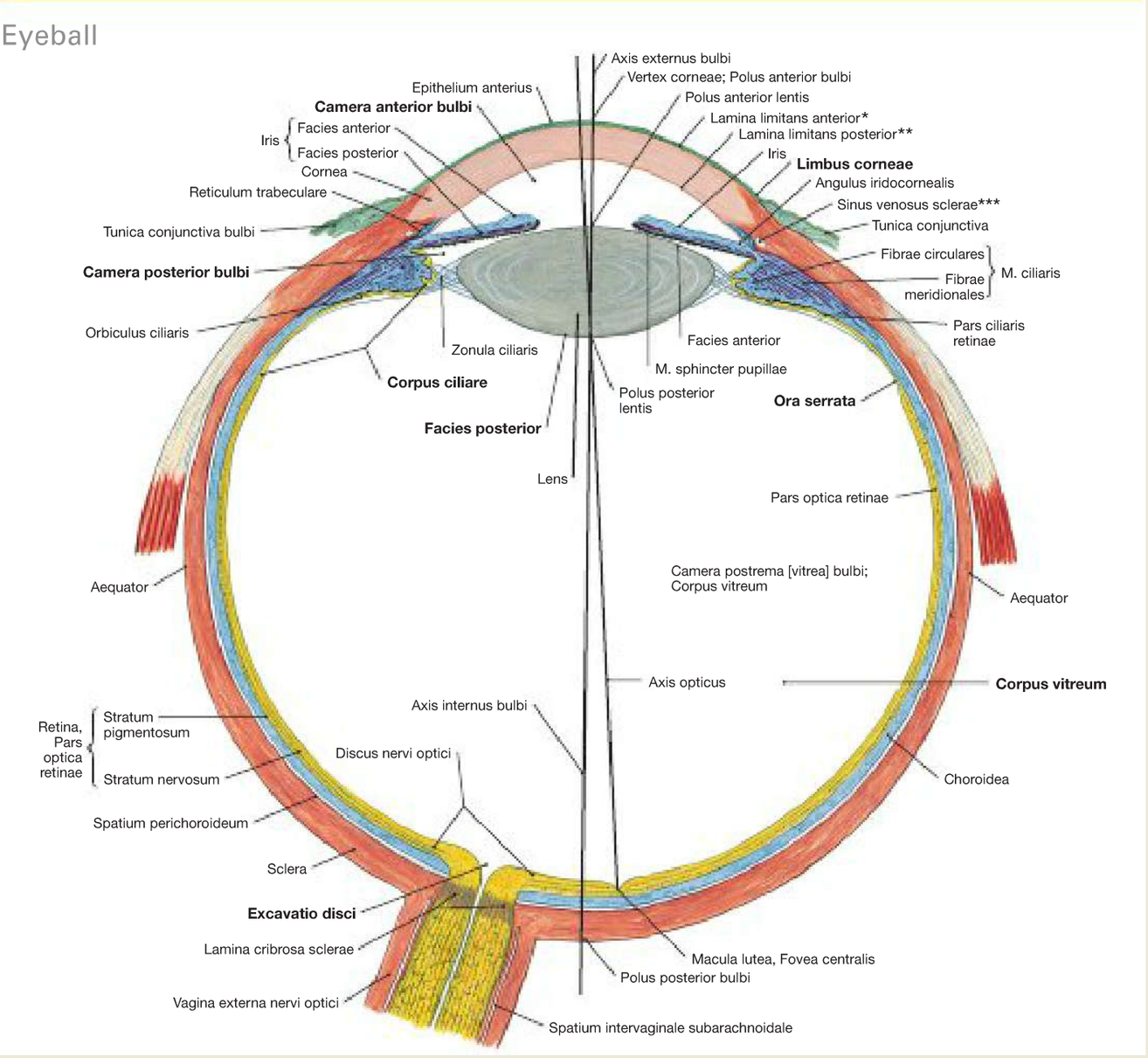

Fig. 9.69 Eyeball, Bulbus oculi, right side; schematic horizontal section at the level of the exit of the N. opticus [II].
In the anterior part of the eye, the outer cover of the eyeball (Tunica fibrosa bulbi) is made up of the sclera and the **cornea**. Shaped like a convex disc, the Cornea bulges out from the rest of the bulbus. At the Limbus corneae, the Cornea merges into the less curved **sclera** which forms the Tunica fibrosa bulbi in the posterior part of the eye. The extraocular muscles insert from outside at the Sclera. The Tunica vasculosa bulbi (vascular layer, Uvea) lies beneath the Sclera. Its anterior part consists of the Iris and the ciliary body (Corpus ciliare), while the **choroid** (Choroidea) forms the posterior part. At the Ora serrata, the ciliary body and the Choroidea meet. The Choroidea represents the most highly vascularised structure in the body. Its blood supply provides nutrients and oxygen to the adjacent retinal layer and is involved in thermoregulation of the eyeball. The **retina** is the innermost layer of the eyeball (Tunica interna bulbi). It contains the neural layer (Stratum nervosum; photoreceptive cells) and the pigmented layer (Stratum pigmentosum; pigment cells), and in the anterior part the pigmented layer of the ciliary body and the epithelium of the Iris. The inner space of the eyeball consists of the **vitreous body** (Corpus vitreum).

* clinical term: BOWMAN's membrane
** clinical term: DESCEMET's membrane
*** clinical term: SCHLEMM's canal

Clinical Remarks

Various diseases (e.g. keratitis = corneal inflammation, keratoconus or chemical irritation) may require the surgical replacement of the cornea to restore proper vision **(corneal transplant).** Since the cornea is not vascularised, a transplant is significantly easier from an immunological point of view than the transplantation of a vascularised organ. Therefore, the corneal transplant (keratoplasty) is the world's most common type of human transplant surgery. **Retinal ablation** (Ablatio or Amotio retinae) describes the detachment of the inner parts of the retina (Stratum nervosum, Neuroretina) from its supplying retinal pigment epithelium (Pars pigmentosa, RPE). Symptoms which include an increase in the number of coloured spots or flashes of light, may not be apparent provided that the macula (point of central vision) is not affected. However, if the macula is detached from its supplying pigment epithelium for more than 48 hours, a permanent loss of function of the corresponding parts of the retina will occur. After a successful reattachment of the retina to the pigment epithelium, the functionality of the retina may improve, depending on the duration of the retinal ablation. If a complete retinal detachment is not corrected, the result will be loss of vision in the affected eye.

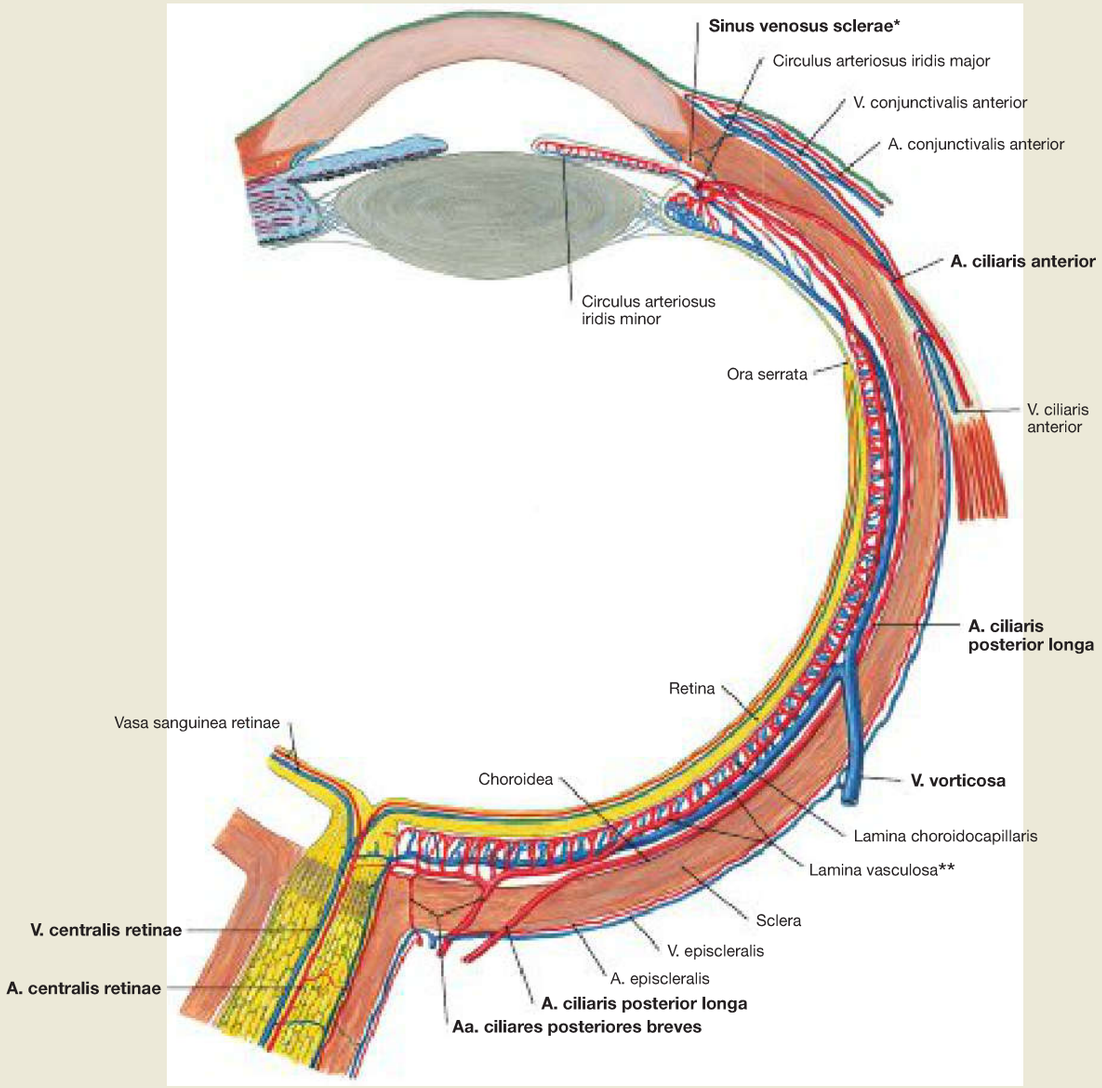

Fig. 9.70 Blood vessels of the eyeball, Bulbus oculi, right side; horizontal section at the level of the N. opticus [II]; view from above. Arterial blood supply (→ Fig. 9.55). The venous drainage occurs via the V. centralis retinae, as well as through four to eight Vv. vorticosae (→ Fig. 9.56). The latter pierce the sclera posterior to the equator of the eyeball and join the Vv. ophthalmica superior and inferior.

* clinical term: SCHLEMM's canal
** clinical term: uvea

Dimensions of the Bulbus oculi (average values according to the anatomic and ophthalmologic literature)			
External bulbar area (Axis bulbi externus)	24.0 mm	Radius of curvature of the sclera	13.0 mm
Internal bulbar area (Axis bulbi internus)	22.5 mm	Radius of curvature of the cornea	7.8 mm
Thickness of the cornea	0.5 mm	Refractive index of the entire eye (distance vision)	59 dioptres
Depth of the anterior chamber	3.6 mm	Refractive index of the cornea	43 dioptres
Thickness of the lens	3.6 mm	Refractive index of the lens (distance vision)	19 dioptres
Distance between lens and retina	15.6 mm	Distance between the two pupils	61–69 mm
Thickness of the retina	0.3 mm		

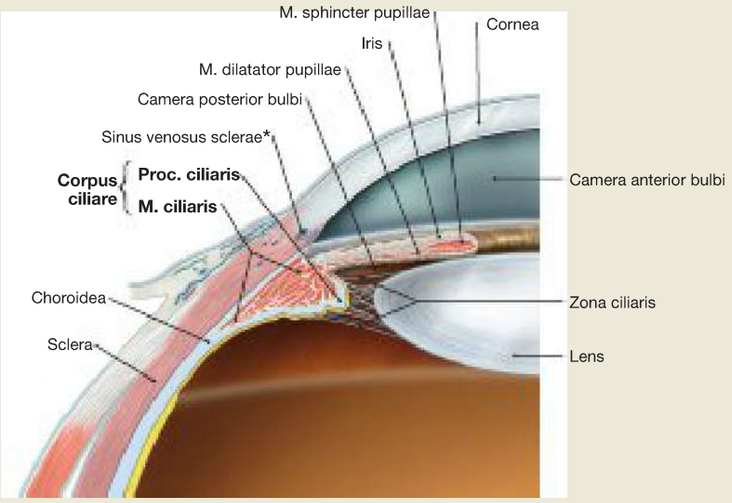

Fig. 9.71 Iridocorneal angle, Angulus iridocornealis, and adjacent structures. [L275]
The iridocorneal angle (Angulus iridocornealis) is borderd by the cornea, iris and sclera. The epithelium of the Corpus ciliare produces the aqueous humour which flows from the posterior chamber to the anterior chamber and through the trabecular meshwork in the Angulus iridocornealis into the SCHLEMM's canal (*) where the fluid drained into the episcleral veins. The M. ciliaris is the major component of ciliary body. It consists of meridional (longitudinal, BRÜCKE's muscle), radial, and circular (MÜLLER's) muscle cells and is important for accommodation.

Clinical Remarks

Insufficient **drainage** of the aqueous humour can lead to increased intraocular pressure (normal 15 mmHg). This mainly causes damage in the area of the papilla of the optic nerve and can cause blindness. Causes include, e.g. blockage of the iridocorneal angle, for instance by adhesion of the iris to the cornea **(angle-closure glaucoma,** rare), or impaired drainage through the trabecular meshwork which covers the SCHLEMM's canal in **open-angle glaucoma** (frequent).

Genetic deficiencies in the synthesis of the connecting protein fibrillin-1 **(MARFAN's syndrome)** result in an insufficiency of the zonular fibres with shifting of the lens (lens luxation) and a permanent ball-shaped lens (impaired distance accommodation).

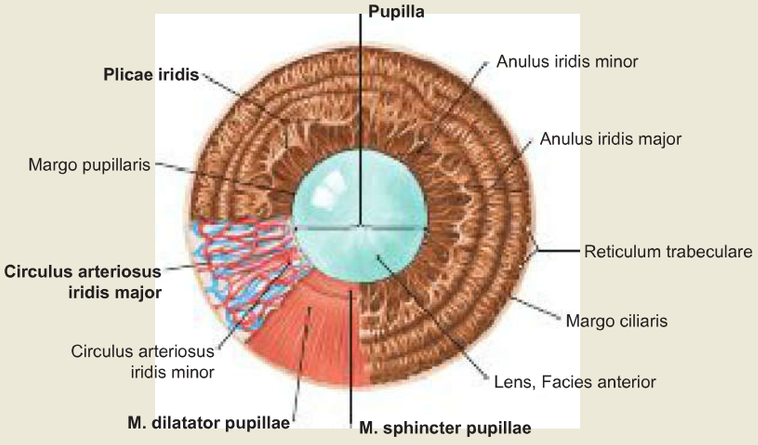

Fig. 9.72 Iris and lens; frontal view.

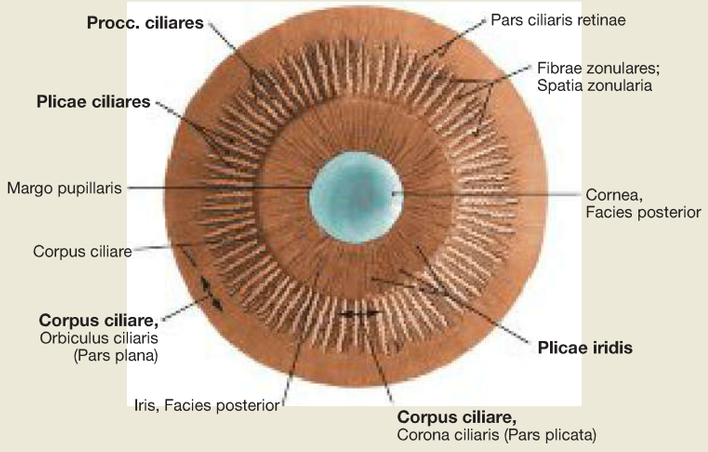

Fig. 9.73 Iris and ciliary body, Corpus ciliare; posterior view; after removal of the lens.
The Corpus ciliare is divided into a plane (Pars plana) and a raised part (Pars plicata). Approximately 70 ciliary processes (Procc. ciliares) originate from the latter. The Corpus ciliare is covered with ciliary epithelium, which, in the area of the Pars plicata, secretes the aqueous humour for the iridocorneal angle (Angulus iridocornealis). Zonular fibres (suspensory ligaments of the lens, Zonulae ciliares) traverse the distance between the ciliary epithelium and the lens capsule.

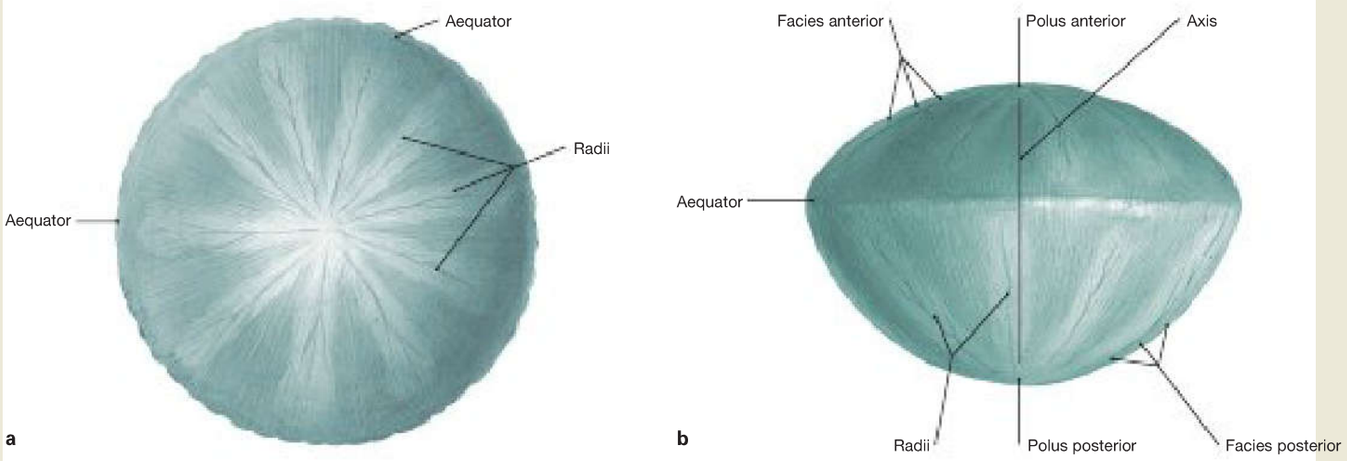

Fig. 9.74 a and b Lens.
a Frontal view
b View from the equator

Depending on its particular level of accommodation, the refractive index of the lens varies between 10–20 dioptres (for comparison, the refractive index of the cornea is 43 dioptres but cannot be modified).

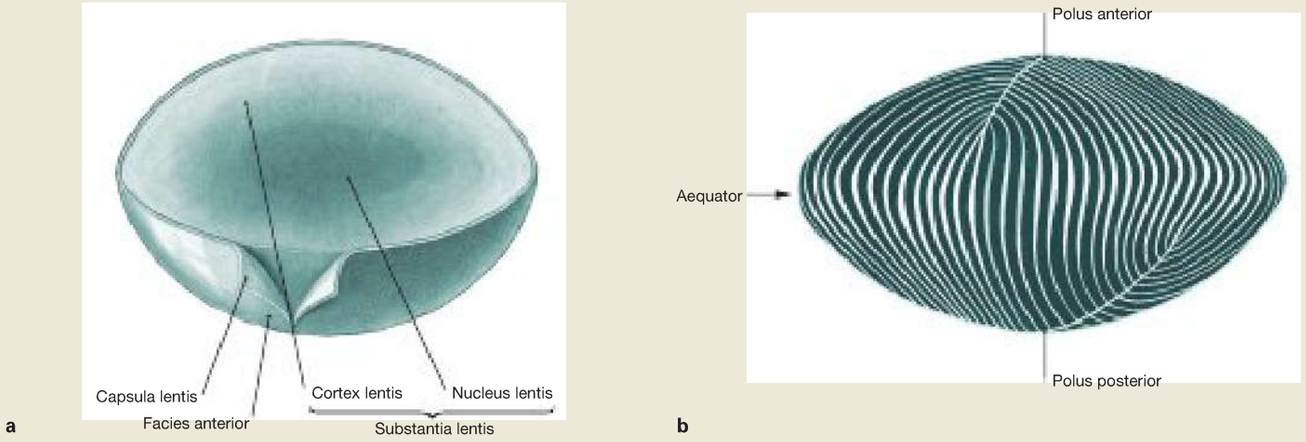

Fig. 9.75a and b Lens.
a Anterior oblique view; after meridional cut and partial detachment of the anterior lens capsule (Capsula lentis).

b Lens fibres of a new-born infant; schematic drawing; view from the equator.
The centres of the planes are known as anterior pole (Polus anterior) or posterior pole (Polus posterior).

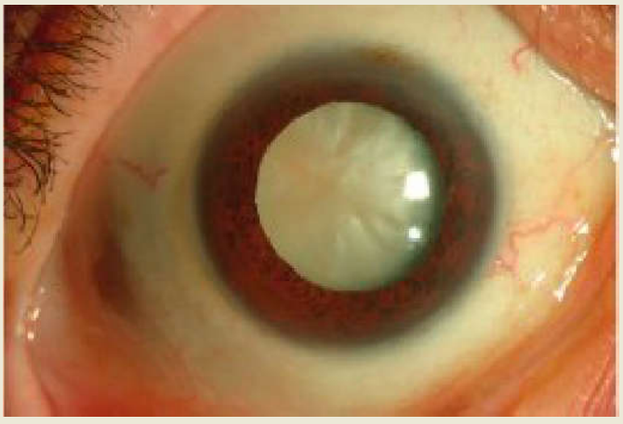

Fig. 9.76 Senile cataracts, Cataracta senilis, right side. [T867]
White turbidity is evidence of an advanced cataract.

Clinical Remarks

The continuous apposition of lens fibres reduces the elasticity (as of age 40) which results in a diminished accommodation of the lens, i.e. the inability to properly focussing on objects at various distances (age related vision impairment, **presbyopia**). Reduction in intracellular water content causes alterations in proteins (crystallines), important for maintaining transparency of the lens. This leads to a cataract (grey senile cataract, **Cataracta senilis**), which is the most common eye disease. A cataract can be diagnosed at an early stage by means of a slit-lamp examination (→ Fig. 9.76). Cataract surgery is one of the most frequently performed surgical procedures in Western industrialised countries (approximately 10% of all 80-year-old patients suffer from an advanced cataract).

Ocular Fundus

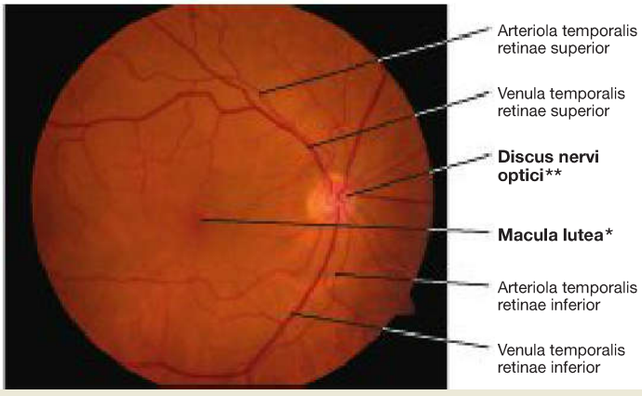

Fig. 9.77 Ocular fundus, Fundus oculi, right side; frontal view; opthalmoscopic native imaging. [T867]
The examination of the ocular fundus by direct ophthalmoscopy (fundoscopy) allows the clinical assessment of the condition of the retina, its blood vessels (in particular the A. and V. centralis retinae), the optic disc (Discus nervi optici), as well as the yellow spot (Macula lutea) and the point of central vision (Fovea centralis). The retinal vessels (A. and V. centralis retinae and their branches) may be assessed and, due to the vessel diameter (arteries – smaller diameter), distinguished from one another. The papilla of the N. opticus [II] normally has a sharp margin, is yellow to orange colour and contains a central depression (Excavatio disci). The Macula lutea (where most of the cone cells are located) sits 3–4 mm temporally of the N. opticus [II]. Numerous branches of the Vasa centralia retinae converge in a radial fashion onto the macula, but do not reach the centre (Fovea centralis). The latter is supplied via the choroidea.

* clinical term: yellow spot
** clinical term: blind spot (Discus = Papilla nervi optici)

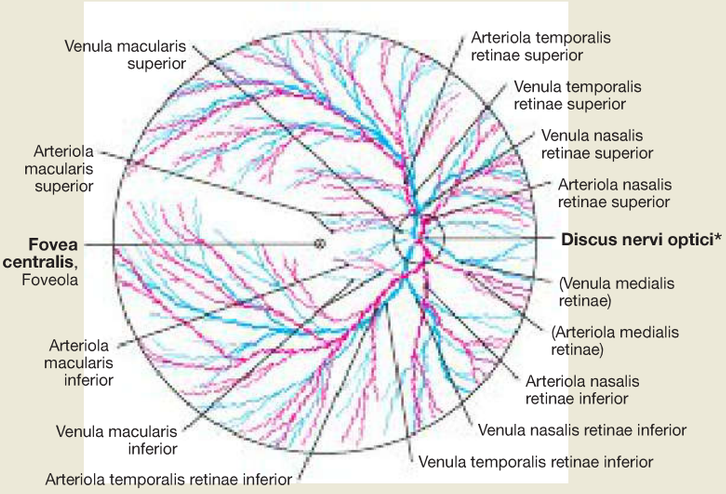

Fig. 9.78 Ocular fundus, Fundus oculi, and blood vessels of the retina, Vasa sanguinea retinae, right side; frontal view; schematic illustration of the course of the blood vessels. [T899]

* Papilla nervi optici

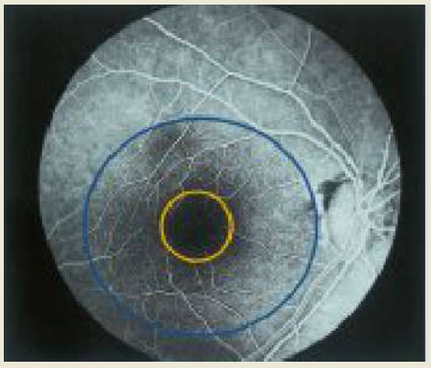

Fig. 9.79 Ocular fundus, Fundus oculi, right side; frontal view; fluorescence angiography during the arteriovenous phase with anatomic landmarks: macula (blue circle); fovea (yellow circle). [E282]

Fig. 9.80 Concentric enlargement of the optic disc due to glaucoma. [T867]

Clinical Remarks

In case of a **retinal detachment** (Ablatio retinae) the retina takes on a whitish-yellow colour. Changes in blood vessels as in diabetic retinopathy or hypertension can be diagnosed at an early stage by fundoscopy. For advanced diagnostics a fluorescence angiography may be performed (→ Fig. 9.79). With increased intracranial pressure (CSF) the papilla of the N. opticus [II] in the Bulbus oculi appears to be slightly protruding and its margins appear less well defined **(papilloedema).** Glaucoma also causes characteristic changes to the optic disc (papillary glaucoma; → Fig. 9.80). Pathological changes in the Macula lutea are frequently age-related. The most **frequent cause of blindness** in Western industrialised countries is age-related macular degeneration (AMD).

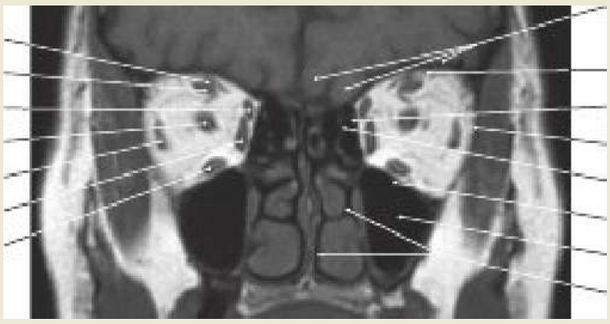

Fig. 9.81 Extraocular muscles, Mm. oculi; magnetic resonance image (MRI), frontal section of a healthy individual at the level of the orbital centre; frontal view. [T916]

One can clearly see the close topographical relationship of the Orbita, Sinus maxillaris, Lobus frontalis, Cellulae ethmoidales and M. temporalis (not shown).

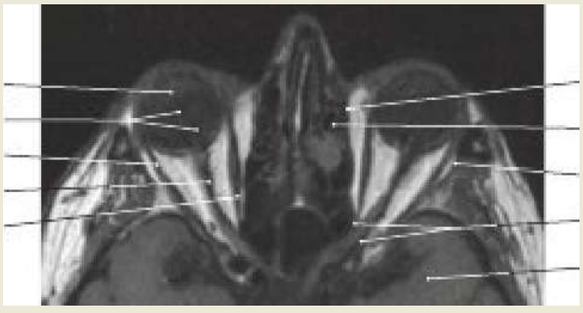

Fig. 9.82 Eyeball, Bulbus oculi, and extraocular muscles, Mm. bulbi; magnetic resonance image (MRI), cross-section of a healthy individual at the level of the N. opticus [II]; superior view. [T916]

In this cross-section one can clearly see the slightly contorted course of the N. opticus [II], which is important as a reserve route for eye movement.

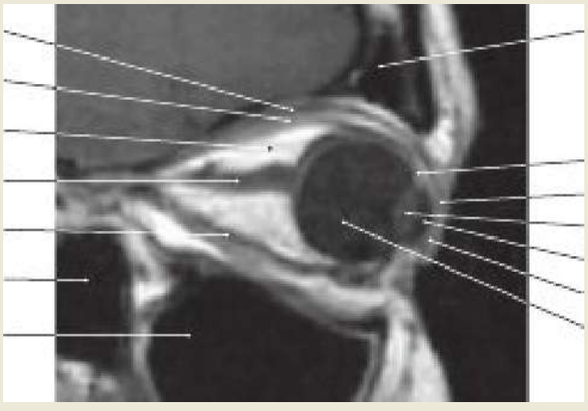

Fig. 9.83 Eyeball, Bulbus oculi, and extraocular muscles, Mm. bulbi; magnetic resonance image (MRI), sagittal section of a healthy individual at the level of the N. opticus [II]; lateral view.

In the MRI the bulbar space and the retrobulbar space can easily be held apart due to the different layers of tissue.

Examination Methods

Most visible structures of the eye can be examined in vivo using special optical instruments (e.g. magnifying glasses, ophthalmoscope, slit lamp) on the patient, e.g. cornea, aqueous humour, iridocorneal angle, iris, lens, vitreous body, retina with papilla of the N. opticus [II] and macula.

Imaging techniques can help in the diagnosis of chronic inflammation or of tumors which are located in areas of the Bulbus oculi that cannot be otherwise examined. Among the most frequently used imaging techniques for the examination of intraorbital structures and their topographical relationships are **computed tomography** (CT) and **magnetic resonance imaging** (MRI). By intravenous administration of a contrast medium, these procedures can often reveal even more detailed information.

If the fundus of the eye cannot be assessed by an ophthalmoscopy (e.g. due to pathological changes, such as corneal opacity, cataract or bleeding into the vitreous humor) an **ultrasound examination** of the eye can be performed.

Visual Pathway and Blood Vessels

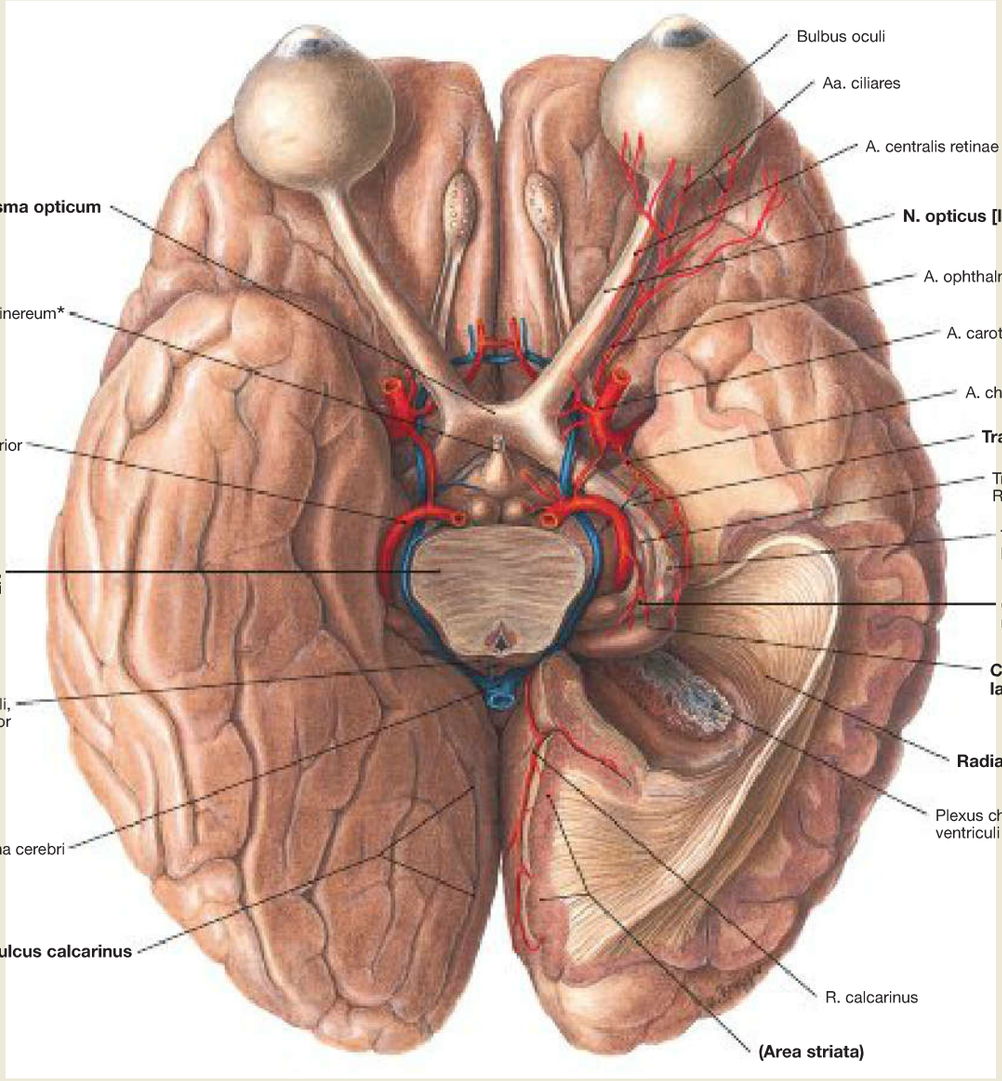

Fig. 9.84 Brain, Cerebrum, and blood supply of the visual pathway; inferior view. The pituitary gland has been removed at its infundibulum (*). It lies in close proximity to the Chiasma opticum.
The visual pathway originates within the retina and contains the first three projection neurons and interneurons (horizontal cells, amacrine cells; → Fig.12.140). They follow each other from the outside to the inside in the following order:
First neuron: photoreceptor cells of the retina (rod and cone cells)
Second neuron: bipolar ganglion cells (perikarya in the Ganglion retinae), which receive the signals from the photoreceptor cells and transmits them to the multipolar ganglion cells (third neuron)
Third neuron: multipolar ganglion cells (perikarya in the Ganglion opticum).
This principle of three neurons forming an intraretinal chain only applies to the cone cells. Up to 40 rod cells converge their signals onto one bipolar cell and this cell will then transmit these signals indirectly, with the help of amacrine cells (20–50 different types of these cells have been described in the literature to date), to one multipolar ganglionic cell. The axons of the Ganglion opticum extend primarily to the Corpus geniculatum laterale (Radix lateralis) although several fibers also extend into the Area pretectalis and in the Colliculus superior (Radix medialis) as well as to the hypothalamus. The fibres run in the N. opticus [II] to the Chiasma opticum. Here they cross the nasal part of the retina to the opposite side. The fibres of the temporal part of the retina do not cross. In the Tractus opticus there are also fibres which transmit information from the contralateral half of the visual field.
Fourth Neuron: Its axons travel primarily from the Corpus geniculatum laterale to the areas 17 and 18 of the cerebral cortex (Area striata) in the region surrounding the Sulcus calcarinus.

Clinical Remarks

Prior to activating the light-sensitive parts of the photoreceptors, light must penetrate through all the other layers of the retina (third neuron, second neuron); this is called the inversion of the retina. The photoreceptors (first neuron) are in close contact with the pigment epithelium, without developing actual adhesion structures between the pigment epithelium and photoreceptors. In this area, retinal ablation (**ablatio** or **amotio retinae)** can occur, which can lead to blindness, if not treated.

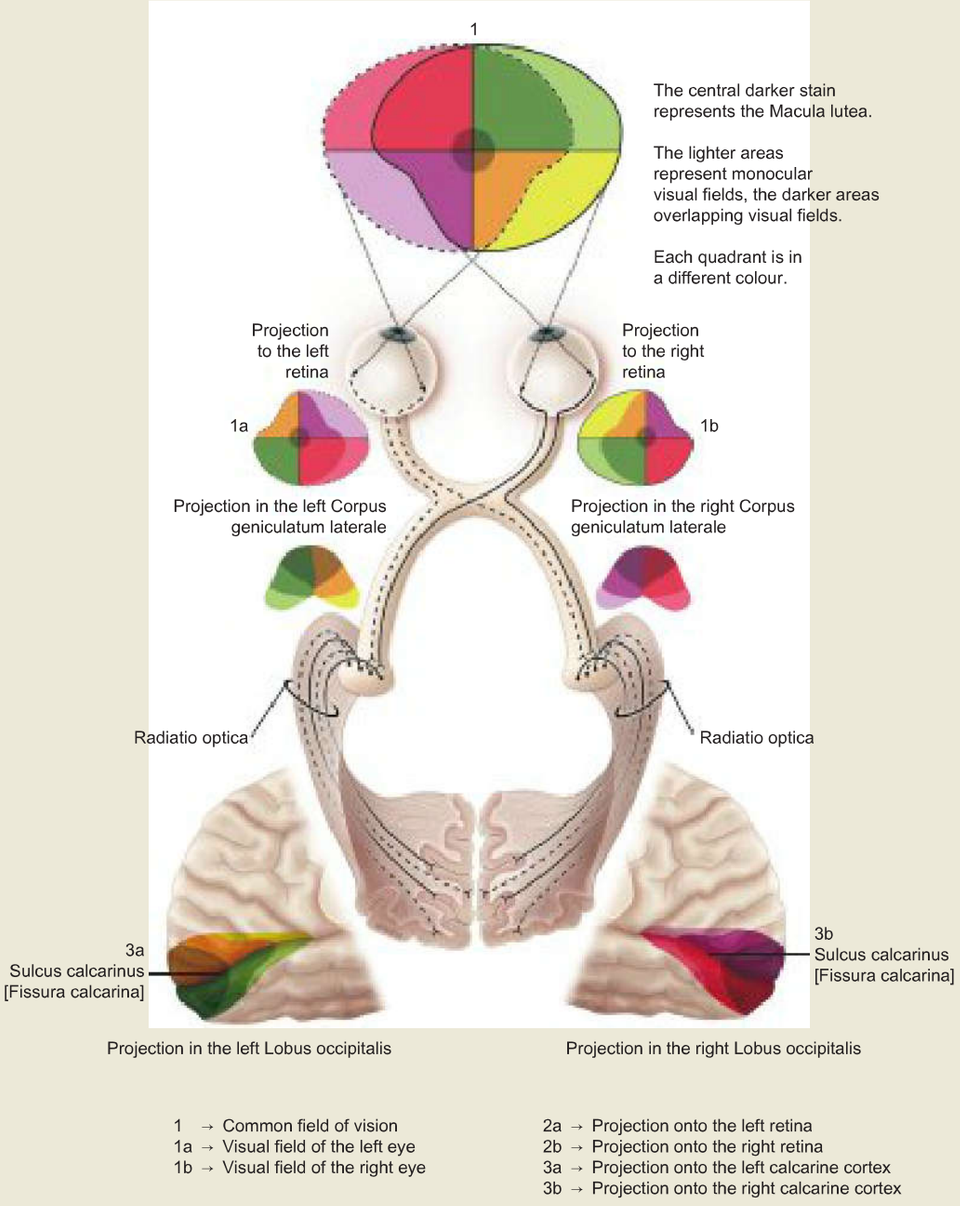

1 → Common field of vision
1a → Visual field of the left eye
1b → Visual field of the right eye

2a → Projection onto the left retina
2b → Projection onto the right retina
3a → Projection onto the left calcarine cortex
3b → Projection onto the right calcarine cortex

Fig. 9.85 Visual pathway; schematic overview; superior view.
The central visual field has a disproportionately large projection area. [L238]
It is only when it is at the level of the visual association cortices, that the image is perceived as it actually should be. Until this point it 'stands on its head'. The classification of visual fields in four colours is used to show how information is transmitted and presented in the corresponding areas in the visual cortex and the various sections of the visual pathway.

Clinical Remarks

Because of the close topographical relationship to the Chiasma opticum, if pituitary tumours increase in size, they can cause a **bitemporal hemianopsia.** Postchiasmatic or intracerebral lesions along the visual pathway can result in **homonymous hemianopsia.** Thus, for example, lesion of the right Tractus opticus can lead to a left-sided homonymous hemianopsia. A lesion of the left Radiatio optica (GRATIOLET's optic radiation) can cause a right-sided homonymous hemianopsia. Additional symptoms may include hemioptic pupillary rigidity, a degeneration of the pupil (after months) or optic papilla oedema. Underlying causes can be tumors, basal meningitis, aneurysm, ischemia and bleeding. Loss of function in both visual cortices causes a **cortical amaurosis** (cortical blindness; → Fig. 12.131).

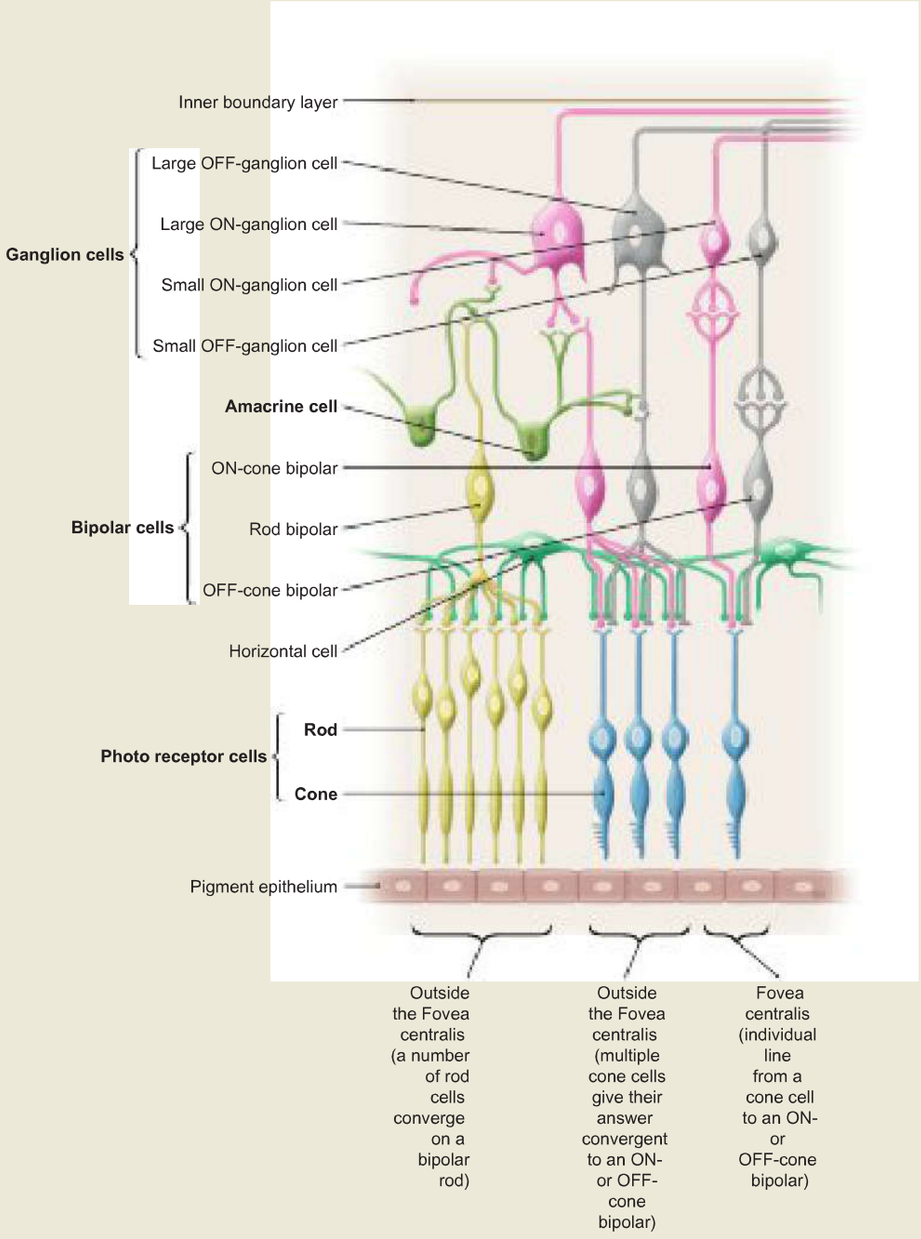

Fig. 9.86 Neuronal interconnections in the retina; simplified diagram. [L238]
The environment (visual field) is perceived with the stationary eye and is relayed to the retina. It contains the first three (cone cells) or four (rod cells) neurons of the visual tract. The first neurons are the photoreceptor cells (rod and cone cells); the second neurons are the bipolar ON- or OFF-cone cells which follow the bipolar rods. The third neurons are large or small ganglion cells that occur as ON- or OFF-ganglion cells for the cones; the third, fourth neuron of the retinal bipolar rod cells are amacrine cells and ganglion cells. Both rod and cone cells can project onto a large ganglion cell. The area of the retina, of which the light leads to a response in a particular ganglion cell and the corresponding nerve fibres of the N. opticus [II], is referred to as the receptive field. If the receptive field is large, the resolution is only low; if it is small, the resolution is high. The ON- and OFF-ganglion cells, with their preliminary ON- and OFF-rod-bipolar cells play a decisive role in the contrast enhancement (stimulating centre and inhibiting environment). These mechanisms are further reinforced by the horizontal cells as interneurons. However, the mechanisms are not yet fully understood.

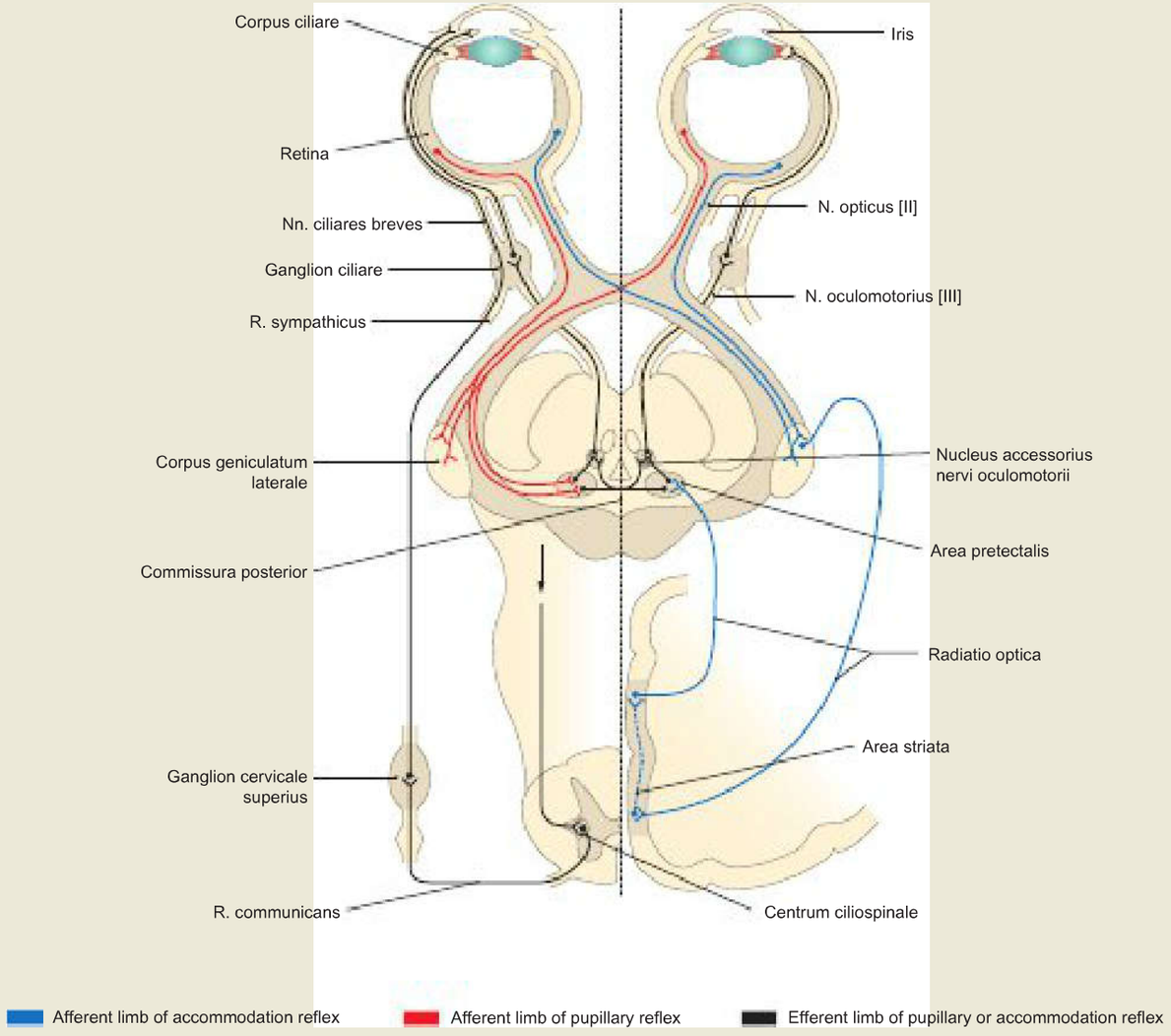

Fig. 9.87 Pupillary, left side, and accommodation reflex, right side. [L126]
For an intact visualising process, it is not only the placement of impressions to the awareness important, but also the light-dark setting, the near-far setting, and the setting of the visual sight lines are of great importance. These functions are coordinated by the pupillary reflex, the accommodation-convergence equipment of the eye and the convergence apparatus.
Pupillary reflex: multi-synaptically mediated reflectory adjustment of the width of the pupil to different lighting conditions. Activation of the photoreceptor cells of the retina, leading to the transmission of the signal into the Area pretectalis, from where the information is first interconnected and then routed to the parasympathetic Nucleus accessorius nervi oculomotorii (EDINGER-WESTPHAL's nucleus) and the ciliospinal centre of the spinal cord. **Pupil constriction:** from the Nucleus accessorius nervi oculomotorii, the information reaches the Ganglion ciliare. Switching over leads to an innervation of the M. sphincter pupillae (myosis). **Pupil Dilatation:** after switching in the Centrum ciliospinale of the spinal cord and further switching in the Ganglion cervicale superius, the postganglionic sympathetic fibres with their arteries reach the M. dilatator pupillae (mydriasis).

Accommodation reflex and convergence reaction: in order to be able to see close objects clearly, the refractive index of the lens must be increased, as well as an alignment of the sight lines through the convergence reaction on the object and thus to the centre, by accommodating and converging. In addition, the depth of field must be increased by narrowing of the pupil (aperture). In the entire visual tract, the afferent reflex branches of each side are identical (up to the visual cortex) and therefore contain the information of both eyes. **Accommodation:** in the efferent reflex branches project neurons of the visual cortex enter into the pretectal area via the tectum (Brachium colliculi superioris) and are configured in the same manner as for the light reflex (crossed and uncrossed). The increase in the refractive power of the lens is carried out by contraction of the general efferent fibres of the N. oculomotorius [III] innervated M. ciliaris, which induce miosis by contraction of the same fibres as for the innervated M. sphincter pupillae. **Convergence reaction:** caused by the somatoefferent fibres of the N. oculomotorius [III] to the eye muscles, because of the stimulation of the neurons of the Nucleus nervi oculomotorii by nerve fibres from the Area pretectalis. It is for the activation of the M. rectus medialis to move the respective bulb to the centre. At the same time, fibres from the Area pretectalis along the Fasciculus longitudinalis medialis to the Nucleus abducentis cause a slackening of the M. rectus lateralis.

Clinical Remarks

Lesions of the retina and N. opticus [II] not only lead to blindness, but also to elimination of the pupillary reflex **(amaurotic pupillary rigidity).** Direct light reaction of the eye is thereby terminated. Lesions of the efferent branch (e.g. damage to the N. oculomotorius [III]) result in the elimination of direct and indirect light reaction **(complete pupillary rigidity).** A loss of any light reaction in both eyes (e.g. in the case of damage to the mesencephalon) would be called a **reflecting pupillary rigidity**.

Practice Exam Questions

To check that you are completely familiar with the content of this chapter, practice questions from an oral anatomy exam are listed here.

Explain the structure of the Orbita:

- Which bone borders the Orbita, which entry and exit points does the Orbita have, and what goes in and out?
- Which structures and cavities confine to the Orbita?
- What passes through the Canalis nervi optici?
- What runs along the floor of the Orbita?
- What lines the Orbita?
- How can the Orbita be divided?
- What are the weak points in the bony structure of the Orbita?
- Why is the middle wall of the Orbita called the Lamina papyracea?

Describe the entrance to the Orbita:

- Which structures close the opening of the Orbita? How are they structured?
- What is the Septum orbitale? Where is it?
- How is the skin around the opening of the Orbita innervated?
- Are there any vascular connections between the face and the Orbita? If so; please describe them.
- Which muscles are involved in the opening and closing movements of the eyelid?
- What is the Conjunctiva bulbi and what is the Conjunctiva palpebrae? Where is the conjunctival sac?
- Where is the lacrimal gland? How is it innervated and how is it provided with blood? Where does it deposit its secretion? What is the function of this secretion?

Describe the structure of the efferent lacrimal ducts:

- Where is the lacrimal sac?
- Where does the nasolacrimal duct enter?
- What happens to used lacrimal fluid?
- How does lacrimal drainage work?
- Which muscle is essential for the drainage of the lacrimal fluid?

Explain the content of the Orbita:

- Which extraocular muscles do you know?
- How are the extraocular muscles innervated and supplied with blood?
- Where do the extraocular muscles have their insertion and their origin?
- In which direction does the Bulbus oculi move in the event of an isolated contraction of the M. obliquus superior?
- What is the trochlea, and what is its function?
- What branches go out from the N. ophthalmicus [V/1], and what innervates them?
- What is the tendinous annulus of ZINN? Which structures go through it?
- How is the Bulbus oculi fixed in the Orbita?
- Which different vascular connections are there between the Orbita and the nose?

Explain the innervation of the eye:

- Where is the Ganglion ciliare? What function does it have?
- What are the names of the inner eye muscles? How are they innervated?
- What is meant by HORNER's triad?
- What is switched in the Ganglion ciliare?

Describe the structure of the Bulbus oculi:

- Where is aqueous humour formed, and how is it circulated?
- How is the cornea structured?
- What is the Corpus ciliare? What is its function?
- How is the ocular lens structured, and how does it work?
- Which different layers participate in the structure of the Bulbus oculi?
- Explain the arrangement of the neurons in the retina.
- Which blood vessels supply the choroid?

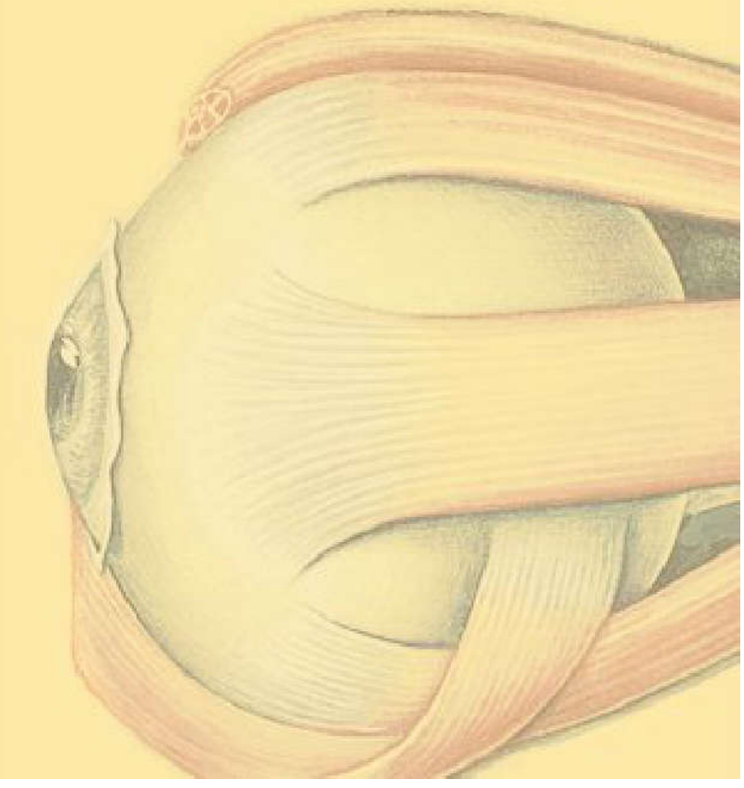

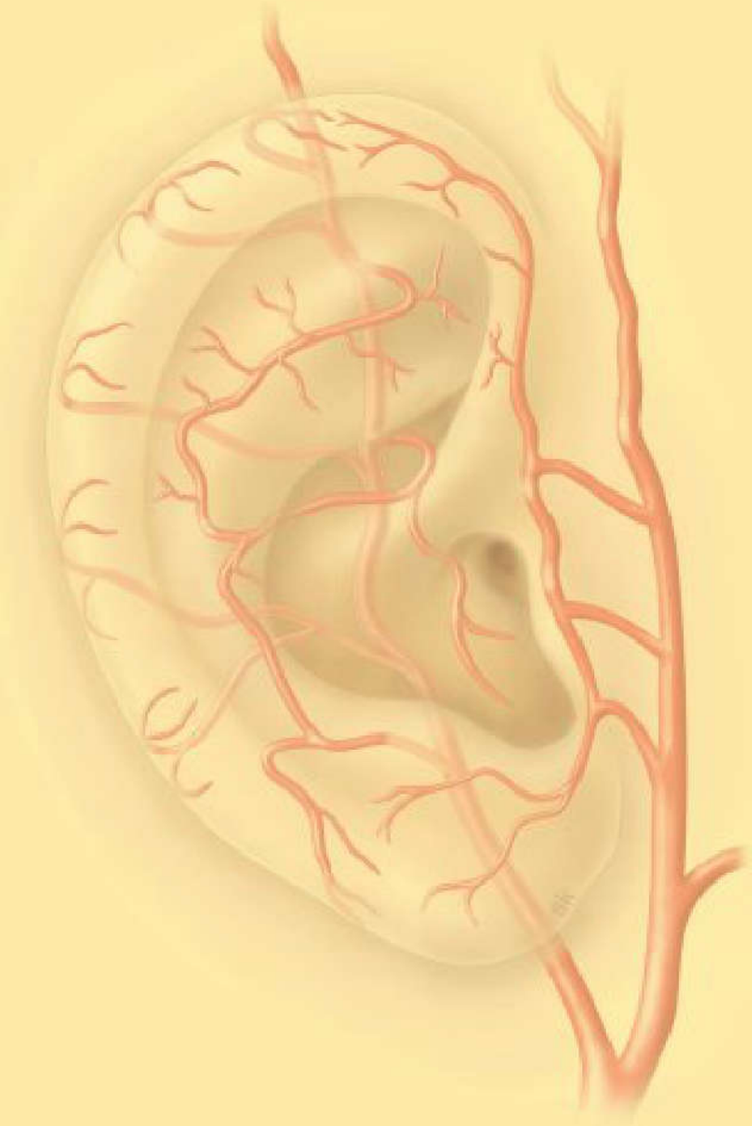

Ear

Overview 168

Outer Ear 172

Middle Ear 174

Auditory Tube 182

Inner Ear 186

Hearing and Equilibrium 192

10

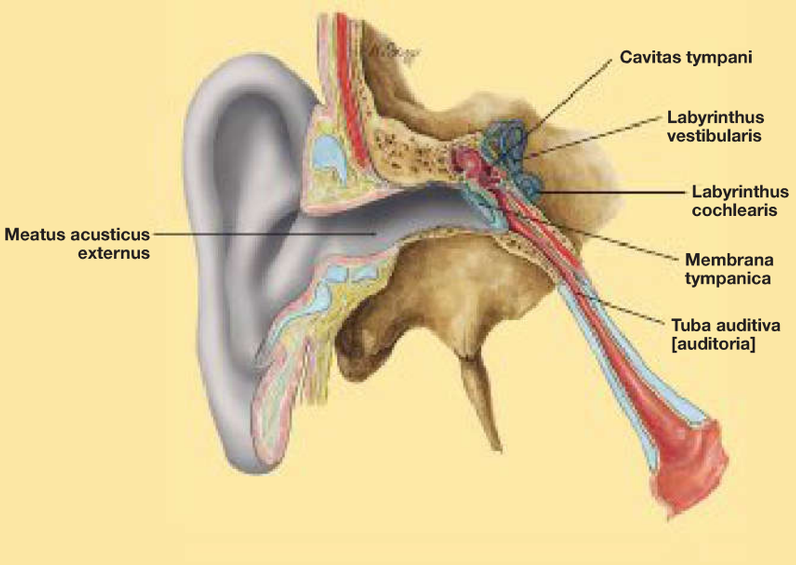

Overview

The ear is divided into the **outer ear, middle ear** and **inner ear.** Forming part of the outer ear are the **auricula** (Auricula pinna), the **ear canal** (Meatus acusticus externus) and the **eardrum** (Membrana tympanica). Behind the eardrum, located in the petrous part of the temporal bone (Pars petrosa ossis temporalis) and belonging to the middle ear, is the **tympanic cavity** (Cavitas tympani) with its **auditory ossicles: malleus, incus** and **stapes**. The tympanic cavity is connected via the auditory tube (Tuba auditiva, Tuba auditoria, EUSTACHIAN tube) to the nasopharynx and continues in adults via the mastoid antrum (Antrum mastoideum) into the ventilated areas of the mastoid process (Cellulae mastoideae). The auditory ossicles form a flexible chain for the transmission of sound waves conducted by the eardrum to the perilymph in the inner ear. The inner ear, which is also called the **labyrinth** and which, like the middle ear, is located in the petrous part of the temporal bone, contains the **organ for hearing and equilibrium** (Organum vestibulocochleare). The **cochlea** is the organ for hearing. It contains ducts filled with perilymph and endolymph and records the vibrations of the lymphs, carried there by the sound-conducting apparatus of the ear. The vestibular organ is made up of three **bony semicircular canals** (Canales semicirculares ossei), two antechamber vesicles (**Utriculus** and **Sacculus**) and the endolymphatic duct **(Ductus endolymphaticus).** The vestibular cells, situated in the Utriculus and the Sacculus, register changes in the head or body position in vertical or horizontal positions (linear acceleration). The sensory cells in the semicircular canals register rotational acceleration. The action potential arising in the perception areas of the hearing and equilibrium organ is relayed via the VIII. cranial nerve (N. vestibulocochlearis).

Main Topics

After studying this chapter, you should be able to:

- explain the anatomy of the outer ear, middle ear and inner ear and describe their content structures;
- clearly define the borders of the three regions, explain their proximity to neighbouring structures and put them into context with clinically relevant aspects;
- correctly describe the path and structure of the auditory tube, the muscles involved in the tube's function and the relationship to the middle ear;
- outline the functional context between tube ventilation, the tympanic cavity and the mastoid process cells;
- explain the neurovascular pathways in the Pars petrosa, including their course as well as the areas they supply and innervate;
- explain the development of the outer ear, middle ear and inner ear, including functional interrelations, and deduce developmental disorders based on that.

Clinical Relevance

In order not to lose reference to future everyday clinical life with so many anatomical details, the following describes a typical case that shows why the content of this chapter is so important.

Otitis media acuta

Case Study

The three-year-old Maximilian has to be picked up from the Kindergarten again soon after drop-off, because he has developed a fever and is touching his ear constantly. As the mother arrives, Maxi runs to her crying. The nursery teachers tell the mother that Maxi did not eat breakfast, kept asking to be held in their arms, cried spontaneously and constantly touched his ear. The mother is already familiar with this and presumes a middle ear infection, which Maxi has already had quite often. She therefore takes him directly from the childcare centre to the clinic.

Results of Examination

The nurse ascertains that Maxi has a temperature of 38.7 °C. The paediatrician asks how Maxi slept the night before, whether he has been snoring lately, breathing through his mouth or been hard of hearing. The mother states that Maxi slept well the previous night, but had actually snored. She could not say whether his hearing was worse. The mother points out that Maxi currently has a cold, with thick yellow nasal secretion, but considers that normal at his age. Looking into his mouth, the paediatrician notices a rugged, slightly red and enlarged pharyngeal tonsil; the oral cavity is otherwise normal. Examination of the right ear using the otoscope reveals a deep red tympanic membrane protruding into the external auditory canal (→ Fig. a).

Characteristic of an Otitis media acuta is a bulging and deep red tympanic membrane, as well as severe ear pain.

The left ear is without symptoms. When touching the cervical lymph nodes, the paediatrician can feel enlarged retroauricular lymph nodes. Pressure on Maxi's mastoid process does not elicit a pain response.

Diagnosis

Acute middle ear inflammation (Otitis media acuta)

Treatment

The paediatrician prescribes decongestant nasal drops and liquid ibuprofen for Maxi for pain relief and to lower the fever. The mother is to be generous with the nasal drops and apply them several times a day on both sides. Using an image of an ear, the paediatrician explains to the mother the connection between the nasopharynx, the auditory tube and the middle ear to clarify why Maxi must be given the nasal drops and over a period of several days. If the situation does not improve over the next two days or if it deteriorates, the mother is to present with Maxi again at the doctor's immediately or take him to A & E at the hospital. But the paediatrician expects that the condition will improve rapidly.

Further Developments

The liquid ibuprofen is effective as expected. Already shortly after taking it, Maxi appears significantly improved, the fever lessens, he begins to interact again, to play, and is almost back to his usual self. In the evening, Maxi once again develops a high fever, and the mother administers liquid ibuprofen again. She also administers the nasal drops regularly. Maxi is restless during the night, but has no fever. To be on the safe side, the mother administers liquid ibuprofen again the next morning. The following day, and on the days after that, the child is without symptoms. On the third day, the mother takes him back to the kindergarten and asks the nursery teachers to administer the nasal drops to Maxi before he takes a nap at midday. Maxi shows no symptoms in the kindergarten as well.

Dissection Lab

In the dissection lab, one should look at the entrance of the auditory tube behind the choanae in the nasopharynx, and, if possible, the open middle ear with the auditory ossicles.

Malleus, incus and stapes

In addition, the connection from the nasopharynx via the auditory tube to the middle ear can be seen clearly using anatomical models.

Back at the Clinic

The paediatrician diagnoses Otitis media acuta by Maximilian. She explains to the mother that this is a common condition in early childhood, since the middle ear structures are still small, and there is a risk of ventilation disorders in the ear, especially in the context of infections, which can then lead to an acute inflammation.

The auditory tube is still small and short in children. Hence a tube ventilation disorder can happen easily in the context of infections.

Such acute inflammations are to be distinguished from a chronic ventilation disorder of the middle ear caused by an enlargement of the pharyngeal tonsil (Tonsilla pharyngea).
Enlarged tonsils are also colloquially referred to as polyps, while Ear, Nose and Throat (ENT) specialists refer to them as adenoids or adenoid vegetation. Hereby the enlarged pharyngeal tonsil displaces the entrance of the auditory tube, in the worst case scenario on both sides. The pharyngeal tonsil enlarges to the extent that the child can no longer breathe through the nose, and breathes only through its mouth instead. Since skull growth has not yet been completed, the child also develops the 'facial expression of a mouth breather' (Facies adenoidea). Because the ventilation of the auditory tube is disrupted, the child cannot hear very well and has difficulty learning to speak as a result. They have difficulty concentrating and – if already of school age – fall behind at school. In these children, the hyperplastic pharyngeal tonsil has to be surgically removed in order to improve the situation. In addition, a tympanostomy tube is placed into a lower quadrant of the tympanic membrane, which ensures ventilation via the external auditory canal in the short term. The tympanostomy tube, provided it does not fall out of its own accord, has to be removed after some time.
Middle ear infections are always fraught with risk due to the topographical proximity to neighbouring structures.

The middle ear has six walls, through which a middle ear inflammation may spread to adjacent regions.

It can result in perforation of the tympanic membrane, inflammation of the mastoid process (mastoiditis), meningitis, brain abscess, thrombosis of the Sinus sigmoideus, spreading of germs into the A. carotis interna with subsequent sepsis, inflammation of the inner ear (labyrinthitis) or other complications.

Fig. a Right tympanic membrane in Otitis media acuta; viewed through the otoscope from the outside in via the external ear canal to the tympanic membrane, which is deep red and protruding. [G548]

Overview

Development

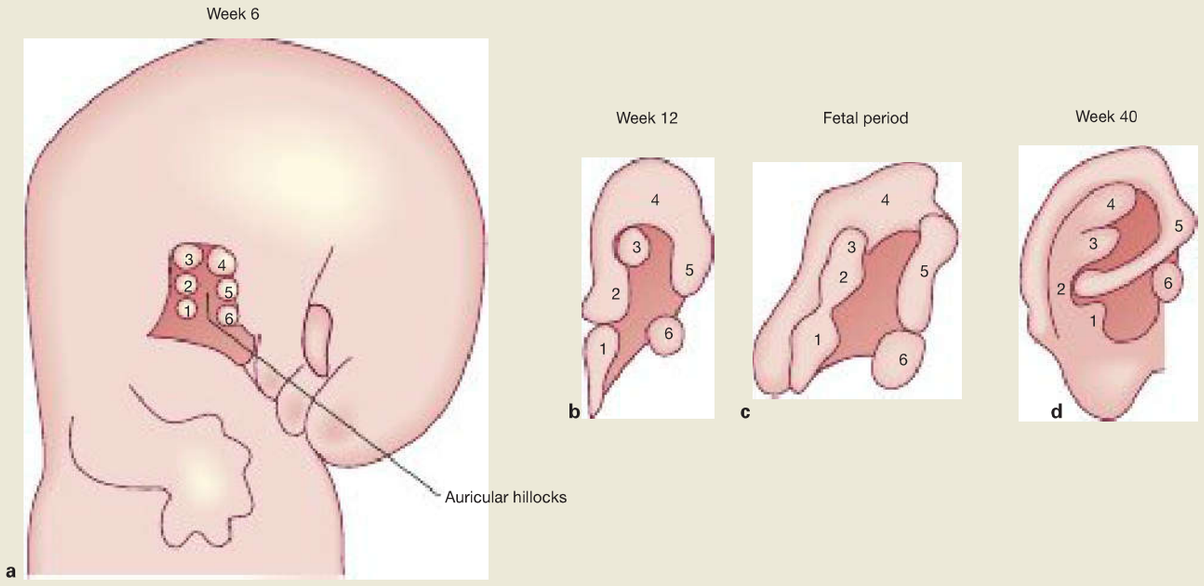

Fig. 10.1a to d Development of the outer ear from the six auricular hillocks, right side. [L131]
Merging of the auricular hillocks (1–6) is a complicated process and disorders in this development are therefore not rare. The primordial auricles originates in the lower region of the neck. As the lower jaw develops, there is a cranial shift so that the outer ears are ultimately positioned level with the eyes. Outer ears that are positioned lower than that are very commonly associated with other (often chromosomal) deformities. The external auditory canal develops from the posterior part of the first pharyngeal groove, which extends inwards as a cone-shaped tube, reaching the entodermal epithelial lining of the tympanic cavity (Recessus tubotympanicus). At the beginning of the ninth week, the epithelial cells of the acoustic floor proliferate and form an ear canal plate. This dissolves in the seventh month. A persistent plate in the external acoustic meatus results in hereditary deafness.

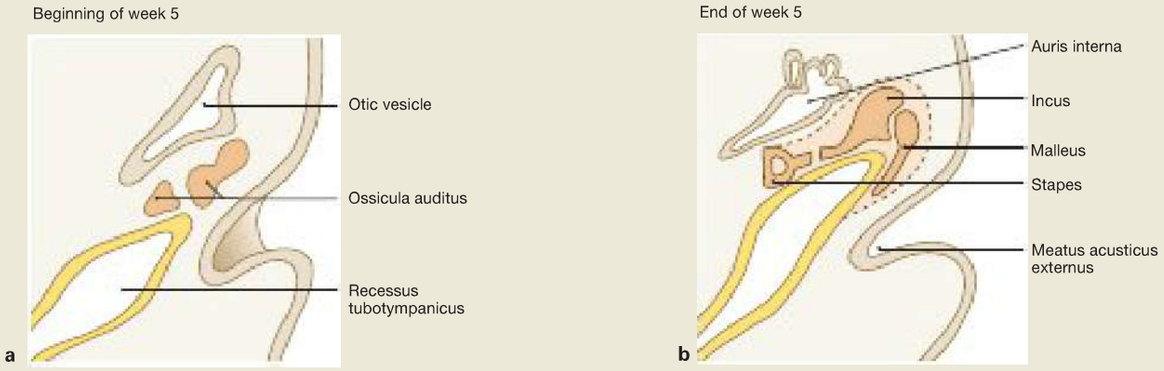

Fig. 10.2a and b Differentiation of the auditory ossicles, Ossicula auditus. [E838]
At the beginning of the fifth week, in the mesenchyme of the first and second pharyngeal arch, the auditory ossicles begin to emerge. The malleus and incus emerge from the first pharyngeal arch as derivatives of MECKEL's cartilage, as well as the M. tensor tympani, which is innervated by the first pharyngeal arch nerve, the N. mandibularis [V/3]. The stapes emerges from the second pharyngeal arch as a derivative of REICHERT's cartilage. It can be moved by the M. stapedius, which is innervated by the second pharyngeal arch nerve, the N. facialis [VII].

Ear Development

On approximately the 22nd day, the **surface ectoderm** on both sides of the rhombencephalon will thicken. These cellular condensations, termed **otic placode**, subsequently folds inward, forming an **otic pit** and then the **otic vesicle** (otocyst). Each vesicle is divided into a **ventral (rostral) section,** from which the saccule as well as the Ductus cochlearis emerge, and a **dorsal (occipital) section,** from which the Utriculus, semicircular canals and Ductus endolymphaticus emerge. The rostral and occipital parts remain connected via a small duct. The resulting structures are in their entirety referred to as **membranous labyrinth**.
The first pharyngeal groove and the first pharyngeal pouch grow towards each other. The external acoustic meatus is formed by the ectoderm of the first pharyngeal groove; the entoderm of the first pharyngeal pouch forms the **middle ear.** Proximally, the latter narrows to form the **auditory tube** (EUSTACHIAN tube). The latter has a very narrow connection with the part of the foregut, which will become the nasopharynx. Distally, the first pharyngeal pouch widens to form the **tympanic cavity.**
On the lateral tympanic cavity wall, the Recessus tubotympanicus is forming, which grows towards the advancing pharyngeal groove. At the point of contact, only a thin membrane remains – the **tympanic membrane.**
The **auditory ossicles** develop in the mesenchyme from the first and second pharyngeal arch at the beginning of the fifth week**.** On the outer edge of the first pharyngeal groove, **six auricular hillocks** form at the beginning of the sixth week, which merge in a complex way until birth to form the adult auricle.

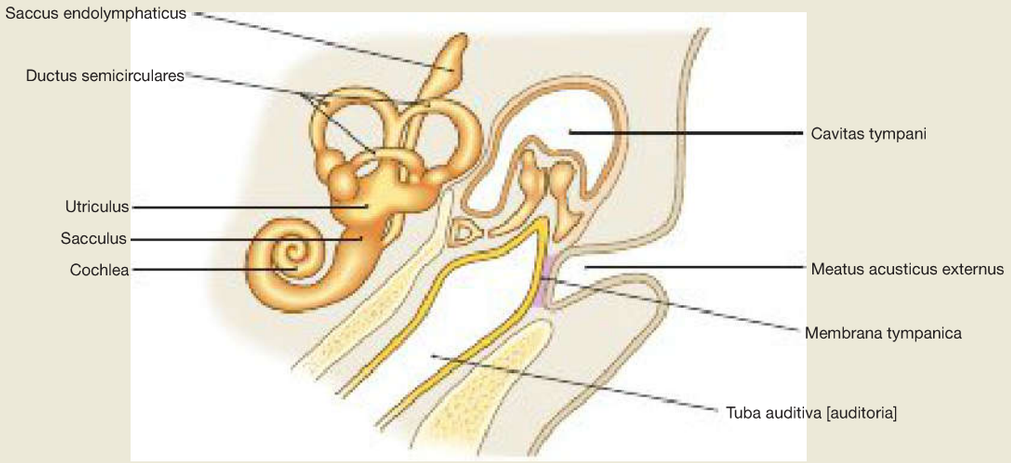

Fig. 10.3 Structures of the inner, middle and outer ear at birth. [E838]

Up to 8 months of pregnancy, the initially cartilaginous auditory ossicles are embedded in the mesenchyme. This gradually recedes and is replaced by an entodermal mucosal lining that covers the entire tympanic cavity.

Fig. 10.4 Child with preauricular skin adnexa. [E347-09]
Grade 1 auricular dysplasia.

Fig. 10.5 Child with diminished, rudimentary auricle (microtis). [E347-09]
Grade 2 auricular dysplasia. The auricle is diminished and severely malformed. Often this also affects the external acoustic meatus.

Clinical Remarks

Congenital deafness occurs in two out of every 1,000 newborns. In approximately one third, a genetic defect is the cause. Other causes include infections during pregnancy, chronic diseases in the mother, medication, alcohol and nicotine. An inability to hear places severe limits on language learning as well as structured thinking and communication. Early detection and subsequent therapy early on in life are therefore of immense importance. **External ear malformations** are common. They are divided into grades of dysplasia from 1 to 3 (→ Fig. 10.4 and → Fig. 10.5). A grade 3 dysplasia, for example, tends to include the genetically dominant FRANCESCHETTI's syndrome (mandibulofacialis dysostosis), which is characterised by malformation of the first pharyngeal arch and first pharyngeal groove, resulting in malformed external ears and zygomatic bone, a receding chin and cleft palate.

Overview

Outer, Middle and Inner Ear

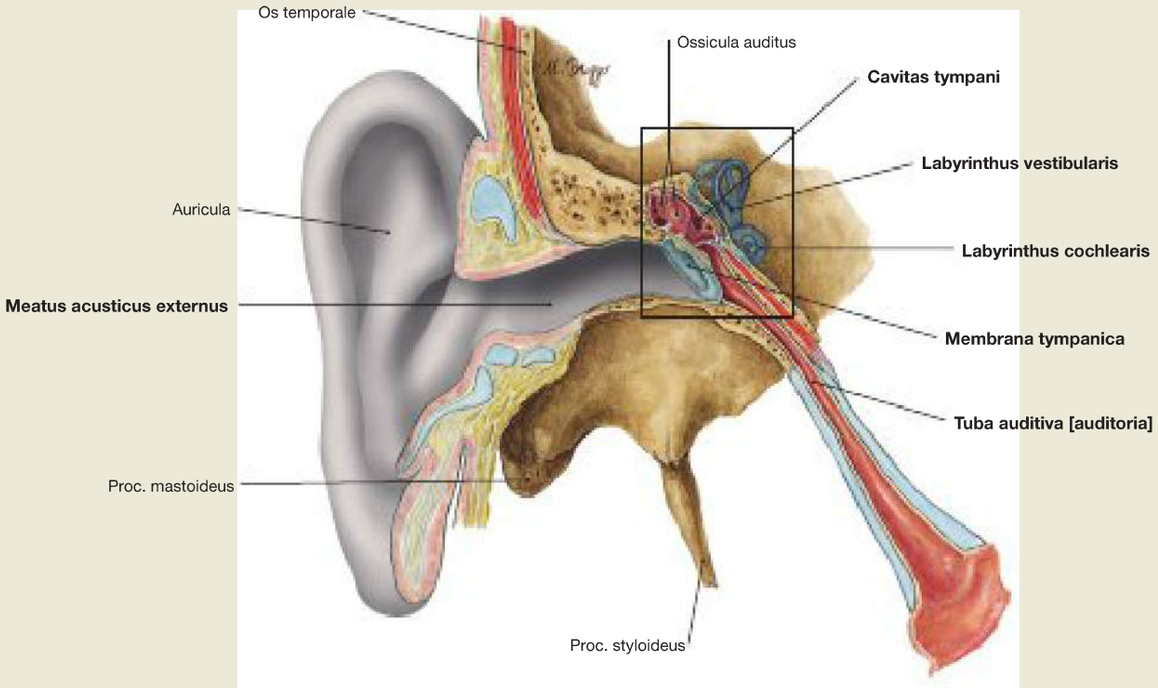

Fig. 10.6 Parts of the ear, Auris, right side; longitudinal section through external acoustic meatus, middle ear and auditory tube; frontal view.
Presentation of the auricle (Auricula), external auditory canal (Meatus acusticus externus), tympanic membrane (Membrana tympanica), tympanic cavity (Cavitas tympani), auditory ossicles (Ossicula auditus), auditory organ (Labyrinthus cochlearis) and vestibular organ (Labyrinthus vestibularis).
Sound waves cause the tympanic membrane to vibrate **(aerotympanal conduction).** The vibrations are carried up to the oval window of the inner ear by the auditory ossicles (→ Fig. 10.25). The low air impedance to the sound waves (acoustic impedance; → Fig. 10.17) by the air is modulated to the high impedance in the fluid-filled inner ear. Moreover, the inner ear can also utilise vibrations via the skull bones **(bone conduction).** Within the inner ear, sound energy continues to travel as a wave (migrating wave). The sensory cells of the inner ear transform the sound energy into an **electrical impulse** that is passed on to the brain via the N. cochlearis. The vestibular organ serves in the perception of rotational and linear accelerations. Movements of the endolymph in the vestibular organ result in a deflection of cilia of the sensory cells which are synaptically linked with afferent fibres of the N. vestibularis.

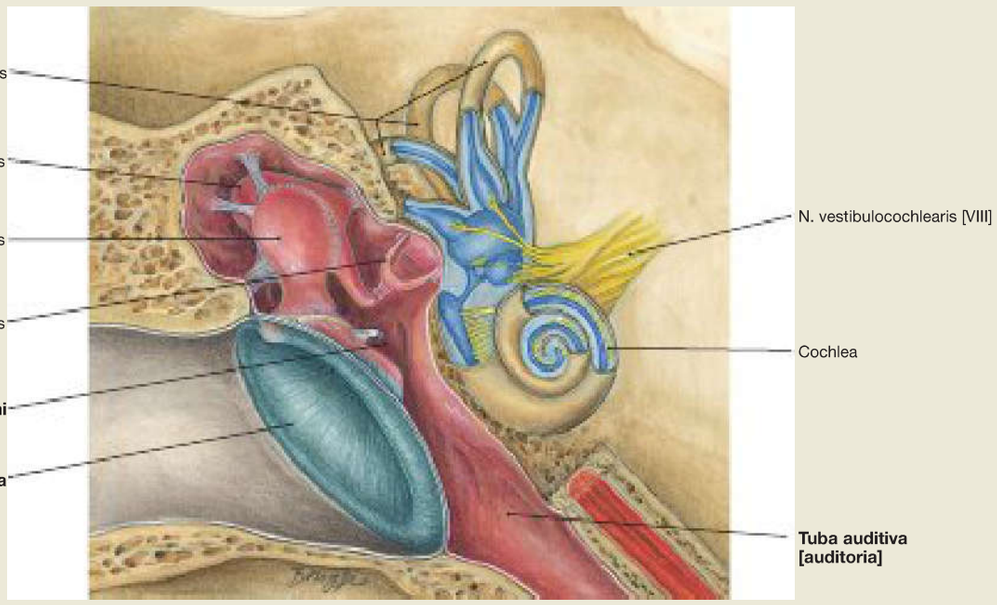

Fig. 10.7 Middle and inner ear, Auris media and interna, right side; enlarged section of → Fig. 10.6; frontal view.
Apart from the tympanic membrane, the three auditory ossicles are visible in the tympanic cavity (Cavitas tympani): hammer-shaped Malleus, anvil-shaped Incus and stirrup-like Stapes, as well as parts of the membranous labyrinth (Labyrinthus membranaceus, blue).

Clinical Remarks

It is not rare for injury or mechanical manipulation (e.g. cleaning the external auditory canal with a cotton swab) to result in an inflammation of the region of the auricle and the external acoustic meatus **(Otitis externa).**

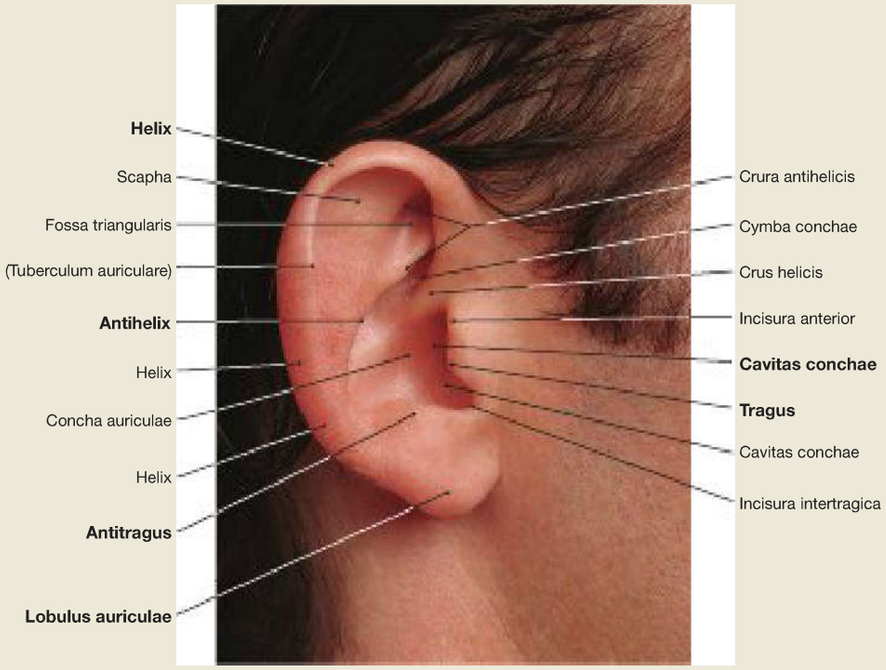

Fig. 10.8 Auricle, Auricula, right side; lateral view.
The basic framework of the auricle is made up of elastic cartilage. The skin across the lateral surface is attached to the perichondrium and cannot be moved; the skin on the back of the auricle is movable. There is no subcutaneous fat tissue. The earlobe (Lobulus auriculae) is non-cartilaginous.

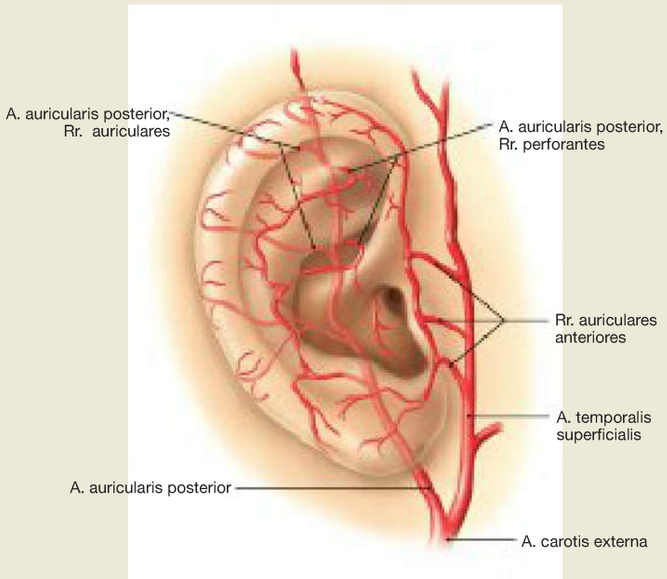

Fig. 10.9 Arteries of the auricle, Auricula, right side; lateral view. [L238]
Due to its exposed location, the auricle is highly vascularised (protection against freezing, suitable for heat convection). The vessels are **branches of the A. carotis externa** (A. auricularis posterior, A. temporalis superficialis).

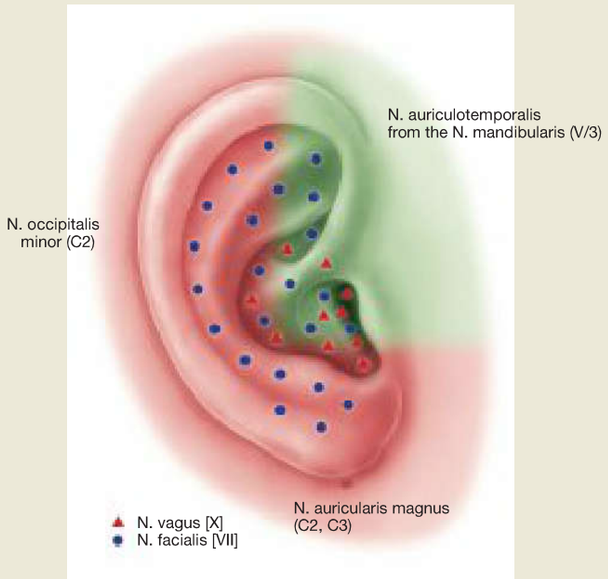

Fig. 10.10 Sensory innervation of the auricle, Auricula, right side; lateral view. [L238]
Innervation in front of the auricle is supplied by the **N. auriculotemporalis** (from the N. mandibularis [V/3]), behind and below the ear by the **Plexus cervicalis** (N. auricularis magnus, N. occipitalis minor), at the auricle itself by the **N. facialis** [VII] (it is not entirely clear which part exactly it supplies), and at the entrance to the external acoustic meatus by the **N. vagus** [X].

Ear Muscles and External Acoustic Meatus

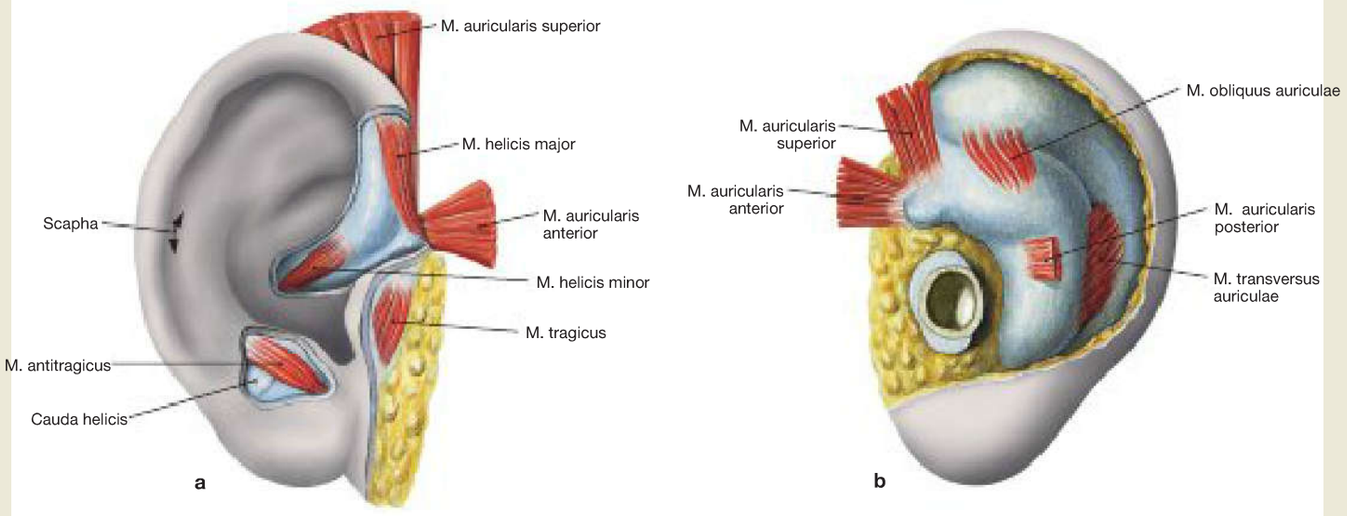

Fig. 10.11a and b Mm. auriculares and cartilage of the auricle, Auricula, right side.
a Lateral view
b Dorsal view
Quite often, rudimentary muscles are still attached to the auricle (some people can move their ears). These facial muscles (innervated by the N. auricularis posterior, a branch of the N. facialis [VII]) form part of a rudimentary sphincter system, and are still very well developed in many animals. Hence a horse, for example, turns his auricles towards the direction of sound. A hedgehog and a bear close their external acoustic meatus so as not to be disturbed by noise during hibernation.

→T 1b

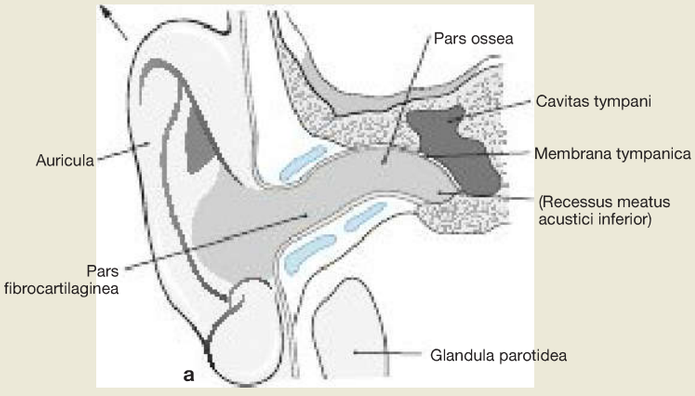

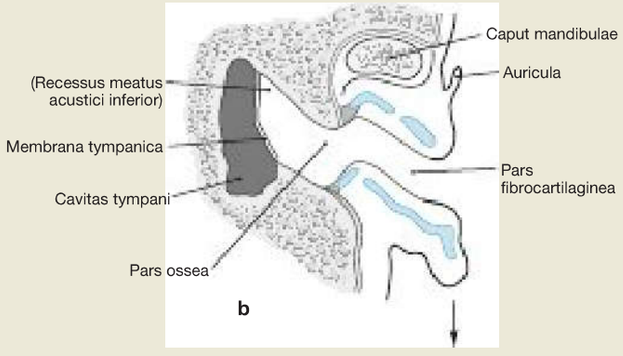

Fig. 10.12a and b External acoustic meatus, Meatus acusticus externus, right side; schematic drawing. [L126]
a Frontal section
b Horizontal section
The external acoustic meatus is S-shaped and is formed by the Pars tympanica of the Os temporale. In order to be able to inspect the tympanic membrane with an otoscopic mirror or a microscope (otoscopy), the auricle has to be pulled upwards and to the back. This stretches the cartilaginous part of the external acoustic meatus and the tympanic membrane can be seen (at least partially). **Innervation** of the external acoustic meatus (not shown) occurs via the N. meatus acustici externi of the N. auriculotemporalis (anterior and superior wall), the R. auricularis of the N. vagus [X] (posterior wall and part of inferior wall) and via the Rr. auriculares of the N. facialis [VII] and the N. glossopharyngeus [IX] (posterior wall and tympanic membrane).

Arrows: Direction the examiner pulled the auricle, to stretch the external acoustic meatus and gain a view of the tympanic membrane.

Clinical Remarks

- An inflammation of the elastic cartilage **(auricular perichondritis)** may occur as a result of injuries or insect stings to the auricle. Treatment includes topical application of disinfecting agents as well as local and systemic application of glucocorticoids and antibiotics.
- Since the earlobe is well supplied with blood, is very easily accessible and has no elastic cartilage, it is often used for the taking of a blood sample, e.g. in diabetic patients to measure blood glucose levels.
- Abnormalities of the auricle often require plastic-reconstructive surgery.
- Due to the sensory innervation of the external acoustic meatus by the N. vagus [X], manipulations in the external acoustic meatus (e.g. the removal of cerumen or foreign objects) regularly initiates a cough reflex in the respective person. In severe cases the manipulation can cause vomiting or a collapse.

Tympanic Membrane

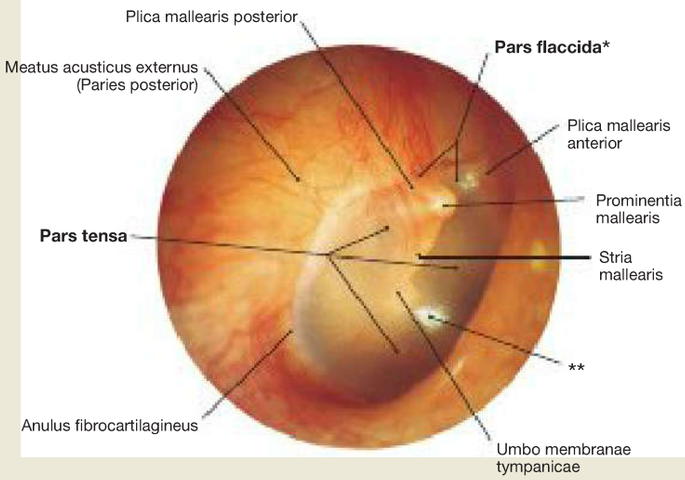

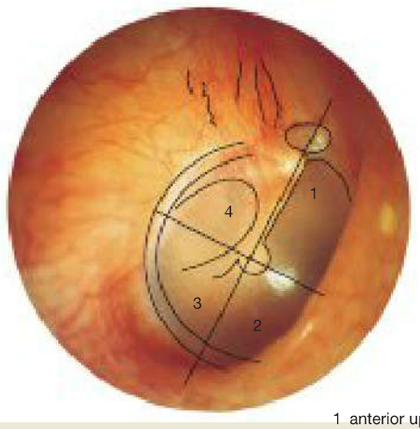

1 anterior upper quadrant
2 anterior lower quadrant
3 posterior lower quadrant
4 posterior upper quadrant

Fig. 10.13 Tympanic membrane, Membrana tympanica, right side; lateral view; otoscopic image.
The Pars tympanica of the Os temporale separates the anterior, inferior and posterior aspects of the Meatus acusticus externus. In its superior aspect, the bony ring is interrupted by the Incisura tympanica (attachment site of the Pars flaccida of the tympanic membrane). With the exception of the Incisura tympanica, the otherwise circular Sulcus tympanicus is located within the Pars tympanica (the Pars tensa of the tympanic membrane is attached here by an Anulus fibrocartilagineus).

* clinical term: SHRAPNELL's membrane
** typically positioned light reflex

Fig. 10.14 Tympanic membrane, Membrana tympanica, right side, with division into four quadrants; lateral view.
When illuminating the tympanic membrane with its shiny, pearl appearance, a triangular light reflex in the anterior lower quadrant is usually produced, which allows for conclusions on the tension of tympanic membrane.

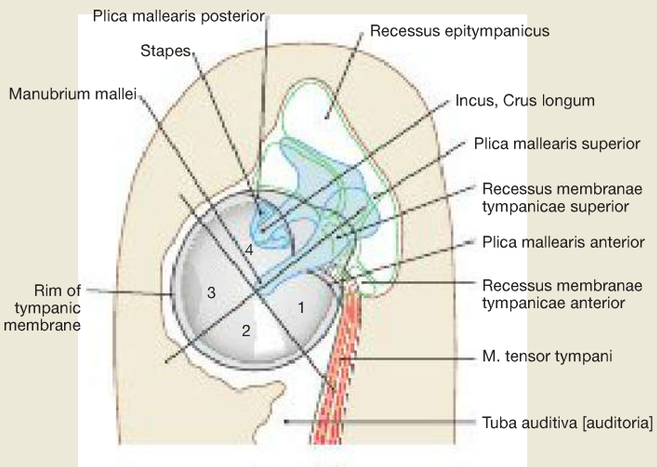

Fig. 10.15 Tympanic membrane, Membrana tympanica and the recessus of the tympanic cavity, Cavitas tympani, right side, with quadrante scheme; lateral view; schematic diagram. [L126]
The quadrante scheme is of practical clinical relevance. The auditory ossicles are located in the upper quadrants. In addition, the Chorda tympani and the attaching tendon of the M. tensor tympani are positioned here (→ Fig. 12.151).

Fig. 10.16 Tympanostomy tube in the anterior lower quadrant. [T720]
To avoid injury of structures of the middle ear, a paracentesis (small surgical incision of the tympanic membrane) is performed in the anterior lower or posterior lower quadrant. For ventilation over a longer period of time, a tympanostomy tube (grommet) is inserted through the incision.

* tympanostomy tube

Clinical Remarks

The Pars flaccida of the tympanic membrane is thinner than the Pars tensa and therefore the preferred location for a **purulent middle ear infection** (Otitis media) for a spontaneous perforation. Tympanic cavity effluent can be seen and drained through the tympanic membrane. Tympanostomy tubes (grommet, myringotomy tube) are inserted for drainage and ventilation over a longer period of time (→ Fig. 10.16). Excessive production of cerumen (earwax) often results in a ceruminal plug that may close the external acoustic meatus **(Cerumen obturans)** and lead to conductive hearing loss. The bitter substances in the cerumen normally serve to keep microorganisms and insects (flies, small beetles, etc.) away.

Auditory Ossicles

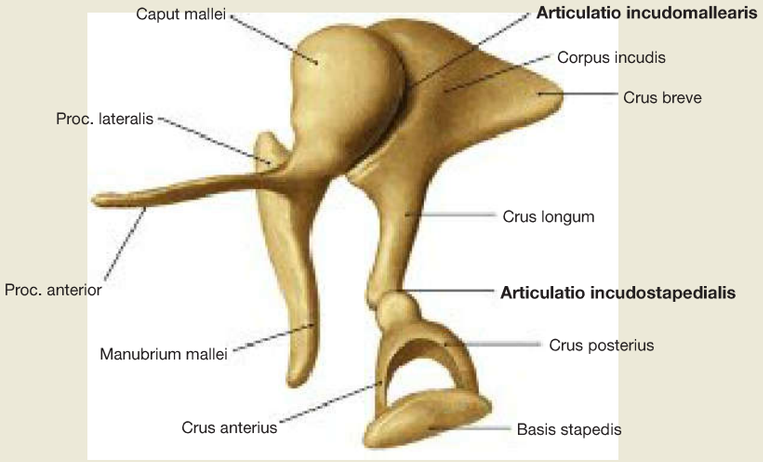

Fig. 10.17 Auditory ossicles, Ossicula auditus, right side; medial view from above.
The auditory bones of the auditory ossicular chain are connected in a series and linked by true joints (Art. incudomallearis – a saddle joint – and Art. incudostapedialis – a spheroidal joint). The auditory ossicles form a flexible chain for the transmission of sound waves conducted by the tympanic membrane to the perilymph of the inner ear. Low air impedance has to be transferred to the significantly higher inner ear air impedance. This requires an amplification of the sound waves (impedance matching), which is achieved by the difference in size of the area of the tympanic membrane (55 mm^2) to the area of the oval window (3.2 mm^2; 17-fold) and the lever action of the auditory ossicle chain (1.3-fold). Thus, the acoustic pressure amplifies by 22-fold.

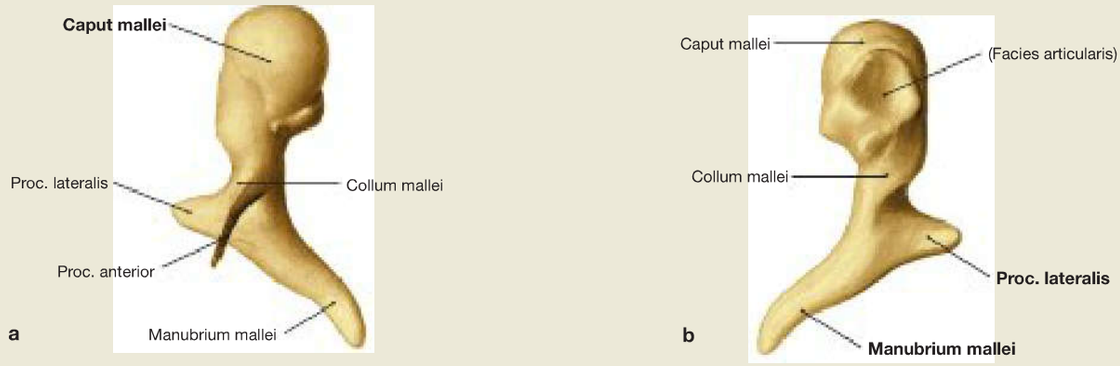

Fig. 10.18a and b Malleus, right side; frontal view **(a),** posterior view **(b).**

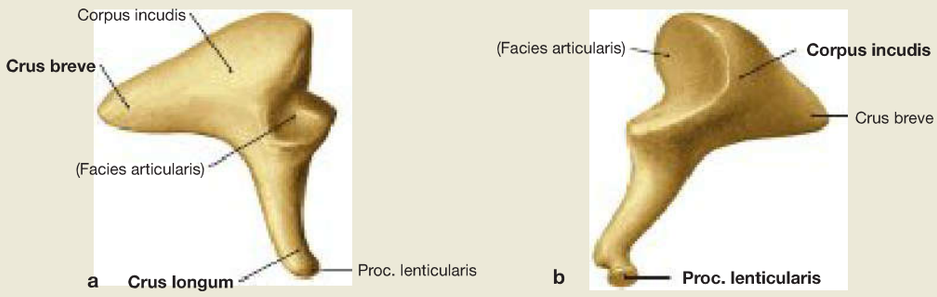

Fig. 10.19a and b Incus, right side; lateral view **(a),** medial view **(b).**

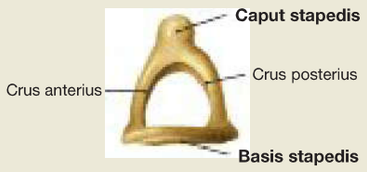

Fig. 10.20 Stapes, right side; superior view.

Clinical Remarks

Defects in the chain of transmission (tympanic membrane, auditory ossicles) result in **conductive hearing loss.** In the event of a complete loss of acoustic pressure transmission, a hearing loss of approximately 20 dB sets in. A typical disorder that leads to such a hearing loss is **otosclerosis.** This is a localised disorder of the petrous part of the temporal bone. The base of the stapes progressively fixes to the oval window through ossification of the Lig. anulare stapediale causing slowly increasing conductive hearing loss sets in. Inflammatory foci in the area of the cochlea may also cause inner ear hearing loss. Women aged 20–40 years are affected twice as often as men. In 70% of cases, otosclerosis affects both ears.

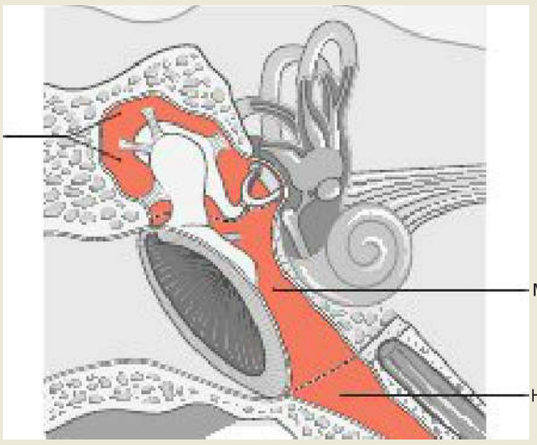

Fig. 10.21 Levels of the tympanic cavity, Cavitas tympani, right side; frontal view. [L126]
From a clinical perspective, the tympanic cavity is divided into three sections in relation to the position of its sections regarding the tympanic membrane:

- The **epitympanum** (Recessus epitympanicus, epitympanic recess, attic) contains the suspension apparatus and the majority of auditory ossicles and is connected to the Antrum mastoideum via the mastoid cells.
- The **mesotympanum** contains the Manubrium mallei, the Proc. lenticularis of the Incus, and the tendon of the M. tensor tympani.
- The **hypotympanum** leads into the Tuba auditiva [auditoria] via the Recessus hypotympanicus.

The boundaries between the three sections are defined by dashed lines.

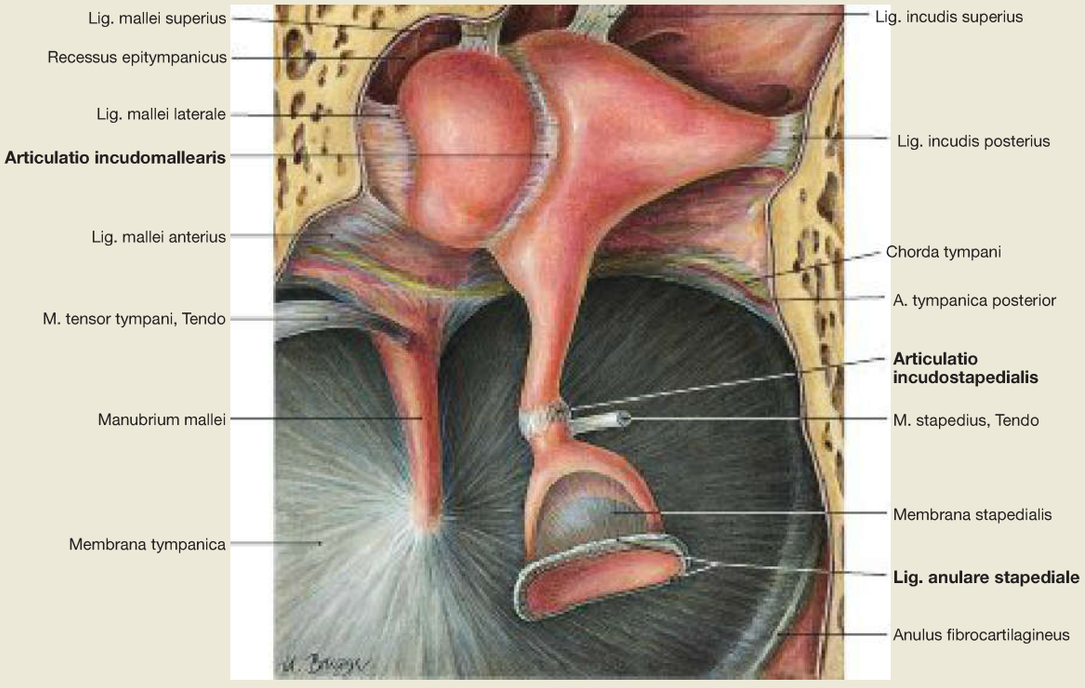

Fig. 10.22 Joints and ligaments of the auditory ossicles, Articulationes and Ligg. ossiculorum auditus, right side; medial view from above.
The malleus and incus are secured via ligaments in the epitympanum and are flexibly interconnected via the saddle joint (Art. incudomallearis). The stapes is in contact with the incus via the spheroidal joint (Art. incudostapedialis). Its base (Basis stapedis) is attached in the oval window (syndesmosis) by the Lig. anulare stapediale. All structures in the tympanic cavity, including the Chorda tympani, are lined with mucosa of the middle ear.

Clinical Remarks

In childhood, one of the most common causes of conductive hearing loss is an occlusion of the Tuba auditiva **(tube occlusion)** because of an inflammation of the tube (tube catarrh) or in cases of restricted nasal breathing due to enlarged pharyngeal tonsils **(adenoids).** If the tube function disorder persists over a longer period of time, restructuring of the mucosa of the middle ear takes place. As a result, an actively secreting epithelium develops, with fluid retention formation in the tympanic cavity **(seromukotympanon).**

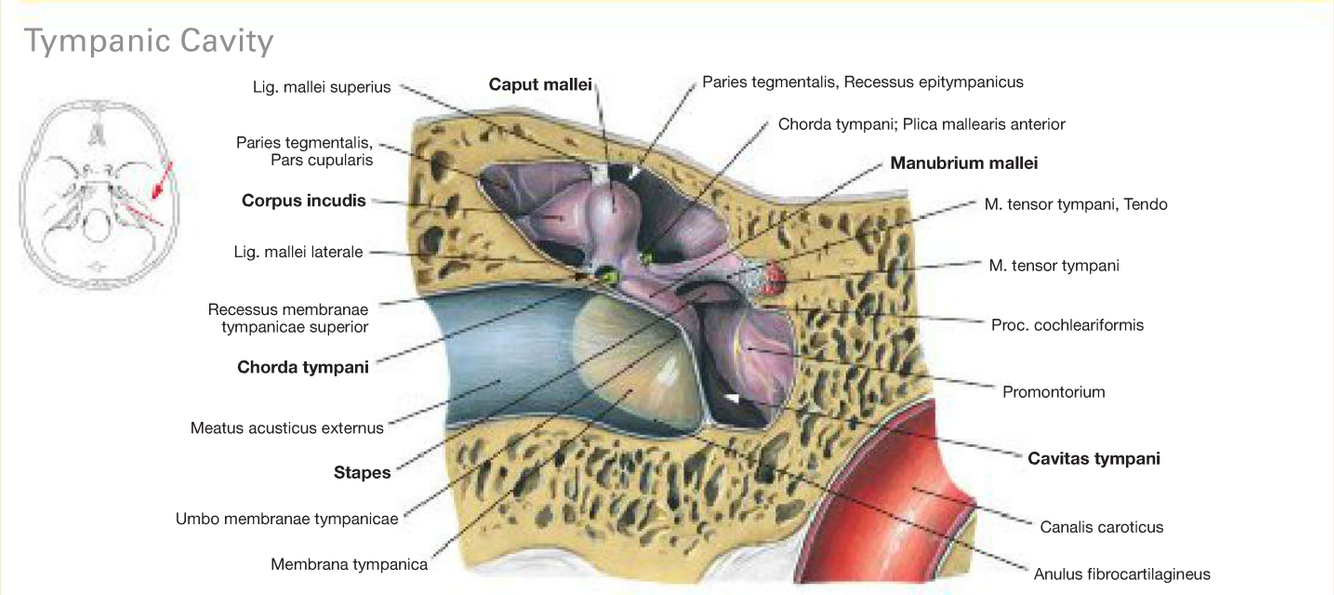

Fig. 10.23 Tympanic cavity, Cavitas tympani, right side; frontal section; frontal view.
The tympanic cavity is an air-filled hollow space inside the middle ear containing the auditory ossicles. It is located directly behind the tympanic membrane and is ventilated via the Tuba auditiva [auditoria] (EUSTACHIAN tube), aiding pressure equalisation. The distance between the epitympanum and the hypotympanum is 12–15 mm at a depth of 3–7 mm. The inner volume is only about 1 cm^3.

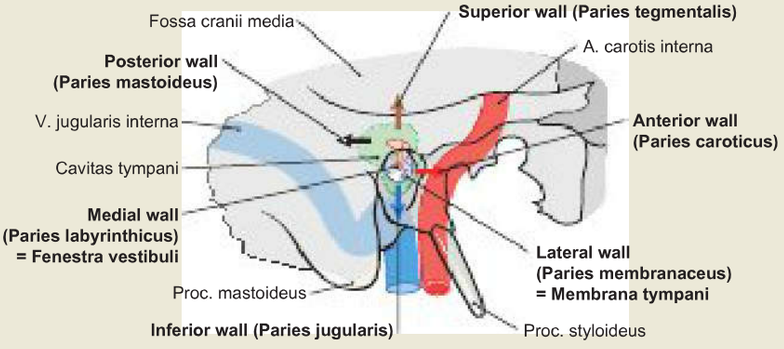

Tympanic Cavity (Cavitas tympani)	
mastoid process (Paries mastoideus)	posterior wall (Proc. mastoideus)
V. jugularis (Paries jugularis)	inferior wall (Fossa jugularis)
A. carotis interna (Paries caroticus)	anterior wall (carotid canal)
middle cranial fossa (Paries tegmentalis)	superior wall (middle cranial fossa)
oval window (Paries labyrinthicus)	medial wall (labyrinth)
tympanic membrane (Paries membranaceus)	lateral wall (tympanic membrane)

Fig. 10.24 Topographical relationships between the tympanic cavity, Cavitas tympani to adjacent structures, right side; lateral view; schematic drawing. [L126]
A thin bony plate (Tegmen tympani, **Paries tegmentalis**) separates the epitympanum from the middle cranial fossa. The anterior wall of the mesotympanum **(Paries caroticus)** is in close proximity to the A. carotis interna. The lateral wall **(Paries membranaceus)** is formed almost exclusively by the tympanic membrane. The Tuba auditiva [auditoria] opens into the tympanic cavity in the inferior wall section. The posterior wall **(Paries mastoideus)** is adjacent to the mastoid process (Proc. mastoideus). In the upper posterior section, a direct connection exists to the pneumatised areas of the mastoid (Aditus ad antrum). The medial wall **(Paries labyrinthicus;** → Fig. 10.25 and → Fig. 10.27) separates the Cochlea from the tympanic cavity. The inferior wall of the tympanic cavity **(Paries jugularis)** forms part of the hypotympanum. It separates the tympanic cavity from the V. jugularis interna. The bone is very thin at that section and partially pneumatised.

Clinical Remarks

An acute middle ear infection **(Otitis media)** is one of the most common illnesses in childhood. It is commonly caused by bacteria and viruses entering the middle ear through the Tuba auditiva [auditoria] during or after an infection of the nasopharynx. The inflammation is characterised by a reddening of the mucous linings, oedema, granulocytic infiltration and formation of pus. Since the suppuration cannot exit via the inflamed and therefore blocked tubes, the inflammation can spread to the surrounding area and cause severe **complications,** such as, e. g.:

- rupturing of the tympanic membrane (most common; via Paries membranaceus)
- mastoiditis (via Paries mastoideus, Antrum mastoideum)
- thrombophlebitis and thrombosis of the V. jugularis (via Paries jugularis)
- sepsis (bacteria spreading into the blood via Paries caroticus)
- brain abscess and/or meningitis (via Paries tegmentalis)
- labyrinthitis (with vertigo and hearing impairment via Paries labyrinthicus)

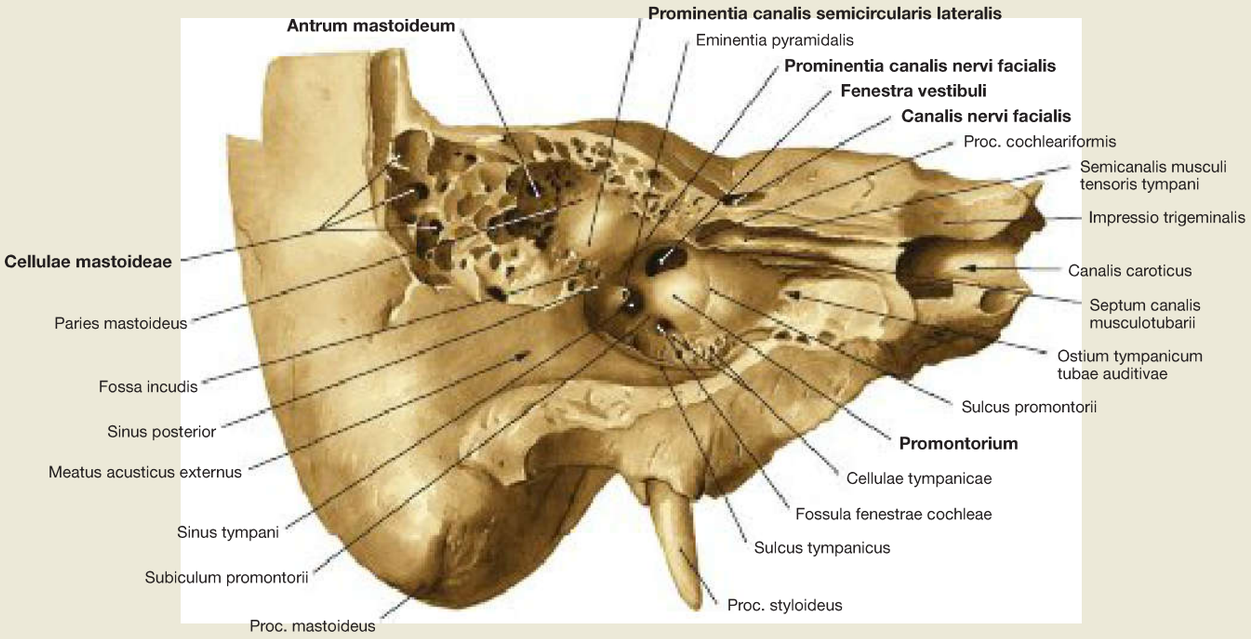

Fig. 10.25 Medial wall, Paries labyrinthicus, of the tympanic cavity, Cavitas tympani, right side; vertical section through the longitudinal axis of the petrous part of the temporal bone; frontolateral view.
Above the oval window, the lateral semicircular canal bulges out the wall of the tympanic cavity from the Prominentia canalis semicircularis lateralis. The N. facialis [VII] passes through the medial wall in the Canalis nervi facialis. The canal creates the horizontal Prominentia canalis nervi facialis in the medial wall. The Tuba auditiva [auditoria] initiates at the Ostium tympanicum tubae auditivae and is demarcated at the top by the Septum canalis musculotubarii from the Semicanalis musculi tensoris tympani. The mastoid process (Proc. mastoideus) is typically pneumatised (Cellulae mastoideae) and is connected to the tympanic cavity via the Antrum mastoideum.

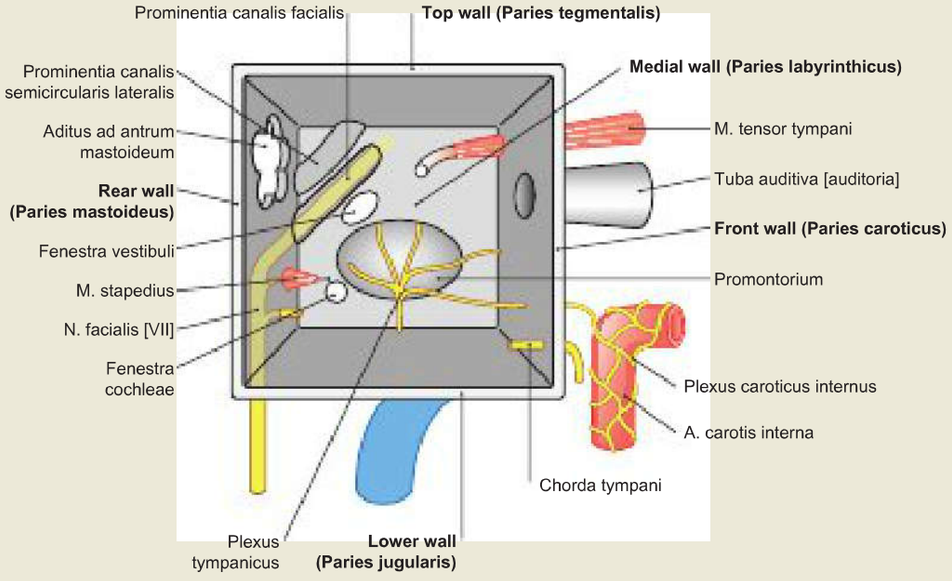

Fig. 10.26 Medial wall, Paries labyrinthicus, of the tympanic cavity, Cavitas tympani, right side; anterolateral view, schematic drawing. [L126]
The illustration presents the tympanic cavity as a rectangular box with six walls, wherein the lateral wall in which the tympanic membrane would be positioned has been omitted. The illustration serves as a basic orientation, facilitating navigation of the anatomical images (→ Fig. 10.25 and → Fig. 10.27) as well as the structures positioned in or passing through the bone.

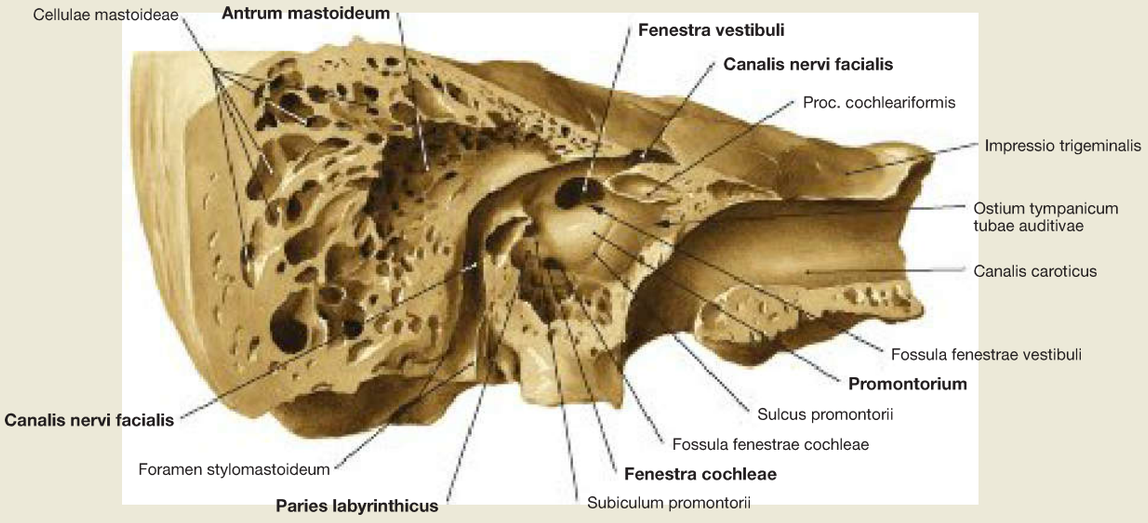

Fig. 10.27 Medial wall, Paries labyrinthicus, of the tympanic cavity, Cavitas tympani, right side; anterolateral view; after removal of the lateral wall and the adjacent parts of the anterior and superior wall; Canalis nervi facialis and Canalis caroticus opened.
The medial wall of the tympanic cavity forms the boundary to the inner ear (labyrinth). It has two openings:

- the **oval window** (Fenestra vestibuli), in which the base of stapes (Basis stapedis) is attached to the Lig. anulare stapediale
- the **round window** (Fenestra cochleae), located more inferiorly, occluded by the Membrana tympanica secundaria

Between the oval and the round window, the basal cochlear turn creates a prominent bulge in the medial wall of the tympanic cavity named the Promontorium.

Clinical Remarks

An inflammation of the Cellulae mastoideae **(mastoiditis)** is often an inflammatory process in the tympanic cavity. It is one of the most frequent complications of a middle ear inflammation (Otitis media). The inflammation can spread from the mastoid to the soft tissue parts behind and in front of the outer ear, the M. sternocleidomastoideus, the inner ear, the Sinus sigmoideus, the meninges, and the N. facialis [VII].

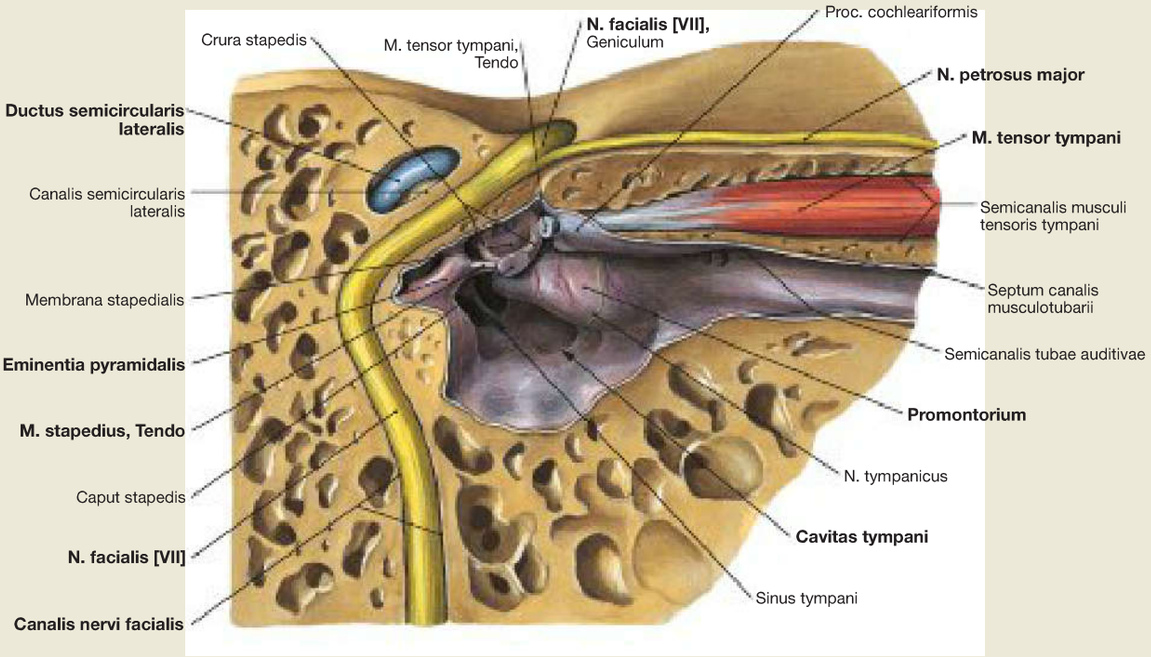

Fig. 10.28 N. facialis [VII], tympanic cavity, Cavitas tympani and Tuba auditiva [auditoria], right side; vertical section of longitudinal axis of petrous part of the temporal bone; frontal view; facial canal opened. The N. facialis [VII] is composed of two branches, the actual N. facialis and the N. intermedius. Both branches combine deep in the facial canal (Canalis nervi facialis) to form the N. intermediofacialis (henceforth referred to as N. facialis [VII]). It arched around the tympanic cavity and generates the Prominentia canalis nervi facialis in the medial wall of the tympanic cavity. The Eminentia pyramidalis protrudes underneath. Located inside is the N. facialis [VII] which innervates the M. stapedius (→ Fig. 12.156). Its tendon exits from the Eminentia pyramidalis and inserts inferior laterally at the small stapedial head.
Function of the M. stapedius: attenuation of vibrations at the oval window by tilting of the stapes, decreasing of acoustic transmission, protection against excessive noises.

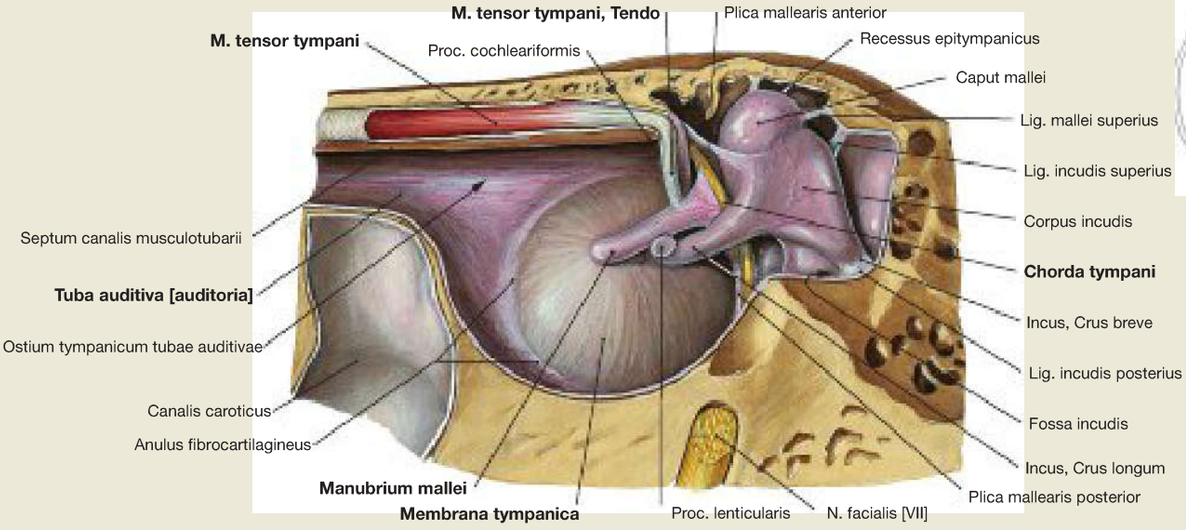

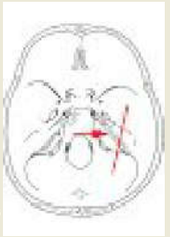

Fig. 10.29 Lateral wall, Paries membranaceus, of the tympanic cavity, Cavitas tympani, right side; medial view.
The Canalis musculotubarius enters the tympanic cavity from the front. It contains two bony semicanals (Semicanales) that are separated by a bony septum. The M. tensor tympani and the Tuba auditiva [auditoria] run inside it. The tendon of the M. tensor tympani make a right angle at the Processus cochleariformis and proceeds towards the Manubrium mallei.

Function of the M. tensor tympani: increasing the tension of the tympanic membrane by pulling on the Manubrium mallei. This results in stiffening the chain of auditory ossicles for improved transfer of high frequency sound waves. Shortly before the end of the Canalis nervi facialis, the Chorda tympani leaves the N. facialis [VII], runs backwards through its bony canal into the tympanic cavity, embedded in mucosa, courses through the center of the tympanic cavity between the malleus and the Crus longum of the incus. The Chorda tympani exits the cranial base via the Fissura sphenopetrosa (or the Fissura petrotympanica).

Clinical Remarks

Paralysis of the N. stapedius in case of facial paralysis alters the sensory innervation. Normal sounds are perceived as uncomfortably loud **(hyperacusis),** because of insufficient dampening action of M. stapedius (no tilting of the base of the base of stapes in the oval window).

Tympanic Cavity and N. facialis [VII]

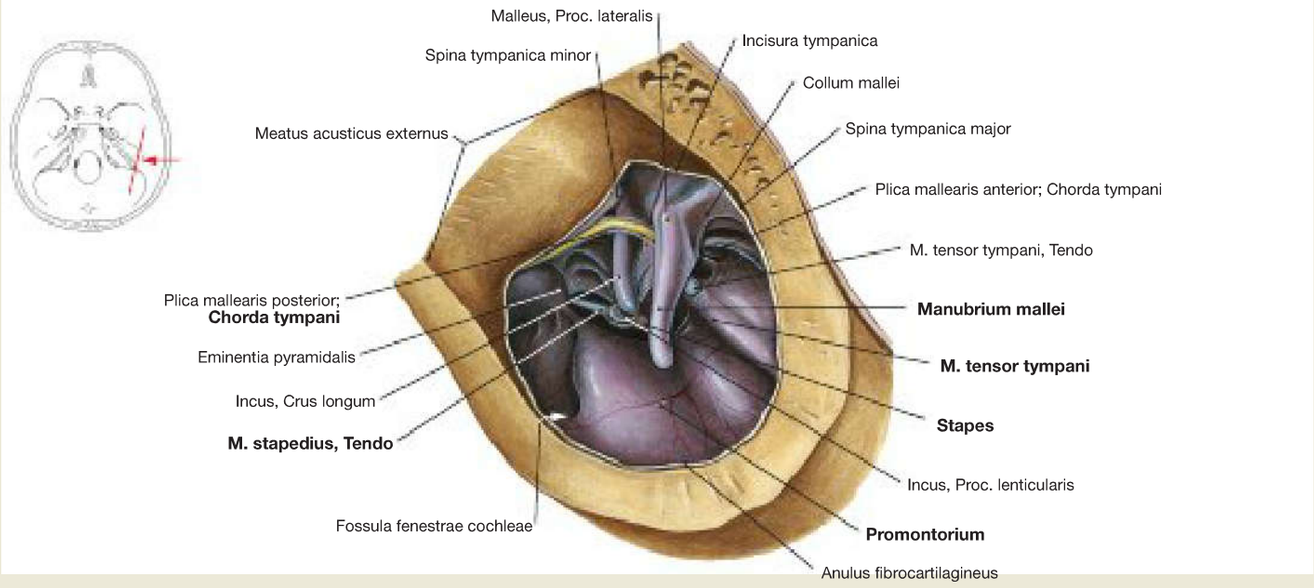

Fig. 10.30 Tympanic cavity, Cavitas tympani, right side; lateral view; after removal of tympanic membrane and mucous layer around the Chorda tympani.

View of the mucous-covered structures in the tympanic cavity.

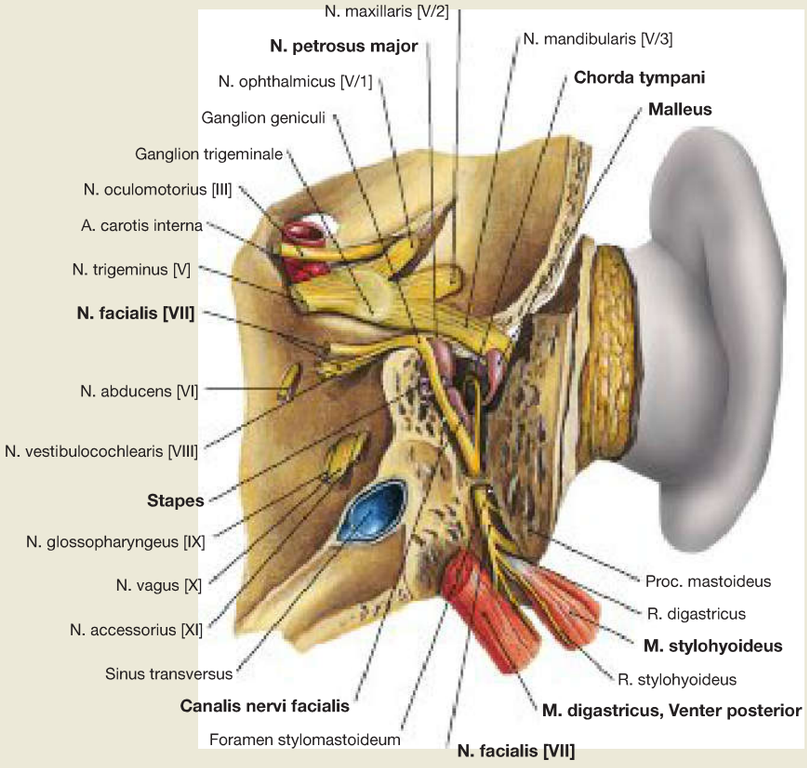

Fig. 10.31 N. facialis [VII] in the petrous part of the temporal bone, Os temporale, Pars petrosa, right side; posterior view; petrous bone partially removed; facial canal and tympanic cavity opened.

After removal of the Proc. mastoideus and opening of the facial canal and the tympanic cavity, the entire course of the N. facialis [VII] with its branches in the bony canal becomes visible (→ Fig.12.148).

Clinical Remarks

Lesions of the N. facialis [VII] can be associated with fractures of the petrous bone and inflammations of the middle ear or mastoid process, as well as with surgical interventions because of these conditions. Various testing methods are used in **facial nerve diagnostics** (e.g. at what level is the injury?) and in follow-up monitoring of facial paralysis: SCHIRMER's test (lacrimal gland function), stapedius reflex test, taste perception test and sometimes also sialometry (measurement of salivary gland function) to check the Chorda tympani, as well as electromyography (EMG) and electroneurography (ENoG) to test facial muscle function.

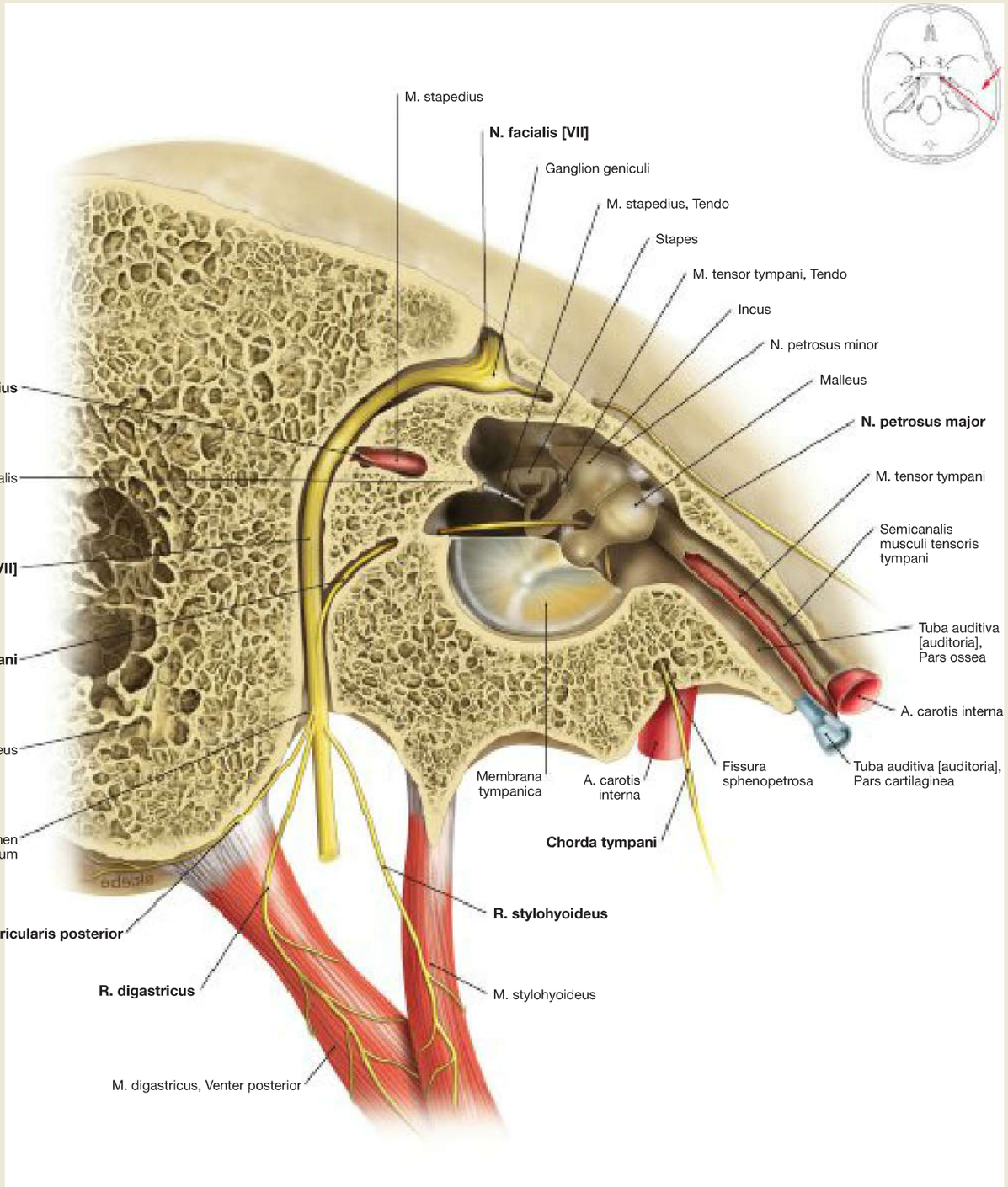

Fig. 10.32 N. facialis [VII], right side; lateral view. [L238]
Presentation of the N. facialis [VII] passing through the petrous bone, up to shortly after exiting the Foramen stylomastoideum (cut off after that). Within the bony facial canal, the **N. stapedius** diverges to innervate the M. stapedius, and the **Chorda tympani**, which regresses into the tympanic cavity and passes almost 'free' within a mucosal fold between the malleus and the incus through the tympanic cavity to the Fissura sphenopetrosa, where it exits the tympanic cavity again.

Clinical Remarks

The course of the Chorda tympani renders it susceptible to injury in surgery conducted on the middle ear. An isolated functional **loss of the Chorda tympani**, with associated dry mouth and loss of taste sensation on the affected side, is common in middle ear inflammations.

N. facialis [VII], Topography

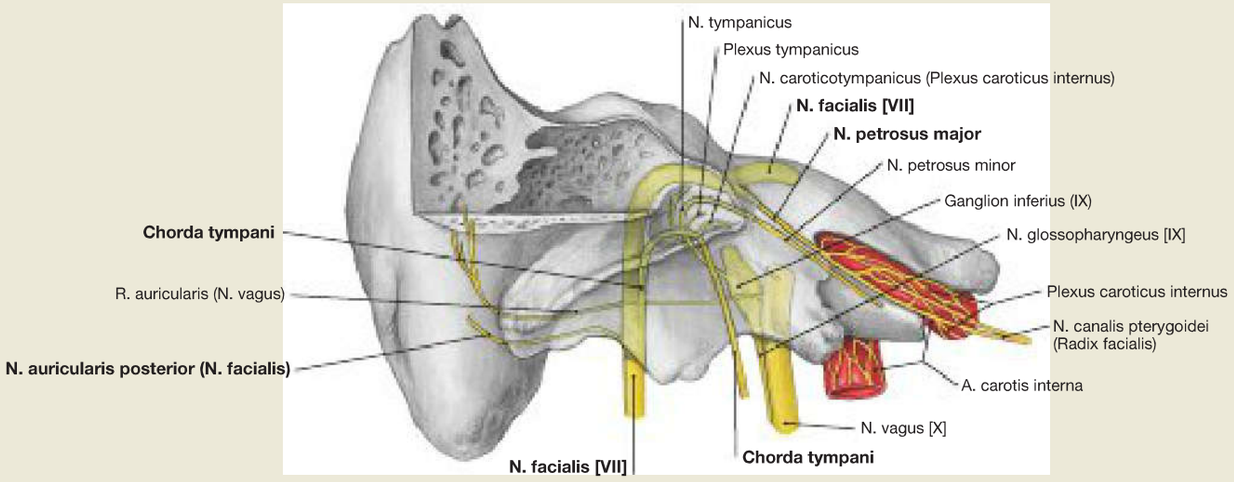

Fig. 10.33 N. facialis [VII], N. glossopharyngeus [IX] and N. vagus [X], right side; frontal view; petrous bone partially removed; nerves shown as transparent.

At the Ganglion geniculi, the first branch of the N. facialis [VII] is the **N. petrosus major**. In the Os temporale it passes frontomedially and exits at the Hiatus nervi petrosi majoris below the Dura mater on the Facies anterior of the Pars petrosa ossis temporalis. The nerve provides preganglionic parasympathetic fibres to the Ganglion pterygopalatinum for the innervation of lacrimal and nasal glands. Shortly after passing through the Foramen stylomastoideum the N. facialis [VII] releases the **N. auricularis posterior** for innervation the ear muscles. Also shown are the R. auricularis of the N. vagus [X] for sensory innervation of the external acoustic meatus as well as the **N. tympanicus** just before it branches off the N. glossopharyngeus [IX] shortly before this cranial nerve passes through the Foramen jugulare. It subsequently proceeds jointly with the A. tympanica inferior through the Canaliculus tympanicus to the tympanic cavity, where it divides into many branches inside the mucosa of the Promontorium (→ Fig. 10.27) and together with branches from the A. carotis interna that surround the sympathetic network (Plexus caroticus internus, Nn. caroticotympanici), forms the Plexus tympanicus. The Plexus tympanicus innervate the entire mucosa of the middle ear, including the mucosa of the Tuba auditiva [auditoria] and the mastoid. The parasympathetic portions of the N. tympanicus transverse the Plexus tympanicus and join up again as the N. petrosus minor. Together the N. petrosus minor and the N. tympanicus form the JACOBSON's anastomosis.

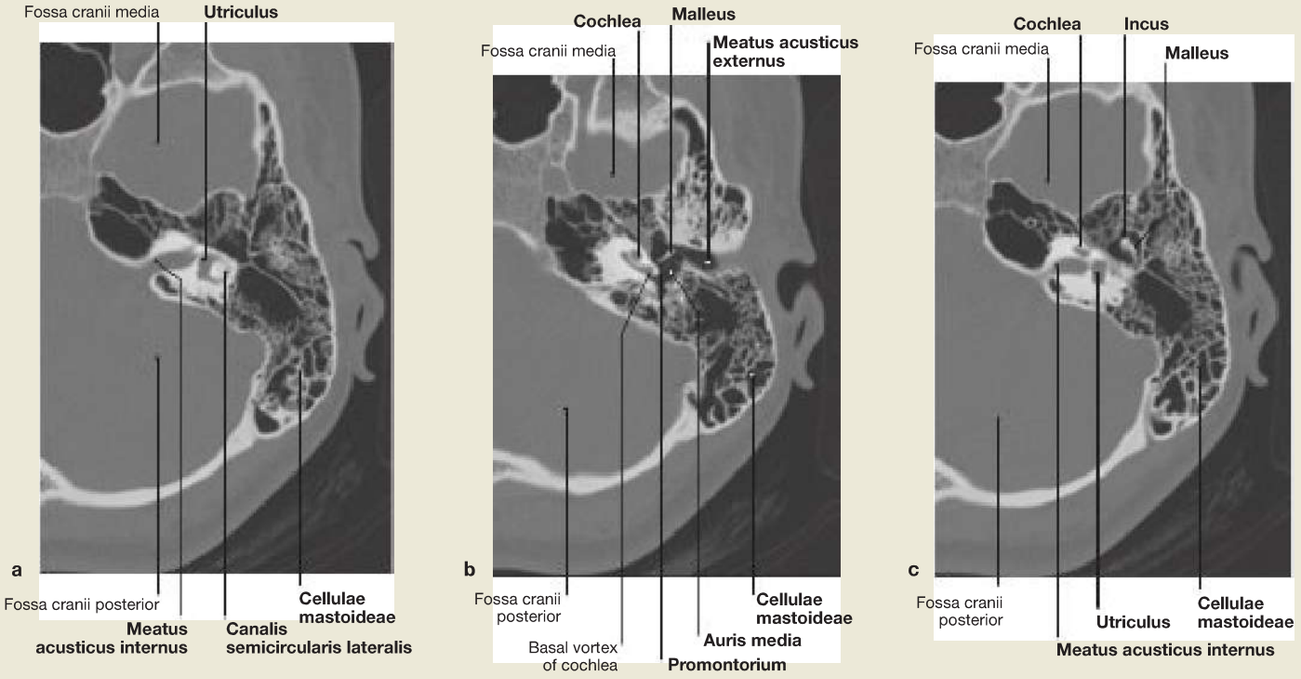

Fig. 10.34a to c Temporal bone, Os temporale, with middle and inner ear, left ear; computed tomography (CT) scan; inferior view. [E460]

High-resolution CT scan is able to visualise in detail all middle ear and inner ear structures. Thus, for example, the internal acoustic meatus, the pneumatisation of the mastoid process, the positioning of the auditory ossicles, as well as the labyrinth, can be assessed.

Clinical Remarks

The N. facialis [VII] can be accessed surgically via the Proc. mastoideus, for example, to provide relief in the context of an inflammatory swelling of the nerve. Upon careful removal of the mastoid bone, the posterior section of the facial canal is exposed.

Fig. 10.35 Cartilage of the auditory tube, Cartilago tubae auditivae, right side; inferior view, exposed at the base of skull.
The approximately 4 cm long Tuba auditiva [auditoria], EUSTACHIAN tube projects at an oblique angle from a cranial posterolateral to a frontomedial caudal position and connects the tympanic cavity with the nasopharynx. Its function is pressure equalisation. For optimal transmission of sound waves, pneumatic pressure in the tympanic cavity (the tympanic membrane is airtight) has to be the same as in the external acoustic meatus. If this is not the case, e.g. during ascent or descent in a plane, some hearing is lost.

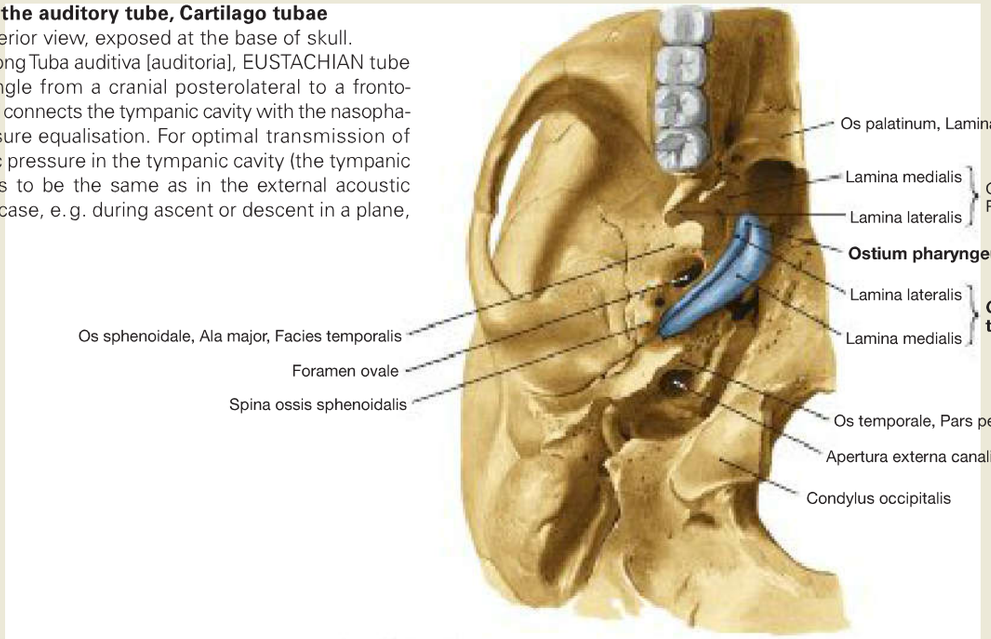

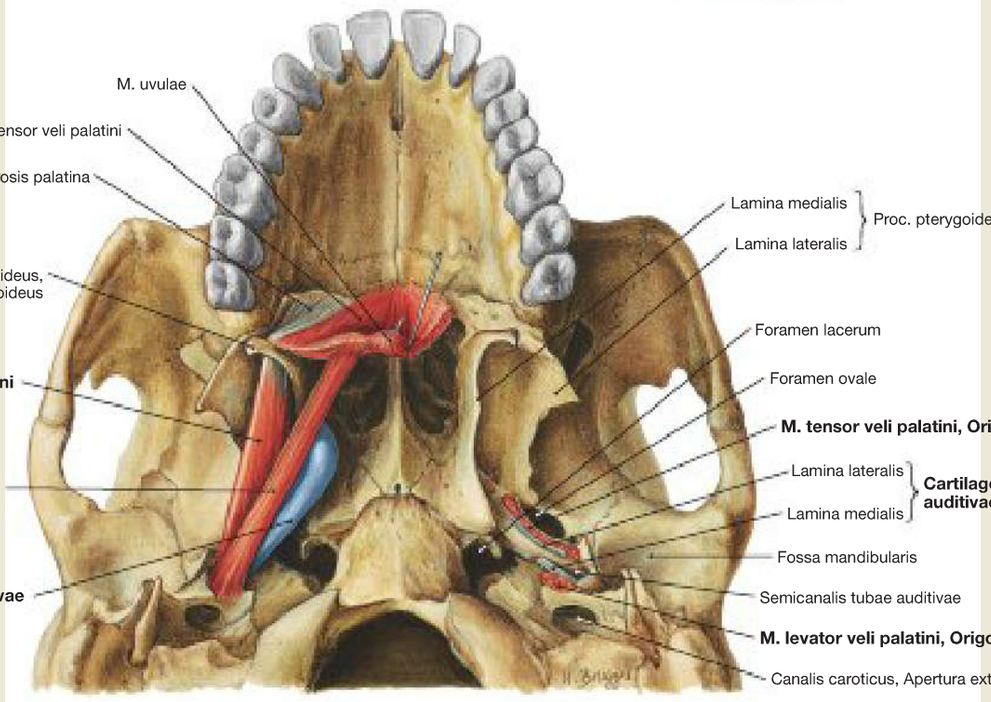

Fig. 10.36 M. levator veli palatini, M. tensor veli palatini and cartilage of the auditory tube, Cartilago tubae auditivae; inferior view.
The Tuba auditiva [auditoria] (bony portion not visible) initiates at Ostium tympanicum tubae auditivae the anterior wall of the tympanic cavity (Paries caroticus) and ends at the pharyngeal opening (Ostium pharyngeum tubae auditivae), which protrudes laterally posterior into the nasopharynx. A distinction is made between a bony section (Pars ossea) and a cartilaginous section (Pars cartilaginea) which is about twice as long. The latter consists of a groove made of elastic cartilage (Cartilago tubae auditivae). The upside-down cartilage groove is medially enclosed by connective tissue (Lamina membranacea) to form a slit-shaped canal. The Tuba auditiva [auditoria] is opened by the contraction of the Mm. tensor and levator veli palatini as part of the swallowing motion.

→T 3

Clinical Remarks

The Tuba auditiva [auditoria] is lined by respiratory ciliated epithelium with goblet cells. The ciliary beat is in the direction of the nasopharynx. Failure of the protective mechanism in the tube can lead to an ascending inflammation with formation of a **tube catarrh** up to a middle ear inflammation. By air injection via the nose, adhesions and closures inside the tubes can be dissolved (e.g. swallowing to compensate ambient pressure changes).

Auditory Tube

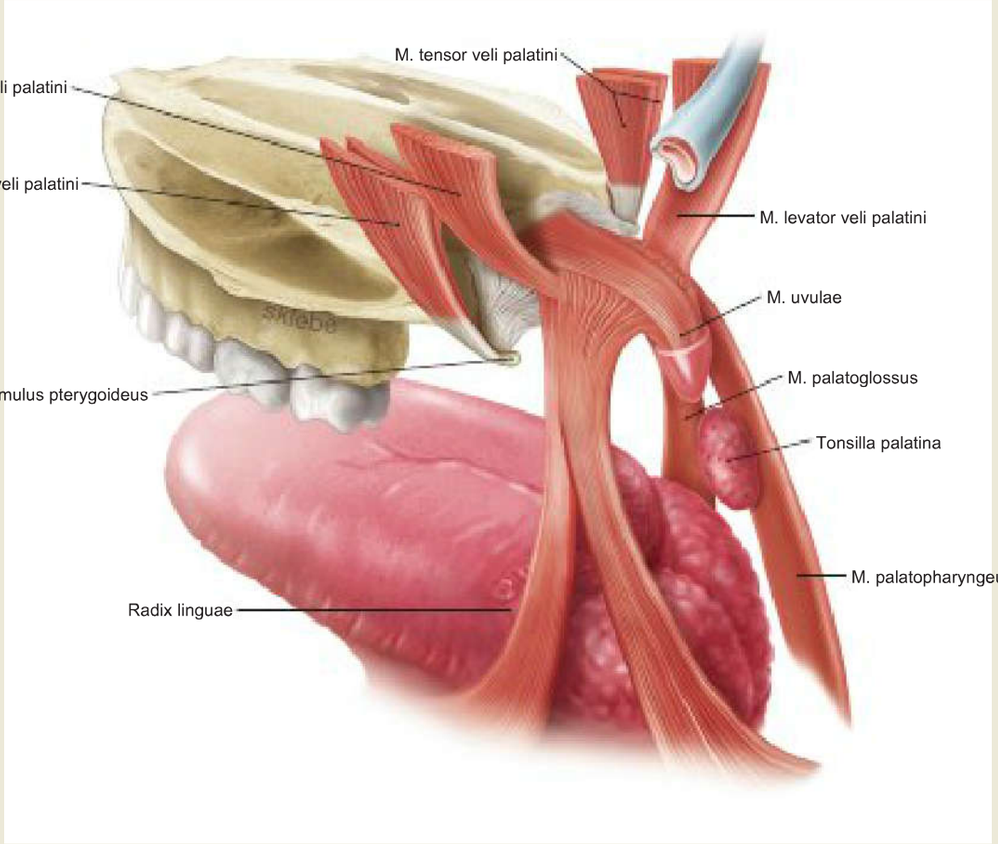

Fig. 10.37 Muscles of the soft palate, Palatum molle; left side; posterior view. [L238]
The basis of the soft palate is a plate of connective tissue (Aponeurosis palatina) into which four paired muscles and the unpaired **M. uvulae**, which forms the uvula, radiate.
The two lower paired muscles are the
- **M. palatoglossus,** which forms the basis of the anterior palatoglossal archway (Arcus palatoglossus)
- **M. palatopharyngeus,** which forms the basis of the posterior palatopharyngeal archway (Arcus palatopharyngeus)

Between the two palatine archways is the Tonsilla palatina. During a contraction, the two paired muscles pull the soft palate down and thus reduce the Isthmus faucium.
The two upper paired muscles are the
- **M. levator veli palatini,** which lifts the velum
- **M. tensor veli palatini,** which tenses the velum

The contraction of the upper pairs of muscles, together with the contraction of the M. uvulae, causes the elevation and tension of the soft palate, which is drawn back to the wall of the pharynx, thereby separating the nasopharynx from the oropharynx (important for swallowing). Moreover, the two upper muscles at the opening of the Tuba auditiva [auditoria] (→ Fig. 10.36 and → Fig. 10.38) are also involved.

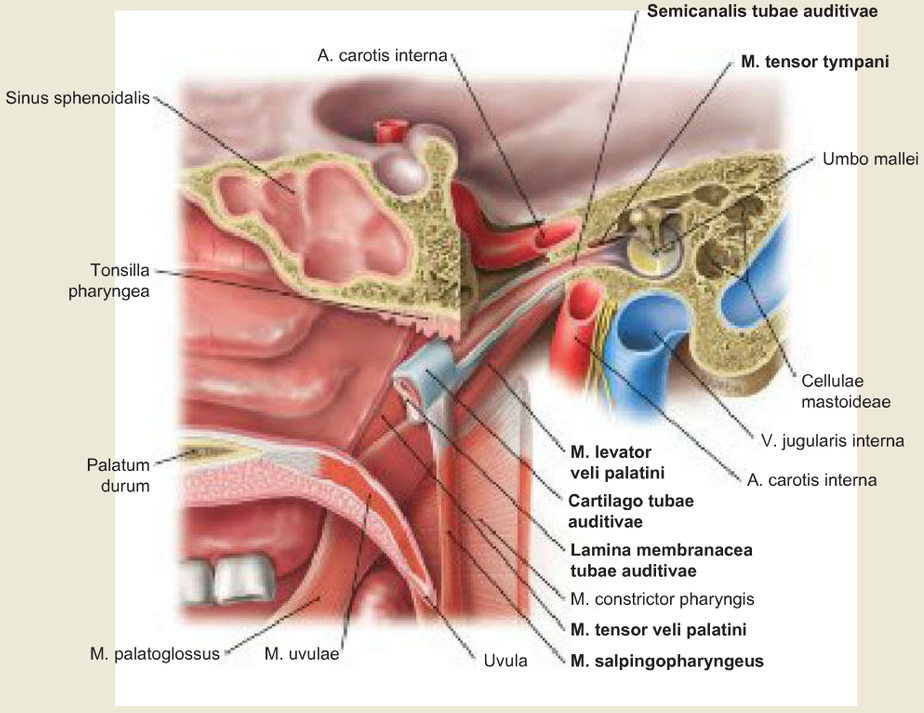

Fig. 10.38 Auditory tube, Tuba auditiva [auditoria], right side; medial view. [L238]
Presentation of the connection between the nasopharynx and tympanic cavity as well as the location of the muscles. The **M. salpingopharyngeus** originates in the lower section of the cartilage of the tube of the nasopharynx. Its contraction causes the tube to close. At the same time, it lifts the pharynx.

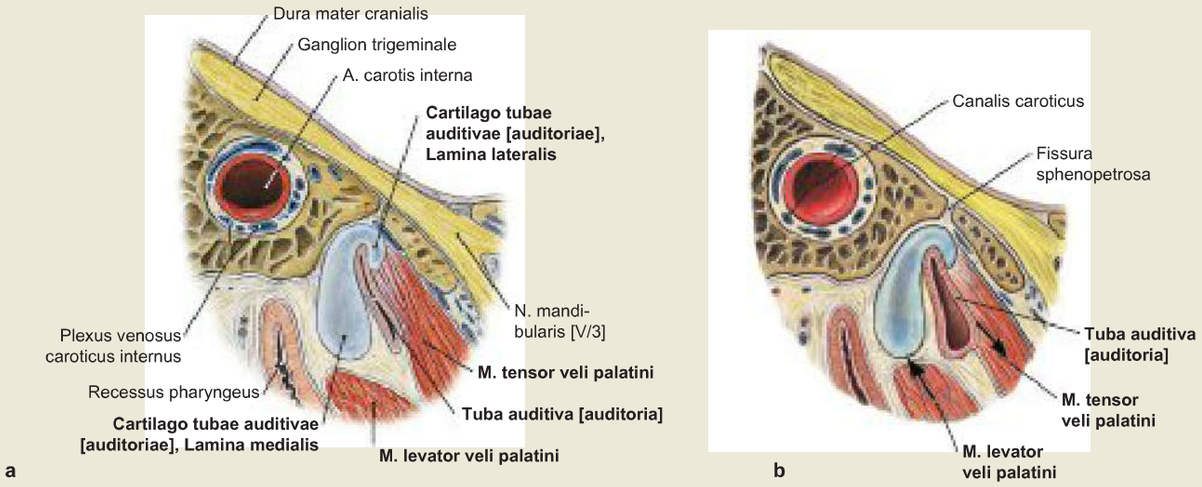

Fig. 10.39a and b Auditory tube, Tuba auditiva [auditoria], right side; cross-sections at the level of the lateral section of the Pars cartilaginea; lateral view.
a Closed tube
b Open tube
The effect of the muscles on the tube is illustrated by arrows.
The M. salpingopharyngeus (not shown) is involved in occluding the tube.

The swallowing motion involves the contraction of the Mm. tensor and the levator veli palatini. The **contraction of the M. tensor veli palatini** causes the tubal lumen to expand by pulling on the Pars membranacea and the upper edge of the cartilaginous part of the auditory tube. The **contraction of the M. levator veli palatini** causes the thickest part of the muscle to push against the tubal cartilage from below. In doing so, the groove is bent open and the tubal lumen expanded.

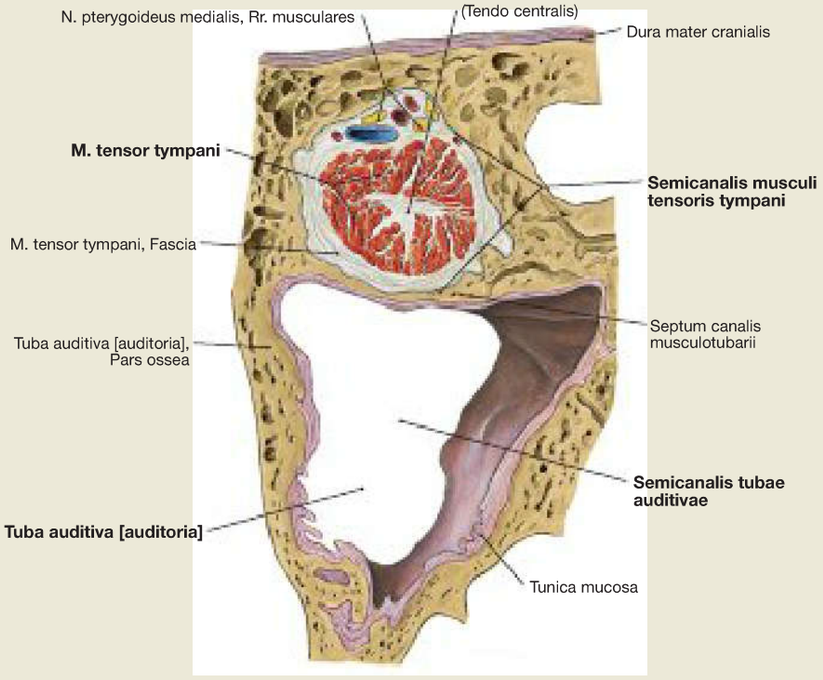

Fig. 10.40 Auditory tube, Tuba auditiva [auditoria], right side; cross-section at the level of the Pars ossea through the Canalis musculotubarius; lateral view.
The osseous part of the Tuba auditiva is inside a triangular bony canal (Semicanalis tubae auditivae of the Canalis musculotubarius) of the Pars petrosa ossis temporalis. Separated by a thin bony wall, the M. tensor tympani proceeds inside the Semicanalis musculi tensoris tympani of the Canalis musculotubarius.

Clinical Remarks

A cleft palate is associated with a loss of function of the Mm. tensor and levator veli palatini, because the Punctum fixum of the muscles is missing and they contract into a void. Thus, the contraction of both muscles fails to open the Tuba auditiva [auditoria]. If left untreated, an **adhesive process** occurs in the middle ear due to the absence of middle ear ventilation. Such children are hard of hearing and often do not learn to speak.

Bony Labyrinth

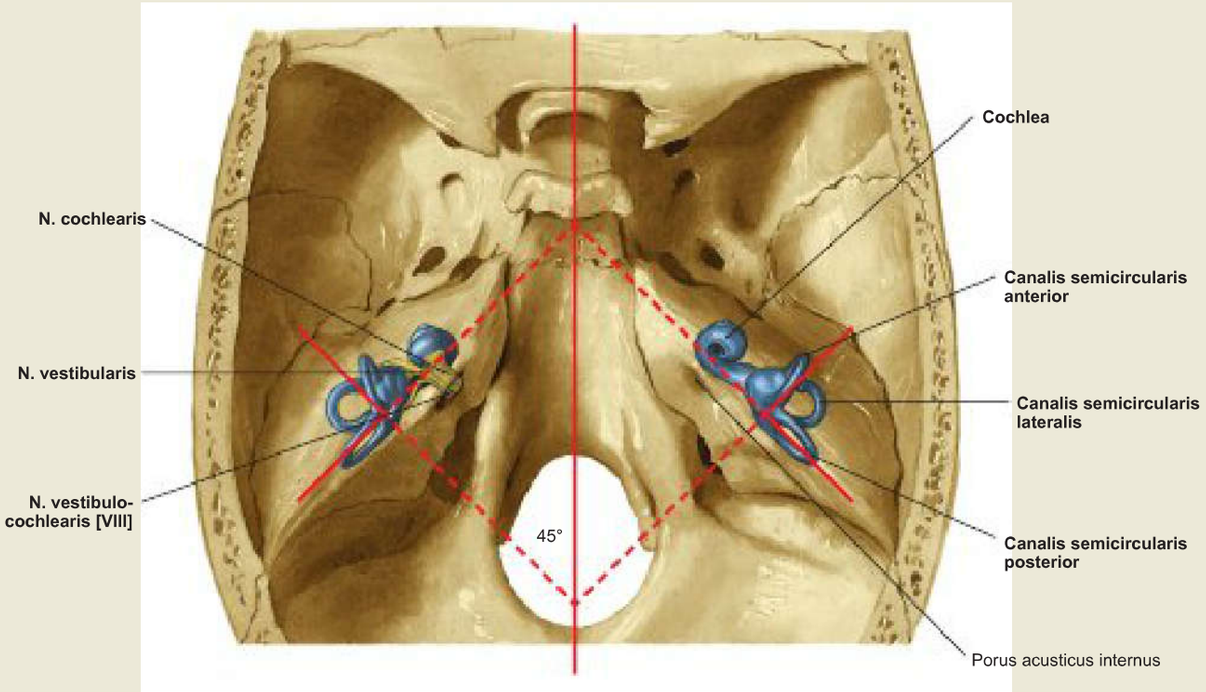

Fig. 10.41 Inner ear, Auris interna and N. vestibulocochlearis [VIII]; superior view; inner ear in its natural position projected onto the petrous part of the temporal bone.
The tip of the cochlea is pointed anterolateral. The semicircular canals (Canales semicirculares) are positioned at a 45° angle in relation to the main planes of the skull (frontal, sagittal and horizontal planes). This is important in the assessment of CT scans of the skull.

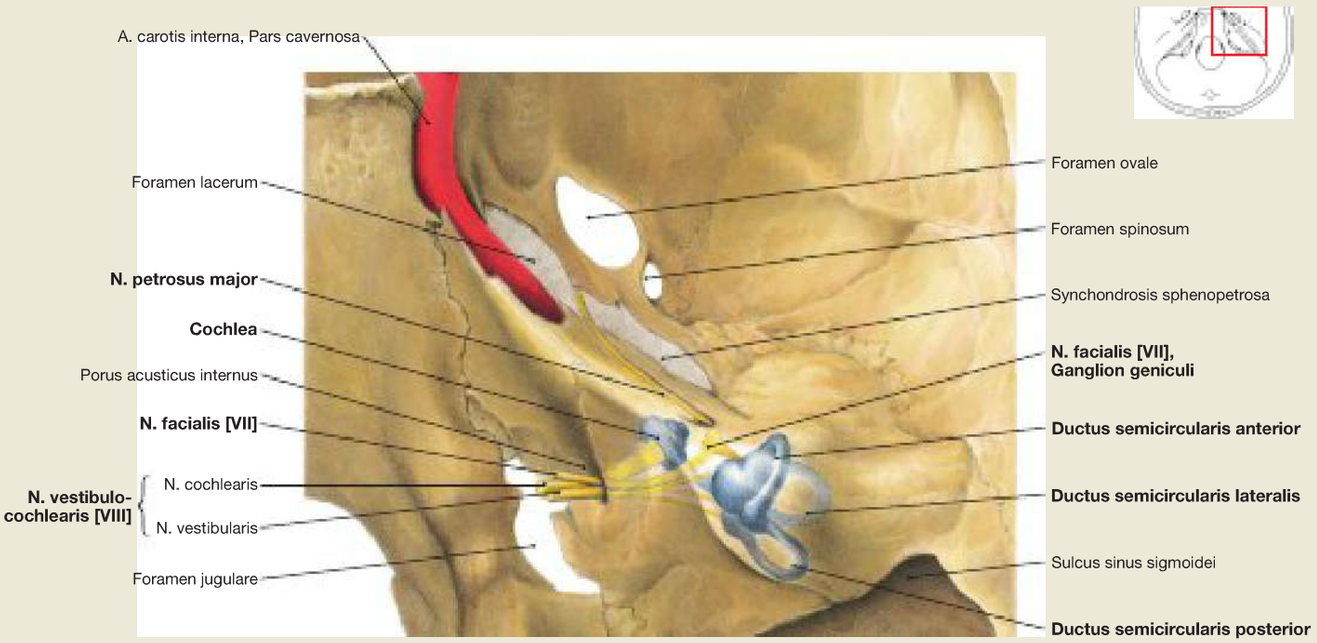

Fig. 10.42 Inner ear, Auris interna with N. facialis [VII] and N. vestibulocochlearis [VIII], right side; superior view of petrous part of the temporal bone.
Upon entering the Porus acusticus internus, the N. facialis [VII] and its intermedius part lie on top of the N. vestibulocochlearis [VIII] (in clinical terms often also referred to as N. statoacusticus), which is composed of the N. cochlearis and N. vestibularis. The nerves divide in the petrous part of the temporal bone. The **N. cochlearis** follows a slightly arched path anterior to the cochlea, and the **N. vestibularis** a slightly arched posterior path. Shortly before reaching the labyrinth, it divides into a Pars superior to the anterior and lateral semicircular canals as well as to the Sacculus, and into a Pars inferior to the Triculus and posterior semicircular canals. The perikarya of the neurons of both parts are combined into the **Ganglion vestibulare**. The N. facialis [VII] proceeds above and between the cochlea and the vestibular organ in the facial canal. The main stem bends at a right angle downward at the outer knee of the facial nerve. At the Ganglion geniculi, the **N. petrosus major** leaves the N. facialis [VII]. It proceeds in a dural duplicature on the petrous bone in the direction of the Foramen lacerum and contains preganglionic parasympathetic fibres for the innervation of the lacrimal and nasal glands.

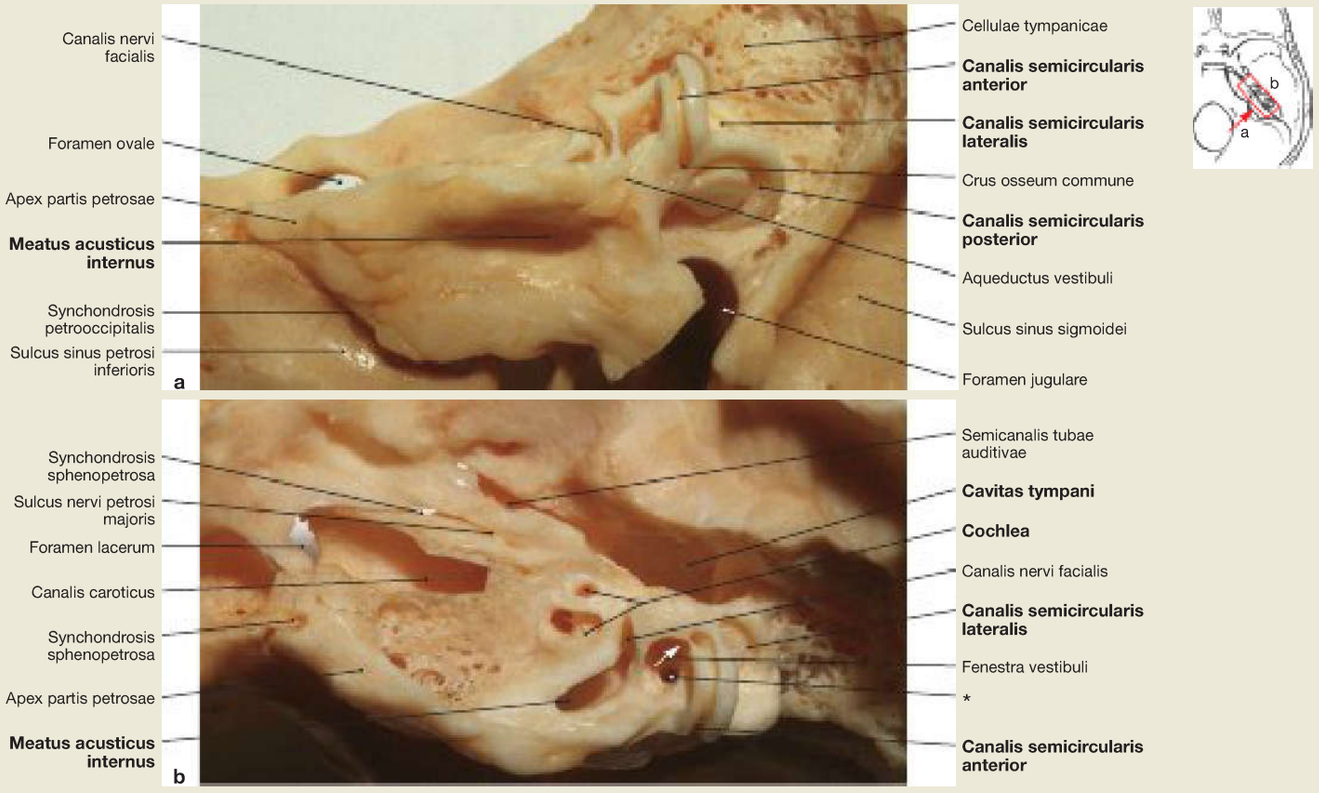

Fig. 10.43a and b Bony labyrinth, Labyrinthus osseus, right side; hollowed out of the petrous part of the temporal bone; posterior view **(a),** superior view **(b).**
The inner ear (Auris interna) is a complex of bony canals and ampullary extensions in the Pars petrosa of the Os temporale (osseous labyrinth). Inside is a system of membranous tubes and sacs called the membranous labyrinth. It harbours the vestibular and cochlear organ (Organum vestibulocochleare).

* opening of the Canaliculus posterior

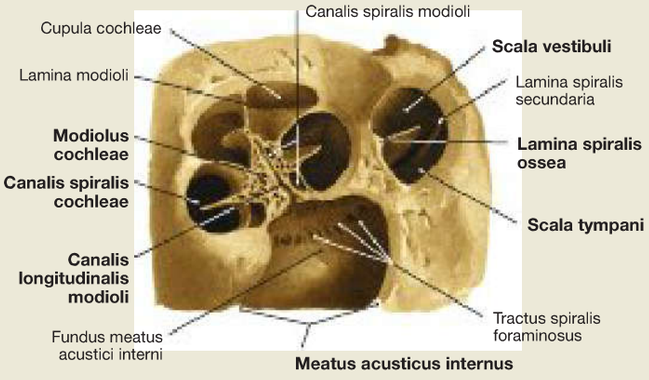

Fig. 10.44 Spiral canal of the cochlea, Canalis spiralis cochleae, right side; superior view; opened along in the axis of the modiolus.
The cochlea consists of a spiral canal (Canalis spiralis cochleae), which is wound in 2½ turns around the cochlear modiolus (Modiolus cochleae). The Ganglion spirale cochleae is situated in the Canales spiralis and longitudinalis modioli contains the perikarya of the bipolar nerve cells of the N. cochlearis. Originating from the modiolus, the Lamina spiralis ossea protudes into the cochlear canal.

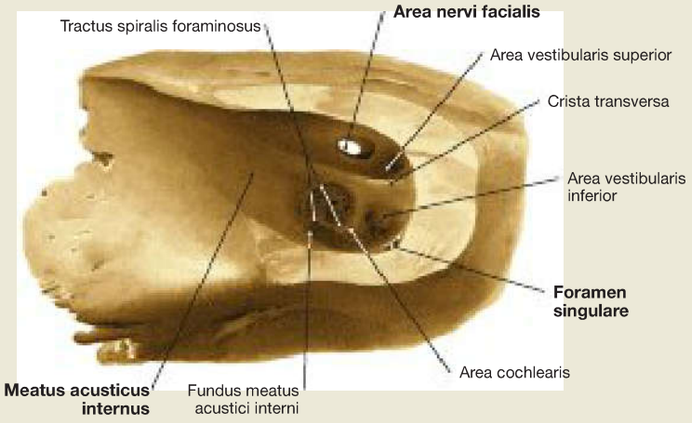

Fig. 10.45 Internal acoustic meatus, Meatus acusticus internus and fundus of the internal acoustic meatus, Fundus meatus acustici interni, right side; medial view; after partial removal of the posterior wall.
The internal acoustic meatus initiates at the Porus acusticus internus and projects laterally for about 1 cm. Here it ends in a perforated bony plate. The N. facialis [VII] and the N. vestibulocochlearis [VIII] proceed in the 1 cm long segment.

Clinical Remarks

The **acoustic neuroma** (vestibular schwannoma) is a benign tumour of the SCHWANN's cells, that most frequently affects the N. vestibularis. It originates in the Meatus acusticus internus and grows in a displacing into the posterior cranial fossa (cerebellopontine angle tumour), it presses on adjacent structures. Early symptoms are impaired hearing and imbalance.

Bony Labyrinth

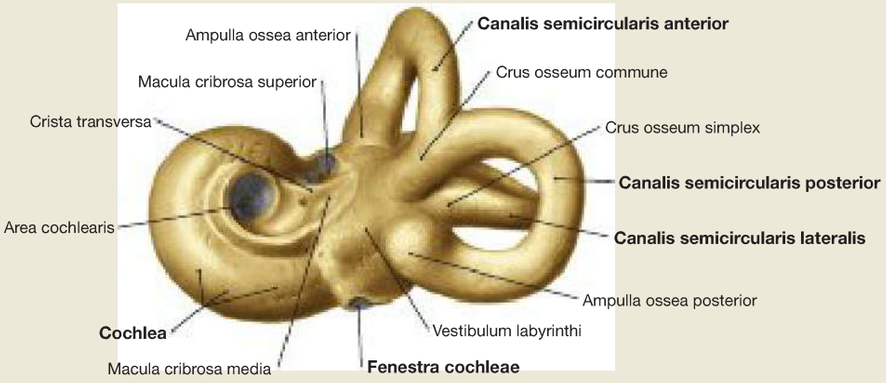

Fig. 10.46 Bony labyrinth, Labyrinthus osseus, right side; posterior oblique view, bony surroundings of the membranous labyrinth removed from petrous part of the temporal bone.

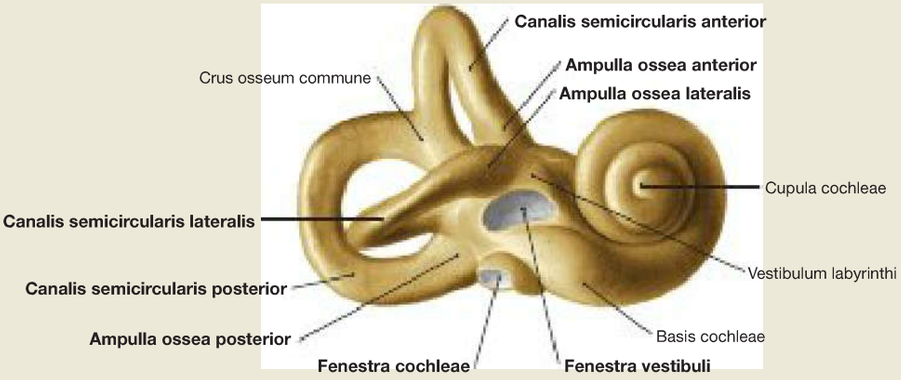

Fig. 10.47 Bony labyrinth, Labyrinthus osseus, right side; lateral view; bony surroundings of the membranous labyrinth removed from petrous part of the temporal bone.

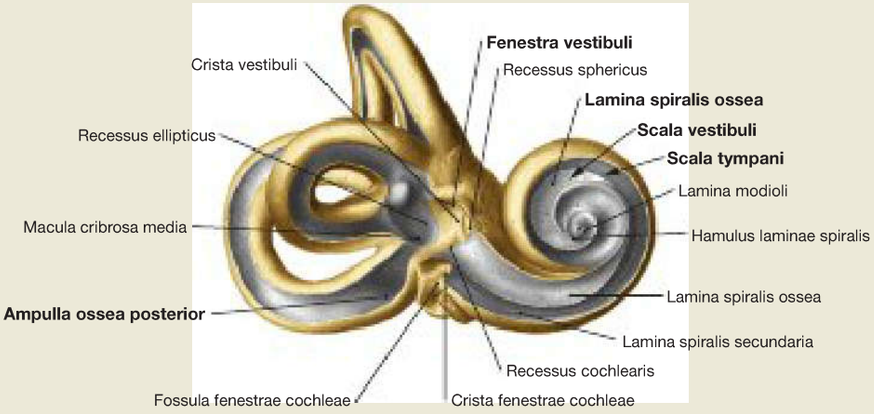

Fig. 10.48 Bony labyrinth, Labyrinthus osseus, right side; anterolateral view; hollowed out cavities.
The bony labyrinth consists of the vestibulum, three bony semicircular canals (Canales semicirculares ossei), the bony cochlea and the internal accoustic meatus (Meatus acusticus internus). The cochlea and semicircular canals commence at the vestibulum. It is connected to the tympanic cavity via the oval window.

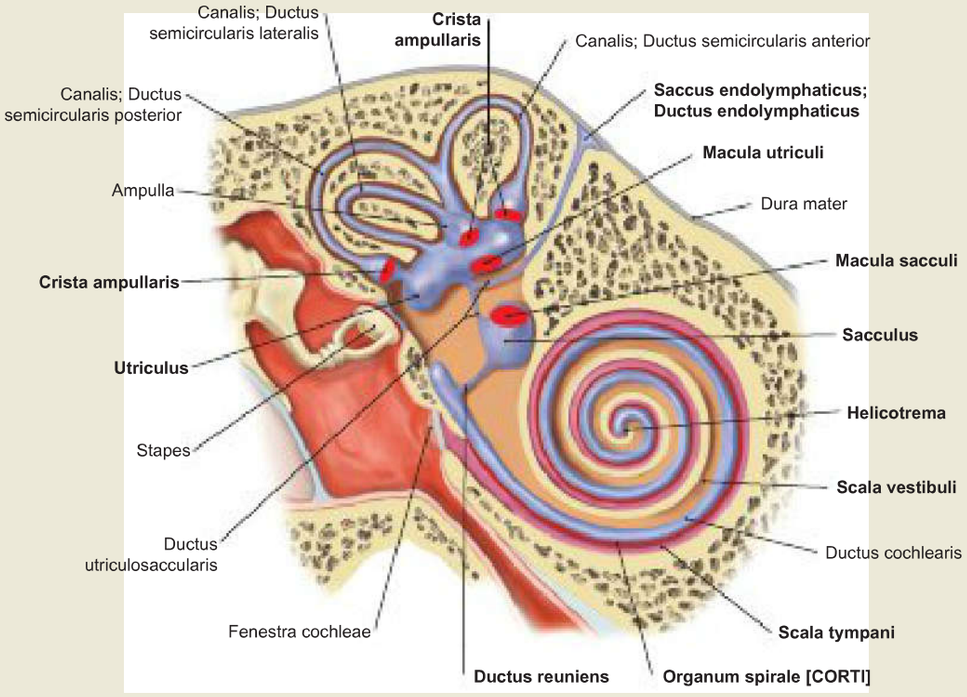

Fig. 10.49 Membranous labyrinth, Labyrinthus membranaceus, right side; longitudinal section through the petrous part of the temporal bone; frontal view, schematic drawing. [L284]
The membranous labyrinth is filled with low-sodium and potassium-rich endolymph. It is not directly adjacent to the bony labyrinth, but separated from it by the perilymphatic space filled with perilymph. The membranous labyrinth is functionally divided into a vestibular and a cochlear compartment. The **vestibular labyrinth** includes the Sacculus and Utriculus located in the vestibulum, the Ductus utriculosaccularis, the three semicircular canals and the Ductus endolymphaticus with the Saccus endolymphaticus. The latter represents an epidural sac, located at the rear surface of the petrous bone, in which the endolymph is resorbed. The **cochlear labyrinth** is formed by the Ductus cochlearis. The Ductus reuniens connects the vestibular and cochlear labyrinth.

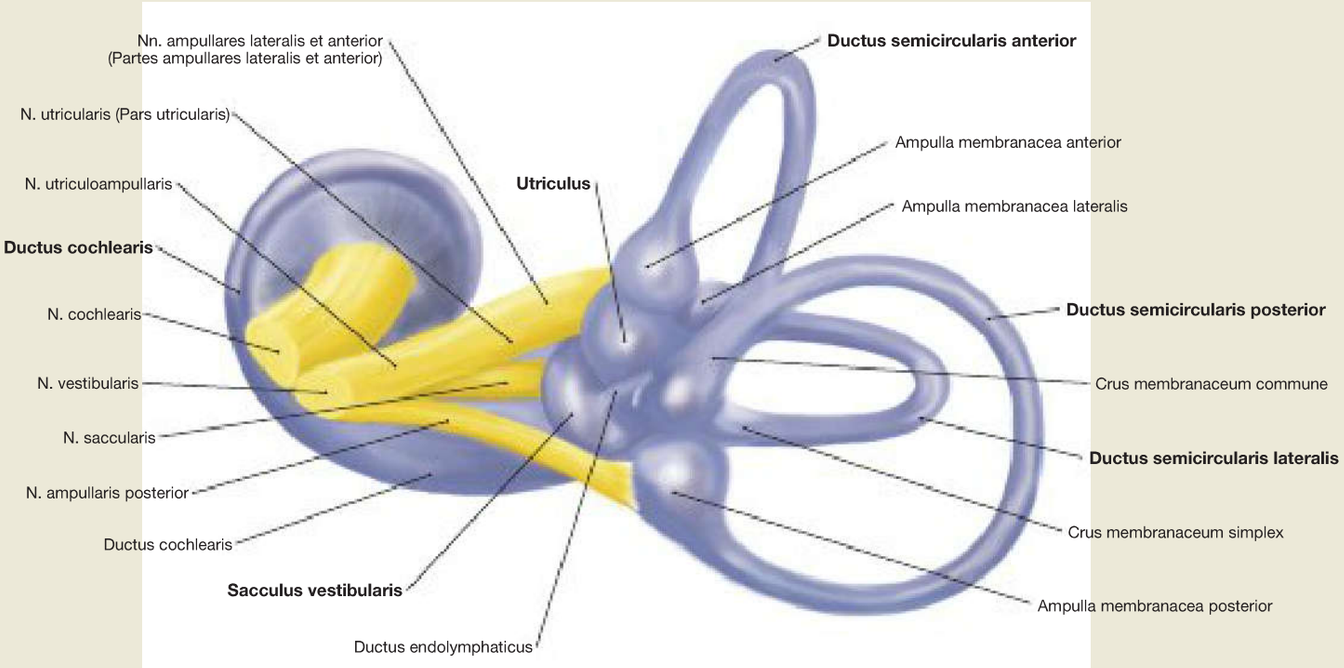

Fig. 10.50 N. vestibulocochlearis [VIII] and membranous labyrinth, Labyrinthus membranaceus; semischematic overview, dorsal view. [L284]
The membranous labyrinth includes the Ductus cochlearis, the Sacculus, the Utriculus, as well as the three membranous semicircular canals (Ductus semicirculares). The latter are in contact with the Utriculus. Each semicircular canal forms an ampulla-shaped dilation (Ampulla membranacea) at the border to the Utriculus. The superior and posterior semicircular canal unite to form a common canal (Crus commune). Each ampulla contains sensory epithelium (Crista ampullaris, not shown).

Blood Supply and Innervation of the Membranous Labyrinth

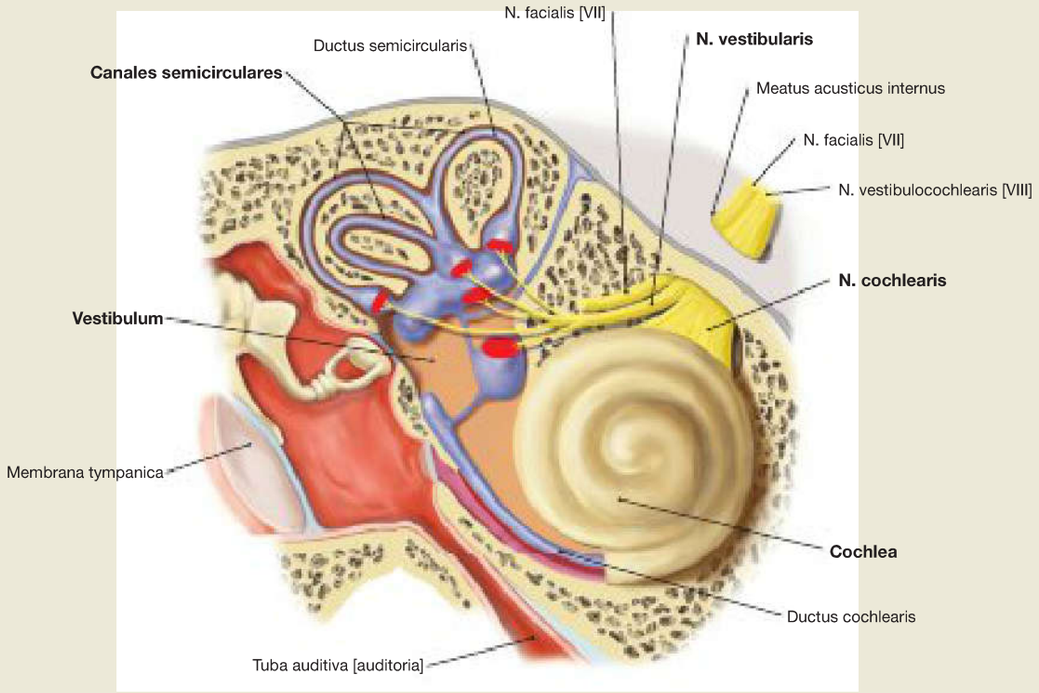

Fig. 10.51 Innervation of the inner ear, Auris interna, right side; longitudinal section through the petrous part of the temporal bone; frontal view, schematic drawing. [L284]

The inner ear divides into the **bony labyrinth** (Labyrinthus osseus) which is surrounded by the compact bone of the petrous part of the temporal bone and includes a system of membraneous tubes, the **membraneous labyrinth** (Labyrinthus membranaceus).

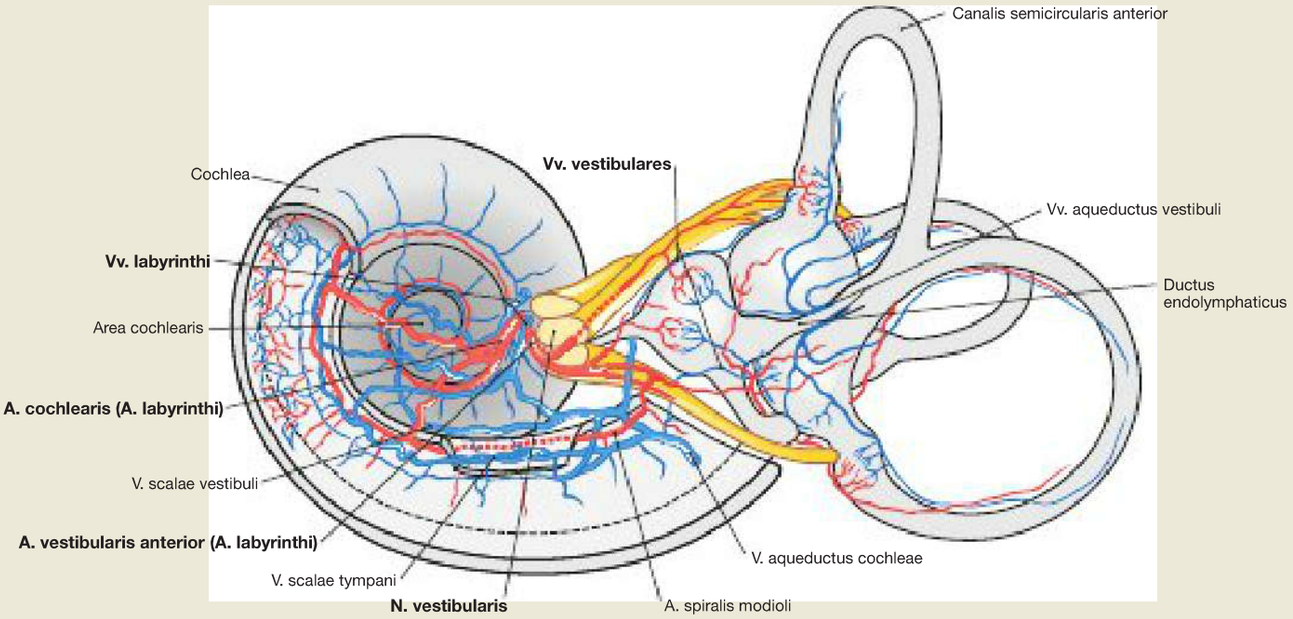

Fig. 10.52 Blood supply and innervation of the inner ear, Auris interna, right side; medial view. [L126]
The entire blood supply of the inner ear is via the branches of the **A. cochlearis (A. labyrinthi;** → Fig. 12.59), venous blood drainage is via the Vv. labyrinthi. The A. and V. inferior anterior cerebelli often project a few millimetres into the internal acoustic meatus (not shown) and branch into the A. and Vv. labyrinthi; supplying the labyrinth with blood (**caveat:** the A. labyrinthi is a terminal artery).

Clinical Remarks

Thrombotic sealing of the A. labyrinthi or its afferent branches is associated with a loss of balance and hearing, because the A. labyrinthi is a terminal artery.
Attacks of vertigo, unilateral hearing loss and unilateral tinnitus are a triad of symptoms referred to as **MENIÈRE's disease**. Its etiology is not clear, but a hydropic swelling of the membranous labyrinth due to impaired resorption of endolymph (hydrops cochleae) is discussed. The pressure imposed by the increased volume of endolymph damages the sensory cells of the vestibulocochlear system.

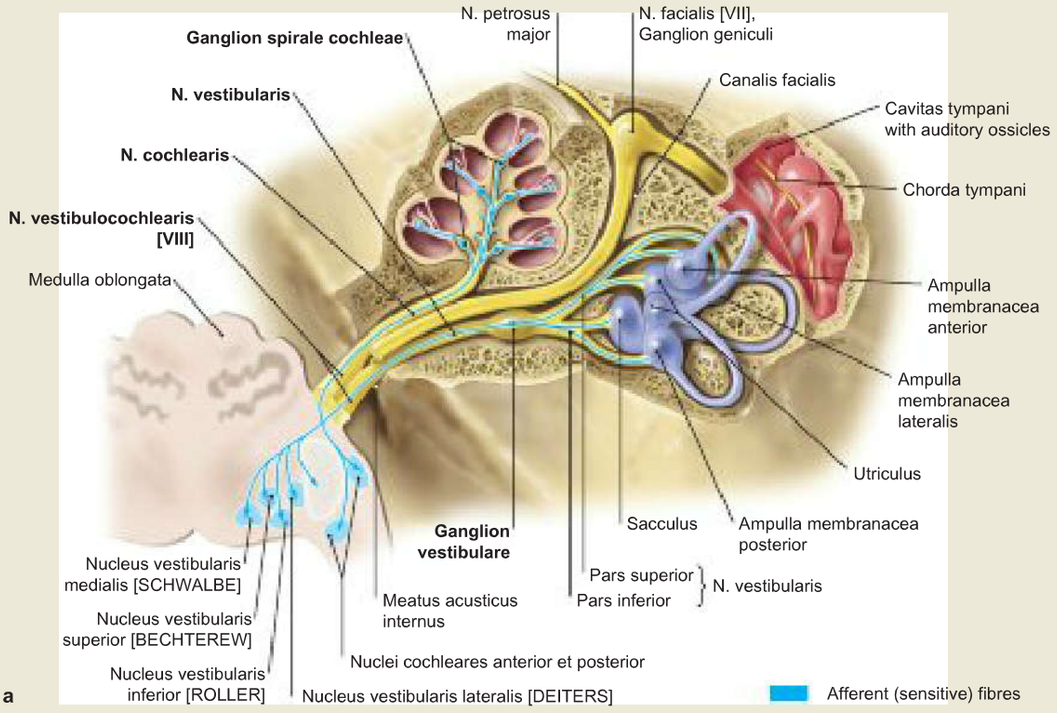

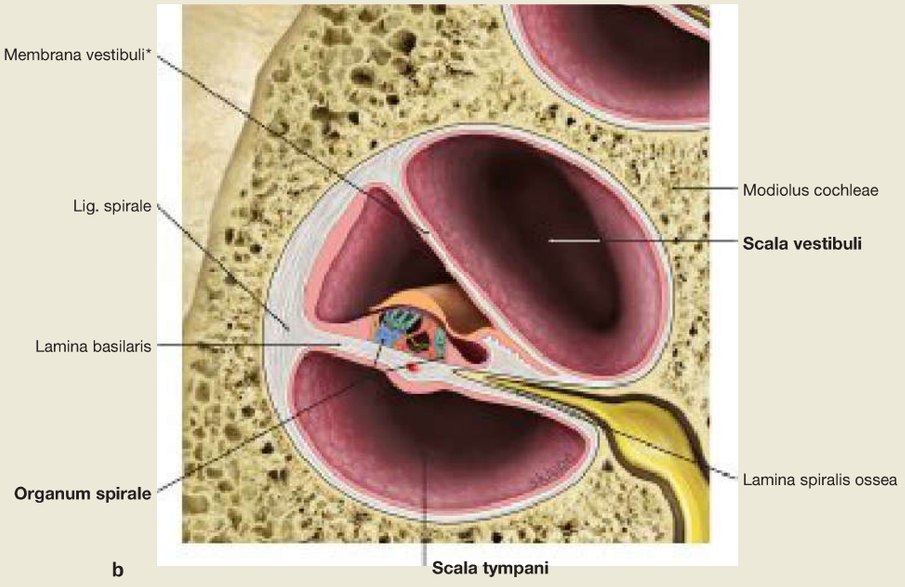

Fig. 10.53a and b Cochlea, vestibular organ, Organum vestibulare, N. vestibulocochlearis [VIII] with nuclei and fibrous qualities, N. facialis [VII] as well as the middle ear, Auris media; view from above, Pars petrosa opened. [L238]

a After entry, the N. facialis [VII] proceeds via the Meatus acusticus internus between the cochlea and vestibular organ. At the Ganglion geniculi it bends forwards and downwards and is found in the topographical proximity of the middle ear (→ Fig. 10.25, → Fig. 10.26, → Fig. 10.27). The N. vestibulocochlearis [VIII] (syn.: N. statoacusticus) contains special somato-afferent (SSA) fibres as well as efferent fibres that form the olivocochlear bundle. Its **cochlear section** conducts hearing information to the anterior and posterior cochlear nuclei in the brain stem; its **vestibular section** conducts body balance information to the Nuclei vestibularis medialis, lateralis, superior and inferior in the brain stem. The perikarya of the bipolar neurons for the cochlea are in the **Ganglion spirale** and for the vestibular organ in the **Ganglion vestibulare.**

b The Membrana vestibuli (* REISSNER's membrane) and the Membrana basilaris divide the Canalis spiralis cochleae into three areas:

- the **Scala vestibuli** (vestibular duct) filled with perilymph, which extends from the Vestibulum to the Helicotrema (opening between Scala vestibuli and Scala tympani in the uppermost turn of the cochlea)
- the **Ductus cochlearis** filled with endolymph
- the **Scala tympani** (tympanic duct) filled with perilymph, which extends from the Helicotrema to the round window in the medial wall of the tympanic cavity. The Scala vestibuli and the Scala tympani join at the Helicotrema.

The floor of the Ductus cochlearis is the basilar membrane (Lamina basilaris), which carries the cochlear organ (organ of CORTI). The endolymph is formed by the Stria vascularis at the lateral bony wall of the cochlea.

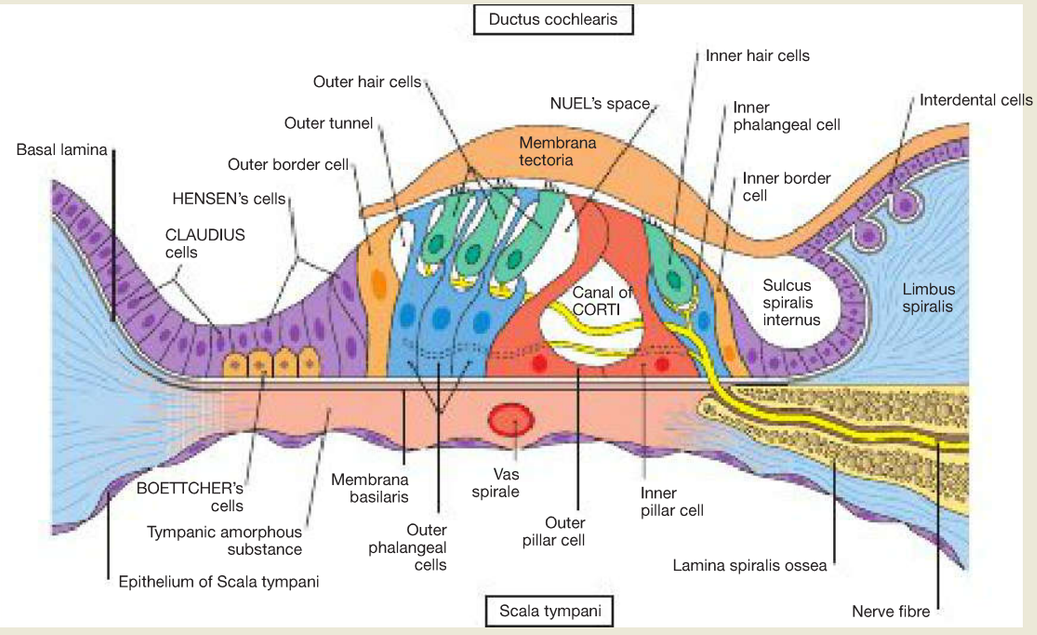

Fig. 10.54 Organum spirale, organ of CORTI; schematic drawing. [R170, L107]
This is a very simplified presentation of the complex afferent and efferent innervation of the hair cells.
The organ of CORTI represents the actual cochlear organ. Here, cochlear sensory cells (hair cells) rest together with supporting cells on the basilar membrane and are covered by a gelatinous membrane (Membrana tectoria). The organ of CORTI extends over the whole length of the Ductus cochlearis.

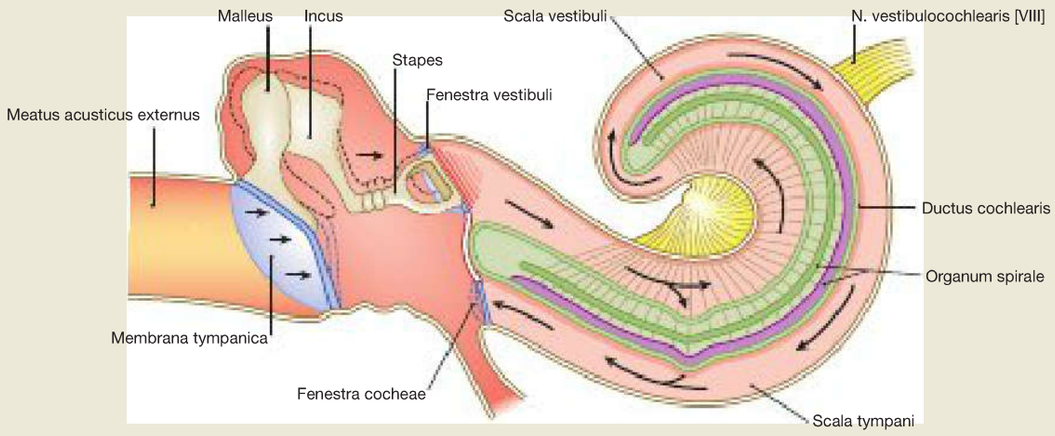

Fig. 10.55 Sound conduction. [L126]
Sound conduction occurs via sound waves that enter via the external ear (auricle and external acoustic meatus) and are transmitted via the tympanic membrane and the auditory ossicular chain, which physically augments the amplitude of sound waves in the middle ear, via the base of stapes to the perilymph. This produces wave movements **(migrating waves)** that migrate along the walls of the Ductus cochlearis (especially the basilar membrane). This results in a deflection of the organ of CORTI. The stereocilia of the inner hair cells are bent (deflection). These biomechanical events are converted by the sensory cells into receptor potentials (mechanical-electrical transduction).

Clinical Remarks

Hair cell damage, e. g. after listening to very loud music or after an explosion (acoustic shock), is very commonly associated with **tinnitus**. In this, the term Tinnitus aurium ('ringing of the ears') or tinnitus for short, refers to a symptom in which the affected person perceives sounds that have no perceptible external cause to other people.

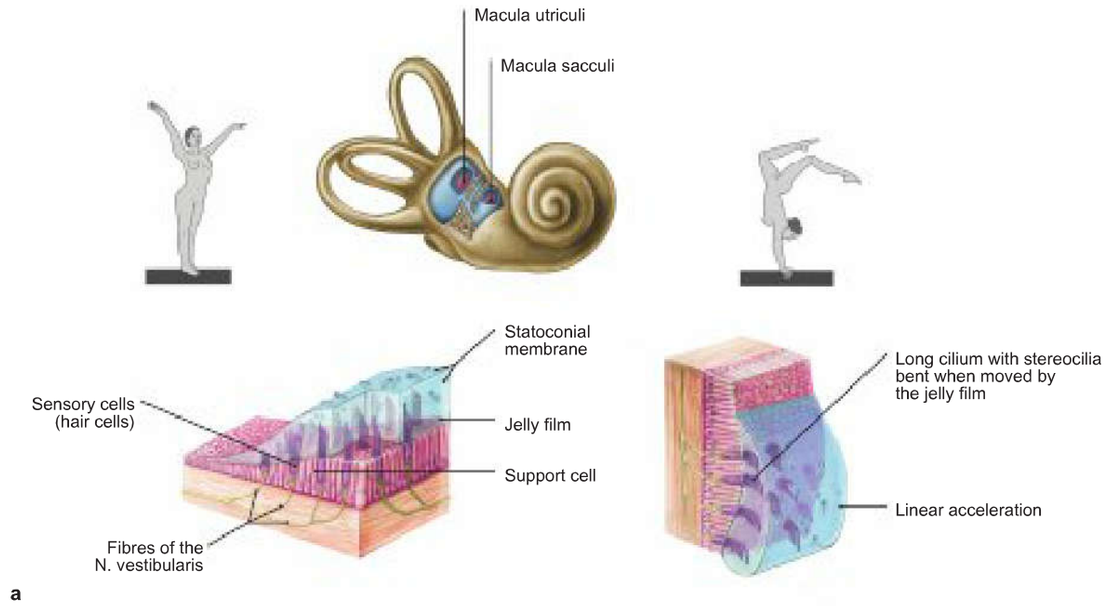

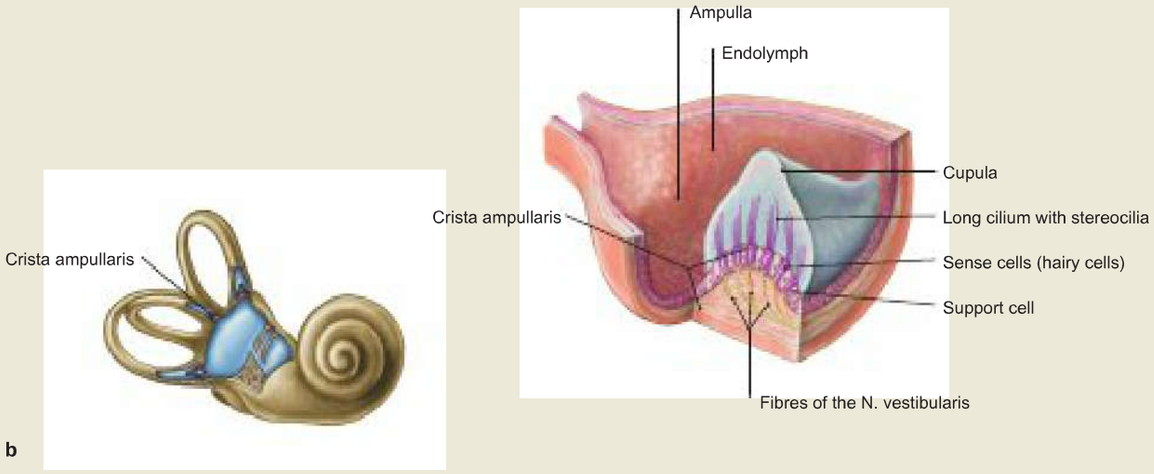

Fig. 10.56a and b Structure of the Maculae utriculi and sacculi and the Cristae ampullares. [L285]
The vestibular labyrinth, filled with endolymph, is made up of the **saccule** (Macula sacculi – vertical linear accelerations), **utricle** (Macula utriculi – horizontal linear accelerations) and the **three semicircular canals** (Cristae ampullares with their Cupulae – horizontal linear accelerations). In the saccule and the utricle **(a)**, in each case an oval epithelial segment (Macula) of 2 mm in length, equipped with sensory cells and support cells, projects above the remaining epithelium. In the ampullas, a transverse positioned segment made of sensory and support cells rises into the extended lumen (Crista ampullaris, **b)**. Above the Maculae and Cristae ampullares in each case is a gelatinous mass called the statoconium membrane or otolithic membrane (Maculae) or cupula (Cristae ampullare). The sensory cells, each of which has a long cilium of 60 µm in length and approximately 80 stereocilia, protrude into the gelatinous layer of Maculae and Cristae and are activated by the fluid motion of the jelly (bending, **a)** which results in the synaptic activation of afferent fibres of the N. vestibularis [VIII].

Clinical Remarks

Labyrinthitis with dizziness, irritation or nystagmus, which can occur in cases of a cholesteatoma (syn.: peritoneal tuberosity of the ear made up of multilayered keratinising squamous epithelium; proliferating into the middle ear, with subsequent chronic purulent inflammation), Otitis media acuta, mastoiditis and after skull injury. Entry pathways for infectious agents are the round and oval window, gaps in the bony labyrinth (after trauma and bone erosion by infected pneumatic areas), or inflammation ascending via nerves and vessels to the cochlear or vestibular ducts. The outcome is **perceptive hearing loss** or even hearing loss and the destruction of the vestibular organ.

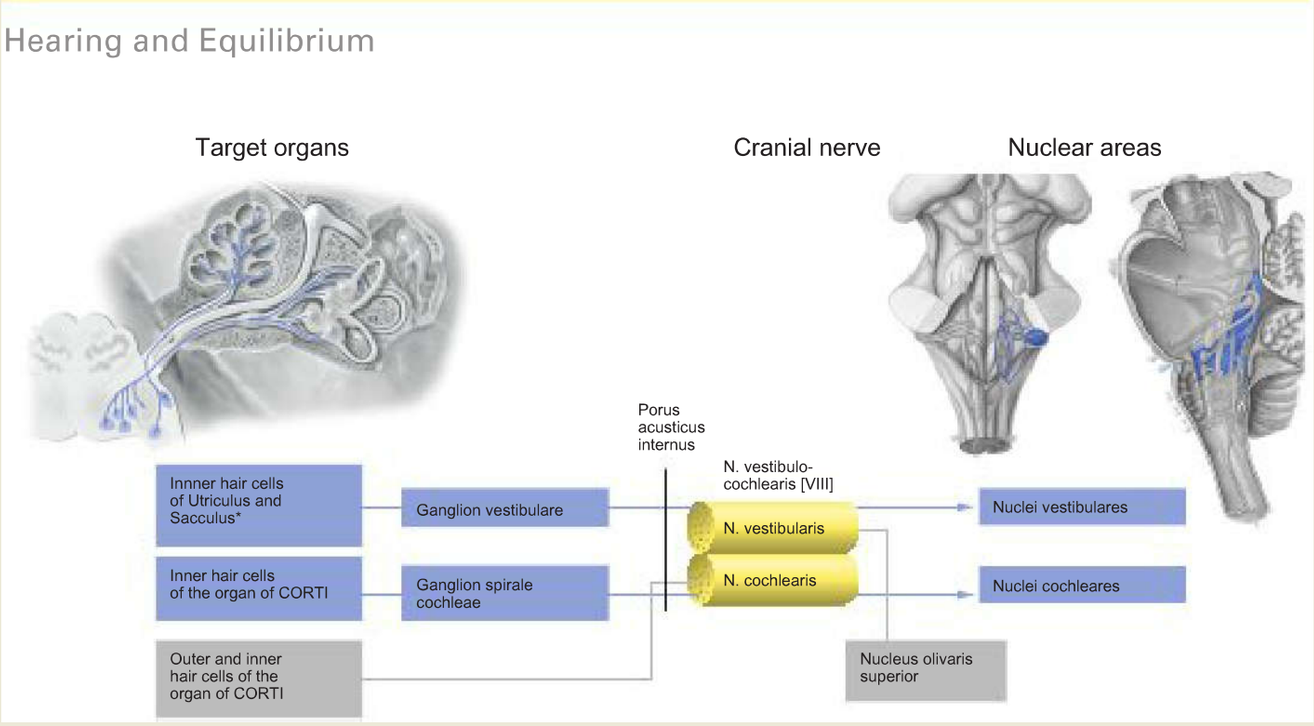

Fig. 10.57 Pathway, branches and fibrous qualities of the N. vestibulocochlearis [VIII]; schematic drawing. [L127]
Hearing and equilibrium perceptions are recorded by the outer and inner hair cells (sensory cells) of the organ of CORTI in the cochlea, or by the hair cells (sensory cells) of the Utriculus and Sacculus, as well as the three semicircular canals. The information is transmitted using the first neuron of the auditory and vestibular tract. The perikarya of the first neuron are positioned in the Ganglion spirale or in the Ganglion vestibulare. The axons of the respective first neuron form the N. cochlearis or the N. vestibularis, which combine to form the N. vestibulocochlearis [VIII] (syn.: N. statoacusticus). The axons of the N. cochlearis project to the two Nuclei cochleares in the brain stem, the axons of the N. vestibularis to the four Nuclei vestibulares. (For the proper names of nuclei → Fig. 10.53.)
Efferent axonal processes reach the hair cells of the inner ear (olivocochlear bundle) from the upper olivary complex. Initially the fibres accompany the N. vestibularis, and then within the Meatus acusticus internus pass over to the N. cochlearis (anastomosis of OORT), with which they reach the hair cells (→ Fig. 10.58).

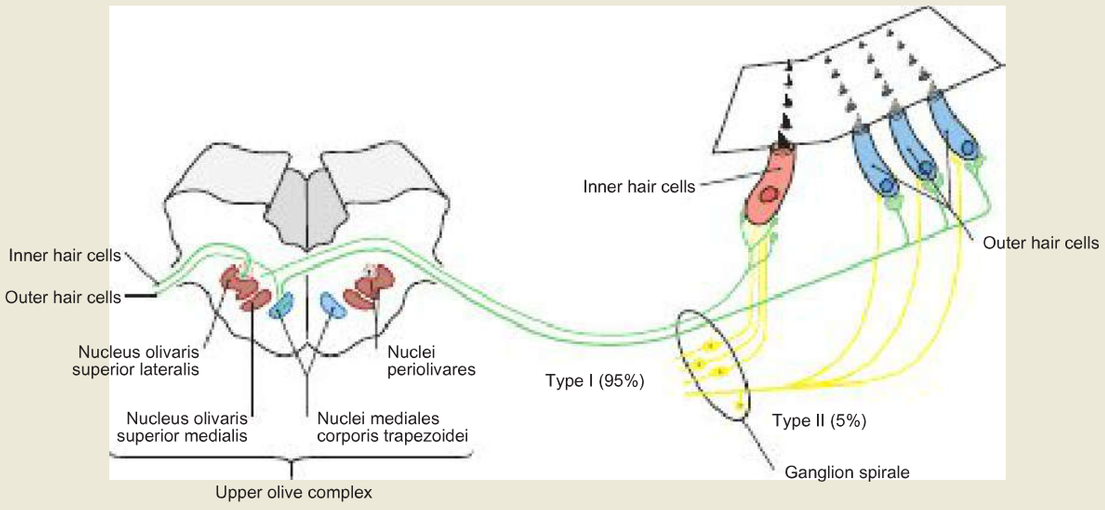

Fig. 10.58 Peripheral sections of the auditory pathway. Origins and terminal areas of the ganglion cells and of the olivocochlear efferent fibres; schematic drawing. [L126]
In the organ of CORTI there are three to four rows of outer hair cells and a series of inner hair cells. The information registered by the outer hair cells in the bending of their stereocilia in the direction of the longest stereocilia, through contact with the tectorial membrane situated above the organ of CORTI, results in the activation of afferent pseudounipolar type II ganglion cells of which the perikarya are located in the Ganglion spirale (only 5 % of all ganglion cells of the Ganglion spirale). Most of their axons do not participate in the formation of the N. cochlearis, but have intrinsic cochlear coordination functions. They serve as a cochlear augmentation mechanism, which is the prerequisite for a very low frequency hearing threshold and the ability to discriminate between frequencies. The inner hair cells activated by type I neurons are bipolar ganglion cells. A ganglia cell receives information from 10–20 inner hair cells. The axons of the bipolar ganglion cells of the perikarya, located in the Ganglion spirale, subsequently form the N. cochlearis and project to the Nuclei cochleares anterior and posterior. Efferent fibers reach the inner and outer hair cells (olivocochlear bundle) from the upper olivary complex. The efferent fibres synapse with the afferent fibres of the inner hair cells and the bases of the outer hair cells.

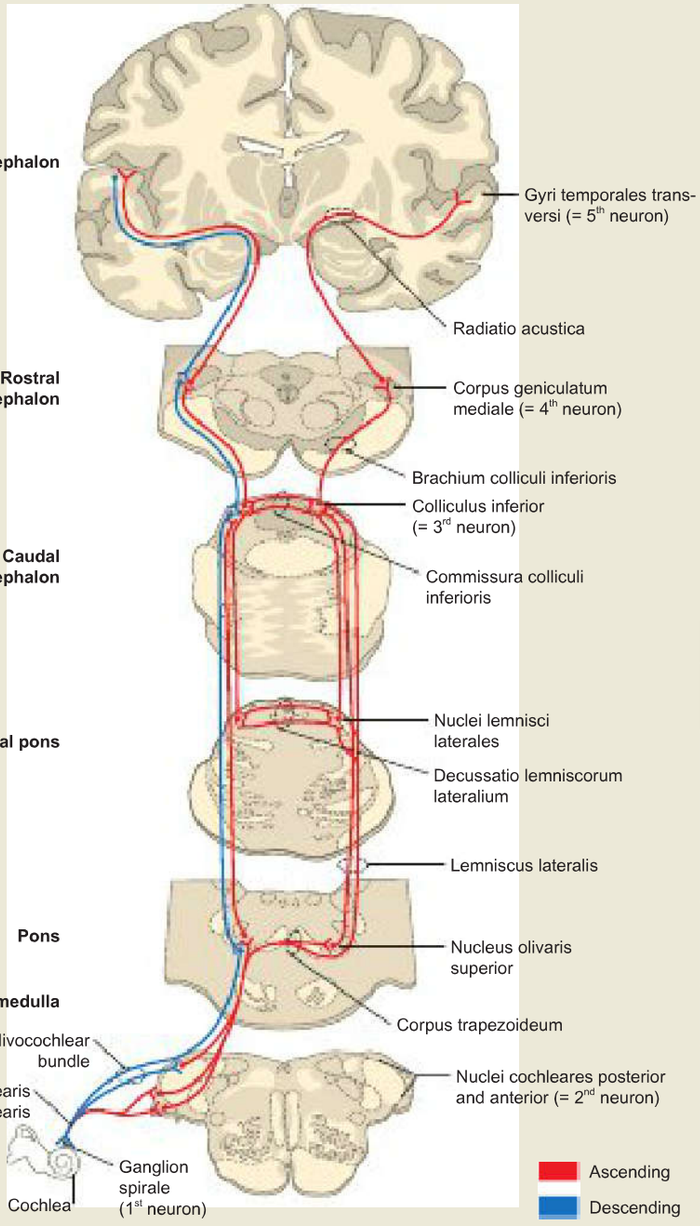

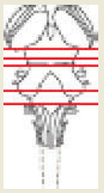

Auditory System	
Chain of Neurons	**Groups of Neurons**
1st neuron	Type I ganglion cells in the Ganglion spirale
2nd neuron	Nuclei cochleares anterior and posterior at the crossing between the Pons und Medulla oblongata in the Recessus lateralis of the 4th ventricle
(indirect auditory pathway)	(Nuclei olivares superiores, if necessary via the Nuclei corporis trapezoidei)
3rd neuron	Nucleus centralis colliculi inferioris in the Tectum mesencephali
4th neuron	Corpus geniculatum mediale of the metathalamus
5th neuron	Gyri temporales transversi (HESCHL's gyri/convolutions), BRODMANN's area 41 in the Lobus temporalis

Fig. 10.59 Auditory pathway. The most important neuronal stations and intersections of the central auditory pathway; schematic drawing. [L127]
The function of the ascending auditory pathway is to transmit acoustic signals to the brain in order to process them and create an acoustic awareness. The auditory pathway is made up of a chain of five groups of neurons (→Table) and is organised tonotopically throughout. Tonotopy means the connections from the ear to the brain are constructed in such a way that the nerve endings in the brain reflect the neighbouring relationships of the cell bodies in the basilar membrane. In the cochlea, the area proximal to the base is stimulated by high frequencies, the apical area by low frequencies. High frequencies tend to be represented laterally and low frequencies medially in the **primary auditory cortex** (Gyri temporales transversi, HESCHL's gyri/convolutions) which is achieved via the axons of the fifth neuron as **Radiatio acustica**. The primary auditory cortex is involved in the perception of tones, sounds and simple acoustic patterns. Words, language or melodies are only processed once they reach the adjacent secondary auditory cortex (not shown).

Clinical Remarks

To ascertain whether a hearing loss originates in the inner ear (sensory) or has neuronal (retrocochlear) causes, an **ABR (auditory brainstem response)** can be carried out, even before language development (still in infancy), to test the function of the inner ear and the central processing of impulses of the auditory pathway. For this purpose, the **acoustically evoked potentials (AEP)** ascertained by standardised acoustic stimulation of the inner ear using surface electrodes placed on the scalp, are assessed, including their latency and amplitude.

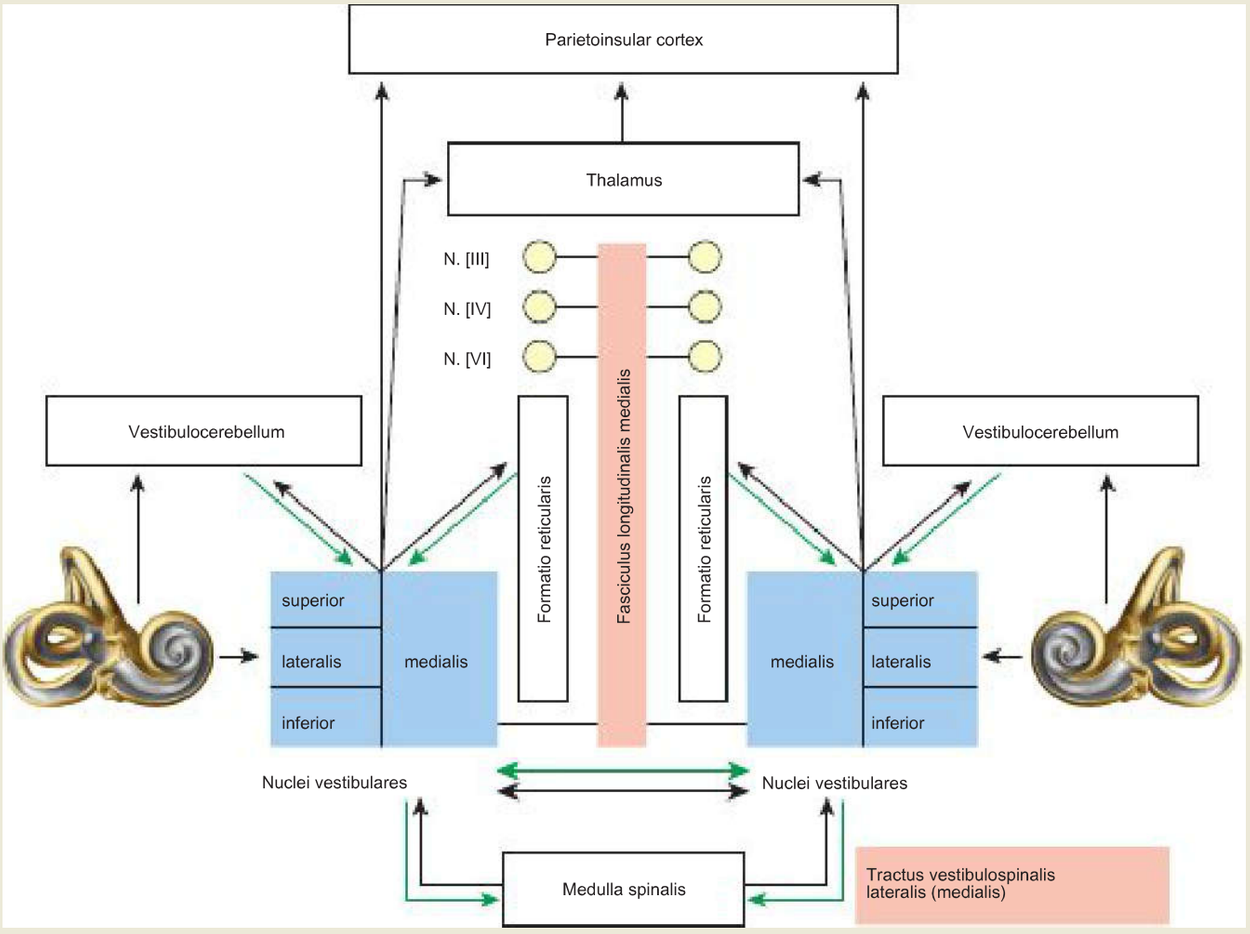

Fig. 10.60 Vestibular system, important afferents and efferents of the Nuclei vestibulares functioning as integration nuclei; schematic drawing. [L126]

The vestibular system registers changes in the body position and/or movement, to maintain the body's balance (→Table). Thereby, the vestibular apparatus in the inner ear registers changes in position and movement. The registered impulses are forwarded not only to the vestibular nuclei in the Medulla oblongata, but also to the cerebellum (Lobus flocculonodularis). Moreover, they are synchronised intensively with proprioceptive impulses generated by the GOLGI tendon organs and muscle spindles, which arrive via the spinal cord at the vestibular nuclei, as well as with information from the optical system (gaze stabilisation). The vestibular nuclei thus form an integration centre, serving to adapt quickly to changes in body position or movement. This takes place subconsciously, without cortical interconnection. To activate awareness, an onward interconnection via thalamus and cortex is necessary. Interestingly, to date no primary cortex area is known that can be assigned to the vestibular system alone. Instead, up to ten areas are under discussion, as being involved in impulse processing (e. g. Sulcus intraparietalis, parietoinsular cortex, somatosensory cortex, hippocampus).

Vestibular System	
Chain of Neurons	**Groups of Neurons**
1st neuron	Ganglion cells in the Ganglion vestibulare
2nd neuron	Nuclei vestibulares superior, lateralis, inferior et medialis in the transition between Pons and Medulla oblongata
3rd neuron	Thalamus (Nucleus posterior ventrolateralis)
4th neuron	Cortex: Sulcus intraparietalis, parietoinsular area, Gyrus postcentralis, BRODMANN's area 7 and hippocampus

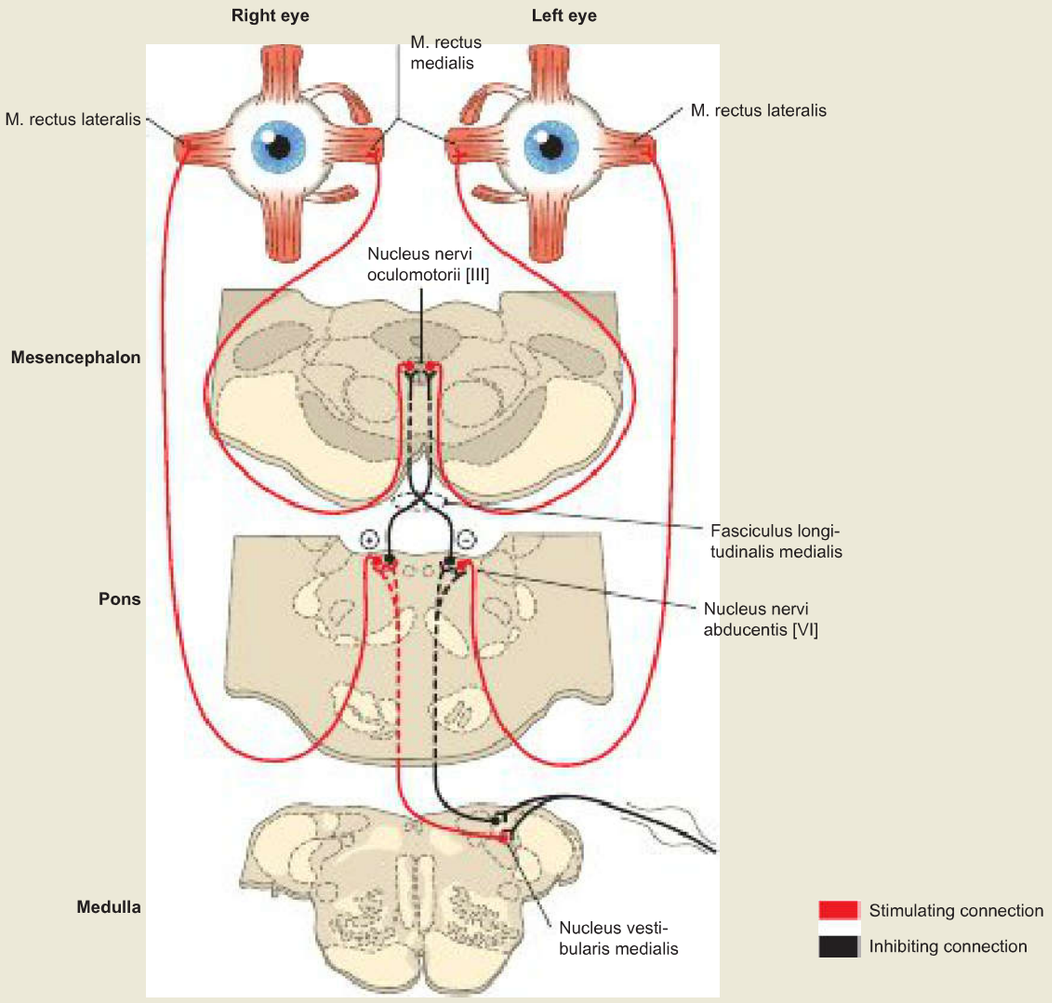

Fig. 10.61 Vestibulo-ocular reflex; schematic drawing. [L127]
The vestibulo-ocular reflex facilitates positional adjustment of the eyes through head movements by connecting the medial vestibular nucleus with the eye muscle nuclei so that the resulting image is projected simultaneously by both eyes onto the Fovea centralis of the retina (site of sharpest vision). In this, Fasciculus longitudinalis medialis of the vestibular system is particularly active (→ Fig. 10.60). Activation of the sensory cells in the Cristae ampullares of the lateral semicircular canal when turning the head (to the left) results in an increased impulse frequency in the left N. vestibularis. Motor neurons of the contralateral Nucleus nervi abducentis are activated via the medial vestibular nucleus, causing the contraction of the M. rectus lateralis (right side). At the same time, interneurons activate the ipsilateral Nucleus nervi oculomotorii, which in turn causes the synchronous contraction of the M. rectus medialis (left side). Via the semicircular canal system of the opposite side, the two muscles acting as antagonists (M. rectus lateralis on the left and the M. rectus medialis on the right) receive opposing commands and thus act antagonistically (they relax).

Clinical Remarks

To objectify any **dizziness** perceived by the patient, and to locate a lesion, the vestibular organ has to be tested. Commonly used tests are **ROMBERG's test** (patient stands up with eyes closed and arms stretched forward) and **UNTERBERGER's step test** (patient walks on the spot with eyes closed) in order to exclude a tendency to fall. Another method is the **nystagmus test** (nystagmus = ocular tremor) using magnifying glasses (FRENZEL's glasses). By nystagmus is meant an uncontrollable, usually horizontal eye movement, characterised by a slow tracking movement and a quick return movement (comparable to eye movements when looking from a moving train). Rapid shaking of the patient's head back and forth by the examiner tests whether a provocation nystagmus can be triggered. This provocation nystagmus test is performed by the examiner in various positions. This would also reveal any latent nystagmus which may be present. The **thermal nystagmus test** is used in testing the labyrinth on either side. For this, the patient is in a supine position with the head slightly elevated in a darkened room and the ear on each side is irrigated with cold and warm water. Cold water hereby physiologically triggers a nystagmus on the opposite side, warm water on the same side. A pathological level of under-excitability or unexcitability on one side suggests a peripheral function impairment.

Practice Exam Questions

To check you are completely familiar with the content of this chapter, practice questions from an oral anatomy exam are listed here.

Explain the structure of the outer ear:

- Outline the development of the outer ear.
- What are auricular hillocks?
- Name some of the characteristic structures on the outer ear.
- What distinguishes the ear lobe from the rest of the outer ear?
- Where is the tragus located?
- Which sorts of things do you look at if you can trigger a tragus pressure pain in a patient?
- Insert your little finger into the ear and open and close the mouth several times. What do you notice?

Describe the external auditory meatus:

- What is the pathway of the external auditory meatus?
- What do you need to do in order to be able to look at the tympanic membrane with an otoscope?
- How is the external auditory meatus constructed? How long is it roughly?
- Which glands are located in the wall of the external auditory meatus? What are their function?

Describe the structure of the tympanic membrane:

- How is the tympanic membrane constructed?
- Outline the development of the tympanic membrane.
- Why is the tympanic membrane clinically divided into quadrants? Which quadrants do you know?
- Why is the front lower quadrant often poorly visible?
- Which structures are located directly behind the tympanic membrane?
- What is the colour of a healthy tympanic membrane, and where is the light reflex?
- How is the tympanic membrane attached?
- Can air penetrate a healthy tympanic membrane?
- How can you test tympanic membrane resistance on yourself?

Explain the structure of the tympanic cavity:

- With what does the tympanic cavity have a positional relationship?
- How big is the tympanic cavity?
- How far is the tympanic membrane from the medial tympanic cavity wall?
- How can the tympanic cavity be divided?
- Which structures are located in the tympanic cavity?
- How is the tympanic cavity ventilated?
- Are the auditory ossicles situated freely in the tympanic cavity?
- Are you aware of any other air-filled spaces in proximity to the tympanic cavity?
- Describe the structure of the auditory ossicles.
- Which muscles are the auditory ossicles attached to?
- What is meant by a consensual reaction in relation to the M. stapedius?
- Why is the Chorda tympani at risk in surgery on the middle ear?
- What is the path of the N. facialis in relation to the tympanic cavity?

Explain the structure of the auditory tube:

- How is the auditory tube structured?
- Which muscles are involved in the tube's function, and how are they innervated?
- The bony part of the auditory tube is also referred to as the Semicanalis tubae auditivae. What is located in the other half (semi-canal)?
- In cases of a cleft palate, what could be the cause of a tube function impairment?

Describe the structure of the inner ear:

- Where in the bony cochlea is the Pars petrosa?
- What is meant by the term 'labyrinth'?
- How is the inner ear supplied with blood?
- Describe sound conduction.
- What is the Ductus endolymphaticus?
- Where are the perikarya of the N. cochlearis located?
- What is the organ of CORTI?
- What are the membranous and the bony labyrinths?
- Where is the round window (Fenestra cochleae)?
- What is the helicotrema?

Explain the auditory pathway and control of equilibrium:

- Describe the path of the auditory pathway.
- Which other nuclear areas is the vestibular organ in contact with?

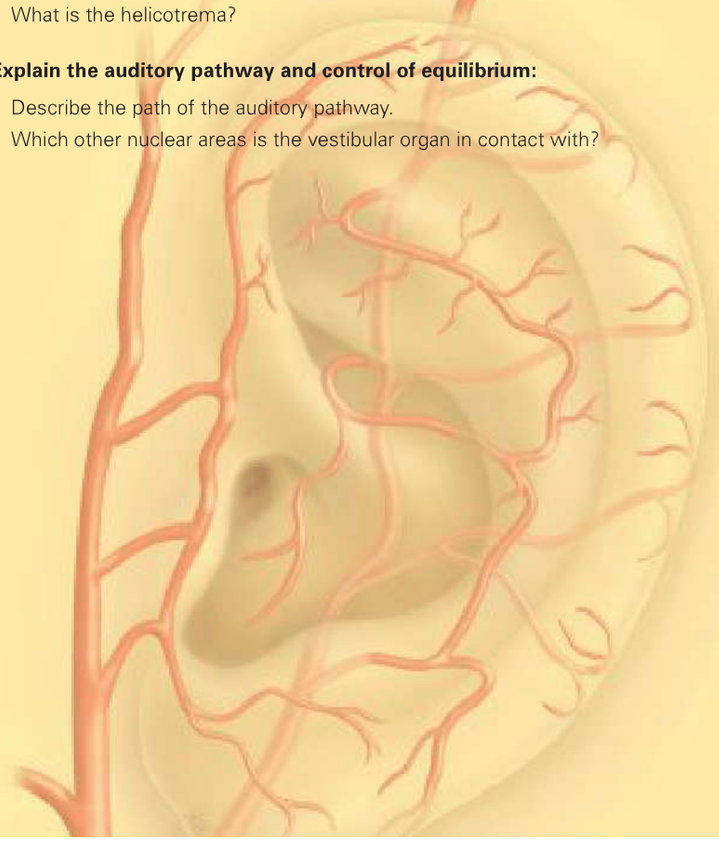

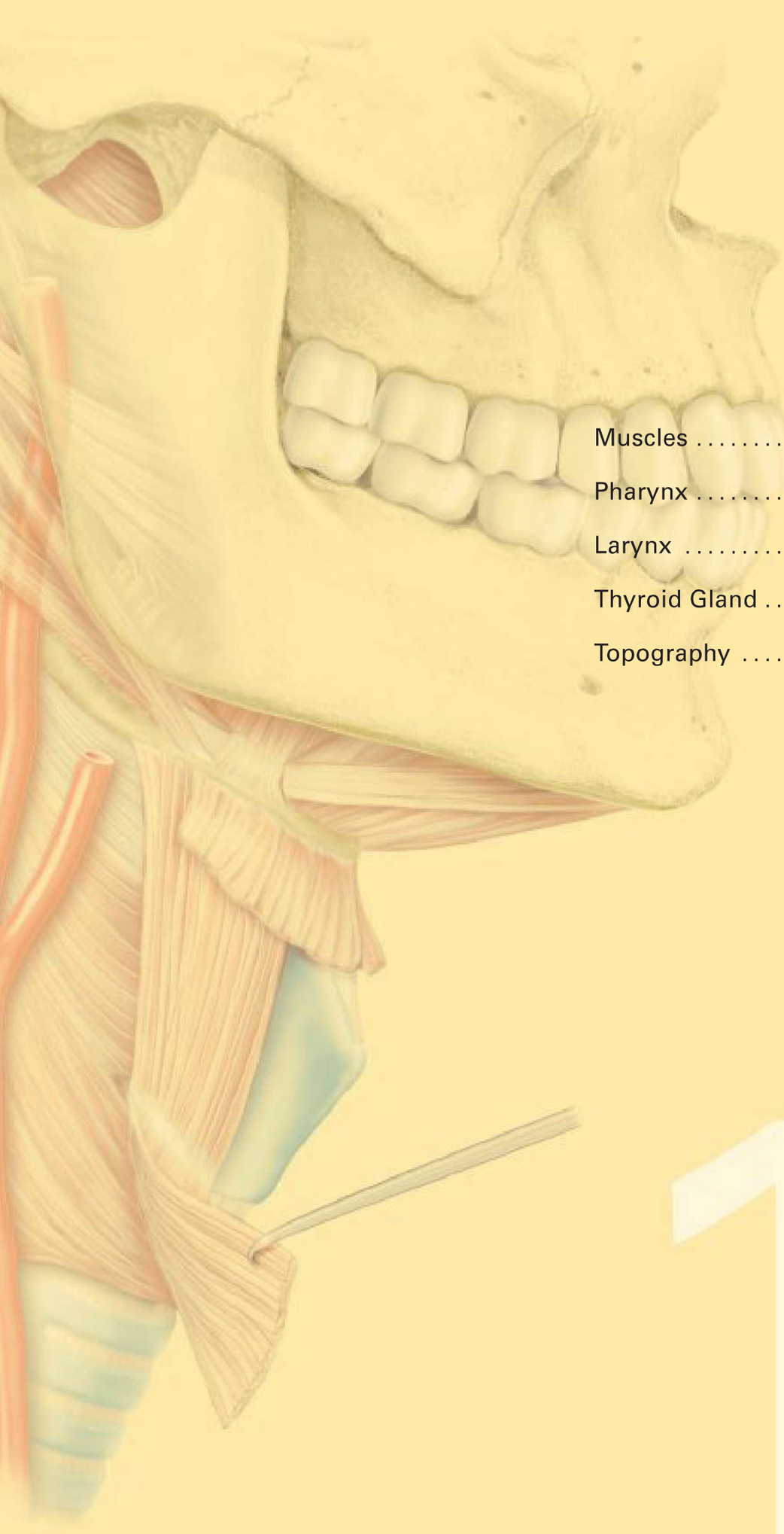

Neck

Muscles 202

Pharynx 213

Larynx 221

Thyroid Gland 234

Topography 240

11

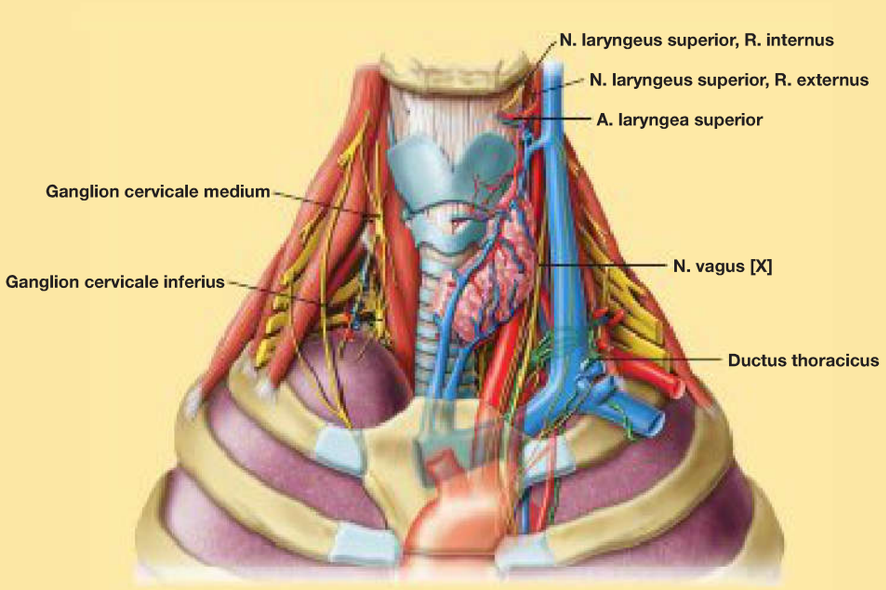

Overview

The **neck** (Collum, Cervix) connects the head with the trunk. The respiratory and digestive tracts, the neurovascular pathways and the central nervous system are somatic connections using the neck as a transit route. An osseous base is provided by the cervical spine, on which the head rests and which allows free rotation relative to the trunk of up to almost 180°. The neck is the location of several specialised organs of the respiratory tract (thyroid gland, parathyroid glands, submandibular salivary glands and larynx). Externally, the neck area can be divided into the anterior, the lateral and posterior cervical regions; the latter is also called the nape region (Nucha). The upper boundary of the neck is formed by the lower rim of the Mandibula, the Proc. mastoideus and the Linea nuchalis superior as far as the Protuberantia occipitalis externa. The neck area extends to the Manubrium sterni, the Clavicula and a connecting line between the Acromion, Spina scapulae and the spinous process of the seventh cervical vertebra. There are many different muscles governing the movement of the head, the skin of the neck and the hyoid bone in the neck, as well as the larynx and the cervical vertebral column. Cervical fascias divide the neck structures into compartments. The external appearance of the neck depends not only on the form-giving structure, the consitutional type of the body and the age, but also in particular on the neck muscles and the amount and distribution of the subcutaneous fatty tissue.

Main Topics

After working through this chapter, you should be able to:

- name the specific structures of the neck and describe the anatomical composition;
- know the boundaries of the neck and correctly name its topographical regions;
- functionally link the passive and active elements of the musculoskeletal system of the neck;
- specify the layers of the cervical fascia, their boundaries and the structures enclosed within;
- name the anatomical spaces of the neck and describe their boundaries;
- classify the neurovascular pathways of the neck and understand what particular areas they innervate or supply;
- name the skeletal elements and ligaments of the larynx;
- describe the laryngeal muscles and their functions;
- explain significant functions of the larynx, its blood supply, lymphatic drainage and innervation;
- classify different levels of the larynx, with internal boundaries and spaces;
- explain terms such as arytenoid and tensioning apparatus or phonation and respiration position;
- locate the blood vessels and nerves of the larynx in relation to the surrounding structures and name important landmarks;
- describe the principles of laryngeal development;
- explain the development of the thyroid and parathyroid glands from the pharynx;
- explain the functions of thyroid and parathyroid glands;
- describe the upper oesophageal constriction and weak muscle triangles at the transition from the throat to the oesophagus.

Clinical Relevance

In order not to lose reference to future everyday clinical life with so many anatomical details, the following describes a typical case that shows why the content of this chapter is so important.

Supraglottic Squamous Cell Carcinoma

Case Study

A 58-year-old bricklayer presents with hoarseness which has persisted for three months,

For hoarseness lasting more than three weeks, an ENT specialist must always be consulted.

a cough, scratchy throat and a hoarse voice at his general practitioner. More recently, occasional pain in his neck is radiating to the right ear. He claims to be suffering with a cold and would like to get medication to help him. The hoarseness does not particularly bother him, but he is also not in the best of health. The general practitioner barely knows the patient. He learns that the patient has been a smoker for many years and likes to drink a beer with his colleagues at work, although this is not permitted. The bricklayer's voice sounds rough, deep and hoarse. He has no difficulty in swallowing, nor any shortness of breath. But he mentions that he has recently lost some weight because he has barely any appetite. He doesn't mind this because he has to lose a little weight anyway.

Secondary symptoms include fever, night sweats and weight loss, and their presence has to be assessed in all patients with cancer.

The general practitioner refers the patient to an ENT specialist to ensure a rapid diagnosis.

Result of Examination

The ENT specialist reads on the referral: hoarseness for three months, exclusion of a laryngeal tumour. After a thorough medical history, he examines the bricklayer carefully (examination of the ears, nose and throat), including the lymph nodes in the ENT area. The laryngoscopy shows an already advanced tumour of the supraglottis with partially ulcerated surface and raised exophytic edge (→ Fig. a). On the right side of the neck at the level of the larynx, the doctor palpates a slightly enlarged lymph node, that is not painful to the touch, in the area of the V. jugularis interna.

Having discussed the findings with the patient, he arranges an appointment in the clinic of the university hospital for taking a sample biopsy which will determine the further steps to be taken in the coming week.

Diagnostic Procedure

At the ENT clinic a microlaryngoscopy is performed under anaesthesia and numerous sample biopsies of the suspected tumour areas are taken, and an endoscopic examination of the other spaces of the upper aerodigestive tract (panendoscopy) is performed to exclude a secondary tumour in another area. The microlaryngoscopy shows that the tumour is limited to the larynx, which is mobile; however, it has already infiltrated the postcricoid region, the right Cartilago arytenoidea and the medial wall of the Sinus piriformis. The pathological findings of the biopsies reveal a slightly horny squamous cell carcinoma. Therefore the patient is submitted to further staging. The X-ray image of the thorax and the ultrasound of the abdomen are normal. A CT (computed tomography) of the neck shows two enlarged and altered cervical lymph nodes on the right-hand side.

Diagnosis

Supraglottic squamous cell carcinoma, right, cT3 cN2b cM0 (→ Fig. a)

Treatment

The choice of treatment will be determined by the tumour size and location, and also the status of the local cervical lymph nodes. Due to the size of the tumour and evidence of lymph node metastases, the patient's larynx must be entirely removed. As part of the primary tumour treatment and to improve the prognosis, a neck dissection in the regional lymphatic drainage area is carried out. To achieve this, the lymph node regions II, III and IV are removed (→ Fig. 11.85) on the right side of the neck.

Further Developments

The complete resection of the larynx (laryngectomy) is a major operation. The larynx allows not only the articulation of sounds and voice, but also separates the respiratory tract from the digestive tract when swallowing. As part of a laryngectomy, a lasting tracheostomy is created, meaning that the trachea opens to the outside in the area of the Fossa jugularis. This means that the respiratory and digestive tracts are completely separated from each other. The patient can no longer breathe through the nose.

Dissection Lab

Malignant tumours of the larynx are the fifth most common malignant tumours worldwide and hence not a rare finding. In dissection classes, great importance should therefore be placed on understanding the regional lymph nodes in the neck, since they should be assessed during any physical examination.

Imagine during dissection that you are carrying out your first neck dissection. Pay attention to the topography of the blood vessels and nerves.

In addition, the division of the larynx into the supraglottis, glottis and subglottis is essential, especially for diagnostic imaging in the context of tumour staging and so indispensable for any subsequent choice of treatment. From the location of the tumour, it is easy to understand why tumours of the glottis as compared, for example, to carcinomas of the supraglottis, are often identified at an early stage (leading symptom: hoarseness).

Back in the Clinic

A total laryngectomy causes the patient to lose his voice. For the bricklayer, this is actually 'the worst thing of the whole operation', as he writes to the speech therapist on a piece of paper. Patients who have undergone a laryngectomy can acquire a 'replacement voice' by means of various voice replacement procedures as part of their voice rehabilitation. One method of voice replacement is the oesophageal speech method.

The oesophageal speech is also colloquially referred to as a 'ructus voice'.

Through a variety of exercises in the area of the oesophageal entrance, a bulge of the mucous membrane develops, which takes over the function of the former vocal cords. The replacement voice can then be achieved by voluntarily controllable movements of air in the oesophagus and by the newly formed bulge of the Plica vocalis. Other methods favour voice prostheses for patients.

Fig. a Supraglottic carcinoma of the larynx, right side, that can be well detected by the viewer on the epiglottis. [T872]

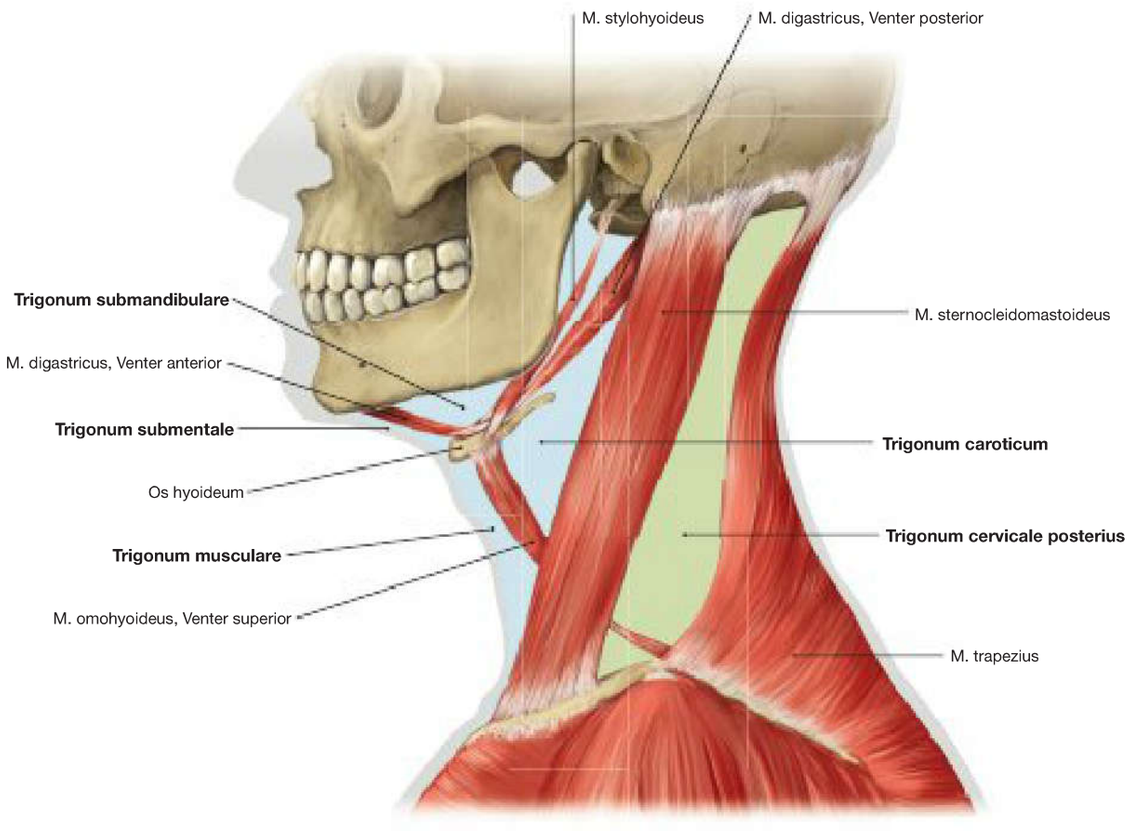

Fig. 11.1 Anterior and lateral regions of the neck; Regiones cervicales anterior et lateralis, left side; lateral view. [L266]
Boundaries of the **anterior triangle of the neck** (Regio cervicalis anterior [Trigonum cervicale anterius]) are the lower rim of the mandible, the anterior rim of the M. sternocleidomastoideus, and the Linea mediana cervicis. Located within the anterior triangle of the neck are the Trigonum submandibulare (margins: mandible, Venter anterior and Venter posterior of the M. digastricus), the Trigonum submentale (margins: Os hyoideum, Venter anterior of the M. digastricus, Linea mediana cervicis), the Trigonum musculare (margins: Os hyoideum, Venter superior of the M. omohyoideus, M. sternocleidomastoideus, Linea mediana cervicis), and the Trigonum caroticum (margins: Venter superior of the M. omohyoideus, the lowest part of the M. stylohyoideus, Venter posterior of the M. digastricus, M. sternocleidomastoideus).
Boundaries of the **posterior triangle of the neck** (Regio cervicalis posterior [Trigonum cervicale posterius]) are the posterior rim of the M. sternocleidomastoideus, the anterior rim of the M. trapezius, the upper rim of the Clavicula and the Os occipitale.

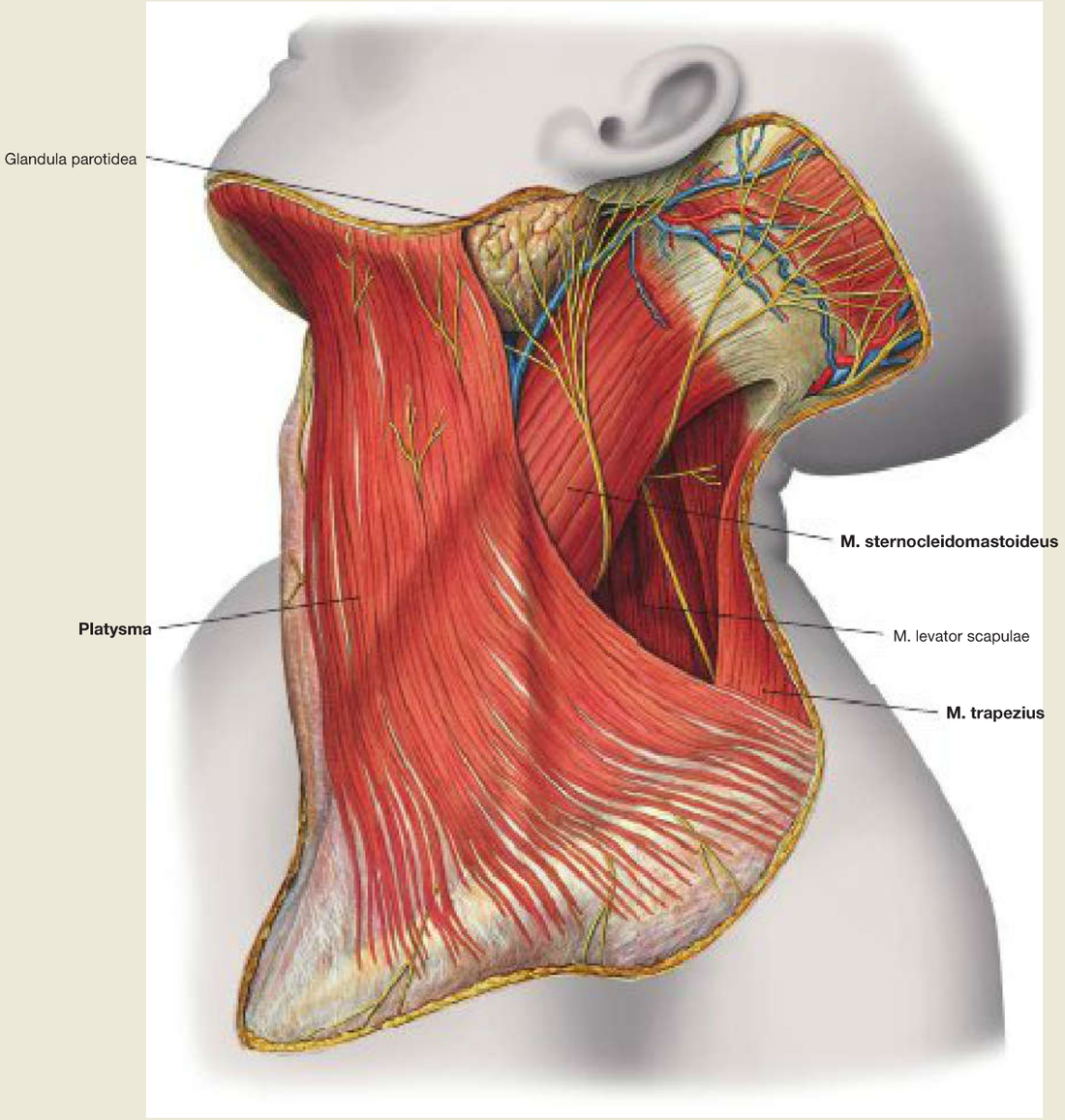

Fig. 11.2 Muscles of the anterior and lateral neck regions, Regiones cervicales anterior et lateralis, superficial layer, left side; lateral view.
On the surface, the platysma (a mimetic muscle without fascia) forms a thin muscular layer located directly under the skin and extends from the Mandibula via the Clavicula to the thorax. Lateral to the rear, the superficial cervical fascia has been removed. You can see the upper part of the M. sternocleidomastoideus, which serves as a reference structure in surgery, and behind underneath the anterior rim of the M. trapezius. The lower pole of the Glandula parotidea, which lies between the platysma and the M. sternocleidomastoideus, can extend into the neck region to a variable degree. The M. levator scapulae can be identified deep in the posterior triangle of the neck.

→ T 1f, 8

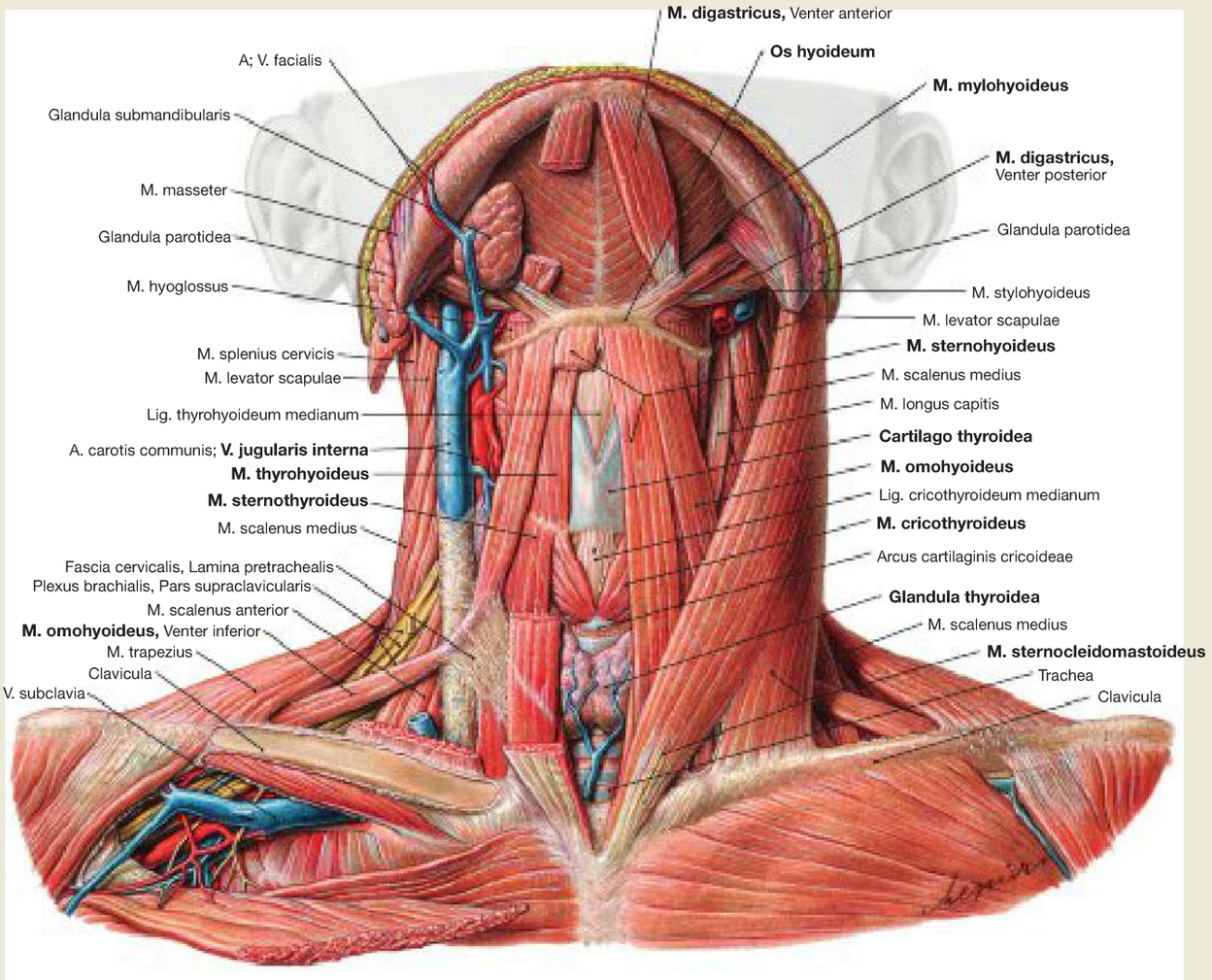

Fig. 11.3 Neck muscles, Mm. colli; ventral view; chin elevated.
Superficially, the M. sternocleidomastoideus runs from its two origins (Caput sternale and Caput claviculare) to the Proc. mastoideus. Its caudal part covers the origin of the **infrahyoid muscles** with the Mm. sternohyoideus, sternothyroideus, thyrohyoideus and omohyoideus, which stretch between the sternum, thyroid cartilage, hyoid bone, and scapula (M. omohyoideus). The M. omohyoideus is composed of two bellies separated by an intermediate tendon affixed to the connective tissue of the carotid sheath (Vagina carotica) and serves to keep the lumen of the V. jugularis interna open. From bottom to top under the infrahyoid muscles can be seen the isthmus of the thyroid gland, the paired M. cricothyroideus (an outer laryngeal muscle), the thyroid cartilage and the hyoid bone. Above the hyoid bone, the floor of the mouth is formed by the M. mylohyoideus.

→ T 8–11

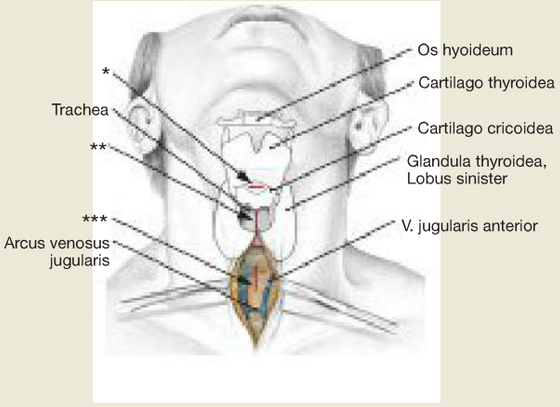

Fig. 11.4 Surgical access to the trachea; ventral view; neck hyperextended dorsally.
In the **coniotomy,** the Lig. cricothyroideum medianum (Lig. conicum, → Fig. 11.32) is separated between the thyroid and cricoid cartilages. In doing so, the inner space of the larynx is reached just below the vocal folds.
For a **tracheotomy,** there are three possible access routes: (i) an upper access above the isthmus of the thyroid gland, (ii) a middle access route by cutting through the isthmus, and (iii) a lower access below the isthmus of the thyroid gland (→ Fig. 11.50).

* coniotomy
** upper tracheotomy
*** lower tracheotomy

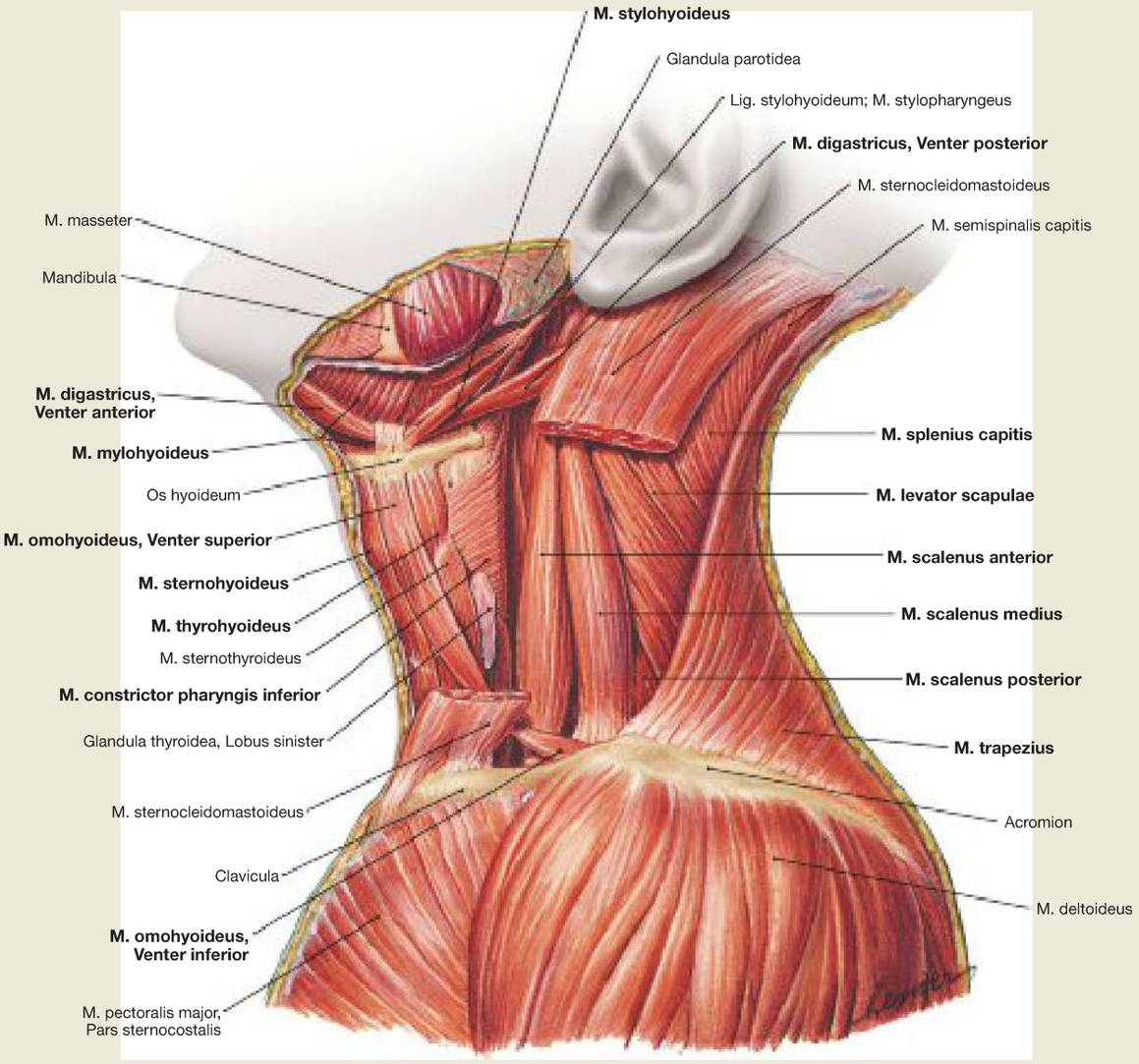

Fig. 11.5 Neck muscles, Mm. colli; lateral view.
All muscle fascias, the platysma and the middle portion of the M. sternocleidomastoideus were removed. From anterior to posterior the following structures can be seen: the **infrahyoid muscles** with the M. sternohyoideus, M. omohyoideus (Venter superior; the Venter inferior runs above the Clavicula in the lateral triangle of the neck), Mm. thyrohyoideus and sternothyroideus, parts of the pharyngeal muscles (M. constrictor pharyngis inferior), the Mm. scaleni (anterior, medius and posterior), the M. levator scapulae, the M. splenius capitis, and the M. trapezius. Above the hyoid bone, three **suprahyoid muscles** can be seen (M. digastricus with its Venter anterior and Venter posterior, M. mylohyoideus and M. stylohyoideus).

→ T 8–11

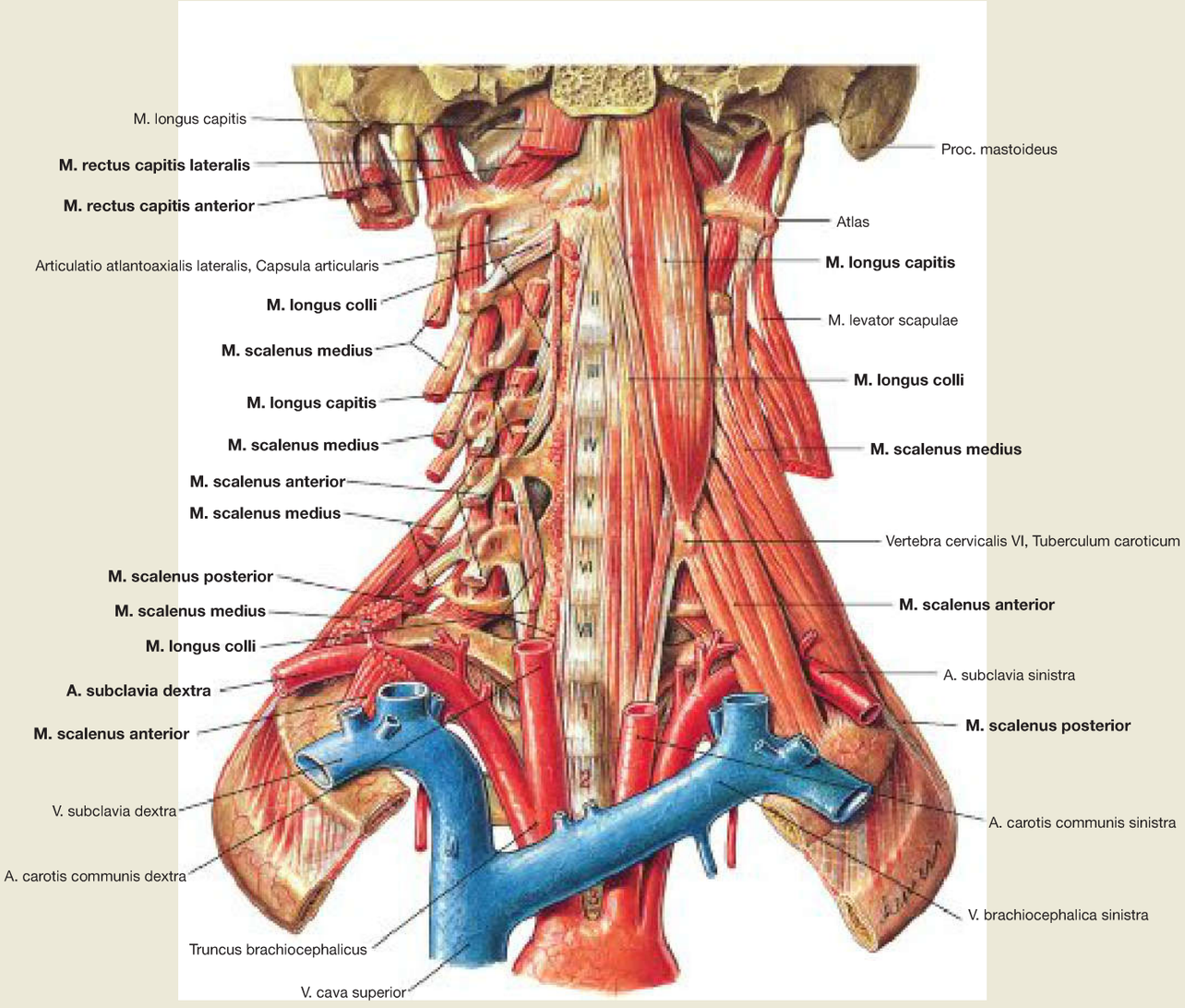

I–VII = 1st–7th cervical vertebrae
1–3 = 1st–3rd thoracic vertebrae

Fig. 11.6 Prevertebral muscles and Mm. scaleni; ventral view.
The **prevertebral muscles** are located on both sides of the vertebral bodies of the cervical and upper thoracic vertebral column and are covered by the Lamina prevertebralis of the Fascia cervicalis. The anterolateral parts of the atlas and axis are linked via the short M. rectus capitis anterior. In addition to the M. rectus capitis anterior, the M. longus capitis and the M. longus colli, are prevertebral muscles. The M. rectus capitis lateralis belongs to the ventrolateral muscles, having migrated into the prevertebral region.
The **Mm. scaleni** anterior, medius and posterior insert at the first ribs and form a triangular-shaped muscle plate in the lateral region of the cervical vertebral column. The Mm. scalenus anterior and scalenus medius, together with the upper rim of the first rib form the **scalene hiatus,** through which pass the A. subclavia and the Plexus brachialis (not shown).
Some authors distinguish between an anterior and a posterior scalene hiatus. The anterior scalene hiatus represents the course of the V. subclavia in front of the M. scalenus anterior across the first rib, whereas the posterior scalene hiatus represents the passage of the A. subclavia and Plexus brachialis running between the Mm. scaleni anterior and medius over the first rib. Because the so-called 'anterior' scalene hiatus is not a real gap, one should only refer to the space between the M. scalenus anterior and M. scalenus medius – as scalene hiatus.

→ T 11, 12

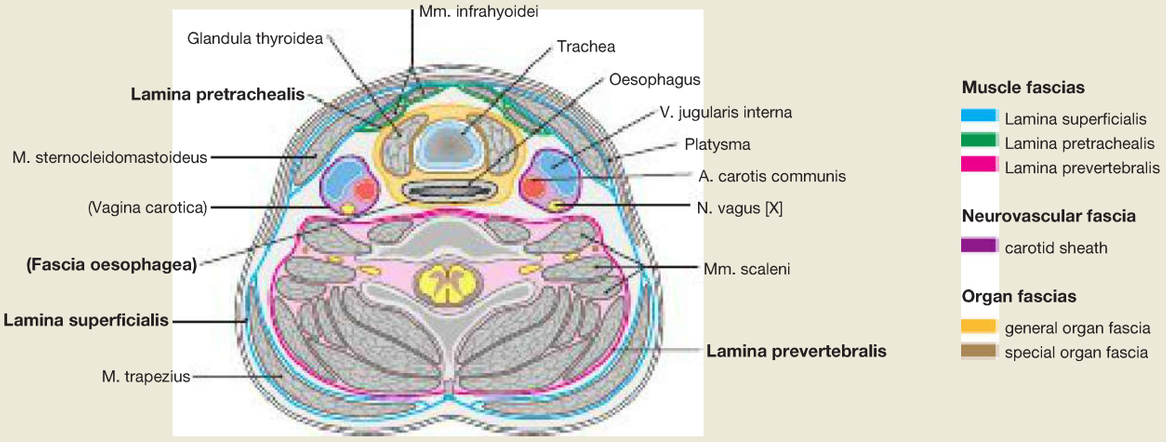

Fig. 11.7 Cervical fasciae, Fasciae cervicales; cross-section through the neck. [L126]
A distinction is made between a muscle fascia with three laminae, a neurovascular fascia, and an organ fascia which has two laminae.

Muscle fascias:
- Lamina superficialis (superficial lamina, encases the whole neck and ensheathes the M. sternocleidomastoideus as well as the Mm. levator scapulae and M. trapezius in the neck region)
- Lamina pretrachealis (middle lamina, surrounds infrahyoid muscles)
- Lamina prevertebralis (deep lamina, ensheathes the Mm. scaleni, prevertebral muscles, M. rectus capitis lateralis and merges with the fascia of intrinsic [autochthonous] muscles of the back)

Neurovascular fascia:
- carotid sheath (ensheathes the Aa. carotides communis, interna and externa and V. jugularis interna, N. vagus [X])

Organ fascias:
- general organ fascia (envelops all viscera of the neck like the pharynx, larynx, thyroid gland, parathyroid glands, upper part of the trachea, and oesophagus with Pars cervicalis)
- special organ fascia = organ capsule (encases all organs of the neck, e. g. Fascia oesophagea)

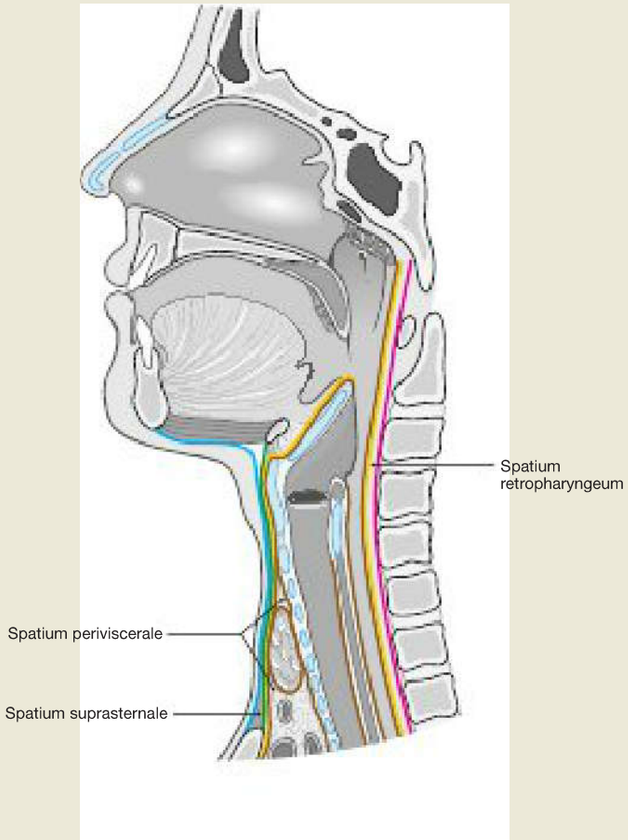

Fig. 11.8 Schematic drawing of the cervical fascias, Fasciae cervicales; sagittal section through the neck at the level of the larynx. [L126]
Above the sternum, the Spatium suprasternale is located between the superficial and middle cervical fascias, and ventrally, the Spatium periviscerale is located between the middle cervical fascia and general organ fascia. The Spatium retropharyngeum (→ Fig. 11.16) is located prevertebrally between the general organ fascia and the deep layer of the cervical fascia.

Cervical Fascias

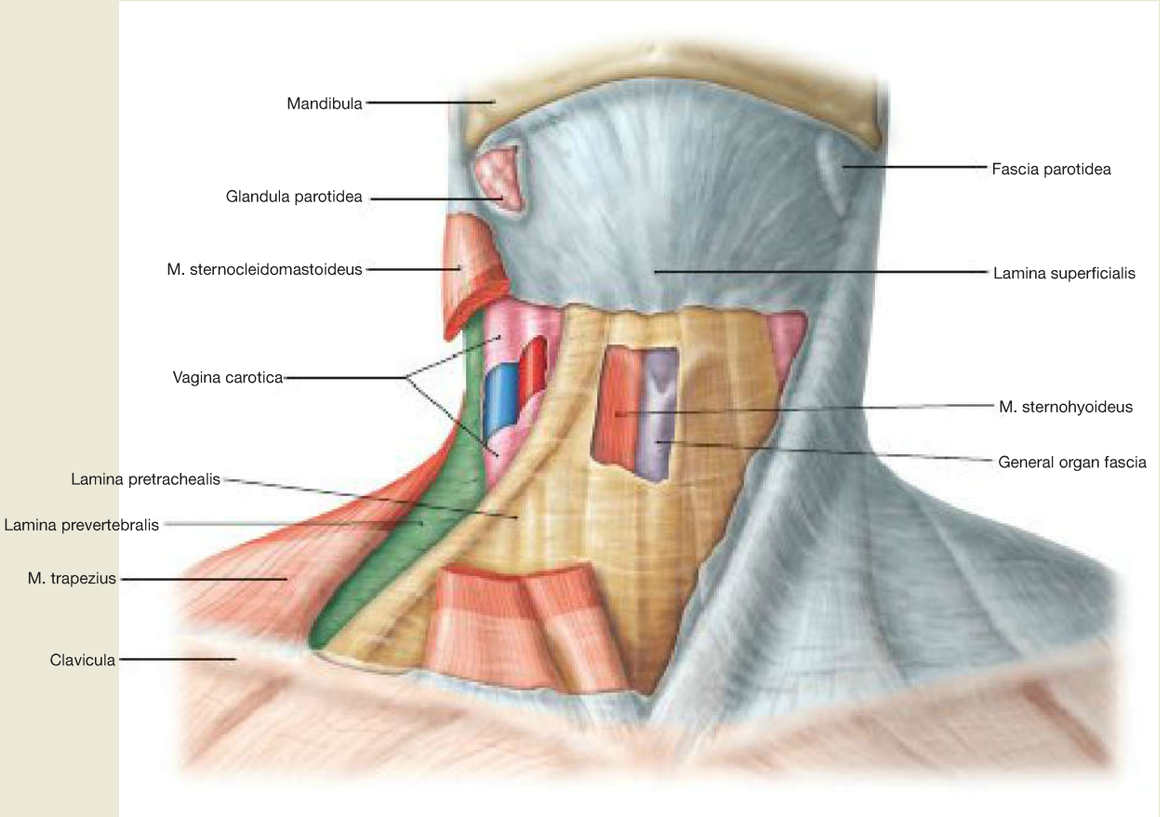

Fig. 11.9 Muscle fascias of the neck, Fasciae cervicales; ventral view. [L238]
The platysma was removed bilaterally. On the right side, the Lamina superficialis of the Fascia cervicalis is intact and forms a sheath around the M. sternocleidomastoideus. On the left side, most of the muscles and the Lamina superficialis of the Fascia cervicalis have been resected. Above the larynx, a small part of the middle cervical fascia was removed to demonstrate the M. sternohyoideus, a muscle normally ensheathed by the middle cervical fascia, and the general organ fascia located below. At the posterior margin of the M. omohyoideus, you can see the fenestrated carotid sheath as well as the deep cervical fascia.

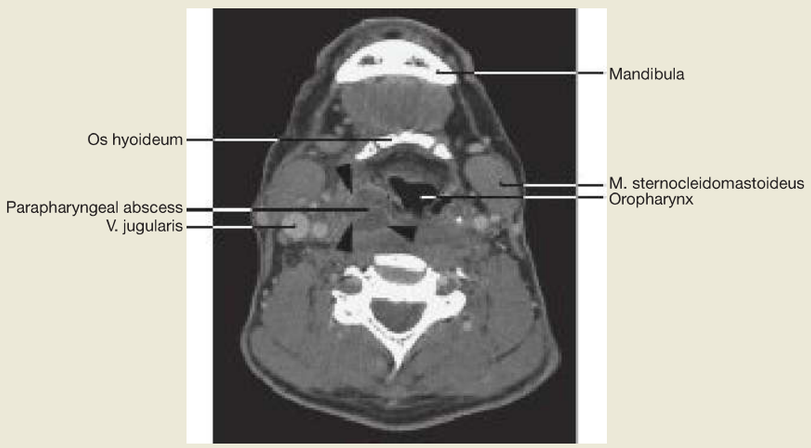

Fig. 11.10 Parapharyngeal abscess, left side; ventral view. [R242]
The abscess extends along the anatomically defined space (Spatium lateropharyngeum) in the cervical region (black arrow tips).

Clinical Remarks

Within the context of neck operations (e.g. neck dissections) the laminae of the cervical fascia and the areas of connective tissue delimited by them serve as reference structures. Between the fascial laminae bleeding and abscesses can spread within the connective tissue and caudally into the mediastinum **(descending abscess).**

The weakness of the walls of the pharynx favours an invasion of microorganisms, most commonly into the parapharyngeal and retropharyngeal spaces **(parapharyngeal** [peripharyngeal], → Fig. 11.10, or **retropharyngeal abscess).**

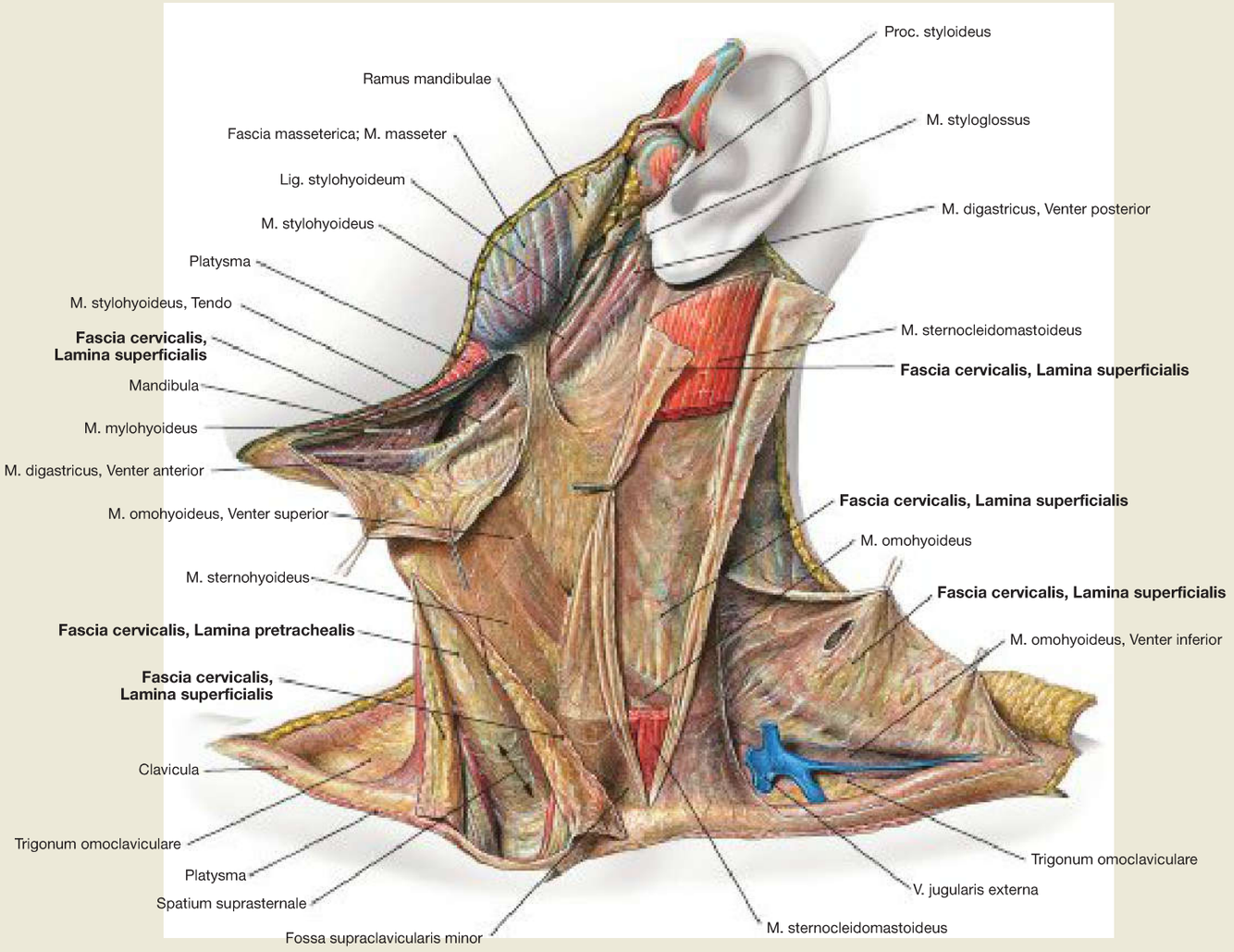

Fig. 11.11 Cervical fascia, Fascia cervicalis, left side; ventral view. The superficial lamina of the cervical fascia (Fascia cervicalis, Lamina superficialis) has been opened or removed in several places. The superficial lamina of the cervical fascia covering the M. sternocleidomastoideus has also been opened and the middle portion of the M. sternocleidomastoideus has been resected. Thus, the fascial sheath and the deep part of the superficial fascia become visible. Above the Incisura jugularis of the sternum, the superficial fascia has been slit down to the Adam's apple of the larynx and has been folded back to the side. Thus the Spatium suprasternale is opened. Upon removal of the adipose tissue (the Arcus venosus jugularis can frequently be found here, → Fig. 11.71), the pretracheal (middle) lamina of the cervical fascia becomes visible, which forms the posterior wall of the Spatium suprasternale. The superficial lamina of the cervical fascia is also removed down to the mandible and folded back. Below this lamina, the tendon of the M. stylohyoideus, the M. mylohyoideus and the Venter anterior of the M. digastricus can be recognised. In the posterior triangle of the neck, the superficial cervical fascia has been removed from the Clavicula and folded upwards. Underneath, the V. jugularis externa can be seen, as well as an indication of the Venter inferior of the M. omohyoideus, which is ensheathed by the middle cervical fascia.

Pharyngeal Muscles

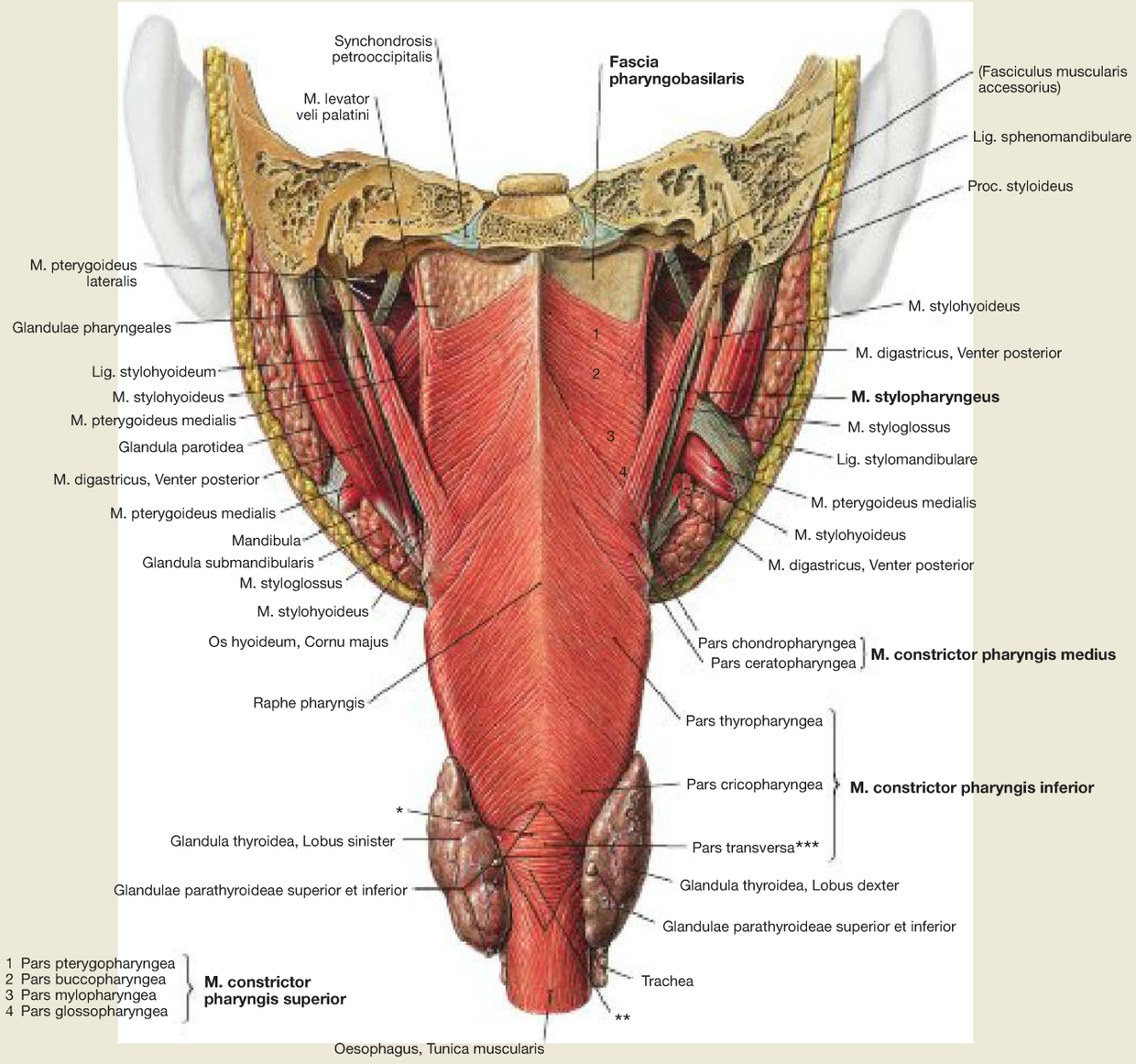

Fig. 11.12 Pharyngeal muscles, Mm. pharyngis; dorsal view.
The pharyngeal muscles (Tunica muscularis pharyngis) consist of the pharyngeal constrictors (Mm. constrictores pharyngis) and three pairs of pharyngeal levator muscles (Mm. levatores pharyngis). In the muscle-free upper part of the pharyngeal wall, the Tela submucosa and Tunica adventitia combine to form the Fascia pharyngobasilaris. The constricting and elevating pharyngeal muscles mainly act during swallowing, choking, and speaking and singing.
The **Mm. constrictores pharyngis** superior, medius and inferior consist of different parts, enclosing the pharyngeal lumen in a horseshoe shape, and overlapping one another, with the inferior muscle slightly covering the lower margin of the superior muscle. The Pars cricopharyngea of the M. constrictor pharyngis inferior is composed of two muscle parts which together form a triangle which is weak in muscle fibres (KILLIAN's dehiscence, also known as KILLIAN's triangle). Dorsally, at the transition from the Pars fundiformis of the M. constrictor pharyngis inferior to the oesophagus there is also a muscle triangle (LAIMER's triangle), formed by radiating oesophageal muscle fibres. The tip of the LAIMER's triangle points in the opposite direction to the tip of the KILLIAN's triangle. The Pars fundiformis (of the Pars cricopharyngea of the M. constrictor pharyngis inferior) forms the basis for both triangles.
The muscles elevating the pharynx are the **Mm. palatopharyngeus, salpingopharyngeus** and **stylopharyngeus.**

* KILLIAN's triangle
** LAIMER's triangle
*** Pars fundiformis of the Pars cricopharyngea (KILLIAN's muscle)

→T 5

Clinical Remarks

The muscle-weak KILLIAN's triangle can be a vulnerable point, particularly in elderly men of advanced age. Due to increased intraluminal pressure, the pharyngeal wall bulges out through the muscular weak point as a **pharyngeal diverticulum** (ZENKER's diverticulum) into the retropharyngeal space. It can be filled with chewed food, which leads to regurgitation (reflux) of undigested food into the oral cavity.

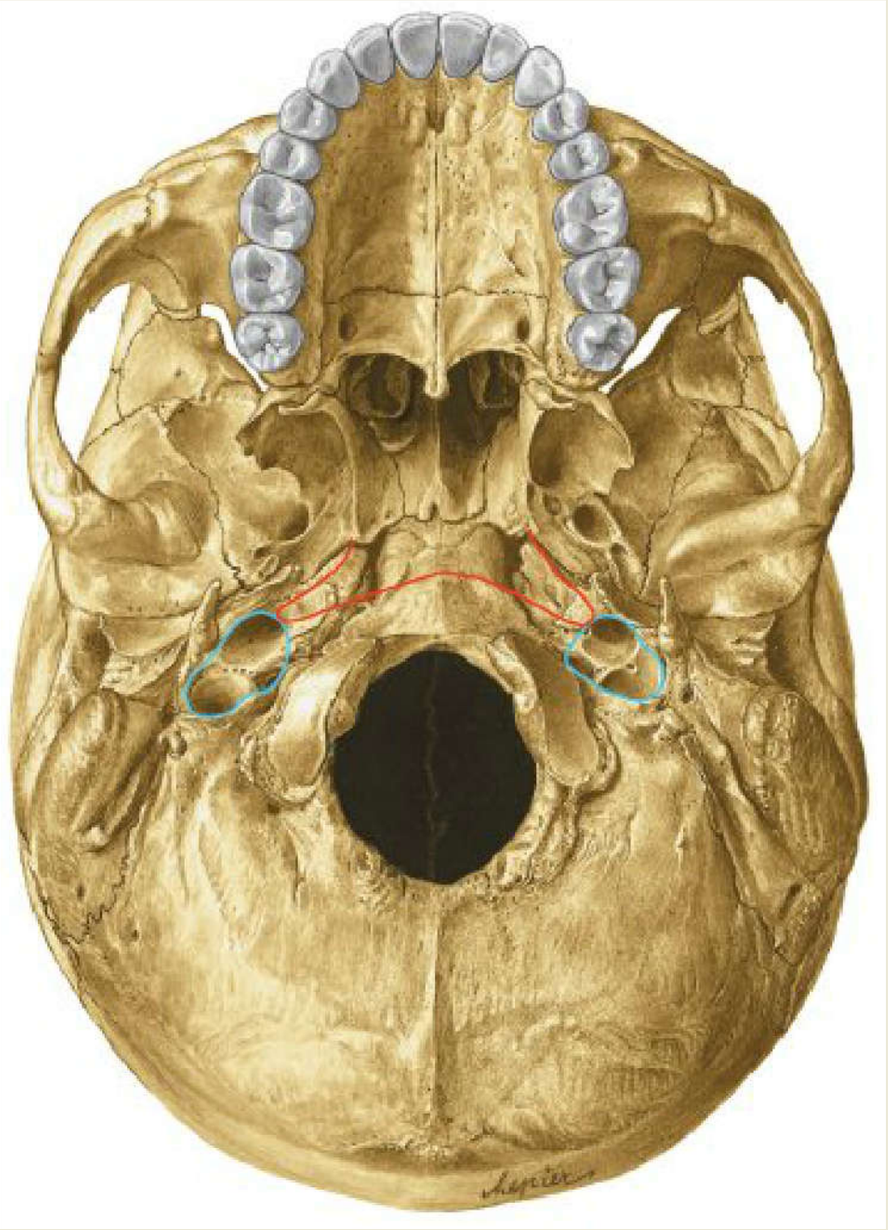

Fig. 11.13 Base of the skull, Basis cranii externa, with attachment zone of the Fascia pharyngobasilaris and passageways to the Spatium lateropharyngeum; caudal view.
The pharynx is suspended by the **Fascia pharyngobasilaris** (red line), located immediately in front of the cervical vertebral column. The Fascia pharyngobasilaris is therefore located directly in front of the occipital condyles, and is laterally attached to the cranial base along the border between the Os sphenoidale and Os occipitale. Lateral to these structures, the passageways of the A. carotis interna, V. jugularis, N. glossopharyngeus [IX], N. vagus [X], N. accessorius [XI] and of the Truncus sympathicus are visible (as the Plexus caroticus internus), which pass through the cranial base (→ Fig. 11.19, → Fig. 11.20 and → Fig. 11.21) on their way out of the Spatium lateropharyngeum (blue circles) or into it.

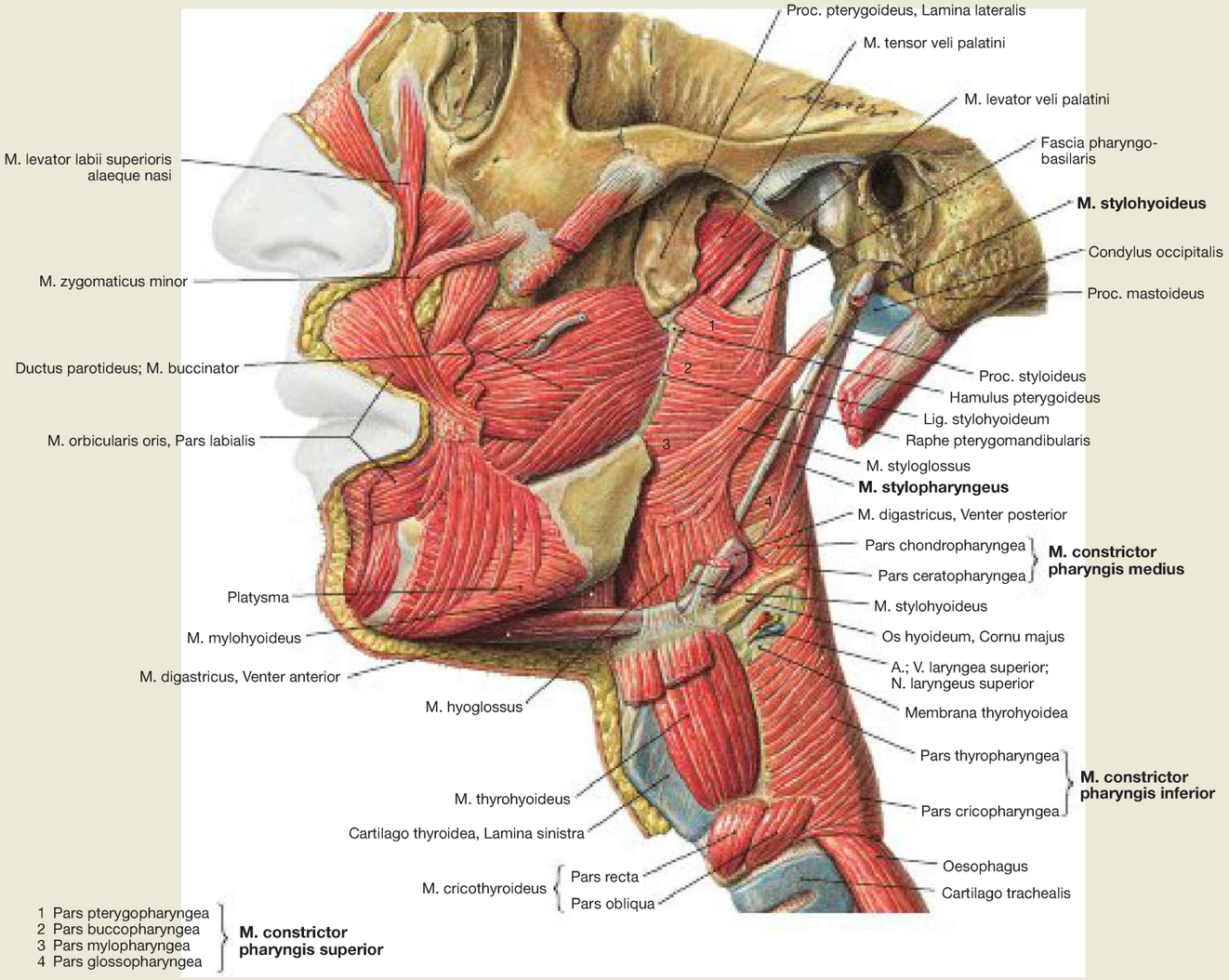

Fig. 11.14 Pharyngeal muscles, Mm. pharyngis, and facial muscles, Mm. faciei, left side; lateral view.
The pharyngeal muscles divide into constrictor muscles (Mm. constrictores pharyngis superior, medius and inferior) and levator muscles (Mm. stylopharyngeus, salpingopharyngeus and palatopharyngeus). This lateral view displays the different parts of the Mm. constrictores pharyngis and the M. stylopharyngeus.

→T 1e, 5

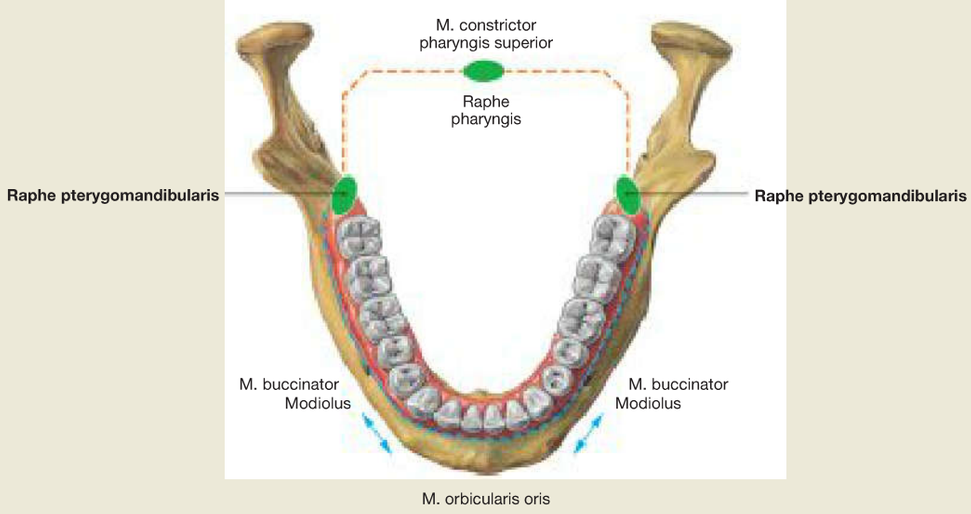

Fig. 11.15 Oropharyngeal muscle system; view from above.
The muscles surrounding the oral cavity (M. orbicularis oris, Mm. buccinatores) form together with the upper pharyngeal muscle (M. constrictor pharyngis superior), an opposing muscle system which is crucially important for swallowing. The muscles form a closed ring. Points of attachment are the paired **Raphe pterygomandibularis**, extending between the Proc. pterygoideus (Lamina lateralis), Hamulus pterygoideus and Mandibula, as well as the occipitally located **Raphe pharyngis.**

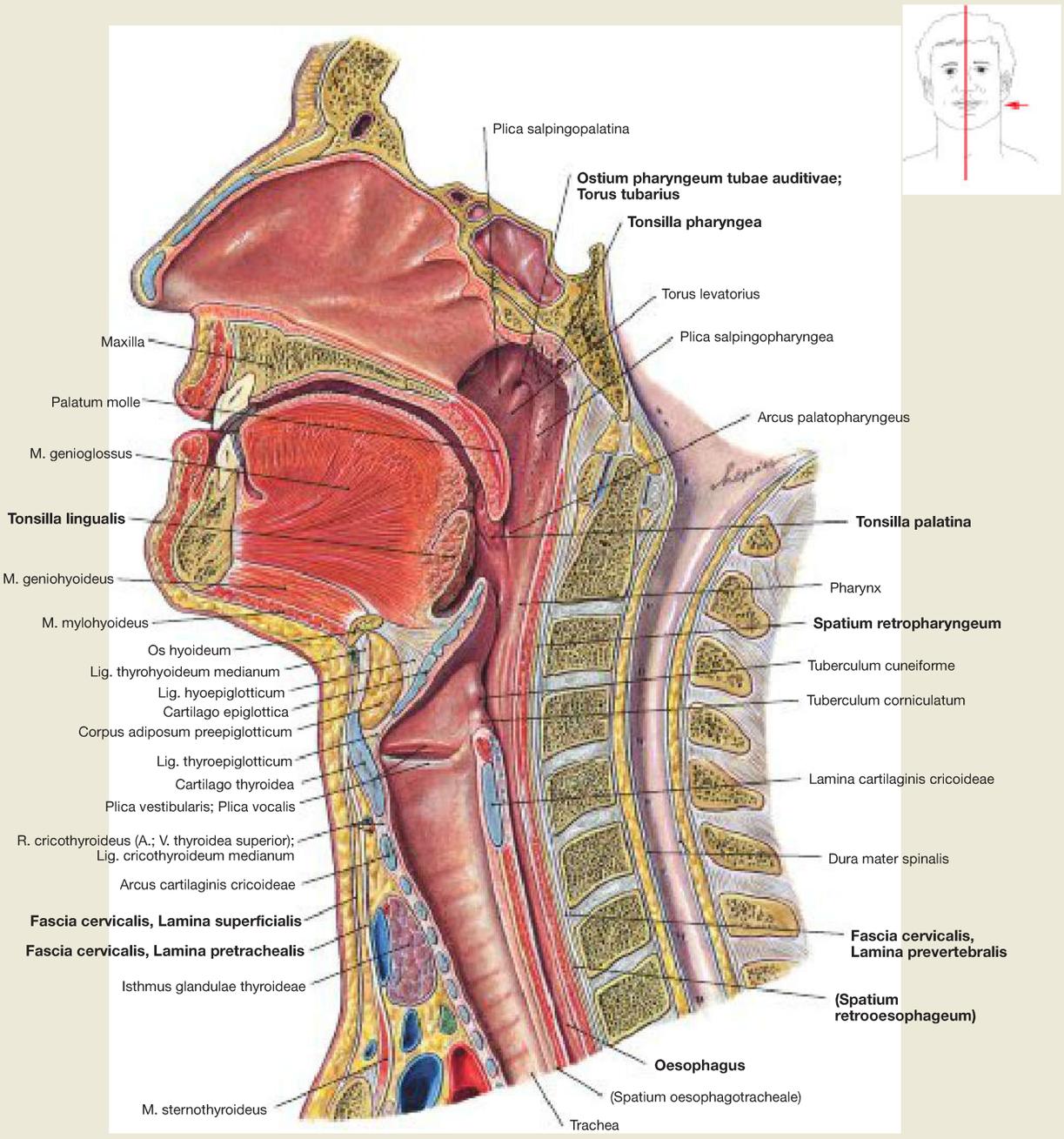

Fig. 11.16 Oral cavity, Cavitas oris, pharynx, and larynx; midsagittal section.
Relationships of the different levels of the pharynx to neighbouring structures:

- The **nasopharynx** connects with the nasal cavity and the middle ear through the choanae and the Tuba auditiva, respectively.
- The **oropharynx** represents the junction between the superior and inferior pharyngeal levels and connects with the oral cavity through the Isthmus faucium.
- The **laryngopharynx** has an anterior connection with the larynx through the Aditus laryngis and transitions caudally into the oesophagus. Respiratory and digestive pathways cross each other within the pharynx.

At the transition from the nasal and oral cavities to the pharynx, the WALDEYER's tonsillar ring is made from lymphoepithelial tissue, which is part of the immune system. It is formed by the Tonsillae pharyngea, tubariae (not shown), palatinae and lingualis, as well as by lateral 'strands' of lymphatic tissue located on the Plicae salpingopharyngeae.

Clinical Remarks

Foreign bodies that are swallowed often end up in the Valleculae epiglotticae at the base of the tongue and can displace the airways by pressure on the epiglottis or lead to **bolus death** (reflexive cardiovascular arrest by vagal stimulation of the sensitive nervous plexus of the pharynx and larynx by a foreign body). This can occur after swallowing a big bite of food (bolus), which becomes jammed in the laryngopharynx so that it can even not be ejected by a forceful cough (expectoration). Smaller, pointed foreign bodies like fish bones or pieces of chicken bone most often get stuck in the Tonsilla palatina.

Levels and Innervation of the Pharynx

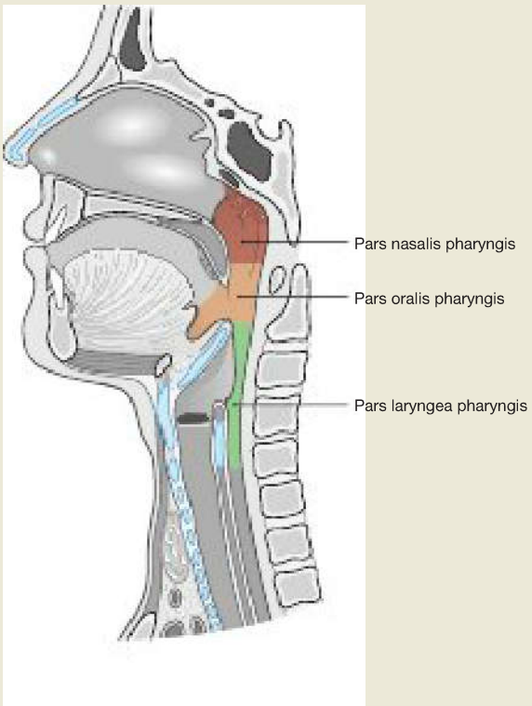

Fig. 11.17 Levels of the pharynx; midsagittal section. [L126]

Corresponding with its openings, the pharynx can be divided into three levels:

- **upper level:** Pars nasalis pharyngis, epipharynx, nasopharynx
- **middle level:** Pars nasalis pharyngis, mesopharynx, oropharynx
- **lower level:** Pars nasalis pharyngis, hypopharynx, laryngopharynx

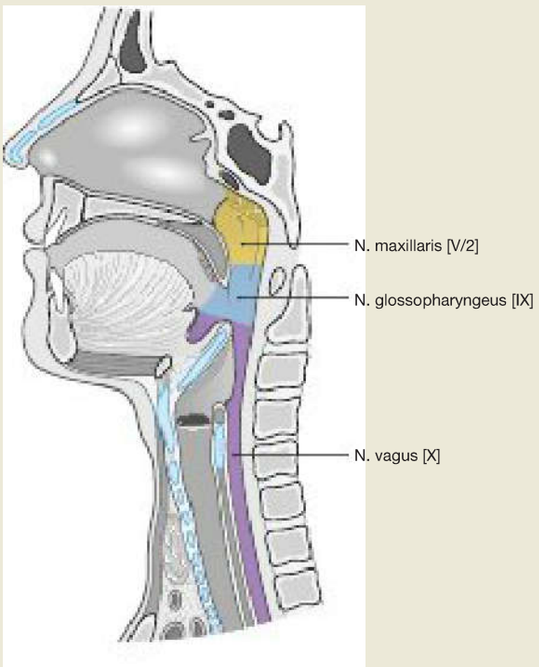

Fig. 11.18 Sensory innervation of the pharynx; midsagittal section. [L126]
Sensory fibres of the second trigeminal branch (R. pharyngeus, a branch of the Rr. ganglionares [Nn. pterygopalatini] of the N. maxillaris [V/2]) contribute to the innervation of the nasopharynx. Branches of the N. glossopharyngeus [IX] and the N. vagus [X] (N. laryngeus superior) innervate the rest of the pharynx. Together with autonomic nerve fibres of the Truncus sympathicus, these fibres form a neuronal network at the outer surface of the pharynx **(Plexus pharyngeus).** Afferent and efferent fibres of the Plexus pharyngeus are part of the vital swallowing and choking reflexes which remain active during sleep. The coordination of these complex reflexes takes place in the Medulla oblongata.

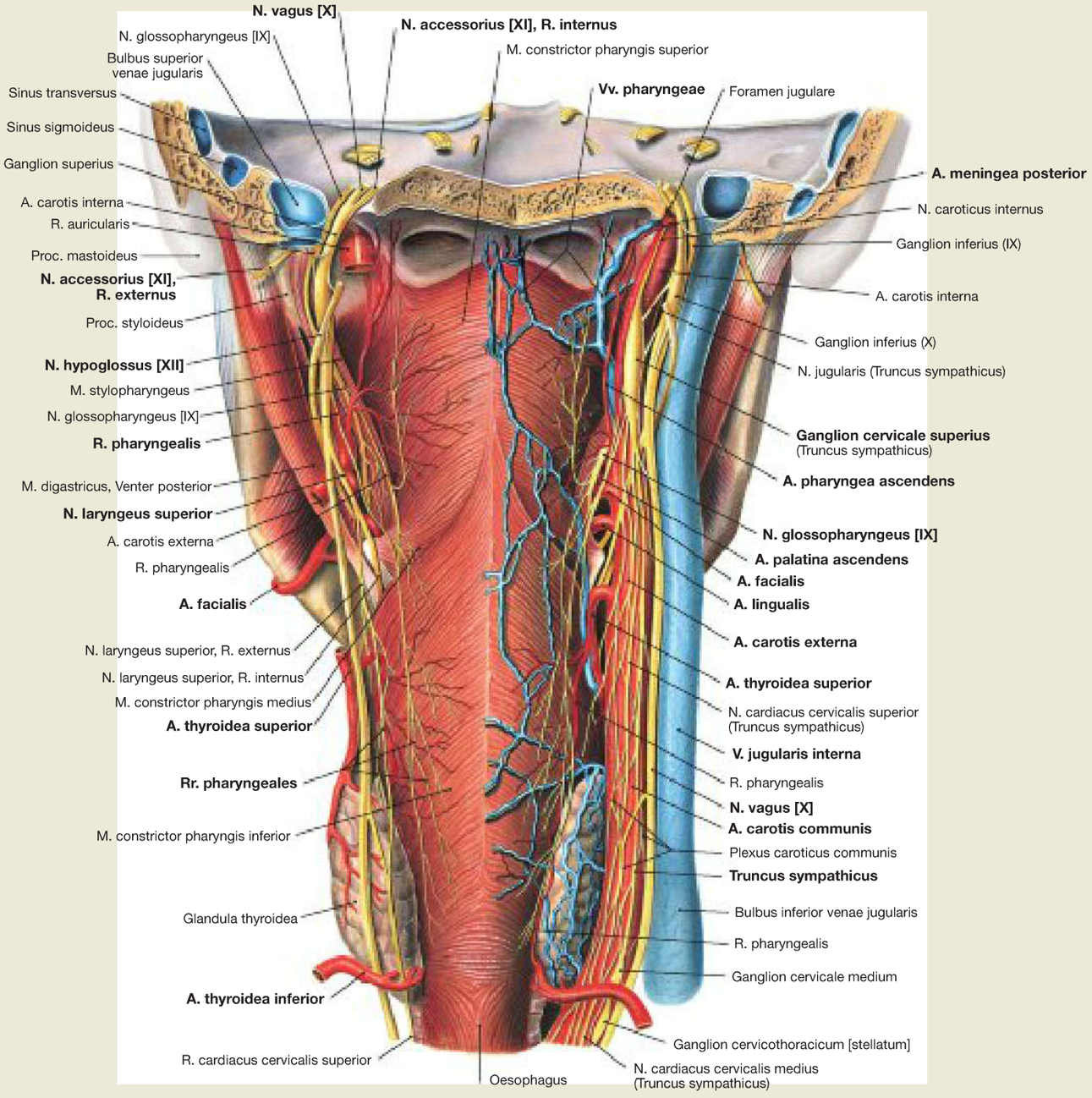

Fig. 11.19 Vessels and nerves of the pharynx and parapharyngeal space, Spatium lateropharyngeum; dorsal view.
The main source of the **blood supply** is the A. pharyngea ascendens. The artery ascends in the parapharyngeal connective tissue, medially to the neurovascular bundle of the neck, to the cranial base. Its terminal branch, the A. meningea posterior, enters the posterior cranial fossa mostly via the Foramen jugulare. Additionally there are inflows in the area of the pharyngeal opening of the auditory tubes via the A. palatina ascendens and into the hypopharynx via the A. thyroidea inferior.
The entire submucosa of the pharynx is surrounded by a venous plexus (Plexus pharyngeus). The **venous draining** occurs via the Vv. pharyngeae into the V. jugularis interna, and in the area of the nasopharynx into the Vv. meningeae.
The **lymphatic drainage** of the Tonsilla pharyngea and the pharyngeal wall is directed to the Nodi lymphoidei retropharyngeales and Nodi lymphoidei cervicales profundi (not shown).
Innervation: In addition to the Plexus pharyngeus and the N. pharyngeus of the N. maxillaris [V/2] (see sensory innervation of the pharynx, → Fig. 11.18 and → Fig. 12.143), the N. glossopharyngeus [IX] provides motor innervation for the superior and some medial constrictor muscles and for the levator muscles of the pharynx; the N. vagus [X] innervates the lower part of the medial pharyngeal constrictor muscle and the M. constrictor pharyngis inferior.

Vessels and Nerves of the Parapharyngeal Space

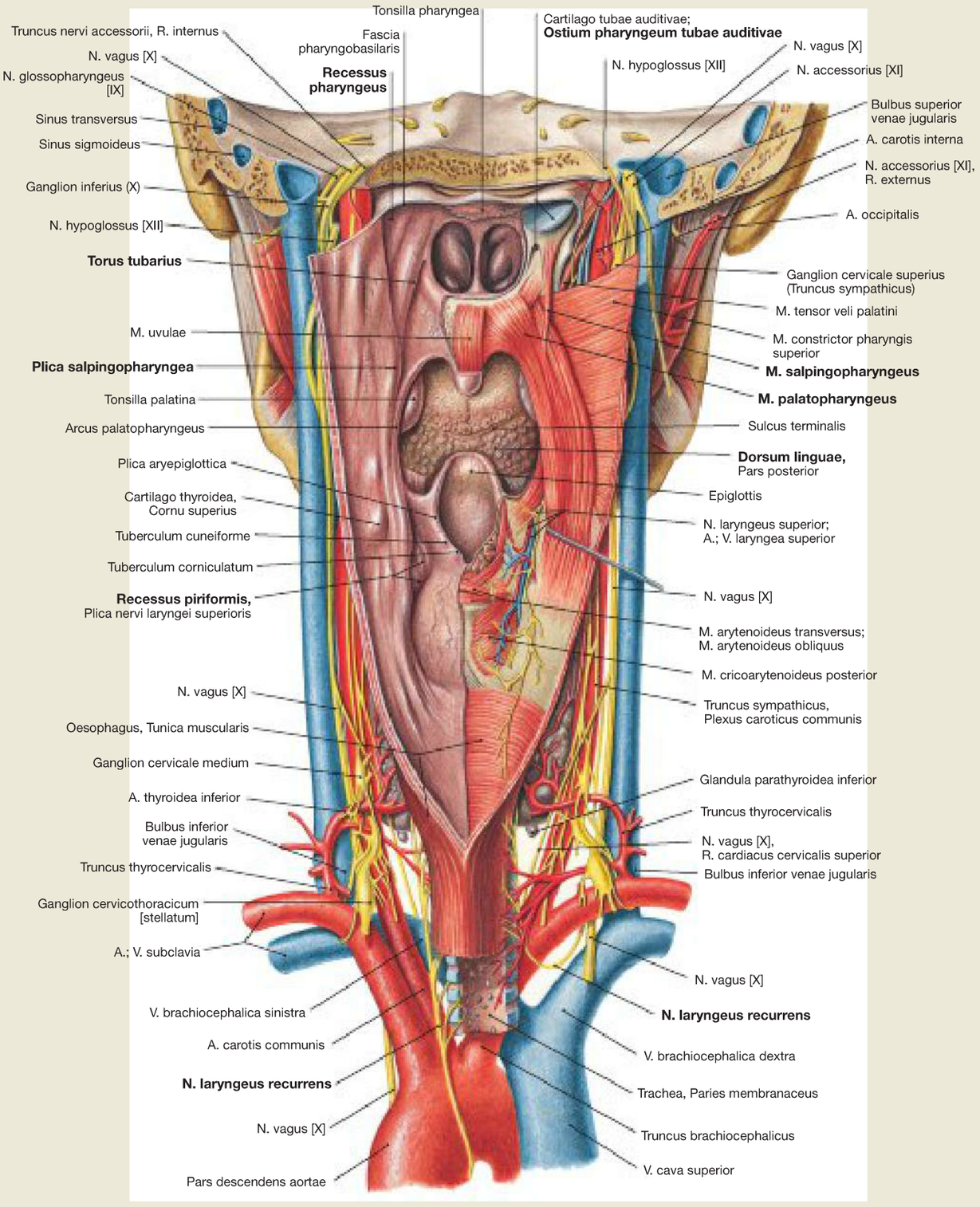

Fig. 11.20 Vessels and nerves of the pharynx and parapharyngeal space, Spatium lateropharyngeum; dorsal view; pharynx opened dorsally.

The opening of the auditory tube (Ostium pharyngeum tubae auditivae) is positioned approximately at the same level as the inferior nasal meatus. It is framed from the back and the top by the torus of the auditory tube **(Torus tubarius).** Caudally, the Torus tubarius extends into a longitudinal mucosal fold (Plica salpingopharyngea) which is created by the M. salpingopharyngeus. The inferior part of the Ostium pharyngeum tubae auditivae displays another elevation, the **Torus levatorius,** which forms on the M. levator veli palatini. This orifice is the entrance to the Tuba auditiva (EUSTACHIAN tube) and connects the Pars nasalis pharyngis with the tympanic cavity. Directly behind the Torus tubarius is a depression (Recessus pharyngeus, fossa of ROSENMÜLLER) which extends cranially to the roof of the pharynx. The M. palatopharyngeus forms the lateral margin of the Isthmus faucium. Looking further down from the dorsal side at the dorsum of the tongue (Dorsum linguae), one can see the entrance into the oesophagus at the back of the larynx. On both sides of the posterior laryngeal wall is the Recessus piriformis. Note the different course of the N. laryngeus recurrens on the two sides; on the left the nerve winds around the Arcus aortae and on the right around the A. subclavia.

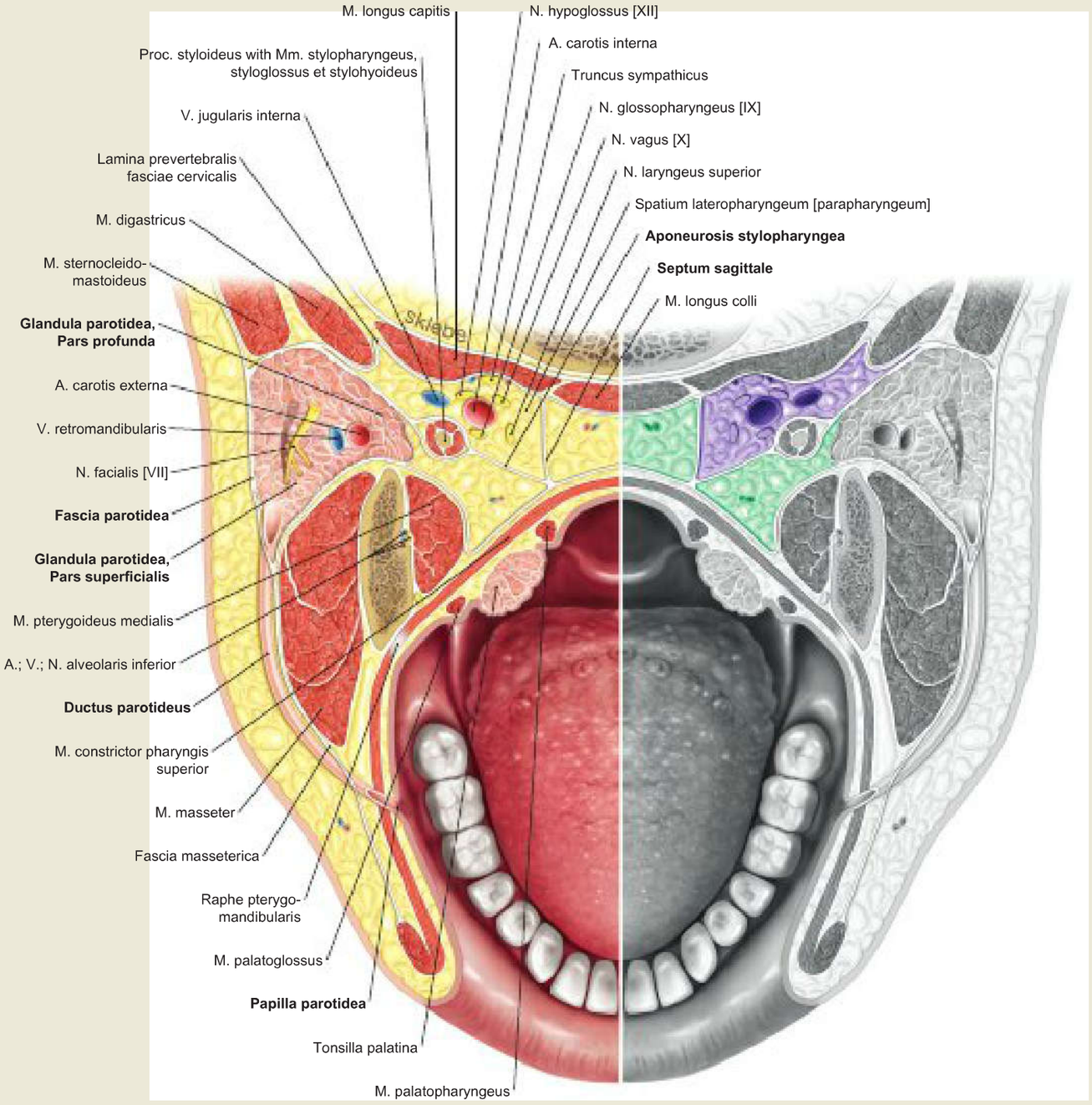

Fig. 11.21 Spatium lateropharyngeum and Spatium retropharyngeum; horizontal section at the level of the oral cavity. [L238]
Between the pharynx (M. constrictor pharyngis superior) and the prevertebral neck muscles (Mm. longus colli and longus capitis) is the **Spatium peripharyngeum** (green + purple). It includes the **Spatium lateropharyngeum** (purple) and the **Spatium retropharyngeum** (green), which are separated from each other sagittally by the septum, as well as by the Aponeurosis stylopharyngea. The Spatium retropharyngeum is divided into two compartments. The deep part (Pars profunda) of the Glandula parotidea is laterally adjacent to the Spatium peripharyngeum, M. pterygoideus medialis and M. digastricus (Venter posterior). Passing through the Spatium lateropharyngeum are the A. carotis interna, the V. jugularis interna, the N. glossopharyngeus [IX], the N. vagus [X] (as well as the off-branching N. laryngeus superior), the N. accessorius [XI] (which leaves the space already just below the cranial base), and the N. hypoglossus [XII]. The Truncus sympathicus runs in the upper part of the neck, together with the aforementioned cranial nerves, in the Spatium lateropharyngeum, pierces the Lamina prevertebralis of the cervical fascia approximately in the middle of the neck and runs in the lower half on the prevertebral neck muscles. Between the Spatium lateropharyngeum and the Spatium retropharyngeum is the Proc. styloideus with the Mm. stylopharyngeus, styloglossus and stylohyoideus attached to it.

Proportions in a Newborn

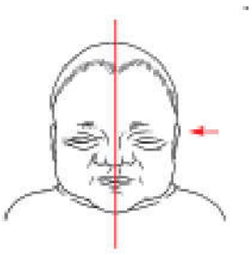

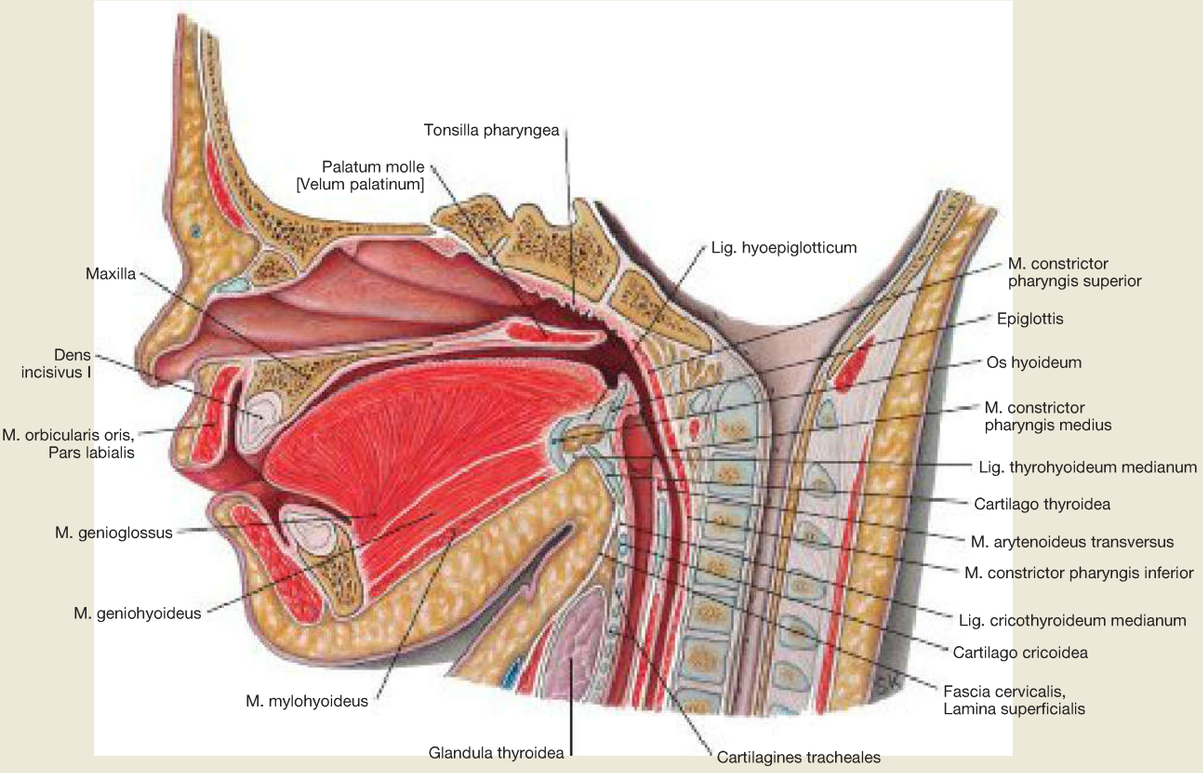

Fig. 11.22 Facial portion of the head, Caput, and neck, Collum, of a newborn; right paramedian sagittal section; medial view of the right side. [L238]

In newborn and infants the larynx is much higher than in adults (→ Fig. 11.16). Unlike adults and children, babies can drink and breathe simultaneously (→ Fig. 11.23).

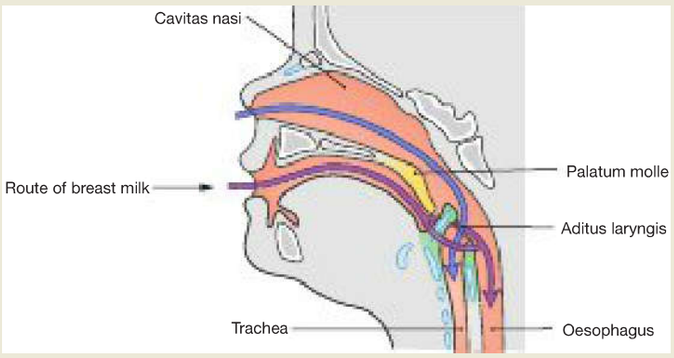

Fig. 11.23 Head of an infant; midsagittal section at the level of the nose and larynx. [L126]
Babies can drink and breathe at the same time. Since the larynx is located relatively high in the neck (→ Fig. 11.22), the epiglottis reaches as far as the nasopharynx. The liquids (breast milk) flow through the Recessus piriformis of the larynx into the oesophagus and do not pass into the lower respiratory tract.

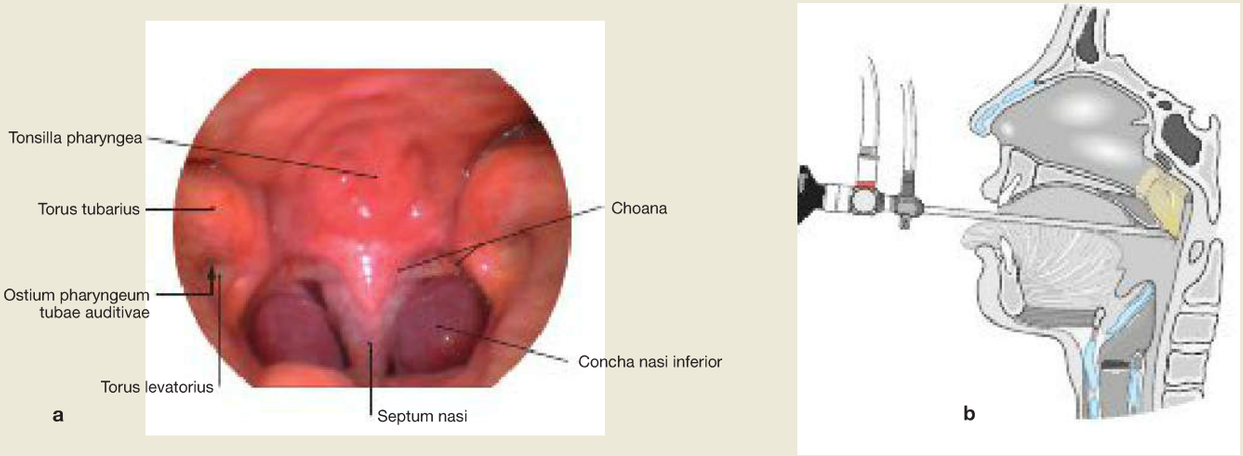

Fig. 11.24a and b Nasopharynx; endoscopy of the nasopharynx; dorsal view on the choanae, the bilateral opening of the Tuba auditiva and the Tonsilla pharyngea. a [T720], b [L126]
The endoscopic view from posterior into the nasopharynx shows the posterior ends of the inferior nasal concha and the entrance to the Tuba auditiva (Ostium pharyngeum tubae auditivae). Located at the roof of the pharynx is the inconspicuous Tonsilla pharyngea.

Clinical Remarks

Hyperplasia of the pharyngeal tonsils **(adenoids)** are common in childhood and often lead to recurrent middle ear infections due to an occlusion of the pharyngeal opening of the auditory tube. This can result in hearing impairment and subsequent developmental delays. In such cases, a removal of the Tonsilla pharyngea **(adenoidectomy)** is indicated.

In front of the Tonsilla pharyngea, a **Hypophysis pharyngealis** (pharyngeal pituitary gland) may be present in the connective tissue on the lower surface of the sphenoid bone, which is a remnant of the stalk of the embryonic RATHKE's pouch. In young people, the Hypophysis pharyngealis can be the starting point for a **craniopharyngeoma.**

Variations in the Course of the A. carotis interna

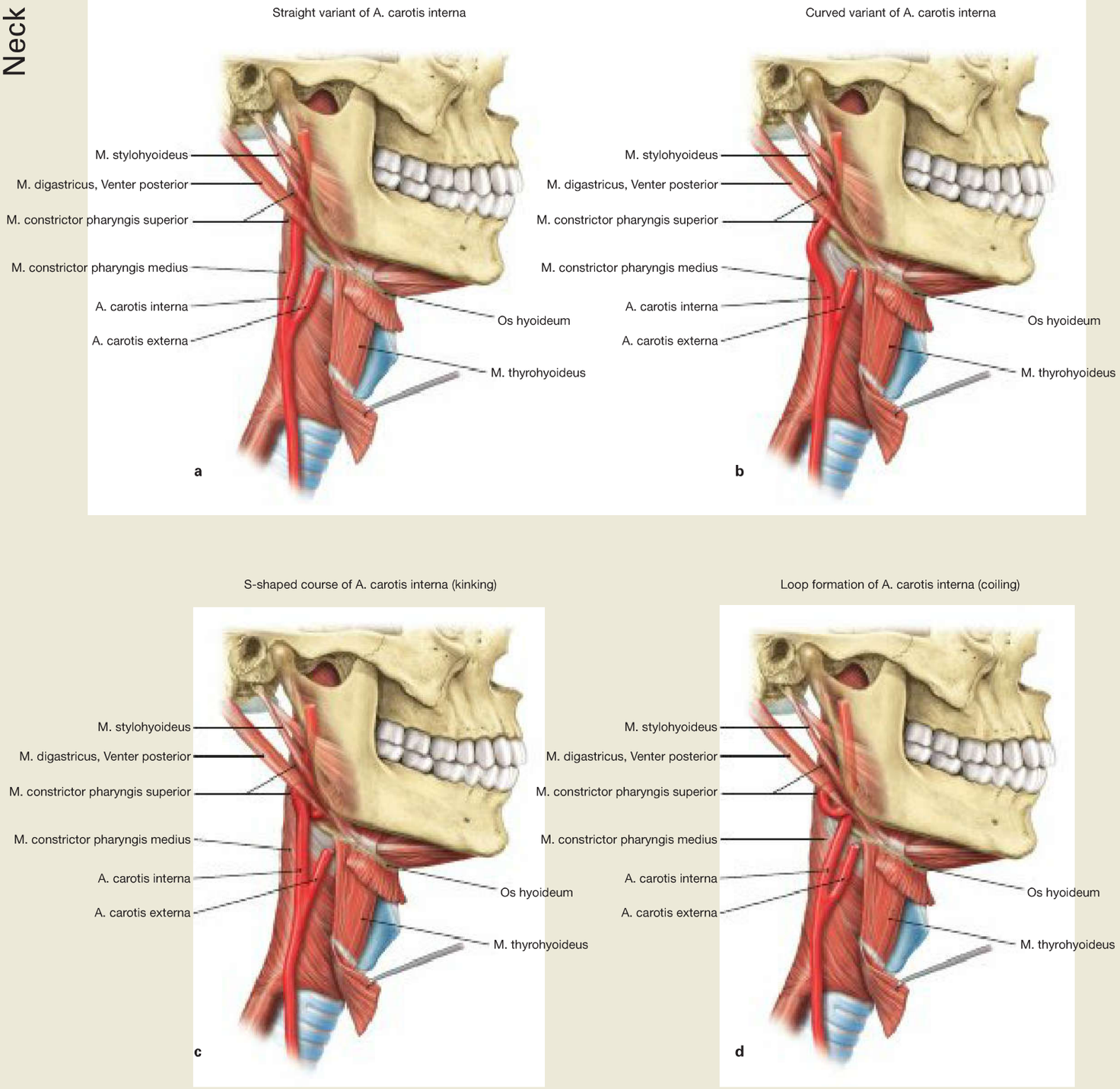

Fig. 11.25a to d Variations in the course of the Pars cervicalis of the A. carotis interna in relation to the pharyngeal wall. [L238]
a Straight variant (frequency 66%)
b Curved variant (frequency 26.2%)
c S-shaped course (frequency 6%, 2.8% thereof in close association with the pharyngeal wall)
d Loop formation (frequency 1.8%, 0.7% thereof in close association with the pharyngeal wall)
The S-shaped course and the loop formation are classified as **dangerous carotid loops** (**c** and **d**).

Clinical Remarks

Due to the close topographical relationship between the A. carotis interna and the tonsils (location of the Tonsilla palatina at the posterior margin of the Isthmus faucium) the presence of a **dangerous carotid loop** can result in the risk of injuries to the A. carotis with accidental fatal bleeding during tonsillectomy or opening of a peritonsillar abscess.

Skeleton of the Larynx

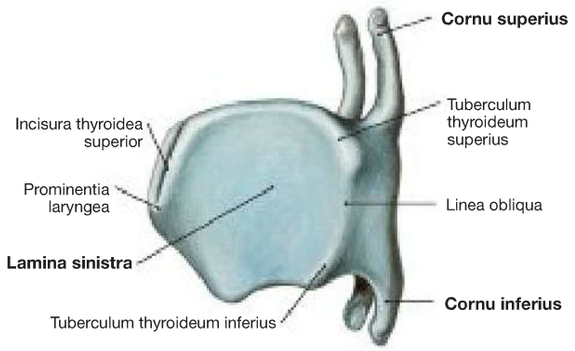

Fig. 11.26 Thyroid cartilage, Cartilago thyroidea; view from the left side.
The thyroid cartilage consists of two laminae (Lamina dextra and Lamina sinistra), each having a dorsal, a superior and an inferior horn.

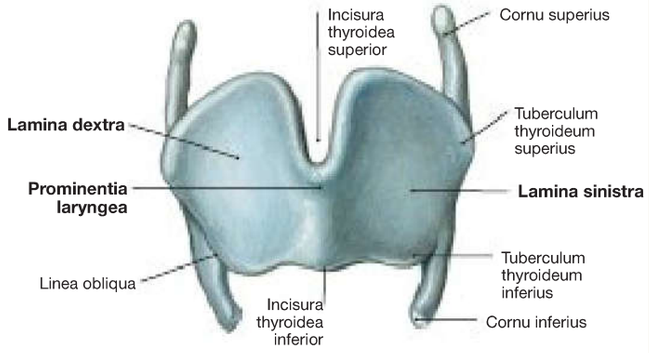

Fig. 11.27 Thyroid cartilage, Cartilago thyroidea; ventral view.
Both lamina of the thyroid cartilage join at an angle of 90° and 120° in men and women, respectively.

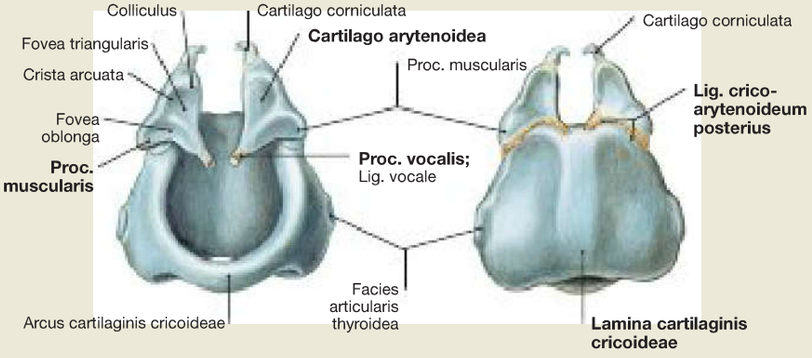

Fig. 11.28 Cricoid cartilage, Cartilago cricoidea, and arytenoid cartilage, Cartilago arytenoidea; ventral and dorsal views.
From the dorsal side, the Lig. cricoarytenoideum posterius can be seen between the cricoid and the arytenoid cartilages.

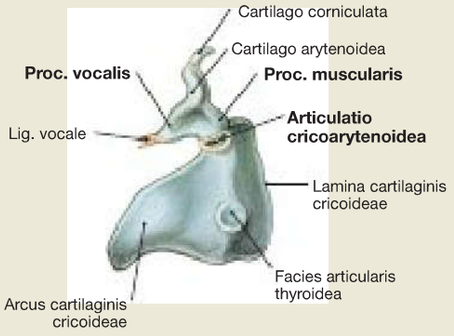

Fig. 11.29 Cricoid cartilage, Cartilago cricoidea, and arytenoid cartilage, Cartilago arytenoidea; view from the left side.
The cricoid and the arytenoid cartilages are connected via the Articulatio cricoarytenoidea, a diarthrosis.

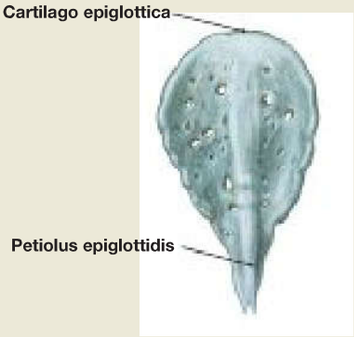

Fig. 11.30 Epiglottic cartilage, Cartilago epiglottica; dorsal view.
Unlike the other major hyaline laryngeal cartilages, the epiglottis is made of elastic cartilage.

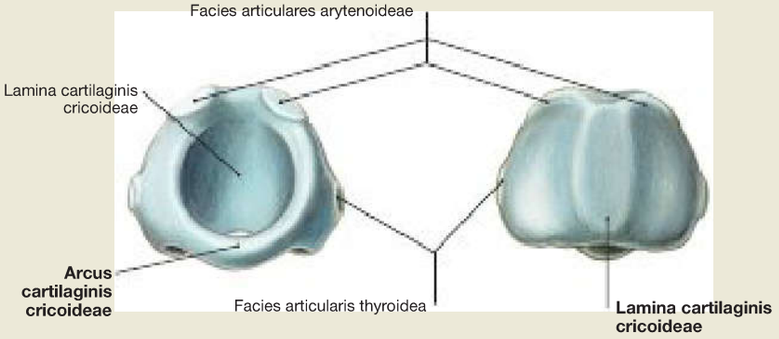

Fig. 11.31 Cricoid cartilage, Cartilago cricoidea; ventral and dorsal views.
The cricoid cartilage is shaped like a signet ring.

Clinical Remarks

At about 30 years of age, the ossification of the hyaline laryngeal cartilages (thyroid, cricoid and arytenoid cartilages) progresses in a slightly different manner in both sexes, so that it is very pronounced in men. **Fractures of the laryngeal skeleton** (e.g. car accidents) can result in severe obstruction of the airways with difficulties in phonation and breathing.

After surgical excision of the thyroid cartilage, for example during the **hemilaryngectomy** in the case of a laryngeal carcinoma, the remaining laminae of the thyroid cartilage can be adjusted and connected with material used for osteosynthesis.
In rare cases, a congenital softening of the laryngeal cartilage **(laryngomalacia)** can cause difficulties in breathing (dyspnoea).

Hyoid Bone and Skeleton of the Larynx

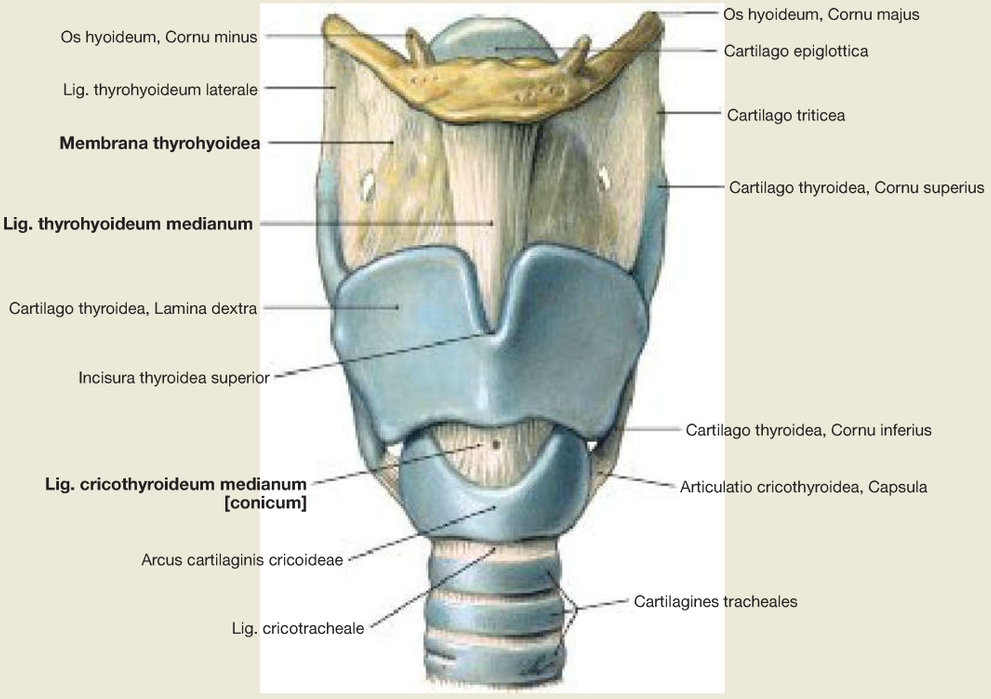

Fig. 11.32 Larynx, and hyoid bone, Os hyoideum; ventral view.
Developmentally and functionally, the Os hyoideum has a close relationship with the laryngeal skeleton. The individual skeletal elements of the larynx are connected by **syndesmosis** or by true joints **(diarthrosis)**.

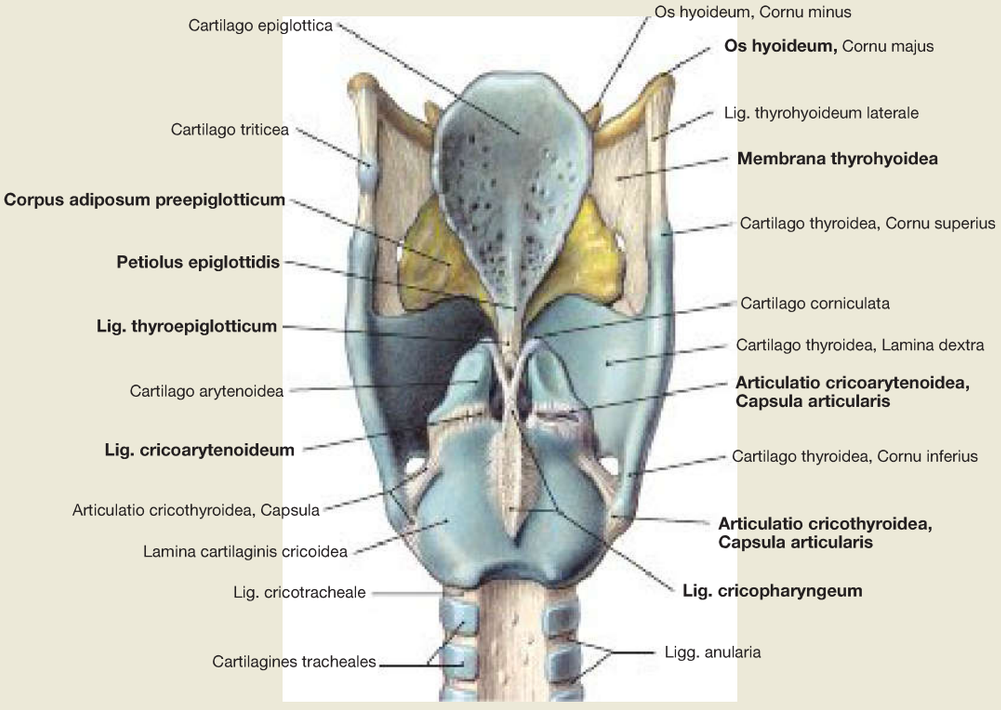

Fig. 11.33 Laryngeal cartilages, Cartilagines laryngis, and hyoid bone, Os hyoideum; dorsal view.
Behind the Membrana thyrohyoidea is a fat body (Corpus adiposum preepiglotticum), which reaches the Lig. hyoepiglotticum cranially and the front surface of the epiglottis dorsal-caudally. The epiglottis is attached by its stalk (Petiolus epiglottidis) via the Lig. thyroepiglotticum to the inside of the thyroid cartilage.

True joints of the larynx are the **Articulatio cricothyroidea,** the paired joint between the Cartilago cricoidea and the inferior horns of the thyroid cartilage (Cartilago thyroidea) as well as the **Articulatio cricoarytenoidea** between the cricoid and arytenoid cartilages. The Lig. cricoarytenoideum and the Lig. cricopharyngeum act as dorsal reins for the arytenoid cartilage.

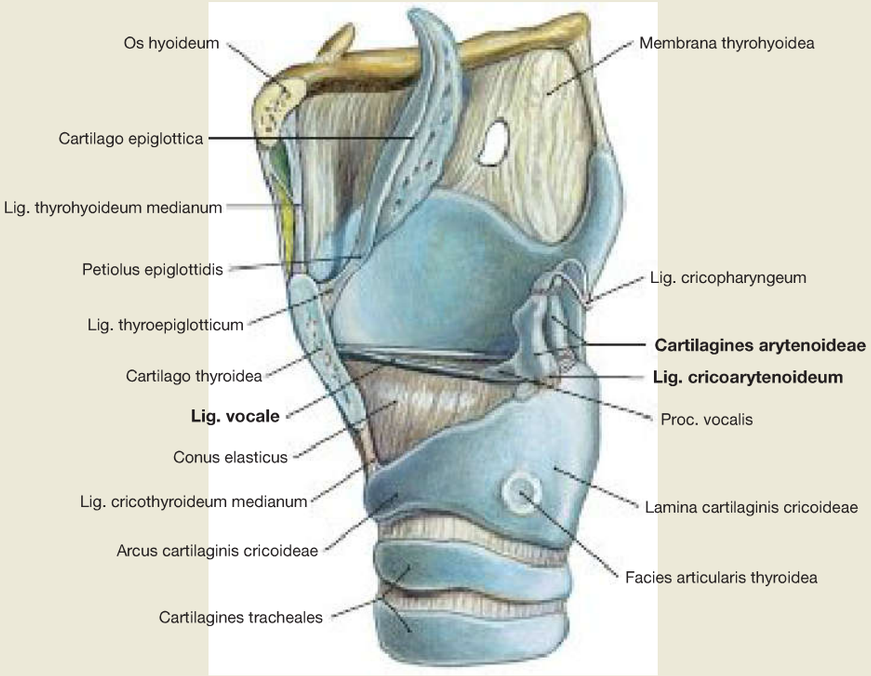

Fig. 11.34 Larynx, and hyoid bone, Os hyoideum; view from the left side on Lig. vocale and arytenoid cartilage; the left lamina of the thyroid cartilage removed.
The cricoid (Cartilago cricoidea) and arytenoid cartilages (Cartilago arytenoidea) articulate within the Articulatio cricoarytenoidea. The articular surfaces of the Cartilago cricoidea are convex and oval in size (cylinder-shaped, → Fig. 11.31); the articular surface of the Cartilago arytenoidea is concave and more round. Besides forming the articulating skeletal parts, a dorsal reinforcement of the capsule, the Lig. cricoarytenoideum (posterius) also ensures movements of the joint. Functionally, this ligament gives attachment to the arytenoid cartilage and counteracts the elastic force of the Lig. vocale.

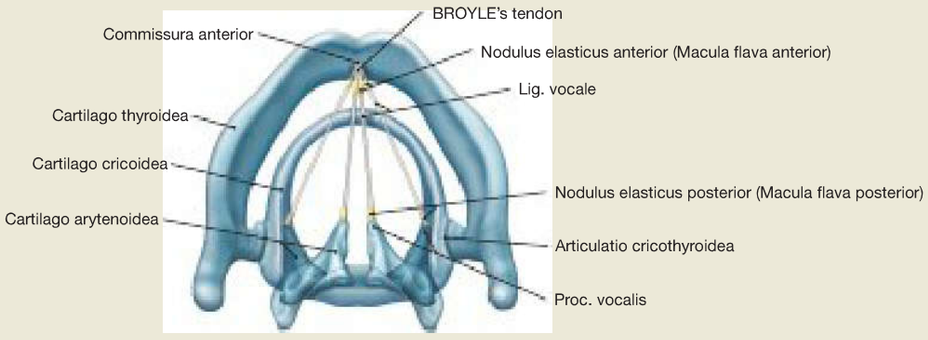

Fig. 11.35 Larynx; median section; superior view. [L238]
The cricoarytenoid joint permits hinge and sliding motions parallel to the cylindrical axis; this joint primarily supports the opening and closing of the space between the Ligg. vocalia (Glottis, Rima glottidis) and also keeps tension on the vocal ligament (Lig. vocale). The rotation of the Cartilago arytenoidea, like a hinge moving outwards, leads to the raising and abduction of the Proc. vocalis and consecutively to the **opening of the glottis.** The inward rotation over the hinge as well as the depression and adduction of the Proc. vocalis lead to the **closing of the glottis.** The hinge movements can be coupled with sliding motions. By doing so, the Cartilago arytenoidea moves in abduction and adduction ventrally or dorsally. The arytenoid and thyroid cartilages remain in contact with each other via the Lig. vocale and the Lig. vestibulare.

Clinical Remarks

Endotracheal intubation and extubation, laryngoscopy or bronchoscopy can lead to dislocation of the arytenoid cartilage in the dorsolateral or medioventral direction. This is referred to as **arytenoid subluxation.** The patient has a hoarse voice since the Lig. vocale on the affected side is immobile. The displacement of the arytenoid cartilage leads to bleeding into the joint cavity or reactive effusions after damage to the synovial membrane folds. The positional anomaly is maintained by muscle contractions. In its wake, due to adhesions of joint surfaces, an ankylosis can occur. An arytenoid subluxation must be distinguished from a nerve lesion.

Skeleton of the Larynx

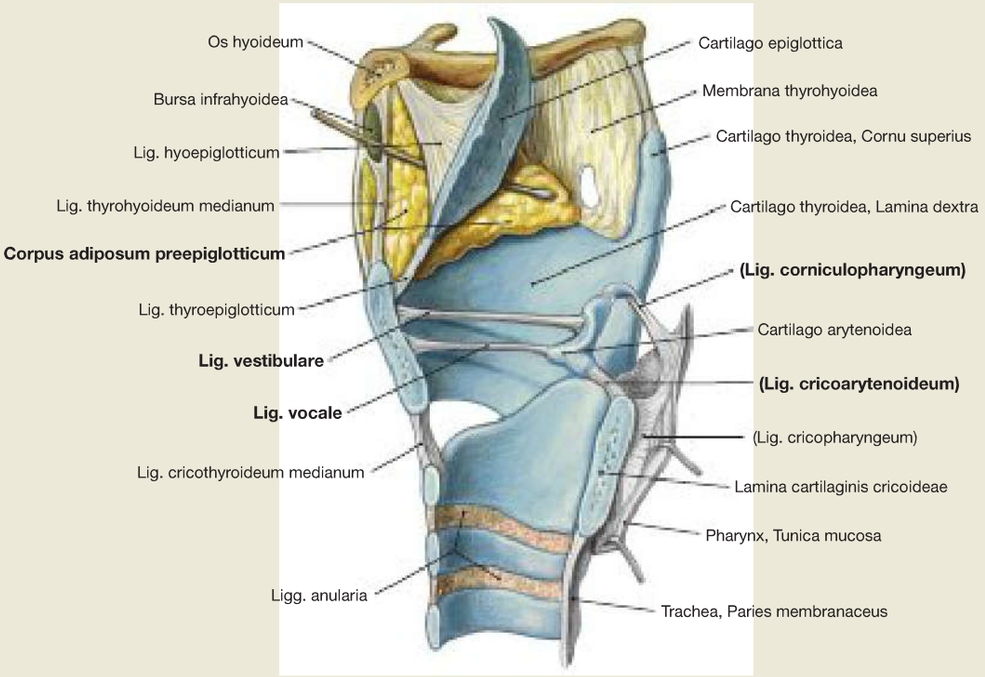

Fig. 11.36 Larynx, and hyoid bone, Os hyoideum; median section, medial view.
The thyroid and cricoid cartilages are linked by the Articulationes cricothyroideae. The cricoid and arytenoid cartilages articulate via the Articulatio cricoarytenoidea. The thyroid and arytenoid cartilages remain in contact with each other via the Lig. vocale and the Lig. vestibulare. The Lig. cricoarytenoideum and the Lig. cricopharyngeum act as dorsal reins of the Cartilago arytenoidea. Laterally and in front of the epiglottis, the Corpus adiposum preepiglotticum can be seen.

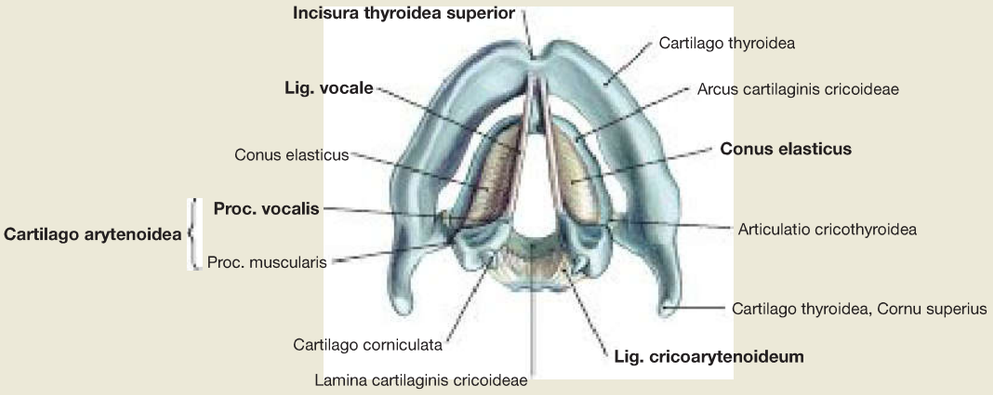

Fig. 11.37 Laryngeal cartilages, Cartilagines laryngis, and vocal ligament, Lig. vocale; superior view.
The paired Lig. vocale extends between the Proc. vocalis of the arytenoid cartilage and the inside of the thyroid cartilage just below the Incisura thyroidea superior. The Conus elasticus extends between the Lig. vocale and the upper rim of the cricoid cartilage. It is an elastic membrane which directs the air flow from the lungs in the direction of the Ligg. vocalia. The strong Lig. cricoarytenoideum can be seen dorsally behind the arytenoid cartilage.

Clinical Remarks

Because the cricoarytenoid joint has an extracellular matrix comparable to articulations of the limbs, the same disorders such as those found in the major limb joints can occur. As a result in older people, degenerative cartilage changes can occur **(degenerative arthritis),** which affect phonation and quality of voice due to improper occlusion of the glottis by the vocal ligaments. Also, joint infections **(infectious arthritis)** or rheumatism **(rheumatoid arthritis)** occur.

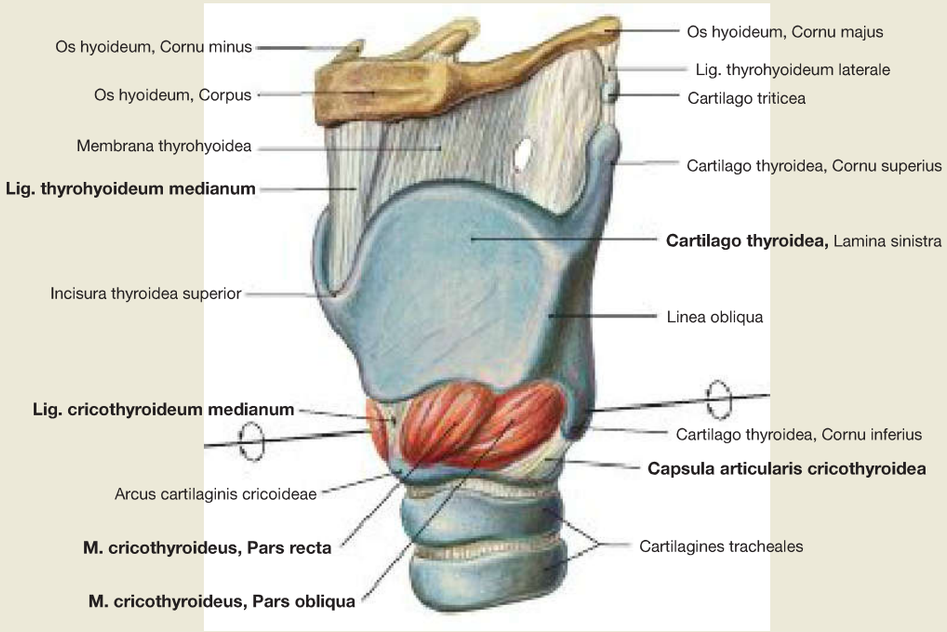

Fig. 11.38 Cricothyroid muscle, M. cricothyroideus; ventral view from the left side.
The cricoid cartilage (Cartilago cricoidea) and the thyroid cartilage (Cartilago thyroidea) articulate in the left and right Articulatio cricothyroidea. These are spheroidal joints with a firm joint capsule. This joint allows hinge movements around a transverse axis and small translation movements (shifting) in the sagittal plane. Contraction of the M. cricothyroideus increases the tension of the vocal folds (→ Fig. 11.39).

→ T 6

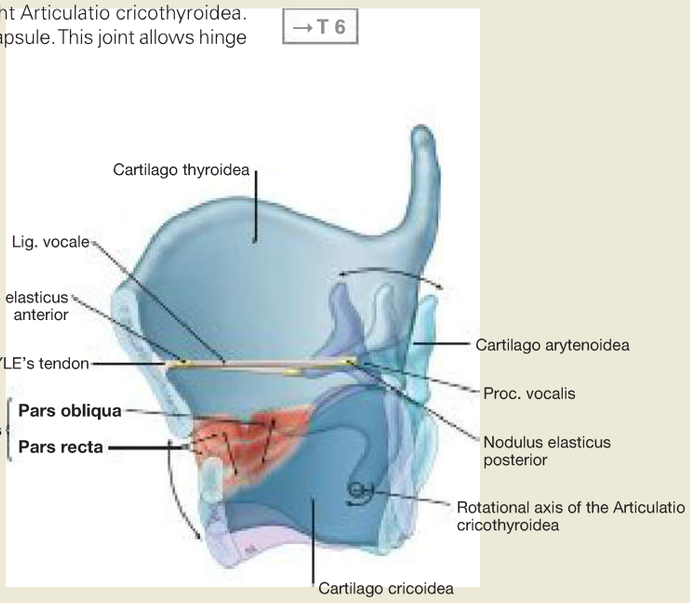

Fig. 11.39 Cricothyroid muscle, M. cricothyroideus; lateral view. [L238]
During the contraction of the M. cricothyroideus, the anterior border of the thyroid cartilage (Cartilago thyroidea) tilts in the direction of the arch of cricoid cartilage (Arcus cartilaginis cricoideae). To an even greater extent, the anterior portion of the cricoid cartilage is pulled towards the frontal lower edges of the thyroid cartilage (mechanical gross tension of the Plicae vocales by extension of the Lig. vocale). The arytenoid cartilages (Cartilagines arytenoideae) are stabilised in this movement by the M. cricoarytenoideus posterior and the Lig. cricoarytenoideum.

Biomechanics of the Plicae vocales: the structures at the insertion site of the vocal ligaments (**Noduli elastici anteriores** and **posteriores** as well as the BROYLE's tendon, → Fig. 11.56) perform biomechanical functions in the context of the oscillating vibrations of the Plicae vocales by adjusting the different elasticity modules of tendon, cartilage and bone. This prevents tearing (rupture) of the vocal ligaments from their anchorage during oscillating vibrations.

→ T 6

Clinical Remarks

Benign and malignant **changes in the area of the Plicae vocales** lead to incomplete closure of the glottis and are accompanied by hoarseness, and at an advanced stage by shortness of breath. The Lig. cricothyroideum medianum [Lig. conicum] extends between the thyroid and cricoid cartilages, and can be easily palpated there. In the event of an emergency, in order to maintain respiratory function, it can be split to insert a breathing tube (→ Fig. 11.4).

Laryngeal Muscles

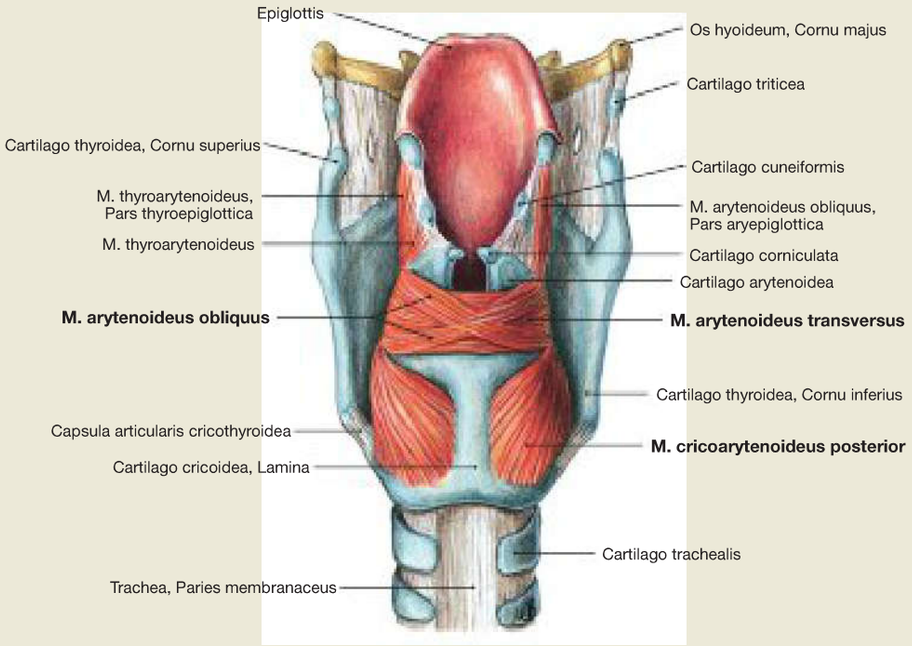

Fig. 11.40 Laryngeal muscles, Mm. laryngis; dorsal view.
The actions of the Mm. laryngis determine the shape of the Rima glottidis and the tension of the vocal ligament. The most important muscle is the **M. cricoarytenoideus posterior** ('posticus'), carrying out the abduction and elevation of the Proc. vocalis of the arytenoid cartilage resulting in widening of the glottis when breathing in. All other muscles that act on the space between the Plicae vocales cause the narrowing of the glottis and include the **M. arytenoideus transversus** and the **M. arytenoideus obliquus** as well as the **Mm. cricoarytenoidei laterales** (→ Fig. 11.41). Whispering is made possible by the isolated contraction of the M. cricoarytenoideus lateralis, which results in the so-called **'whispering triangle',** the formation of a small triangular opening in the posterior part of the Rima glottidis (→ Fig.11.53).

→ T 6

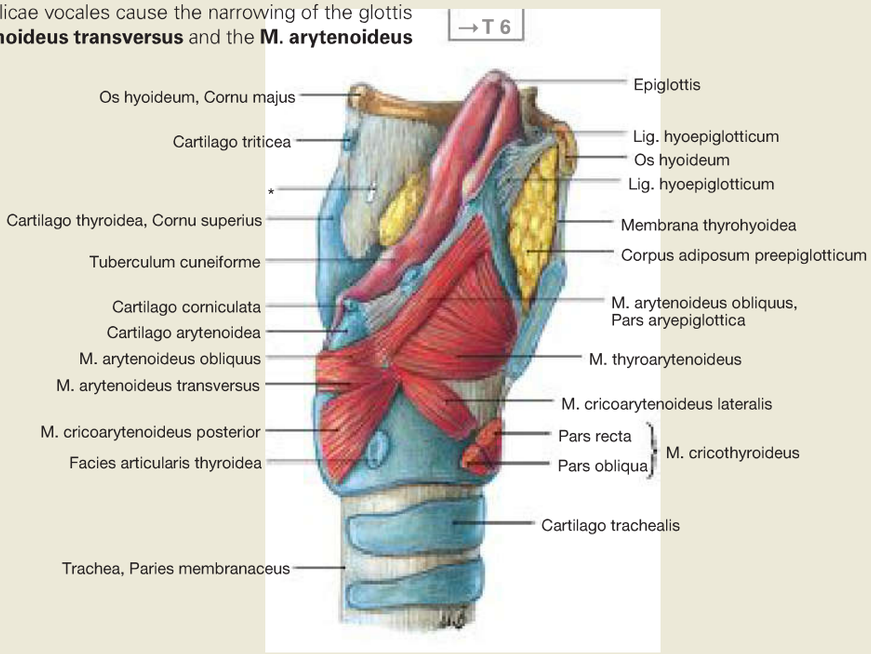

Fig. 11.41 Laryngeal muscles, Mm. laryngis; dorsal view obliquely from the right side, the posterior part of the right lamina of the thyroid cartilage with the horns is removed.
By removing the posterior part of the thyroid cartilage one can see the **M. thyroarytenoideus** with its strong Pars externa (→ Fig. 11.43) and the Pars thyroepiglottica on top of it, the **Pars aryepiglottica,** which contributes in the lowering of the epiglottis, as well as the muscular variant of a M. thyroarytenoideus superior. Coming below from the outside of the cricoid cartilage, the **M. cricoarytenoideus lateralis** is extending to the Proc. muscularis of the arytenoid cartilage.

→ T 6

Clinical Remarks

After an isolated, unilateral **paralysis of the M. cricoarytenoideus posterior,** the Plica vocalis is in the paramedian position; a bilateral paralysis results in respiratory distress due to narrowing of the glottis and may even lead to death.

Dysphonia refers to all signs of a phonation ('sound formation') disorder. This also includes hoarseness in patients with a unilateral paralysis of the M. cricoarytenoideus posterior. **Aphonia** means the complete loss of voice.

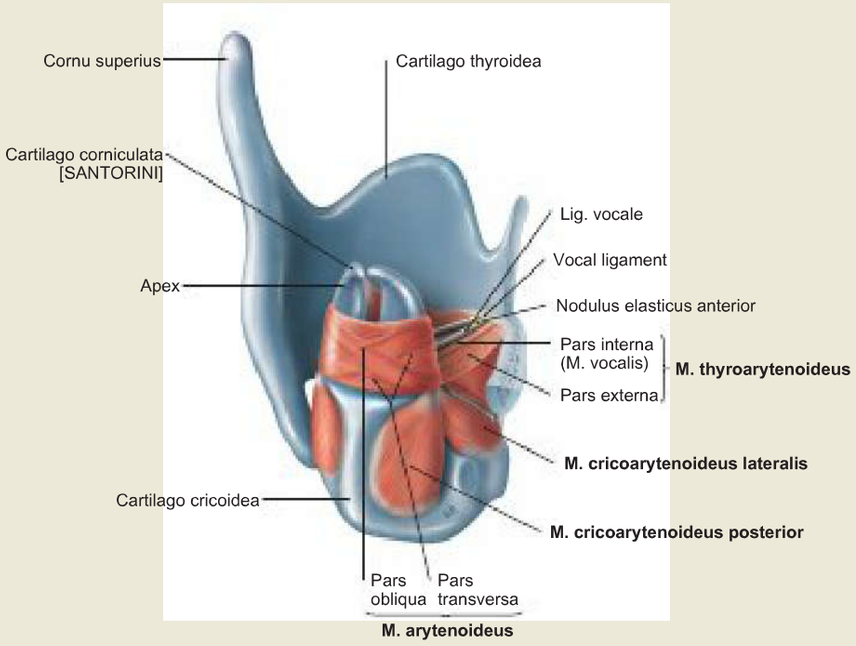

Fig. 11.42 Laryngeal muscles, Mm. laryngis; dorsal view. [L238]
From this angle, the M. cricoarytenoideus lateralis and the Pars interna of the M. thyroarytenoideus (M. vocalis) can be seen. The M. cricoarytenoideus lateralis belongs to the arytenoid apparatus, it narrows the glottis. The **fine tension of the vocal folds** results from the **M. vocalis** (Pars interna of the M. thyroarytenoideus), its muscle fibres are running parallel to the Lig. vocale and Plica vocalis. The muscle creates a cushion which acts like the mouthpiece of a blowpipe. The tension of this mouthpiece is regulated by isometric muscle contractions and its length is shortened by isotonic muscle contractions. The M. vocalis thus has a decisive impact on the sound quality and the voice or vocalisation.

→ T 6

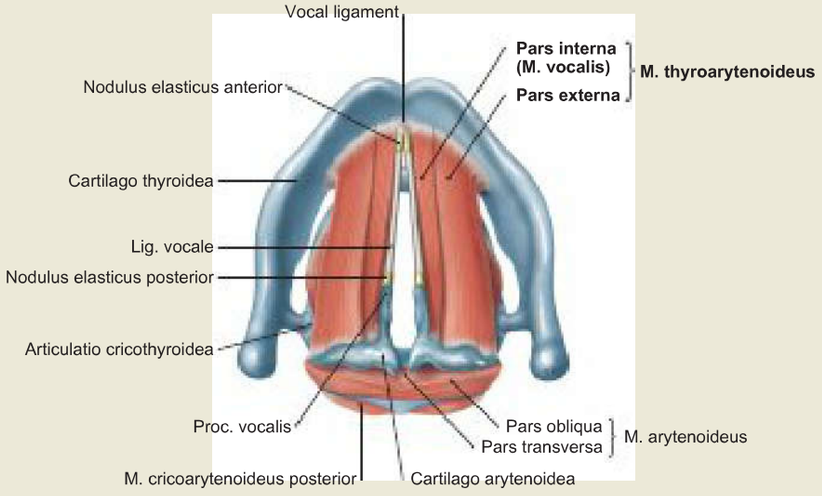

Fig. 11.43 Laryngeal muscles, Mm. laryngis; dorsal view. [L238]
Lateral to the M. vocalis (Pars interna of the M. thyroarytenoideus) is the strong Pars externa of the M. thyroarytenoideus, which contracts to adduct and abduct the Proc. vocalis of the arytenoid cartilage, thus closing the Pars intermembranacea of the glottis (→ Fig. 11.47b).

Inner Surface of the Larynx

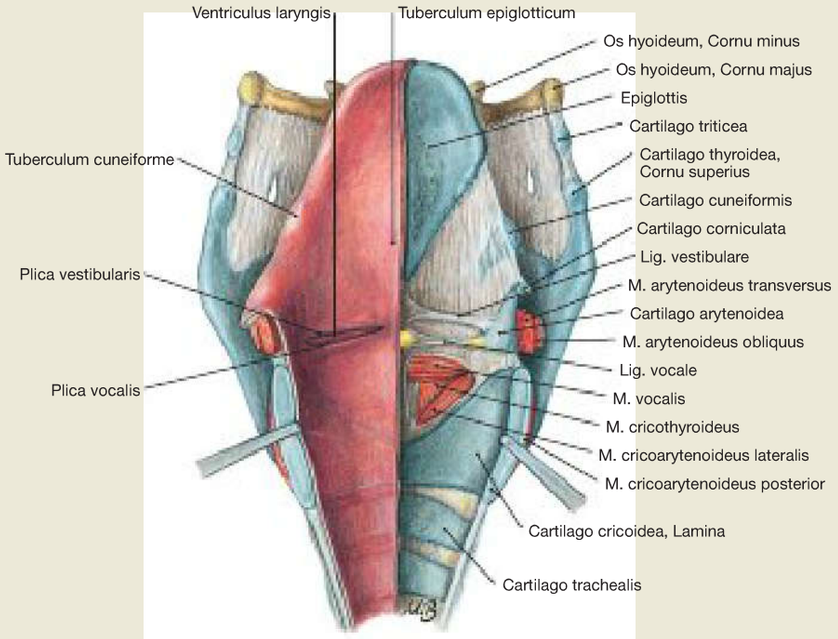

Fig. 11.44 Larynx; dorsal view; the larynx was sectioned dorsally in the median plane and separated with hooks.
On the left side, the mucosal lining is shown; on the right side, the laryngeal muscles (M. vocalis [= Pars interna of the M. thyroarytenoideus], M. cricothyroideus and M. cricoarytenoideus lateralis), the cartilages (epiglottis, arytenoid, cricoid, and thyroid cartilages, as well as the small laryngeal cartilages), and the mucosal folds (Plicae vestibularis and vocalis) are depicted.

→T 6

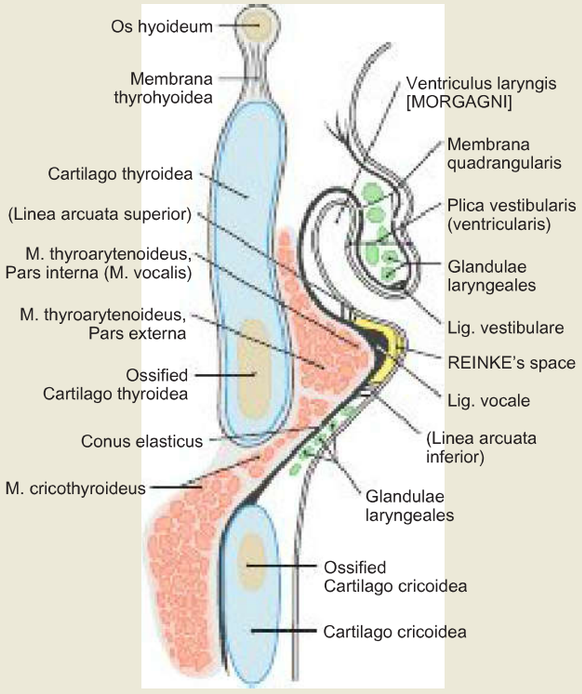

Fig. 11.45 Larynx; frontal section through a sagittally halved larynx, schematic drawing. [L126]
In the frontal section, one can see the elastic tissues (black) of the larynx, which extend as a **Conus elasticus** from the top of the cricoid cartilage to the **Lig. vocale** of the Plica vocalis, and from here on as a **Membrana quadrangularis** below the mucosa of the Ventriculus laryngis to the top of the thyroid cartilage. In the vestibular fold or false vocal cord, the Membrana quadrangularis is thickened to the **Lig. vestibulare.** Below the mucosa of the Plica vocalis there is very loose connective tissue. It reaches cranially to the **Linea arcuata superior,** caudally to the **Linea arcuata inferior** and forms the **REINKE's space.** The loose connective tissue forms the base for the mucosal wave that takes place in phonation (→ Fig. 11.49). In the vestibular fold and below the mucosa of the subglottic area there are numerous bundles of glands that form a seromucous substance for moistening the Plicae vocales.

Clinical Remarks

An accumulation of fluid in the REINKE's space creates a swelling of the Plicae vocales, which extends into the glottis and results in hoarseness and dyspnoea **(REINKE's oedema).** The REINKE's oedema must be distinguished from a **'glottic oedema'.** The latter means that fluid collects in the Lamina propria of the mucous membrane of the supraglottic space (e. g. in allergic reactions), thus is spreading above the glottis. It leads to wheezing due to the narrowing of the lumen of the larynx, hoarseness and severe shortness of breath.

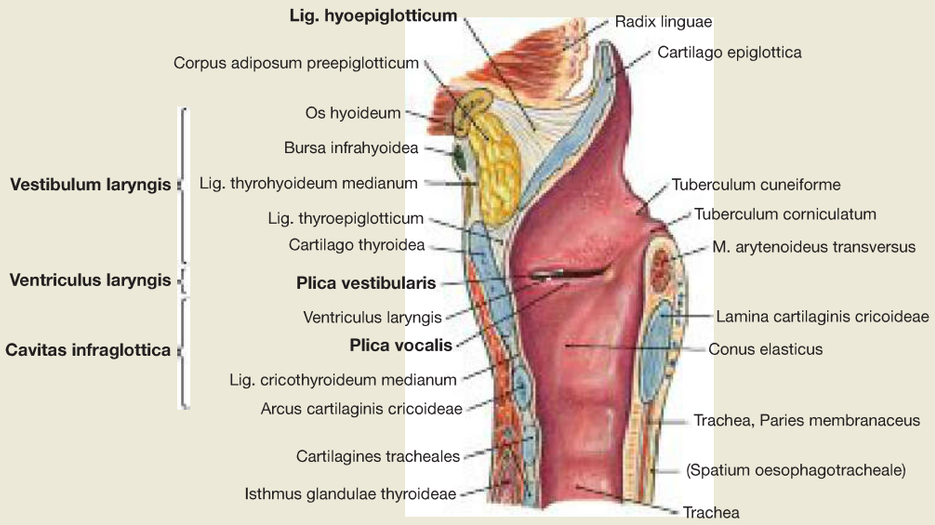

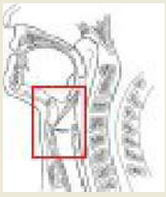

Fig. 11.46 Larynx; midsagittal section.
The paired vocal folds (Plicae vocales) are located below the paired vestibular folds (Plicae vestibulares) in the middle laryngeal compartment. The largest part of the Cavitas laryngis is lined by **respiratory epithelium.** In addition, there are some consistent areas of multilayered, nonkeratinised stratified **squamous epithelium,** which in other areas occurs only occasionally with interindividual variations. One can find it consistently on the Plicae vocales covering the Lig. vocale. It spreads further in the mucous membrane of the arytenoid cartilages and passes continuously into the squamous epithelium of the hypopharynx. The lingual surface of the epiglottis is covered with squamous epithelium. The distribution of both types of epithelium on the Plicae vestibulares and within the entire Cavitas laryngis can show significant individual variations. The areas of squamous epithelium change their extent in the course of a lifetime. With increasing age, laryngeal areas covered with squamous epithelium increase.

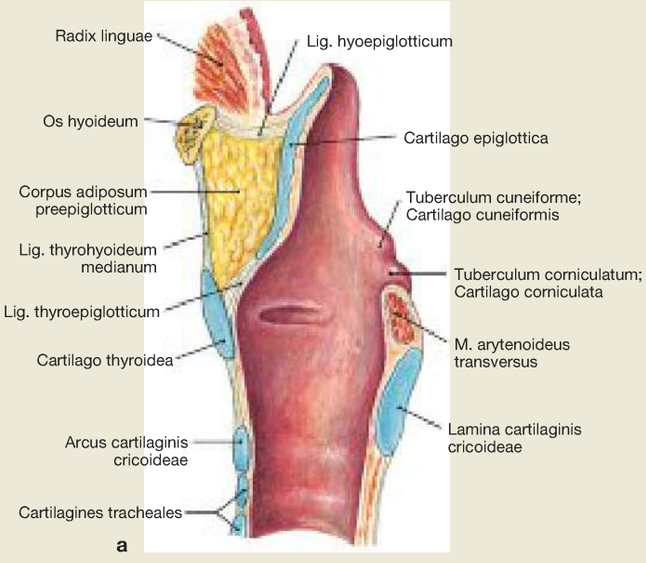

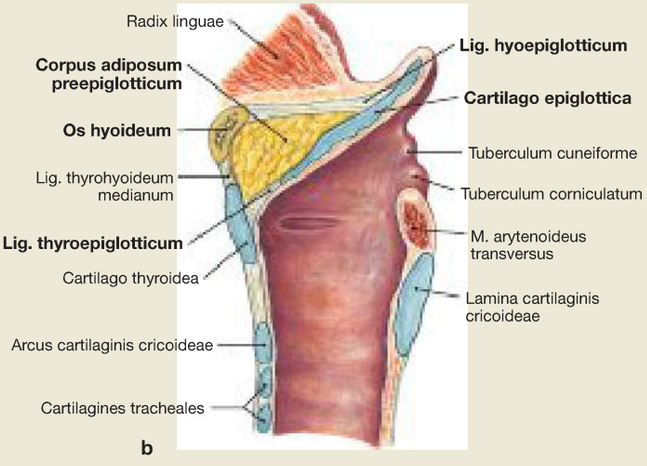

Fig. 11.47a and b Larynx, position of the epiglottis at rest (a) and when swallowing (b); midsagittal section.
During the swallowing process, the structures of the Aditus laryngis will be displaced. The epiglottis is pushed downward by the bite of food. This is assisted by the M. aryepiglotticus (→ Fig. 11.41). The pre-epiglottic fat body moves dorsally, and the Aditus laryngis is narrowed.

Clinical Remarks

The term 'vocal cord', used routinely in the clinical setting, is anatomically incorrect; the term should only be used to describe the Lig. vocale.

The squamous epithelium, which increasingly grows throughout one's life within the larynx, can be the starting point of a **squamous cell carcinoma** of the larynx.

Structure of the Larynx and Movement of the Plicae vocales

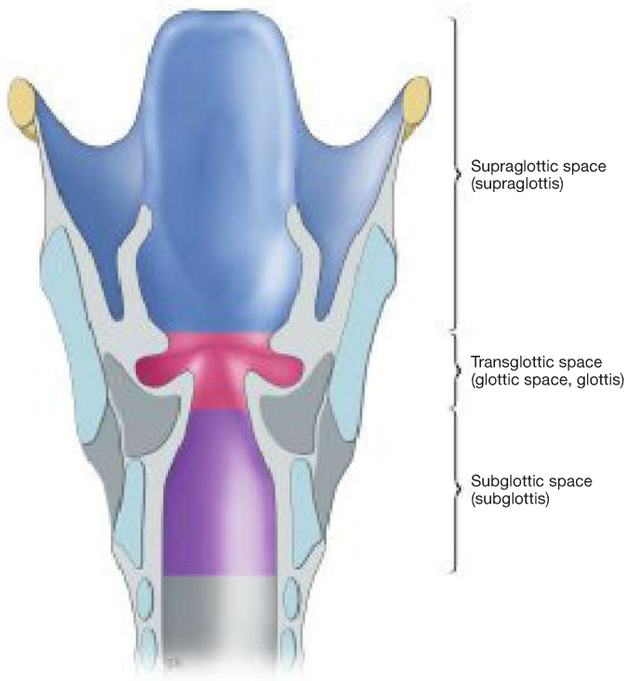

Fig. 11.48 Spaces (compartments) of the larynx. [L238]
In clinical terms, the following areas of the larynx are differentiated:
Supraglottic space (supraglottis): It extends from the Aditus laryngis, up to the level of the Plicae vestibulares, and can be subdivided into:

- epilarynx: laryngeal area of the epiglottis, Plicae aryepiglotticae and arytenoid cartilages
- Vestibulum laryngis: Petiolus epiglottidis, Plicae vestibulares = ventriculares, Ventriculus laryngis = MORGAGNI's ventricle

Glottic space (glottis): The glottis is an area containing the free margin of the Plicae vocales and is contrasted with the 'transglottic space', which surrounds the area containing the glottis, the vestibular folds and the Ventriculi laryngis. The anterior part of the glottis, including the anterior commissure (Commissura anterior) is known as Pars intermembranacea; the dorsal part of the glottis between the arytenoid cartilages is the Pars intercartilaginea (→ Fig. 11.53) and constitutes two-thirds of the Rima glottidis. In their dorsal part, the Plicae vocales end at the transition of the Pars intercartilaginea into the Plica interarytenoidea (→ Fig. 11.53b).
Subglottic space (subglottis): The subglottis is the space that extends below the Plicae vocales to the lower rim of the cricoid cartilage. It is a conical space between the free margin of the Plica vocalis, the area below the Plica vocalis, and the lower margin of the cricoid cartilage. The cranial border of the subglottis is the macroscopically visible Linea arcuata inferior (→ Fig.11.45) of the Plica vocalis. The caudal border is at the level of the lower rim of the subglottis. Craniolaterally, it is delimited by the Conus elasticus, and further caudally by the cricoid cartilage. The subglottic space which caudally has a cylindrical shape, narrows further cranially, corresponding to the shape of the Conus elasticus. The Lig. cricothyroideum (Lig. conicum) is defined as ventral border, and the cricoid cartilage is defined as dorsal border of the subglottic space.

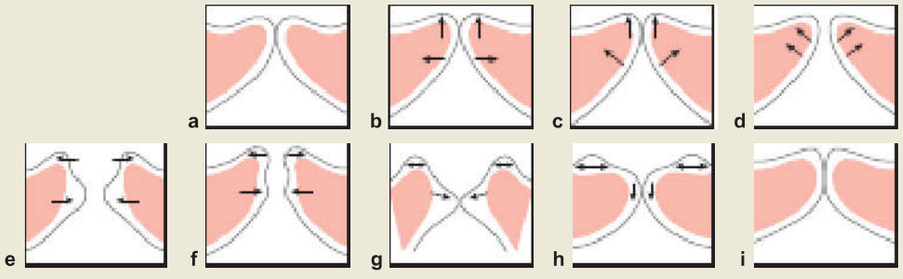

Fig. 11.49a to i Mucosal waves of the vocal folds during the opening and closing phase; schematic drawing. [L126]
For phonation, the mucosa of the Plicae vocales is set in motion by the forced airflow from the lungs, which is further beamed by the shape of the Conus elasticus. This leads to harmonic motion (oscillating vibrations) of the Plicae vocales. The basis for this is the loose connective tissue of the REINKE's space. With sufficient tension of the vocal cords **mucosal waves** are formed by the wave-shaped motion of the mucosa at the free margin of the Plicae vocales. When the 'mucosal wave' rolls towards the subglottic space and back from there, the mucous membranes on both sides meet each other for a short period and completely stop the airflow. This increases the flow pressure and forces them to separate again. This results in a constant changing of obstruction and release of the airflow (vibration): the Plicae vocales swing in the air stream. **a** Starting position with closed Plicae vocales. **b–d** The rising subglottic pressure reaches a threshold value, pushing the Plicae vocales apart. Initially there is a separation of the lower margins with an upward progression until both Plicae vocales are completely separated. **e–h** The breathing air is now directed (like through a nozzle) into the supraglottis and the pharynx. The airflow to the side leads to a suction effect (BERNOULLI's principle), which results in the mucosal wave. The epithelium and the loose connective tissue of the REINKE's space (→ Fig. 11.45) will be aspirated and contracted. The lower margins close first, and the upper margins follow once the airflow from the subglottic region is cut off (rolling of the epithelium on the Lig. vocale from bottom to top). **i** The subglottic pressure forces the Plicae vocales to separate again, and a new cycle begins. Repeated cycles lead to rhythmic vibrations.

Clinical Remarks

The subdivision of the larynx as described above is relevant for imaging techniques as part of the staging for **determining the spread of a tumour**. For the diagnostic imaging of the larynx, the recommended standard procedure is the spiral computed tomography (CT) in thin-layer reconstruction. Although magnetic resonance imaging (MRI) is the most sensitive of all imaging techniques for tumour staging, this method is prone to significant motion artefacts due to patient's movements.

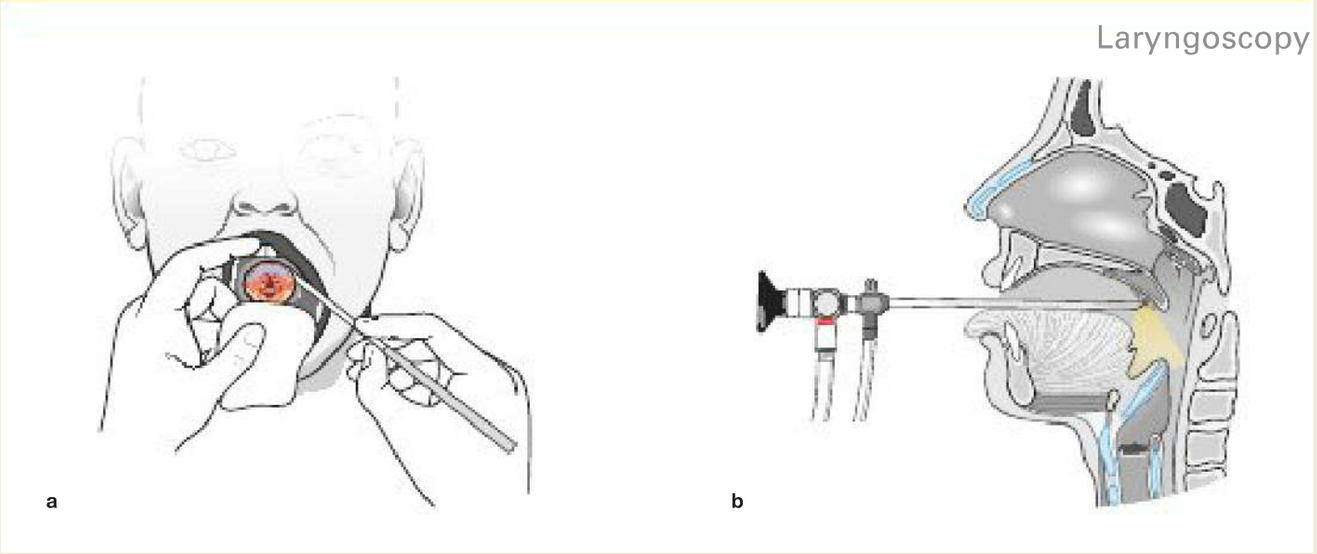

Fig. 11.50a and b Laryngoscopy. [L126]
a Indirect laryngoscopy
b Direct endoscopic laryngoscopy

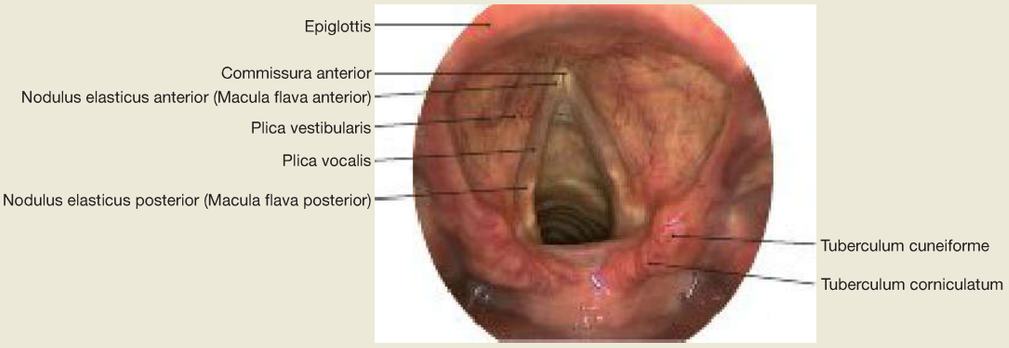

Fig. 11.51 Direct laryngoscopy;
breathing (respiration) position. [T719]

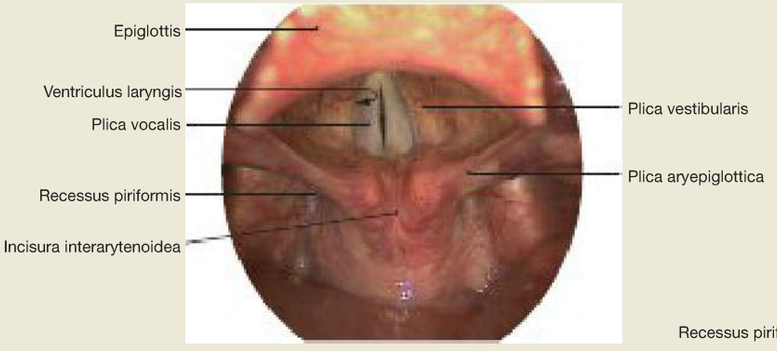

Fig. 11.52 Direct laryngoscopy;
speaking (phonation) position. [T719]

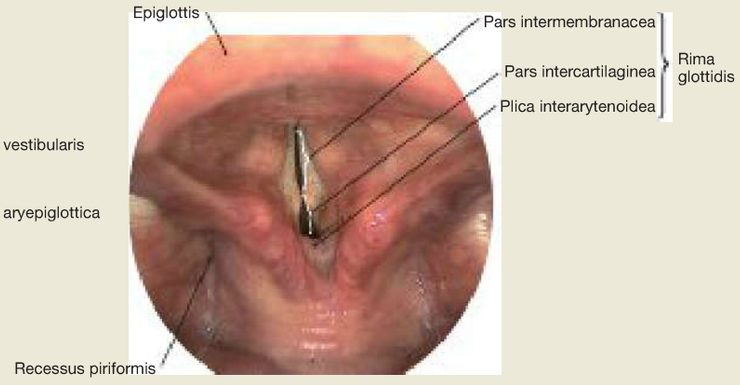

Fig. 11.53 Direct laryngoscopy;
whispering position. [T719]

Clinical Remarks

Overuse (in speaking professions) or misuse of the voice can lead to the formation of **vocal cord nodules from shouting or singing** on the free margin of the Plicae vocales. Due to weakness of the M. arytenoideus, the Pars intercartilaginea of the Plica vocalis can no longer be closed (open whispering triangle). The voice sounds breathy as a result.

The most frequently observed benign tumours of the Plica vocalis are **polyps;** and **squamous cell carcinomas** are the most frequent malignant tumours. In cases of longer-term intubation, **intubation granuloma** may develop in the Pars intercartilaginea.

Arteries and Nerves of the Larynx

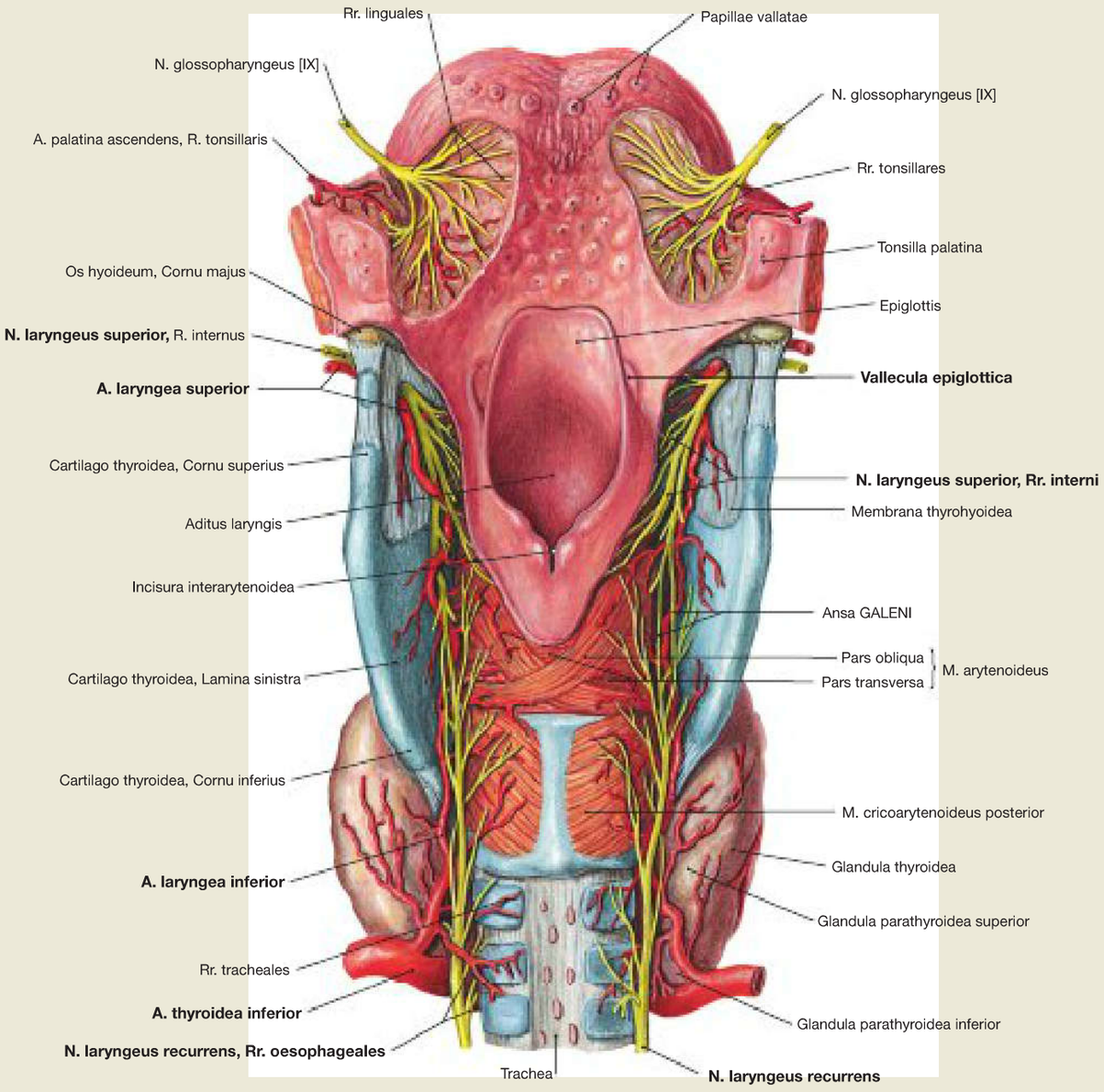

Fig. 11.54 Arteries and nerves of the larynx and root of the tongue, Radix linguae; dorsal view.
The A. thyroidea superior originates from the A. laryngea superior. Below the Cornu majus of the Os hyoideum it penetrates the Membrana thyrohyoidea and divides under the mucosa of the Recessus piriformis. There it forms numerous anastomoses and collaterals with the A. laryngea inferior.
The larynx receives bilateral innervation through **two branches of the N. vagus [X]:**

- The **N. laryngeus superior** is divided into a R. internus and a R. externus (→ Fig. 11.91). The R. internus runs laterally in the pharyngeal wall and passes together with the A. laryngea superior through the Membrana thyrohyoidea in the larynx. Here it sensorily innervates the supraglottic mucosa, the mucosa of the Valleculae epiglotticae and the epiglottis. The sensory innervation of the laryngeal mucosa is very dense (cough reflex). Apart from motor and sensory nerve fibres, the N. laryngeus superior also carries numerous parasympathetic fibres for the innervation of glands.
- The motor innervation of the inner laryngeal muscles is provided by the **N. laryngeus recurrens** [inferior]. Here the innervation of the two dorsal Mm. cricoarytenoideus posterior and arytenoideus can be seen. The connection between the N. laryngeus superior and N. laryngeus inferior is called Ansa GALENI (anastomosis of GALEN). For the course of the Nn. laryngei recurrentes → Fig. 11.20 and → Fig. 11.65.

Clinical Remarks

Lesions of the N. laryngeus superior are accompanied by somatosensory disorders (frequent choking) and paralysis of the M. cricothyroideus. Insufficient tension of the Plicae vocales results in an incomplete glottic closure with voice or phonation disorders.

Acute oedema at the entrance to the larynx (e.g. due to allergic reactions) may fully extend into the loose connective tissue and lead to severe shortness of breath.
Acute bacterial infections of the epiglottis occur most frequently in children and can cause acute and life-threatening obstructions of the airways.

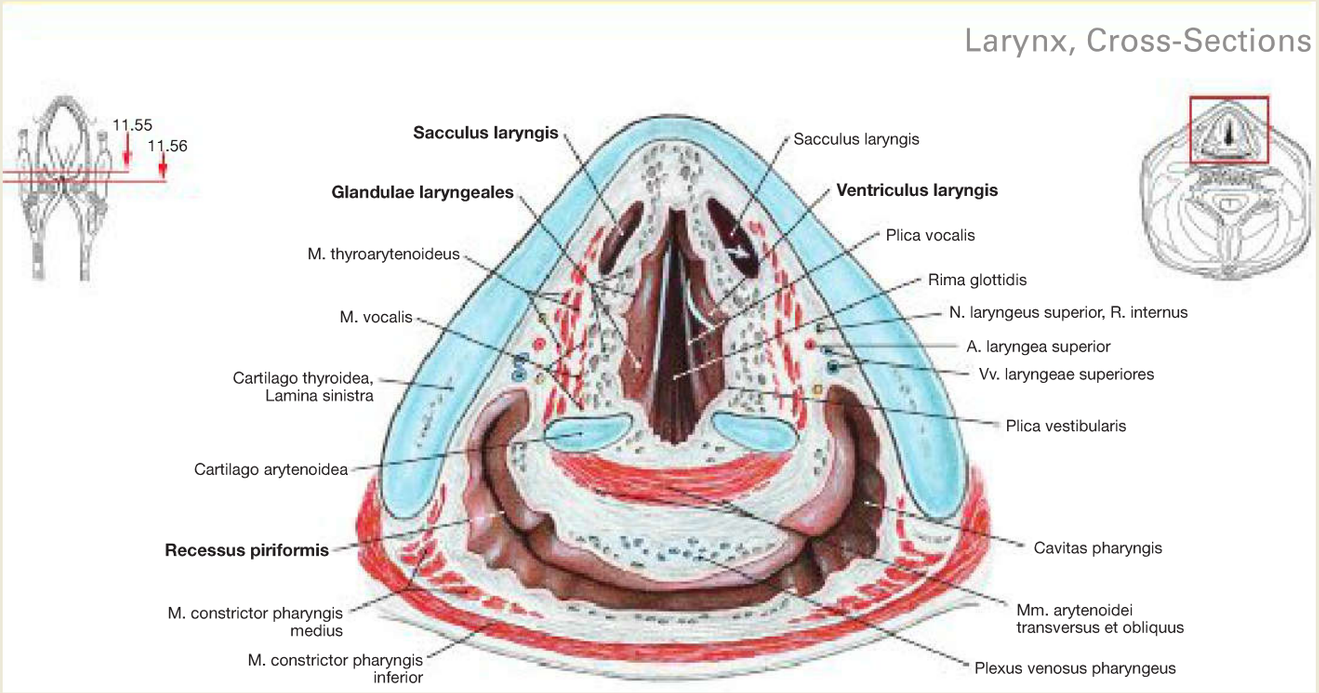

Fig. 11.55 Larynx; cross-section at the level of the Plicae vestibulares. The vestibular folds (Plicae vestibulares) contain multiple seromucous glands (Glandulae laryngeales) which serve to moisten the Plicae vocales. The white arrow indicates the connection between the Ventriculus laryngis and the Sacculus laryngis. Posterior to the larynx, the laryngopharynx can be seen with the Recessus piriformis.

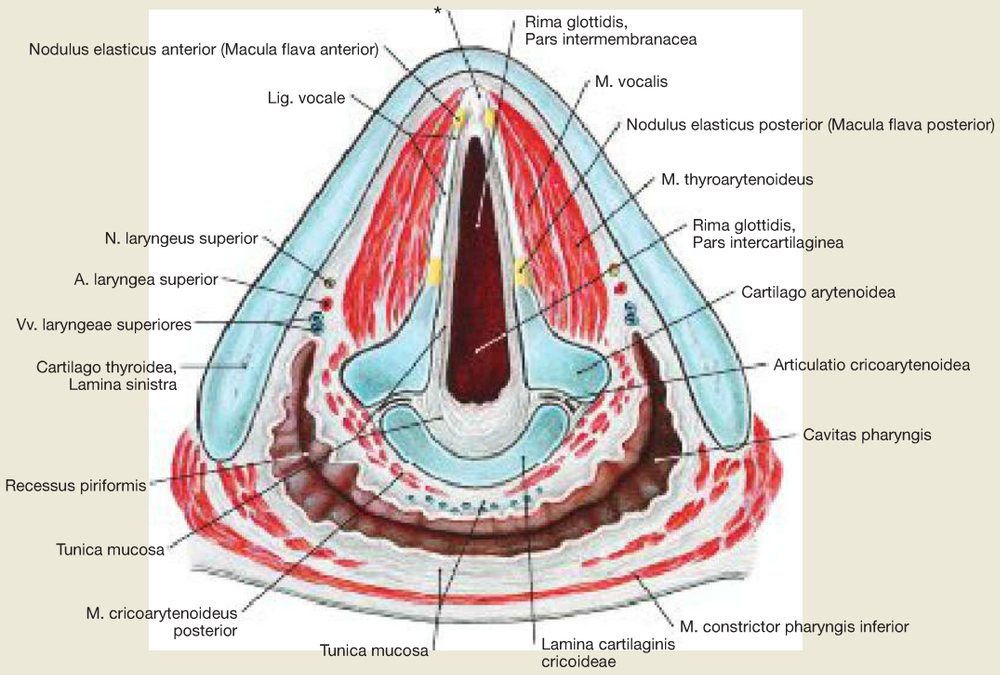

Fig. 11.56 Larynx; cross-section at the level of the Plicae vocales. The section at the level of the true opening of the vocal ligaments (glottis, Rima glottidis) displays the mucosa (Tunica mucosa) of the vocal ligaments. Following from the inside to the outside: the Lig. vocale, the M. vocalis (Pars interna of the M. thyroarytenoideus), and the Pars externa of the M. thyroarytenoideus. The cartilage-free part of the Plica vocalis is the Pars intermembranacea, the part between the two arytenoid cartilages is the Pars intercartilaginea (→ Fig. 11.53). The Plicae vocales run in front of the thyroid cartilage. The insertion site is referred to as the anterior commissure. Here, the Plicae vocales insert via Nodulli elastici anteriores and the tendon of the Lig. vocale (BROYLE's tendon*) at the thyroid cartilage. Dorsally, the Lig. vocale inserts via the Nodulus elasticus posterior on Proc. vocalis of the arytenoid cartilage.

Location of the Thyroid Gland in Relation to the Larynx

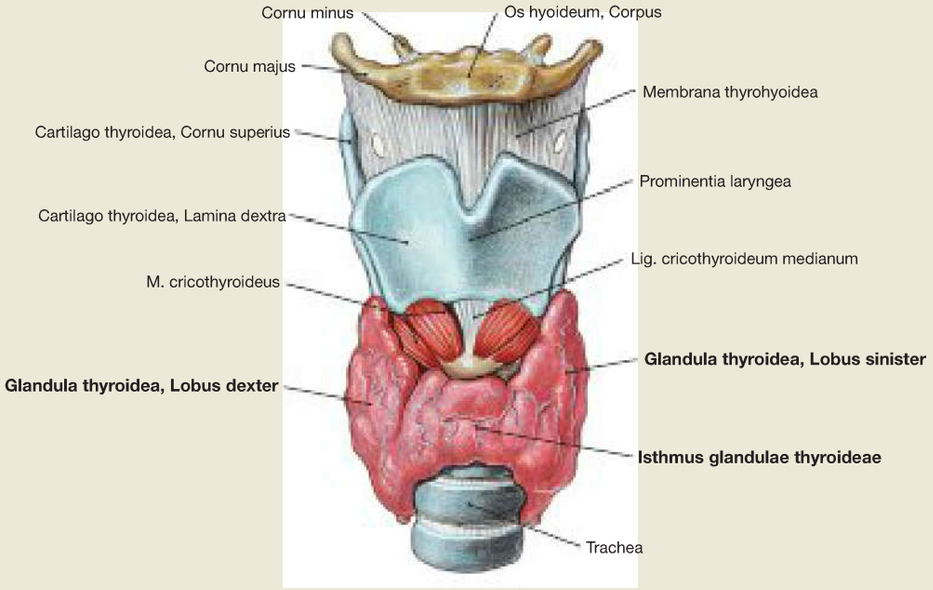

Fig. 11.57 Location of the thyroid gland, Glandula thyroidea; ventral view.

The thyroid gland (weight in an adult 20–25 g) is located below the larynx. It surrounds the upper part of the trachea on each side with a lobe (Lobus dexter and Lobus sinister) as well as at the front with an anterior isthmus.

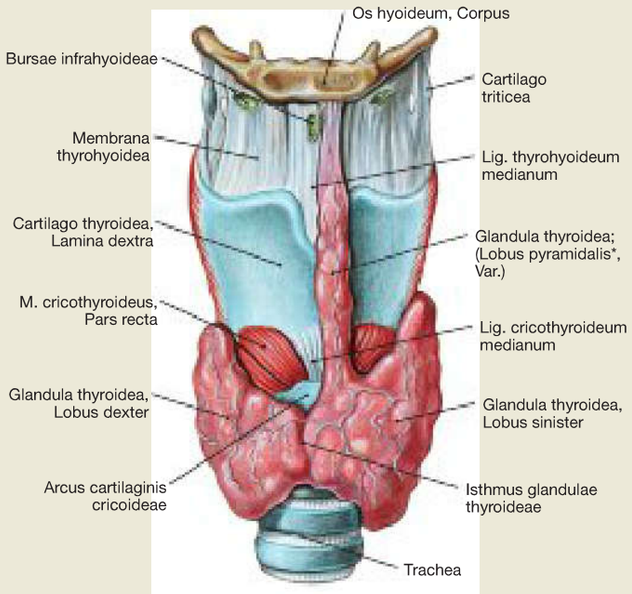

Fig. 11.58 Location of the thyroid gland, Glandula thyroidea, with Lobus pyramidalis; ventral view.
As an embryonic remnant of the descent of the thyroid gland, often remains a Lobus pyramidalis, which spans almost in the centre and is secured to the Os hyoideum by a strip of connective tissue. In a cricoidotomy (→ Fig. 11.4) it can be a risk factor for unexpectedly severe bleeding.

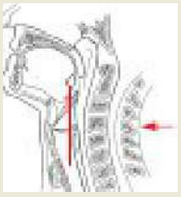

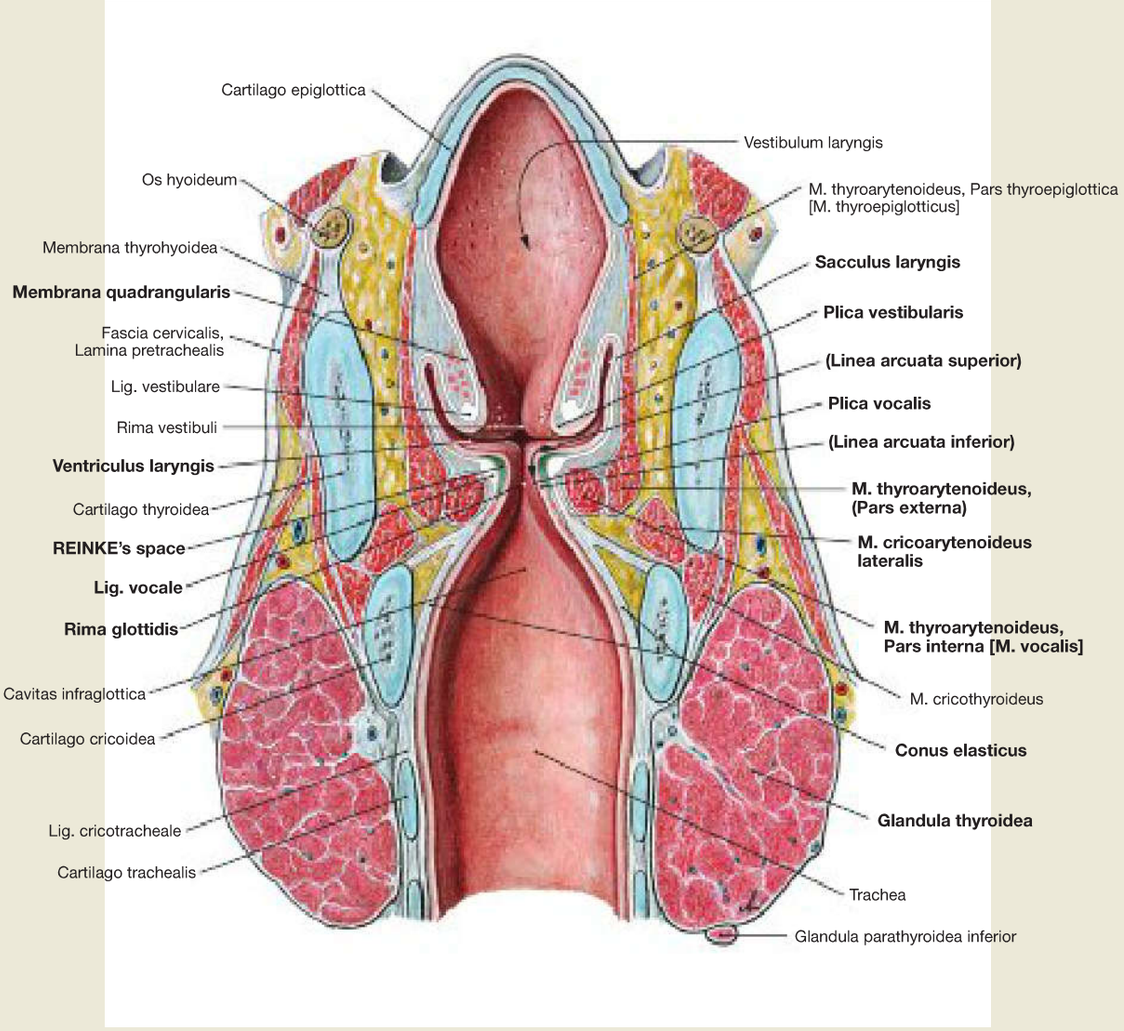

Fig. 11.59 Larynx and thyroid gland, Glandula thyroidea; frontal section.
Normally, the Plicae vocales protrude further into the lumen of the larynx than the Plicae vestibulares, so that they can be assessed in a laryngoscopy. The Plicae vocales are composed of an outer mucosa, the Lig. vocale, the caudally adjacent Conus elasticus, and in particular the M. vocalis (Pars interna of the M. thyroarytenoideus), and the Pars externa of the M. thyroarytenoideus. The M. cricoarytenoideus lateralis follows laterally. Together the Plicae vocales demarcate the opening of the vocal ligaments (glottis, Rima glottidis) which represents the part of the larynx responsible for phonation.
Subepithelial loose connective tissue above the Lig. vocale between the Linea arcuata superior and the Linea arcuata inferior enables sliding movements (REINKE's space, arrow). The Ventriculus laryngis extends between the Plicae vocales and the Plicae vestibulares. The elastic connective tissue of the Membrana quadrangularis provides the basis for the vestibular folds. The two lobes of the thyroid gland are located at the transition between the cricoid cartilage and the upper tracheal semicircular cartilages.

Thyroid Gland

Topography

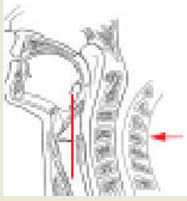

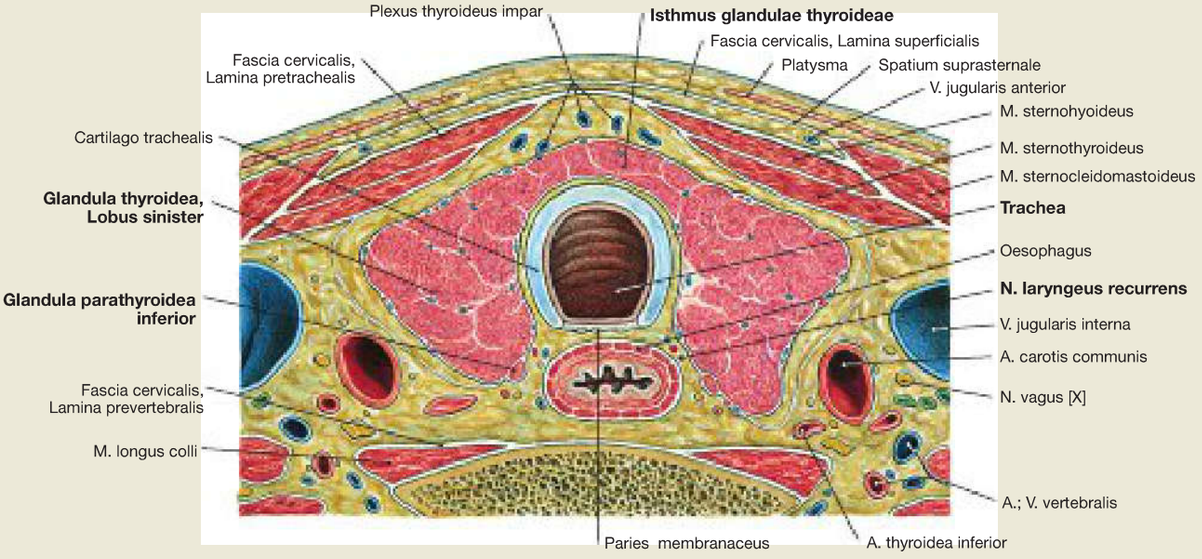

Fig. 11.60 Thyroid gland, Glandula thyroidea; horizontal section. The thyroid gland covers the upper tracheal part laterally and ventrally. It is the largest endocrine gland in the body and secretes the hormones thyroxine (tetraiodothyronine, T4), tri-iodothyronine (T3), and calcitonin. The gland is ensheathed by its own capsule and, together with the larynx, trachea, esophagus, and pharynx, is surrounded by the general organ fascia.

At the posterior side of each glandular lobe there are two grain-sized epithelial bodies (parathyroid glands, **Glandulae parathyroideae**) weighing 12–50 mg, which produce the parathyroid hormone (PTH). On both sides, the **N. laryngeus recurrens** runs between the trachea and the oesophagus. The nerve is located outside of the special organ fascia, but within the general organ fascia.

Clinical Remarks

Thyroid gland surgery requires the ventral opening of the Fascia pretrachealis and the joined special and general organ fascia at the anterior side of the thyroid gland. Surgeons here refer to the outer (Fascia pretrachealis) and inner (organ fascia) thyroid capsule.

Hyperplasia, adenomas or carcinomas of the epithelial bodies may result in a glandular hyperactivity in the form of a primary **hyperparathyroidism.** The increased production of parathyroid hormone leads to increased calcium levels in the serum and causes characteristic symptoms of bones, kidneys and the gastrointestinal tract.

Development of the Thyroid Gland and Clinics

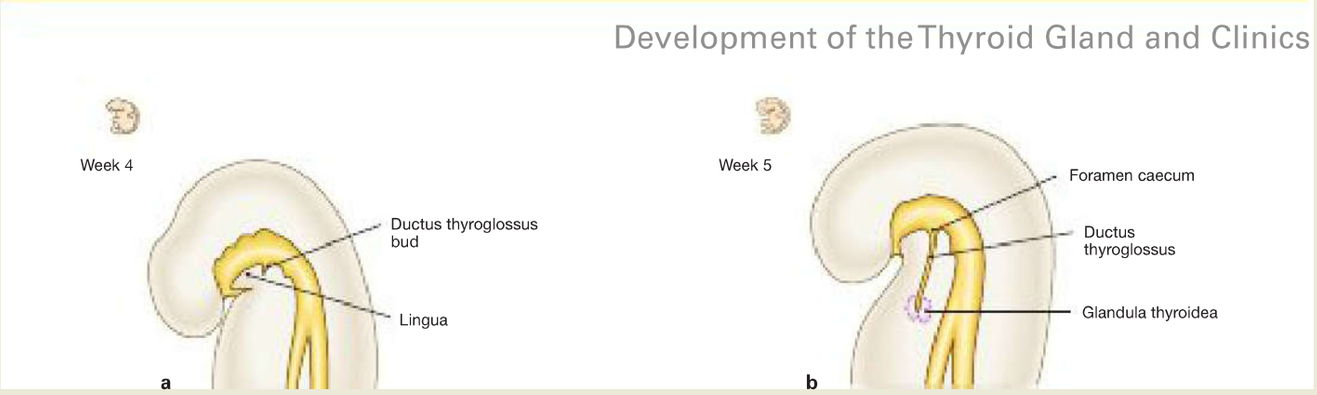

Fig. 11.61a and b Development of the thyroid gland. [E838]
From day 24, epithelium from the ectodermal stomodeum sprouts caudally in the median plane bypassing the hyoid bone and the larynx, and forms the **Ductus thyroglossus** (→ Fig. 11.61a). When the Ductus thyroglossus has reached its final location at the thyroid cartilage of the larynx in week 7, it forms the isthmus and the two lobes of the thyroid gland (→ Fig. 11.61b). The cranial part of the Ductus thyroglossus regresses. The proximal opening of the Ductus thyroglossus persists as **Foramen caecum** behind the Sulcus terminalis, and frequently a **Lobus pyramidalis** (thyroid gland tissue) is found along the passageway of the former Ductus thyroglossus (→ Fig. 8.191).
From the fifth pharyngeal pouch protrudes the ultimobranchial body, from which the C-cells (producing calcitonin) develop which then migrate into the thyroid gland. The epithelial bodies (producing parathyroid hormone) derive from the third and fourth pharyngeal pouches.

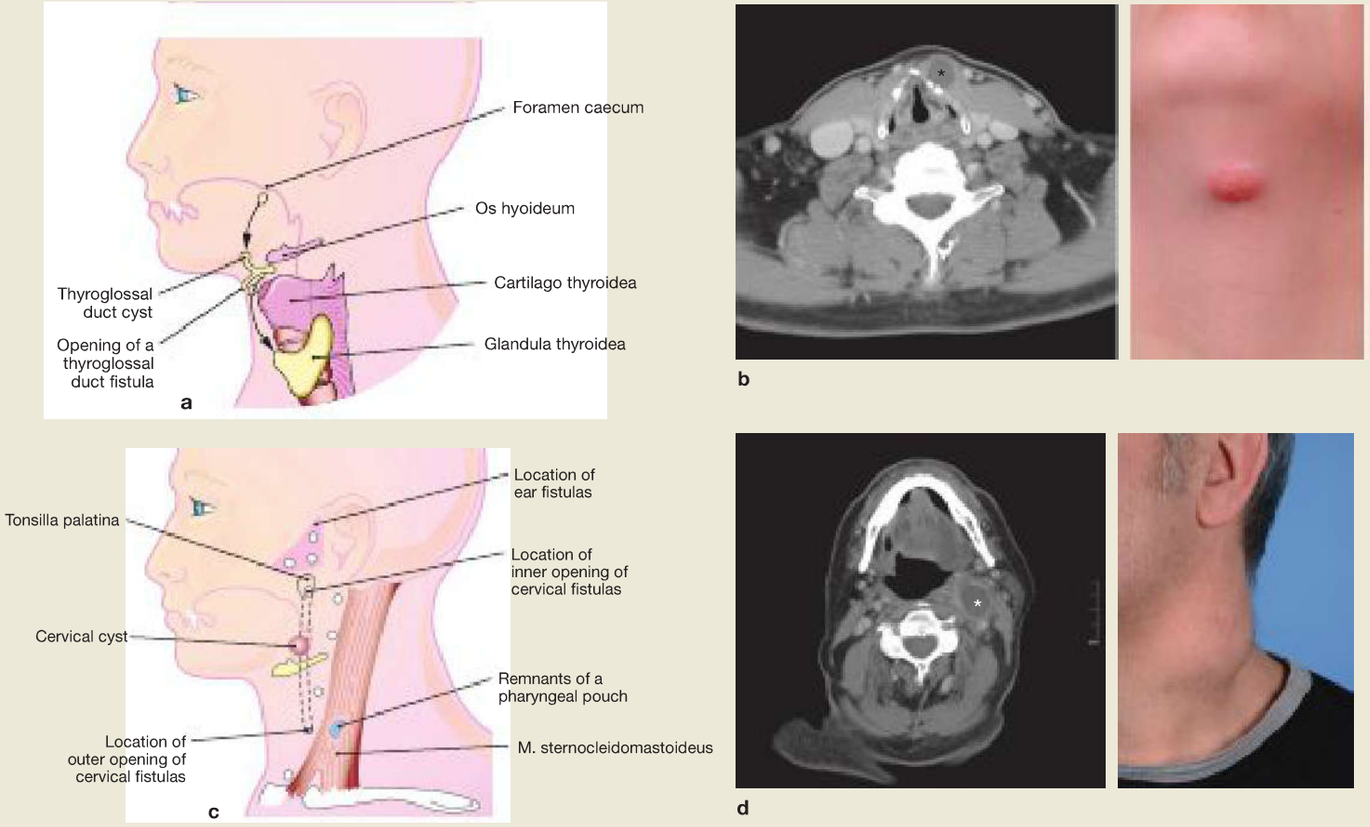

Fig. 11.62a to d Cervical cysts and cervical fistulas.
a, c [E347-09], b, d [T882]
a Possible locations of cysts derived of the Ductus thyroglossus (arrows indicate the location of the Ductus thyroglossus during the descent of the thyroid gland from the Foramen caecum to the final position in the Regio cervicalis anterior)
b Left: computed tomography (* cervical cyst), right: neck swelling due to a median cervical cyst
c Possible locations of cervical cysts and cervical fistulas
d Left: computed tomography (* cervical cyst), right: neck swelling due to a lateral cervical cyst

Clinical Remarks

It is possible that a portion of the Ductus thyroglossus persists in the form of a **median cervical cyst** or, in the case of a connection to the outside, in the form of a **median cervical fistula** (→ Fig. 11.62a and b). Both have no clinical significance, as long as they are not inflamed. **Lateral cervical cysts** arise when the branchial clefts or the Sinus cervicalis are not completely obliterated.

Lateral cervical fistulas usually open at the anterior margin of the M. sternocleidomastoideus (→ Fig.11.62c); the accumulation of fluid in **lateral cervical cysts** results in a swelling at the side of the neck (→ Fig.11.62d).

Vessels and Nerves of the Thyroid Gland

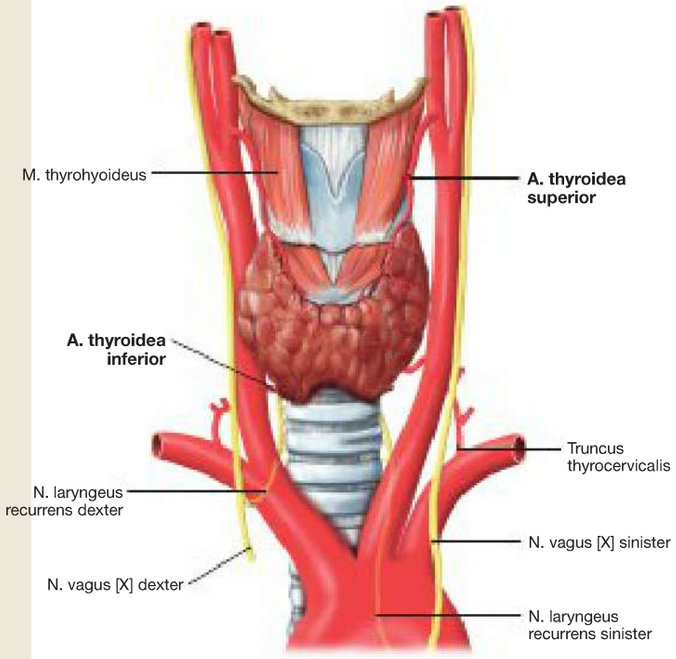

Fig. 11.63 Arteries of the thyroid gland, Glandula thyroidea; ventral view. [L275]
As an endocrine organ, the thyroid gland is very well perfused. It receives blood via the **A. thyroidea superior** (Rr. glandulares anterior and posterior) from the A. carotis externa as well as via the **A. thyroidea inferior** from the Truncus thyrocervicalis. Sometimes, a small A. thyroidea ima from the Truncus brachiocephalicus or the Arcus aortae also contributes to the blood supply (not shown). The blood vessels also supply the epithelial bodies (→ Fig. 11.65).

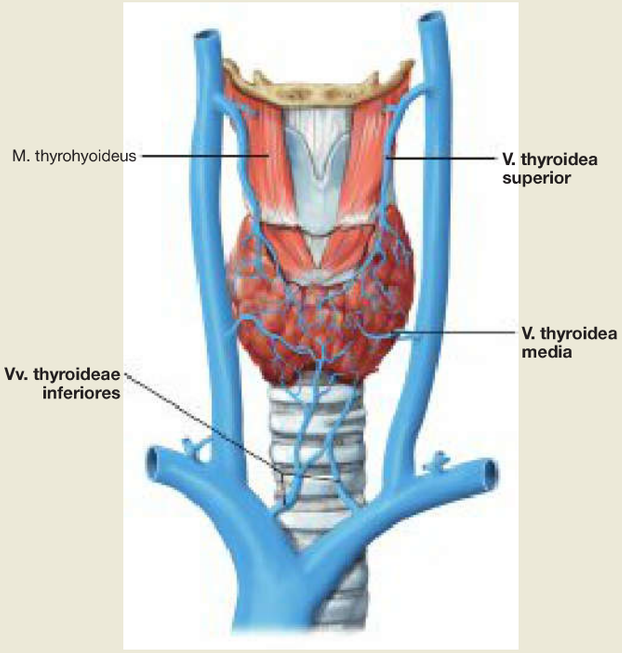

Fig. 11.64 Veins of the thyroid gland, Glandula thyroidea; ventral view. [L275]
Three paired veins collect the blood of the thyroid gland. The **Vv. thyroideae superior and media** drain into the V. jugularis interna, and the **V. thyroidea inferior** passes its blood into the left V. brachiocephalica.

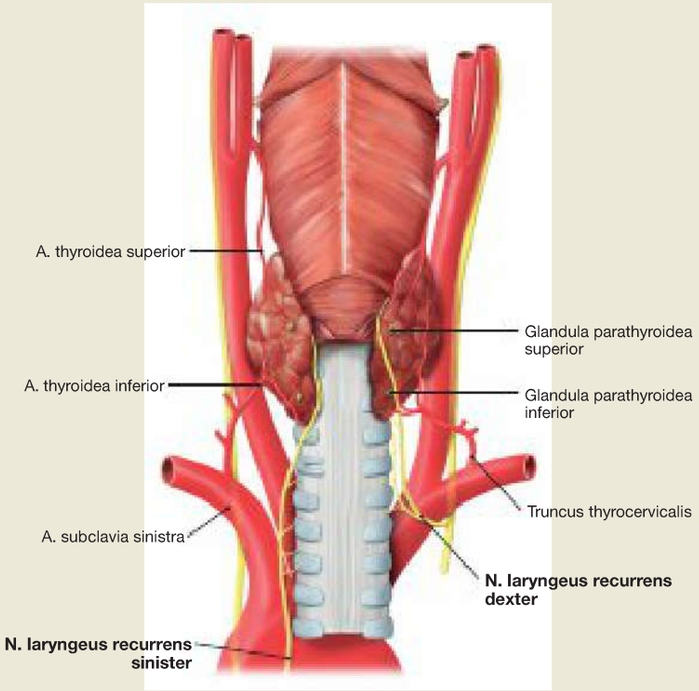

Fig. 11.65 Aa. thyroideae superior and inferior, as well as Nn. laryngei recurrentes sinister and dexter; dorsal view. [L275]
The thyroid gland has close topographical relationships with the Nn. laryngei recurrentes (Nn. laryngei inferiores). Within the groove between the trachea and the oesophagus, these nerves run cranially to the larynx (→ Fig. 11.46).

Clinical Remarks

Most common causes of **paralysis of the laryngeal muscles** are goitre operations (thyroidectomy, mostly subtotal strumectomies). The enlargement of the thyroid gland disrupts the normal topography of the N. laryngeus recurrens. Even in the case of a **goitre** the nerve maintains a close relationship with the thyroid gland and the A. thyroidea inferior, but is more difficult to localise and is therefore at great risk of injuries. An enlarged thyroid gland can constrict the trachea or in an advanced stage may lead to breathing difficulties. An operation is therefore often unavoidable.

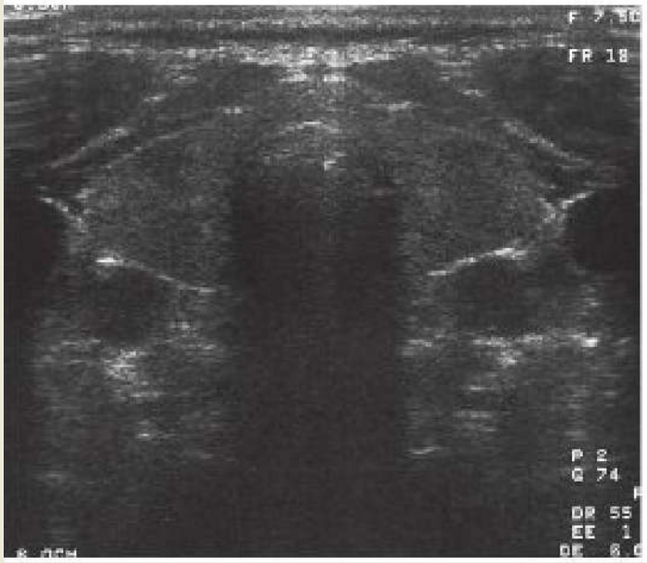

Fig. 11.66 Thyroid gland, Glandula thyroidea; ultrasound image, normal finding, cross-section at the level of the thyroid gland. [R316-007]

Fig. 11.67 Enlargement of the thyroid gland (Struma multinodosa). [T908]
One can recognise the highly enlarged thyroid gland with nodular change (multinodal goitre).

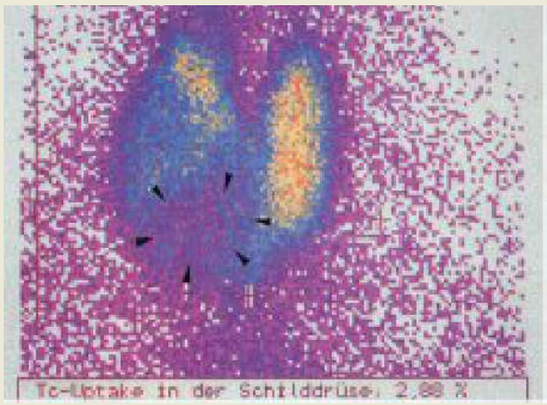

Fig. 11.68 Thyroid gland, Glandula thyroidea; scintigraphic scan, ventral view. [R132]
Thyroid scintigraphy is a functional topographical examination procedure. This scan was taken 20 minutes after intravenous injection of technetium-99m-pertechnetate and shows a cold nodule (arrowheads) in the right thyroid lobe, extending into the isthmus. In the left thyroid lobe, you can see a homogeneous distribution of nuclides. There is no active thyroid tissue in the cold nodule.

Fig. 11.69 Patient with endocrine ophthalmopathy.
Exophthalmos (bulging eyes) and retraction of the upper eyelid due to hyperthyroidism. [T127]

Clinical Remarks

The pathology of the thyroid gland is complex. **Diffuse** (→ Fig.11.67) and **focal** (→ Fig.11.68) **alterations in the thyroid gland** are the main distinctions. There are numerous causes for both. In addition, a deficient **(hypothyroidism)** or excessive production **(hyperthyroidism)** of the hormones thyroxine and tri-iodothyronine can occur. An example of this is the hyperthyroidism in a diffuse goitre **(GRAVES' disease),** which is due to an immunological process. It is frequently associated with orbitopathy. This is likely the result of circulating antibodies against an antigen derived from the external ocular muscles. The antibodies will show a cross-reaction with the microsomal fraction of the follicular epithelial cells of the thyroid gland. An **exophthalmus** can result from a retro-orbital oedema, deposition of glycosaminoglycans, lymphocytic infiltrates and progressive fibrosis (→ Fig. 11.69).

Vessels and Nerves of the Neck

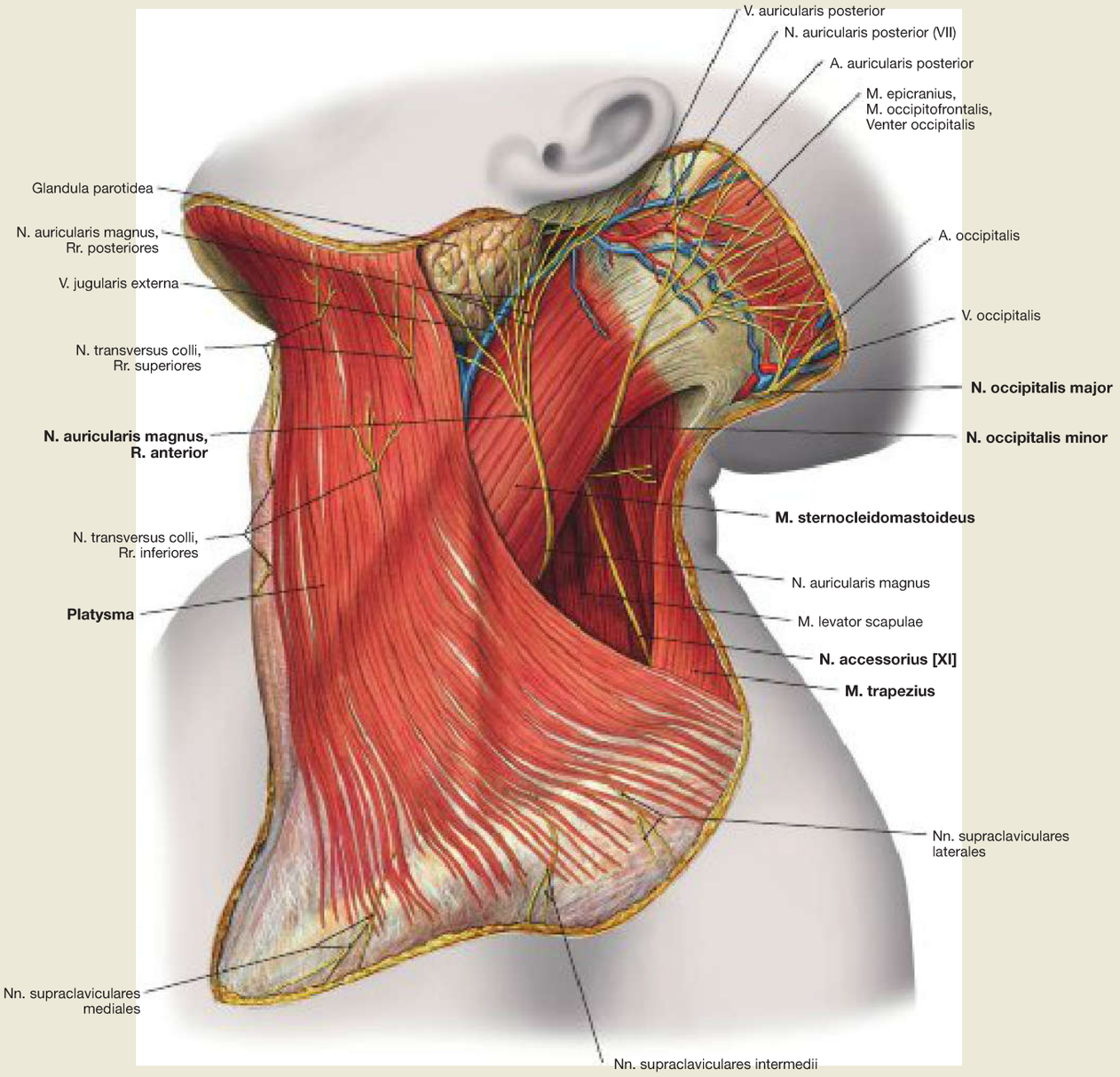

Fig. 11.70 Vessels and nerves of the anterior and lateral cervical regions, Regiones cervicales anterior et lateralis; lateral view.
The superficial fascia of the neck is positioned dorsally to the platysma. The **N. auricularis magnus** and the **N. occipitalis minor** come from behind the M. sternocleidomastoideus and curve around it in an anterior and superior direction. Both are sensory nerves derived from the Plexus cervicalis (C1–C4) and innervate the skin in front of and below the auricle to the occipital region. The **N. occipitalis major** passes through the tendinous origin of the M. trapezius at the Linea nuchalis superior and continues the sensory innervation of the skin in the occipital region. It is the R. dorsalis of the spinal nerve C2. The **N. accessorius [XI]** lies on top of the M. levator scapulae and runs through the lateral triangle of the neck from the M. sternocleidomastoideus to the M. trapezius, while innervating the two muscles. The nerve has its origin in the brain stem and the upper cervical spinal cord (→ Fig.12.172).

Clinical Remarks

In the case of surgical interventions in the lateral cervical region (e.g. removal of a neck lymph node or during a neck dissection) the **N. accessorius [XI]** is at risk. Injury to the nerve in this region will generally lead to paralysis of the M. trapezius only. The arm can no longer be elevated above the horizontal plane.

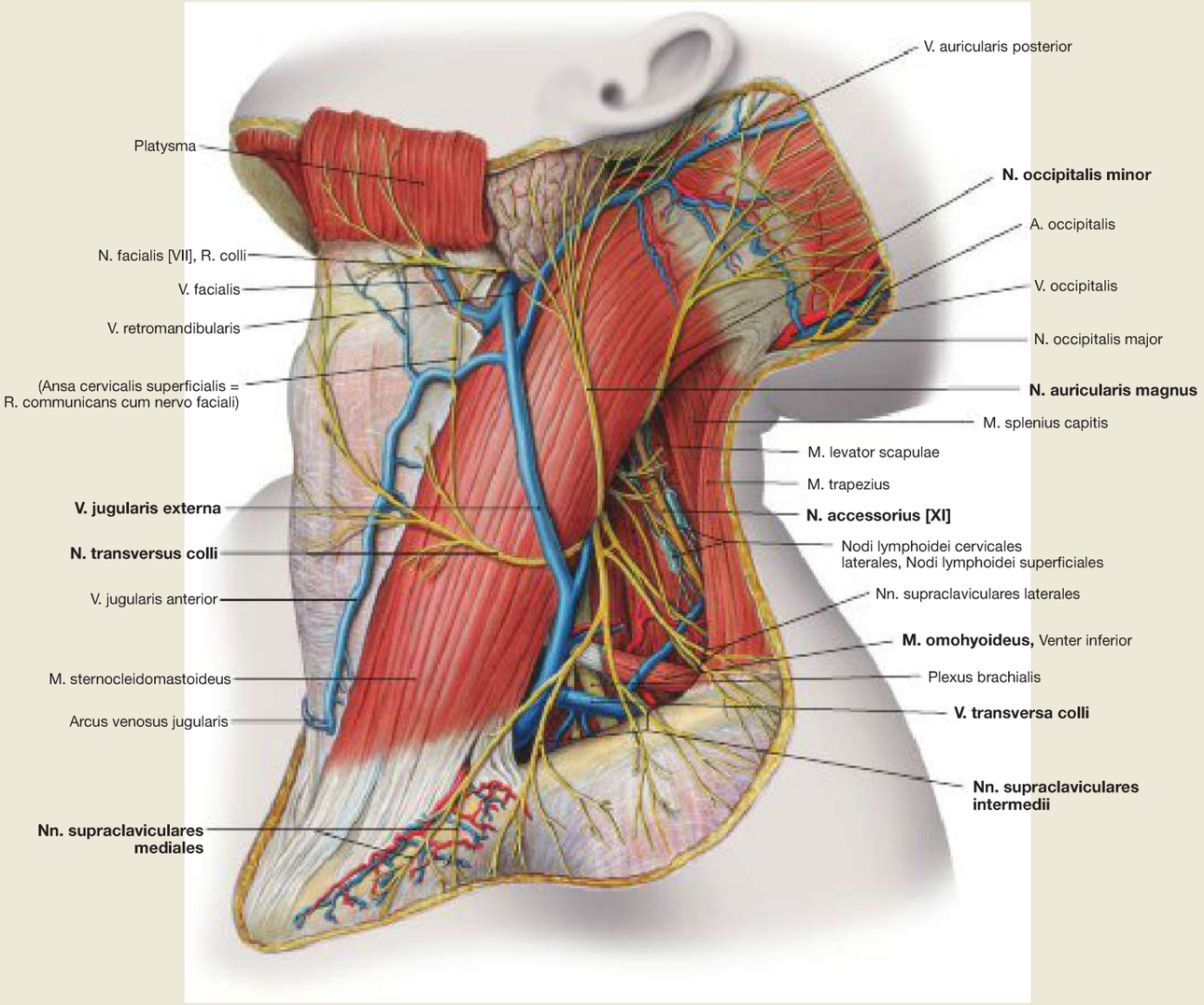

Fig. 11.71 Vessels and nerves of the lateral cervical region, Regio cervicalis lateralis, left side; lateral view. Parts of the platysma folded upwards, Lamina superficialis of the Fascia cervicalis largely removed. The sensory nerves of the Plexus cervicalis emerge at the posterior margin of the M. sternocleidomastoideus and penetrate the superficial fascia of the neck. The passageways of the Nn. supraclaviculares, the N. transversus colli and the N. auricularis magnus are located tightly packed in the middle of the muscle. This place is called the **Punctum nervosum** (ERB's point). The Punctum nervosum also includes the N. occipitalis minor, although it exits significantly more cranially. In the posterior triangle of the neck can also be seen the N. accessorius [XI], the M. omohyoideus and the V. transversa colli, which drains into the V. jugularis externa running variably across the M. sternocleidomastoideus.

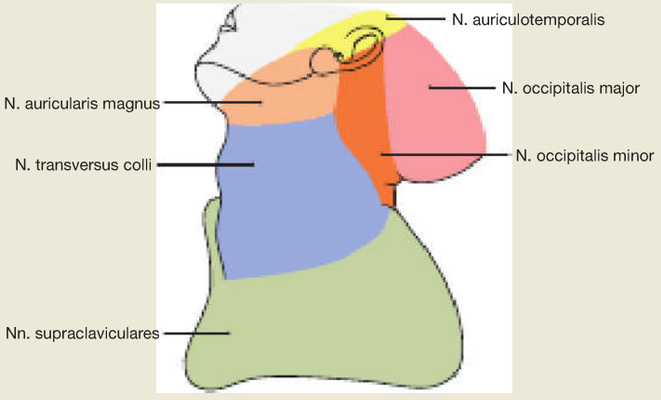

Fig. 11.72 Sensory innervation of the skin in the cervical region (cutaneous nerves). [L126]
The sensory innervation of the skin of the neck is provided by the Nn. supraclaviculares, transversus colli, auricularis magnus, occipitalis minor, occipitalis major and occipitalis tertius (not visible).

Vessels and Nerves of the Neck

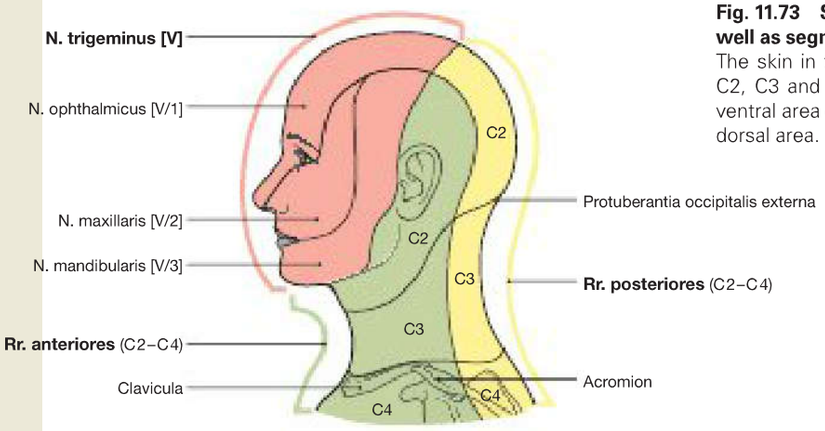

Fig. 11.73 Sensory innervation of the skin of the neck and head, as well as segmental mapping of the cutaneous areas. [L126]
The skin in the neck region is innervated from the cervical segments C2, C3 and C4. The Rr. anteriores of the spinal nerves innervate the ventral area of the neck, and the Rr. posteriores are responsible for the dorsal area.

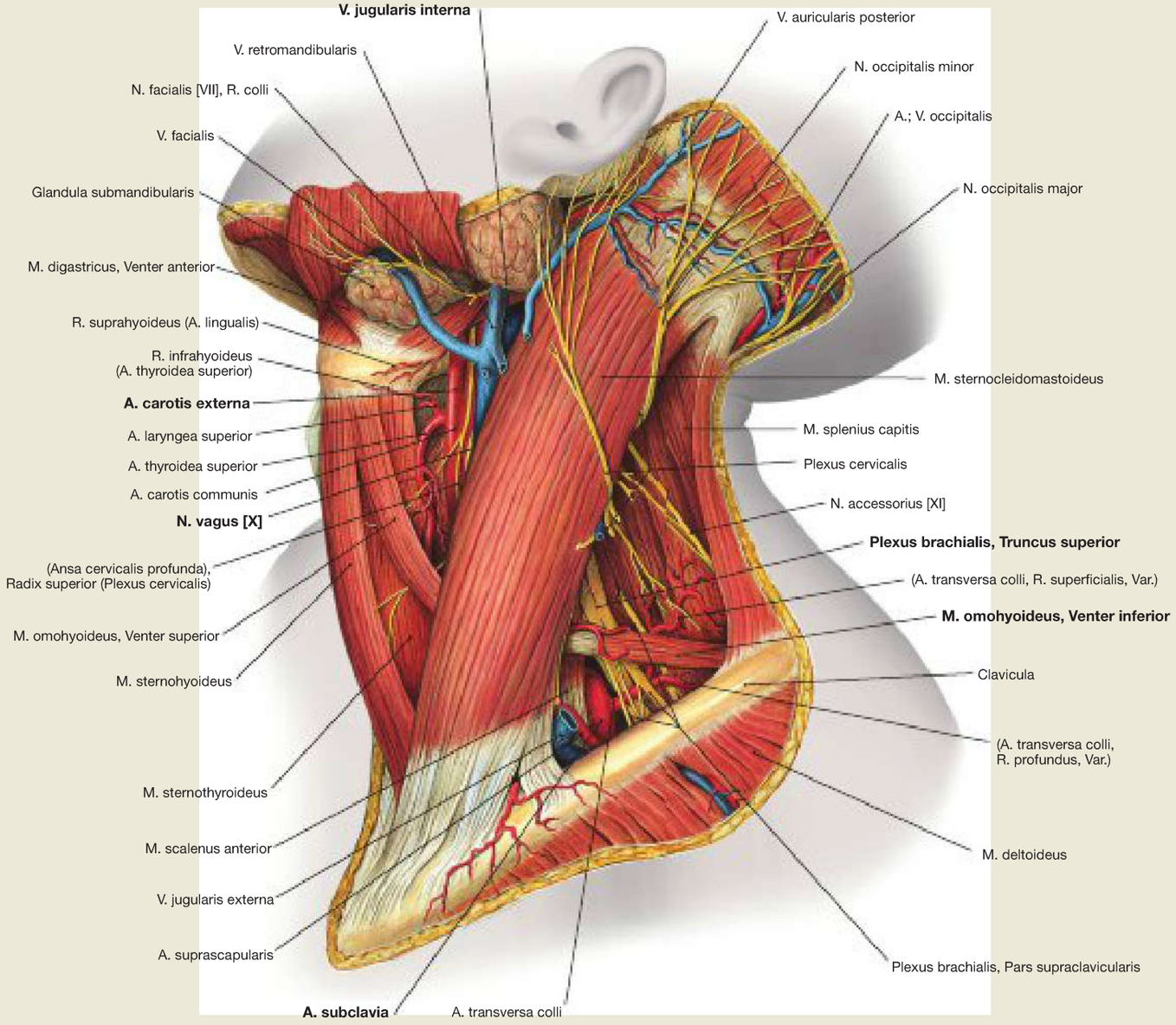

Fig. 11.74 Vessels and nerves of the anterior and lateral cervical regions, Regiones cervicales anterior et lateralis, left side; lateral view; after removal of the superficial and the middle cervical fascia.

In the anterior triangle of the neck structures are visible which are normally covered by the carotid sheath (A. carotis externa, N. vagus [X], V. jugularis interna); displayed in the posterior triangle of the neck are the Plexus brachialis and the A. subclavia in the scalene hiatus, which are crossed by the Venter inferior of the M. omohyoideus.

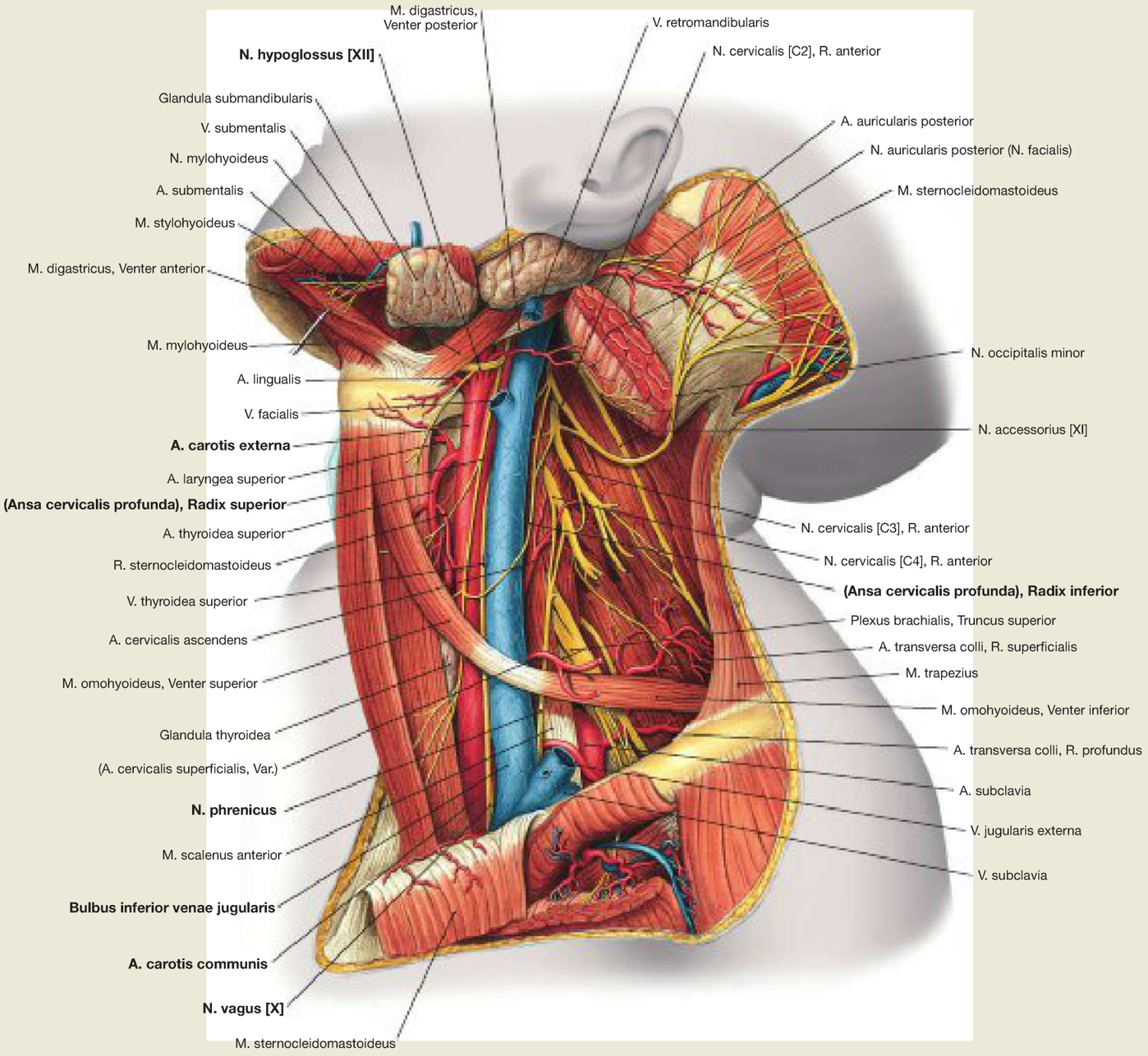

Fig. 11.75 Vessels and nerves of the lateral cervical region, Regio cervicalis lateralis, left side; lateral view; after extensive removal of the M. sternocleidomastoideus.
The removal of the M. sternocleidomastoideus permits an unobstructed view of the **A. carotis communis** in the lower cervical region, the **A. carotis externa** in the upper cervical region as well as the **N. vagus [X]** and the **V. jugularis interna.** The **Ansa cervicalis (profunda)** is positioned in the upper cervical region with its Radices superior and inferior lying around the V. jugularis interna. The Radices send branches to the infrahyoid muscles. Lateral to the V. jugularis interna, the **N. phrenicus** branches off the Plexus cervicalis and crosses the M. scalenus anterior in the lower cervical region to reach the upper thoracic aperture. In the upper cervical region, the **N. hypoglossus [XII]** passes forward across the A. carotis externa in the area of the outflow of the A. lingualis and disappears under the M. stylohyoideus.

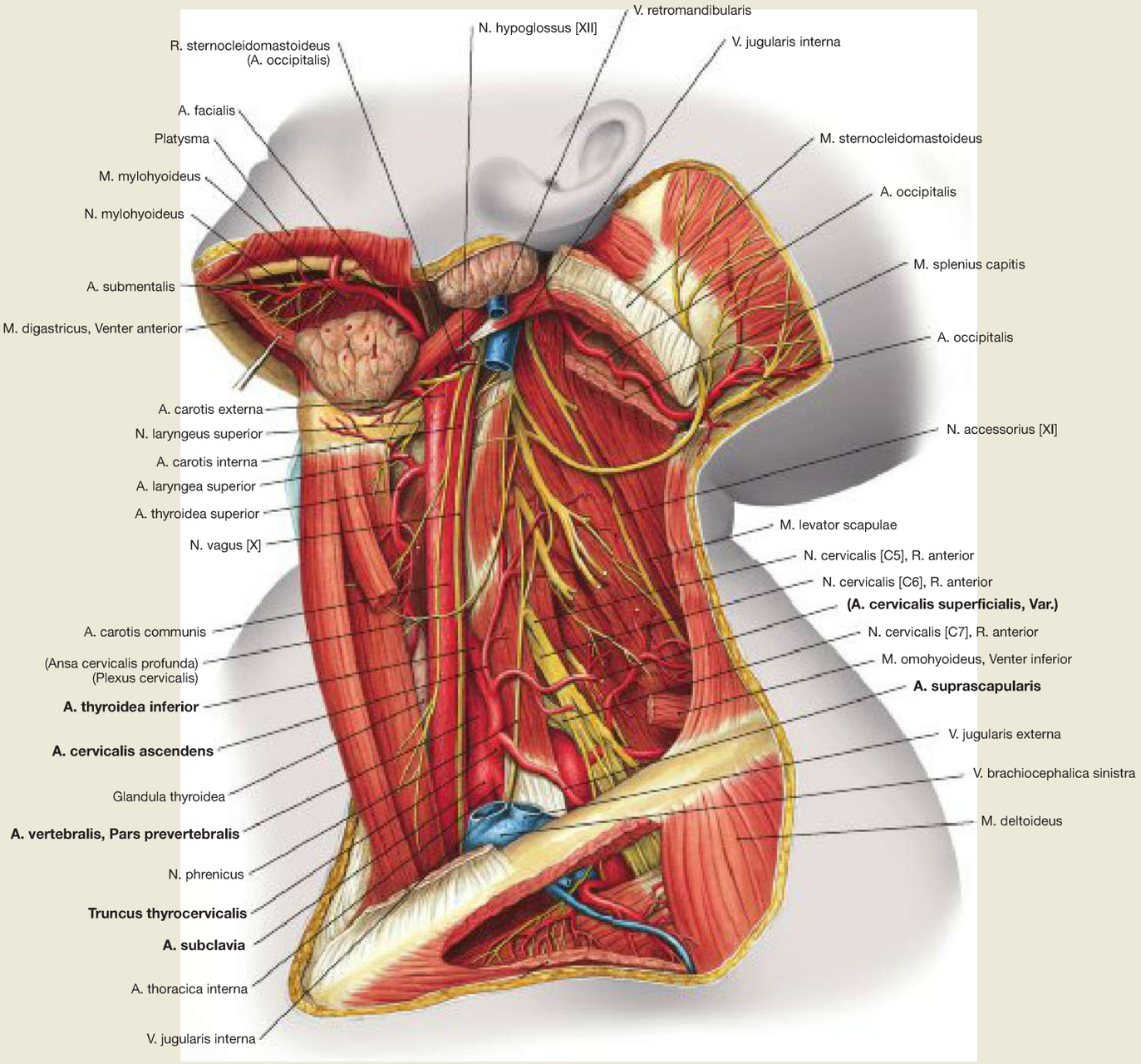

Fig. 11.76 Vessels and nerves of the lateral cervical region, Regio cervicalis lateralis, deep layer, left side; lateral view.
After removal of the V. jugularis interna it is possible to see the **A. subclavia,** the **A. vertebralis** and the **Truncus thyrocervicalis** originating from the A. subclavia. The A. subclavia runs dorsally of the M. scalenus anterior and, together with the Plexus brachialis, passes through the scalene hiatus.

Branches of the Truncus thyrocervicalis	
• A. thyroidea inferior – A. laryngea inferior – Rr. glandulares – Rr. pharyngeales – Rr. oesophageales – Rr. tracheales	• A. suprascapularis – R. acromialis • A. transversa colli – R. superficialis – R. profundus
• A. cervicalis ascendens – Rr. spinales	• (A. dorsalis scapulae)

Clinical Remarks

A proximal high-grade stenosis (narrowing) of the A. subclavia sinistra, or less frequently of the A. subclavia dextra, can result in a retrograde (reversed) flow in the A. vertebralis of the affected side during intense physical activity of the arm **(subclavian steal syndrome; SSS).** The resulting reduction in the blood perfusion of the brain can cause dizziness and headaches.

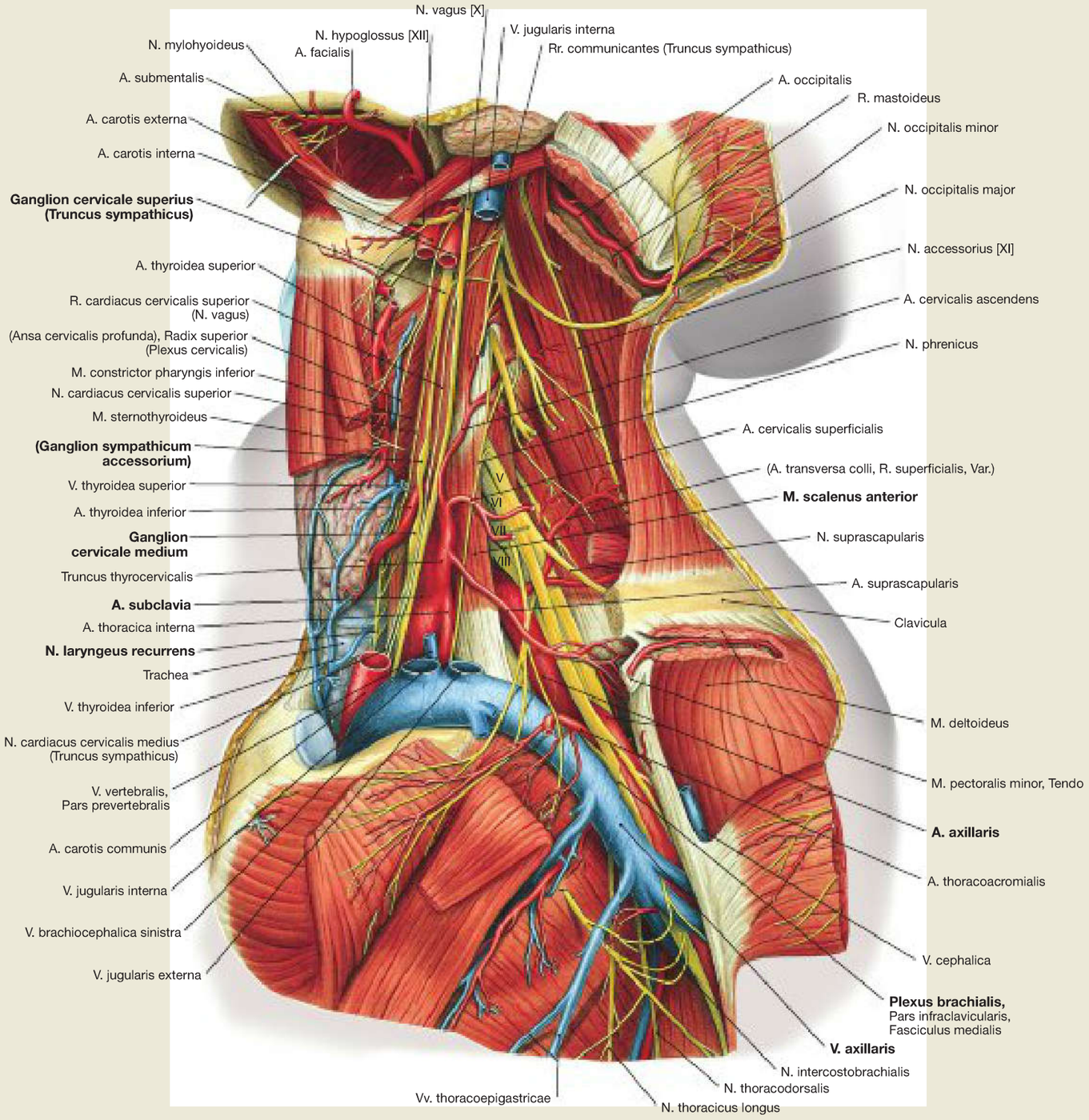

Fig. 11.77 Vessels and nerves of the lateral cervical region, Regio cervicalis lateralis, and the axillary region, Regio axillaris.
The numbers V to VIII mark the ventral branches of the corresponding cervical nerves.
After the removal of the anterior two-thirds of the Clavicula, the **Plexus brachialis** and the **A. subclavia** passing through the scalene hiatus (between M. scalenus anterior and M. scalenus medius), and the course of the V. subclavia (in front of the M. scalenus anterior) across the first rib into the upper limb are visible. In some cases, the upper part of the Plexus brachialis can penetrate the M. scalenus medius. In the cervical region, the Plexus brachialis delivers several smaller branches and rearranges itself after multiple fibre exchanges to fascicles, all of which lie just below the Clavicula, laterally from the A. subclavia. Only in the middle of the axilla they reach the topographical position as depicted by their name.
On top of the deep neck muscles lies the **Truncus sympathicus** with the Ganglia cervicalia superius and medium (in the upper cervical region the Truncus sympathicus runs within the general organ fascia, in the lower cervical region between the Fascia prevertebralis and the general organ fascia, not shown). Between the trachea and the oesophagus, the **N. laryngeus recurrens** is visible below the thyroid gland.

Plexus cervicalis

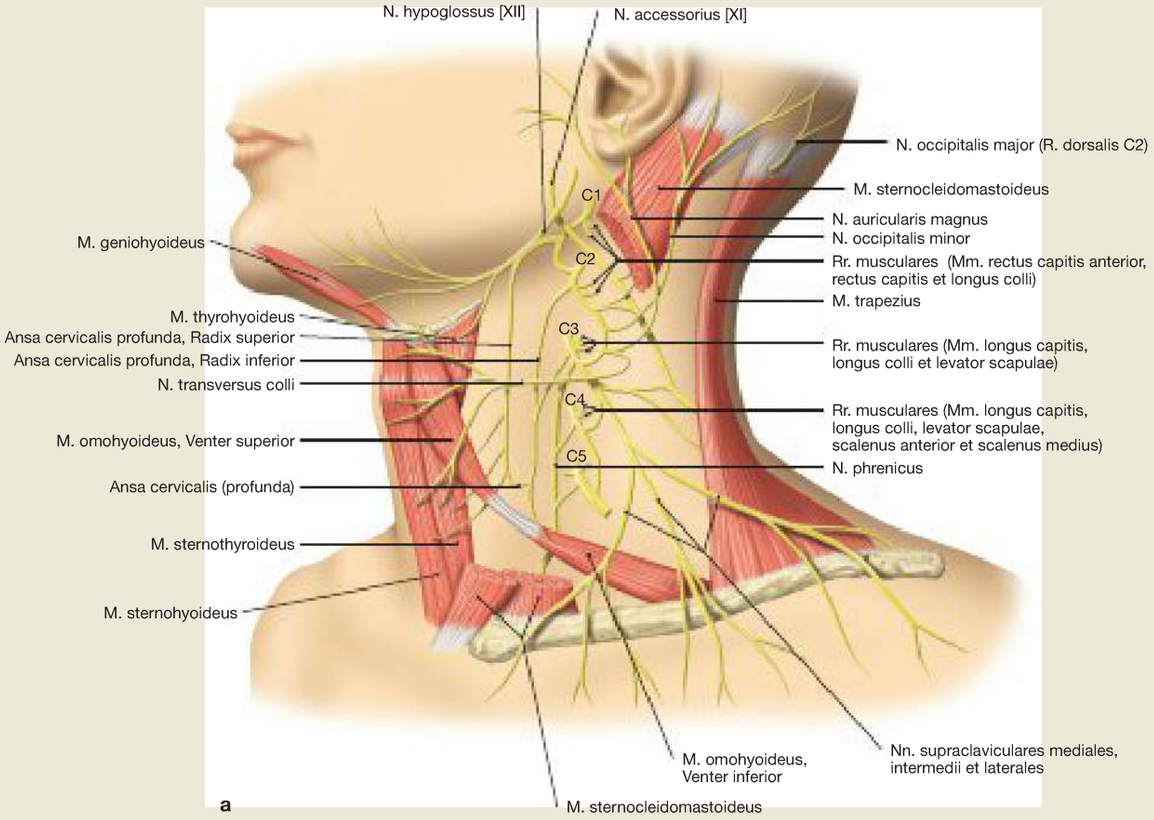

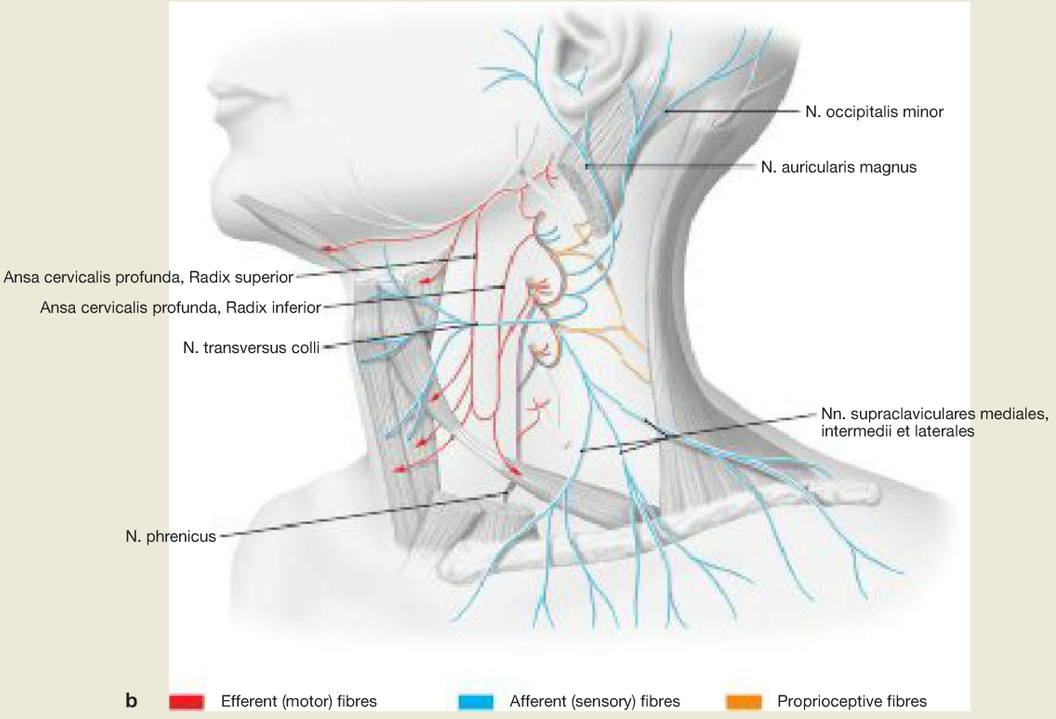

Fig. 11.78a and b Plexus cervicalis, sensory and motor branches. Schematic drawing. [L127]
For teaching purposes, nerves, muscles and bones in the figure are projected onto the body surface without regard to topographical layers. Thus, for example, the M. geniohyoideus appears to be on the outside of the Mandibula and the N. hypoglossus looks like a cutaneous nerve. The Ansa cervicalis profunda and the N. phrenicus constitute the motor branches of the Plexus cervicalis. The **Ansa cervicalis profunda,** consisting of a Radix superior from segment C1 and a Radix inferior from segments C2 and C3, serves to innervate the infrahyoid muscles (Mm. thyrohyoideus, sternohyoideus, sternothyroideus, and omohyoideus). Additional motor branches innervate the suprahyoid M. geniohyoideus, the prevertebral muscles, the M. rectus capitis anterior, the Mm. scaleni anterior and medius, as well as parts of the M. levator scapulae. The **N. phrenicus** derives from the segments C3 to C5, runs caudally, and enters the thoracic cavity through the upper thoracic aperture.

→T 7

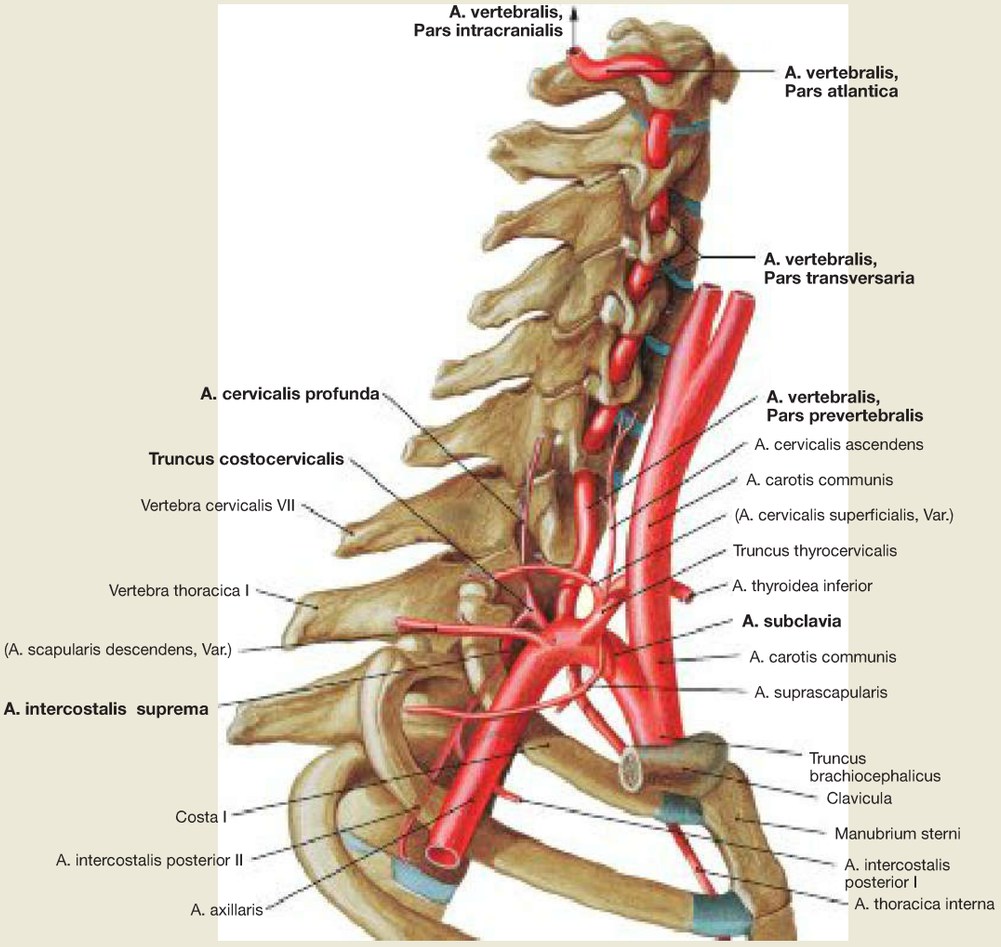

Branches of the A. vertebralis

- **Pars prevertebralis**
- **Pars transversaria [cervicalis]**
  - Rr. spinales
    - Rr. radiculares
    - Aa. medullares segmentales
  - Rr. musculares
- **Pars atlantica**
- **Pars intracranialis**
  - Rr. meningei
  - A. inferior posterior cerebelli
    - A. spinalis posterior
    - R. tonsillae cerebelli
    - R. choroideus ventriculi quarti
  - A. spinalis anterior
  - Rr. medullares mediales et laterales

Branches of the Truncus costocervicalis

- A. cervicalis profunda
- A. intercostalis suprema
  - A. intercostalis posterior prima
  - A. intercostalis posterior secunda
    - Rr. dorsales
    - Rr. spinales

Fig. 11.79 Branches of the Aa. subclavia and vertebralis, as well as the Truncus costocervicalis; lateral view.

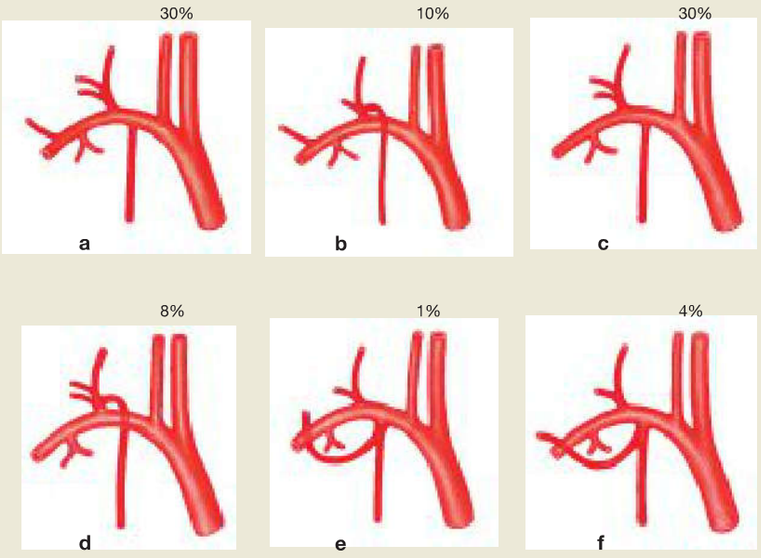

Fig. 11.80a to f Variations of branching types of the A. thyroidea inferior, A. suprascapularis, A. transversa colli and A. thoracica interna with separate outflow from the A. vertebralis and Truncus costocervicalis.

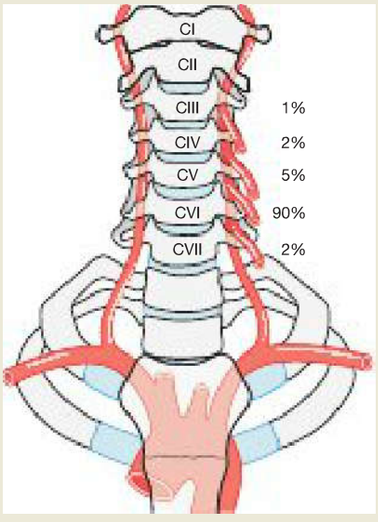

Fig. 11.81 Variations of the entry level of the A. vertebralis into the Foramina transversaria. [L126]

Veins of the Neck

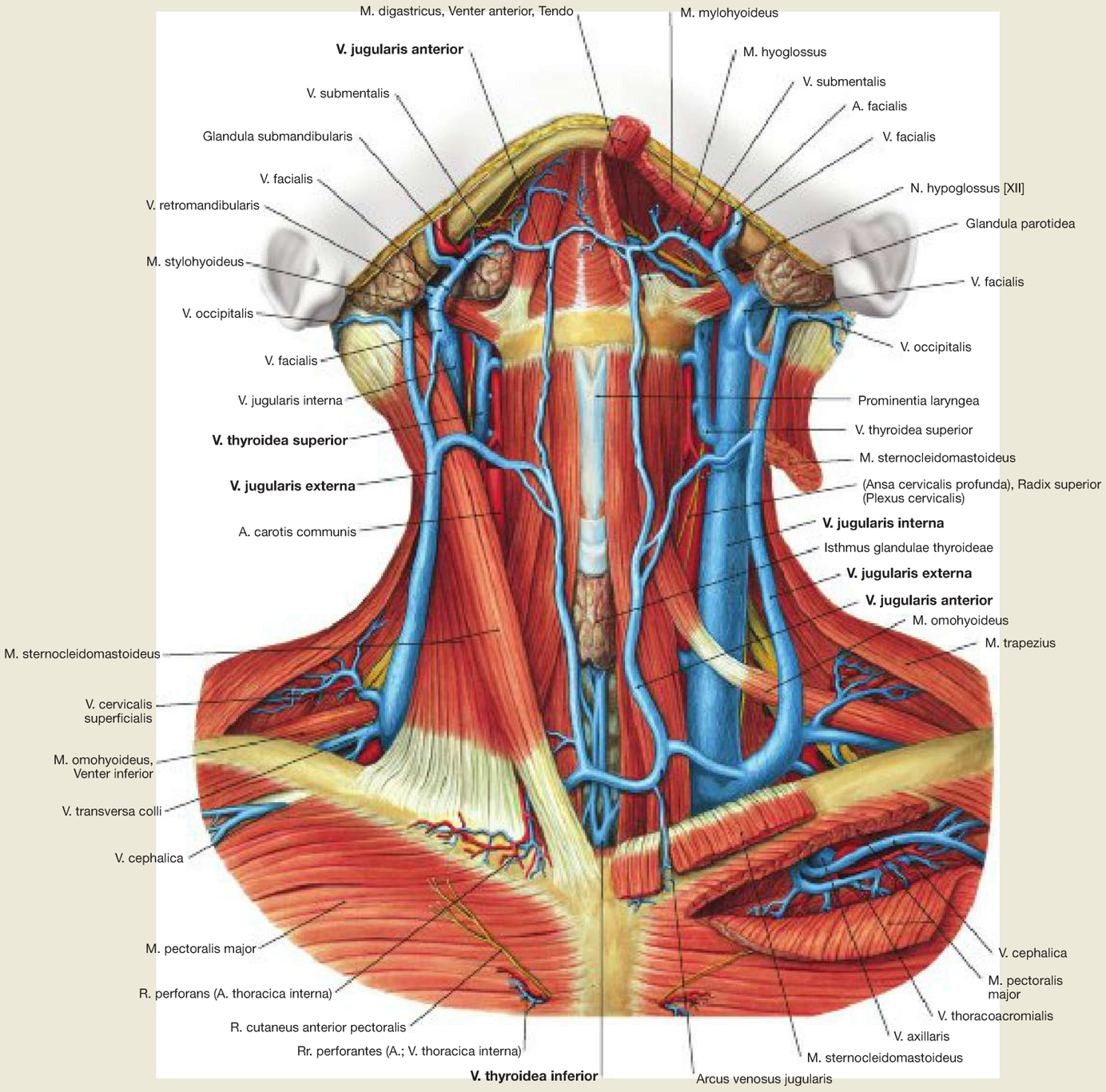

Fig. 11.82 Veins of the neck; ventral view.
The M. sternocleidomastoideus was largely removed on the left side. All cervical fascias are removed.
Superficial veins of the neck are the Vv. jugulares anteriores and the Vv. jugulares externae, which drain venous blood into the Vv. jugulares internae, subclaviae and brachiocephalicae. The **deep** cervical veins include the Vv. jugulares internae and thyroideae superiores, the V. thyroidea inferior and the Plexus thyroideus impar (not visible). The course of the superficial veins is very variable.

Clinical Remarks

The creation of an **intravenous access** is the most commonly used invasive technique in preclinical emergency care. The V. jugularis externa provides a good accessibility for venipuncture, even where veins are in poor condition. The guidelines for cardiovascular resuscitation recommend this as the first choice for an intravenous access route.

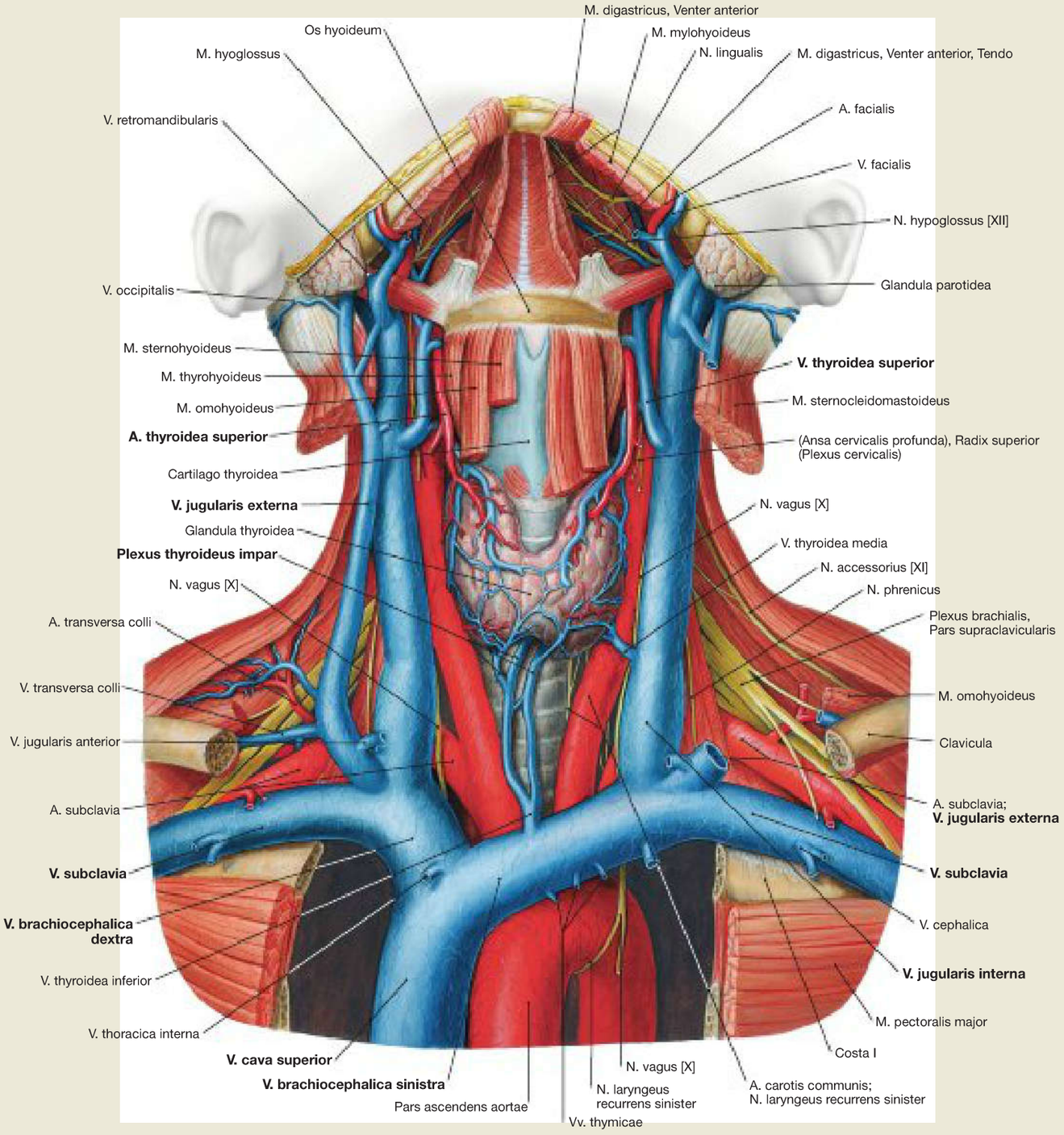

Fig. 11.83 Vessels and nerves of the neck, and upper thoracic aperture, Apertura thoracis superior; ventral view.
The sternum, parts of the Clavicula, the M. sternocleidomastoideus, and parts of the infrahyoid muscles were removed.
Presentation of the venous tributary of the **V. cava superior** (Vv. brachiocephalicae, jugulares internae, jugulares externae and subclaviae) with particular emphasis on the venous drainage of the thyroid gland (→ Fig.11.64). In addition, one can see the passage of the Plexus brachialis, the A. and V. subclavia running between the Clavicula and first rib, the course of the N. phrenicus on the M. scalenus anterior and the course of the left N. laryngeus recurrens around the Arcus aortae.

Clinical Remarks

The **PANCOAST's tumour** (apical sulcus tumour) is a rapidly progressing peripheral bronchial carcinoma in the apex of the lung (Apex pulmonis; → Fig. 11.89), which spreads relatively quickly into ribs, soft tissues of the neck, Plexus brachialis, and vertebrae. Other affected structures can be the N. phrenicus, the N. laryngeus recurrens, the A. and V. subclavia, and the Ganglion stellatum (with HORNER's triad: enophthalmus, miosis, narrow eyelid fissures).

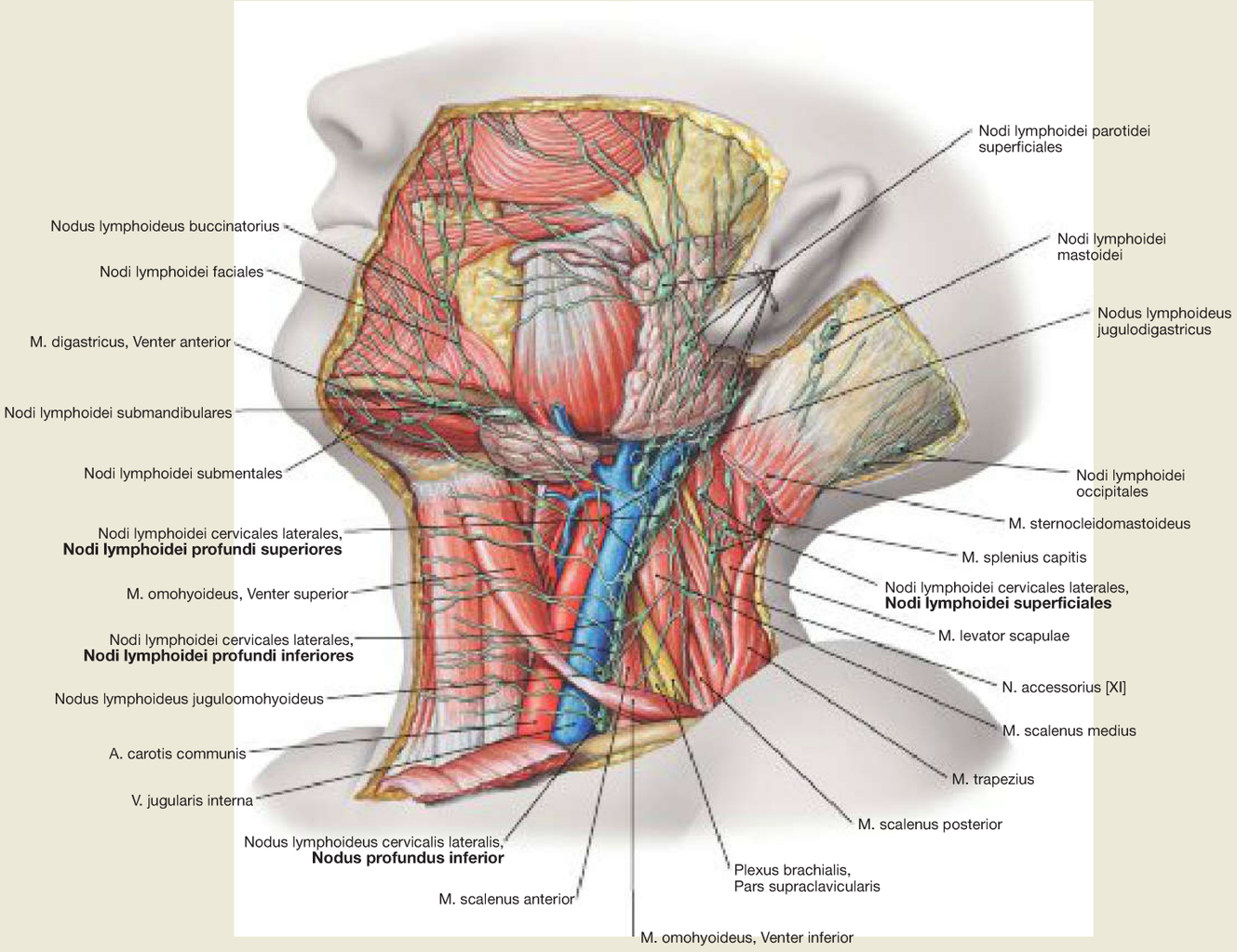

Fig. 11.84 Superficial lymphatic vessels, Vasa lymphatica superficialia, and lymph nodes, Nodi lymphoidei, of the head and neck of a child.
The cervical region contains 200 to 300 lymph nodes. The largest part of it is arranged along the neurovascular bundle (→ Table, → Fig. 8.98).

Lymphatic fluid of the right side of the head and neck drains into the **Ductus lymphaticus dexter** (→ Fig. 8.99), whereas the left side of the head and neck drains into the **Ductus thoracicus**. For the entry of the Ductus thoracicus into the left venous angle → Figure 11.91.

Lymph Nodes of the Neck (Nodi lymphoidei cervicales)	
Nodi lymphoidei cervicales anteriores	**Nodi lymphoidei cervicales laterales**
• Nodi lymphoidei superficiales	• Nodi lymphoidei superficiales
• Nodi lymphoidei profundi – Nodi lymphoidei infrahyoidei – Nodi lymphoidei prelaryngei – Nodi lymphoidei thyroidei – Nodi lymphoidei pretracheales – Nodi lymphoidei paratracheales – Nodi lymphoidei retropharyngeales	• Nodi lymphoidei profundi superiores – Nodus lymphoideus jugulodigastricus – Nodus lymphoideus lateralis – Nodus lymphoideus anterior
	• Nodi lymphoidei profundi inferiores – Nodi lymphoidei juguloomohyoidei – Nodus lymphoideus lateralis – Nodi lymphoidei anteriores
	• Nodi lymphoidei supraclaviculares
	• Nodi lymphoidei accessorii – Nodi lymphoidei retropharyngeales

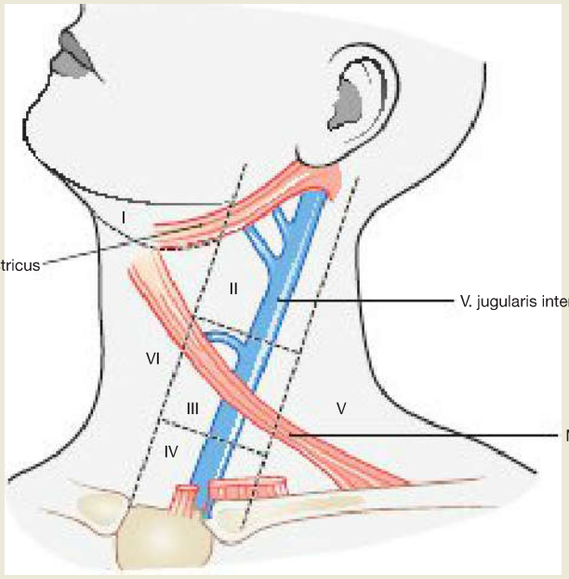

Fig. 11.85 Drainage areas of the head and neck, division into compartments; according to the classification of the American Joint Committee of Cancer (AJCC). [L126]

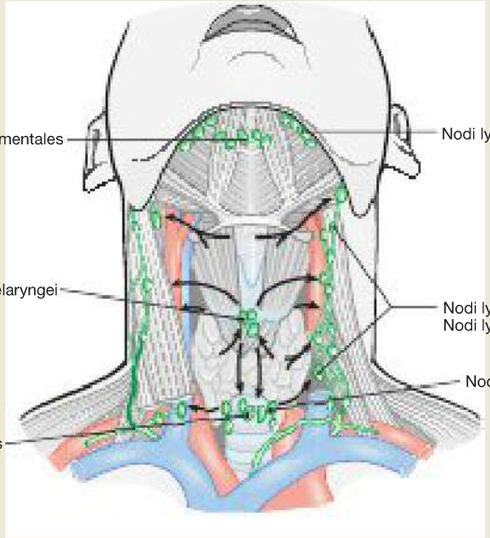

Fig. 11.86 Lymphatic vessels and lymph nodes of the larynx, thyroid gland, Glandula thyroidea, and trachea; ventral view. [L126]
All three organs drain into the deep lymph nodes of the neck.

Clinical Remarks

According to the classification of the American Joint Committee of Cancer (AJCC), the lymph nodes of the neck, in terms of the onset of regional **lymph node metastases,** are divided into six zones (**compartments I–VI;** → Fig.11.85). These compartments serve as reference zones for the elective surgical removal of lymph nodes with metastases due to the lymphogenic spread of malignant tumours of the head and neck region (neck dissection).
Injuries to the Ductus thoracicus during surgery in the neck region can lead to the formation of a **chylous fistula.**

Vessels and Nerves of the Trigonum submandibulare

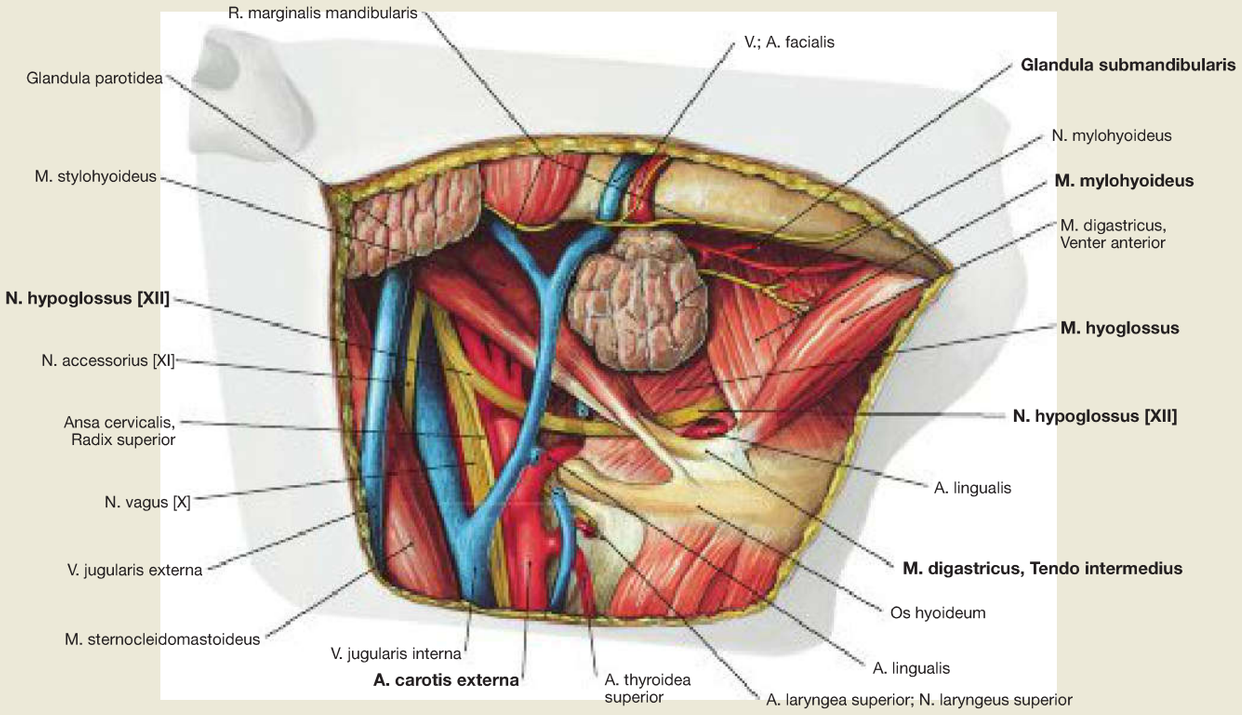

Fig. 11.87 Vessels and nerves of the Trigonum submandibulare; inferolateral view.
After removal of all fascial layers to expose the Glandula submandibularis and the neurovascular pathways, the arc-shaped course of the **N. hypoglossus [XII]** can be seen; this nerve leaves the neurovascular bundle in the parapharyngeal space and passes forwards across the A. carotis externa, running between the M. hyoglossus and the intermediate tendon of the M. digastricus, until it disappears under the M. mylohyoideus.

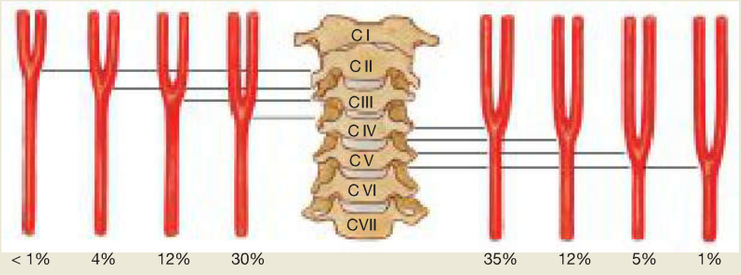

Fig. 11.88 Level of the bifurcation of the A. carotis communis, with regard to the cervical vertebral column; frontal view.
Generally the bifurcation of the A. carotis communis is located between CIII and CIV. In rare cases, it can also be positioned higher (CII) or lower (under edge CV).

Clinical Remarks

Inflammations in the region of the lower molars can lead to an **abscess formation in the fascial compartment of the Glandula submandibularis** and the sublingual compartment. Abscesses from the wisdom teeth can even extend into the fascial compartment of the Fossa retromandibularis and descend from here along the cervical fascia into the mediastinum to cause a life-threatening infection.
Injury to the N. hypoglossus [XII], e. g. due to tumour infiltration of a cervical lymph node metastasis, is easy to diagnose: when sticking out the tongue, it deviates to the diseased side since the muscles pushing it out on the healthy side no longer have any opposition on the diseased side.

The carotid bifurcation is often affected by **vascular changes** (extracranial arteriosclerosis: plaques, stenosis, obliteration). The Glomus caroticum located in the carotid bifurcation (not shown in → Fig. 11.87) is a paraganglion that contains chemoreceptors, which react to changes in the pH, oxygen and carbon dioxide content of the blood. A **carotid sinus syndrome** is defined as hypersensitivity of the pressoreceptors of the carotid sinus, which often triggers a reflex at rotating movements of the head, which in turn strongly reduces the heart rate (vasovagal reflex). This can result in major circulatory complications and cardiac arrest.

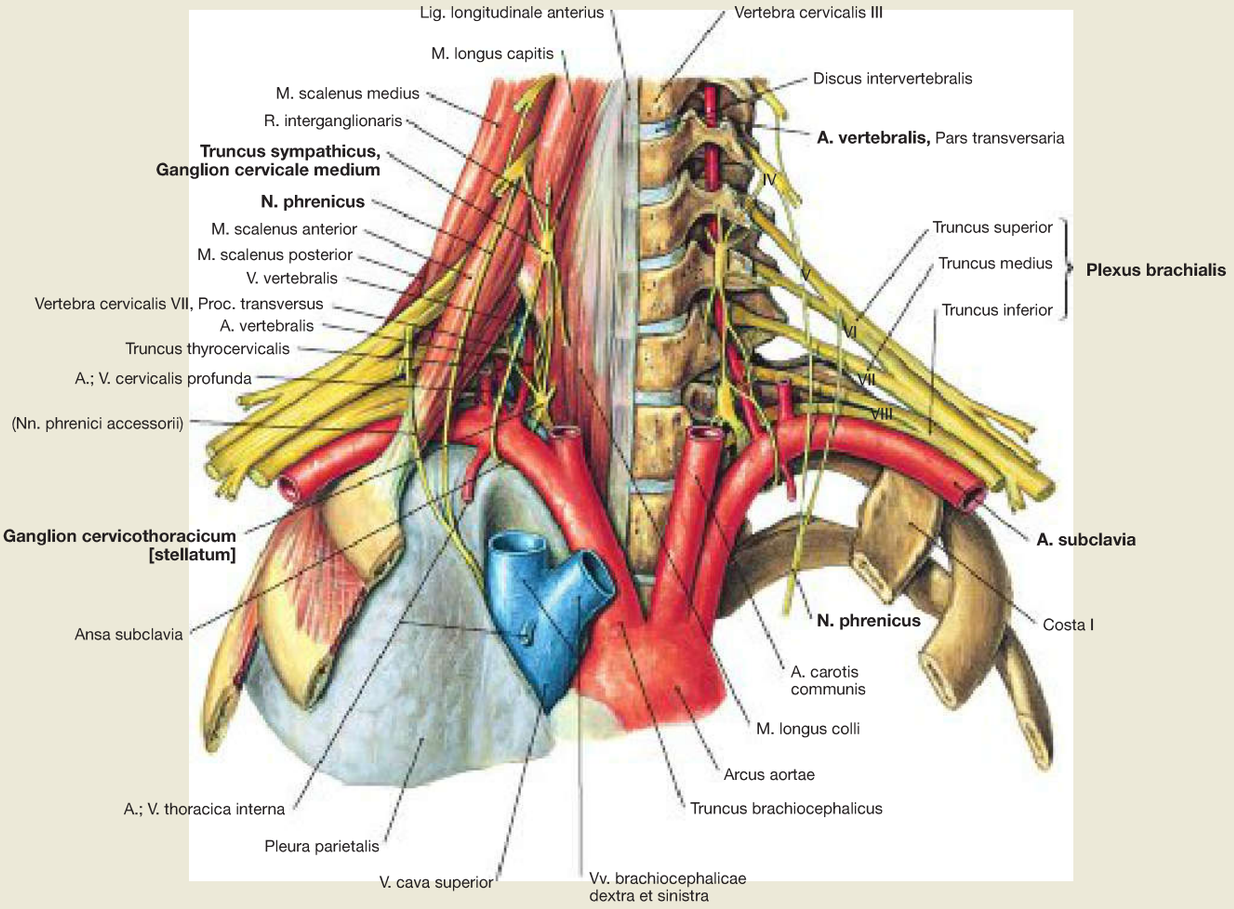

Fig. 11.89 Vessels and nerves in the transition zone from the neck to the thorax and to the upper limb.
Visible are the pleural cupula with the scalene hiatus, the lower and middle sympathetic ganglia (Ganglion cervicale inferius/cervicothoracicum/stellatum on the head of rib I and Ganglion cervicale medium on the M. longus colli), the course of the N. phrenicus, the course of the A. vertebralis, and the trunks of the Plexus brachialis and the A. subclavia. The numbers IV to VIII indicate the ventral branches of the corresponding spinal nerves.

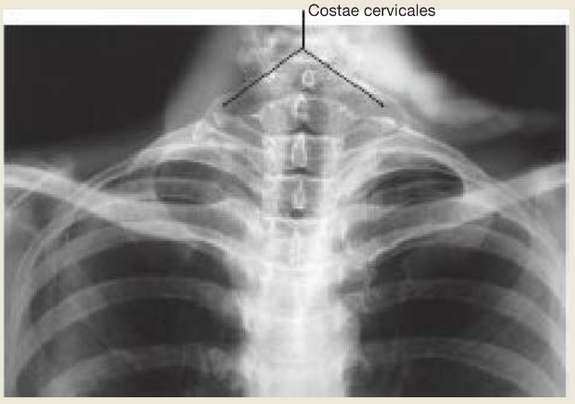

Fig. 11.90 Neck, Collum; X-ray in anteroposterior (AP) beam projection. [E402]
On both sides a cervical rib can be seen (Costa cervicalis).

Clinical Remarks

Anatomic variations in the region of the scalene hiatus (cervical rib [cervical rib syndrome], narrow scalene hiatus, accessory M. scalenus minimus, or aberrant muscular fibres [collectively called **scalenus anticus syndrome],** or narrowing of the space between rib I and Clavicula [costoclavicular syndrome]) can cause a **thoracic outlet syndrome (TOS).** The TOS can result in the compression of the Plexus brachialis and the A. subclavia.
In the scalene hiatus, an **interscalene brachial plexus block** can be applied for the local anaesthesia of the Plexus brachialis.

Pleural Cupula and Entry of the Ductus thoracicus

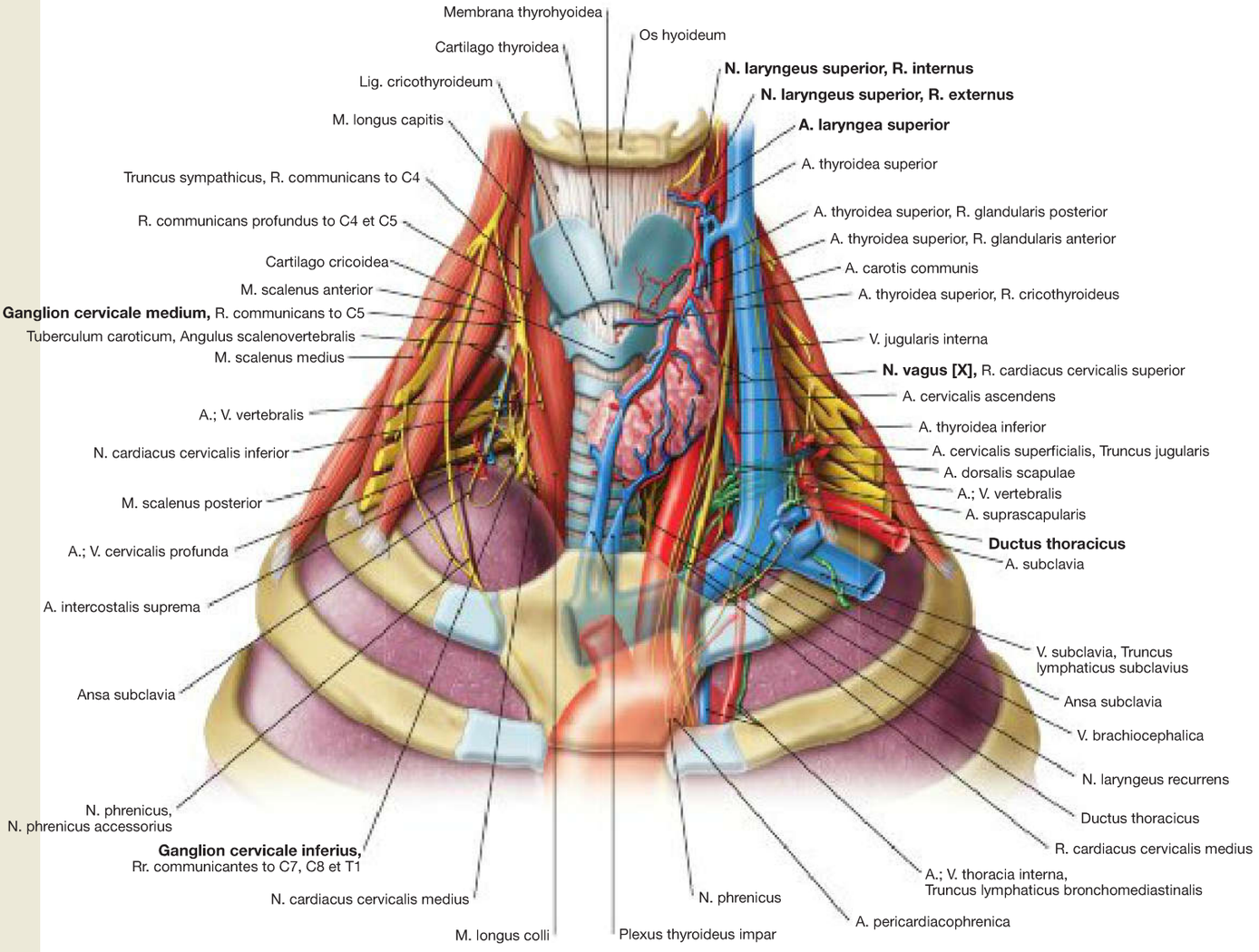

Fig. 11.91 Prevertebral and paravertebral structures of the neck and the upper thoracic aperture; ventral view. [L238]
On the right side of the body, the great blood vessels were removed to permit an unobstructed view of the pleural cupula and the Truncus sympathicus. You can see the **Ganglion cervicale inferius** (Ganglion cervicothoracicum [stellatum]) on the head of rib I and the **Ganglion cervicale medium** on the M. longus colli. The pleural cupula extends beyond the upper thoracic aperture. On the left side, the great blood vessels and the left thyroid lobe were left in place. It is possible to see the blood supply to the thyroid gland, the R. internus of the N. laryngeus superior and the Vasa laryngea superiora, the entry of the Ductus thoracicus into the left venous angle as well as the course of the N. vagus [X] between the A. carotis communis and the V. jugularis interna.

Practice Exam Questions

To check that you are completely familiar with the content of this chapter, practice questions from an oral anatomy exam are listed here.

Explain the structure of the neck:

- Which regions of the neck do you know and how are they delimited?
- How is the Regio cervicalis anterior subdivided and where are the boundaries?
- Which osseous parts of the skeleton are found in the pharyngeal region?
- What is the function of the Os hyoideum?
- Are there any mimetic muscles located in the pharyngeal region?
- Explain the course, function, blood supply and innervation of the M. sternocleidomastoideus.
- Where is the infrahyoid muscle? What is its function and how is it innervated?
- Which suprahyoid muscles do you know? Explain their location, function and innervation.
- What is the function of the prevertebral muscular system, where is it located, what are the muscles called and how are they innervated?

Describe the structure of the Fascia cervicalis:

- How can the Fascia cervicalis be categorised?
- Can you name muscles included in the superficial Fascia cervicalis?
- Which structures are located in the carotid sheath?
- Which cervical organs have their own fascia (organ fascia)?
- Name virtual spaces/compartments within the connective tissue of the neck, enclosed by fascias.
- Which structures are located in the Spatium lateropharyngeum?
- How far does the Spatium retropharyngeum extend in the cranial and caudal direction?
- What is meant by the term Spatium peripharyngeum?

Describe the neurovascular pathways in the pharyngeal region:

- Which branches usually emerge from the Truncus thyrocervicalis, and which from the Truncus costocervicalis?
- How does the A. vertebralis run through the pharyngeal region?
- At which height does the carotid bifurcation usually lie? Which organ can be found in the bifurcation?
- Name branches of the A. carotis externa.
- Which large veins are located in the pharyngeal region?

Explain the route of the nerves in the pharyngeal region:

- What is the ERB's point? Where is it located and which branches does it provide? What is another name for it?
- What is meant by the Ansa cervicalis?
- Describe the course of the N. phrenicus through the pharyngeal region.
- Which motor branches are in the Plexus cervicalis?
- Which muscle is innervated from the Plexus cervicalis via an anastomosis with the N. hypoglossus?
- What is the scalene hiatus? What passes through it?
- Describe the course of the N. accessorius. Which muscles does it innervate and what is their function?
- Where does the Truncus sympathicus run in the pharyngeal region? Which ganglia do you know in the cervical region?
- Describe the course of the N. vagus from the point where it passes through the cranial base. Which branches run through the cervical region? What do they innervate here?

Explain the lymphatic drainage of the neck:

- How many lymph nodes are there in the cervical region?
- Which lymph node groups are there in the cervical region?
- Why is the neck divided into distinct regions (compartments) of lymphatic drainage?
- Which structures drain their lymph into the cervical lymph nodes?

Describe the structure of the thyroid and the parathyroid glands:

- Explain the location, structure and function of the thyroid gland.
- How does the thyroid gland develop?
- What is a Lobus pyramidalis? On what can it have a disruptive effect?
- What can develop when a part of the Ductus thyroglossus persists during development? From what should it be differentiated?
- How is the thyroid gland supplied with blood?
- Where are the parathyroid glands usually located?
- Which structure is particularly vulnerable during thyroid gland surgery?

Explain the position and structure of the larynx:

- How is the larynx structured?
- Which muscles are involved in the tensioning of the Plicae vocales?
- How is the larynx supplied with blood?
- Describe the innervation of the larynx.
- What is a coniotomy? Where is it performed?
- Which muscle in particular is activated when breathing in and out deeply?
- What is the Conus elasticus, and the Membrana quadrangularis?
- Which structures form the Plica vocalis?
- What is the REINKE's space?
- What is the function of the Plica vocalis?
- What is the function of the Plica vestibularis?
- What is meant by the mucosal wave?
- Which spaces or compartments of the larynx do you know?
- From where to where does the transglottic space extend?
- What innervates the N. laryngeus superior?
- Describe the course of the N. laryngeus recurrens/inferior on the left and on the right side.
- How is the epiglottis structured and where is it attached? Are muscles involved in the movement of the epiglottis?
- Are you aware of changes in the laryngeal structures that contribute to voice alterations with age?
- Show the Recessus piriformis.

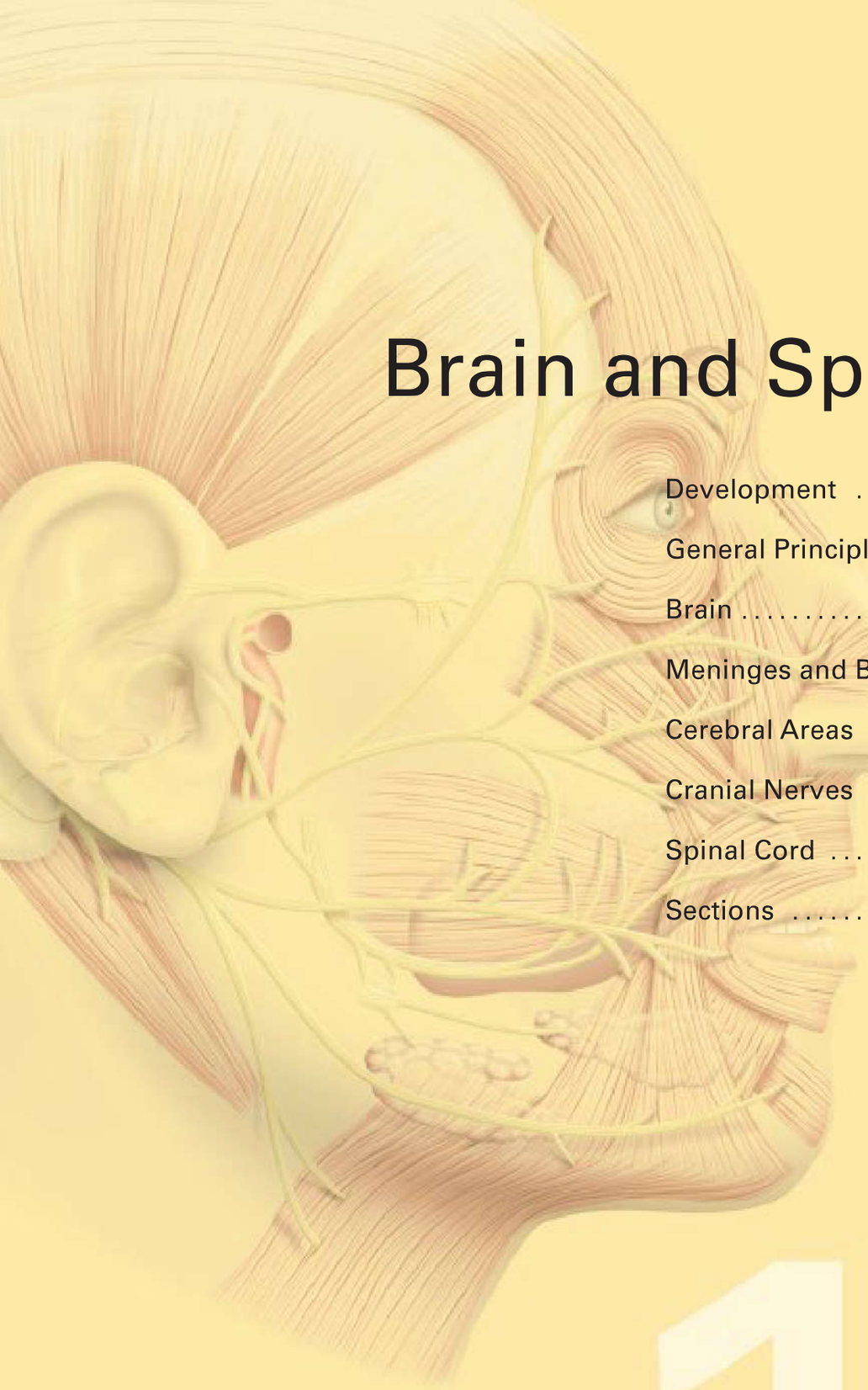

Brain and Spinal Cord

Development 260

General Principles 270

Brain 272

Meninges and Blood Supply 295

Cerebral Areas 317

Cranial Nerves 345

Spinal Cord 392

Sections 425

12

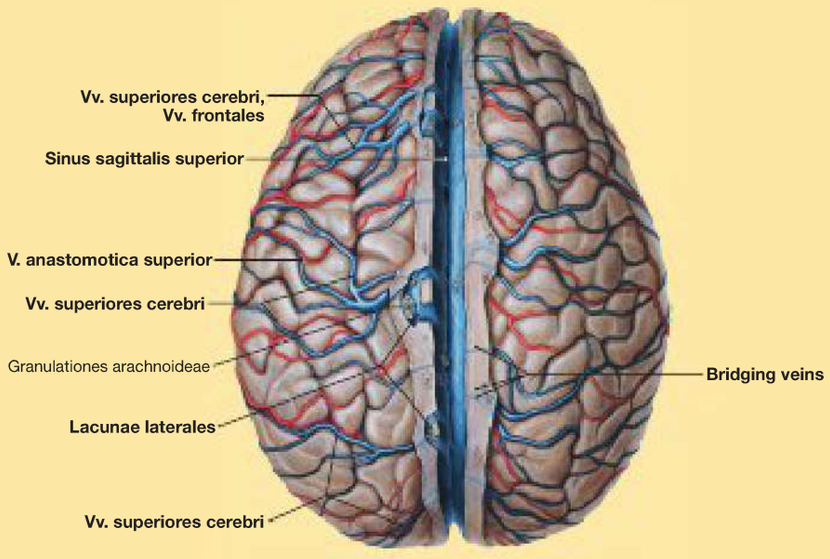

Overview

The human nervous system consists of 30–40 billion nerve cells, which come into contact via synapses. Functionally, the somatic (voluntary) nervous system is separated from the autonomic (involuntary) nervous system. The **somatic nervous system** controls all processes, which are subject to conscience and will via the sympathetic, parasympathetic and enteric nervous systems in particular, the **autonomic nervous system** regulates the activities and functions of the internal organs during physical exertion, digestion, rest phases, but also in emergency situations. Topographically, a distinction is made between the central nervous system (CNS) and the peripheral nervous system. The CNS consists of the **spinal cord** (Medulla spinalis) and the **brain** (encephalon). The latter has five subdivisions in a cranial to caudal order: **telencephalon or cerebrum**, **diencephalon** ('intermediate' brain), **mesencephalon** (midbrain), **pons** and **Medulla oblongata** or myelencephalon. The **cerebellum**, which together with the Medulla oblongata and pons forms the **rhombencephalon**, is located on the dorsal side of the pons. The **brain stem** includes the Medulla oblongata, pons and mesencephalon. With the exception of two cranial nerves, all nerves outside the spinal cord and the brain belong to the peripheral nervous system (PNS).

Main Topics

After studying this chapter, you should be able to:

- explain the principles of the development of the nervous system;
- name the internal structure of the telencephalon including the nuclei in sections/cuts of the brain;
- name the meninges, relate them to the brain and spinal cord, as well as to the surrounding bony structures, and explain their innervation and blood supply;
- explain the cerebrospinal fluid system in detail;
- identify the large blood vessels supplying the brain, describe their segments and their pathways, and find and name their main bifurcations and terminal branches;
- outline the Circulus arteriosus located at the cranial base and name its vessels;
- place the functional cortical areas in relation to the supply areas of the cerebral arteries;
- name the blood vessels of the Capsula interna;
- explain the venous system of the Sinus durae matris, bridging veins and cerebral veins as well as venous anastomoses;
- explain the fibre connections of the brain and their function;
- describe the parts of the neocortex;
- describe the regions belonging to the hippocampus and explain the relationship between this formation and the ventricular system;
- explain the individual parts of the Cortex cinguli as well as the areas of the paleocortex, and the olfactory cortical areas and functions;
- explain the connections between the paleocortex and other regions of the brain, in particular with the limbic system;
- explain the arrangement, location and function of the central subcortical nuclei;
- explain the components, organisational structure and functions of the diencephalon, thalamus, hypothalamus and epithalamus;
- explain the parts of the brain stem, and describe its functional systems, including important brain stem reflexes;
- explain the surface, structure, blood supply, function and nuclei as well as the internuncial neurons and fibre systems of the cerebellum;
- correctly name the twelve pairs of cranial nerves, their nuclei, exit points, pathways, and fibre qualities, the special position of the cranial nerves I and II, the respective target organs as well as their topographical position;
- describe the segmentation of the spinal cord;
- define the pyramidal and extrapyramidal systems;
- know different neuronal function systems;
- describe the olfactory and gustatory systems;
- present basic knowledge about different forms of pain;
- describe the circuits of the visceral motor system, the structure of sympathetic and parasympathetic systems, including paravertebral and prevertebral ganglia, and show these on the dissection;
- explain the enteric nervous system;
- describe the visceral sensory system and its importance for autonomic reflex arches and control loops;
- name parts of the autonomic nervous system, show the location of the centres, such as the respiratory centre and the cardiovascular centre, and describe the hypothalamus;
- explain the limbic system including its connections.

Clinical Relevance

In order not to lose reference to future everyday clinical life with so many anatomical details, the following describes a typical case that shows why the content of this chapter is so important.

Meningioma

Case Study

A successful 48-year-old project manager from the financial sector has only been been to the doctor a few times in the past. But because she has been suffering from headaches for several weeks, sometimes without any relief, she has gone to her GP. After a thorough medical history and physical examination, he prescribed strong painkillers and advised her to reduce her workload and to practice sport if possible. The painkillers improved the symptoms, but the headaches were still there. Two months after the visit, she took a holiday and followed the doctor's advice to practice sport (jogging). Nevertheless, the headaches persisted. During a cycling tour with her husband she suddenly fell from the bicycle and lay twitching on the ground. Her husband sought medical help immediately, as she was unresponsive. When the ambulance arrived, the woman was already responsive, but still very groggy. The ambulance took her to the nearest hospital, her husband accompanying her.

Result of Examination

When being examined in the ambulance the woman reported no other complaints than headaches and two painful grazes on the chin and right forearm. But she is still slightly dizzy. During the initial examination in the hospital the doctor on duty observes that the woman seems to have lost urine spontaneously. He asks her husband about details of the fall and previous illnesses. The husband tells of his wife's 'twitching' after the fall, but that she is otherwise always healthy. In the past few months she had frequently complained about severe headaches, supposedly because she works a lot and had already been to the doctor, who had prescribed painkillers. After conducting a thorough physical examination to exclude fractures and internal injuries, the doctor arranges for a computed tomography of head.

Diagnostic Procedure

The CT shows a round, smoothly marginated mass with a strong and homogeneous uptake of contrast agent, making it look like a snowball (→ Fig. a). It is located at the cranial vault, in a parasagittal-right plane in the middle third of the Sinus sagittalis superior. Other pathologies or a trauma caused by the fall with the bike can now be ruled out. The CT finding and the seizure lead the radiologist to the suspected diagnosis of a meningioma.

Diagnosis

Meningioma.

Treatment

Due to the location, size and symptoms as well as the good general condition of the patient, she is advised to undergo immediate surgical removal of the tumour. She agrees and is transferred to the neurosurgery department, receives patient information and is operated on the next day. After opening the cranium, the neurosurgeons can resect a confined, round, grey-white tumour of solid consistency, including the infiltrated Dura mater, and thereby minimise the risk of relapse. For confirmation of the diagnosis, the resected tissue is brought to the pathology department.

The histopathologic examination with HE staining reveals grouped, uniform tumour cells, emerging from cells of the arachnoid mater and enclosed by collagen septa.

Many meningiomas contain small focal calcifications.

The result of the pathological-anatomical evaluation is a meningioma of the meningotheliomatous type, WHO grade I. This classification is especially important for the prognosis. 90 % of all meningioma are of this type, i. e., they grow very slowly without infiltrating the brain and do not form metastases. The tumour is therefore classified as benign.

Dissection Lab

The dissection lab is the best place to get an idea of the location of the meninges. The three meninges (Dura mater, Arachnoidea mater and Pia mater) are very closely interlinked. The observation of the meninges shows how and where a meningioma can develop from the cells of the arachnoid. As the arachnoid also surrounds the spinal cord, meningiomas are found throughout the cranial-spinal axis.

9 % of all patients have multiple meningioma.

The following intracranial predilection sites of meningioma should be looked up during dissection: Falx cerebri, Sinus sagittalis superior, Alae ossis sphenoidalis, Tuberculum sellae, the olfactory groove and N. opticus.

The blood supply is guaranteed via meningeal branches of the A. carotis externa.

Back in the Clinic

The indication for surgery depends on factors such as location, size, symptoms and the health status of the patient. Because they are mostly benign tumours with slow growth rates, very small meningiomas without clinical symptoms must often only be controlled. In the case of faster growth rates or incipient clinical symptoms as in the above-mentioned patient, a surgical procedure is indicated.

Further treatment options are the fractionated or stereotactic radiation (radiotherapy) or the gamma knife.

The prognosis is particularly positive for grade I meningioma. Following complete removal of the tumour, the probability of recurrence is approximately 9 % over the next five years. Long-term monitoring with MRI is often sufficient. The project manager has already left the hospital and is now in a rehabilitation clinic. In eight weeks' time, she can expect to return to her professional life.

Fig. a Paramedian CT, right side, sagittal plane. The arrow points to a round, smoothly marginated mass, with homogeneous storage of contrast agent. [T534]

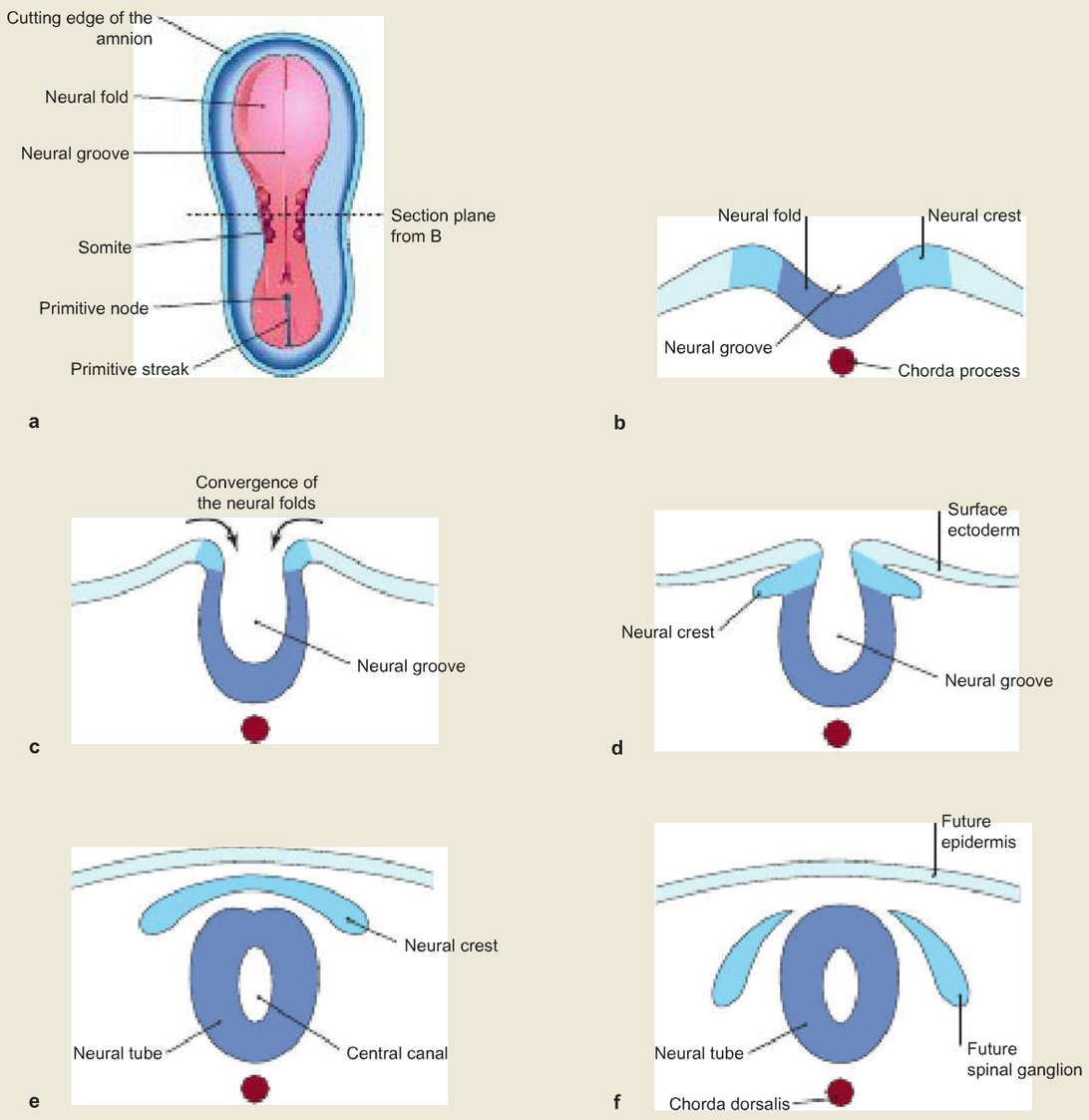

Fig. 12.1a to f Formation of the neural groove, neural folds, neural tube and neural crests. [E347-09]
a Superior view after removal of the amniotic cavity.
b to f Cross-sections of embryos in consecutive developmental stages.
The CNS and PNS originate from the ectoderm. The CNS develops via a neural plate, which forms a neural groove as well as two neural folds and neural crests on its right and left side. While the neural groove deepens, the right and left neural folds move closer together and soon fuse to become the neural tube (starting from the fourth to sixth somites) that encloses the central canal. Initially, the neural tube is still open to the amniotic cavity via the Neuroporus anterior (rostralis) and the Neuroporus posterior (caudalis). On the 24th day, the Neuroporus anterior closes, and on the 26th day the Neuroporus posterior. The right and left neural crests also approach each other and fuse above the neural tube to the neural crest, before separating again shortly afterwards. The PNS begins to differentiate from the neural crest cells.

Clinical Remarks

If the rostral part of the neural tube does not close (open Neuroporus rostralis), the regular development of the three brain vesicles will not take place. Only a diffuse cluster of neural tissue is formed due to misleading induction processes. The absence of brain development also results in an improper development of the skull. Only a facial skull is formed, but the brain and neurocranium are absent **(anencephaly).** This developmental malformation is always fatal.

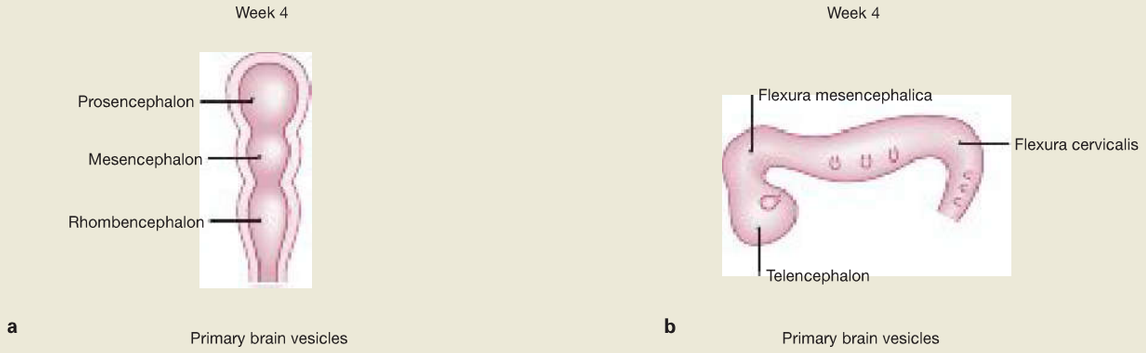

Fig. 12.2a and b Development of the brain: primary brain vesicles; a schematic frontal section; **b** schematic lateral view. [E838]
a In **week 4,** the neural tube is closed at both ends. The rostral end begins to enlarge and forms the three successive **primary brain vesicles:** forebrain (prosencephalon), midbrain (mesencephalon), and hindbrain (rhombencephalon).

b Also during **week 4,** the **midbrain flexure** (Flexura mesencephalica) emerges between the forebrain (prosencephalon) and the midbrain (mesencephalon), and the **cervical flexure** (Flexura cervicalis) forms between the hindbrain (rhombencephalon) and the spinal cord.

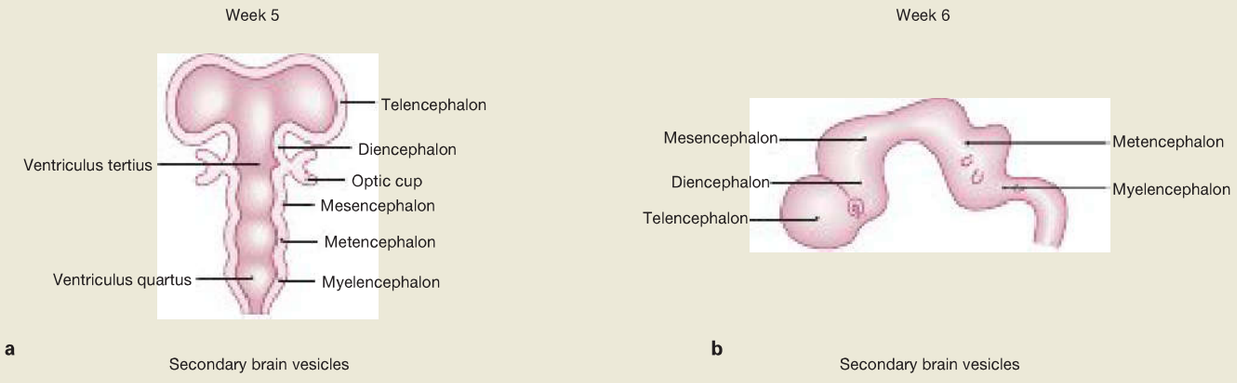

Fig. 12.3a and b Development of the brain: secondary brain vesicles; a schematic frontal section; **b** schematic lateral view. [E838]
a In **week 5,** a part of the prosencephalon enlarges on the right and left sides of the median line to become the **telencephalon**, from which the cerebral hemispheres emerge. Also, the diencephalon originates from the prosencephalon. The third ventricle is formed between the diencephalon and mesencephalon. As an anterior part of the hindbrain, the **metencephalon** evolves beneath the mesencephalon; later its main components will be the pons and cerebellum. Caudally the posterior part of the hindbrain follows, the **myelencephalon**; it includes the fourth ventricle and the Medulla oblongata and transitions into the spinal cord.

The three primary brain vesicles give rise to six **secondary brain vesicles** (paired vesicles of the telencephalon, and the diencephalon, mesencephalon, metencephalon and myelencephalon).
b In week **6,** the telencephalon, diencephalon, mesencephalon, metencephalon, and myelencephalon are clearly definable. The optic cups (or eye cups) become visible between the telencephalon and diencephalon. The development of the cerebellum starts with a lateral extension of the rhombencephalon. At the dorsal aspect of the metencephalon, the developing cerebellum can already be seen.

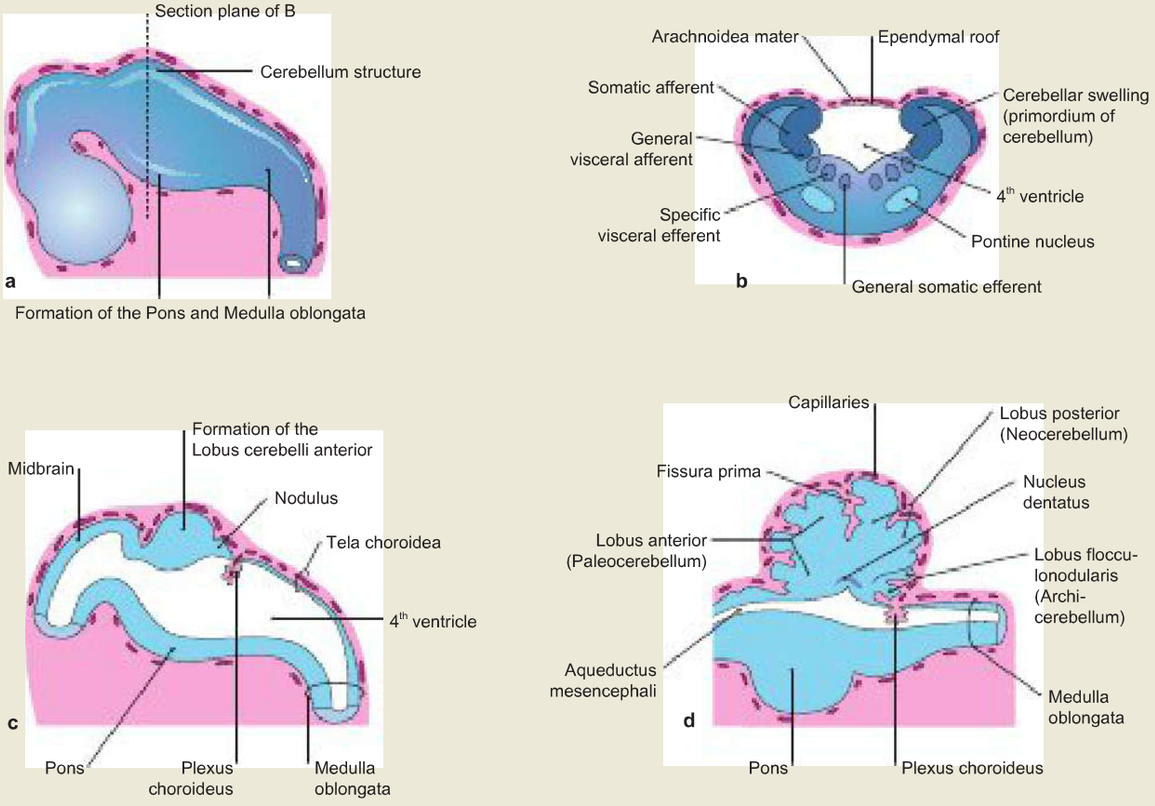

Fig. 12.4a to d Development of the brain; a schematic lateral view; **b** schematic cross-section; **c, d** schematic sagittal sections. [E347-09]
a In **week 5**, the primordial pons, Medulla oblongata and cerebellum are formed (from the myelencephalon vesicle). **b** The central canal in the rhombencephalon enlarges and the dorsal alar plates flap open, so that the canal is only covered by a thin roofplate (formation of the rhomboid fossa). In this process the alar and basal plates lie next to each other, separated by the Sulcus limitans. The future nuclei of the cranial nerves are located symmetrically next to each other. As a consequence, the primordial structures of the cerebellum expand further dorsally and, by uniting in the median line, they will later enclose the rhomboid fossa (not shown). The sagittal sections through the rhombencephalon in **week 6 (c)** and in **week 17 (d)** clearly show the ongoing development of the pons and cerebellum.

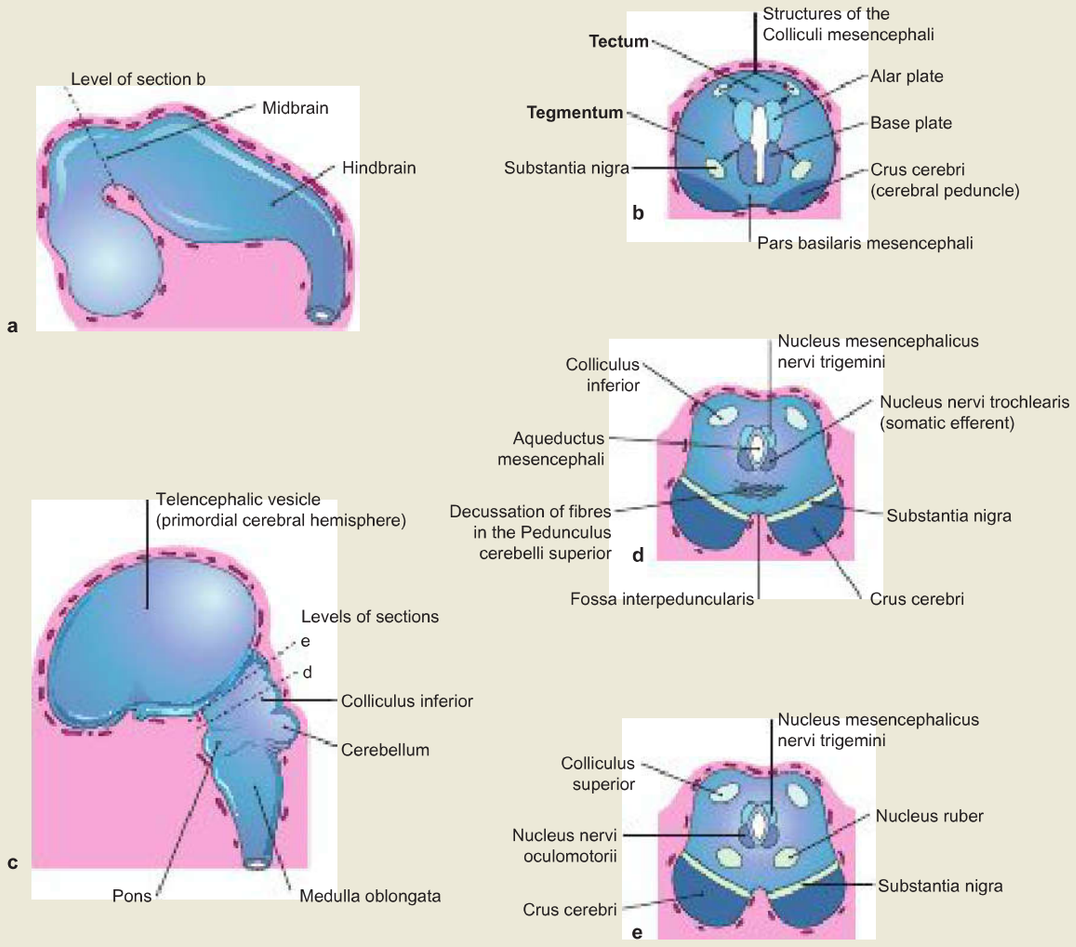

Fig. 12.5a to e Development of the mesencephalon. [E347-09]
a Schematic lateral view. In **week 5**, the primordial mesencephalon emerges in the area of the Flexura mesencephalica. In relation to other parts of the brain, the area of the mesencephalon vesicle undergoes only minimal changes.
b Schematic cross-section. The centrally located lumen narrows, due to the strong growth of the lateral walls. This leads to the formation of the Aqueductus mesencephali (SYLVII), a relatively thin structure as compared to other internal parts of the cerebrospinal fluid system, which connects the third ventricle to the fourth ventricle. The surrounding tissue forms a roofplate **(tectum)** and a larger ventral covering **(tegmentum),** which with its most anterior part as the **Pars basilaris mesencephali** includes the Crura cerebri. From the alar plates that have arisen from the dorsal-lateral parts of the neural tube, neuroblasts migrate into the Tectum mesencephali and form the paired Colliculi superiores and inferiores here. It is debatable whether the Nucleus ruber and the Substantia nigra originate from differentiated neuroblasts of the alar plates or roofplates (presented here is the formation of the Substantia nigra from the basal plates).
c Schematic sagittal section and schematic cross-sections **(d** and **e)** of the mesencephalon in **week 11**. Neuroblasts of the former basal plates migrate into the Tegmentum mesencephali and form the group of motor nuclei (e. g. Nucleus nervi oculomotorii) here. In week 11, the structure of the mesencephalon has already developed to its definitive form.

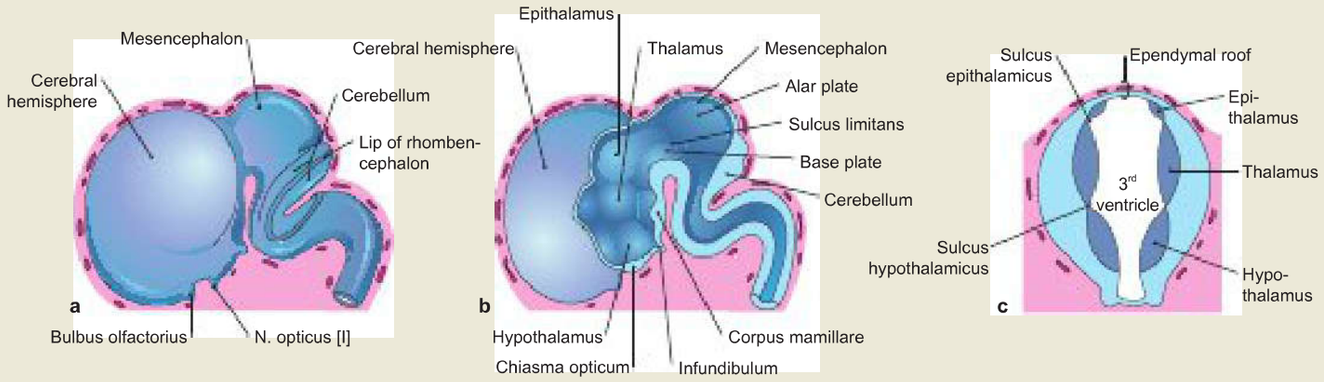

Fig. 12.6a to c Development of the brain in week 7. [E347-09]
a Schematic view of the surface of the brain. Due to the increasing size/expansion of the telencephalon, the diencephalon is visible only at a few points from the outside.
b Schematic median section with prosencephalon and mesencephalon. The former vesicle of the diencephalon differentiates further into the parts of the diencephalon, including the hypothalamus with pituitary gland, thalamus, epithalamus and subthalamus. The primordial eyes also emerge from the diencephalon.
c Schematic cross-section through the diencephalon. The centrally located lumen enlarges to become the third ventricle. The epithalamus, thalamus and hypothalamus differentiate in the lateral wall of the neural tube. Grooves or depressions (Sulcus epithalamicus, Sulcus hypothalamicus) are formed between the areas of the nuclei.

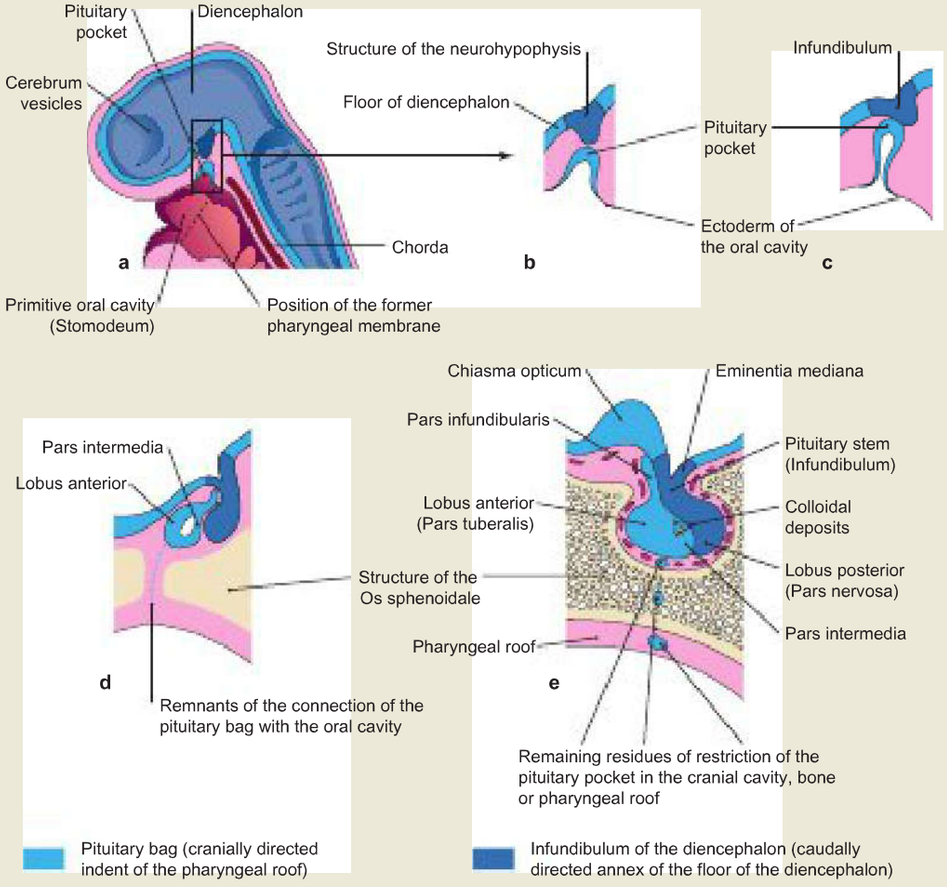

Fig. 12.7a to e Development of the pituitary gland. [E347-09]
a Schematic overview in the median section with the roof of the stomodeum (RATHKE's pouch) and base of the diencephalon.
b to **d** Folding of the epithelium of the roof of the stomodeum (RATHKE's pouch, forms the adult adenohypophysis) and fusion with the infundibulum (forms the adult neurohypophysis). The pituitary gland emerges from two types of tissue: (1) Around the 36th day of development, the ectodermal epithelium of the roof of the stomodeum forms a fold or duplication (so-called RATHKE's pouch), which later becomes the adenohypophysis (anterior lobe of the pituitary gland). It grows towards (2) the infundibulum, which is the primordial neurohypophysis (posterior lobe of the pituitary gland), and within a short time both structures merge to form the pituitary gland.
e Position of the pituitary gland (hypophysis) in the Sella turcica.

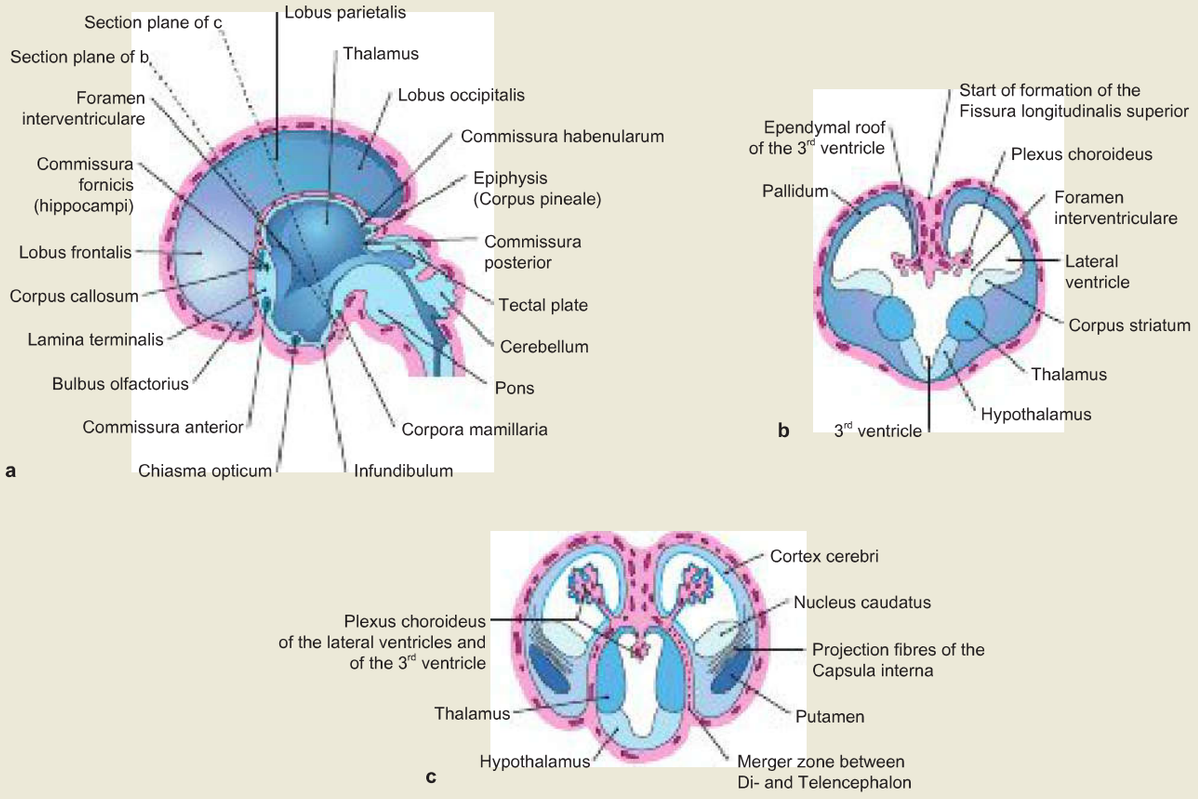

Fig. 12.8a to c Development of the forebrain (mesencephalon). [E347-09]
a Schematic lateral view of the medial surface of the mesencephalon in week 10. The telencephalon vesicle develops into a median part and two lateral appendages. The latter differentiate to become the later adult cerebral hemispheres.
b Cross-section of the mesencephalon at the level of the Foramina interventricularia that shows the Corpus striatum and the Plexus choroideus of the lateral ventricles. Due to the considerably slower growth of the cover plate, the rapidly growing cerebral hemispheres arch over the cover plate. Thereby, the Fissura longitudinalis superior is created between them; the former cover plate is located in the area of the later Corpus callosum. The basal and alar plates become the grey matter and form the Pallium. Thickening of the basal plate gives rise to the basal ganglia at the bottom of the lateral ventricles. The inner (subarachnoid) spaces of the cerebrospinal fluid emerge from the lumen of the neural tube. The ventricles and their communicating ducts are created by the faster and slower growth rates in different parts. In the telencephalon, the crescent- or C-shaped growth direction of the two cerebral hemispheres results in the typical structure of the first and second ventricles. The Plexus choroideus of the two lateral ventricles and of the third ventricle emerge from the cover plate.
c Comparable section in week 11. The ingrowing Capsula interna divides the Corpus striatum into Putamen and Nucleus caudatus. All afferent and efferent nerve fibres (tracts) to or from the telencephalon have to pass through the diencephalon. A majority of these fibres (tracts) is therefore visible as Capsula interna. The nuclei located here in the fields of the subthalamus are pushed aside by the fibres (tracts). These lateral parts of the diencephalon are called Globus pallidus (Pallidum). They lie in the telencephalon, but originate from the diencephalic basal plate.

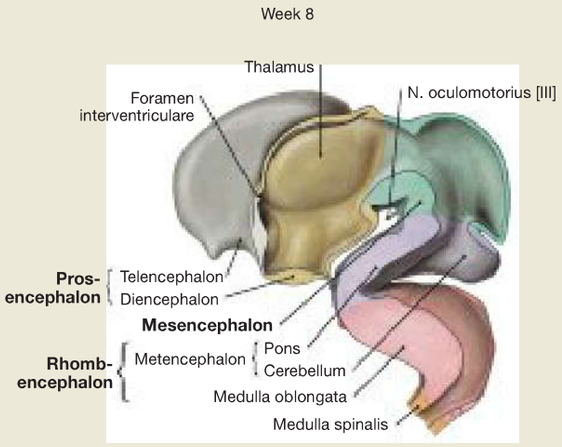

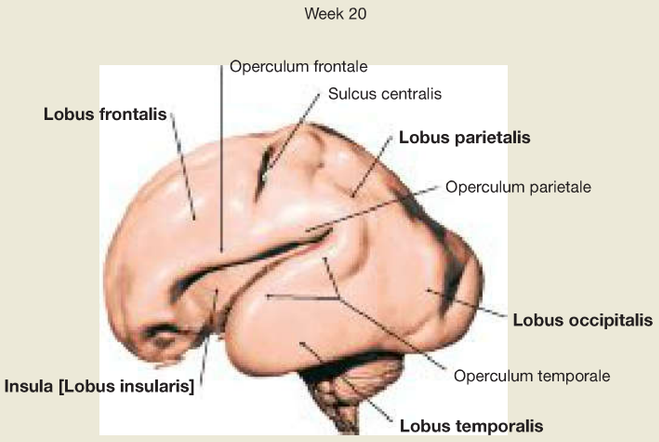

Fig. 12.9 Development of the brain; median section.
In **week 8**, the individual brain structures are already clearly definable. The telencephalon and diencephalon have emerged from the prosencephalon. You can already recognise the thalamus in the diencephalon. In the mesencephalon the exiting N. oculomotorius [III] becomes visible. The rhombencephalon has differentiated into the metencephalon and the Medulla oblongata (myelencephalon). The pons and cerebellum emerge from the metencephalon. The Medulla oblongata is followed by the Medulla spinalis.

Fig. 12.10 Development of the brain; view from the left side.
The growth of the telencephalon is already far advanced in **week 20 of the foetal development** (crown-rump length 20 cm). In the area of the cerebral hemispheres, the Lobi frontalis, parietalis, occipitalis and temporalis have already been formed. However, the Lobus insularis is not yet completely covered or overgrown by the Lobi frontalis, parietalis and temporalis. Only parts of the pons, cerebellum and Medulla oblongata are still visible structures of the brain stem.

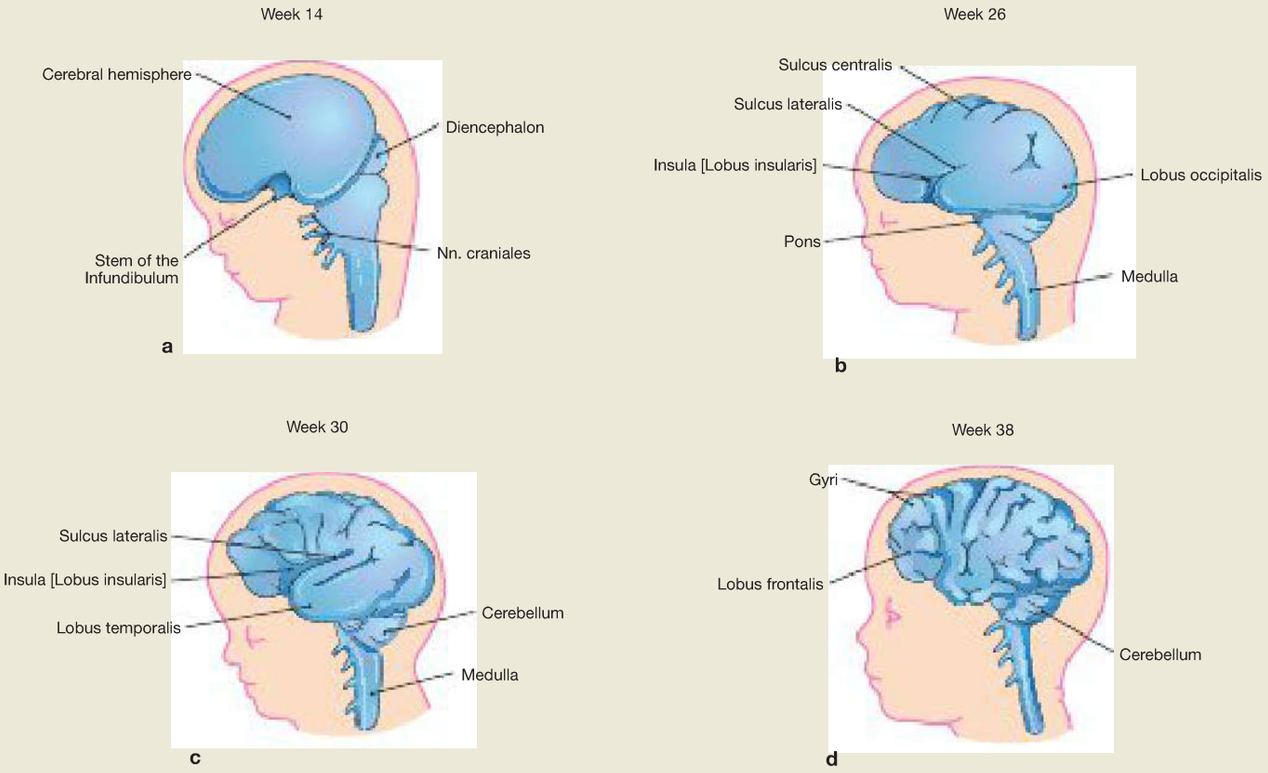

Fig. 12.11a to d Development of the left cerebral hemisphere, diencephalon and brain stem; schematic drawing; lateral view. [E347-09]
In week 14, the telencephalon still has a completely smooth surface. Subsequently, convolutions (Gyri) and grooves (Sulci) of the brain develop incrementally (**gyrification,** surface enlargement), combined with the formation of the Insula and its overlapping by the Lobi frontalis, parietalis and temporalis.

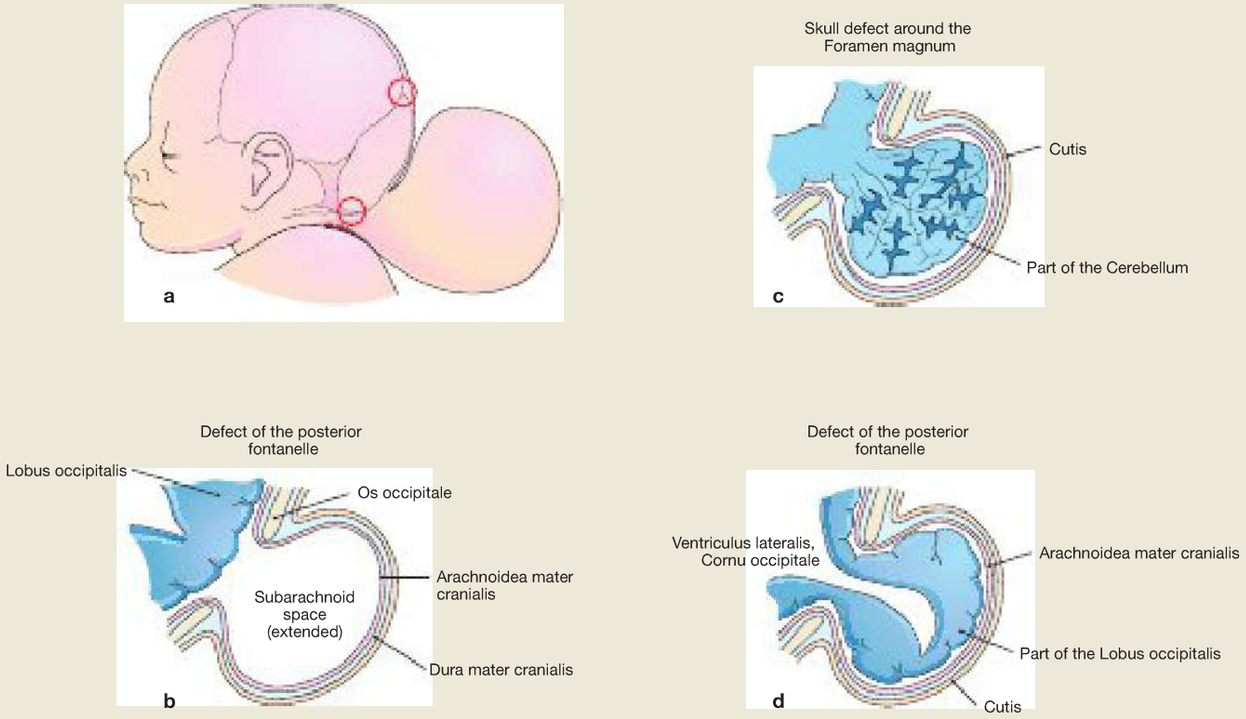

Fig. 12.12a to d Cranium bifidum formation and various types of herniation of the brain and/or meninges, schematic drawing. [E347-09]

a Head of a newborn with an extensive herniation in the occipital region. The upper red circle marks the defect in the area of the small fontanelle, the lower red circle indicates the defect in the area of the Foramen magnum.

b Meningocele: the hernial sac is formed by skin and meninges and is filled with cerebrospinal fluid.

c Meningoencephalocele: the hernial sac contains parts of the cerebellum and is covered by meninges and skin.

d Encephalocystocele: the content of the hernial sac is formed by parts of the Lobus occipitalis and a part of the posterior horn of the lateral ventricle.

Fig. 12.13 Meningoencephalocele. [E347-09]

Clinical Remarks

The term **encephalocele** (hernia cerebri, cerebral hernia, outer brain prolapse, cranium bifidum) summarises defective developmental malformations with a median gap of the skull (at the root of the nose, forehead, cranial base, or occiput) through which parts of the meninges **(meningocele),** or parts of the brain **(meningoencephalocele)** can protrude without involvement of the cerebrospinal fluid spaces **(encephalocele)** or including parts of the brain ventricles **(encephalocystocele, meningohydroencephalocele)**.

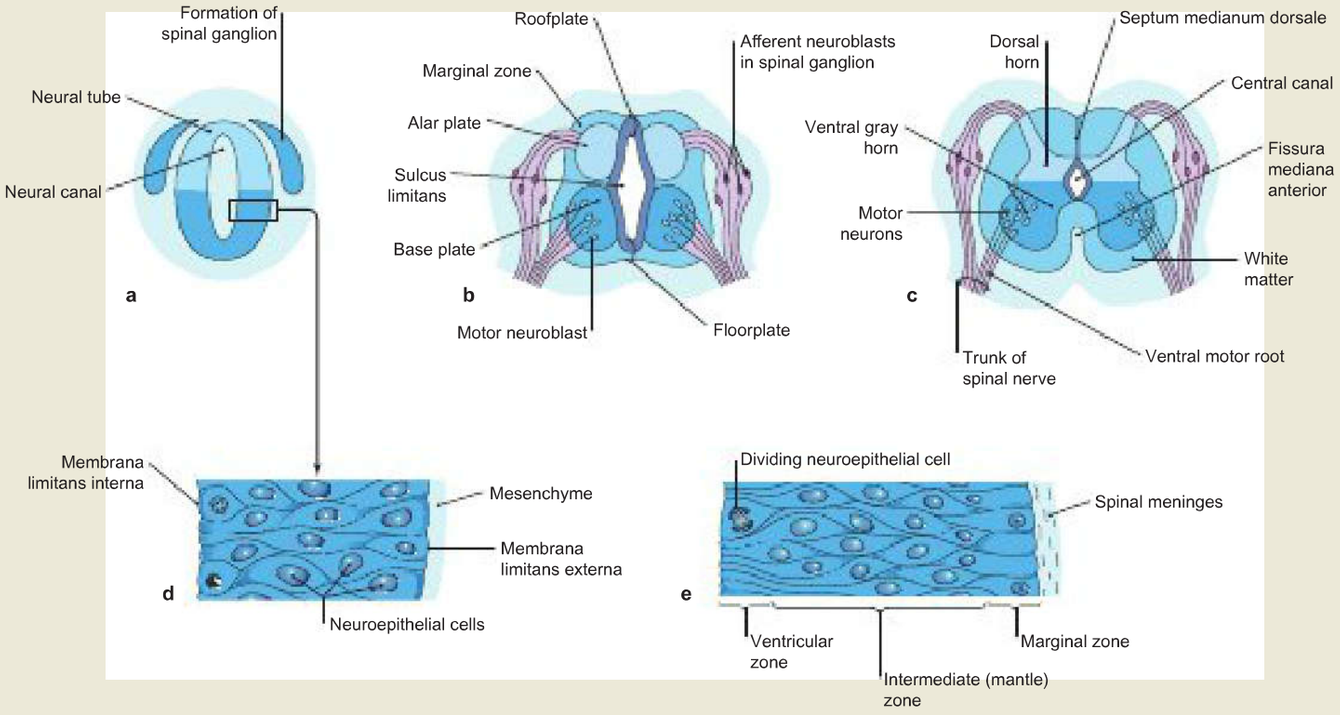

Fig. 12.14a to e Development of the spinal cord from the caudal portion of the neural tube, schematic drawing. [E347-09]
a Day 23. In the caudal portion of the neural tube, the lateral parts of the alar and basal plates begin to thicken.
b Week 6. The efferent fibres emerge from the basal plate (later: the motor anterior horn) and form the Radix anterior. Afferent fibres assemble in the direction of the alar plate (later: the sensory posterior horn) and form the Radix posterior.
c Week 9. Due to the growth processes of other structures and the simultaneous growth retardation of the basal and roofplates, the latter are shifted into a deeper position. This results in the formation of the Fissura mediana anterior and of the Sulcus medianus posterior. The lumen of the neural tube hardly enlarges and remains as the central canal (Canalis centralis).
d The wall of the neural tube thickens, and **e** differentiates into three zones: (1) ventricular zone, (2) intermediate zone, (3) marginal zone.

Fig. 12.15 Spina bifida occulta. [E347-09]
The hairy skin area in the lumbosacral region is a visible sign of the underlying spina bifida occulta.

Fig. 12.16 Spina bifida cystica. [E347-09]
Child with Spina bifida cystica (meningomyelocele) in the lumbar region.

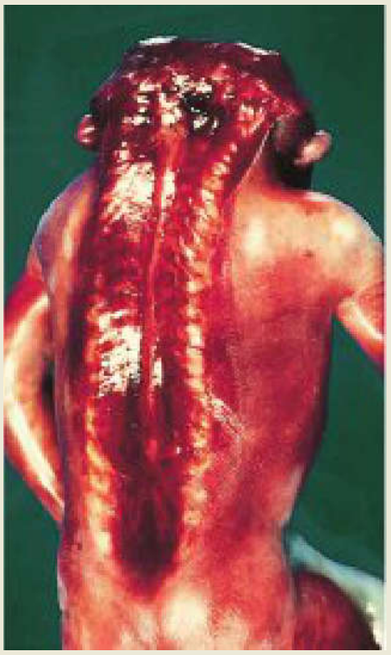

Fig. 12.17 Rhachischisis with anencephaly. [E347-09]
Newborn with pronounced rhachischisis.

Clinical Remarks

Spina bifida is a congenital cleft formation of the spine and spinal cord, which is caused by teratogenic substances (e. g. alcohol, medication) or by the absence of induction of the Chorda dorsalis.
In the case of a **spina bifida occulta** (→ Fig. 12.15) only the vertebral arches are affected. The vertebral cleft usually results from the failed fusion of one or two vertebrae. The skin overlying the area of the defect is often hairy and strongly pigmented. But there are usually no clinical symptoms.
In the case of a **spina bifida cystica** (→ Fig. 12.16), the closure or fusion of several adjacent vertebrae remains incomplete; the membranes of the spinal cord protrude cyst-like into the defect (meningocele). If the cyst additionally contains parts of the spinal cord and nerves, it is defined as meningomyelocele (usually associated with deficits).
The **spina bifida aperta** (rhachischisis, myeloschisis, myelocele; → Fig. 12.17) is the most severe form of a clefting or closure disorder of the vertebral arches, and occurs in combination with a non-union defect of the neural folds. In this case, the undifferentiated neural plate lies open on the back and is not covered by skin. Newborns with such defects usually die shortly after birth. If the defect extends to the rostral end of the neural groove, the primordial brain will not have been developed either (anencephaly).

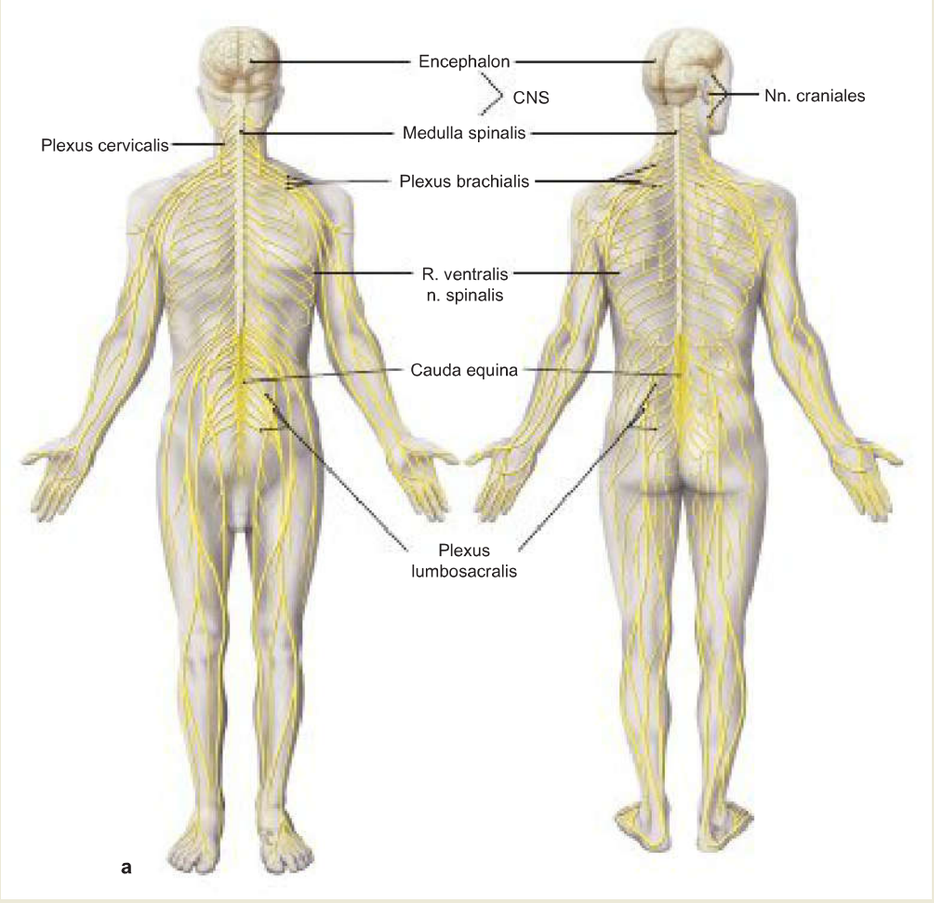

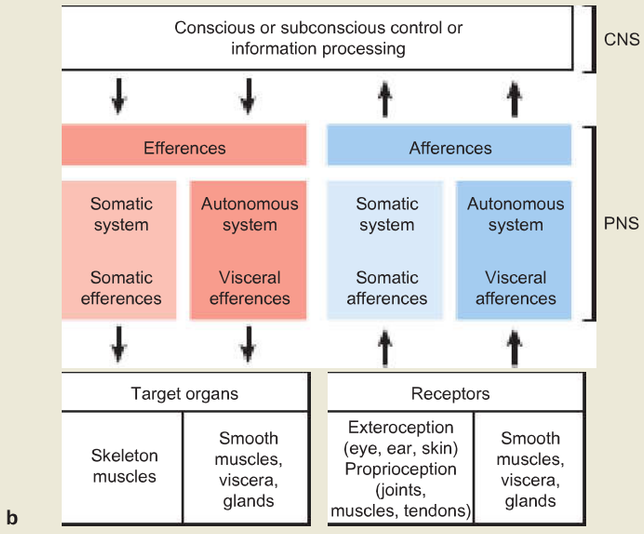

Fig. 12.18a and b Organisation of the nervous system, Systema nervosum; a morphological structure, ventral and dorsal views; **b** functional structure. a [L127], b [L126]

The nervous system is divided into the central (CNS) and the peripheral nervous system (PNS). The **central nervous system (CNS)** consists of the brain and spinal cord, and accomplishes complex functions such as storage of experience (memory), development of ideas (thinking), as well as emotions, and serves for the rapid adjustment of the whole organism to extrinsic and intrinsic changes in the external environment and the internal milieu of the body. The CNS is well protected in the skull and the Canalis vertebralis. The **PNS** is mainly composed of spinal nerves (with connections to the spinal cord) and cranial nerves (with connections to the brain). It enables the communication between the organs and the CNS, controls the activity of muscles and viscera, and provides the communication links between the environment and the interior of the body. The structures of the PNS leave the protective vertebral canal through the Foramina intervertebralia of the spine.

Functionally, the nervous system is divided into an **autonomic** (vegetative, visceral, to control visceral activity, mostly involuntary) and a **somatic** (animalic, innervation of skeletal muscles, voluntary perception of sensory input, communication with the environment) nervous system. Both systems are closely interlinked and interact with each other. The functional structure is not identical to the morphological structure in all parts.

In addition to the nervous system, the endocrine system also participates in the regulation of the entire organism.

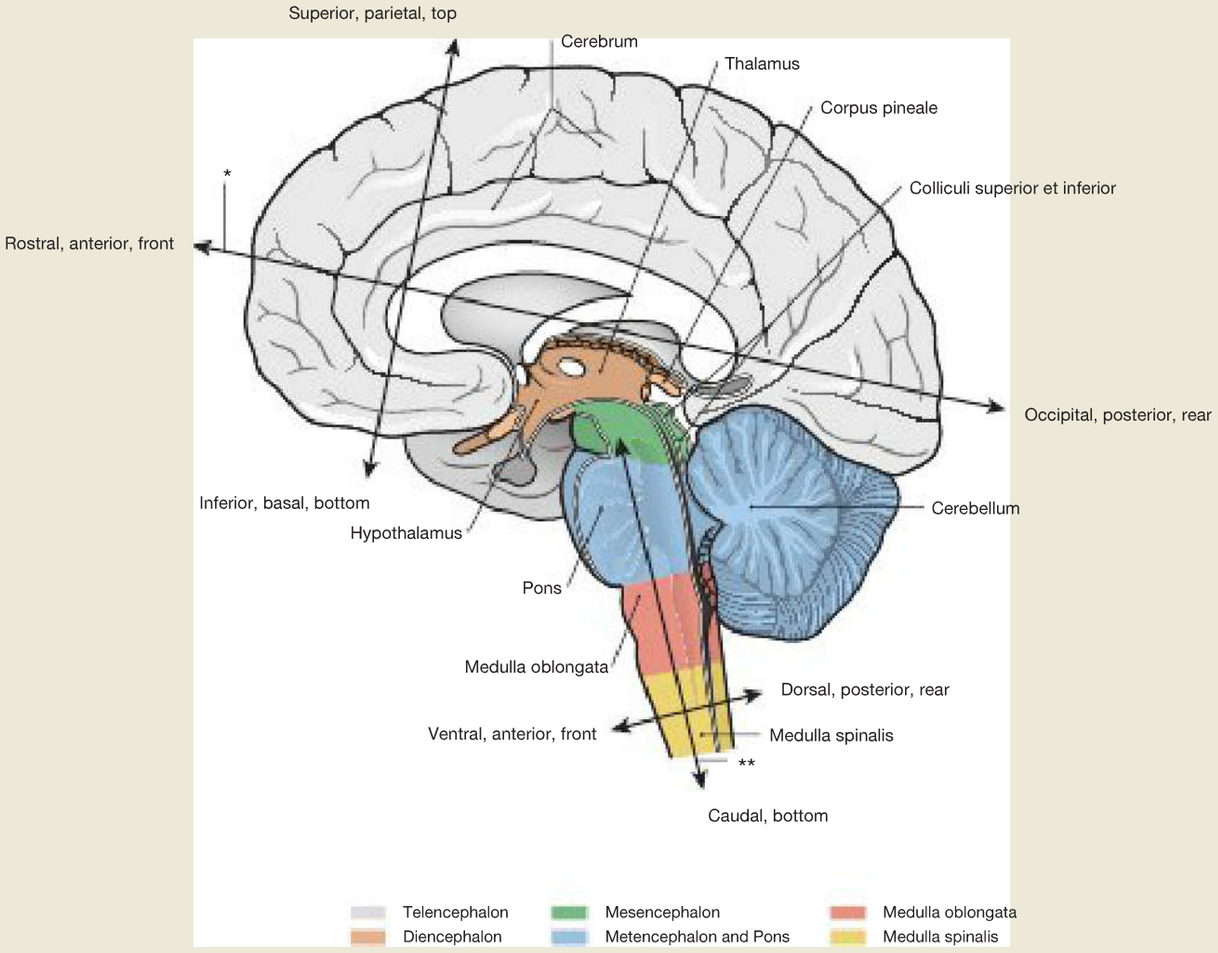

Fig. 12.19 Terms of direction and position at the level of the CNS and spinal cord; median section. [L126]
In the course of the development of the brain, a bending of the neural tube occurs. Thereby the longitudinal axis of the forebrain (prosencephalon = diencephalon and telencephalon) tilts forward. Consequently, a unique nomenclature is generated for the brain, as is shown in the figure. For example, although former dorsal parts, e.g. the metencephalon, shifted in a parietal direction, they are still referred to as dorsal. The topographical axis between the telencephalon and diencephalon is referred to as **FOREL's axis** (*), and the axis through the centre of the brain stem (Truncus encephali) is called **MEYNERT's axis** (**).

Clinical Remarks

The clinical neurological examination includes a physical examination and a medical history to obtain information in particular on previous neurological disease, cranial-cerebral trauma, congenital or familial neurological disorders, risk factors and autonomic functions. This is complemented by a symptom-focused history and specific diagnostic techniques to evaluate the cranial nerves and their corresponding functional systems. In addition, the physician should try a preliminary assessment of the patient's consciousness, orientation in space and time, memory function, concentration and basic mood. Disorders of the consciousness are clinically divided into **somnolence** (abnormal sleepiness, however easy to wake up; delayed reaction to verbal communication, immediate response to pain stimuli), **sopor** (abnormally deep sleepiness, difficult to wake up; delayed, but targeted defensive reaction to pain stimuli), and **coma** (cannot be woken up by external stimuli). A quantitative assessment of impaired conscious states, e. g. within the context of a follow-up, can be attained with the **Glasgow coma scale**. The severity of a consciousness disorder is quantitatively evaluated by testing the patient's spontaneous activity, and his or her response to verbal requests and pain stimuli, and scoring these reactions with points. Disorientation, confusion and perception disorders (e. g. in the context of an alcoholic or drug delirium) can lead to substantial disturbance of consciousness.

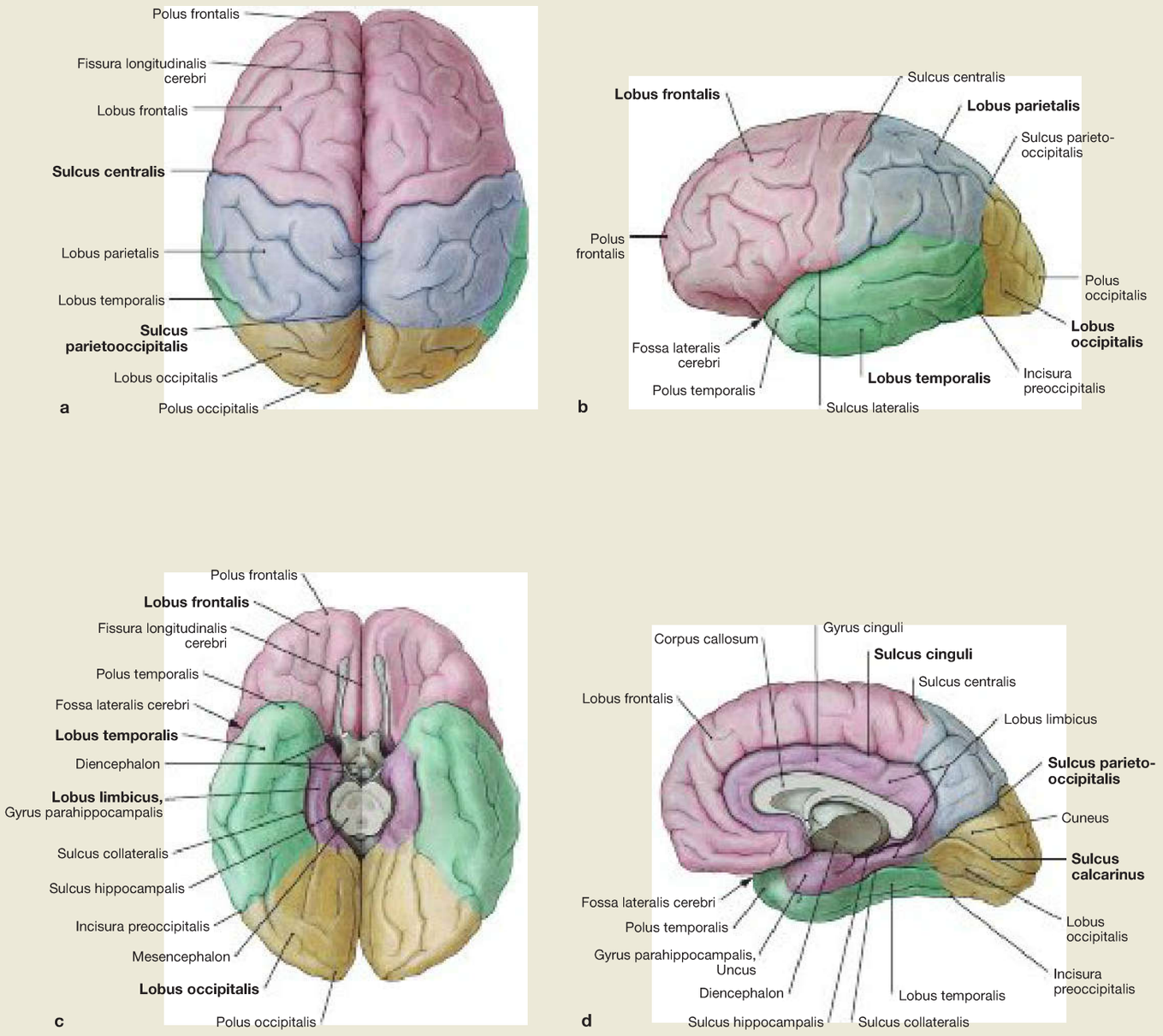

Fig. 12.20a to d Lobes of the cerebrum, Lobi cerebri; superior view (→ Fig. 12.20a), lateral view from the left side (→ Fig. 12.20b), inferior view (→ Fig. 12.20c), medial view from the left side to the sagittal section of the right hemisphere (→ Fig. 12.20d).
Towards the end of the eighth embryonic month, the primary grooves of the telencephalon are developed. These are consistently present in all humans. Each cerebral hemisphere is divided into **four lobes**:

- frontal lobe (Lobus frontalis)
- parietal lobe (Lobus parietalis)
- temporal lobe (Lobus temporalis)
- occipital lobe (Lobus occipitalis)

In addition to the four cerebral lobes, the **Lobus limbicus** (composed mainly of the Gyrus cinguli, together with the Gyrus parahippocampalis and the Uncus) and the **Lobus insularis** (Insula, not visible, as it is covered by the Opercula of the frontal, parietal, and temporal lobes) can be distinguished (→ Fig. 12.21) . Secondary and tertiary grooves of the telencephalon develop in an individually variable pattern. So the boundaries between the individual lobes are in large parts arbitrary (e. g. Incisura preoccipitalis).

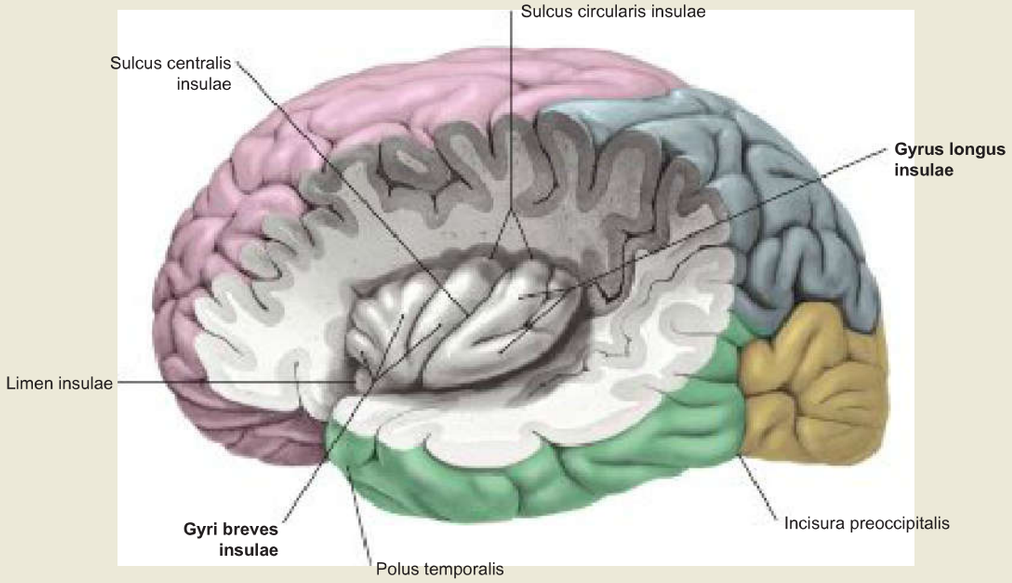

Fig. 12.21 Convolutions, Gyri, and grooves, Sulci, of the cerebral hemispheres; view from the left side; after removal of the parts of the frontal, parietal and temporal lobes covering the insula.

The cortical regions of the Lobi frontalis, parietalis and temporalis that surround the Sulcus lateralis are called the Opercula and have been removed to expose the Insula (→ Fig. 12.20). The processing of olfactory, gustatory and visceral information takes place in the Insula. It is usually considered an independent lobe.

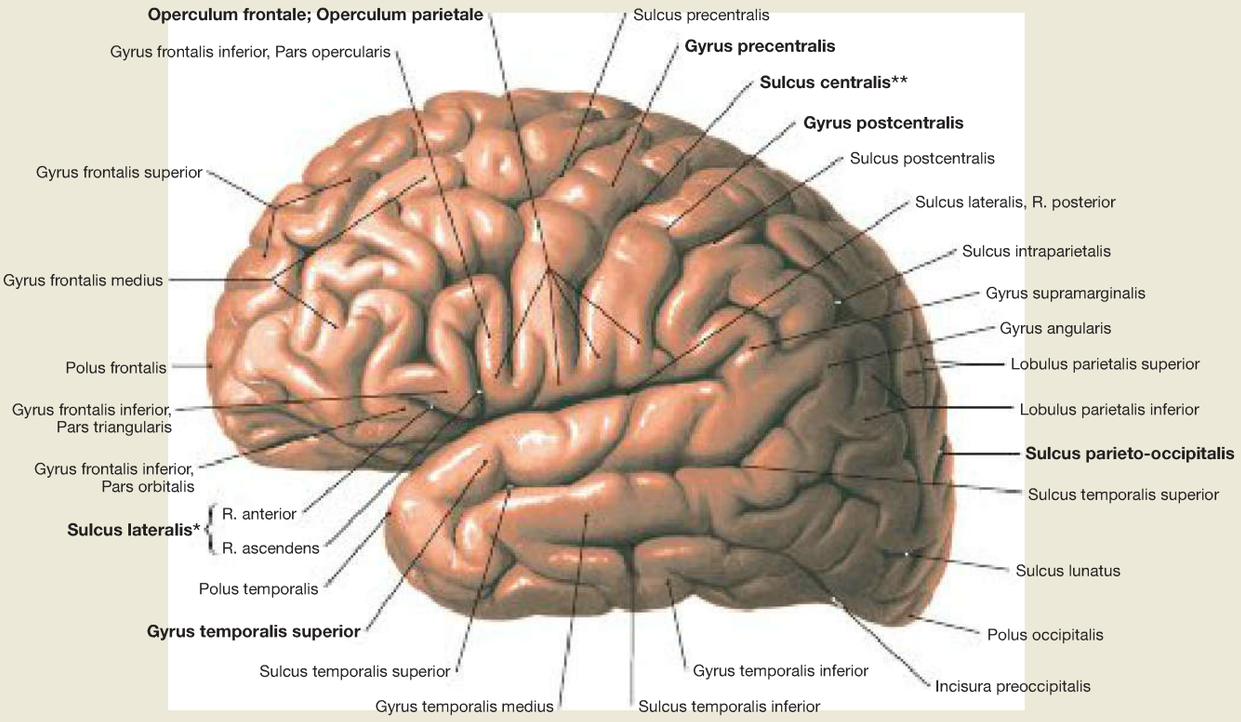

Fig. 12.22 Convolutions, Gyri, and grooves, Sulci, of the cerebral hemispheres; view from the left side.
Although the labelled Gyri and Sulci can be identified in each human brain (e. g. Sulcus centralis, Sulcus lateralis or Gyrus temporalis superior), not even both hemispheres of the same brain display an identical pattern of Gyri and Sulci. The individual uniqueness of the brain surface is comparable to a fingerprint.

* SYLVIAN fissure or sulcus
** Fissure or sulcus of ROLANDO

Telencephalon, Cortex

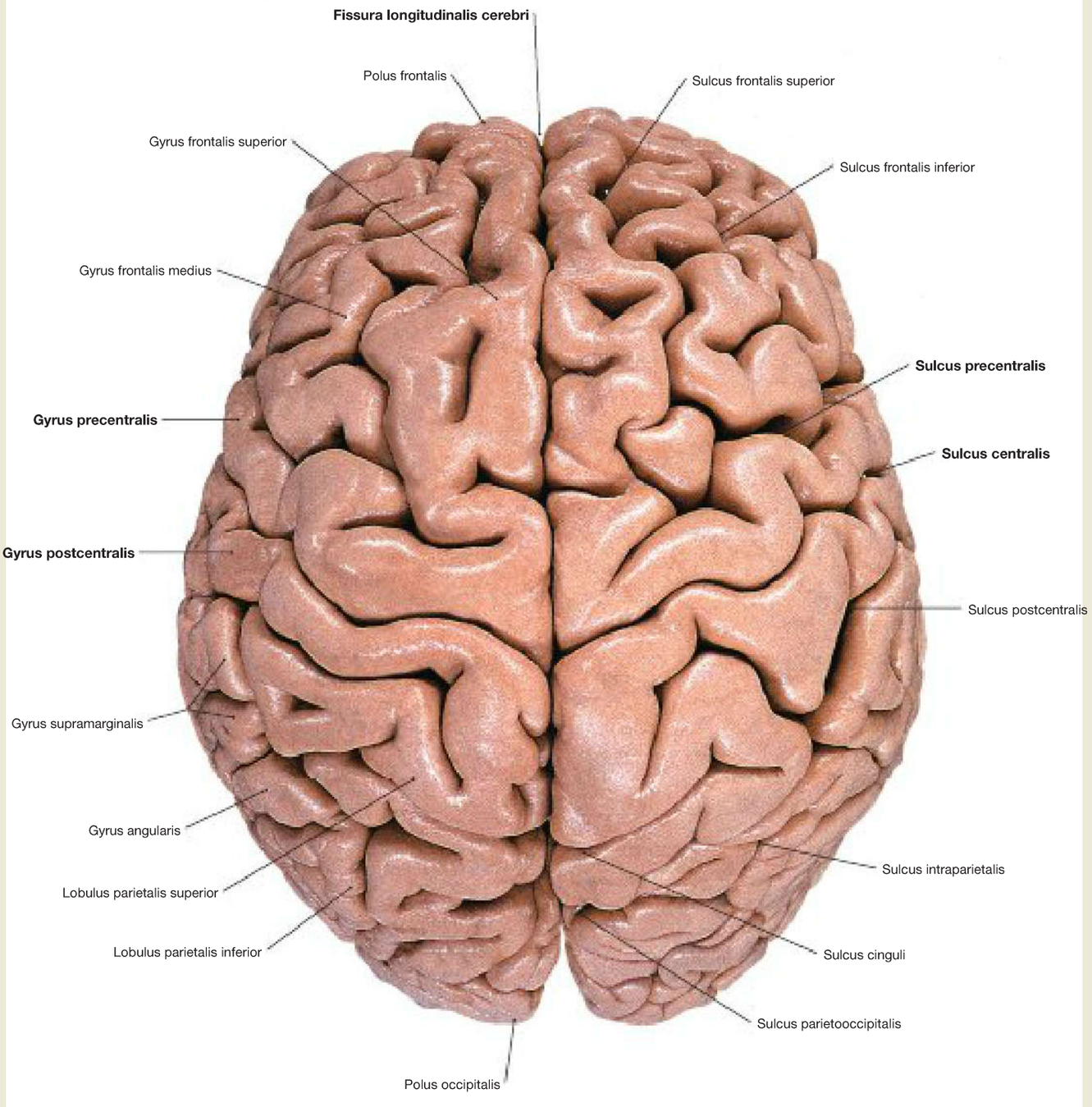

Fig. 12.23 Cerebrum; superior view; after removal of the leptomeninx. The cerebrum constitutes the major part of the brain. It is composed of **two hemispheres** which are separated by the **Fissura longitudinalis cerebri**. During early development, the surface of the brain is still smooth. Its strong growth results in the quite variable formation of grooves **(Sulci)** and convolutions **(Gyri).** Due to this folding, the surface area of the brain is significantly increased. Of the cerebral surface, an area of two-thirds is thus not visible from the outside.

Clinical Remarks

Atrophy of the brain develops with advanced age. This is associated with a widening of the Sulci and a narrowing of the Gyri. However, the decreasing memory function with advanced age is not directly linked to this atrophy of the brain, it is caused above all by a shorter duration of the deep sleep phases. With ageing, the proportion of deep sleep will diminish significantly. Up to the 26th year of life, 19% of the total sleep duration is spent in deep sleep phases. Between 36 and 50 years of life this percentage drops to 3%. Studies have shown that this correlates to significant decreases in memory function.

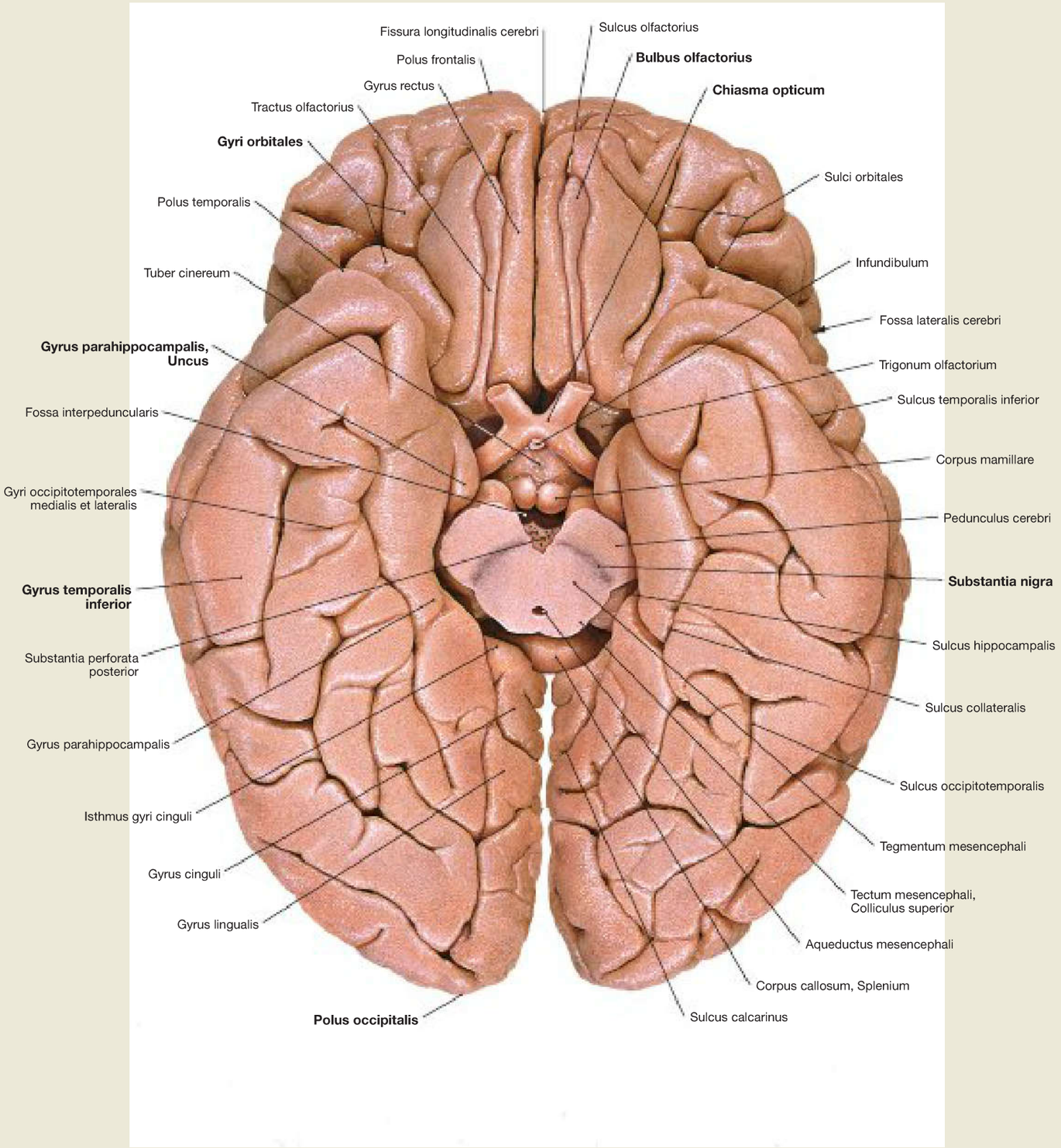

Fig. 12.24 Convolutions, Gyri, and grooves, Sulci, of the cerebral hemispheres; inferior view; after cutting through the midbrain (mesencephalon).
The telencephalon accounts for the largest part of the cranial base. Here the Gyri orbitales are located with the overlying Bulbi and Tractus olfactorii. In addition to the Chiasma opticum, the Gyrus parahippocampalis in the Lobus temporalis with its characteristic anterior bend (Uncus), the Gyri temporales and the Polus occipitalis are visible. In the mesencephalon, the darkish Substantia nigra can be clearly differentiated.

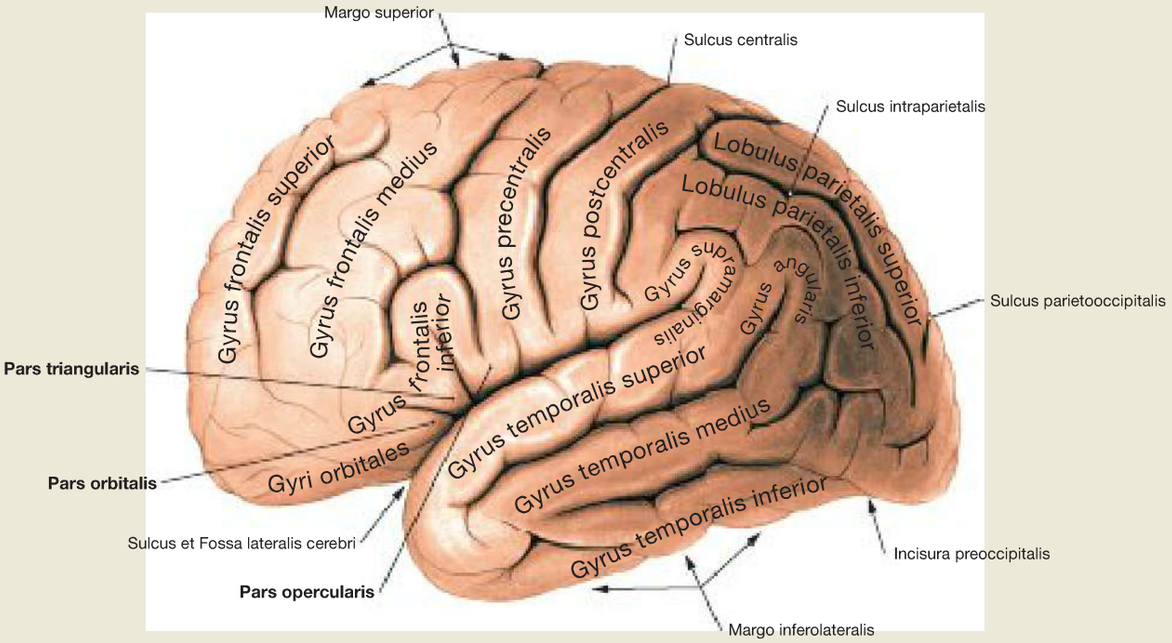

a

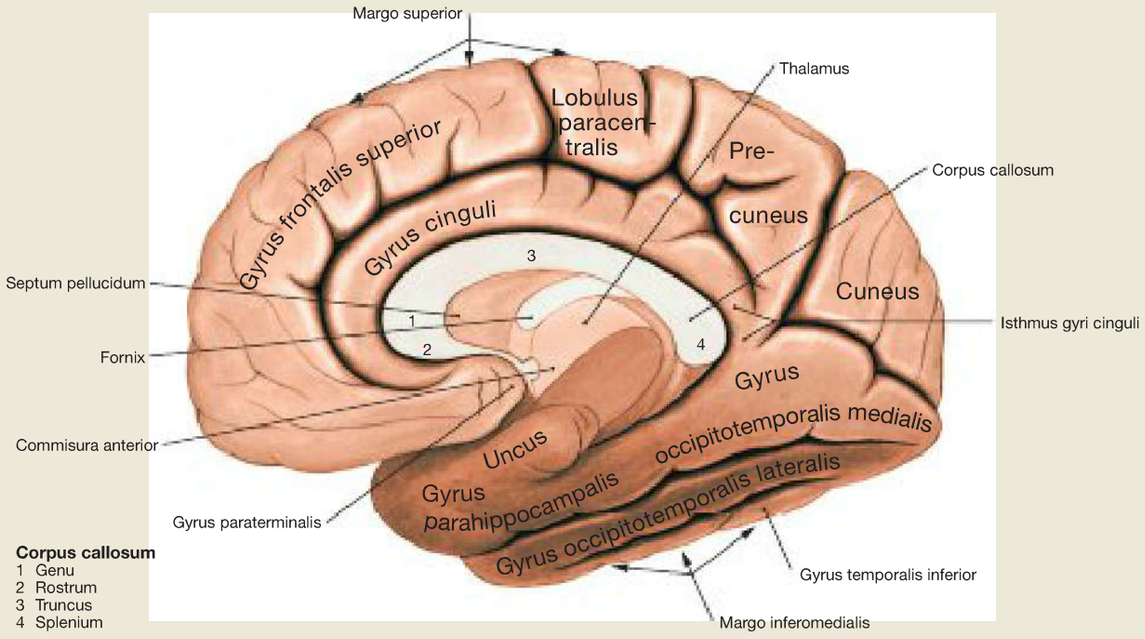

b

Fig. 12.25a and b Convolutions, Gyri, of the cerebral hemispheres. **a** View from the left side. The Gyrus frontalis inferior is divided into a Pars orbitalis, a Pars triangularis and a Pars opercularis. **b** Medial view. The Corpus callosum is composed of the Rostrum, Genu, Truncus and Splenium. In addition, the Fornix, the Commissura anterior, the Thalamus and the Septum pellucidum are visible.

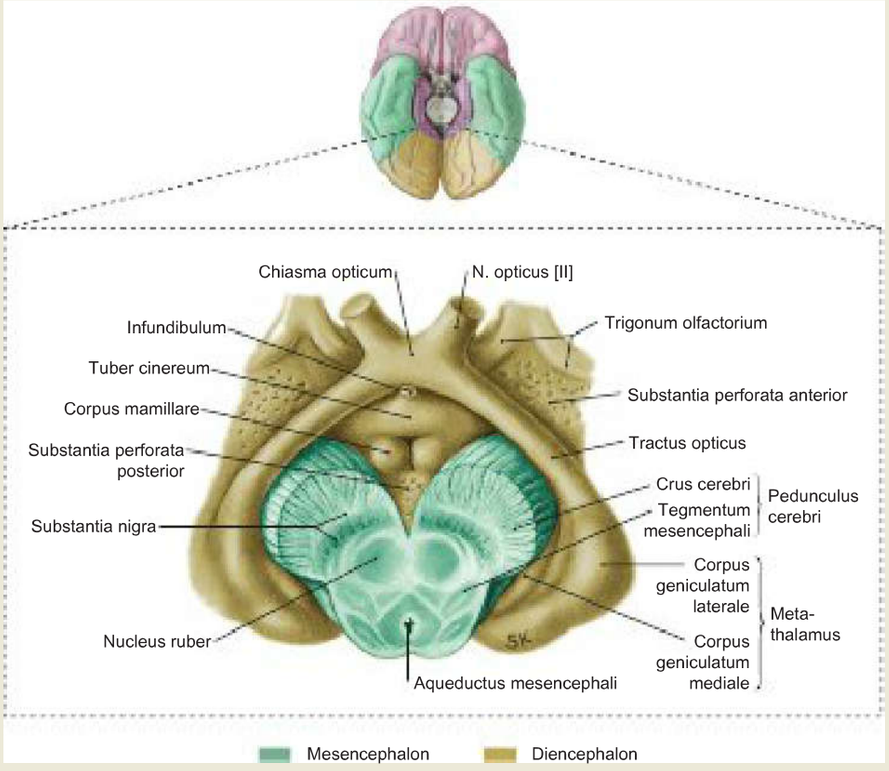

Fig. 12.26 Diencephalon; inferior view; the brain stem was cut at the level of the mesencephalon (see dotted line of incision in → Fig. 12.27). [L238]
The diencephalon does not only control the link between the brain stem and cerebrum, but also coordinates the neuronal and endocrine systems. It is barely visible from outside, as it is almost completely covered by the telencephalon due to the embryological development. Only in the inferior view are some of its parts visible, such as the N. opticus [II], Chiasma opticum, Tractus opticus, Corpus geniculatum laterale, Corpus geniculatum mediale, Substantia perforata anterior, Infundibulum of pituitary gland (infundibular stalk), Tuber cinereum and Corpora mamillaria.

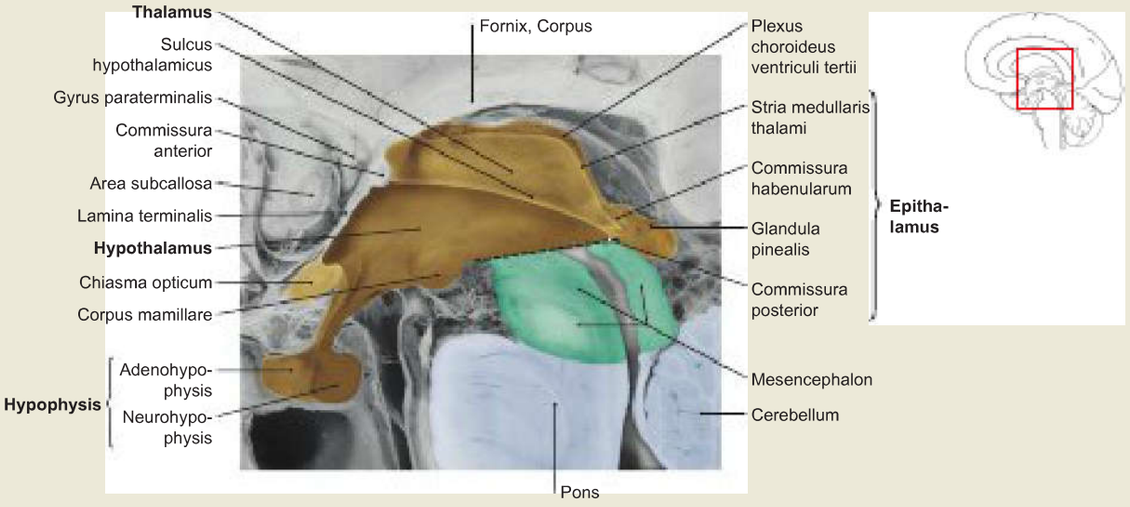

Fig. 12.27 Third ventricle, Ventriculus tertius, and structure of the diencephalon; median section.
The diencephalon can be divided into different structures:
- epithalamus
- thalamus
- hypothalamus
- subthalamus

The subthalamus is not visible in this section, since it comprises several accumulations of nerve cell bodies, which were shifted laterally during the development of the third ventricle (→ Fig. 12.8).

Mesencephalon and Brain Stem

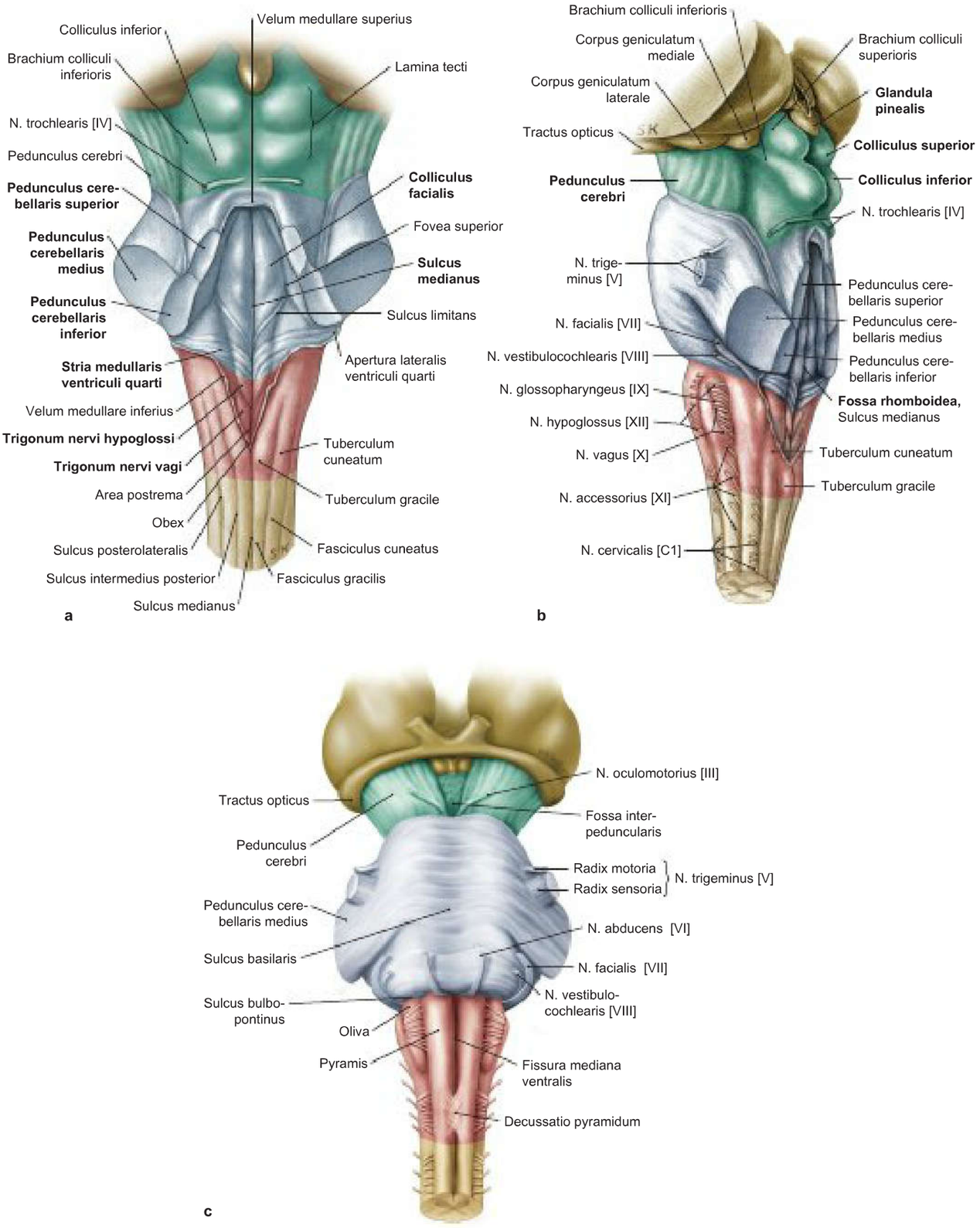

Fig. 12.28a to c Brain stem, Truncus encephali; dorsal view (→ Fig. 12.28a), lateral view (→ Fig. 12.28b) and ventral view (→ Fig. 12.28c). [L238]
The brain stem consists of the **mesencephalon** ('midbrain', green), the **pons** (blue) and the **Medulla oblongata** (red). The **mesencephalon** extends from the diencephalon to the upper margin of the pons.

The **cerebellum** was cut at the cerebellar peduncles (Pedunculi cerebellares). The exit points of the cranial nerves III to XII, with their nuclei located in the brain stem, are also visible.

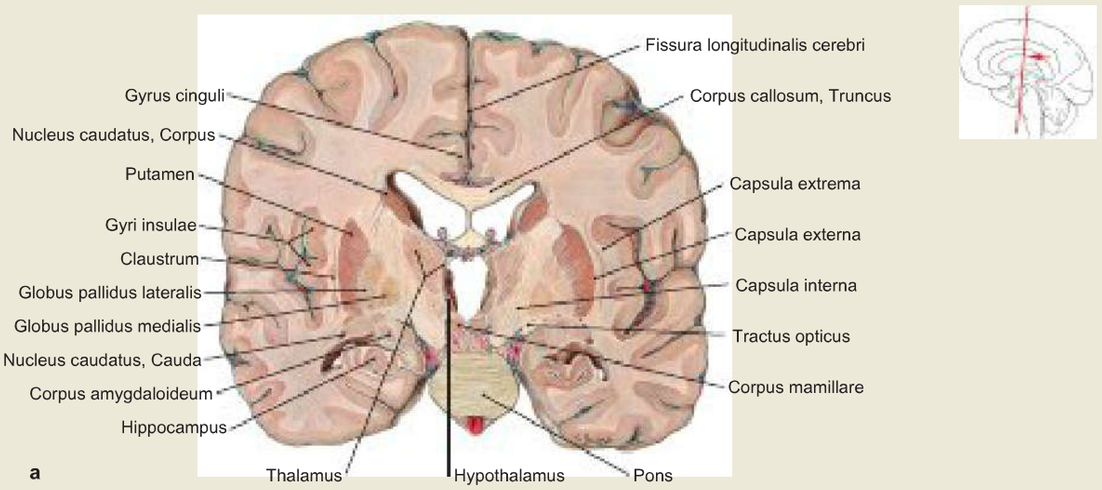

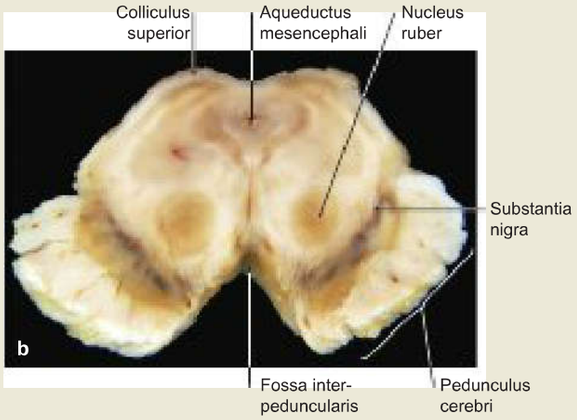

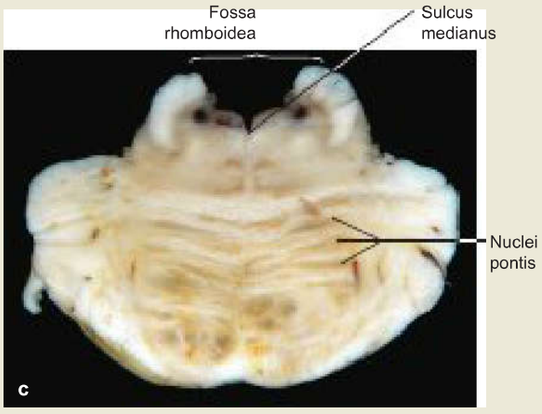

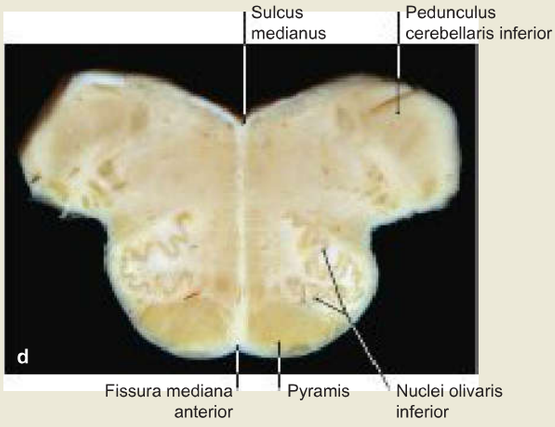

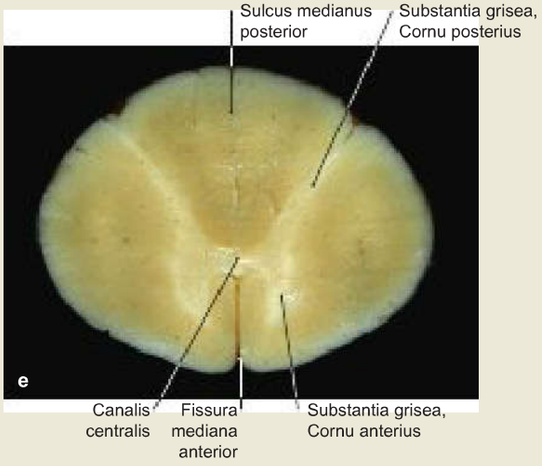

Fig. 12.29a to e Distribution of the Substantiae grisea et alba in the central nervous system; in the telencephalon (frontal section at the level of the Corpora mamillaria, → Fig. 12.29a); in the mesencephalon (→ Fig. 12.29b); in the pons (→ Fig. 12.29c); in the Medulla oblongata (→ Fig. 12.29d); and in the Medulla spinalis (→ Fig. 12.29e). b to e [R247]

Along the Gyri and Sulci of the telencephalon, there is an approx. 0.5 cm broad layer of grey matter (Substantia grisea), which is known as the Cortex cerebri. Here the neuronal perikarya and glial cells are arranged in six layers, the isocortex. Its counterpart is the allocortex, having only three to four layers. The latter is characteristic for the older parts of the brain in evolutionary terms such as the paleocortex (e. g. olfactory cortex) and the archicortex (e. g. hippocampus). Adjacent to the inner side of this 0.5 cm broad layer is the white matter (Substantia alba). Deep inside the white matter of the telencephalon are embedded areas of nuclei (Nucleus caudatus, claustrum, putamen, Globus pallidus and amygdala) or the thalamus in the diencephalon. In the brain stem, the external white matter is interspersed with accumulations of grey matter, e. g. the Substantia nigra and the Nucleus ruber in the mesencephalon, the Nuclei pontis in the pons, the Nucleus olivaris inferior in the Medulla oblongata. In the brain stem, the white matter and grey matter are more or less clearly distinct and arranged in zones: ventral fibres (white matter, e. g. Crura cerebri), in the middle nuclei of the cranial nerves, and dorsal superior centres of reflexes (tectum, cerebellum). Therefore, in the mesencephalon one speaks of the Basis, Tegmentum and Tectum mesencephali.

Association and Commissural Tracts

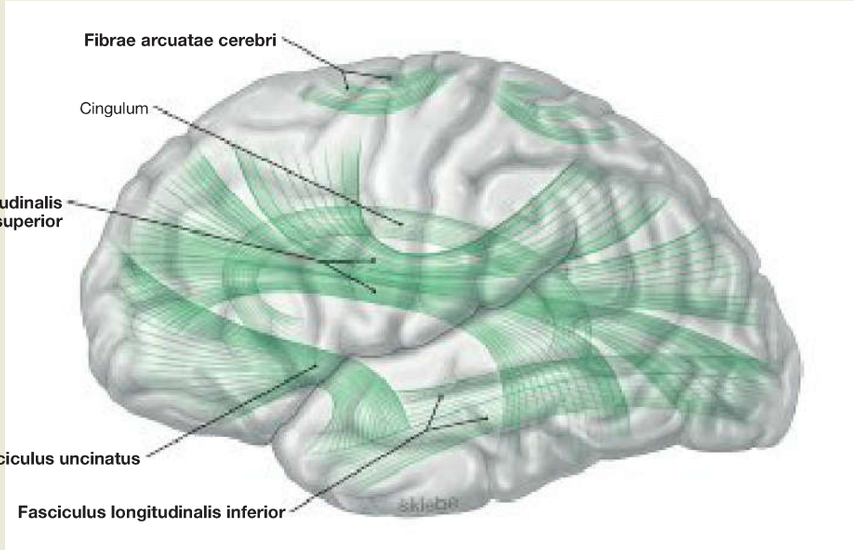

Fig. 12.30 Association tract, Neurofibrae associationes, and arcuate fibres, Fibrae arcuatae; overview; view from the left side. [L238]

Association fibres (→ Table, p. 281) account for the largest part of the fibre pathways of the white matter. They connect different areas of a cerebral hemisphere and thus enable associative and integrative functions by interlinks between functionally different areas.

Short association fibres are also referred to as arcuate fibres (Fibrae arcuatae cerebri). They are located near the cortex and connect adjacent Gyri in a U-shaped manner. **Long association fibres** are located deeper in the medulla and connect the cerebral lobes with each other.

Functionally important **bundles of association fibres** are the Fasciculi longitudinalis superior, longitudinalis inferior and uncinatus as well as the Fibrae arcuatae cerebri and the Cingulum.

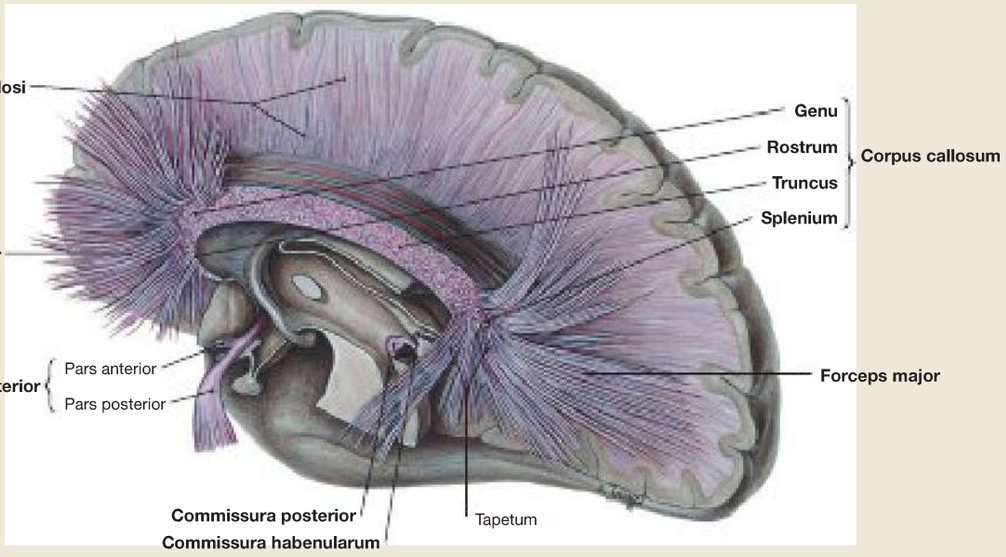

Fig. 12.31 Commissural tracts, Neurofibrae commissurales; topographical overview; view from the left side; the Corpus callosum was largely severed next to the median plane, individual fibres are presented here.

Commissural fibres (→ Table, p. 281) serve to exchange information between the two cerebral hemispheres, for example to process the visual (optic) information arriving in both hemispheres into an overall visual impression. While **homotopic** commissural fibres connect corresponding regions of the brain, **heterotopic** fibres serve to exchange information between non-corresponding areas of the brain.

Each phylogenetic part of the cerebrum has its own commissure: the paleocortex possesses the Commissura anterior, the archicortex the Commissura fornicis and the neocortex the Corpus callosum. The latter consists of the Rostrum, Genu, Truncus, and Splenium corporis callosi. Because the Corpus callosum is shorter than the hemispheres, its rostral and occipital fibres radiate in a fan-like manner into the respective lobes (**Radiatio corporis callosi,** with Forceps minor and Forceps major).

But there are also homotopic areas of the brain, which are not connected by commissural fibres. These include the primary visual cortex, the primary auditory cortex, and the somatosensory cortical fields of hand and foot.

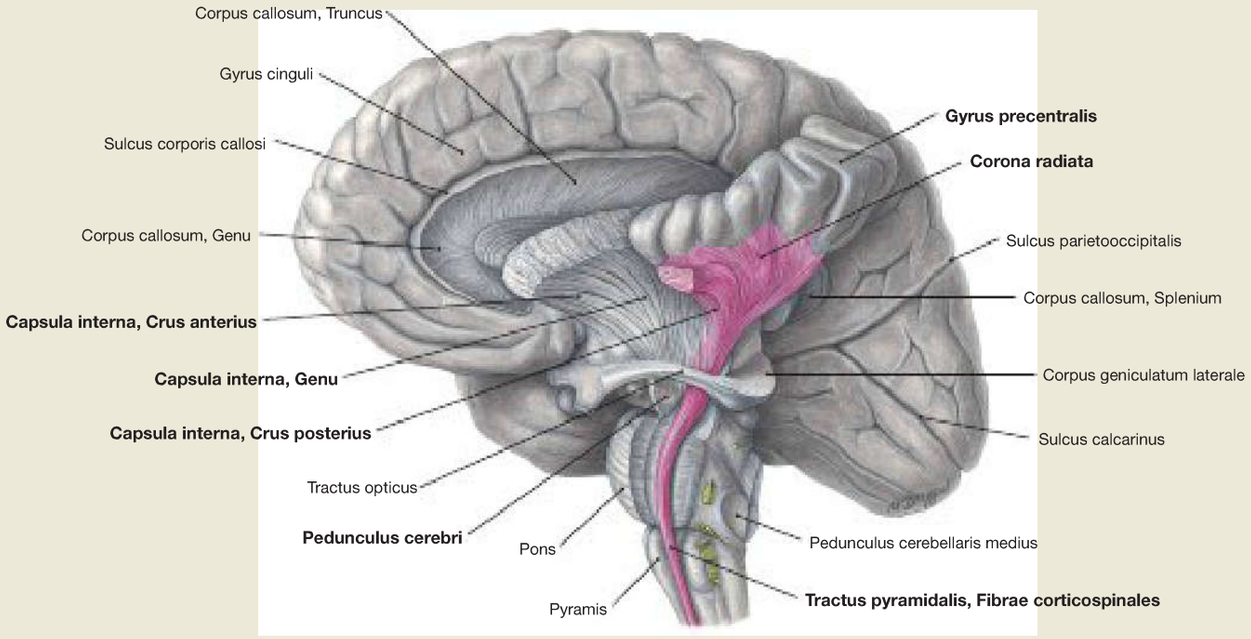

Fig. 12.32 Projection tracts, Neurofibrae projectiones; view from the left side; after exposing the internal capsule and the pyramidal tract. Projection tracts consist of projection fibres connecting the cortex with deeper structures of the CNS (e.g. thalamus, brain stem). In the area of the Striatum and Pallidum, the fibres meet narrow passages in which they have to converge. These constrictions are formed by the Capsula interna and Capsula externa between the Nucleus lentiformis and the claustrum as well as by the Capsula extrema between the insular cortex and the claustrum. The **Capsula interna** is the main route for projection fibres, in contrast to the **Capsula externa** and **Capsula extrema**, along which mainly long association fibres pass. The radially arranged projection fibres between the cerebral cortex and the Capsula interna are called **Corona radiata**.

Fibre Systems of the Substantia alba	
Fibre System	**Connection**
Association Fibres	
Fasciculus longitudinalis superior	Lobus frontalis with Lobus parietalis and Lobus occipitalis
Fasciculus longitudinalis inferior	Lobus occipitalis with Lobus temporalis
Fasciculus arcuatus	Lobus frontalis with Lobus temporalis (BROCA's area with WERNICKE's area)
Fasciculus uncinatus	Lobus frontalis with basal Lobus temporalis
Cingulum	lower parts of the Lobus frontalis with lower parts of the Lobus parietalis and Lobus parahippocampalis
Commissural Fibres	
Corpus callosum	Frontal, parietal and occipital lobes of both hemispheres
Commissura anterior	Tractus olfactorius; anterior parts of the Lobus temporalis (Amygdala; Gyrus parahippocampalis) of both hemispheres
Commissura posterior	Nuclei commissurae posteriores of both hemispheres
Commissura fornicis	Hippocampus of both hemispheres
Projection Fibres	
Tractus corticospinalis	Cortex (especially Gyrus precentralis) with spinal cord
Tractus corticopontinus	Cortex with nuclei of the pons (Nuclei pontis)
Tractus corticonuclearis	Cortex with nuclei of the cranial nerves in mesencephalon, pons and Medulla oblongata
Fornix	Hippocampus with parts of the limbic system and the diencephalon
Fasciculi thalamocorticales	Thalamus with cortex

Clinical Remarks

The developmental **failure of the primordial structure (agenesis) of the Corpus callosum** is with 3–7 cases/1,000 births a relatively common malformation in humans. It can have a wide range of causes and may be associated with absent or underdeveloped connections between the left and right hemispheres, without inevitably leading to changes in behaviour. The clinical signs and symptoms depend largely on the cause. It often presents with neuropsychiatric deficits and difficulties in problem-solving behaviour, in the understanding of language and grammar or in the verbal description of emotions (alexithymia). For the treatment of therapy-resistant epilepsy, a neurosurgical resection of the Corpus callosum can be conducted **(callosotomy)**; but this is only practised in exceptional cases today. In patients, who underwent this treatment **(split-brain patients)**, the information processed in the right half of the brain can no longer be transmitted to the left dominant hemisphere and thus to the language centre. They can recognise and also describe such information, but are not able to name it precisely.

Meninges

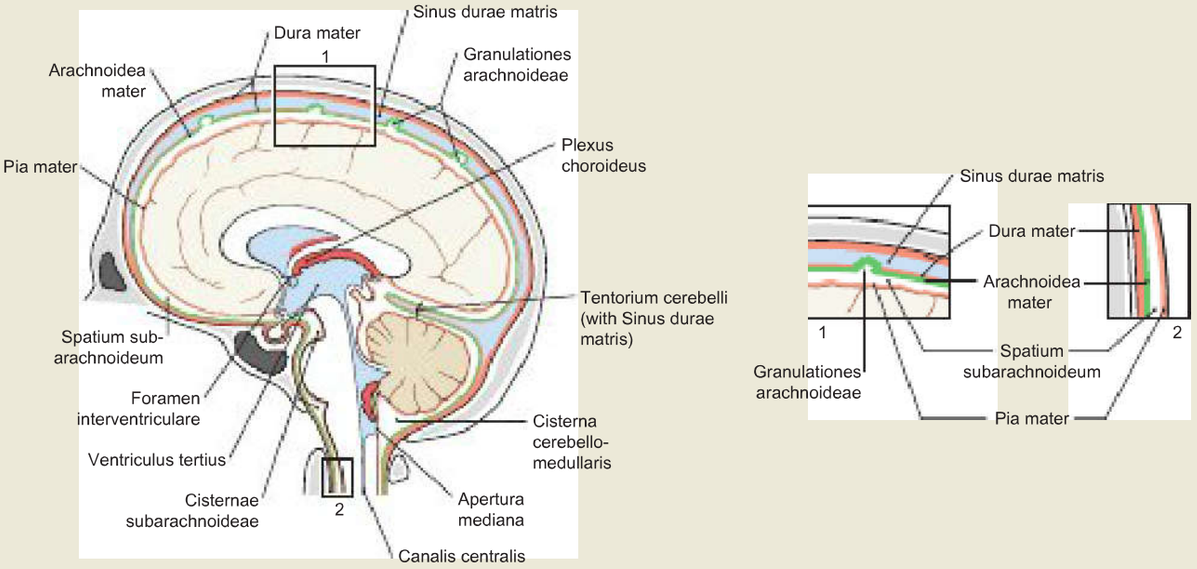

Fig. 12.33 Topographical relationships of the meninges in the bony skull; sagittal section, medial view. [L126]
The brain and the spinal cord are surrounded by a fibrous system of membranes (meninges). The meninges consist of a solid **(pachymeninx)** and a soft part **(leptomeninx)**; the leptomeninx is divided further into two components. The most exterior hard membrane (**Dura mater,** pachymeninx) is made of tight interlaced fibres of connective tissue and is fused with the periosteum inside the skull. The leptomeninx follows underneath. It consists of a complex system of meningeal cells and thin collagen fibres. In the course of the development, a space forms within the leptomeninx and a distinction is made between two laminae, the outer **Arachnoidea mater** is directly adjacent to the Dura mater; and the inner **Pia mater** is directly adjacent to the brain tissue, with everything drawn into the Gyri and Sulci. The space between the arachnoid mater and the Pia mater, the **subarachnoid space (Spatium subarachnoideum)** is filled with cerebrospinal fluid and traversed by arachnoid trabeculae. So the brain and spinal cord are completely surrounded by cerebrospinal fluid.

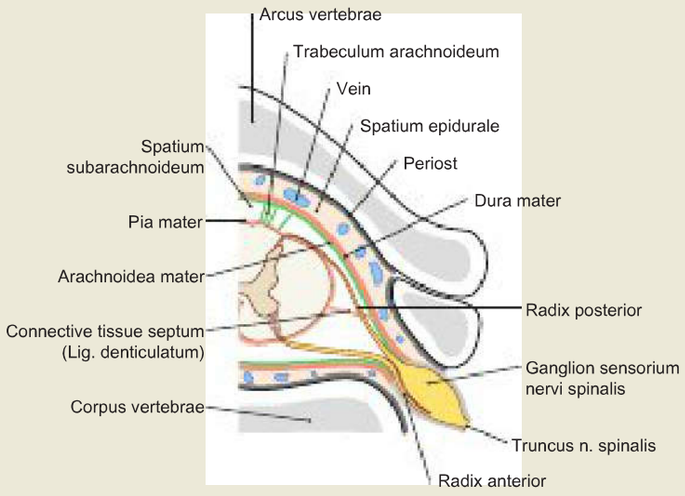

Fig. 12.34 Topographical relationships of the meninges in the vertebral canal; cross-section at the level of the 4th cervical vertebra. [L126]
In contrast to the Dura mater inside the skull, which is fused with the cranial periosteum (→ Fig. 12.33), the Dura mater of the spinal cord (Dura mater spinalis) forms a tubular sac, which surrounds the spinal cord but is not fused with the bony vertebral canal, except for its anchorage around the Foramen magnum and at the Os sacrum. The dural sac is located in the epidural space (Spatium epidurale; syn. peridural space, Spatium peridurale), which is filled with adipose tissue and a dense venous plexus (Plexus venosus vertebralis internus).

Clinical Remarks

If a cerebrocranial trauma is accompanied by rupture of the Dura mater and the Arachnoidea mater, e. g. in the area of the nose or ear, this can lead to a **fistula of cerebrospinal fluid (CSF fistula)**. This means that cerebrospinal fluid runs out of the nose **(rhinoliquorrhoea)** or the ear **(otoliquorrhoea).** For testing whether it is actually caused by a CSF fistula, a small amount of the secretion is collected to determine its content of glycoprotein β_2-transferrin, as this isoform only occurs in the CSF.

The **epidural or peridural anaesthesia (PDA)** is a standard anaesthetic method. After the insertion of a cannula into the epidural or peridural space (without penetrating the dura), local anaesthetics can be injected. These anaesthetics act on the spinal roots and spinal ganglia. The PDA is used for the regional elimination of pain, e. g. in the case of surgical procedures, which cannot or do not need to be conducted under general anaesthesia, for example in obstetrics.

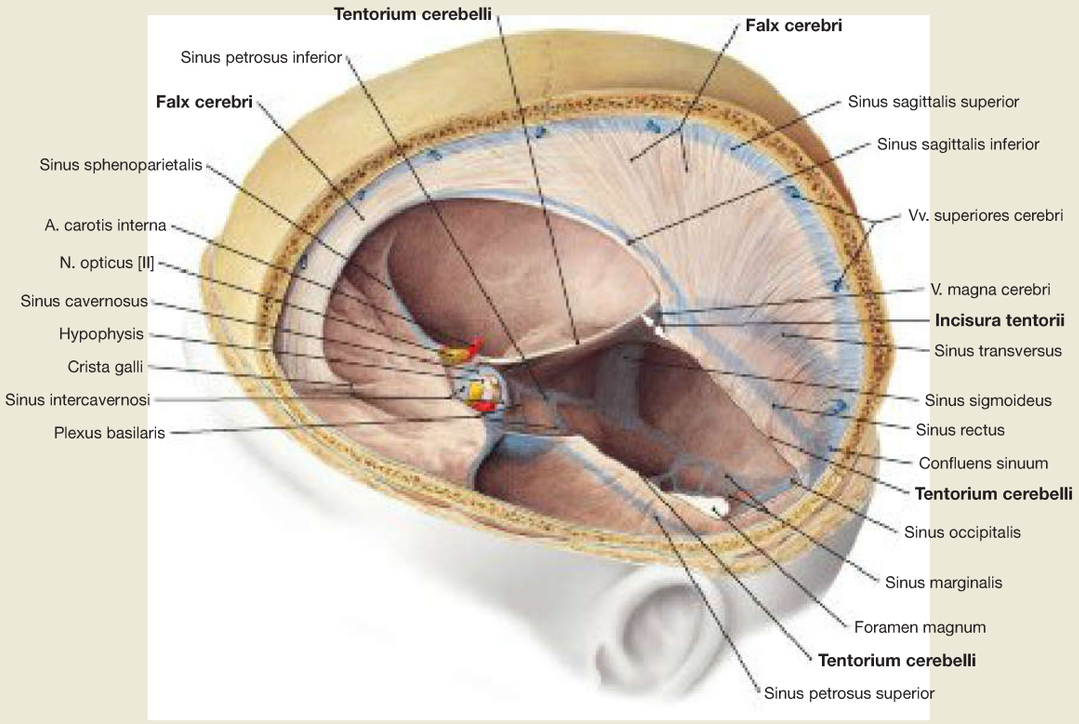

Fig. 12.35 Dura mater cranialis and dural septa; lateral view.
In the skull, the Dura mater consists of two laminale: (1) the **Lamina externa** is firmly attached to the periosteum, and (2) the **Lamina interna** is adjacent to the Arachnoidea mater. In several areas the two laminae are split to form elongated cavities with endothelial lining **(Sinus durae matris),** into which the venous blood of the brain is drained. The sinuses form a vascular system around the brain, in which the great majority of the venous blood flows to the V. jugularis interna. The Lamina interna also forms strong plate-like dural septa, which separate individual parts of the brain from each other and stabilise the entire brain in the skull. The dural septa/dural duplications include the **Falx cerebri** ('cerebral crescent'), **Tentorium cerebelli** ('cerebellar tent'), **Falx cerebelli** ('cerebellar crescent') and **Diaphragma sellae.** A slit-like gap between the legs (crura) of the Tentorium cerebelli (**Incisura tentorii**) enables the passage of the brain stem.

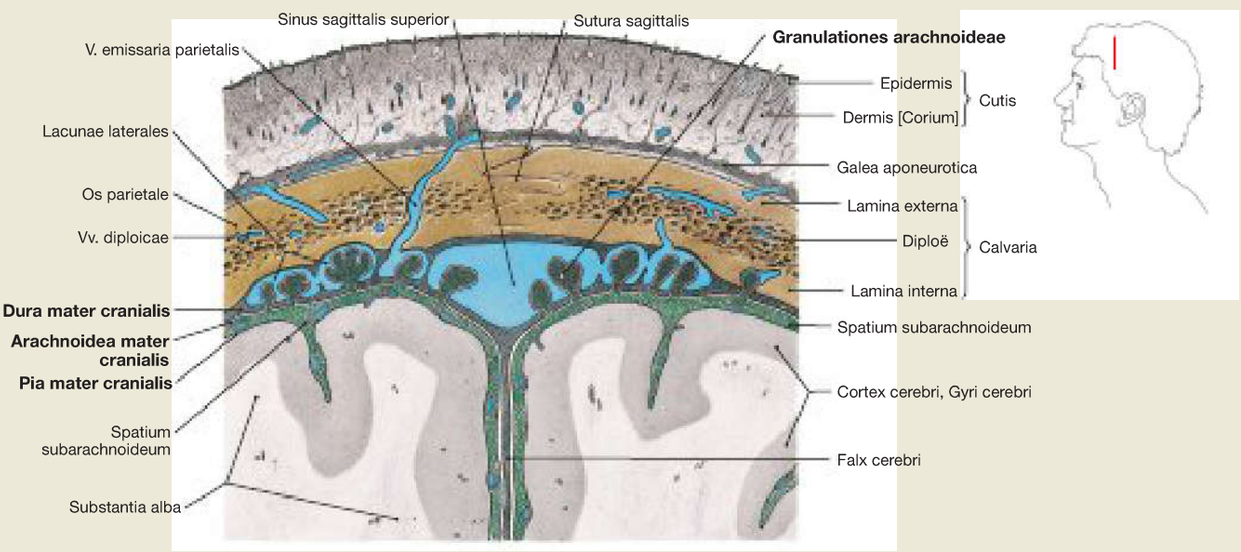

Fig. 12.36 Roof of skull, Calvaria, meninges, and venous sinuses, Sinus durae matris; frontal section.
In adults, the resorption of the cerebrospinal fluid (CSF) occurs mostly via the **arachnoid or PACCHIONIAN granulations** (Granulationes arachnoideae, arachnoid protrusions in the Sinus sagittalis superior or the Lacunae laterales) along the Sinus sagittalis superior (→ Fig. 12.33), and additionally via the lymphatic sheaths of small vessels in the Pia mater and the perineural sheaths of cranial and spinal nerves (not shown).

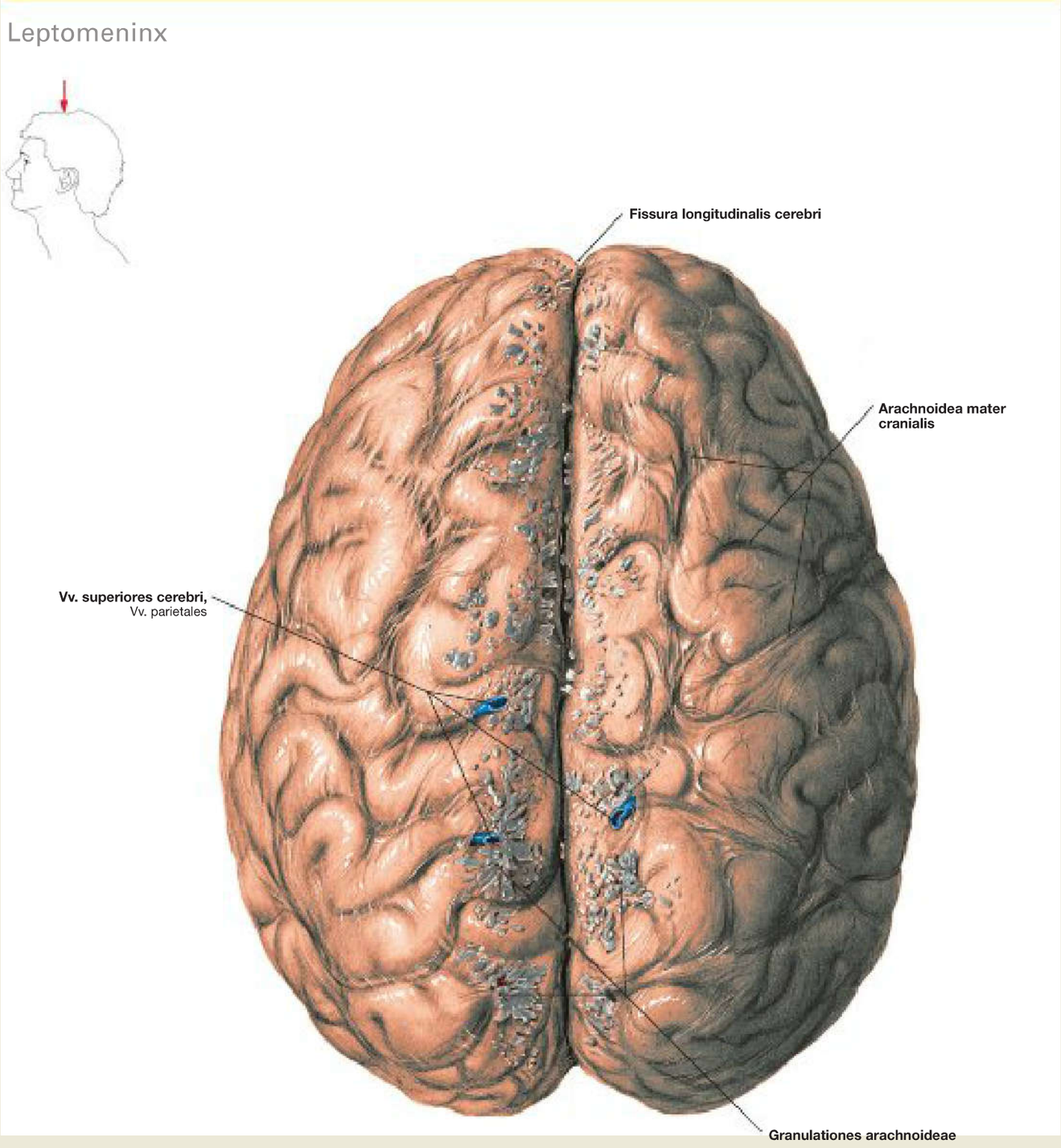

Fig. 12.37 Brain, Encephalon, with arachnoid mater, Arachnoidea mater cranialis; superior view.
The brain is covered by the cobweb-like Arachnoidea mater. The **Fissura longitudinalis cerebri** normally harbours the Falx cerebri (a duplication of the Dura mater cranialis; → Fig. 12.35), which divides the two cerebral hemispheres into a right and a left half and extends deep down to the Corpus callosum (not shown here). On both sides of the Fissura longitudinalis cerebri numerous arachnoid or PACCHIONIAN granulations (Granulationes arachnoideae) are visible, which reach beyond the level of the arachnoid mater. These granulations are responsible for the resorption of the CSF. In addition, several cerebral veins (Vv. superiores cerebri, Vv. parietales) are visible, which were separated from the bridging veins (small veins piercing the Dura mater cranialis and flowing to the Sinus sagittalis superior) during the removal of the brain from the skull.

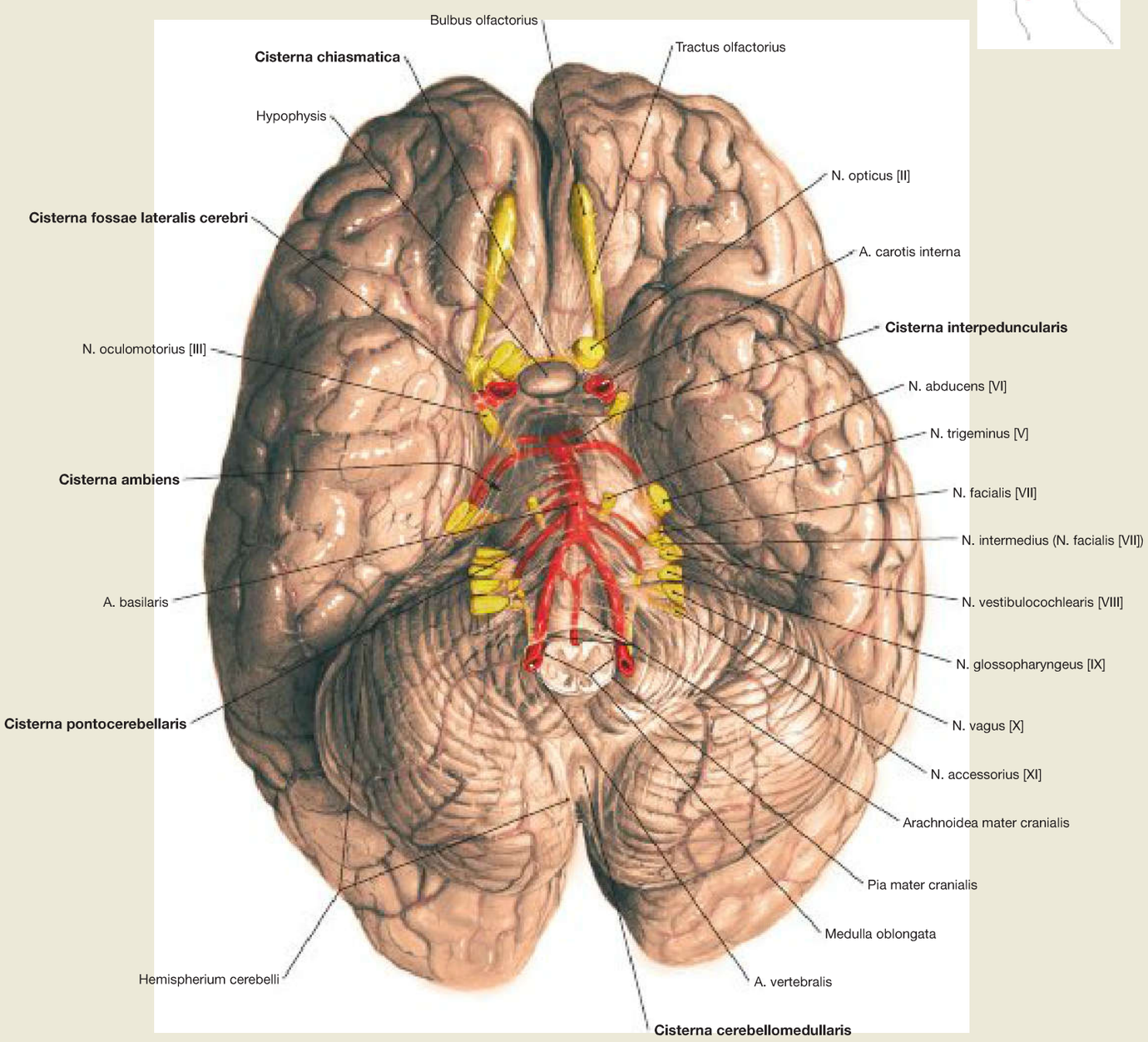

Fig. 12.38 Brain, Encephalon, with arachnoid mater, Arachnoidea mater cranialis; inferior view.
The brain is surrounded by the cobweb-like Arachnoidea mater. Nerves and blood vessels run in the Spatium subarachnoideum. The inferior view shows the frontal, temporal and occipital lobes, as well as the cerebellum. The Circulus arteriosus cerebri (WILLISII; → Fig. 12.58) is preserved but only partially visible. The arachnoid mater does not cover all of the brain evenly so that superficial irregularities of the brain or the cranial base can lead to enlargements of the subarachnoid space. Particularly wide expansions of the subarachnoid space are the so-called cisterns (CSF cisterns). The most important cisterns are:

- Cisterna cerebellomedullaris (Cisterna magna)
- Cisterna chiasmatica
- Cisterna interpeduncularis
- Cisterna ambiens
- Cisterna fossae lateralis cerebri
- Cisterna pontocerebellaris

Ventricles of the Brain

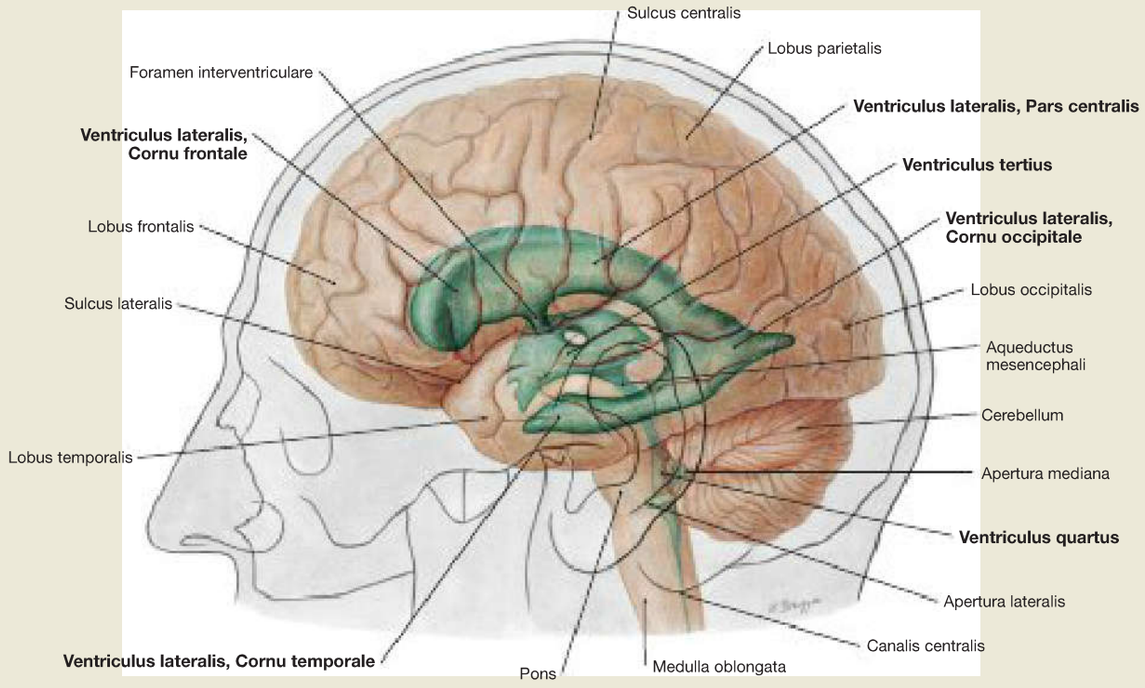

a

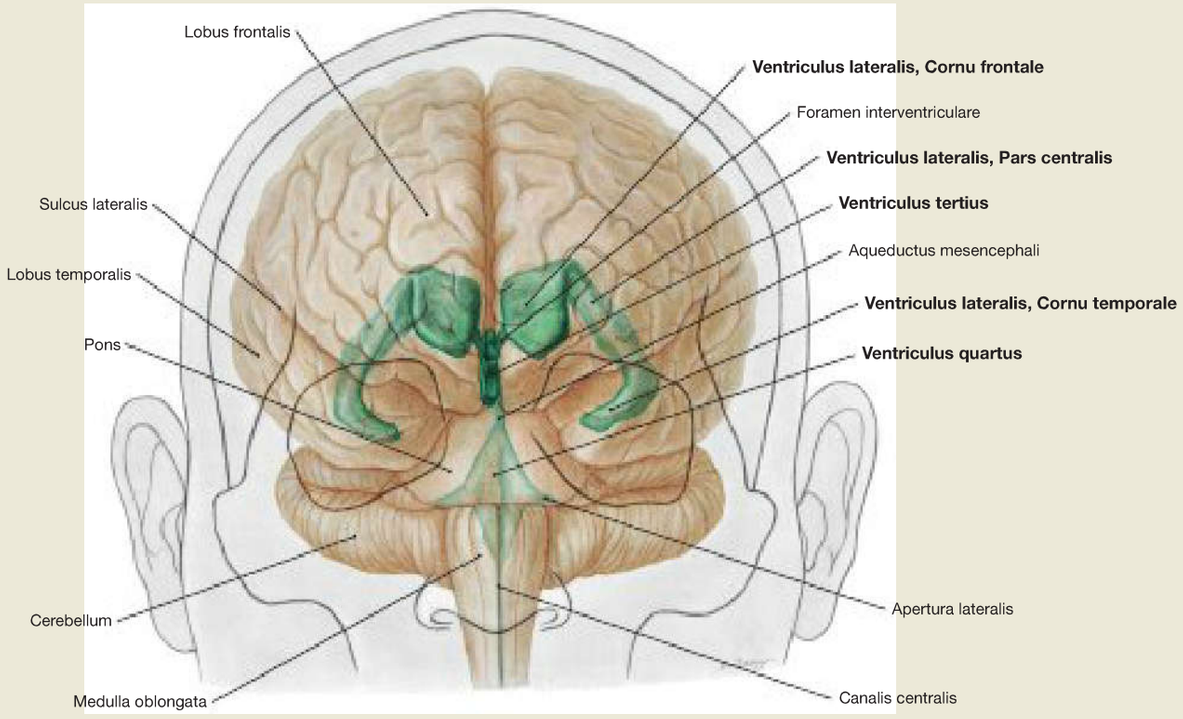

b

Fig. 12.39a and b Ventricles of the brain, Ventriculi encephali; view from the left side (→ Fig. 12.39a); anterior view (→ Fig. 12.39b).
a The inner subarachnoid (CSF) space consists of the ventricular system and the central canal (Canalis centralis) of the spinal cord. The ventricular system comprises the **paired lateral ventricles** (Ventriculi laterales) with Cornu frontale, Pars centralis, Cornu occipitale and Cornu temporale, the **third ventricle** (Ventriculus tertius), the Aqueductus mesencephali and the **fourth ventricle** (Ventriculus quartus).
b The anterior view shows the paired lateral ventricles, as well as the third and fourth ventricles located in the median line, in projections onto the brain.

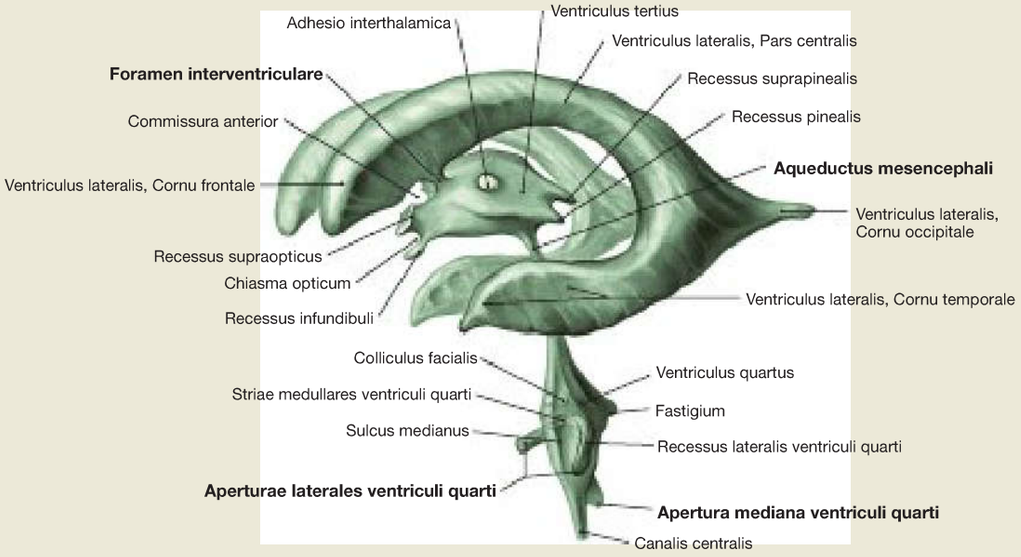

Fig. 12.40 Inner subarachnoid spaces, Ventriculi encephali; corrosion cast specimen; oblique view from the left side.
Each lateral ventricle is connected to the third ventricle via an Foramen interventriculare **(Foramen of MONRO)**. The third ventricle communicates with the fourth ventricle via the **Aqueductus mesencephali.** The fourth ventricle has three openings (Aperturae) to the outer subarachnoid (CSF) space: the Apertura mediana (Foramen of MAGENDIE) and the paired Aperturae laterales (Foramina of LUSCHKA).

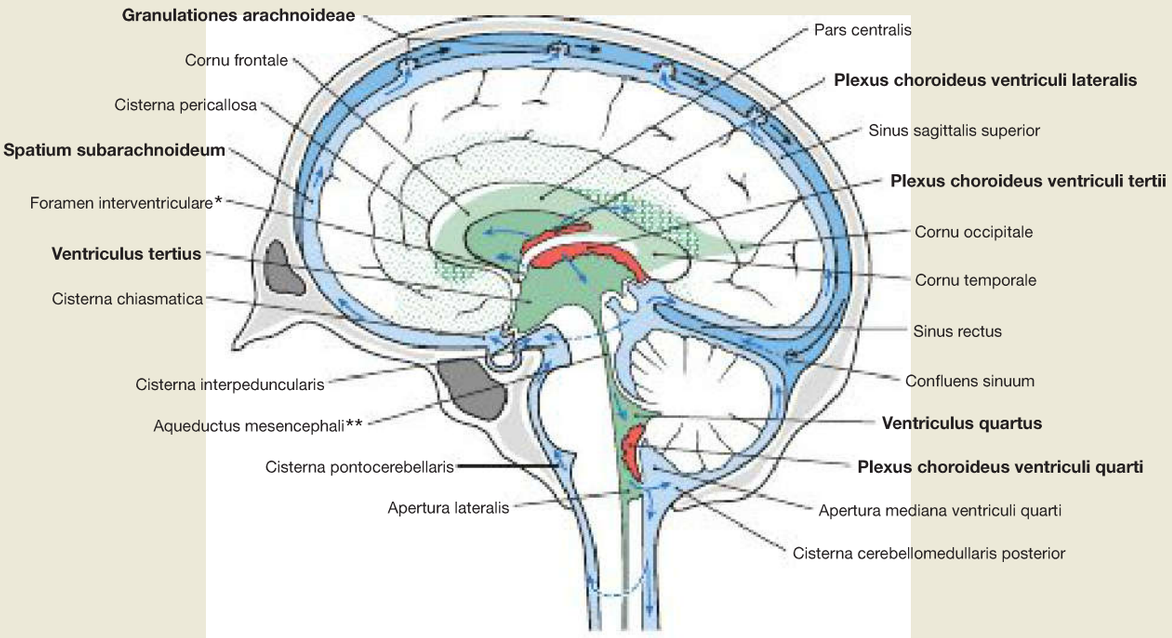

Fig. 12.41 Ventricles of the brain, Ventriculi encephali, and subarachnoid space, Spatium subarachnoideum; schematic drawing of the CSF circulation (arrows) from the inner to the outer subarachnoid spaces. [L126]
The outer subarachnoid space is located between Arachnoidea mater and Pia mater. This space surrounds the brain as well as the spinal cord. The major part of the cerebrospinal fluid (Liquor cerebrospinalis) is secreted by the Plexus choroidei in the ventricles.
The circulating fluid volume (150 ml) is exchanged permanently (daily production of approx. 500 ml.

Functionally, the cerebrospinal fluid (CSF) serves as a protective cushion of the CNS against mechanical forces, as a means of weight reduction of the CNS (by creating a buoyancy it lowers the weight from 1,400 g to 45 g, e. g. about 97%), it also supports the metabolism of the CNS, the removal of toxic substances, and the transport of hormones (e. g. leptin).

* clinical term: foramen of MONRO
** clinical term: aqueduct of SYLVIUS

Blood Supply of the Dura mater

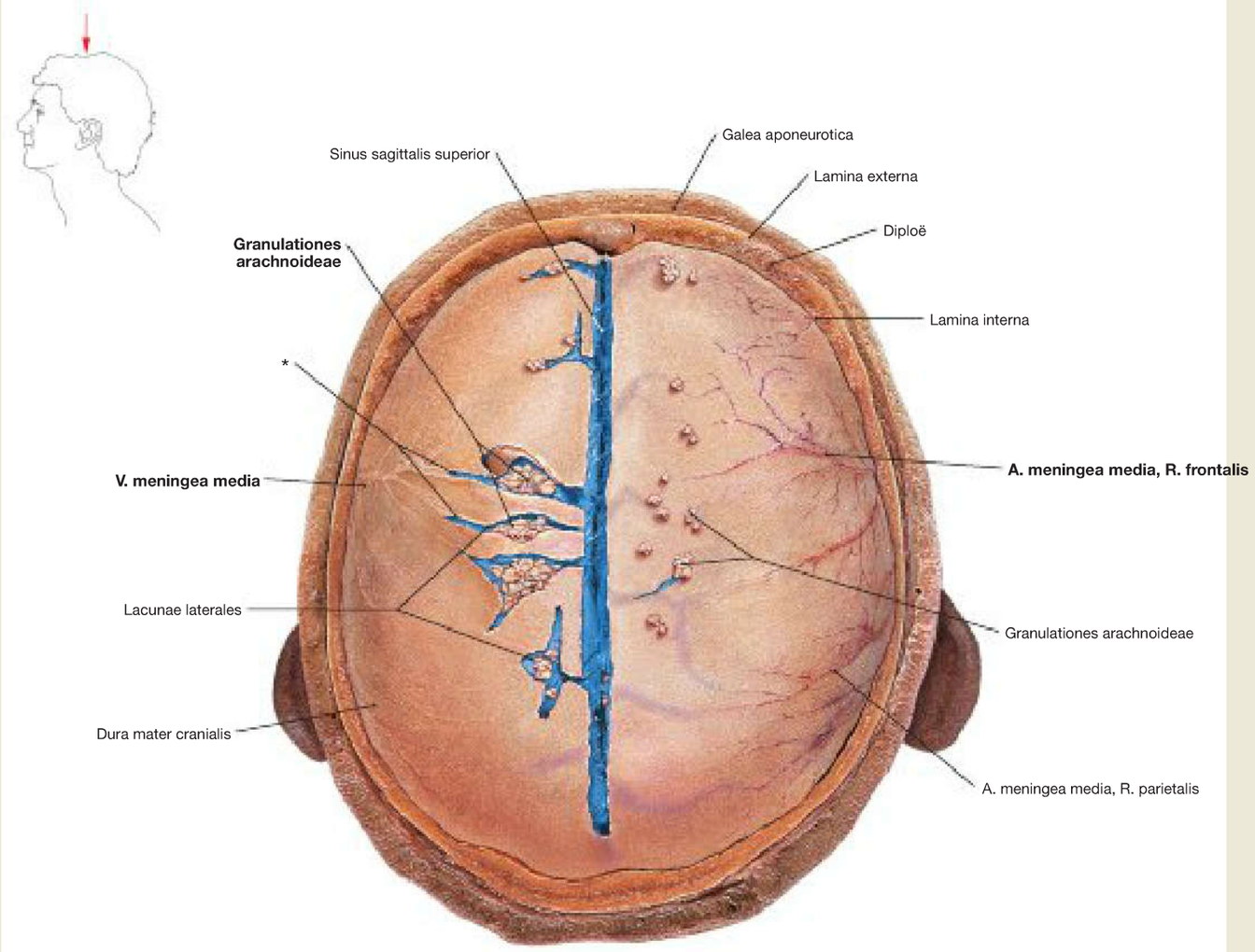

Fig. 12.42 Dura mater cranialis, and Sinus sagittalis superior with several Lacunae laterales; superior view.
The Calvaria are removed and on the left side of the head the Dura mater cranialis (hard meningeal membrane) has been opened along the **Lacunae laterales**, and the confluence (openings) of the **Vv. meningeae mediae** into the lacunae is visible. In the lacunae lie the arachnoid or PACCHIONIAN granulations (Granulationes arachnoideae). On the right side, one can see some elevated Granulationes arachnoideae, which rise above the level of the dura. These arachnoid granulations extend into the bones of the skull where they leave impressions and are in contact with the Vv. diploicae.

* openings of the Vv. meningeae mediae into the Lacunae laterales

Clinical Remarks

Meningiomas are slow-growing, usually benign intracranial tumours. They develop preferably in the PACCHIONIAN granulations (Granulationes arachnoideae), alongside the Falx cerebri, in the region of the sphenoidal wings, and in the olfactory groove. They mostly originate from mesothelial cells in the arachnoid mater. Initially, they often remain unnoticed because the surrounding tissue can adapt to the tumour growth rate. So they can achieve a significant size before causing symptoms, e. g. a sudden seizure or increasing headaches. If a surgical resection is possible, the prognosis is very good.
In contrast to the brain and spinal cord, the meninges are extremely well innervated and therefore very pain sensitive. This is particularly apparent in patients with **meningitis**, who suffer from severe headaches, accompanied by stiffness of the neck and overextension of the spine **(meningism).** A suspected meningism can be diagnosed with two tests:
(1) If the head of the supine patient is passively bent forward, and this leads to a reflexive flexion of the legs for pain relief (decompression of the meninges), the **BRUDZINSKI's sign** is positive.
(2) In the case of a positive **KERNIG's sign**, the passive lifting of the straightened leg is followed by an active flexion of the knee joint due to irritation of the meninges.

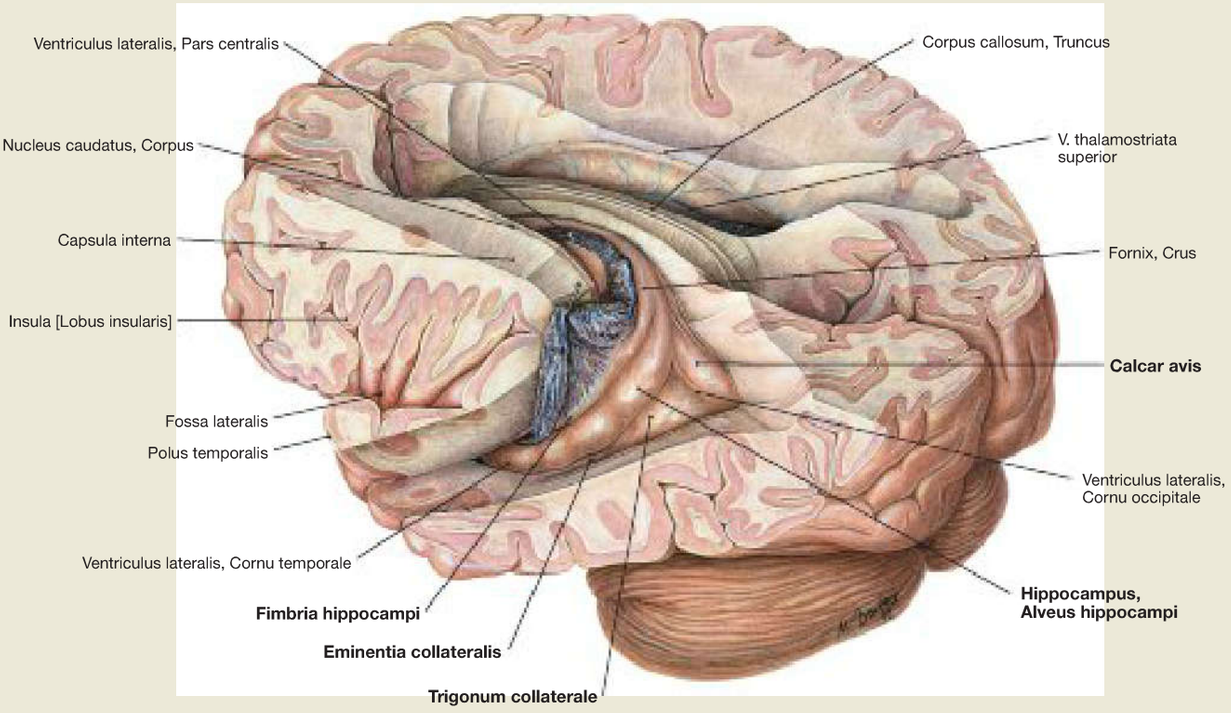

Fig. 12.43 Lateral ventricles, Ventriculi laterales; posterior-superior view from the left side; after removal of the upper parts of the cerebral hemispheres.
This is a view into both the lateral ventricles. In the left lateral ventricle, the **Plexus choroideus** is visible, which has been lifted up with a probe at the transition from the Pars centralis to the Pars temporalis of the lateral ventricle. In the Plexus choroideus, the **fluid production** takes place.
The walls of the ventricles are presented in the table.

Topography of the Lateral Ventricles

Ventricle, Parts	Wall	Adjacent Structures	Plexus choroideus
Ventriculi laterales, Crus frontale	Roof	Corpus callosum (Truncus)	No
	Anterior wall	Corpus callosum (Genu)	
	Medial wall	Septum pellucidum	
	Lateral wall	Caput nuclei caudati	
Ventriculi laterales, Pars centralis	Roof	Corpus callosum	Yes
	Floor	Thalamus	
	Medial wall	Septum pellucidum, Fornix	
	Lateral wall	Corpus nuclei caudati	
Ventriculi laterales, Crus occipitale	Roof	Medullary body of the Lobus occipitalis	No
	Floor	Medullary body of the Lobus occipitalis	
	Medial wall	Calcar avis	
	Lateral wall	Radiatio optica	
Ventriculi laterales, Crus temporale	Roof	Cauda nuclei caudati	Yes
	Floor	Hippocampus	
	Medial wall	Fimbria hippocampi	
	Lateral wall	Cauda nuclei caudati	
	Anterior wall	Amygdala	
Ventriculus tertius	Roof	Tela choroidea ventriculi tertii	Yes
	Floor	Hypothalamus	
	Anterior wall	Lamina terminalis ventriculi tertii	
	Lateral wall	Thalamus, epithalamus	
Ventriculus quartus	Roof	Velum medullare superius cerebelli and Velum medullare inferius cerebelli	Yes
	Floor	Fossa rhomboidea	
	Lateral wall	Pedunculi cerebri	

Depiction of the Ventricles

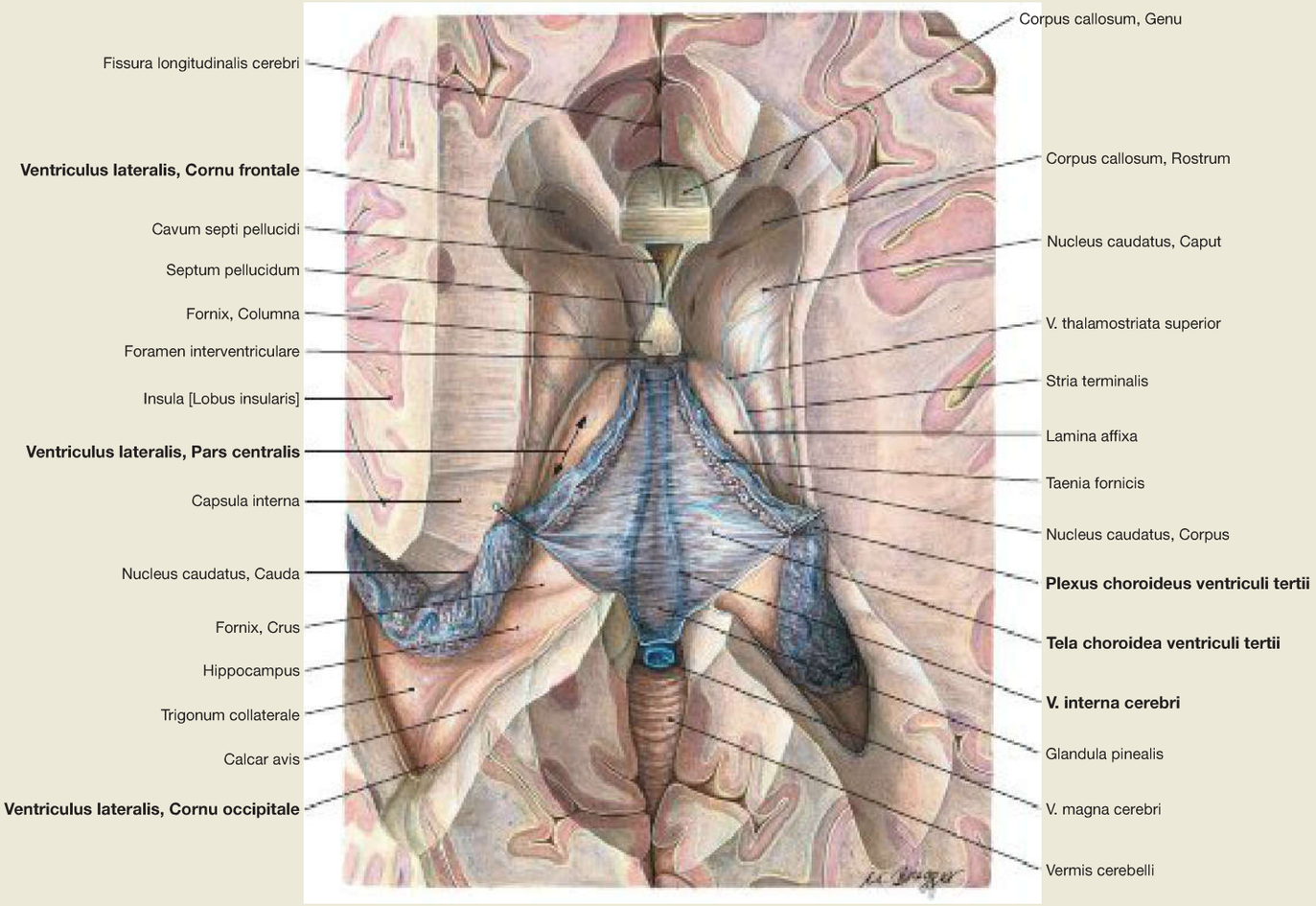

Fig. 12.44 Lateral ventricles, Ventriculi laterales; superior view; after removal of the central part of the Corpus callosum and the columns (Crura) of the fornix.
The **Tela choroidea** spans the third ventricle, as shown here. The Vv. internae cerebri, which are glimmering through, drain to the V. magna cerebri. The Cornu frontale, the Pars centralis and the Cornu occipitale of the lateral ventricles can be seen. Laterally, the **Plexus choroideus** continues on the hippocampus into the Cornu temporale.

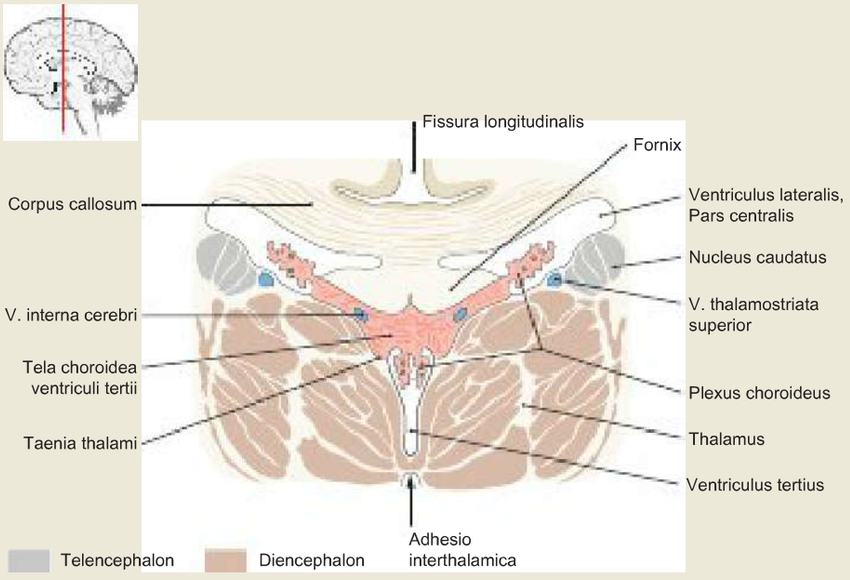

Fig. 12.45 Plexus choroideus in the lateral ventricles, Ventriculi laterales, and in the third ventricle, Ventriculus tertius; schematic frontal section. [L126]
In the **Plexus choroideus** the cerebrospinal fluid (CSF) is produced; choroid plexuses are present in the paired lateral ventricles (first lateral ventricle on the left side, and second lateral ventricle on the right side) as well as in the third and the fourth ventricles (not shown). In the Plexus choroidei, the capillary blood and subarachnoid space are separated by a **blood-CSF barrier**.

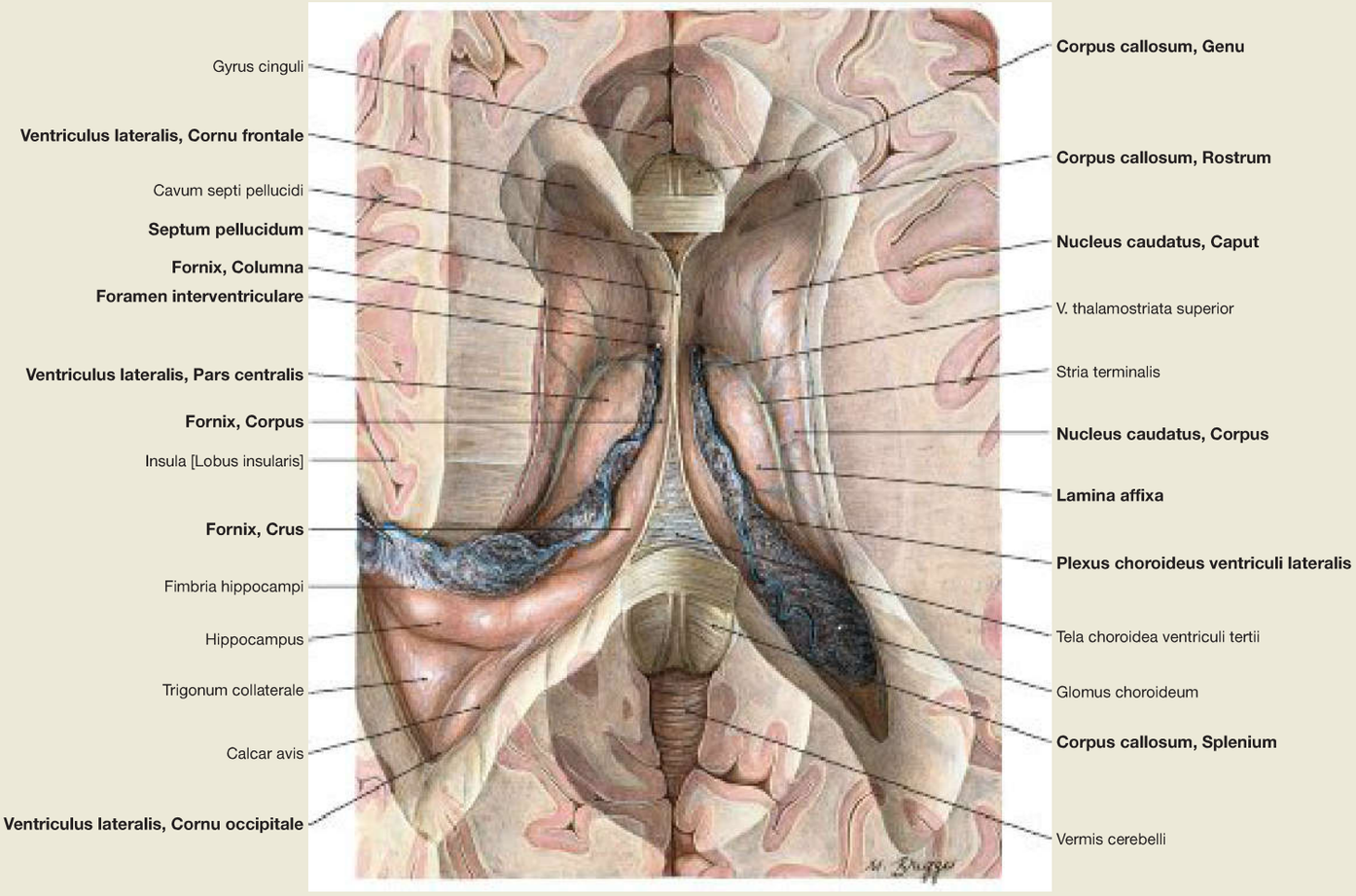

Fig. 12.46 Lateral ventricles, Ventriculi laterales; superior view; after removal of the upper parts of the cerebral hemispheres and the central part of the Corpus callosum.
This view shows the Cornu frontale, the Pars centralis and the Cornu occipitale as well as the transition to the Cornu temporale of both lateral ventricles. The **Cornu frontale** is bordered by the Genu of the Corpus callosum (anterior wall), the Truncus of the Corpus callosum (the roof is not visible because of the cut at the level of the Genu and Splenium), the Septum pellucidum (medial wall), the Caput of the Nucleus caudatus (lateral wall), as well as by the Rostrum of the Corpus callosum (floor). In addition, the Foramina interventricularia **(Foramina of MONRO)** are visible in the Cornu frontale. Like the roof of the Pars frontalis, the roof of the Pars centralis is also formed by the Truncus of the Corpus callosum (removed). The Crus of the Fornix and the Septum pellucidum form the medial wall, the Corpus of the Nucleus caudatus forms the lateral wall, whereas the floor consists of the Lamina affixa of the Plexus choroideus and the Crus of the Fornix.

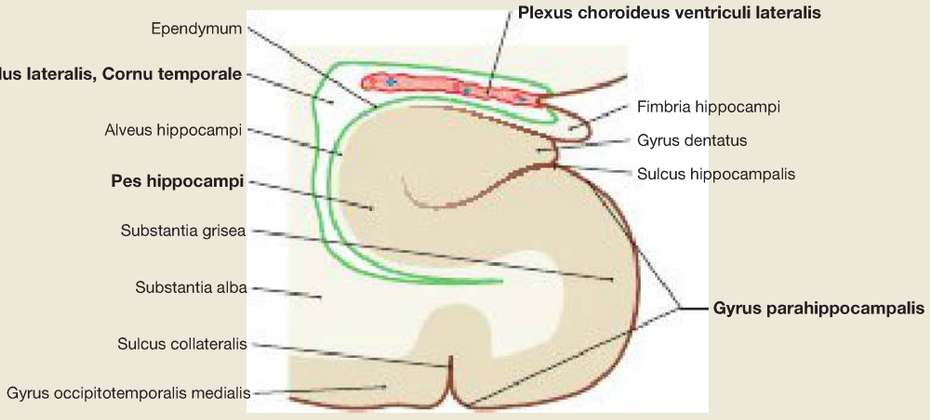

Fig. 12.47 Temporal horn, Cornu temporale, of the lateral ventricle, Ventriculus lateralis; schematic frontal section. [L126]
The schematic drawing shows how the lateral ventricle is arranged around the hippocampus formation. The Plexus choroideus protrudes into the lateral ventricle. The walls of the ventricle are marked with light green lines, the fluid or inner ventricular space is coloured in white.

Depiction of the Ventricles

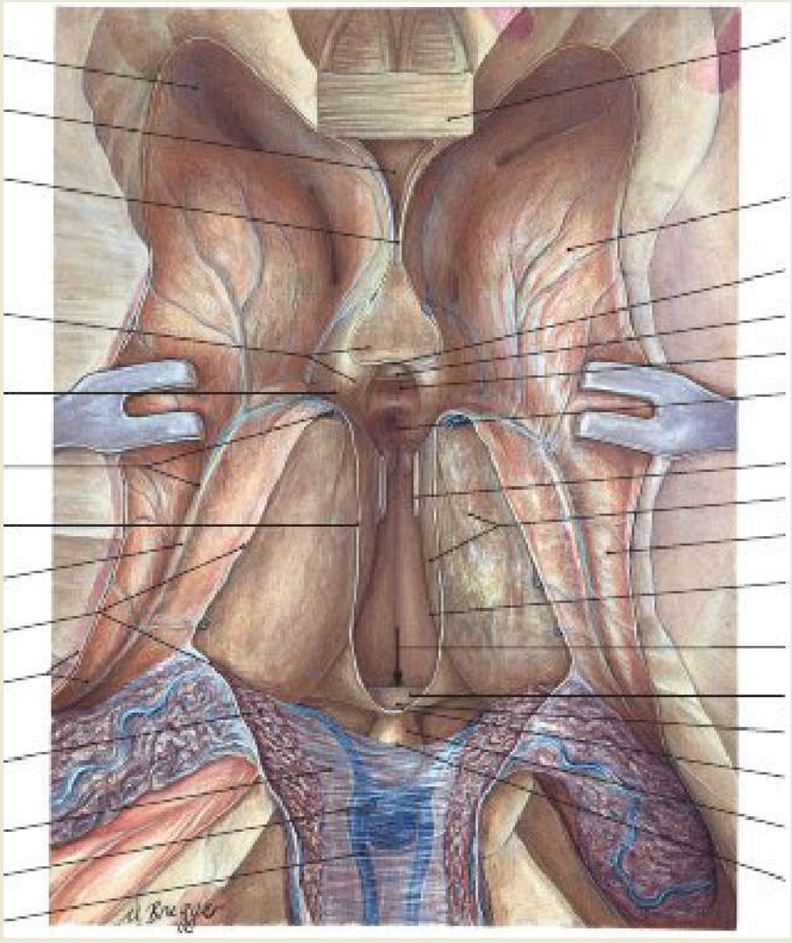

Fig. 12.48 Lateral ventricles, Ventriculi laterales, and third ventricle, Ventriculus tertius; superior view; after removal of parts of the cerebral hemispheres and the central part of the Corpus callosum, the Fornix and the Plexus choroideus; the Tela choroidea of the third ventricle is folded back.

The boundaries of the third ventricle are listed in the table on p. 289.

* Adhesio interthalamica cut in the median plane

Arterial Blood Supply of the Plexus choroidei (→ Fig. 12.63)	
Ventricle	**Artery**
Ventriculi laterales	A. choroidea anterior (from the A. carotis interna) A. choroidea posterior lateralis (from the A. cerebri posterior)
Ventriculus tertius	A. choroidea posterior medialis (from the A. cerebri posterior)
Ventriculus quartus	A. inferior posterior cerebelli (from the A. vertebralis) A. inferior anterior cerebelli (from the A. basilaris)

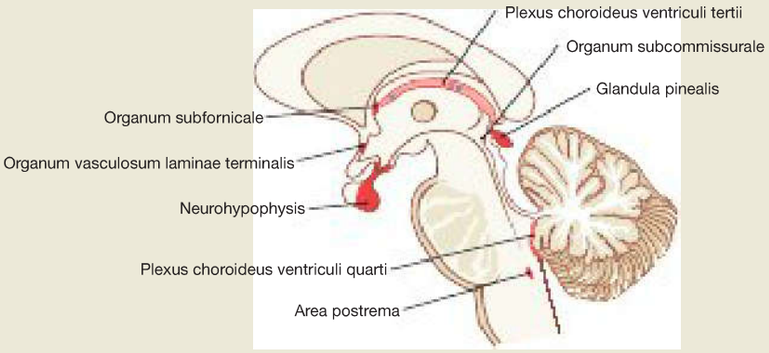

Fig. 12.49 Circumventricular organs; median sagittal section. [L126] Characteristic features of the circumventricular organs (CVOs) are their rich vascularisation, modified ependyma (tanycytes with tight junctions), and a blood-CSF barrier instead of a blood-brain barrier.
The CVOs are divided into sensory and secretory organs: secretory CVOs include the neurohypophysis, the Eminentia mediana of the (pituitary) infundibulum, and the pineal gland (Glandula pinealis). Sensory CVOs in the narrow sense are the Organum vasculosum laminae terminalis and the Organum subfornicale (both: regulation of blood volume and arterial pressure, release of hormones such as angiotensin, somatostatin, inducing fever), the Organum subcommissurale (only existent in the foetal and newborn phase; release of a glycoprotein-rich secretion) and the Area postrema (trigger zone of nausea/vomiting).

Clinical Remarks

Due to their blood-CSF barrier instead of a blood-brain barrier, the circumventricular organs serve as pharmacological access routes. For example in the case of fever, **acetylsalicylic acid (ASA)** has an antipyretic action as inhibitor of cyclooxygenase by reducing the production of prostaglandin. In the case of fever the temperature-sensitive neurons of the Organum vasculosum laminae terminalis have a reduced sensitivity for intrinsic prostaglandins. These neurons normally initiate cooling mechanisms, which in the case of fever only function to a minor extent or not at all. By reducing the prostaglandin formation, ASA can therefore increase the sensitivity of neurons. As a result, the down-regulation of the set-point caused by the fever is readjusted to the standard value – and the high temperature/fever is lowered. Central vomiting (emesis), e. g. due to opioids, can be treated with **neuroleptic drugs**, which bind to dopamine receptors in the Area postrema and thus have an antiemetic effect.

Clinical Remarks

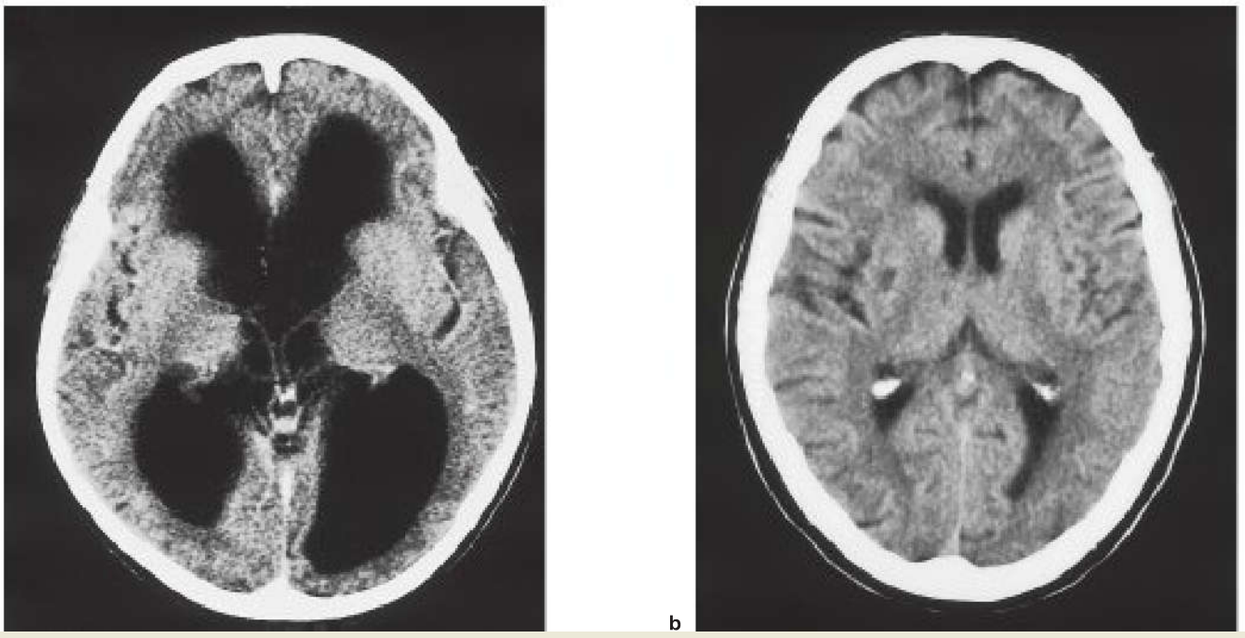

Fig. 12.50a and b Computed tomographic (CT) cross-sections of the head. [R317]
a CT scan of a patient with impaired CSF circulation due to narrowing of the Aqueductus mesencephali. The ventricles are significantly enlarged at the expense of the parenchyma of the brain (hydrocephalus). The patient suffered from massive intellectual deficits and significant gait disorders.
b CT scan of a healthy person

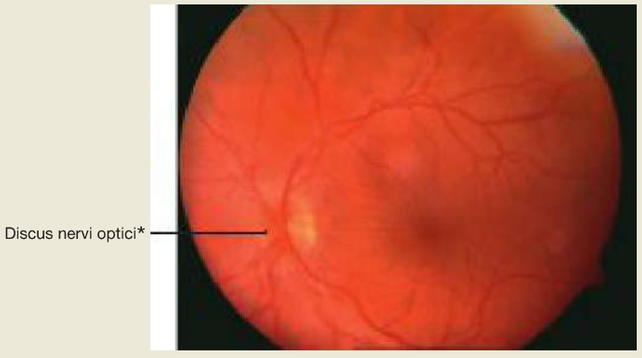

Fig. 12.51 Ocular fundus, Fundus oculi; left side; anterior view; ophthalmoscopic image of the central area showing a congested Papilla nervi optici due to increased cranial pressure.

A congested Papilla nervi optici (optic disc) is visible on the ocular fundus as a clinical sign of an intraventricular neurocytoma WHO grade II. Since the N. opticus [II] is surrounded by meninges and fluid, the optic disc is bulging in the eyeball.

* clinical term: papilla or blind spot

Clinical Remarks

Obstructions of the fluid circulation can be caused by tumours, malformations, bleeding or other factors, and due to increased intracranial pressure they can lead to headaches, nausea and a papilledema (→ Fig. 12.51). In the case of a blockade in the inner CSF space, a **hydrocephalus internus** (→ Fig. 12.51) will occur and an impaired drainage in the outer CSF or subarachnoid space will lead to a **hydrocephalus externus. Hydrocephalus e vacuo** is the term for a condition with considerably increased ventricular size because of a loss of brain substance, e.g. as in ALZHEIMER's disease.

The circumventricular organs (→ Fig. 12.49) **lack the blood-brain barrier** and, thus, are capable of monitoring the plasma-blood milieu; as such they are of more interest than a purely pharmacological level. The Area postrema for example contains numerous dopamine and serotonin receptors. Highly promising antiemetic effects can be achieved by using dopamine or serotonin antagonists. In addition, the excitability of biochemical receptors in the area postrema is a protective mechanism for the whole body, for example by centrally triggered vomiting after the ingestion of spoiled food, so that the major part of the potentially harmful substance is eliminated from the body.

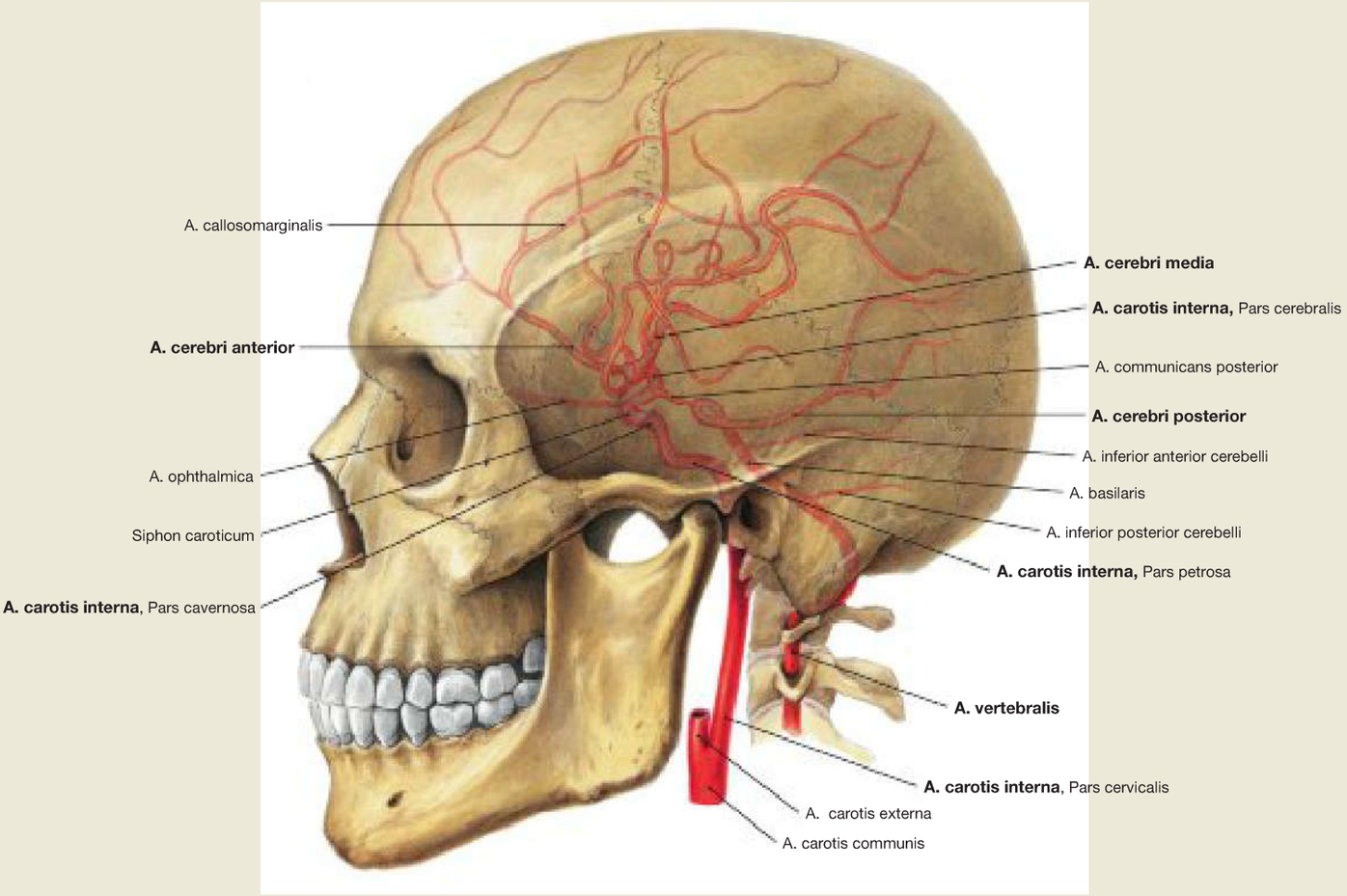

Fig. 12.52 Internal arteries of the head.
The blood supply to the brain is provided by four major arteries: the two Aa. carotides internae and the two Aa. vertebrales. The four vessels supply the **Circulus arteriosus cerebri** (**WILLISII;** → Fig. 12.58), located at the base of the brain and forming the anastomosis between the Aa. carotides internae and the Aa. vertebrales, from which the paired cerebral arteries (Aa. cerebri anterior, cerebri media and cerebri posterior) exit.
The anastomotic vessels of the Circulus arteriosus cerebri (WILLISII) are often so thin that no important blood exchange takes place via them. In most cases, under normal conditions of intracranial pressure, each hemisphere is supplied with blood by the ipsilateral **A. carotis interna** and the ipsilateral **A. cerebri posterior**. In 10 % of the cases, both Aa. cerebri anteriores originate from the A. carotis interna on one side. In 10 % of the cases, also the A. cerebri posterior originates from the A. carotis interna via the A. communicans posterior. The A. carotis interna originates together with the A. carotis externa from the A. carotis communis. The Glomus caroticum sits in this bifurcation.

Clinical Remarks

The cerebral blood flow is of great clinical relevance. The brain tissue will be irreversibly damaged **(ischemia tolerance)** within a maximum time of 7–10 min. This must be taken into account in the cardiovascular resuscitation of patients with cardiac arrest. The importance of the brain circulation immediately becomes clear when a standing up too quickly leads to a blackout, because the brain is not sufficiently supplied with blood for a short moment. The same occurs with fainting (syncope). The brain is not supplied with enough blood, and as a result, the patient drops to the floor. In the supine position, the cerebral blood flow improves and the brain functions return.

Vascular changes (extracranial arteriosclerosis: plaques, stenosis, obliteration) are often located in the carotid bifurcation. The Glomus caroticum (not shown in → Fig. 12.52, → Fig. 12.161) is a 'paraganglion' located in the carotid bifurcation; it contains chemoreceptors, which react to changes of the pH, oxygen and carbon dioxide levels of the blood.
The **carotid sinus syndrome** is defined as a hypersensitivity of pressure receptors in the carotid sinus, which may already in response to head rotations trigger a reflex that strongly lowers the heart rate (vasovagal reflex). This can result in cardiovascular collapse and cardiac arrest.

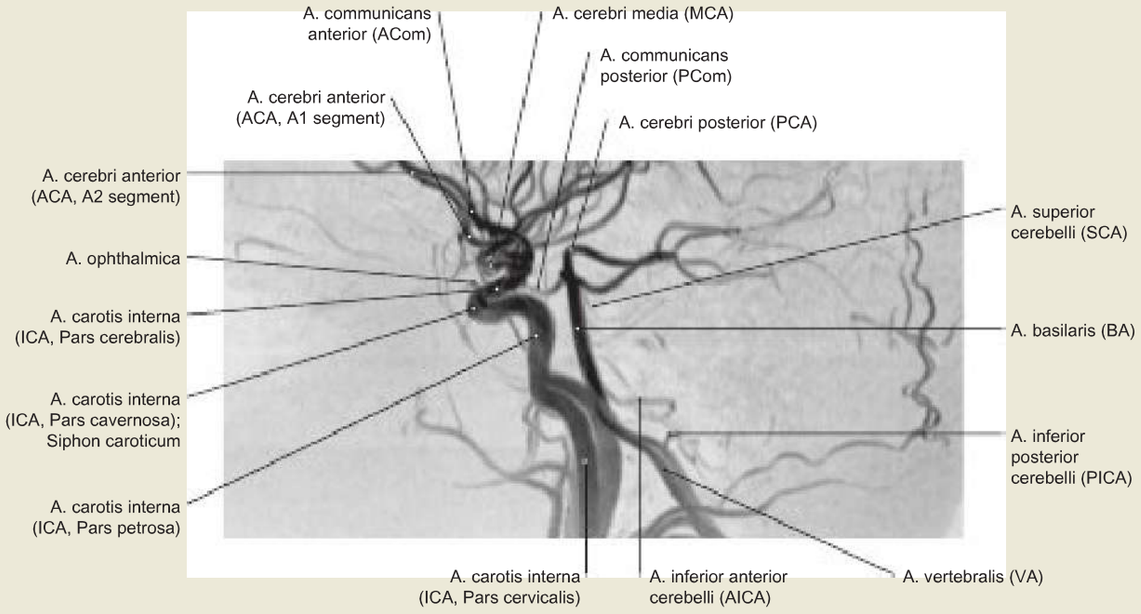

Fig. 12.53 MR angiography of the arteries supplying the brain; lateral view. [T786]

The figure shows the carotid siphon (Siphon caroticum; → Fig. 12.52).

Clinical (radiological) Names of the Vascular Segments of the Major Blood Vessels Supplying the Brain

Artery	Segment	Topography/Anatomical Structures
A. carotis interna, ICA = internal carotid artery	C1 – cervical	Pars cervicalis
	C2 – petrous	Pars petrosa up to the end of the Canalis caroticus
	C3 – lacerum	up to a ligament between Lingula sphenoidalis and the apex of the Os petrosum ('Lig. petrolingualis')
	C4 – cavernous	in the Sinus cavernosus until exiting the dura below the Proc. clinoideus
	C5 – clinoid	between Proc. clinoideus anterior and the base of the Os sphenoidale
	C6 – ophthalmic	up to the outlet of the A. communicans posterior; outlet of the A. ophthalmica
	C7 – communicating	up to the bifurcation of the ACI into the Aa. cerebri anterior et media
A. cerebri anterior, ACA = anterior cerebral artery	A1	Pars precommunicalis; from its origin to the outlet of the A. communicans anterior
	A2	Pars postcommunicalis; from the outlet of the A. communicans anterior to the outlet of the A. callosomarginalis; also: Pars infracallosa
	A3	Pars postcommunicalis; distally of the outlet of the A. callosomarginalis (A. pericallosa); some authors differentiate even more segments (A4 and A5)
A. cerebri media, MCA = middle cerebral artery	M1	Pars sphenoidalis; from its outlet to the bifurcation in two or three main branches
	M2	Pars insularis; in the Fossa lateralis, above the Insula
	M3	Pars opercularis; in the Fossa lateralis, lateral branches in the direction of the cortical surface
	M4	Pars terminalis; after the exit of all vessels from the Sulcus lateralis
A. cerebri posterior, PCA = posterior cerebral artery	P1	Pars precommunicalis; from its outlet to the A. communicans posterior; passes through the Cisterna interpeduncularis
	P2	Pars ambiens; from the A. communicans posterior to the outlet of the Rr. temporales anteriores (at the level of the Cisterna ambiens)
	P3	Pars quadrigeminalis; from the Rr. temporales anteriores to the bifurcation into the Aa. occipitales medialis and lateralis (at the level of the Cisterna quadrigeminalis)
	P4	Pars calcarina; terminal branches: A. occipitalis medialis and A. occipitalis lateralis
A. vertebralis, VA = vertebral artery	V1	Pars prevertebralis
	V2	Pars transversaria
	V3	Pars atlantica
	V4	Pars intracranialis

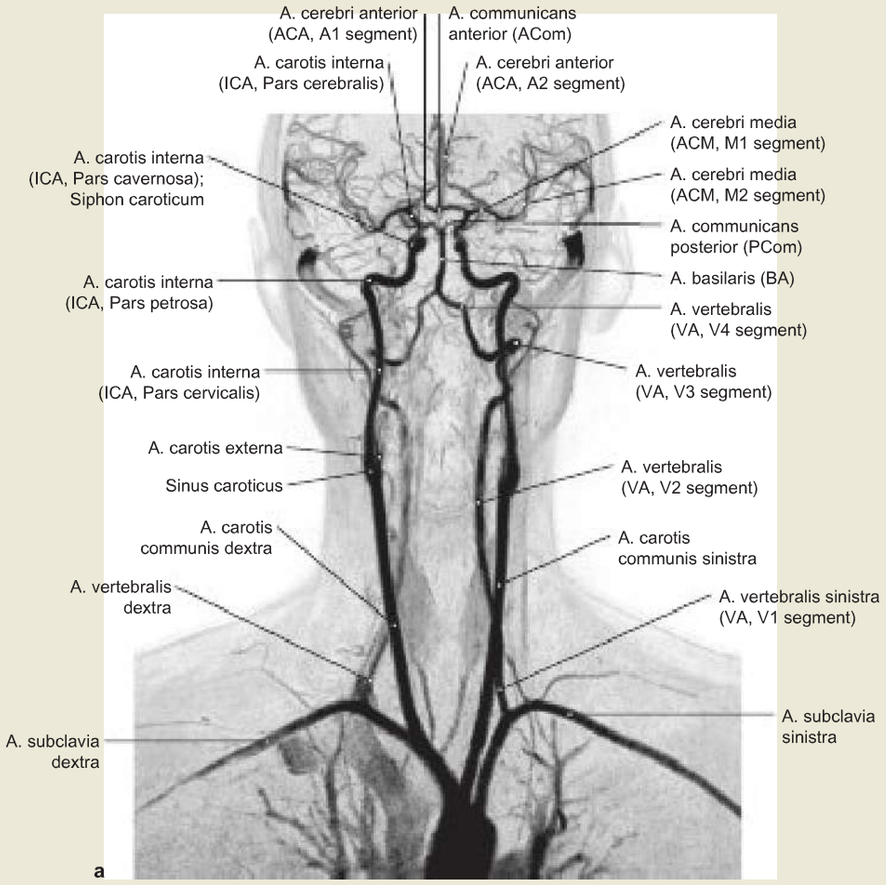

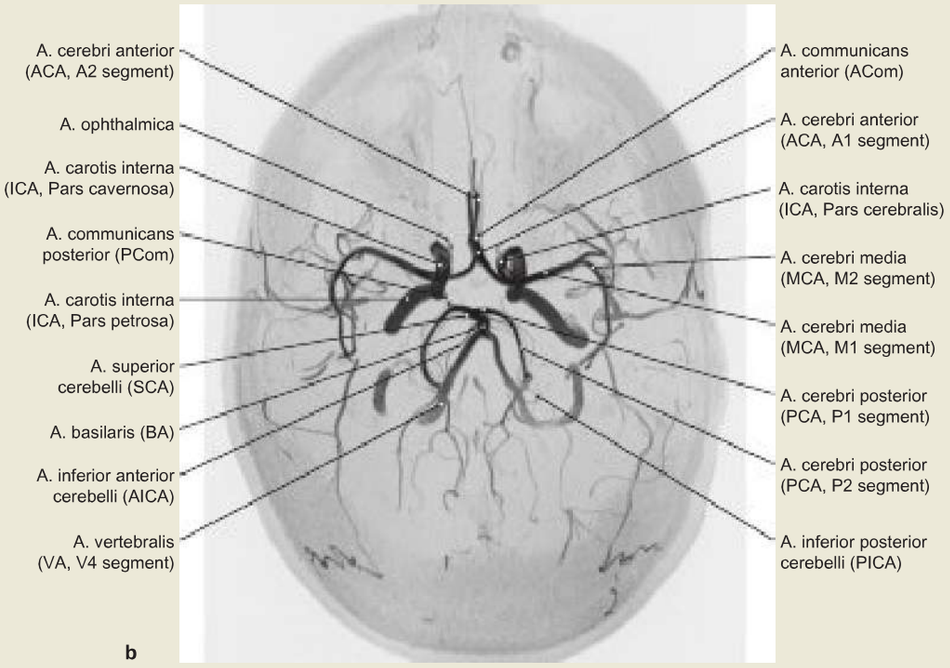

Fig. 12.54a and b MR angiography of the arteries supplying the brain; a frontal view, **b** caudal view. [T786]

Sinus cavernosus

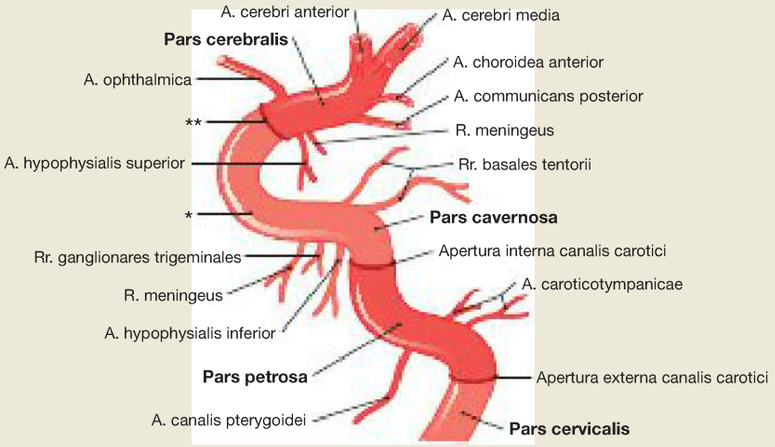

Fig 12.55 Segments of the A. carotis interna. [L126]
The A. carotis interna forms an S-shaped loop system (Siphon caroticum) and can be divided into four segments: Pars cervicalis, Pars petrosa, Pars cavernosa and Pars cerebralis. Along its course in the region of the cranial base, the A. carotis interna passes through the Apertura externa canalis carotici, the Apertura interna canalis carotici and the Dura mater. In the Pars cervicalis no vessels branch off. The first larger branch is the A. ophthalmica. The A. carotis interna ends with its bifurcation into the A. cerebri anterior and the A. cerebri media. It supplies the pituitary gland, the trigeminal ganglion, the eye, and the anterior parts of the telencephalon and of the diencephalon. A frequent variation of the vascular pattern is the outlet of the A. canalis pterygoidei from the Pars petrosa of the A. carotis interna. In most cases, the A. canalis pterygoidei originates from the Pars sphenopalatina of the A. maxillaris. Based on: Tillmann B.N. Atlas der Anatomie. 2. Aufl. Springer, 2010

* carotid siphon
** passage through the Dura mater cranialis in the area of the Diaphragma sellae

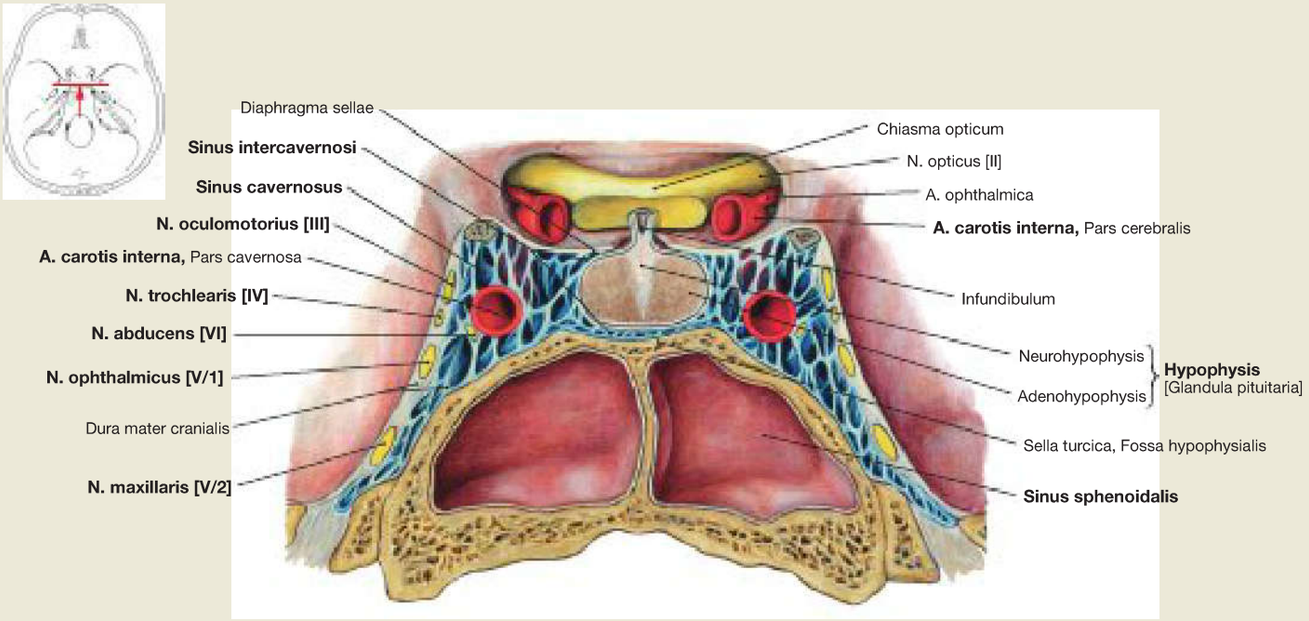

Fig. 12.56 A. carotis interna, Pars cavernosa; frontal section; posterior view.
The pituitary gland (hypophysis) is surrounded by the right and left Sinus cavernosus, which communicate via the Sinus intercavernosi. The Pars cavernosa of the A. carotis interna and the laterally adjacent N. abducens [VI] run through the centre of the Sinus cavernosus; the N. oculomotorius [III], N. trochlearis [IV], N. ophthalmicus [V/1], and N. maxillaris [V/2] are located in its wall. The Sinus sphenoidalis is located beneath the Sella turcica which harbours the pituitary gland.

Clinical Remarks

Arteriosclerotic changes in vascular walls are relatively common findings at the outlet of the A. carotis interna from the A. carotis communis and in the Pars cavernosa.
More than 90% of all **cerebral aneurysms** occur in the basal cerebral vessels of the Circulus arteriosus cerebri (WILLISII). Most often, the A. communicans anterior (up to 40%) and the A. carotis interna are affected. During the surgical removal of an aneurysm in the A. communicans anterior, attention must be paid to the A. striata medialis distalis (HEUBNER's recurrent artery, A. centralis longa). This artery is a branch which runs anti-parallel (recurrent) to the initial segment of the A. cerebri anterior (→ Fig. 12.65). In addition, also the other branches of the A. communicans anterior should be spared, as otherwise postoperative disorders of the memory function could occur (syndrome of the A. communicans anterior).

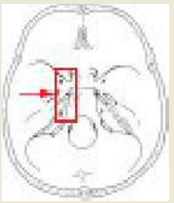

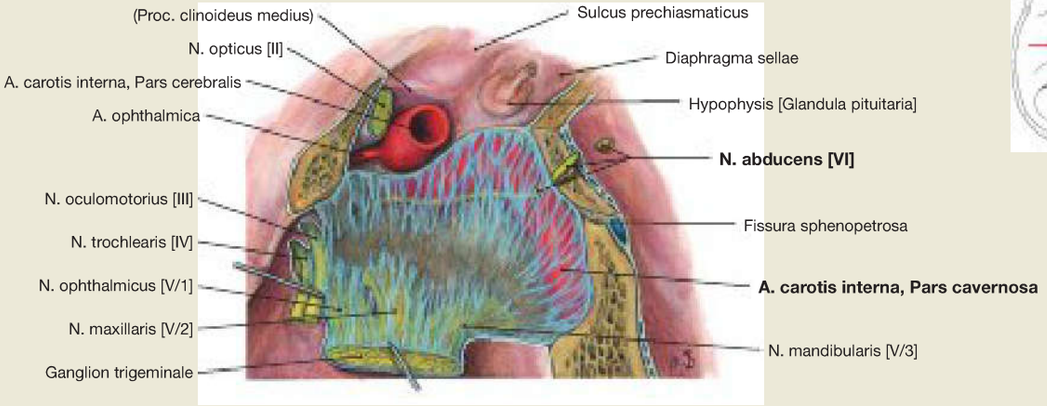

Fig. 12.57 A. carotis interna, Pars cavernosa, and Sinus cavernosus, on the left side; lateral view; after removal of the lateral wall-forming part of the dura; the Ganglion trigeminale was folded back laterally.

In this view the course of the Pars cavernosa of the A. carotis interna and of the N. abducens [VI] in the Sinus cavernosus are visible.

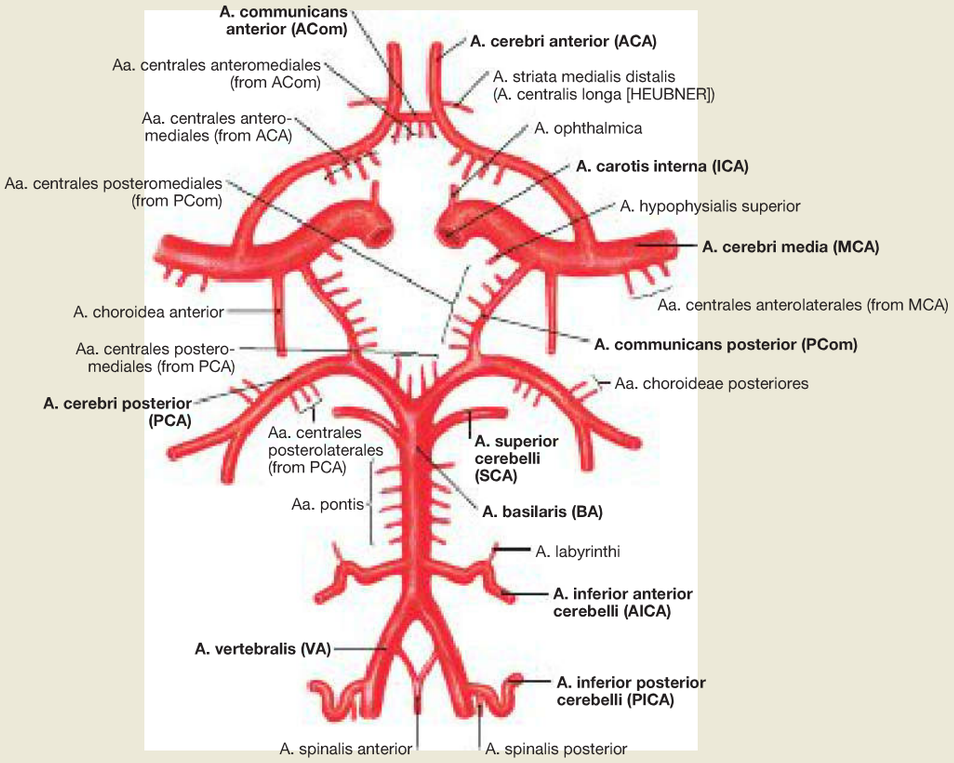

Fig. 12.58 Arterial circle of the brain, Circulus arteriosus cerebri (WILLISII); superior view.
On both sides the Aa. communicantes posteriores connect the Aa. cerebri posteriores to the Partes cerebrales of the Aa. carotides internae.

In front, the A. communicans anterior connects both Aa. cerebri anteriores. In this way, a closed arterial ring (circle) is formed, which serves the communication of the Aa. carotides internae with each other and with the vertebral arterial system.

Clinical Remarks

Most cerebral aneurysms are caused by congenital defects of the Tunica media in the vascular wall near the outlet of the branches. Often, aneurysms are associated with other diseases, such as polycystic kidneys or fibromuscular dysplasia. Cerebral aneurysms are usually asymptomatic. However, the pressure of the aneurysmal sac can lead to a cranial nerve compression.

Cerebral aneurysms have a tendency to **rupture** and are the most frequent cause of subarachnoid bleeding (haemorrhage). In the case of a rupture, sudden severe headaches occur, combined with vomiting and impaired consciousness.

Arteries of the Brain

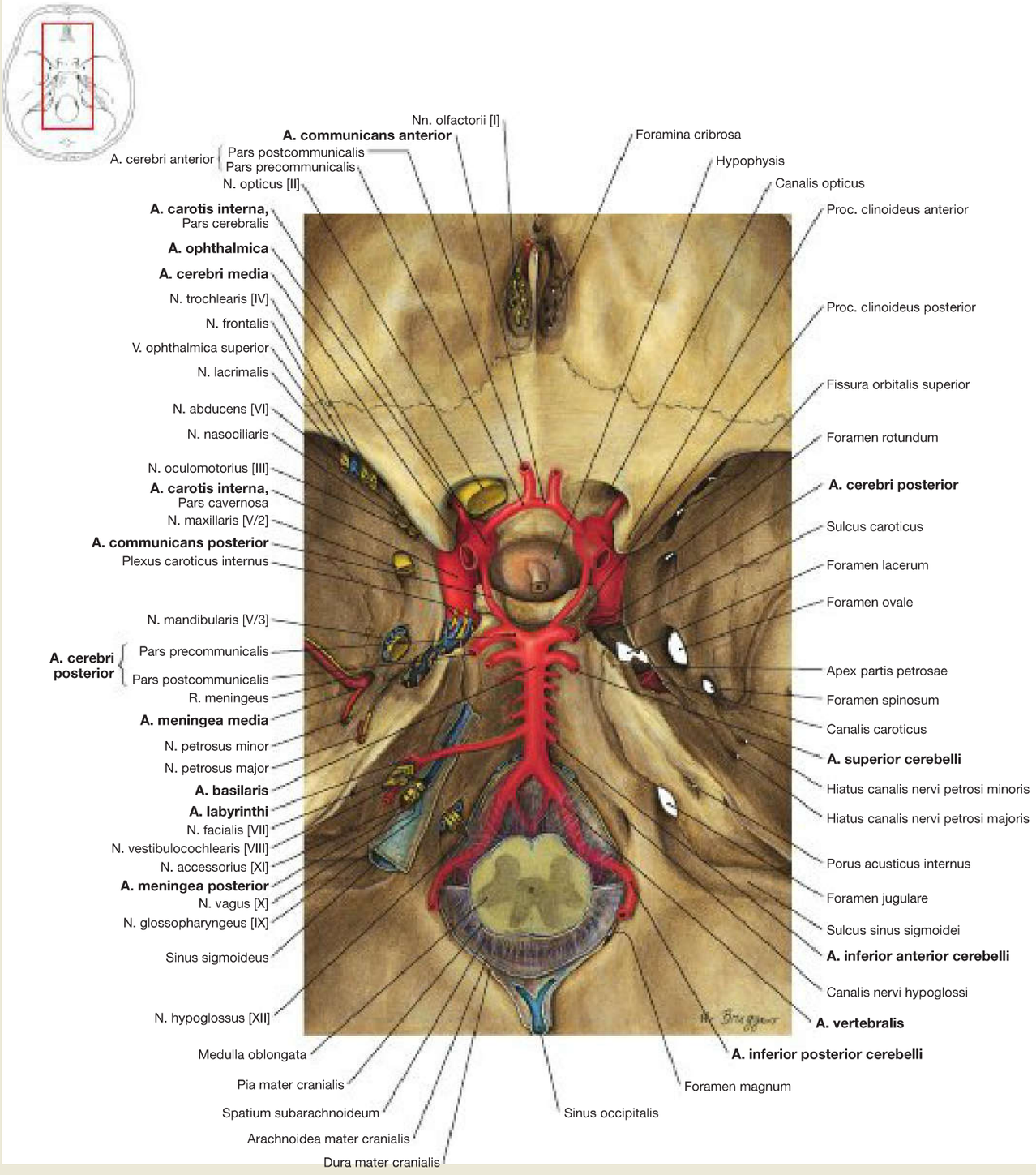

Fig. 12.59 Passageways of vessels and nerves through the internal surface of the cranial base, Basis cranii interna, and arterial circle of the brain, Circulus arteriosus cerebri (WILLISII); superior view.
The Circulus arteriosus cerebri projects from above around the Fossa hypophysialis. The A. ophthalmica originates from the **A. carotis interna** at the Canalis nervi optici and, together with the N. opticus [II], passes through this bony canal into the orbita. The **A. basilaris** runs on top of the clivus. The **A. inferior anterior cerebelli** branches off the A. basilaris and bypasses the Porus acusticus internus or enters it in a loop-shaped form, and then provides the **A. labyrinthi**.
For an overview of the passageways through the cranial base → Fig. 8.23 and → Fig. 8.24.

Clinical Remarks

The blood vessels of the brain show relatively great variations in their pattern, which correspond to the variability of the supplied areas. Disorders of the blood flow in these **'atypical' vessels** can therefore lead to stroke symptoms that cannot be explained in terms of the normal 'textbook' anatomy. Not without reason do we say: 'The exception proves the rule.'

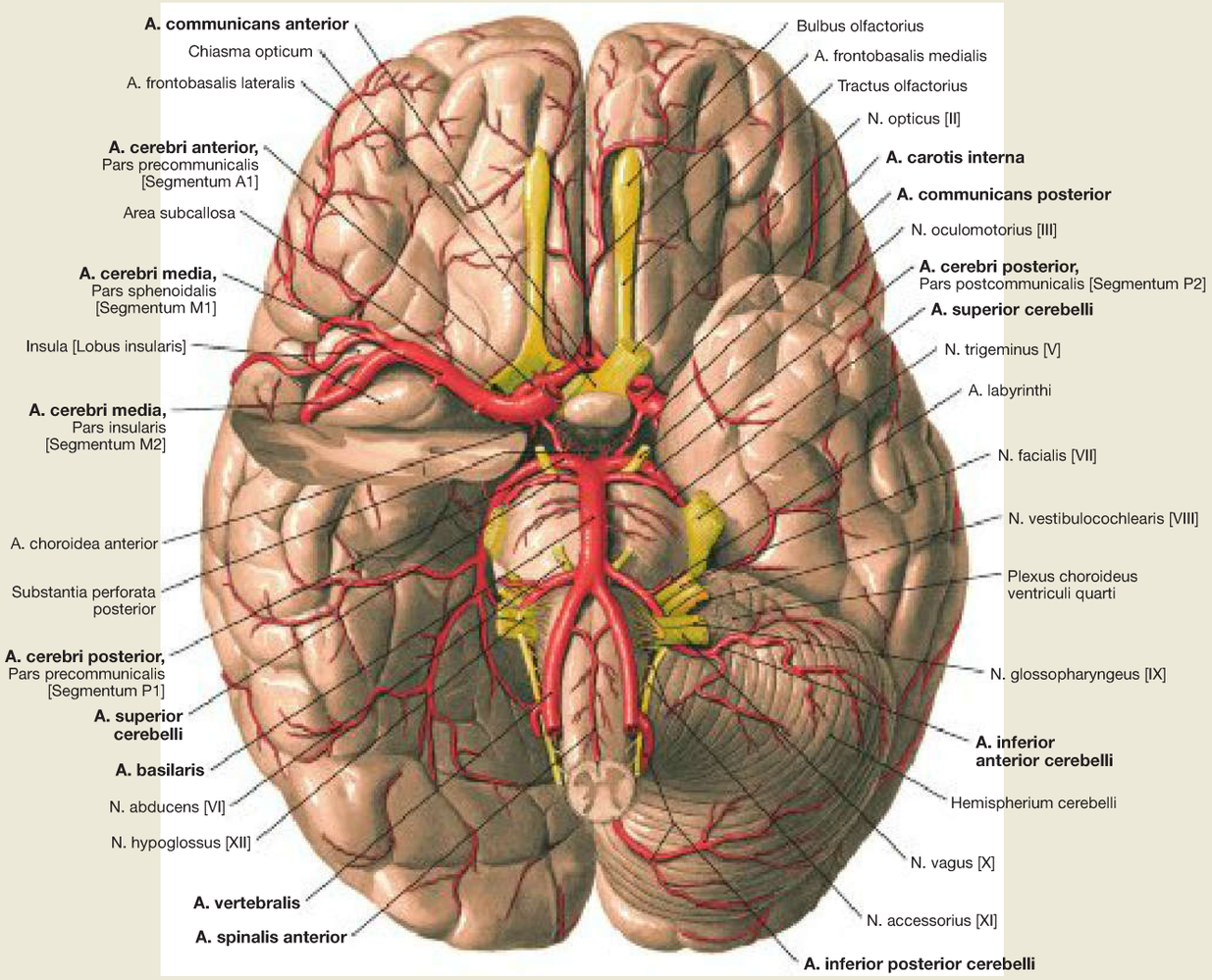

Fig. 12.60 Arteries of the brain; inferior view.
The figure shows the location of the arteries at the cranial base. The Aa. vertebrales converge to form the A. basilaris, which gives rise to the Aa. cerebri posteriores, as well as to the blood vessels supplying the brain stem, the cerebellum and the inner ear **(vertebral arterial system).** Via small connecting arteries (Aa. communicantes posteriores) the Aa. cerebri posteriores are linked with the two Aa. carotides internae. Each of the latter contributes an A. cerebri media and an A. cerebri anterior, which together supply the largest part of the hemispheres with blood **(carotid arterial system).** Both Aa. cerebri anteriores are connected via the A. communicans anterior. Clinically, the Aa. cerebri anterior, media, and posterior are divided into segments (→ Table, on p. 296). Some segments are visible in this figure.

Clinical Remarks

One of the most frequent types of cerebral circulatory disorders (ischemia) in the vertebral arterial system is the so-called **WALLENBERG's syndrome** (dorsal-lateral Medulla oblongata syndrome). In this case, an occlusion or impaired blood flow in the A. inferior posterior cerebelli (PICA = posterior inferior cerebellar artery) causes a broad range of symptoms, including nystagmus, equilibrium disorder, dizziness (Nuclei vestibulares, inferior olive), ipsilateral hemiataxia (Pedunculus cerebellaris inferior, cerebellum), contralateral dissociated sensations (Nuclei gracilis et cuneatus, Tractus spinothalamicus), swallowing difficulties, singultus (volley of hiccups) and dysphonia (Nucleus ambiguus), HORNER's syndrome and rapid pulses (central sympathetic system and cardiovascular centre in the rostral-ventrolateral Medulla oblongata), as well as respiratory disorders (respiratory centre in the ventrolateral Medulla oblongata with pre-BÖTZINGER complex).

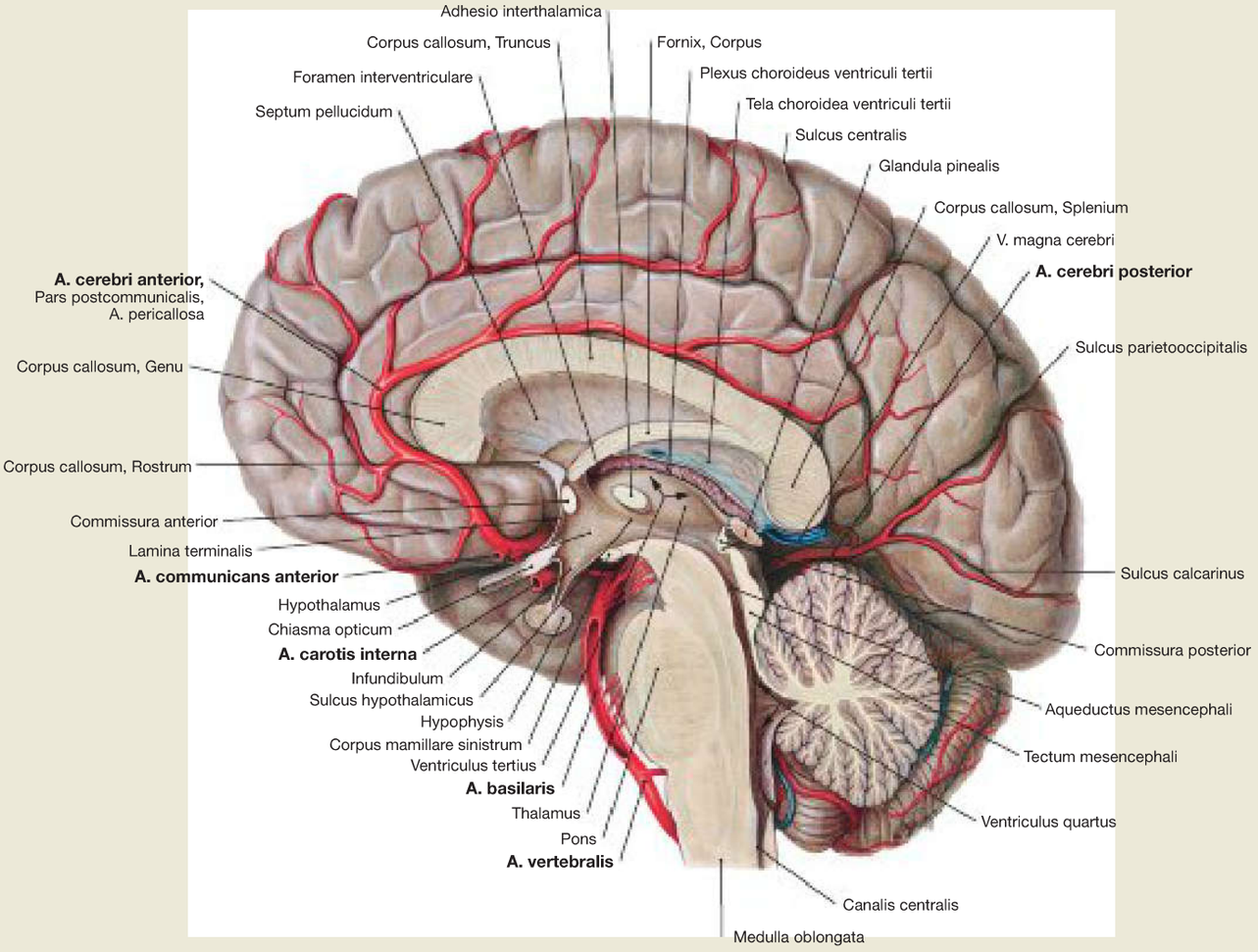

Fig. 12.61 Medial surface of the brain, Facies medialis hemispherii cerebri, Diencephalon, and brain stem, Truncus encephali; staggered median section; view from the left side.
After providing the A. communicans anterior, the **A. cerebri anterior** passes with its Pars postcommunicalis (A. pericallosa) around the Rostrum and the Genu of the Corpus callosum, and continues along the surface of the Corpus callosum. Its branches extend to the Sulcus parietooccipitalis. The A. cerebri anterior supplies the medial surface of the frontal and parietal lobes, as well as the rim of the hemisphere and a smaller area alongside thereof at the cerebral convexity (→ p. 308).
The **A. cerebri posterior** flows to the occipital lobe, the basal part of the temporal lobe, the lower part of the striatum (not visible), and to the thalamus.

Clinical Remarks

In most cases a **stroke** is caused by an acute circulation disorder in a smaller or larger brain area supplied by the affected cerebral artery (ischemia, 80–90 % of the cases). Acute bleeding in the brain (intracerebral haemorrhage) accounts for nearly 10 % of all strokes, followed by subarachnoid haemorrhages (approx. 3 %). The first diagnostic measure to confirm or exclude a haemorrhage, ischemia or a totally different cause of the neurological symptoms, is **CT of the brain.** Its great advantage compared to the MRI is the short duration. With modern equipment, CT scans of the brain can now be obtained in less than half a minute. If the ischemia is caused by a thrombus, a pharmacological therapy **(thrombolysis)** can be tried. The outcome is largely determined by the time interval since the stroke ('time is brain'). Therefore many clinical centres have specialised stroke departments (stroke units). For patients with intracerebral haemorrhage, however, a thrombolysis is contraindicated. The rapid diagnostic evaluation therefore plays a crucial role in stroke treatment.
In the foetal period, all three cerebral arteries are fed by the ipsilateral A. carotis interna. Once the connection of the **A. cerebri posterior** to the A. vertebrobasilaris arterial system is established, the original (primary) vessel atrophies and becomes the predominantly thin A. communicans posterior. However, in 20% of the cases this does not happen, so that in adults (just like in the foetus) an A. cerebri posterior persists which is fed by the A. cerebri posterior.

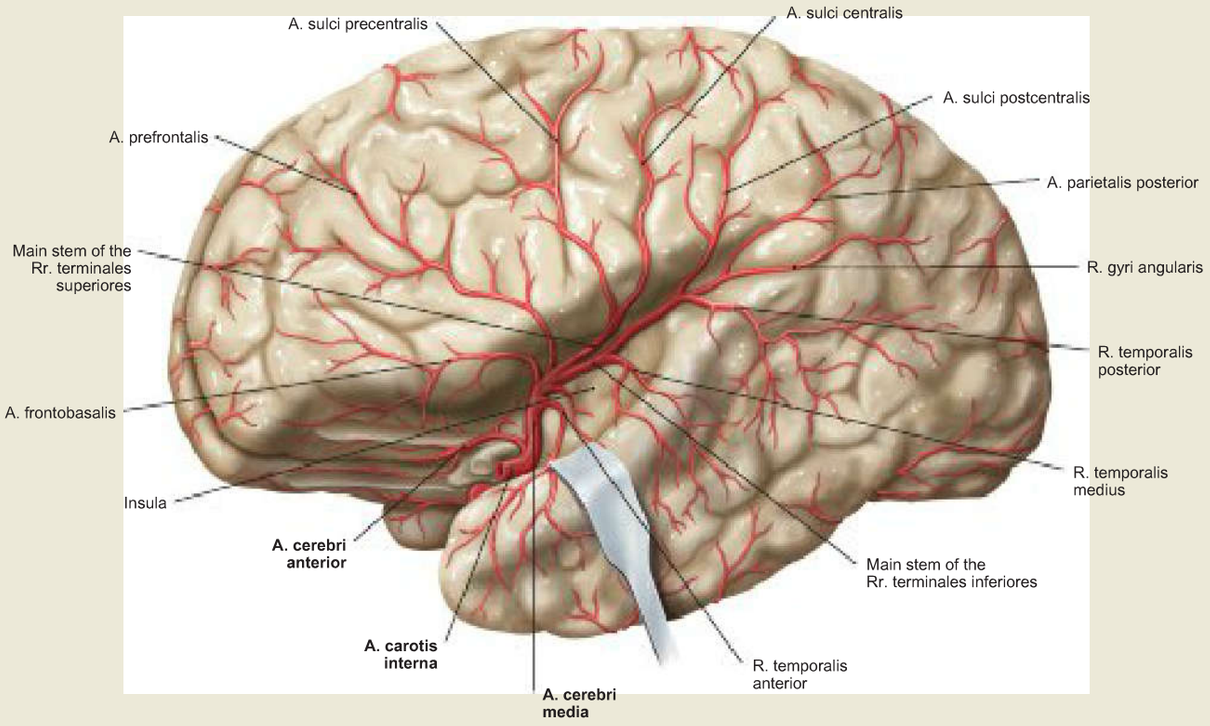

Fig. 12.62 A. cerebri media on the Facies lateralis cerebri; view from the left side. [L127]

The **A. cerebri media** supplies the major part of the lateral surface of the hemisphere, the insula and, with central branches, also the Capsula interna (parts of the Crus anterius, Genu) as well as the basal ganglia.

Clinical Remarks

Occlusions in the bifurcation area of the A. cerebri media due to arteriosclerosis or embolism result in **cerebral infarction** (stroke, apoplexy) with severe deficits. These include a contralateral, predominantly brachiofacial hemiplegia with hypaesthesia (circumscribed or general decrease of touch and pressure sensations of the skin). If the dominant hemisphere is affected, this results in aphasia (speech disorder), agraphia (inability to write words and text although the necessary mobility of the hand, as well as the intellectual ability is given) and alexia (inability to read). In patients with high blood pressure (hypertension), changes in the wall of cerebral vessels can cause a vascular rupture and bleeding into the cerebral parenchyma (possibly leading to massive bleeding). The basal ganglia in particular are commonly affected by this.

Arteriosclerosis-induced changes in the wall of vessels are often found in the A. carotis interna. Small thrombi emerging of these plaques can cause an occlusion of the A. centralis retinae via the A. ophthalmica, and thus lead to a sudden painless unilateral blindness. If the thrombus dissolves within a short time one speaks of **amaurosis fugax** (short-term blindness). As a frequent sign of cerebral circulatory disorders, it can be a red flag for an impending stroke.

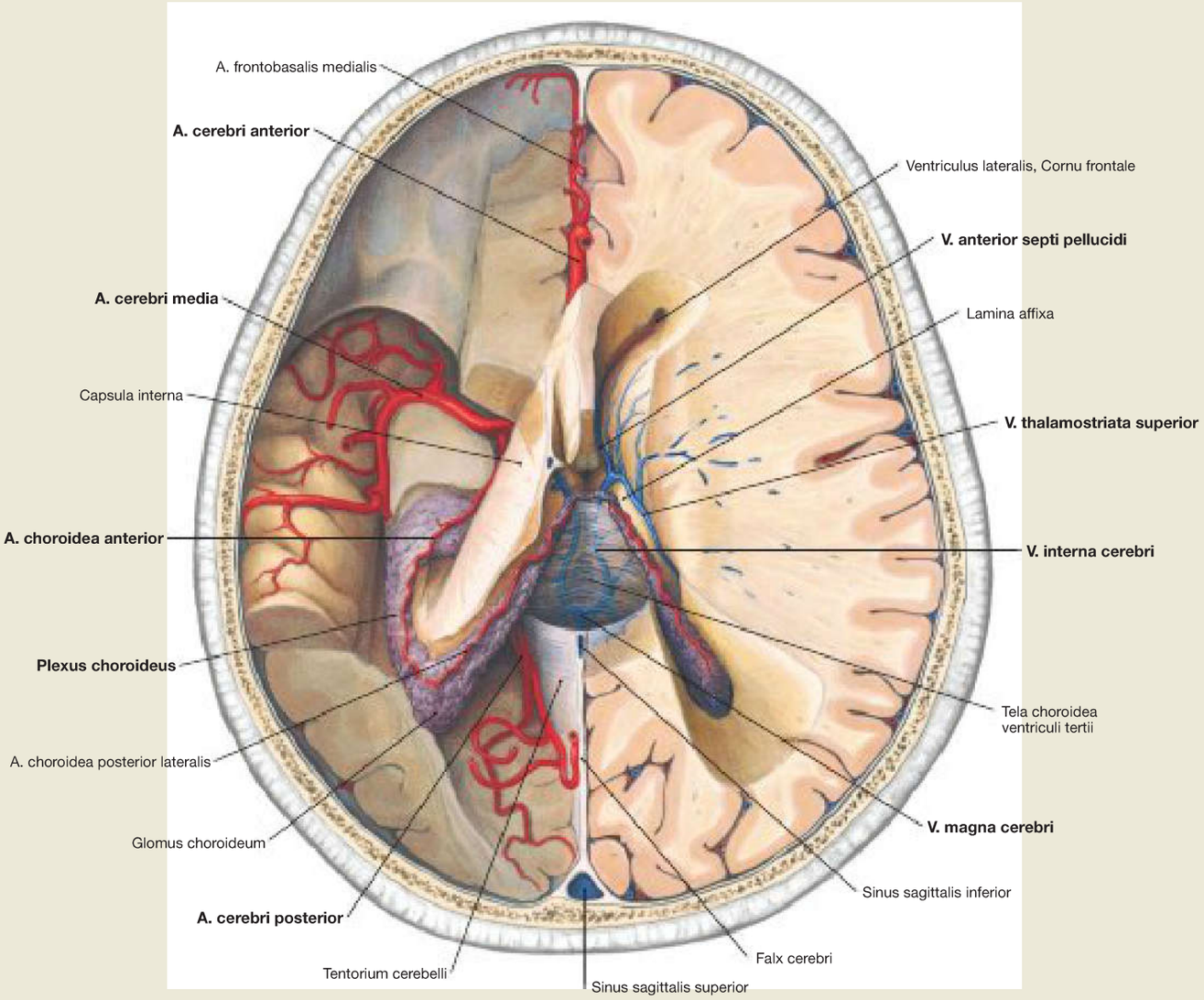

Fig. 12.63 Branching of the A. cerebri media in the insular region and the outer cerebral surface, choroid arteries and internal cerebral veins; after removal of large areas of the brain with exposure of the Fossa lateralis (left) and the lateral ventricles.

The **A. cerebri media** passes laterally into the Fossa lateralis and divides into four segments (→ Fig. 12.60):

- **Pars sphenoidalis** (M1), where the A. choroidea anterior branches off (→ Table)
- **Pars insularis** with short branches to the insular cortex (M2)
- **Pars opercularis** for the cortex of the temporal lobe (A. frontobasalis lateralis and Aa. temporales; M3)
- **Pars terminalis** (M4) with the Rr. terminales inferiores and superiores for cortical areas of the Sulcus centralis and parietal lobe

In the lateral ventricles, the **A. choroidea anterior** (from anterior below; originating from the A. cerebri interna) and the **Aa. choroideae posteriores laterales** (from dorsal above; originating from the A. cerebri posterior) form a plexus of vessels. In addition, on the right side, the inner venous system can be seen in the vicinity of the Tela choroidea of the third ventricle.

Choroid Blood Vessels

Vessel	Origin	Tributary
A. choroidea anterior	A. carotis interna	• Tractus opticus • Capsula interna (Crus posterius) • anterior hippocampus • Crura cerebri, Tegmentum mesencephali • Plexus choroideus
Aa. choroideae posteriores	A. cerebri posterior	• Corpus geniculatum laterale • hippocampus and fornix • thalamus (posterior parts) • dorsal mesencephalon • Glandula pinealis

Clinical Remarks

The **anterior choroid artery syndrome** is caused by circulatory disorders in the area of the A. choroidea anterior and is associated with a triad of symptoms including motor, sensory and visual dysfunctions: hemiplegia (failure of motor fibres in the Crura cerebri), hemi-sensory disorders (failure of the Crus posterius of the Capsula interna) and hemianopsia (failure of the Tractus opticus and parts of the Radiatio optica).

Circulatory disorders of the A. cerebri posterior lead to visual failures, but can also be associated with temporary deficits of memory function (amnesia), since parts of the hippocampus formation are also supplied with blood from here (→ Fig. 12.85).

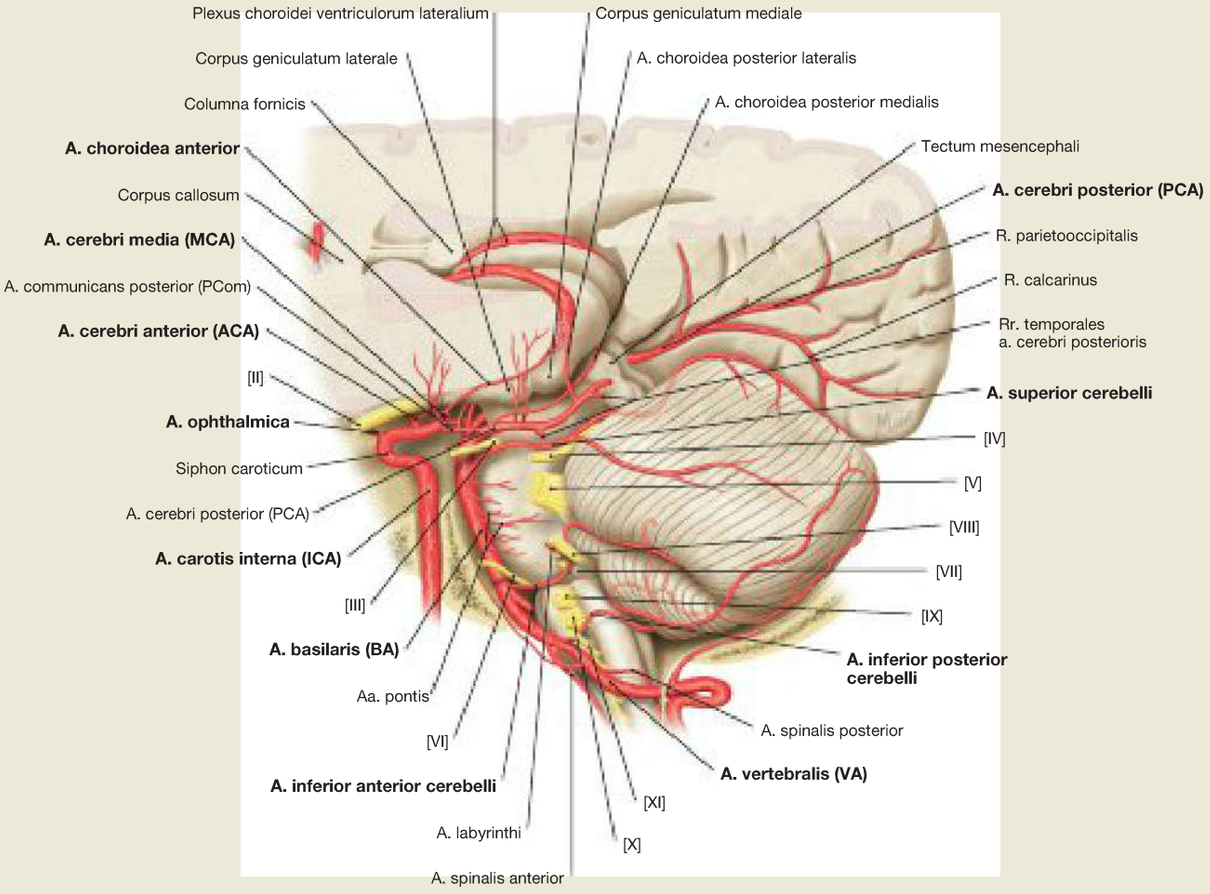

Fig. 12.64 Arteries of the posterior cranial fossa: A. vertebralis, A. basilaris and its branches; view from the left side. [L127]

The posterior parts of the cortex, cerebellum and of the Truncus encephali are mainly supplied via blood vessels of the vertebrobasilar arterial system. The **A. vertebralis** branches off the A. subclavia at the level of the first thoracic vertebra and can be divided into four segments (→ Table, on p. 307):

- **Pars prevertebralis** (V1), from the outlet of the A. subclavia (at the level of the first thoracic vertebra) up to the Foramen transversarium of the fourth cervical vertebra
- **Pars transversaria** (V2), within the Foramina transversaria of the sixth to second cervical vertebrae
- **Pars atlantica** (V3), from the transition to the atlas and arch of the atlas to the passage through the Foramen magnum
- **Pars intracranialis** (V4), the intracranial part up to the origin of the A. basilaris

Along its course, the A. vertebralis sends a number of branches to the neck muscles, the meninges, the cerebellum and spinal cord. The two most important branches are the **A. inferior posterior cerebelli** (which often gives rise to an A. spinalis posterior) and the **A. spinalis anterior.** Both Aa. vertebrales unite at the level of the pontomedullary transition to the unpaired, centrally located **A. basilaris** (→ Fig. 12.60). It runs in the middle of the pons and supplies large parts of the brain stem and the cerebellum with its branches. Branches of the A. basilaris are the **A. inferior anterior cerebelli** (giving rise to the A. labyrinthi which supplies the inner ear), the **Aa. pontis** and the **A. superior cerebelli.** At the approximate level of the mesencephalon (Cisterna interpeduncularis) the A. basilaris bifurcates into the Aa. cerebri posteriores. The latter supply large parts of the mesencephalon and occipitotemporal parts of the hemispheres. Branches of the **A. cerebri posterior** are the **Aa. centrales posteromediales,** the **Aa. centrales posteromediales** (→ Table, on p. 307) and the **Aa. choroideae posteriores** (→ Table, on p. 304).

Clinical Remarks

The A. vertebralis can be assessed in the so-called vertebral artery triangle (→ Fig. 2.77) between the M. obliquus capitis superior, the M. obliquus capitis inferior and the M. rectus capitis posterior major; when the head is bent forward, the blood flow is controlled with a **DOPPLER ultrasound examination**.

In the case of a stroke, very unusual symptoms can develop due to the blood supply to certain regions. So it is possible that, for example, **circulatory disorders of the Aa. pontis** lead to failures of motor fibre tracts in ventral parts of the pons, which may be associated with an acute paraplegia. Since the dorsal parts of the pons are supplied by branches of the A. superior cerebelli, important regions of awareness such as the Formatio reticularis and also the eye movements remain intact. Despite their paraplegia, these so-called **locked-in syndrome** are fully conscious without cognitive impairment. But they can only communicate with eye movements and blinking.

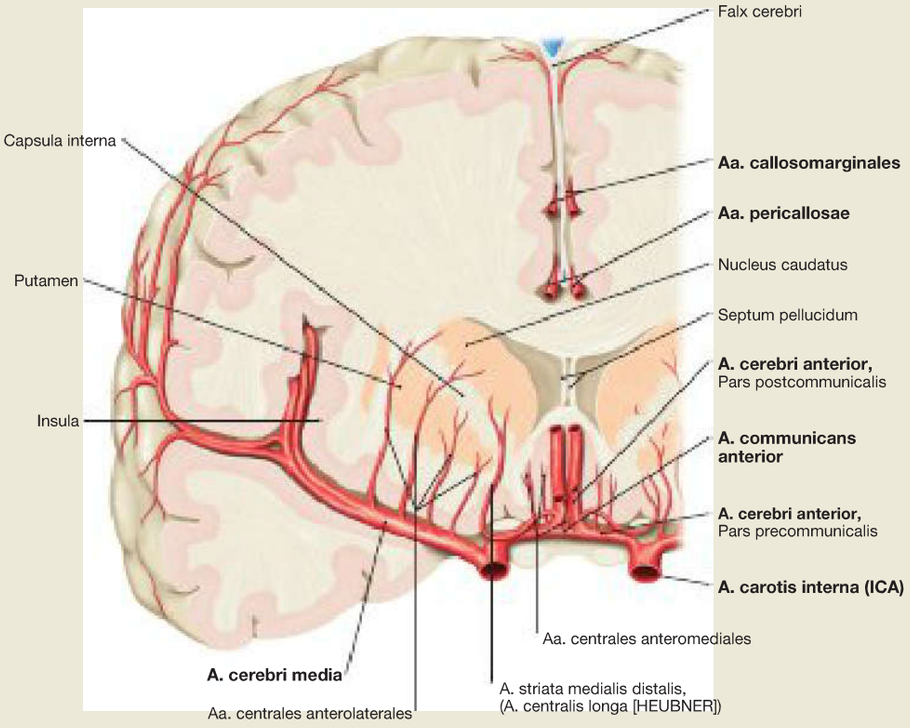

Fig. 12.65 Central arteries; frontal section at the level of the bifurcation of the A. carotis interna. [L127]
The so-called central arteries provide the anterior inner part of the brain with the subcortical nuclei, the Corpus medullare including the Capsula interna and the diencephalon. These penetrating vessels form vascular groups which enter the brain at the Basis cerebri, and thereby perforate the tissue (Substantia perforata; → Table). They supply:

- as Aa. centrales anteromediales the anterior-medial structures, such as the Nucleus caudatus
- as Aa. centrales anterolaterales (= Aa. lenticulostriatae) the anterior-lateral structures such as the Globus pallidus, and the Putamen
- as Aa. centrales posteromediales and Aa. centrales posterolaterales the posterior structures such as the thalamus, and the hypothalamus

In addition, interior parts of the brain are supplied by the choroid blood vessels (→ Table, on p. 304). The choroid blood vessels of the lateral ventricles are connected via the Plexus choroideus and form a vascular corona or plexus (→ Fig. 12.63), which connects the tributaries of the A. carotis interna and of the A. vertebralis/basilaris.

Clinical Remarks

Since the **Aa. centrales anterolaterales** branch off the A. cerebri media almost in a right angle, this part is particularly prone to turbulent blood flow and to secondary arteriosclerotic changes. In patients with high blood pressure (hypertension), **occlusions** can therefore frequently be found at these bifurcations. Occlusions as well as **haemorrhages** from these blood vessels can lead to tissue necrosis in the nuclear region of the telencephalon (basal ganglia) and the Capsula interna with resulting (contralateral) hemiplegia. Depending on their location, **lesions of nuclei in the telencephalon** can cause severe hyperkinetic or hypokinetic disorders (dystonia).

Blood Supply of the Capsula interna

Capsula interna	Arteries	Origin
Crus anterius	Aa. centrales anteromediales	A. cerebri anterior
	A. striata medialis distalis (A. centralis longa; A. recurrens HEUBNER)	A. cerebri anterior
	Aa. centrales anterolaterales	A. cerebri media
Genu	Aa. centrales anterolaterales	A. cerebri media
Crus posterius	Aa. centrales anterolaterales	A. cerebri media
	A. choroidea anterior	A. carotis interna

Topography of the Arteries Supplying the Brain

Artery	Topography and Special Features
A. carotis interna (ICA, internal carotid artery)	• four topographic-anatomical defined segments: Pars cervicalis, Pars petrosa, Pars cavernosa, Pars cerebralis • exiting the Sinus cavernosus lateral of the Chiasma opticum
A. ophthalmica	• first major vessel of the A. carotis interna • originates below the N. opticus and passes through the Canalis nervi optici into the orbit • anastomosis (A. dorsalis nasi) with the A. facialis (A. angularis)
A. choroidea anterior	• branch of the A. carotis interna • passes along the Tractus opticus to the inferior horn of the lateral ventricle
A. cerebri anterior (ACA, anterior cerebral artery)	• lateral to the Chiasma opticum it runs rostrally • enters the Fissura longitudinalis cerebri • runs above the Corpus callosum occipitally
A. communicans anterior (ACom, anterior communicating artery)	• between the Aa. cerebri anteriores • located in front of the Chiasma opticum
A. cerebri media (MCA, middle cerebral artery)	• passes around the Polus temporalis to the Fossa lateralis cerebri • bifurcation via the insula, leaving the Sulcus lateralis, course of the branches on the lateral surface of the telencephalon
A. vertebralis (VA, vertebral artery)	• four topographic-anatomical defined segments: Pars prevertebralis, Pars transversaria, Pars atlantis, Pars intracranialis • passes ventrally and forms the A. basilaris (at the lower rim of the Pons)
A. inferior posterior cerebelli (PICA, posterior inferior cerebellar artery)	• flows out of the A. vertebralis at the level of the olive (may be absent) • loop at the level of the cerebellar tonsils (radiological feature) • enters the Vallecula cerebelli above the vermis
A. basilaris (BA, basilar artery)	• course in the Sulcus basilaris of the Pons • bifurcation into the Aa. cerebri posteriores (at the level of the mesencephalon)
A. inferior anterior cerebelli (AICA, anterior inferior cerebellar artery)	• flows out of the lower segment of the A. basilaris, ventrally of the cranial nerves VI, VII, VIII • runs to the Meatus acusticus internus, provides the A. labyrinthi (normally) and from there passes to the underside of the cerebellum
A. superior cerebelli (SCA, superior cerebellar artery)	• flows caudally out of the N. oculomotorius [III] from the A. basilaris • runs below the Tentorium cerebelli • passes posteriorly to the surface of the cerebellum
A. cerebri posterior (PCA, posterior cerebral artery)	• arises cranially of the N. oculomotorius [III] • runs above the Tentorium cerebelli • passes posteriorly to the occipital-basal surface of the telencephalon
A. communicans posterior (PCom, posterior communicating artery)	• connects the A. carotis interna and the A. cerebri posterior • runs laterally of the pituitary gland and the Corpora mamillaria

Central Blood Vessels

Vessel/Vascular Group	Passage	Origin	Supply Area (e.g.)
Aa. centrales anteromediales	Substantia perforata anterior	• A. cerebri anterior • A. communicans anterior	• Caput nuclei caudati • Globus pallidus • Commissura anterior • Capsula interna
Aa. centrales anterolaterales (Aa. lenticulostriatae)	Substantia perforata anterior	• A. cerebri media	• Nucleus caudatus • Putamen • Globus pallidus • Capsula interna (medial vessels)
Aa. centrales posteromediales	Substantia perforata posterior	• A. cerebri posterior • A. communicans posterior	• Thalamus • Hypothalamus • Globus pallidus
Aa. centrales posterolaterales	Substantia perforata posterior	• A. cerebri posterior (Pars postcommunicalis)	• Thalamus • Corpus geniculatum mediale • Colliculi • Glandula pinealis

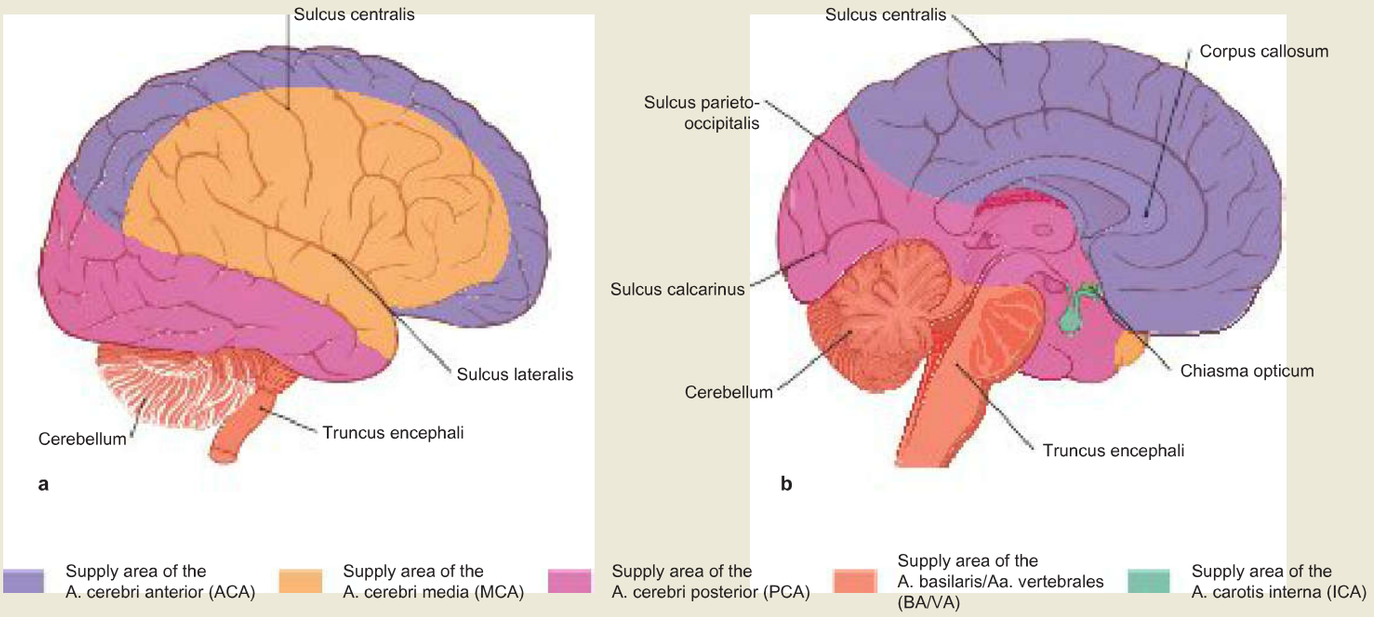

Fig. 12.66a and b Areas supplied by the cerebral arteries (telencephalon); a lateral view from outside, **b** medial view of a brain in the sagittal plane. [L126]
The **A. cerebri anterior** supplies the frontal and parietal areas of the cerebral cortex approximately 1 cm beyond the hemispherial rim (→Table, on p. 307). The **A. cerebri posterior** provides blood to the occipital pole and the lower margin of the temporal lobe. The outer surface of the remaining cortical area is supplied by the **A. cerebri media**. The blood supply in the area of the Gyri precentralis and postcentralis is fed in part by the **A. cerebri anterior** and in part by the A. cerebri media. In the medial view, the A. cerebri anterior supplies the medial surface of the frontal and parietal lobes beyond the hemispheral rim up to the Sulcus parieto-occipitalis. The occipital lobe and the base of the temporal lobe are supplied by the **A. cerebri posterior**. The blood supply of the cerebellum and brain stem is provided by the vertebrobasilar arterial system.

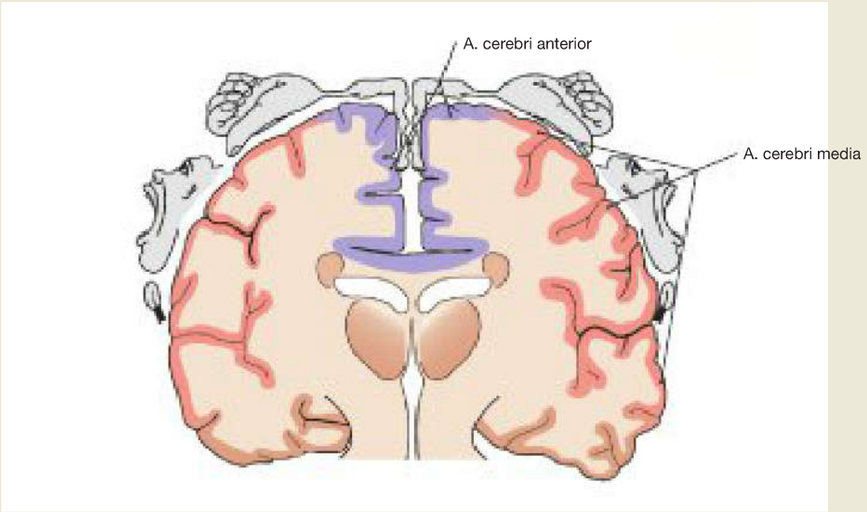

Fig. 12.67 Arteries in the region of the Gyrus precentralis and their projection onto the homunculus of the primary motor cortex. [L238]
The **A. cerebri anterior** supplies the cortex of the Gyrus precentralis approximately 1 cm beyond the hemispheral rim with blood; this corresponds to the cortical representation areas of the lower limb, the pelvis and the rib cage. The areas supplied by the **A. cerebri media** correspond to the cortical representation areas of the upper limb and the entire head.

Clinical Remarks

Due to the blood supply in the region of the Gyrus precentralis, circulatory disorders of the A. cerebri anterior are associated predominantly with **leg paralysis** and circulatory disorders of the A. cerebri media with **brachiofacial paralysis**. The patient's clinical picture (leg or brachiofacial paralysis) therefore allows conclusions about the affected vessel.

Stroke or haemorrhages in the area of the Capsula interna can usually be traced back to the A. striata medialis distalis (HEUBNER's recurrent artery, A. centralis longa) as a branch of the A. cerebri anterior (belonging to the Aa. centrales anteromediales), or to the A. lenticulostriata as a branch of the A. cerebri media (belongs to the Aa. centrales anterolaterales) (→ Fig. 12.65).

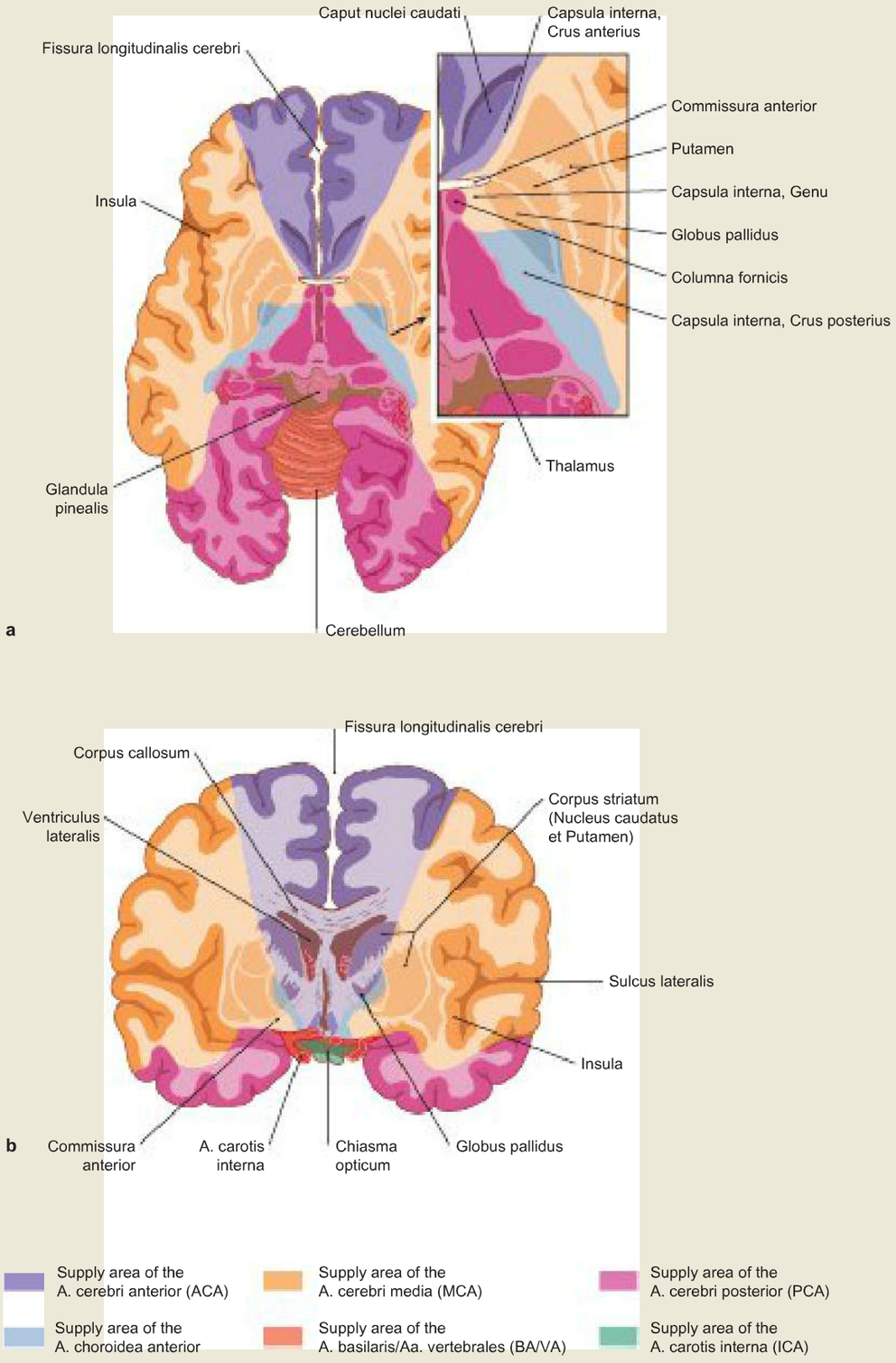

Fig. 12.68a and b Areas supplied by the cerebral arteries (telencephalon); a horizontal section, **b** frontal section. [L126]

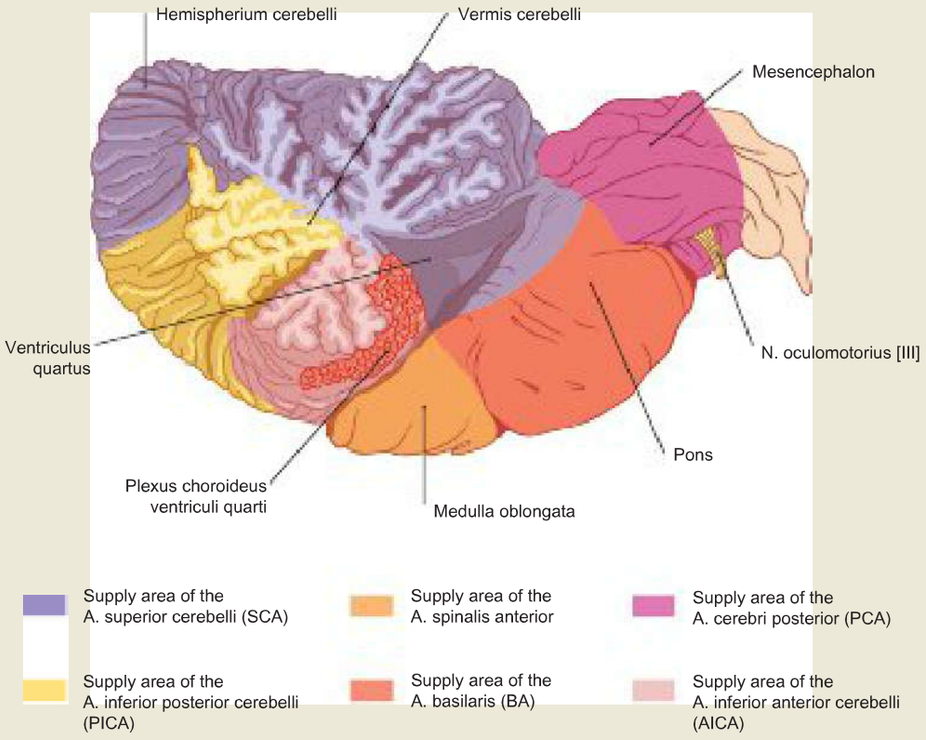

Fig. 12.69 Areas supplied by the cerebral arteries (brain stem and cerebellum); sagittal section. [L126]

Arterial Supply of the Brain Stem		
Parts of the Brain Stem	**Medial Supply Area**	**Lateral Supply Area**
Mesencephalon	• A. cerebri posterior	• A. superior cerebelli • A. cerebri posterior
Pons	• A. basilaris (Aa. pontis)	• A. superior cerebelli • A. inferior anterior cerebelli (very variable)
Medulla oblongata	• Aa. vertebrales • A. spinalis anterior • Aa. spinales posteriores	• A. inferior posterior cerebelli

Arterial Blood Supply of the Cerebellum		
Artery	**Cortical Area**	**Central Area**
A. superior cerebelli (SCA; constant)	upper part of the cerebellum	Nucleus dentatus
A. inferior anterior cerebelli (AICA; variable)	anterior lower part of the cerebellum	
A. inferior posterior cerebelli (PICA; variable)	posterior lower part of the cerebellum	remaining nuclei

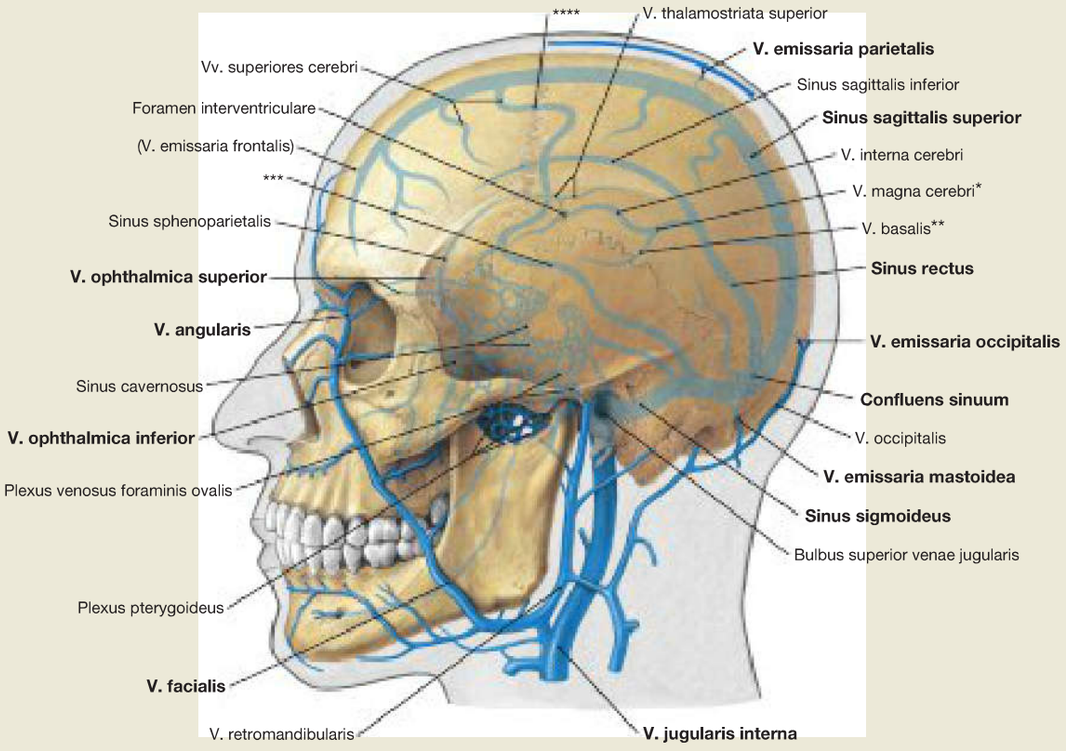

Fig. 12.70 Internal and external veins of the head.
The internal and external veins of the head are connected via numerous anastomoses. These include the Vv. emissariae and ophthalmicae, as well as the Plexus venosi.

* GALEN's vein
** ROSENTHAL's vein
*** LABBÉ's vein or anastomosis
**** TROLARD's vein or anastomosis

Passageways of the Vv. emissariae Through the Skull

V. emissaria	Passageway
V. emissaria parietalis	Foramen parietale
V. emissaria mastoidea	Foramen mastoideum
V. emissaria occipitalis	Opening near the Protuberantia occipitalis externa
V. emissaria condylaris	Canalis condylaris
Plexus venosus canalis nervi hypoglossi	Canalis nervi hypoglossi
Plexus venosus foraminis ovalis	Foramen ovale
Plexus venosus caroticus internus	Canalis caroticus

Clinical Remarks

Due to a lack of venous valves in this area, scalp injuries can lead to a reversed blood flow, and thus favour the **spreading of bacteria via the Vv. emissariae** and via veins located in the diploe (Vv. diploicae, → Fig. 12.71) into the Sinus durae matrix and subsequently the interior of the skull.

Course of the Sinus durae matris

Sinus durae matris	Course and Characteristics
Sinus sagittalis superior	• in the anterior-posterior direction in the Sulcus sinus sagittalis of the cranial bones • bridging veins, draining into the sinus or its lateral lacunae • flows toward the Confluens sinuum
Sinus sagittalis inferior	• along the inferior margin of the falx to the Sinus rectus
Sinus rectus	• originates from the Sinus sagittalis superior and the V. magna cerebri at the intersection of the falx and tentorium
Confluens sinuum	• confluence of the Sinus transversi, rectus, sagittalis superior and occipitalis
Sinus occipitalis	• flows toward the Confluens sinuum
Sinus marginalis	• surrounds the Foramen magnum • connected to the Sinus occipitalis and Plexus venosus vertebralis internus
Sinus transversus	• passes laterally from the Confluens sinuum to the Sinus sigmoideus
Sinus sigmoideus	• S-shaped course via the Pars mastoidea of the Os temporale to the Foramen jugulare and V. jugularis
Sinus cavernosus	• chambered venous space on both sides of the Sella turcica • via the Plexus basilaris connected to the Sinus cavernosus on the opposite side
Sinus petrosi superior et inferior	• along the upper or lower edge of the Pars petrosa ossis temporalis • connection between the Sinus cavernosus and the Sinus sigmoideus

Veins of the Head

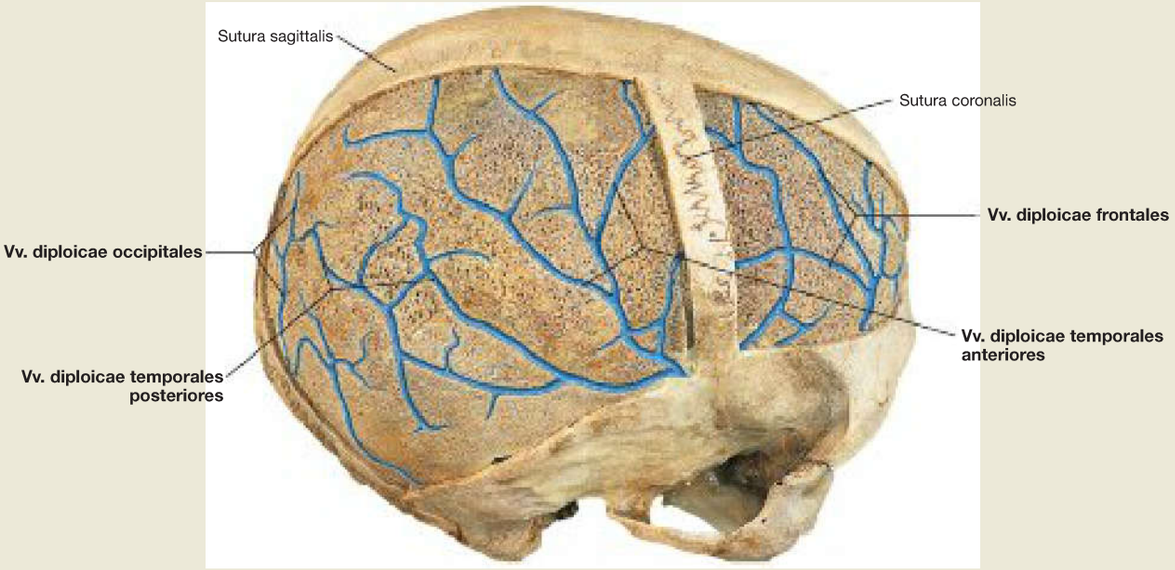

Fig. 12.71 Diploic canals, Canales diploici, and diploic veins, Vv. diploicae, of the Calvaria, right side; oblique superior view; after removal of the outer layer of the Calvaria.

The diploe is interspersed with diploic canals, in which the Vv. diploicae run. They are connected to the Vv. emissariae and the Sinus durae matris.

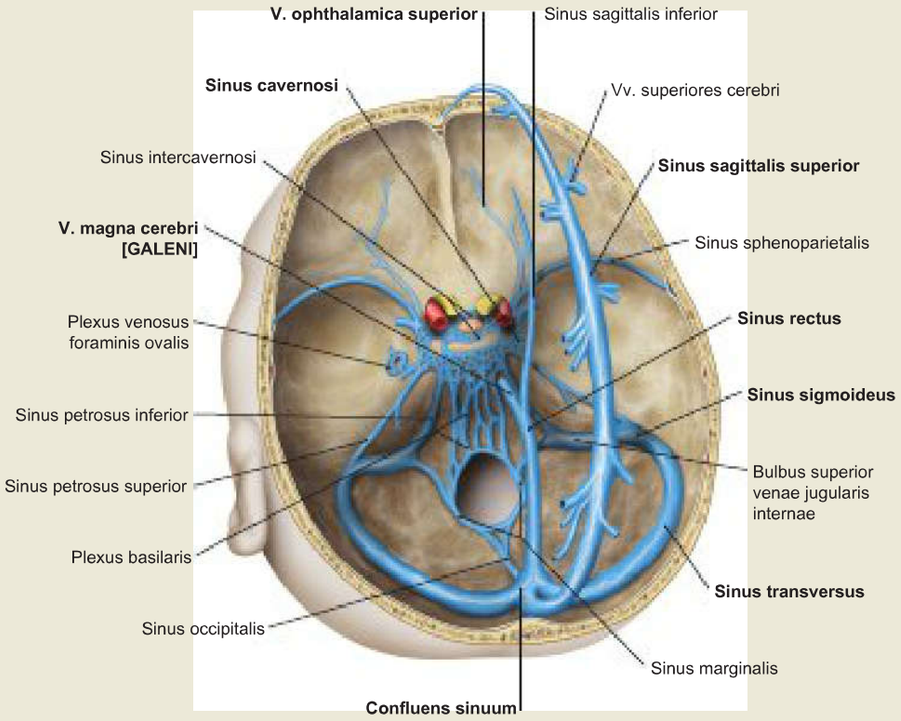

Fig. 12.72 Sinus durae matris projected onto the cranial base; oblique superior view; after removal of the Calvaria.

The Sinus durae matris are large venous blood vessels around the brain, derived from dural folds or duplications (→ Fig. 12.36 and → Table, on p. 311).

Clinical Remarks

Altitude sickness refers to suddenly occurring headaches, dizziness and nausea when ascending heights of 2,500 meters above sea-level within a short period of time and without prior acclimatisation (e. g. journey to La Paz/Bolivia with an altitude of 3,600 meters). Up to 25 % of all people are affected. It is assumed that due to the lower partial oxygen pressure at high altitude, the arterial blood flow to the brain is increased, in order to supply it with more oxygen. The larger amount of blood can only be drained if the cerebral veins could strongly dilate, but they are only capable of doing this to a rather limited extent; the resulting congestion of blood explains the symptoms.

Sinus thrombosis (a thrombosis in a Sinus durae matris) is always a serious condition. Possible causes are, e. g., protracted infections of the face (cavernous sinus thrombosis) or middle ear infections (sigmoid sinus thrombosis) (= septic sinus thromboses), but also coagulopathies with increased clotting. The patients suffer from headaches, seizures, paralysis and clouding of consciousness.

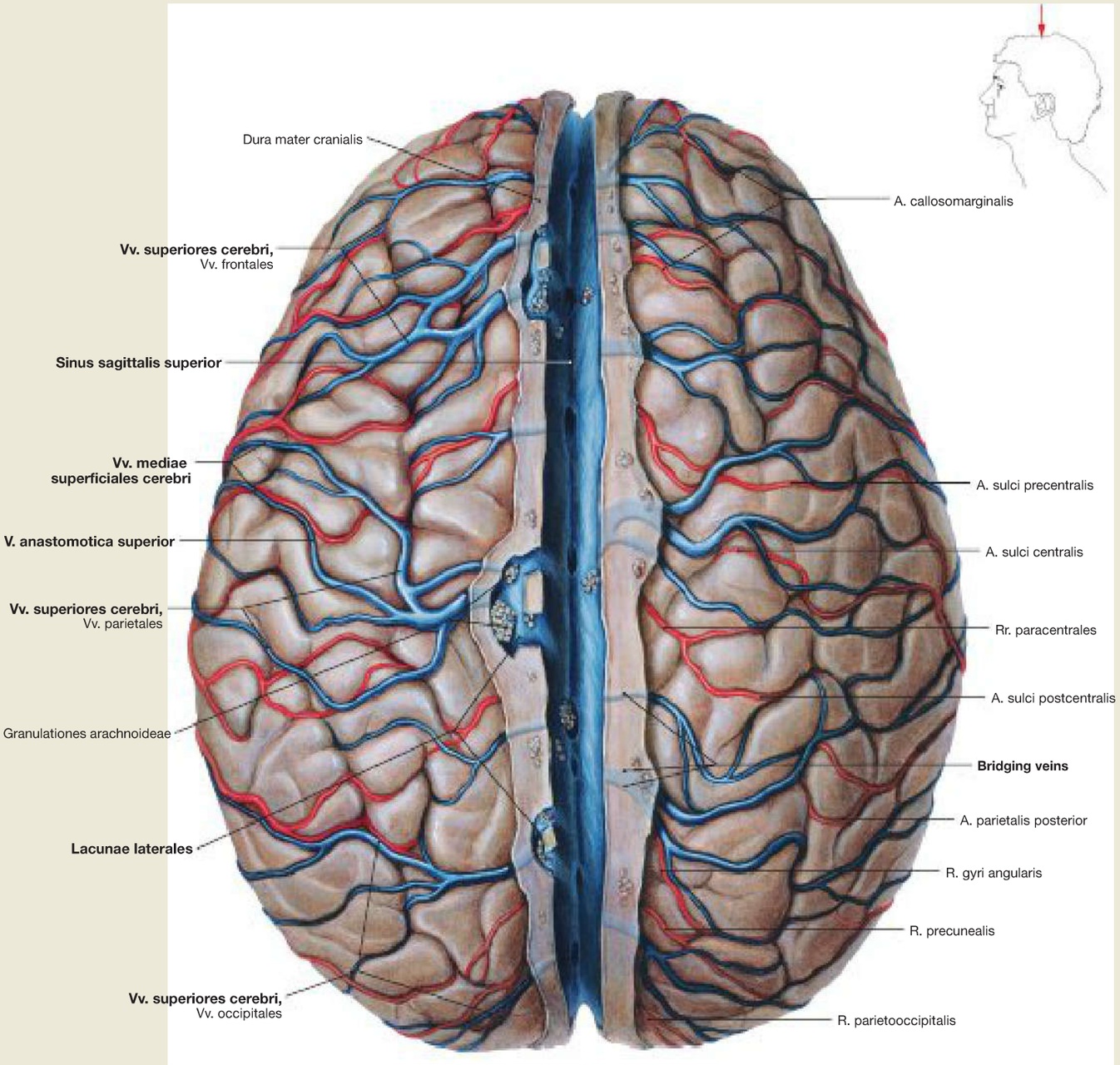

Fig. 12.73 Superficial arteries and veins of the brain; superior view; after removal of the Dura mater, and opening of the Sinus sagittalis superior; arachnoid mater also removed.
The superficial arteries and veins supply the cerebral cortex and the subjacent basal ganglia. The superficial veins include the Vv. superiores cerebri, the V. media superficialis cerebri and the Vv. inferiores cerebri (not visible here). The large veins are generally connected via anastomoses (V. anastomotica superior [TROLARD's vein] and V. anastomotica inferior [LABBÉ's vein]; → Fig. 12.70). The Vv. superiores cerebri drain into the Sinus sagittalis superior via small bridging veins, which pass through the Dura mater cranialis, or are connected by bridging veins to the Lacunae laterales, which then drain into the Sinus sagittalis superior.

Clinical Remarks

Injuries of the bridging veins can lead to bleeding between the Dura mater and Arachnoidea mater, and thus cause a subdural haematoma (→ Fig. 12.78). In particular, elderly patients with age-related atrophy of the brain and fragile bridging veins tend to develop a **chronic subdural haematoma**, which can easily be overlooked due to the insidious venous bleeding after a minor trauma that the patient often cannot remember.

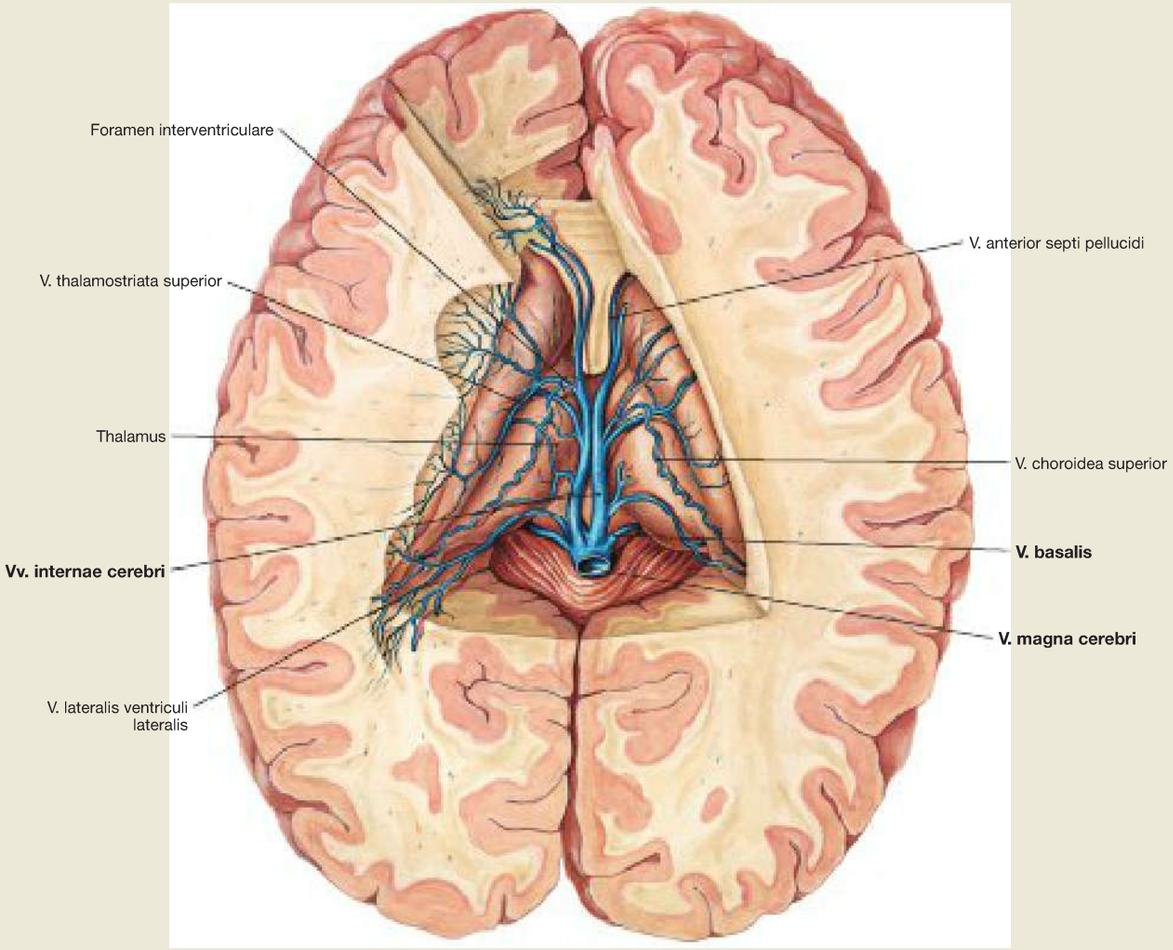

Fig. 12.74 Deep cerebral veins, Vv. profundae cerebri; superior view.
The Vv. internae cerebri run within the Tela choroidea ventriculi tertii. The veins of the ventricular system, of the basal ganglia, and of the internal capsule also belong to the deep cerebral veins. The blood from these structures flows via the Vv. thalamostriatae superiores to the Vv. cerebri internae, and from here it is drained into the V. magna cerebri (GALEN's vein).

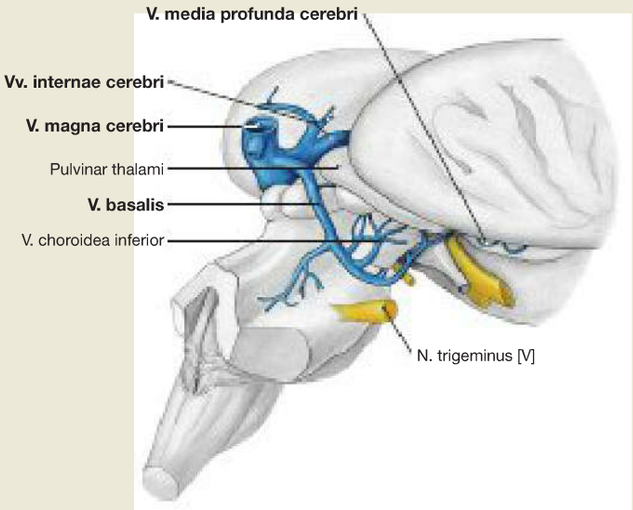

Venous Tributaries to the V. magna cerebri		
Vein	**Most Important Tributaries**	**Areas of the Brain**
V. interna cerebri	V. choroidea superior	Plexus choroideus, Hippocampus
	V. septi pellucidi	Septum pellucidum
	V. thalamostriata	Nucleus caudatus
V. basalis	V. anterior cerebri	Corpus callosum and adjacent gyri
	V. profunda cerebri	Putamen, Globus pallidus

Fig. 12.75 Deep cerebral veins, Vv. profundae cerebri; posterior view from the right side.
After removal of the cerebellum, the basal cerebral veins are visible, which drain the venous blood from the rhombencephalon, mesencephalon and insula. Venous vessels of this region are the paired V. media profunda cerebri and the V. basalis (ROSENTHAL's vein), which just like the Vv. internae cerebri drain the blood into the V. magna cerebri (GALEN's vein).

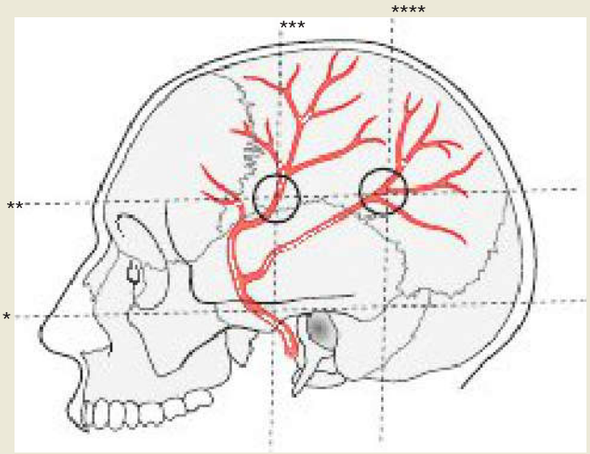

Fig. 12.76 Projection of the Rr. frontalis and parietalis of the A. meningea media onto the lateral cranial wall. Circles mark the projections of the main branches of the A. meningea media. [L127]
The main branches of the A. meningea media run at the intersections of the upper horizontal line with the vertical line passing through the middle of the zygomatic arch, and through the posterior part of the Proc. mastoideus.

* clinical term: Linea horizontalis auriculo-orbitalis (Frankfort [German] Horizontal Line)
** clinical term: Linea horizontalis supraorbitalis
*** vertical line through the middle of the Arcus zygomaticus
**** vertical line through the posterior part of the Proc. mastoideus

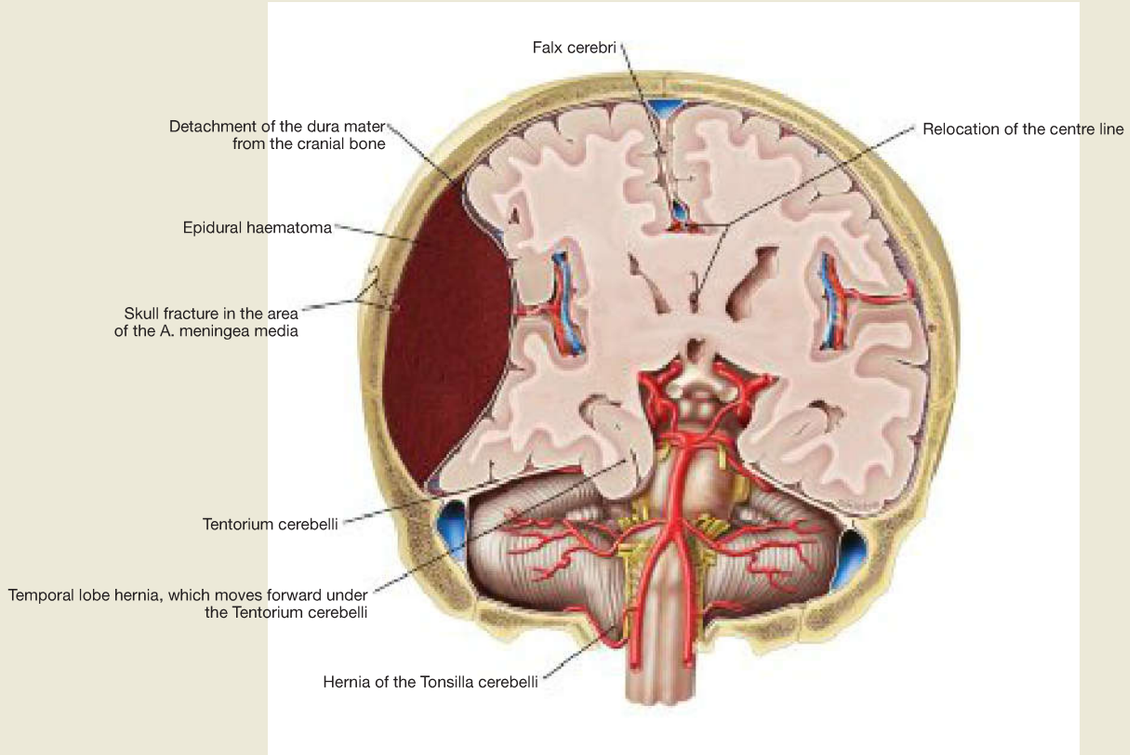

Fig. 12.77 Epidural haematoma; frontal section; anterior view. [L238]
An injury to the A. meningea media on the right side of the body has resulted in arterial bleeding between the Calvaria and Dura mater. The haematoma induced a shift of the centre line; in addition a part of the temporal lobe was pushed through the Incisura tentorii underneath the Tentorium cerebelli.

Clinical Remarks

Blunt cranial trauma with forces acting on the skull from the side often leads in the area of the above (→ Fig. 12.76) marked interfaces to **fractures of the Calvaria.** This can easily cause ruptures of the R. frontalis or R. parietalis of the A. meningea media, which supplies the Dura mater with blood. Often, the patient has no apparent injuries or does not develop symptoms during the first 30 minutes. The arterial bleeding induces a detachment of the Dura mater from the Calvaria and the formation of an **epidural haematoma** (→ Fig. 12.77) which can lead to shifting of parts of the brain and increased pressure on the brain, brain stem and cranial nerves. Serious deficits with pathological reflexes can be the result. The cranial CT scan shows an area of hyperdensity (i.e. denser than the surrounding tissue), which is biconvex and does not extend beyond the sutures. The latter is due to the attachment of the Dura mater to the sutures. Surgery with ligation of the bleeding vessel as soon as possible and relief of the intracranial pressure (by decompression) are crucial prognostic factors.

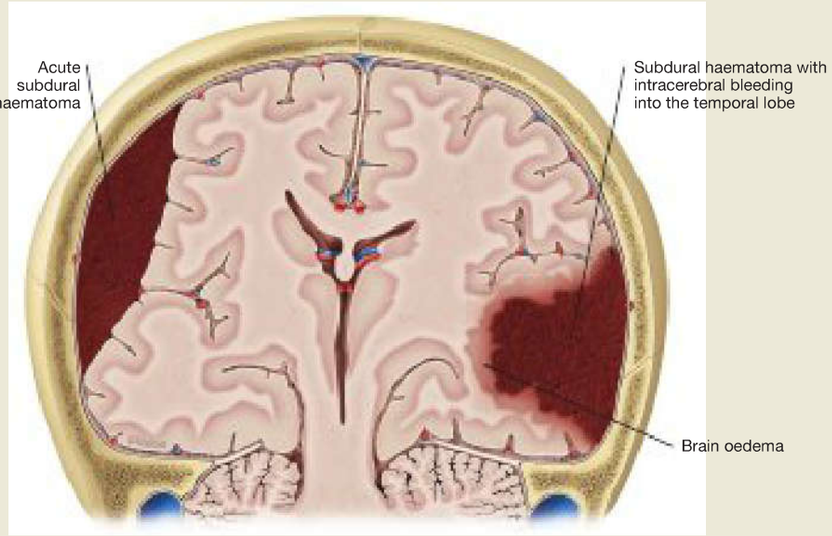

Fig. 12.78 Subdural haematoma and intracerebral haemorrhage; frontal section; anterior view. [L238]
Ruptures of bridging veins have caused an acute subdural haematoma on the right side of the head and subdural haematoma with intracerebral bleeding into the temporal lobe on the left side.

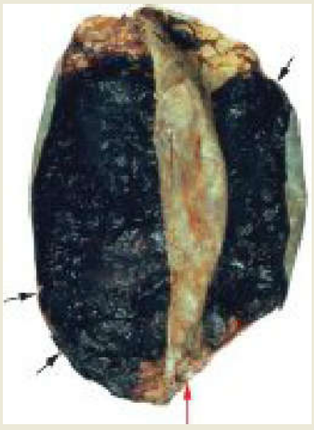

Fig. 12.79 Subdural haematoma; superior view onto the brain. [R235]
Extended bilateral acute traumatic subdural haematoma (arrows) on the inner side of the Dura mater (red arrow = Falx cerebri). The dura above the haematoma was folded upwards.

Clinical Remarks

Since the veins of elderly persons are less resilient compared to those of younger people, minor injuries can cause rupture or tearing of the bridging veins (connection between cerebral veins and Sinus durae matris) with subsequent development of a **subdural haematoma** (→ Fig. 12.78 and → Fig. 12.79). In this acute or insidious process (sometimes taking weeks), venous blood collects between the Dura mater and arachnoid mater, which is associated with unspecific symptoms such as dizziness, headache, fatigue, lack of energy or confusion. Subdural haematoma can also be associated with intracerebral bleeding and corresponding acute neurological deficits (→ pp. 299, 306, 326 and 408). In CT scans, subdural haematoma appear as hyperdense, crescent-shaped areas, extending beyond the sutures. The therapy consists of a surgical procedure with insertion of an outflow drainage.
Subarachnoid haematoma can usually be traced back to ruptures of aneurysms (pathological bulging of arteries). Aneurysms are particularly common in the area of the Circulus arteriosus WILLISII and their rupture causes bleeding into the subarachnoid space. Subarachnoid haemorrhages also appear as hyperdense areas in the CT, but strictly limited to the affected parts of the subarachnoid space, which can be especially clearly seen in the respective cisterns. An early intervention with surgical ligation of the blood source is prognostically important.

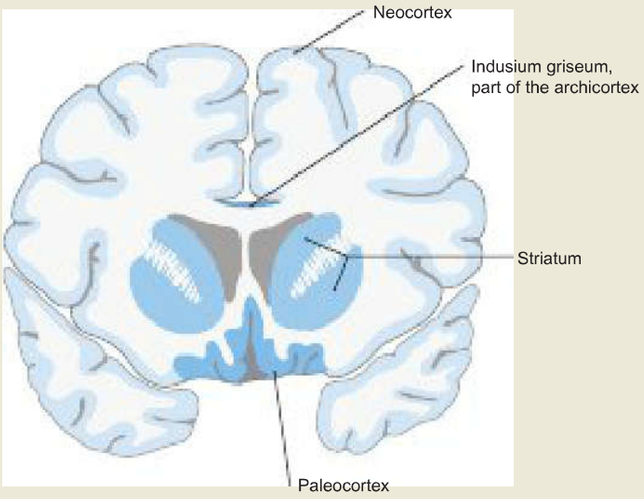

Fig. 12.80 Parts of the telencephalon; frontal section, schematic drawing. [L126]
The cortex of the telencephalon can be divided into three parts:
- Neocortex – mainly consists of six layers and accounts for the largest part.
- Archicortex – comprises the mostly three-layered parts (Allocortex) of the limbic system.
- Paleocortex – also mostly three-layered (Allocortex), and essentially it encompasses the olfactory lobe (rhinencephalon).

Furthermore, the subcortical nuclei belong to the telencephalon, e. g. the striatum.

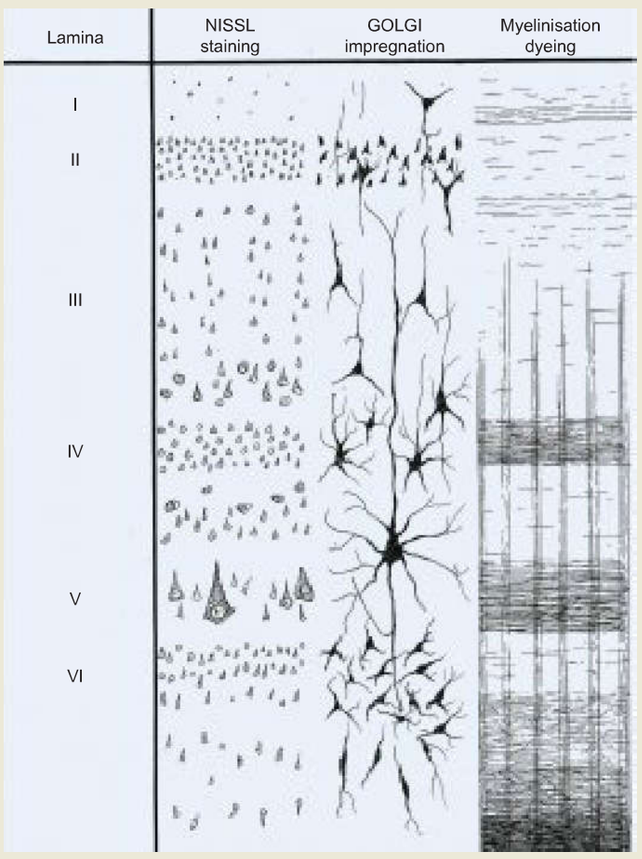

Fig. 12.81 Lamination of the isocortex (neocortex); schematic drawing. [L240/S010-2-16]
The laminar structure of the cerebral cortex, which consists of six layers mostly ca. 4 mm thick (but in the primary visual cortex, e. g., only 2 mm), is clearly visible in histological preparations obtained by perpendicular incisions to the surface of the brain. The layers are numbered from outside to inside:
- Lamina I – molecular layer (Lamina molecularis) – a few neurons, no pyramidal cells, but CAJAL-RETZIUS cells
- Lamina II – external granular layer (Lamina granularis externa) – tightly packed, small 'non-pyramidal cells' (granular cells), a few glutamatergic pyramidal cells
- Lamina III – external pyramidal layer (Lamina pyramidalis externa) – consists of three Sublaminae and small pyramidal cells
- Lamina IV – internal granular layer (Lamina granularis interna) – tightly packed, small 'non-pyramidal cells' (granular cells)
- Lamina V – internal pyramidal layer (Lamina pyramidalis interna) – pyramidal cells of varying sizes, including giant cells of BETZ
- Lamina VI – multiform layer (Lamina multiformis) – often composed of Lamina VIa (dense in cells) and Lamina VIb (poor in neurons, with small pyramidal cells)

Cerebral Areas

Telencephalon, Neocortex

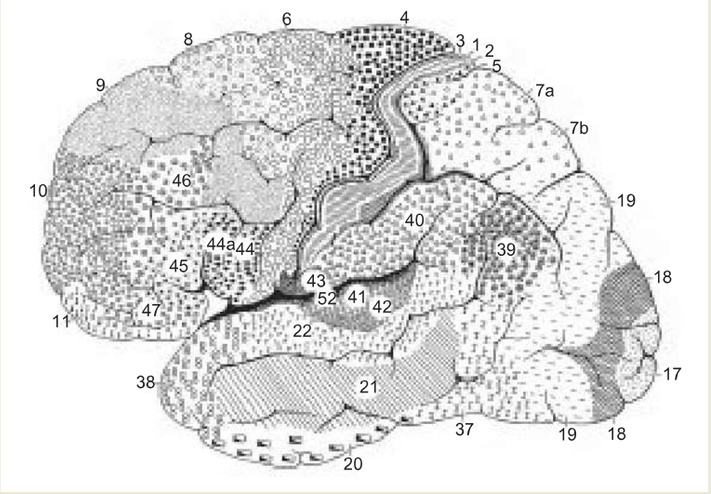

Fig. 12.82 BRODMANN's areas; view from the left side, schematic drawing. [S010-2-16]
The brain is divided into so-called BRODMANN's areas according to histological criteria.
The six-layered structure of the isocortex varies extremely by region. In the past, the layered structure has been analysed and mapped to the cortical areas (BRODMANN's areas). The numbering begins with the Gyrus postcentralis. The individual cortical areas are not only similar in their histology, but also assume functionally similar tasks.

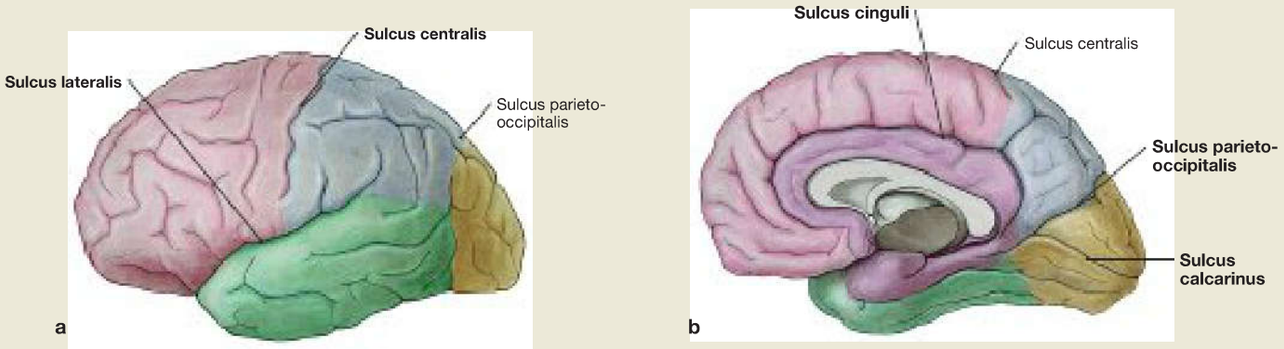

Fig. 12.83a and b Primary grooves of the cortex; a view from the left side, **b** medial view.

Primary grooves (→ Table) as well as Sulci that are developed and identifiable in each brain, divide the neocortex into five lobes (Lobi) visible from the outside.

Primary Grooves of the Cortex	
Sulcus	**Location/Course**
Sulcus centralis	extends between the frontal and parietal lobes; separates the (motor) Gyrus precentralis from the (sensory) Gyrus postcentralis
Sulcus lateralis	separates the frontal, parietal and temporal lobes from each other; Fossa lateralis and Insula are located in the depth
Sulcus parieto-occipitalis	passes from the parasagittal cortex at the medial surface of the hemisphere to the Sulcus calcarinus; separates the parietal and occipital lobes
Sulcus calcarinus	runs like the Sulcus parietooccipitalis along the medial surface and both together limit the Cuneus
Sulcus cinguli	separates the Gyrus cinguli (Lobus limbicus) from the frontal and parietal lobes

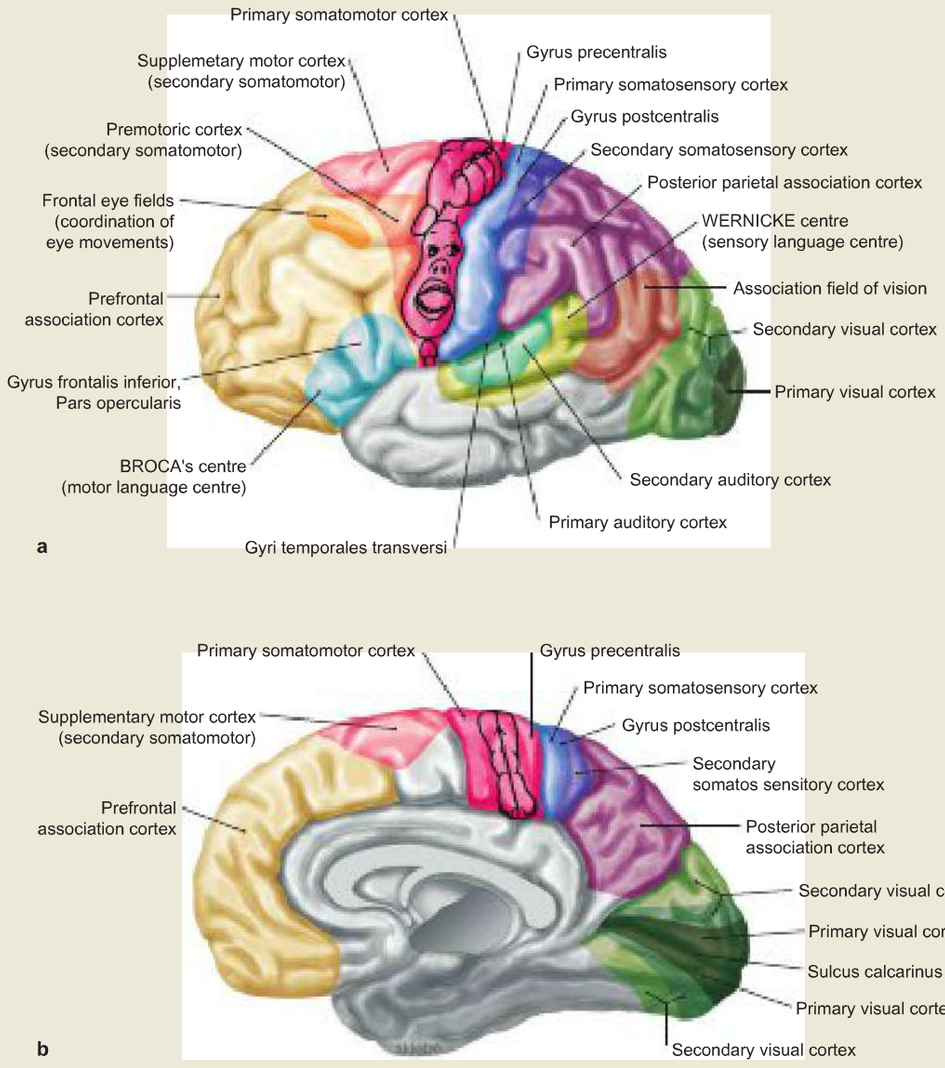

Fig. 12.84a and b Functional cortical areas of the cerebral hemispheres; view from the left side (→ Fig. 12.84a), the homunculus (inserted manikin) roughly reflects the somatotopic map of the primary somatomotor cortex; medial view (→ Fig. 12.84b), primary and secondary auditory cortex, and the WERNICKE's centre extend beyond the superior margin of the temporal lobe to its inner surface. [L238]
Higher cortical functions such as speech are only possible by the interaction of various cortical areas. At the neocortex, primary fields or areas (e. g. Gyrus precentralis, primary somatomotor cortex) are distinguished from secondary and association fields (e. g. premotor cortex, supplementary motor cortex). Primary and secondary cortical areas serve a certain sensory function (e. g. perception and interpretation of visual stimuli by the visual cortex in the occipital lobe), whereas association areas (e. g. prefrontal association cortex) occupy the largest part of the neocortex and serve the integration of different complex information.

Clinical Remarks

BROCA's aphasia is caused by failure of the BROCA's speech centre (e. g. due to a stroke). Although the speech (language) production is severely restricted, the ability to name objects, and the understanding (comprehension) of speech are often preserved. The syntax is usually no longer correct and mixed with deficient articulation of sounds.
Unilateral **lesions of the primary auditory cortex** lead to impairment of the directional hearing, as well as to problems in the discrimination of frequencies and intensities. If the adjacent WERNICKE's area is affected, this will have a strong impact on speech comprehension **(WERNICKE's aphasia).** Although speech production and language melody are preserved, the verbal language is often senseless and without sentence structure (syntax).
Damage to the primary visual cortex on one side leads to **cortical blindness** with a homonymous hemianopsia. The visual field on the opposite side fails completely. If the secondary cortical areas are affected, the patient can still receive visual stimuli, but not interpret and coordinate them **(visual agnosia).** Lesions in the frontal visual field that are associated with a failure of the area 8, result in a deviation of the gaze of both eyes to the affected side **(déviation conjuguée).**

Telencephalon, Archicortex

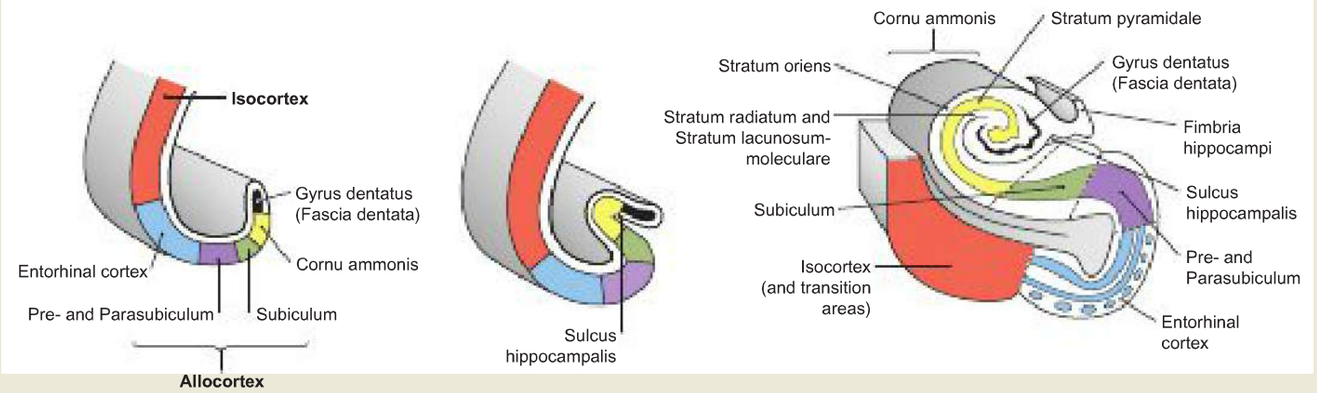

Fig. 12.85 Development of the hippocampus formation; schematic frontal sections. [L126]
The hippocampus is named with the generic term of hippocampus formation, which summarises several cortical regions: Area entorhinalis (entorhinal cortex), Fascia dentata (Gyrus dentatus), Cornu ammonis (CA1, Hippocampus proprius), Subiculum, Presubiculum and Parasubiculum. These regions of the brain are largely unidirectionally connected and form a functional unit. The development of the hippocampus begins as early as in week 9 of pregnancy. As the S-shaped folding of the mediobasal cortex resembles the mythical creature Hippocamp (a type of sea horse), it was named accordingly. Throughout one's life new neural cells can be produced in the Fascia dentata (niche of neurogenic tissue with up to 700 new neural cells/day). The archicortex is part of the limbic system and functionally important for learning and memory processes. Via the limbic system it is connected intensely with cerebral regions, which are important for the control of autonomic and emotional processes.

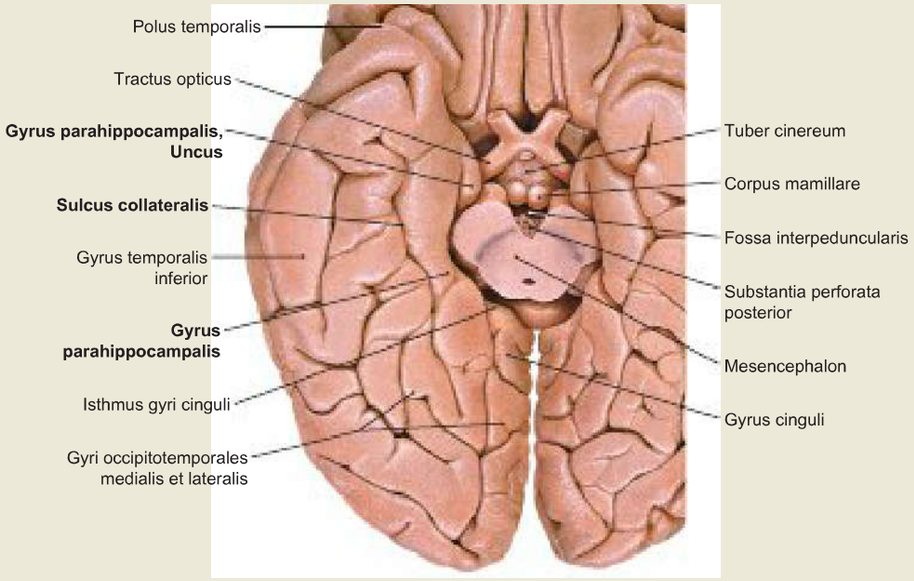

Fig. 12.86 Functional cortical areas of the hippocampus; inferior view; after dissection of the mesencephalon.
Due to its folding (→ Fig. 12.85), the position of the hippocampus formation can only partially be understood in a dorsomedial view of the brain surface (→ Fig. 12.87). The hippocampus is only macroscopically visible after opening the inferior horn of the lateral ventricle (→ Fig. 12.88). This view from below onto the gyri and sulci of the cerebral hemispheres shows the Gyrus parahippocampalis with the Uncus and the neighbouring Sulcus collateralis.

Clinical Remarks

The hippocampus has great clinical relevance. Because it plays an important role in neurodegenerative diseases with memory loss (e.g. ALZHEIMER's disease), in neuropsychiatric diseases (e.g. schizophrenia, depression, autism) and in temporal lobe epilepsy (most common form of epilepsy).
Temporal lobe epilepsy (TLE) usually begins with an aura (discomfort that announces a seizure, e. g. seeing light flashes), followed by motor symptoms (in the case of focal seizures, e. g. smacking and chewing buccal motions up to convulsive movements of the whole body) and loss of consciousness. The treatment is with drugs, and in therapy-resistant cases also the unilateral removal of the hippocampus should be considered.

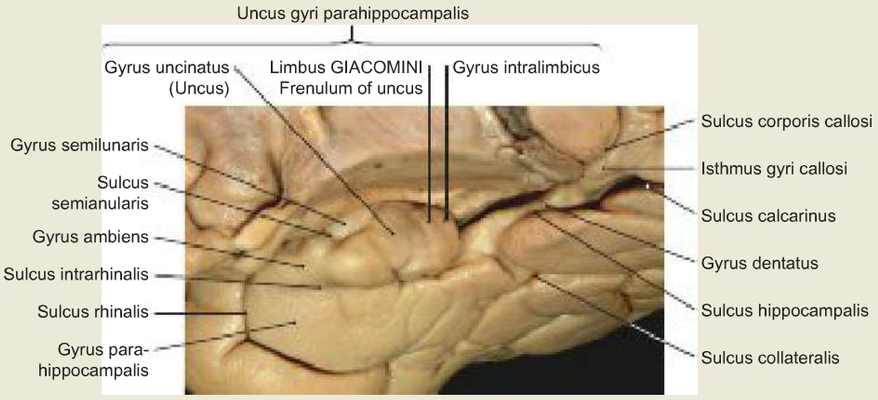

Fig. 12.87 Functional cortical areas of the hippocampus; temporal lobe in the dorsomedial view. [R247]
Due to its folding (→ Fig. 12.85), the position of the hippocampus formation can only partially be understood in a caudal view of the brain surface (→ Fig. 12.86). The hippocampus is only macroscopically visible after opening the inferior horn of the lateral ventricle (→ Fig. 12.88). The dorsomedial view shows parts of the Uncus, the Gyrus dentatus, Gyrus semilunaris, Gyrus ambiens, Gyrus parahippocampalis and the adjacent Sulci.

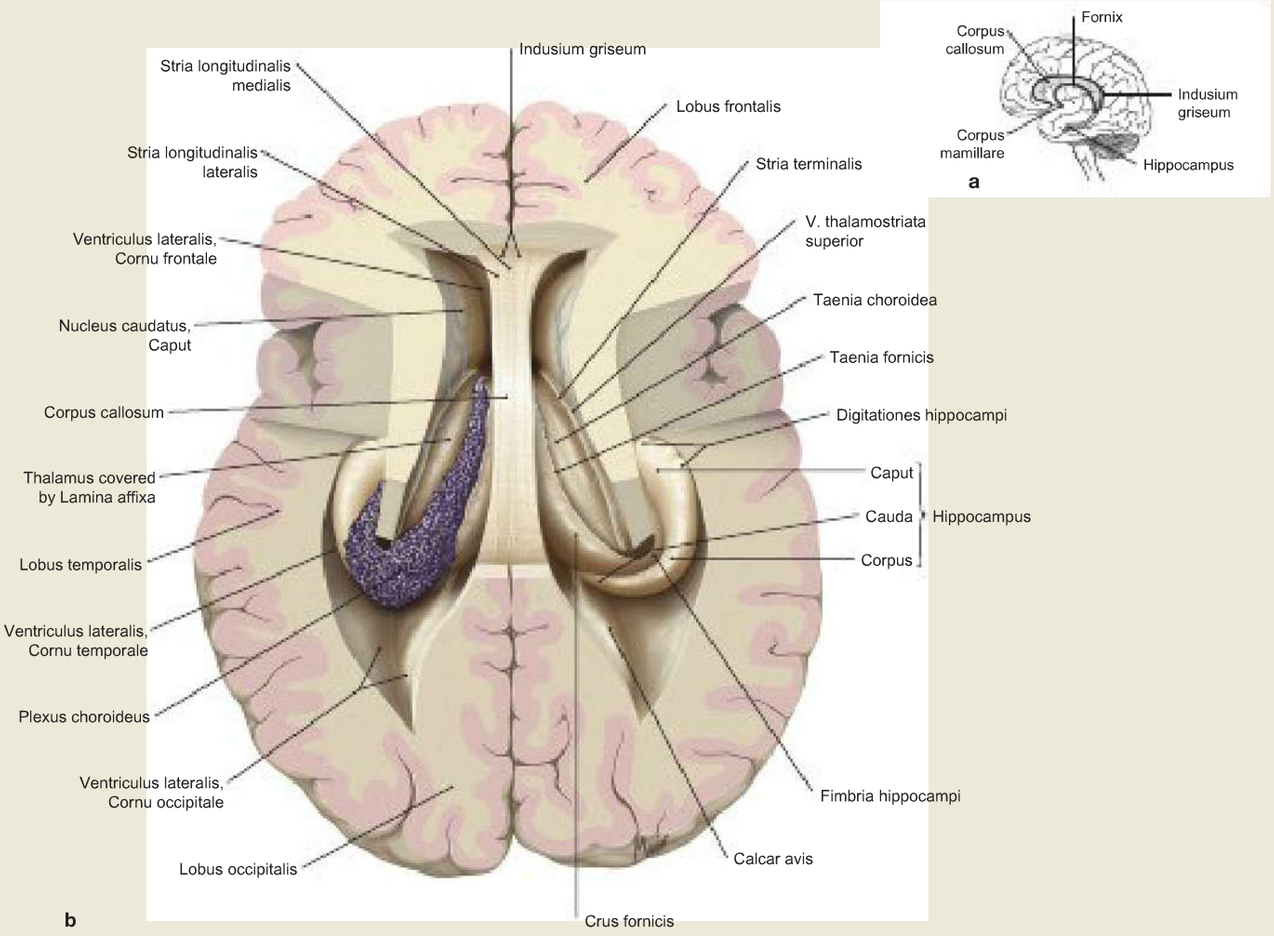

Fig. 12.88a and b Opened lateral ventricle with hippocampus; view from the left side (→ Fig. 12.88a), for visualising the three-dimensional structure of the hippocampus, the brain was depicted transparently; with a superior view (→ Fig. 12.88b) after dorsal and lateral opening of the lateral ventricles. [L127]
The hippocampus formation lies in the medial temporal lobe and arches above the Corpus callosum. Depending on the topographical relationships to the Corpus callosum, a distinction is made between three macroscopic parts:

- **Hippocampus retrocommissuralis** (cortex of the temporal lobe) = 'hippocampus' in the proper sense and clinical term
- Hippocampus supracommissuralis (above the Corpus callosum)
- Hippocampus precommissuralis (beneath the Genu corporis callosi)

Caput, Corpus and Cauda of the hippocampus are located at the bottom of the inferior horn of the lateral ventricle, and covered by the Plexus choroideus on the left side. The plexus on the right side has been removed.

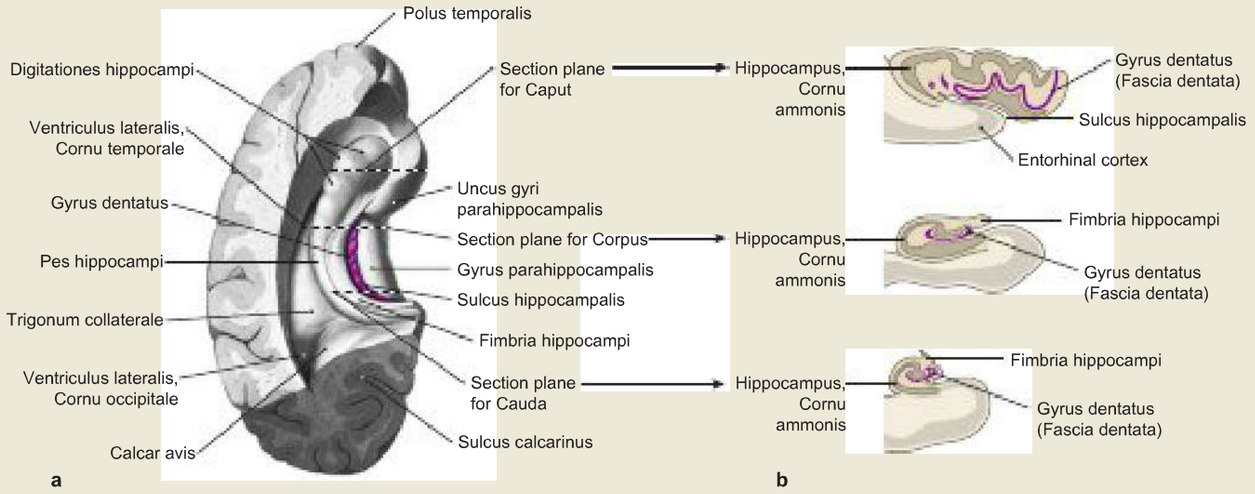

Fig. 12.89a and b Hippocampus; posterior view from above (→ Fig. 12.89a) on the inferior horn of the opened lateral ventricle; cross-sections through the hippocampus (→ Fig. 12.89b) at the level of its head, body and tail (Caput, Corpus, Cauda hippocampi). b [L127]

In the Gyrus dentatus (purple) one can see significant differences in the arrangement of the principal cells. Anterior frontal sections cut the regions of the hippocampus several times; at the level of its body and tail the 'classical' arrangement of the regions can be seen.

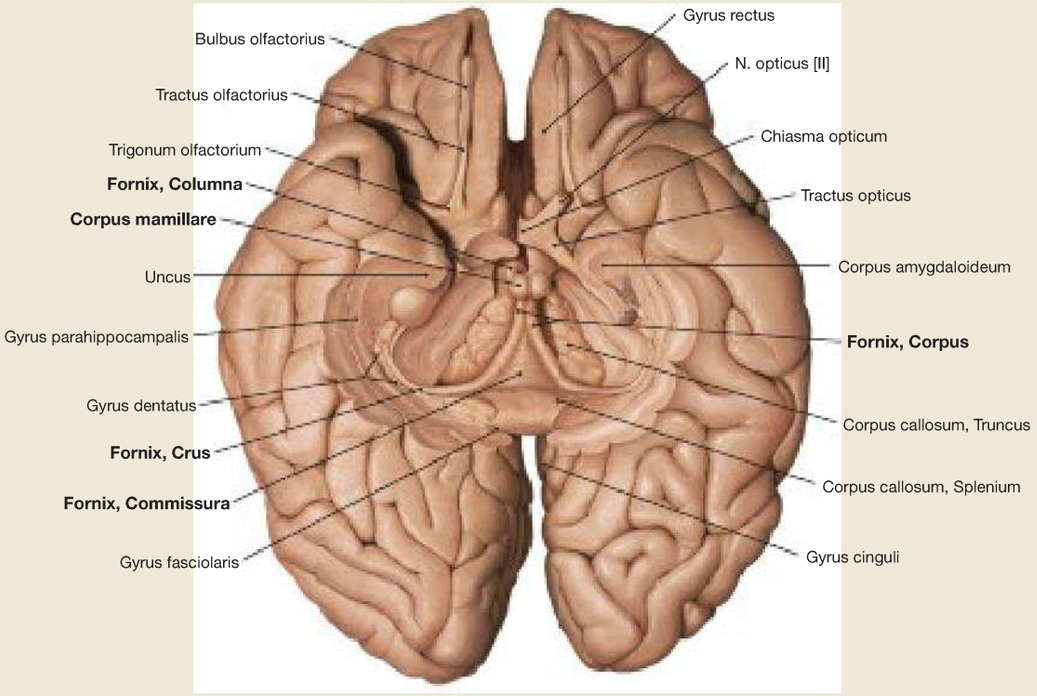

Fig. 12.90 Fornix; inferior view; after removal of the basal parts of the brain.
The Fornix is a paired structure composed of Crus, Commissura, Corpus and Columna fornicis. From its origin at the hippocampus and the subiculum in the temporal lobe it forms an arch above the third ventricle towards the Corpus mamillare. Before reaching the Corpora mamillaria the two fornices unite (Commissura fornicis). At this point, an **exchange of fibres** between both sides takes place (→ Fig. 12.91).

Clinical Remarks

Neurodegenerative diseases are associated with an insidious destruction of nerve cells. If the hippocampus formation is affected, this is combined with disorders of the spatial memory and orientation functions. New knowledge and new experiences can no longer be stored. **ALZHEIMER's disease** is the most famous form of neurodegenerative diseases. It is associated with the formation of extracellular protein deposits ('amyloid plaques') and intracellular protein aggregations in the brain. The hippocampus formation is affected at an early stage. In addition to spatial disorientation, there is a loss of memory function. If the neocortex is involved later on, the remaining memories will also be deleted. Thus, in advanced stages, patients cannot remember themselves as a person/personality nor the life events they have experienced.

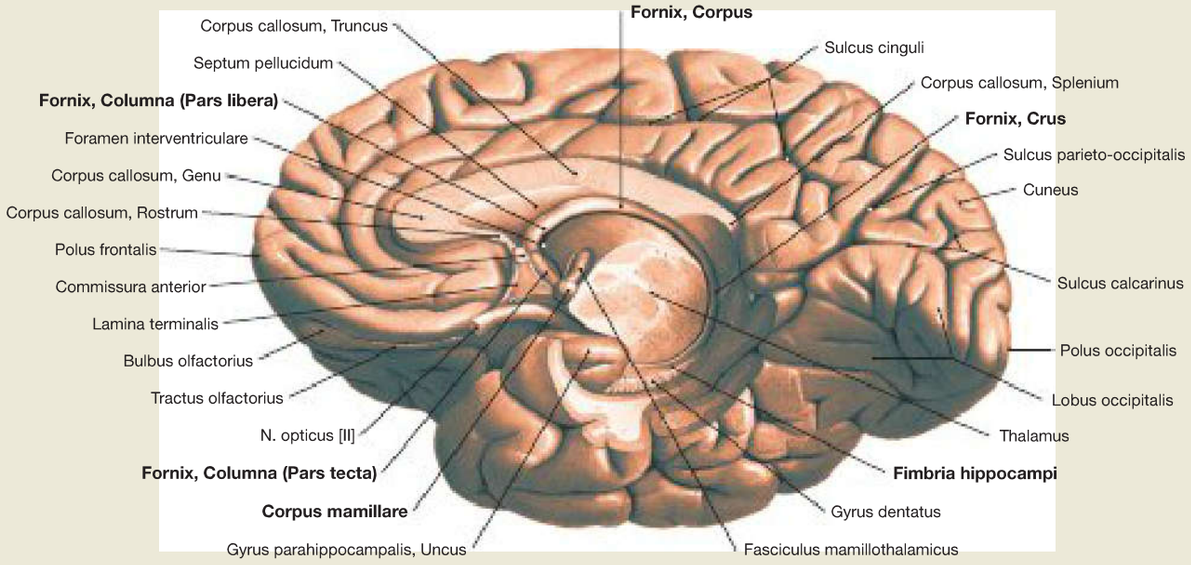

Fig. 12.91 Fornix; medial view from below.
The Fornix is an important tract of the limbic system. **Fibre connections** exist to the anterior hypothalamic nuclei, the thalamus, and the Habenulae. The figure shows the topographical relationships of the Fornix.

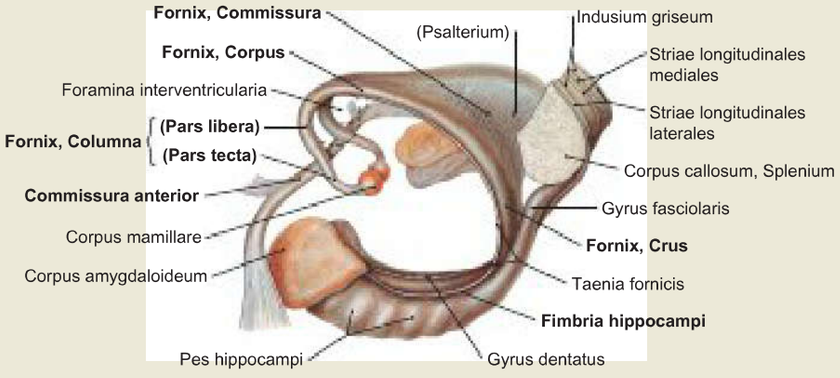

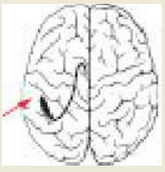

Fig. 12.92 Anterior commissure, Commissura anterior, Fornix and hippocampus formation, Indusium griseum; view from the left side.
All structures shown here are part of the **limbic system,** a functional concept with input from numerous structures in the telencephalon, diencephalon, and mesencephalon. The most relevant structures are both hippocampi, the Corpora amygdaloidea, the Gyri cinguli and the Nuclei septales. The limbic system controls functions such as impulse, learning, memory, emotions, but also the autonomic regulation of food intake, digestion, and reproduction.
The **Commissura anterior** (→ Fig. 12.31 and → Table, on p. 281) is a system of commissural fibres, composed of a Pars anterior and a Pars posterior. The Pars anterior connects the olfactory tracts and the olfactory cortices of both sides. The Pars posterior connects the Paries anteriores of the temporal lobes (particularly the cortex and Corpora amygdaloidea). The Corpus amygdaloideum is in contact with the hippocampus.
Visible structures of the **hippocampus** are the Digitationes hippocampi of the Pes hippocampi and the Fimbria hippocampi, which transition into the Crus of Fornix. In the region of the Columna, an exchange of fibres occurs between both sides. In the rostral direction, the Fornix continues via the Corpora in the Columnae, which respectively consist of a Pars libera and a Pars tecta. The Pars tecta is connected to the Corpus mamillare.

Clinical Remarks

Like the Fornix and hippocampus, the Corpora mamillaria are part of the limbic system. They probably play a role in memory function. However, precise details are not yet known. A lack of thiamine (vitamin B_1), e. g. due to chronic alcohol abuse, may lead to the destruction of the Corpora mamillaria, which is associated with most severe memory loss **(amnesia),** disorders of movement coordination **(ataxia)**, as well as disorientation and untrue story-telling **(confabulations; WERNICKE-KORSAKOFF syndrome).** The patient tries to create false 'stories' to conceal his memory gaps.

Telencephalon, Archicortex

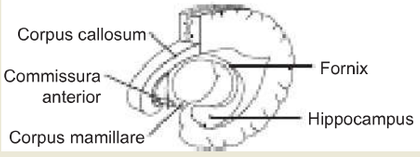

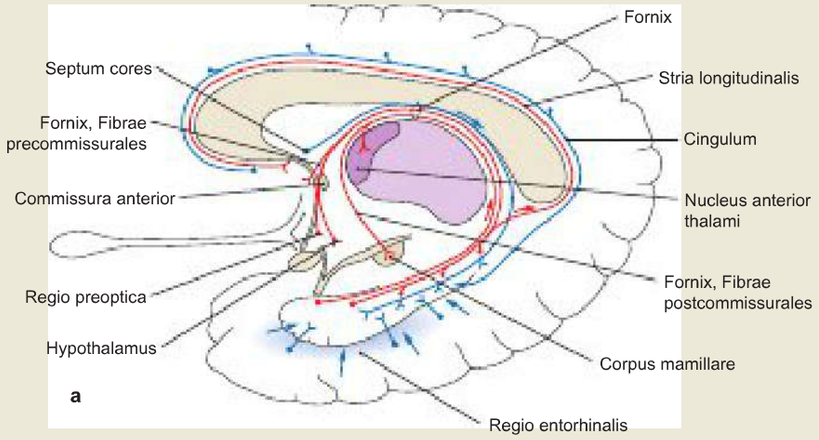

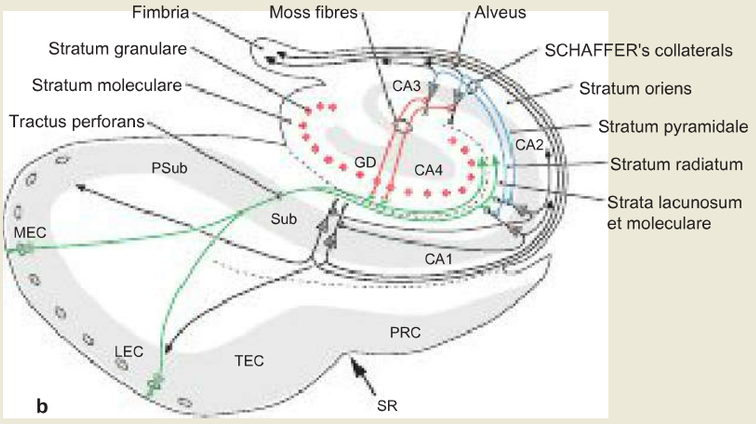

Fig. 12.93a and b Connections of the hippocampus formation; PAPEZ circuit (→ Fig. 12.93a); regions of the hippocampus formation and their intrinsic interconnections (→ Fig. 12.93b). Frontal section through the Corpus of the hippocampus; CA = Cornu ammonis, GD = Gyrus dentatus, Sub = Subiculum, PSub = Presubiculum, MEC/LEC = medial/lateral entorhinal cortex, TEC = transentorhinal cortex, PRC = perirhinal cortex, SR = Sulcus rhinalis. a [L127], b [L141]

Connections of the hippocampus formation are:

- neocortical (via entorhinal cortex, the 'gateway to the hippocampus'; subiculum complex)
- intrinsic (entorhinal cortex – Fascia dentata – CA3 – CA1 – subiculum complex – entorhinal cortex)
- commissural (especially entorhinal cortex and Subiculum)
- subcortical (septal nuclei, Corpora mamillaria, Amygdala, brain stem, etc.)

Broadly speaking, the neuronal circle (PAPEZ' circuit) connects the hippocampus via the Fornix to the Corpora mamillaria, and continues via the mamillothalamic bundle to the Nucleus anterior of the thalamus, and then to the Gyrus cinguli. The Gyrus cinguli projects via the Cingulum to the Regio entorhinalis of the Gyrus parahippocampalis, and this in turn via the Tractus perforans to the hippocampus, so that the circuit is closed. Today, it is assumed that the PAPEZ' circuit supports the storage of memory, by transferring the content of the primary memory in the form of the secondary memory and tertiary memory.

Clinical Remarks

Sometimes the affected parts of the hippocampus formation are surgically removed on one side, as treatment in the case of severe and **drug therapy-resistant temporal lobe epilepsy**. While this strategy apparently does not lead to memory impairment, the resection of both hippocampi results in a high-grade, mainly anterograde amnesia (inability to store and recall new memory contents).

Lesions of cingulate cortical areas lead to cognitive changes, which do also occur in complex neuropsychiatric diseases (depression, schizophrenia, anxiety disorder, lethargy).

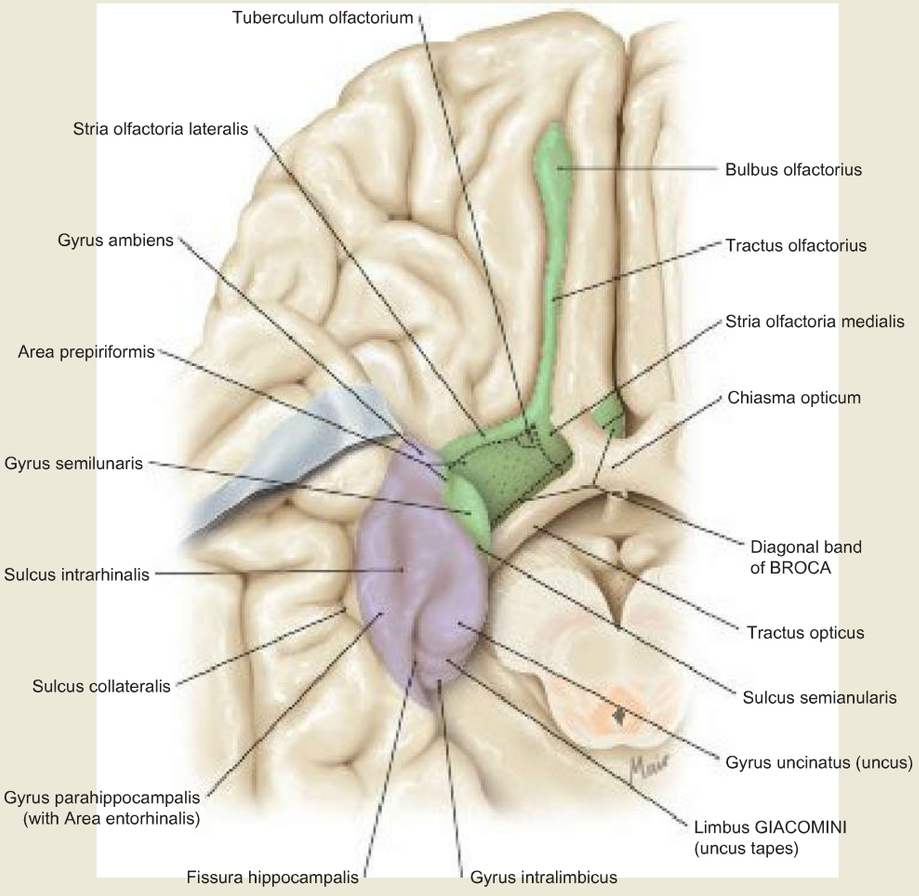

Fig. 12.94 Structures of the paleocortex (green) and the adjacent archicortex (purple); inferior view. [L127]
The paleocortex is the oldest cortical part in terms of phylogeny. It includes the Bulbus olfactorius, Tractus olfactorius, Nucleus olfactorius anterior, Tuberculum olfactorium, the septal nuclei, the Regio periamygdalaris and Regio prepiriformis. Bulbus and Tractus olfactorius show clear histological differences to the six-layered isocortex. Therefore they belong to the allocortex (allo = different, as opposed to the six-layered isocortex). The paleocortex is responsible for the sense of smell. The olfactory sensations of the receptor cells in the nasal mucosa (→ Fig. 12.129) are passed directly via the Bulbus olfactorius to the primary olfactory cortex without being switched in the thalamus. This distinguishes the sense of smell from all other senses or sensations. However, there are close connections to different parts of the limbic system. Olfactory cortical areas exert their effects on other areas of the brain via connections to the thalamus and the insula.

Clinical Remarks

Since **neurodegenerative diseases** such as ALZHEIMER's and PARKINSON's disease are often associated with smell disorders at an early stage, an evaluation of the sense of smell by using standardised (olfactory) tests is discussed as an early diagnostic marker for these diseases.

Cerebral Areas

Telencephalon, Subcortical Nuclei

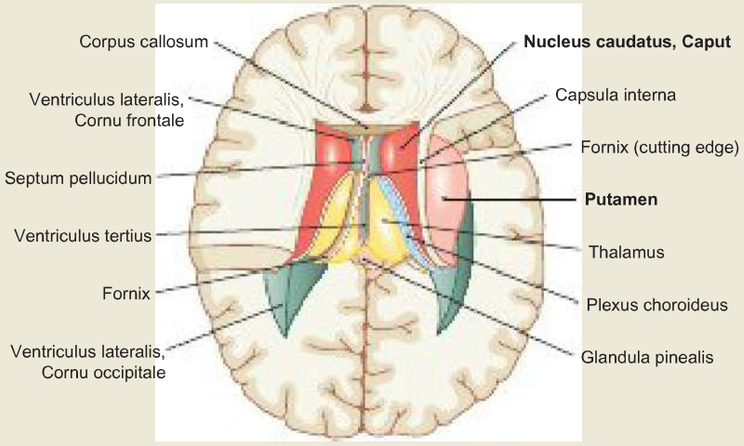

Fig. 12.95 Basal ganglia, thalamus and lateral ventricles; overview; superior view after dorsal and lateral opening of the lateral ventricles. [L126]
The basal ganglia belong to the group of subcortical nuclei. Further subcortical nuclei are the Amygdala and the Nucleus basalis MEYNERT (neither is shown). The basal ganglia (nuclei) are involved in the design of movement sequences, as well as in the regulation of higher brain functions such as learning, memory, motivation and emotion. They primarily belong to the extrapyramidal motor system (EPMS).
The basal ganglia include:

- Striatum (Corpus striatum) consisting of Nucleus caudatus and Putamen
- Pallidum (Globus pallidus; not visible)

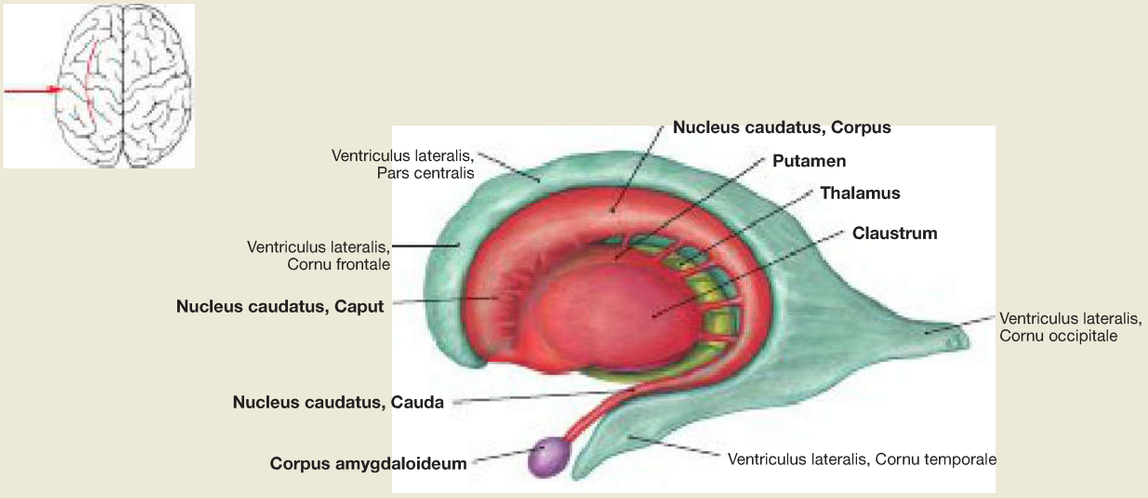

Fig. 12.96 Basal ganglia and thalamus; view from the left side.
The illustration shows the topographical relationship between Ventriculus lateralis, Nucleus caudatus, Amygdala, Putamen, Globus pallidus and Thalamus. Many nuclei of the telencephalon are summarised under the generic term **basal ganglia**. The basal ganglia include the Striatum (Nucleus caudatus and Putamen, shown here) and the Pallidum as well as the Nucleus subthalamicus and Substantia nigra (all three structures not shown here) in the mesencephalon.

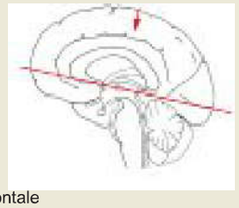

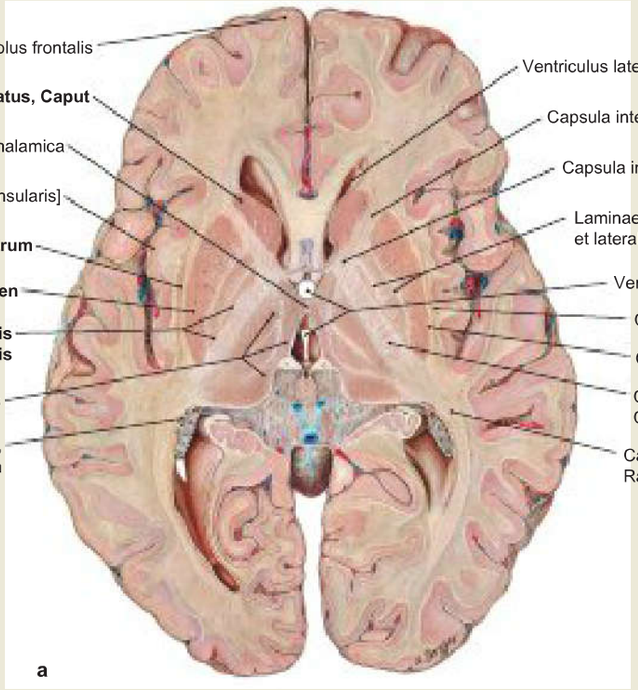

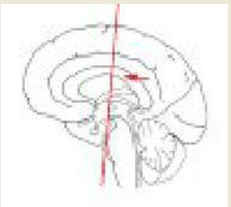

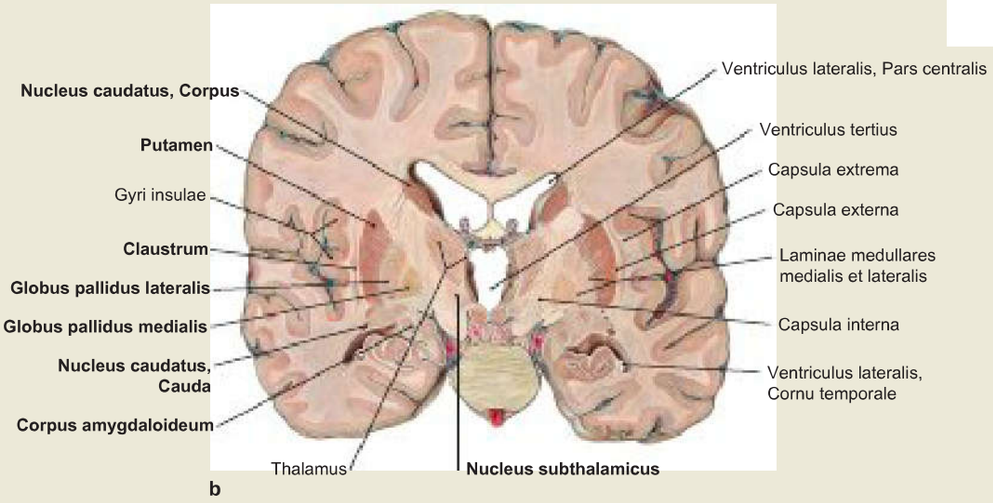

Fig. 12.97a and b Subcortical nuclei; horizontal section (→ Fig. 12.97a) through the centre of the third ventricle; frontal section (→ Fig. 12.97b) at the level of the Corpora mamillaria.

Clinical Remarks

The **Morbus PARKINSON** (PARKINSON's disease) is caused by a degeneration of dopaminergic neurons and thus can be traced back to a loss of nigrostriatal fibres (fibres between Substantia nigra and Striatum). The result is a general inhibition of motor activity with restrictions of the motion drive (from hypokinesia to akinesia = physical inactivity). This is characterised by short tripping steps and a lack of the accompanying arm swings. Furthermore, there is usually a unilateral tremor (trembling of the hand) at rest, as well as a general muscle stiffness (rigor, e. g. lack of facial expression). In addition, these patients suffer from increased secretion of saliva, tears, sweat, and sebum, and psychologically they are also slower and emotionally more unstable. The disease affects approximately 1% of the age group over 60 years. Similar conditions to PARKINSON's disease can occur after encephalitis, intoxications, long-term use of psychotropic drugs, among others.

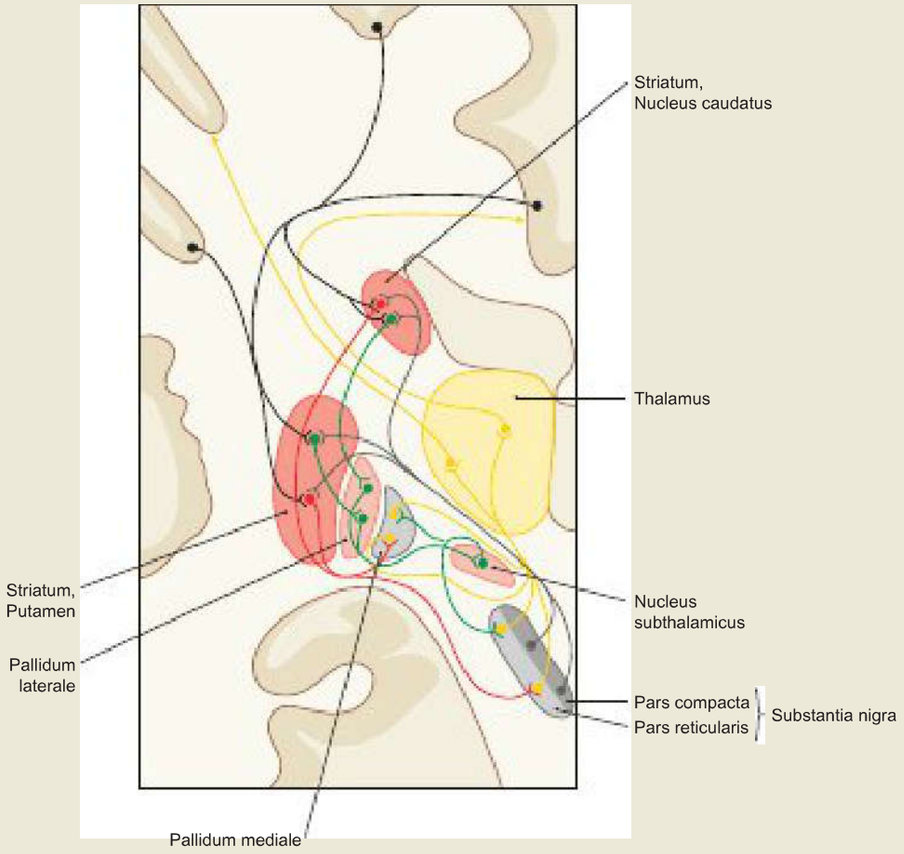

Fig. 12.98 Neuronal circuits of the subcortical nuclei; schematic drawing, frontal section. [L126]

Internal structure and fibre connections of the basal ganglia. The Striatum is the main entrance station of the basal ganglia (→ Fig. 12.99).

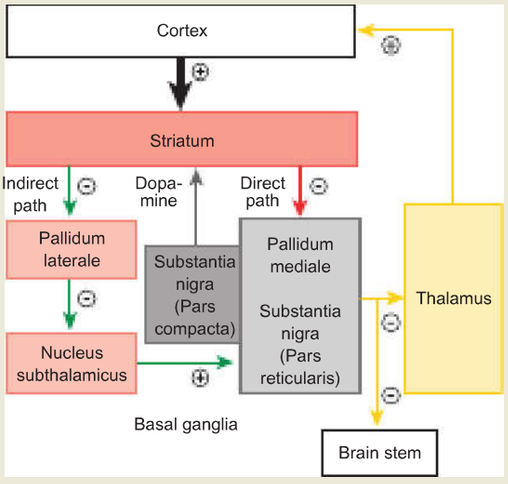

Fig. 12.99 Neuronal circuits of the subcortical nuclei; schematic drawing. [L126]
The basal ganglia are involved in the **planning of motion programs** via their integration into various cortical feedback loops (cortex – basal ganglia – thalamus – cortex) Their main task is the modulation of movements (force, direction, deviation). The impulses entering the basal ganglia are processed either in a direct mode, promoting motion, or in an indirect mode, inhibiting motion.

Clinical Remarks

Changes in the huntingtin gene lead to autosomal dominant inherited **HUNTINGTON's disease.** The neurodegenerative disorder is associated with a degeneration of striatal GABAergic projection neurons, in particular of the indirect processing mode, and leads to exaggerated involuntary movements with reduced muscle tone (choreatic hyperkinesia).

Damage to the Nucleus subthalamicus causes disorders of the indirect processing mode. The patients perform proximally accentuated, acute catapulting movements **(hemiballism)** with the unaffected limb on the contralateral side of the body.

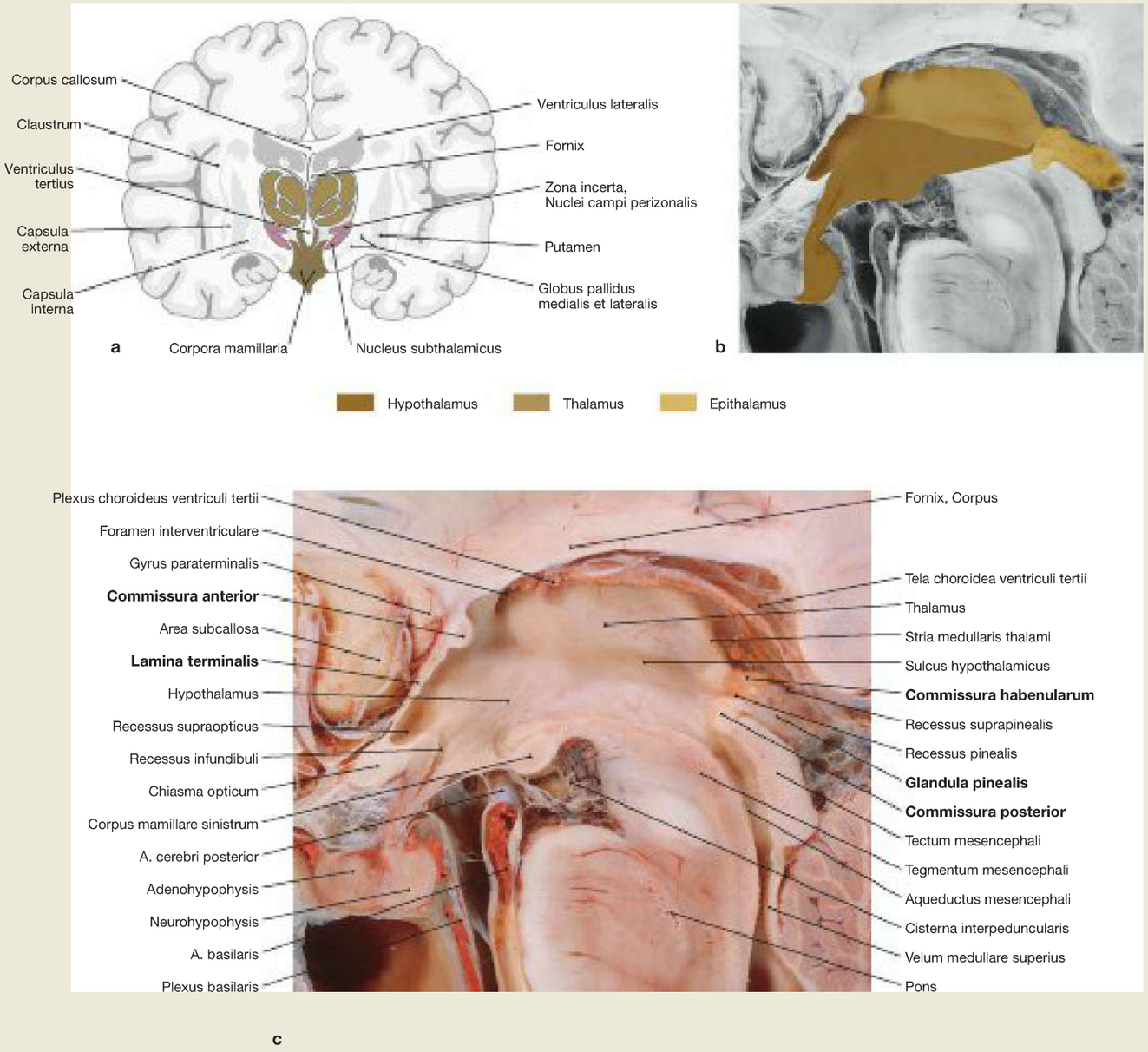

Fig. 12.100a to c Distinct parts of the diencephalon; frontal section (→ Fig. 12.100a), schematic drawing; mid-sagittal section (→ Fig. 12.100b) and original image (→ Fig. 12.100c) of b. a [L126]
The diencephalon is divided structurally and functionally into four levels:

- Epithalamus (upper level on top of the thalamus, includes Corpus pineale, Habenulae and Commissura posterior)
- Thalamus dorsalis (large, tightly packed nuclear complex, extends bean-shaped on both sides of the third ventricle, including the Corpora geniculata = metathalamus)
- Subthalamus (Thalamus ventralis, transition zone between diencephalon and mesencephalon, motor zone of the diencephalon, nuclei for the control of motoric functions such as Globus pallidus and Nucleus subthalamicus)
- Hypothalamus (lowest level, nuclei and fibre tracts at the bottom of the third ventricle and in the lower parts of the lateral ventricles)

In terms of phylogeny, the diencephalon belongs to the prosencephalon and is located between the telencephalon and the mesencephalon. It surrounds the third ventricle. Rostrally, the diencephalon is bordered by the Commissura anterior (reaching up to the Chiasma opticum) and the Lamina terminalis. The posterior border is formed by the Commissura posterior, the Commissura habenularum and the pineal gland (Glandula pinealis).

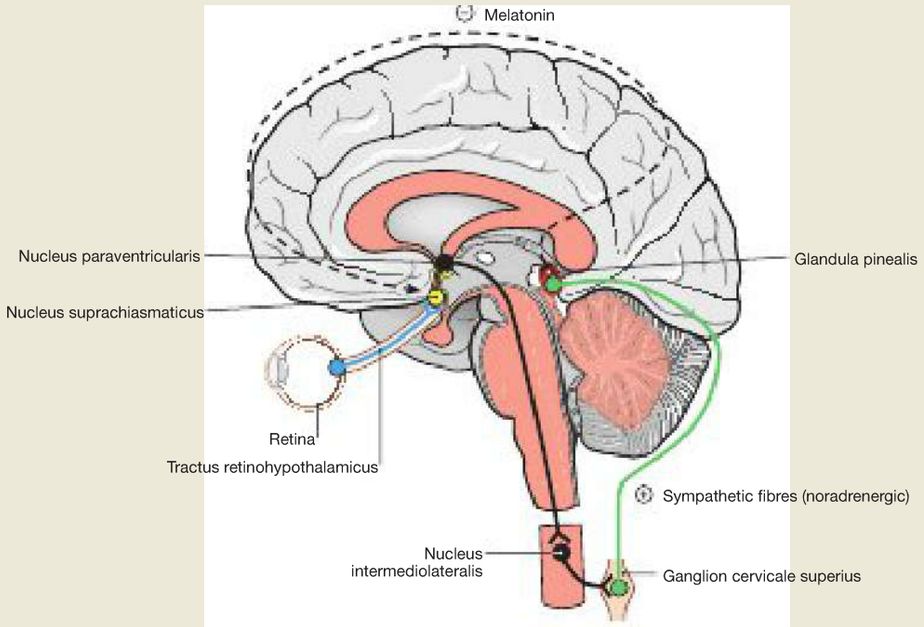

Fig. 12.101 Circuit for controlling the pineal gland, Glandula pinealis; schematic median section. [L126]
The Epithalamus comprises the Striae medullares thalami, the Habenulae, the Nuclei habenulares, the Commissura habenularum, the Commissura posterior (epithalamica), the Area pretectalis and the Glandula pinealis. The production of **melatonin** in pinealocytes of the Glandula pinealis is light dependent; melatonin regulates circadian rhythms by affecting the function of other endocrine organs. Furthermore, melatonin has a feedback effect on the Nucleus suprachiasmaticus, which synchronises endogenous with exogenous environmental rhythms.
The **circuit** starts at the photoreceptors of the retina which send signals to the Nucleus suprachiasmaticus in the hypothalamus (Tractus retinohypothalamicus). From there, the information is transmitted via the Nucleus paraventricularis of the hypothalamus to the sympathetic Ganglion cervicale superius, and then to the pinealocytes of the Glandula pinealis. Melatonin is produced in larger quantities at night.

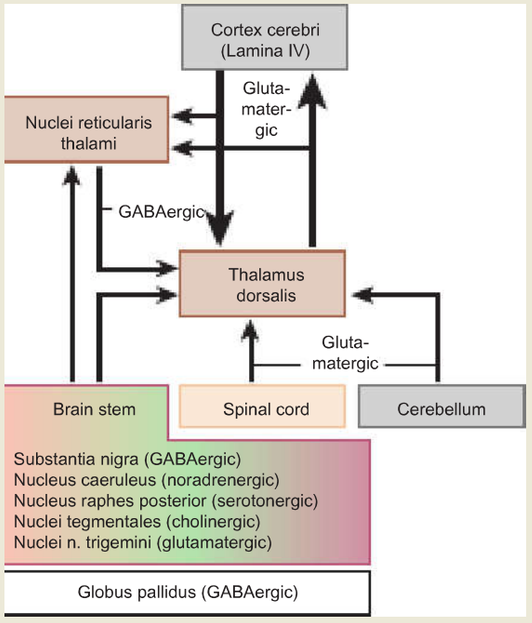

Fig. 12.102 Afferent and efferent connections of the Thalamus dorsalis; schematic drawing. [L126]
The Thalamus dorsalis performs key tasks in the communication of cortical areas with the periphery and from the periphery to central cerebral regions **('gateway to consciousness')**. All sensations, with the exception of smelling, are relayed through the thalamus, like a switch board. Furthermore, specialised nuclei/nuclear areas are involved in the motor (motion) control and are integrated into different subcortical feedback circuits, such as the limbic system. Finally, the thalamus also participates in autonomic and motor activities.

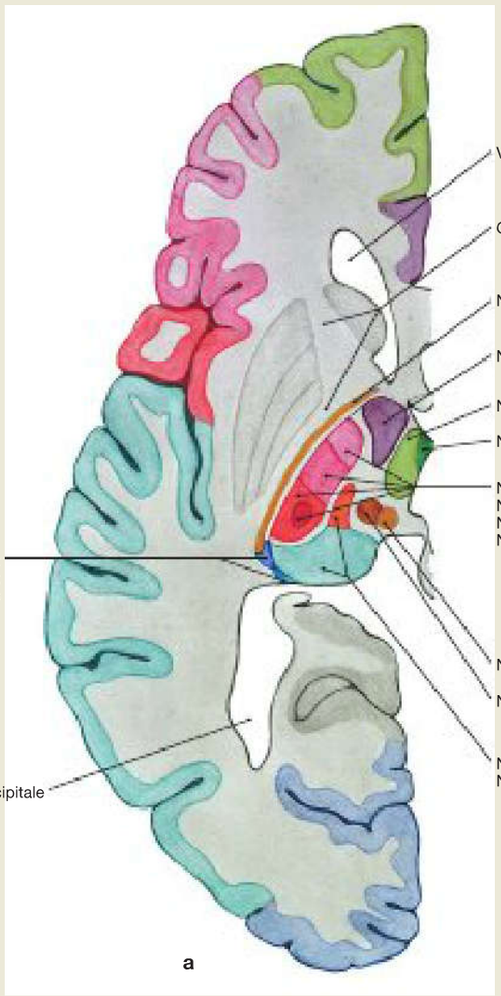

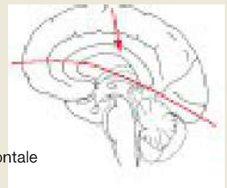

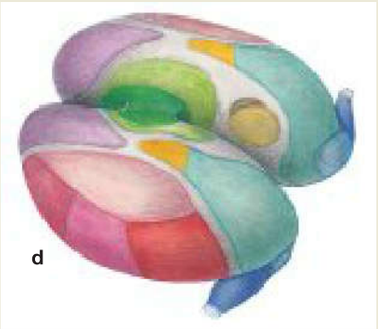

Fig. 12.103a to d Nuclei and cortical projection of the thalamus. Corresponding nuclei and cortical regions are marked by the same colours, respectively.
a Horizontal section through the left cerebral hemisphere
b Left lateral view of the left cerebral hemisphere
c Medial view of the right cerebral hemisphere
d Oblique superior view of both thalami

All sensory impulses from the body enter the thalamus, where they are relayed (exception: smell), integrated and sent to the cortex. In addition, the thalamus participates in autonomic and motor activities. Its various groups of nuclei are structurally divided by lamellae **(Lamina medullaris medialis interna)** into three nuclear areas:

- ventrolateral group **(Nuclei ventrolaterales)**
- medial group **(Nuclei mediani)**
- anterior group **(Nuclei anteriores)**

Furthermore, a distinction is made between the Nuclei mediani embedded in the Lamina medullaris medialis interna, the occipital Pulvinar, and the Nuclei reticulares. The respective groups of nuclei can be subdivided into smaller functional units (more than 100 nuclear areas). Specific nuclei (Palliothalamus) control defined cortical areas (primary cortical projection and association fields/areas); non-specific nuclei (Truncothalamus) project to the brain stem and to some rather diffuse cortical areas.

Clinical Remarks

Damage in the area of the non-specific thalamic nuclei, e. g. in the case of circulatory disorders, often leads to a reduced state of consciousness with impaired awareness. Depending on the location, damage to **specific thalamic nuclei** may cause sensory impairment (Nucleus ventralis posterolateralis), hemianopsia, pain (thalamic pain), or motor disorders like paralysis, ataxia (Nucleus anterior ventrolateralis) as well as personality changes.

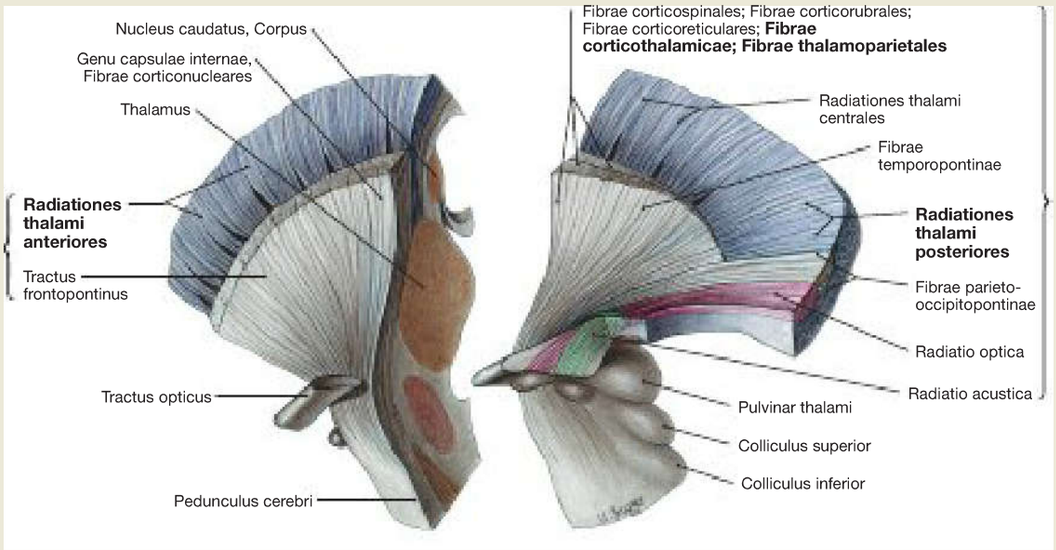

Fig. 12.104 Radiations of the thalamus, Radiationes thalami, and internal capsule, Capsula interna; view from the left side; cut in two parts by a frontal section.

The thalamic nuclei project mainly to the cortex. Their tracts form parts of the Crus anterius and the Crus posterius of the Capsula interna. The tracts include the Radiationes thalami anteriores and posteriores. Other tracts are the Fibrae corticothalamicae and the Fibrae thalamoparietales.

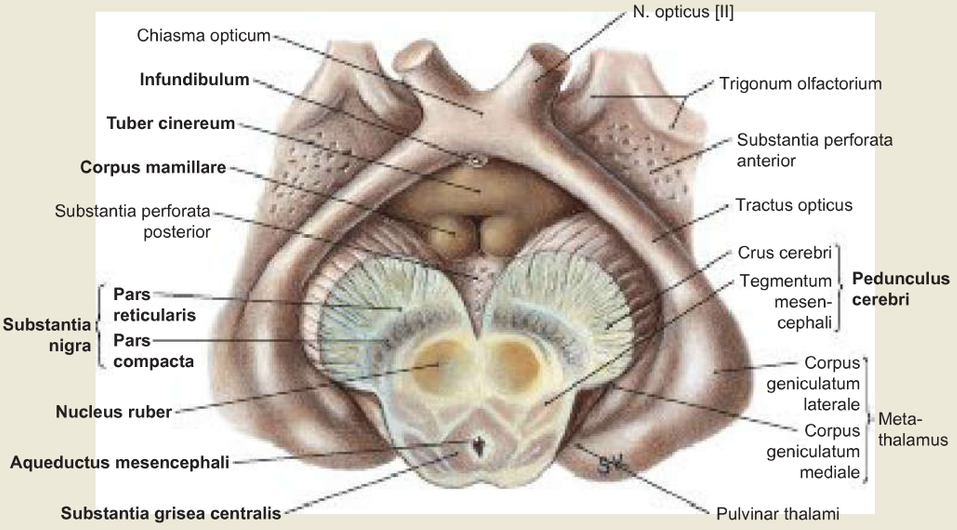

Fig. 12.105 Parts of the hypothalamus; inferior (basal) view. [L238]
Parts of the hypothalamus, extending between the Chiasma opticum, the Tractus optici and the Corpora mamillaria, can be seen from the base of the brain.

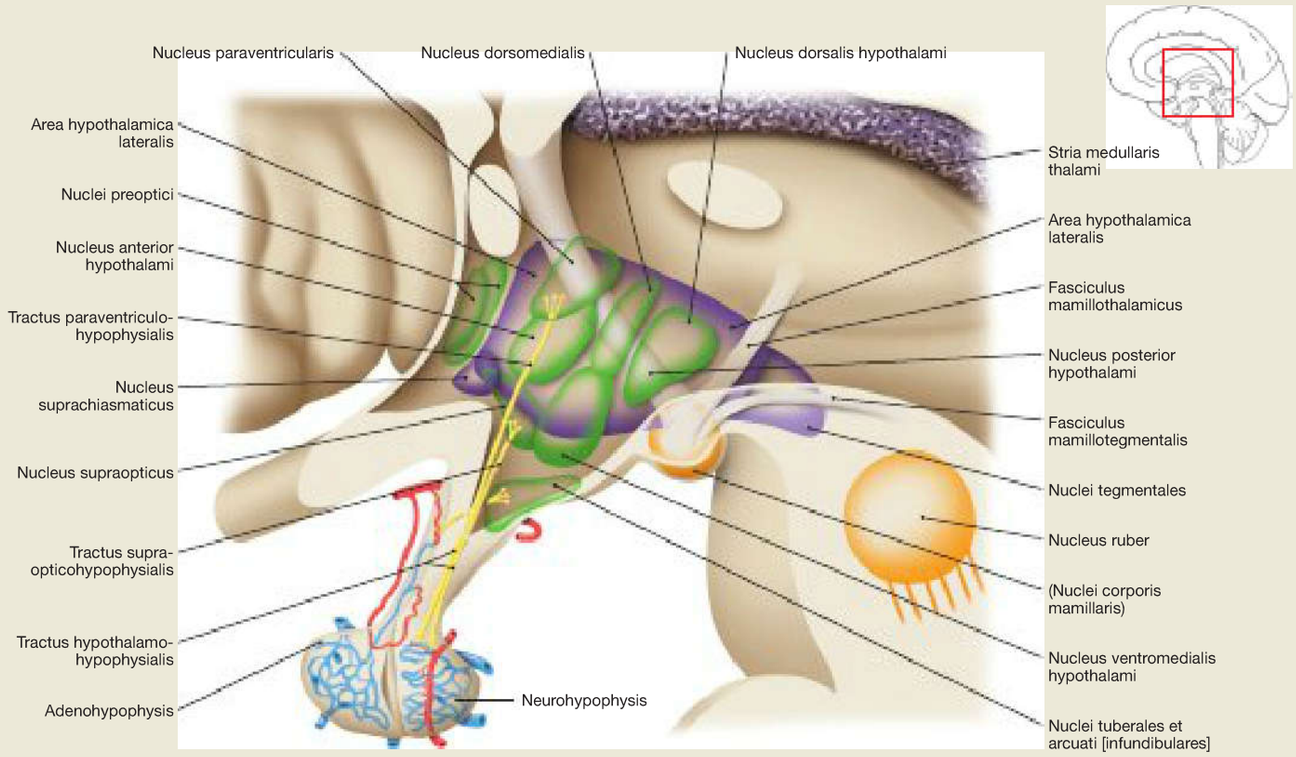

Fig. 12.106 Hypothalamus; medial view; overview, nuclear areas (nuclei) illustrated transparently. [L127]

Forming the floor of the diencephalon, the hypothalamus is the supervisory regulatory centre of the autonomic nervous system.

The hypothalamus has a number of nuclear areas which according to their location are divided into the anterior, middle and posterior groups of nuclei:

- The nuclei of the **chiasmatic or anterior group** include the Nucleus suprachiasmaticus (central pacemaker of circadian rhythms, sleep-wake cycle, body temperature, blood pressure), the Nuclei paraventricularis and supraopticus (production of antidiuretic hormone [ADH] and oxytocin, axonal transport [Tractus hypothalamohypophysialis] in the Neurohypophysis), and the Nuclei preoptici (participate in the regulation of blood pressure, body temperature, sexual behaviour, menstrual cycle, gonadotropin).
- The nuclei of the **intermediate or middle group** include the Nuclei tuberales, dorsomedialis, ventromedialis and arcuatus [infundibularis = semilunaris] (production and secretion of releasing and release-inhibiting hormones, participation in the regulation of water and food intake).
- The nuclei of the **posterior group** include the Nuclei corporis mamillaris in the Corpora mamillaria, which are integrated in the limbic system by afferent fibres from the fornix and efferent fibres to the thalamus (Fasciculus mamillothalamicus). They modulate sexual functions and play an important role in activities related to memory and emotions. They are connected to the Tegmentum mesencephali via the Fasciculus mamillotegmentalis.

The hypothalamus continues downwards (caudally) via the Infundibulum into the pituitary gland, which consists of Neurohypophysis and Adenohypophysis. The portal vein system of the pituitary gland receives blood from the A. hypophysialis superior, a branch of the Pars cerebralis of the A. carotis interna. The blood flow then passes through two venous tributaries. The first is located on the Eminentia mediana of the hypothalamus (zone with neurosecretory axon endings of parvocellular neurons). Here, these neurons release statins and liberins (= releasing and inhibiting hormones) into the venous blood. The second venous system, lying in the Adenohypophysis, takes up the hormones produced here (→ Table, on p. 334), and transports them throughout the body.

Organisation of the Hypothalamus in Regions, Zones, Important Areas and Nuclei

Periventricular Zone	Medial (intermediate) Zone	Lateral Zone
Supraoptic (chiasmatic) Region		
• Nucleus preopticus medianus • Nuclei periventriculares, preopticus et anterior hypothalami • Nucleus suprachiasmaticus	• Area preoptica medialis (Nucleus preopticus medialis) • Area hypothalamica anterior (Nucleus anterior hypothalami) • Nucleus paraventricularis • Nucleus supraopticus • Nuclei interstitiales hypothalami anteriores	• Area preoptica lateralis • Area hypothalamica lateralis • Nuclei interstitiales hypothalami anteriores
Intermediate (tuberal) Region		
• Nucleus arcuatus	• Nucleus ventromedialis • Nucleus dorsomedialis	• Area hypothalamica lateralis • Nuclei tuberales laterales • Nucleus tuberomamillaris
Posterior (mamillary) Region		
• Nucleus periventricularis posterior • Area hypothalamica posterior (Nucleus posterior hypothalami)	• Nuclei mamillares medialis et lateralis	• Area hypothalamica lateralis • Nucleus tuberomamillaris

Diencephalon, Hypothalamus and Pituitary Gland

Afferent and Efferent Fibres of the Hypothalamus	
Important Afferent Fibres to the Hypothalamus	**Important Efferent Fibres of the Hypothalamus**
• Limbic system • Hippocampus • Corpus amygdaloideum • Septal region • Olfactory cortex • Formatio reticularis, posterior horn of the spinal cord, sensory nuclei of the cranial nerves • Retina • Within the hypothalamus • Insular cortex	• Cerebral cortex, thalamic nuclei • Nuclei of the cranial nerves, Formatio reticularis • Spinal cord • Within the hypothalamus • As part of the magnocellular system to the neurohypophysis

Hormones of the Adenohypophysis (Anterior Lobe of the Pituitary Gland)

Hormone	Staining Characteristics	Function	Hypothalamic Regulation via
Pars distalis			
Prolactin (PRL)	acidophil	Milk synthesis	Prolactostatin (dopamine)
Growth hormone (GH, STH)	acidophil	Growth	GHRH (growth hormone-releasing hormone, somatoliberin)
Corticotropin (ACTH)	basophil	Stimulation of the adrenal gland	CRH (corticoliberin)
Melanotropin (α-MSH)	basophil	Pigmentation of the skin	CRH (corticoliberin)
β-Endorphine	basophil	Opioid receptors	CRH (corticoliberin)
Follicle-stimulating hormone (FSH)	basophil	Maturation of ovum/sperm	GnRH
Luteinising hormone (LH)	basophil	Ovulation, Corpus luteum	GnRH
Thyroid-stimulating hormone (TSH)	basophil	Stimulation of thyroid cells	TRH (thyroliberin)
Pars intermedia			
Corticotropin (ACTH)	basophil	Stimulation of the adrenal gland	CRH (corticoliberin)
Melanotropin (MSH)	basophil	Pigmentation of the skin	CRH (corticoliberin)
β-Endorphine	basophil	Binding to opioid receptors	CRH (corticoliberin)
Pars tuberalis			
Specific cells of the Pars tuberalis	chromophobe	Circadian/circa-annual rhythm	? (Melatonin)

Fig. 12.107 The foot of a patient with acromegaly (left side) compared to the foot of a healthy person of the same height. [R236]
The disorder is due to an overproduction of the growth hormone somatotropin (STH) in the anterior lobe of the pituitary gland. The cause is usually a benign tumour in the anterior lobe of the pituitary gland (as a part of the diencephalon).

Clinical Remarks

Lesions of the Nucleus paraventricularis and particularly of the Nucleus supraopticus lead to deficiency of the **anti-diuretic hormone (ADH = vasopressin)**, resulting in a lack of water re-absorption in the collecting tubules of the kidney. This is called **central diabetes insipidus**. In this case, patients pass up to 20 litres of urine daily.
The adenohypophysis can be affected by various tumours. These tumours most commonly secrete prolactin, growth hormone (GH) and corticotropin (CRH). In women, prolactinomas (prolactin-secreting adenoma) suppress the menstrual cycle (amenorrhoea), induce the production of breast milk by the mammary gland (galactorrhoea), and lead to infertility with signs of masculinisation. **Acromegaly** is defined as the distinct enlargement of limbs or protruding parts (acra) of the body like hands, feet (→ Fig. 12.107), chin, mandible, ears, nose, eyebrows, or genitalia. The causal factor is an overproduction of growth hormone **(GH)** in the anterior lobe of the pituitary gland, mainly due to a benign, or rarely, a malignant tumour. If a GH-producing tumour develops in the anterior lobe of the pituitary gland before completion of the longitudinal growth, this results in **gigantism** (pituitary gigantism). After ossification of the epiphyses only the extremities become enlarged. Rarely, corticotropin-producing tumours lead to **CUSHING's syndrome** (with hypertension, striae, abdominal obesity and redness of the cheeks).
Tumours of the pituitary gland can lead to compression of the Chiasma opticum (bitemporal hemianopsia; → Fig. 12.132) or nerves in the Sinus cavernosus (→ Fig. 12.56).

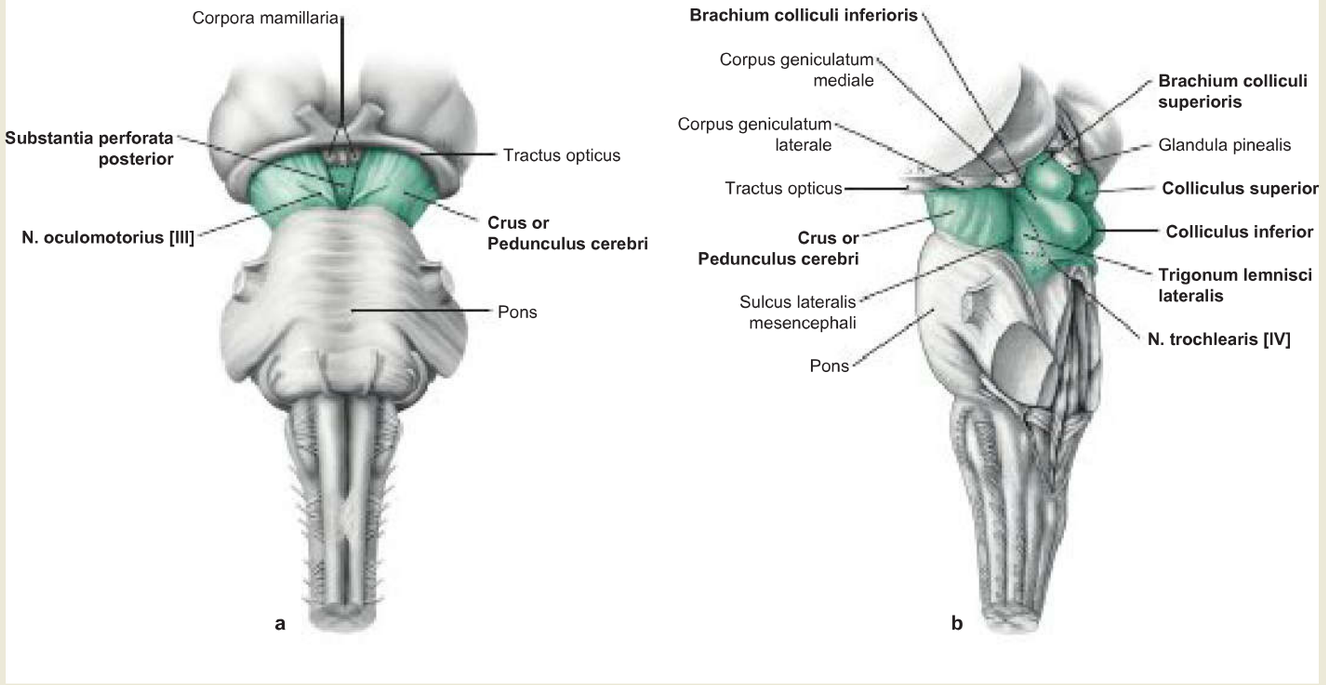

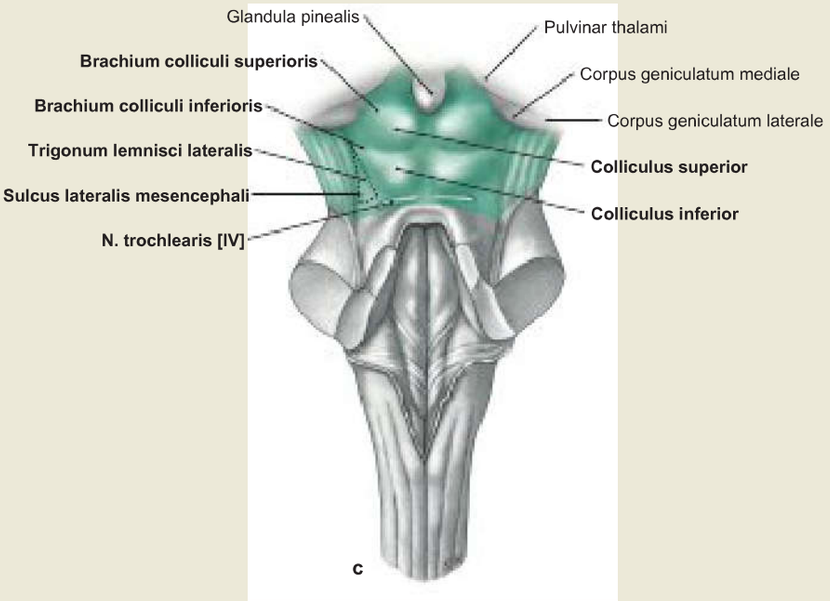

Fig. 12.108a to c Midbrain, Mesencephalon; anterior view (→ Fig. 12.108a), lateral view (→ Fig. 12.108b), posterior view (→ Fig. 12.108c). [L238]
The mesencephalon is the uppermost part of the brain stem. It is bordered above by the diencephalon, and beneath by the pons. The Pedunculi cerebri pass along the anterior surface. The Colliculi superiores and inferiores of the Tectum mesencephali lie on the dorsal side; due to its characteristic form, this structure is called the quadrigeminal plate (Lamina tecti [Lamina quadrigemina]). The Glandula pinealis, as part of the diencephalon, is located above the quadrigeminal plate, and below the mesencephalon follows the fourth ventricle at the level of the pons and the Medulla oblongata.

Clinical Remarks

In the case of supratentorial expanding processes (above the Tentorium cerebelli) (e. g. bleeding, tumour) medial parts of one or both temporal lobes can be compressed in the space between mesencephalon and Tentorium cerebelli **(infratentorial herniation).** This may result in dysfunction of the ipsilateral N. oculomotorius [III] with mydriasis, compression of the pyramidal tract in the Crura cerebri combined with motor deficits, extensor spasms of the extremities and exaggerated reflexes, as well as compressions of the inner tracts and autonomic centres of the Substantia grisea centralis of the mesencephalon. The latter can derange the circulatory regulation and the autonomic system, and lead to loss of consciousness **(midbrain syndrome).**
Endogenous endorphins deploy their effects by binding to opiate receptors – similar to opiates (e. g. morphine and its derivatives), which therefore can be used as compounds of a **central analgesic (pain) therapy**. They stimulate neurons in the Substantia grisea centralis, and thereby activate the endogenous pain-inhibiting system.

Mesencephalon

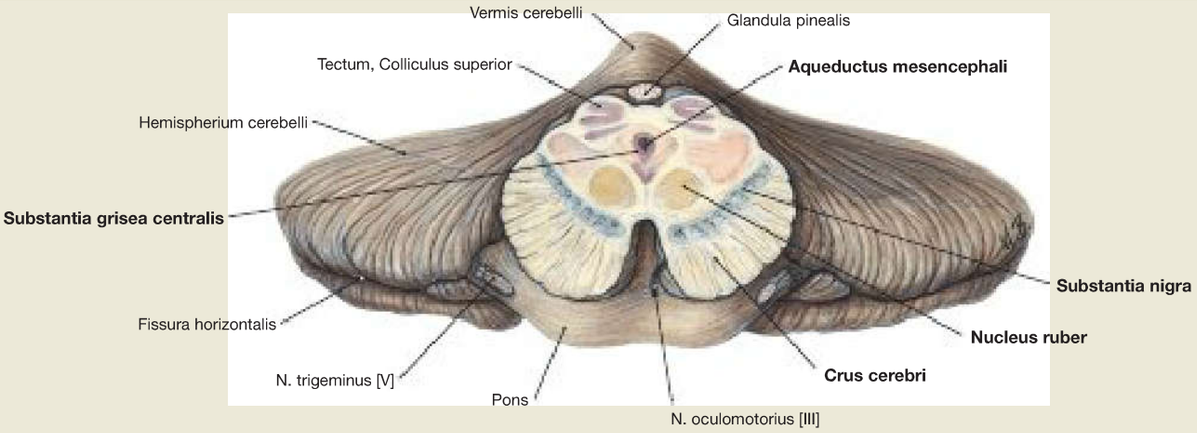

Fig. 12.109 Midbrain, Mesencephalon; cross-section at the level of the Colliculi superiores; anterior view.
The Aqueductus mesencephali passes through the mesencephalon which is divided in Basis, Tegmentum and Tectum mesencephali. Tegmentum and Basis mesencephali are summarised as Pedunculus cerebri. The **Basis mesencephali** comprises the cerebral legs (Crura cerebri), traversed by different tracts (e. g. Fibrae corticonucleares).
The **Tegmentum mesencephali** comprises the Substantia grisea centralis, which surrounds the Aqueductus mesencephali (participates in the central suppression of pain, mediates fear and flight reflexes, regulates autonomic processes), and the Substantia nigra, which belongs to the basal ganglia. Additional structures of the Tegmentum mesencephali include the Nucleus ruber, an important relay station of the motor system, the mesencephalic parts of the Formatio reticularis, the nuclei of the cranial nerves II and IV, as well as ascending and descending tracts.
The **Tectum mesencephali** (Lamina tecti [Lamina quadrigemina]) includes the Colliculi superiores and inferiores, which are important relay stations for visual reflexes (Colliculi superiores) and the central auditory pathway (Colliculi inferiores).

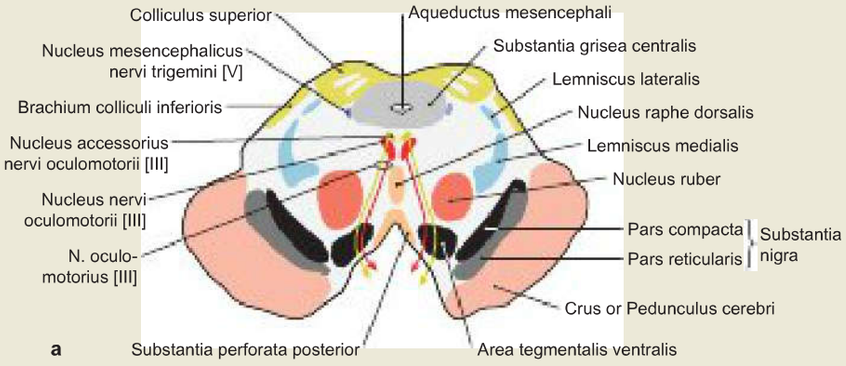

Fig. 12.110a and b Midbrain, Mesencephalon; cross-section of the rostral mesencephalon at the level of the exit of the N. oculomotorius [III]; schematic drawing (→ Fig. 12.110a), anatomic specimen (→ Fig. 12.110b). a [L126], b [R247]
The mesencephalon includes important nuclei, such as the Nucleus nervi oculomotorii, Nucleus nervi trochlearis, Nucleus oculomotorius accessorius (EDINGER-WESTPHAL), Nucleus mesencephalicus nervi trigemini, Nucleus ruber, Substantia nigra and Formatio reticularis, and several major tracts pass through it, only some of which are shown: Tractus corticospinalis, Tractus spinothalamici anterior and lateralis, Tractus tegmentalis centralis, Lemnisci medialis and lateralis, Fasciculi longitudinales medialis and dorsalis, Fibrae corticopontinae, Fibrae corticonucleares, Fibrae temporopontinae.

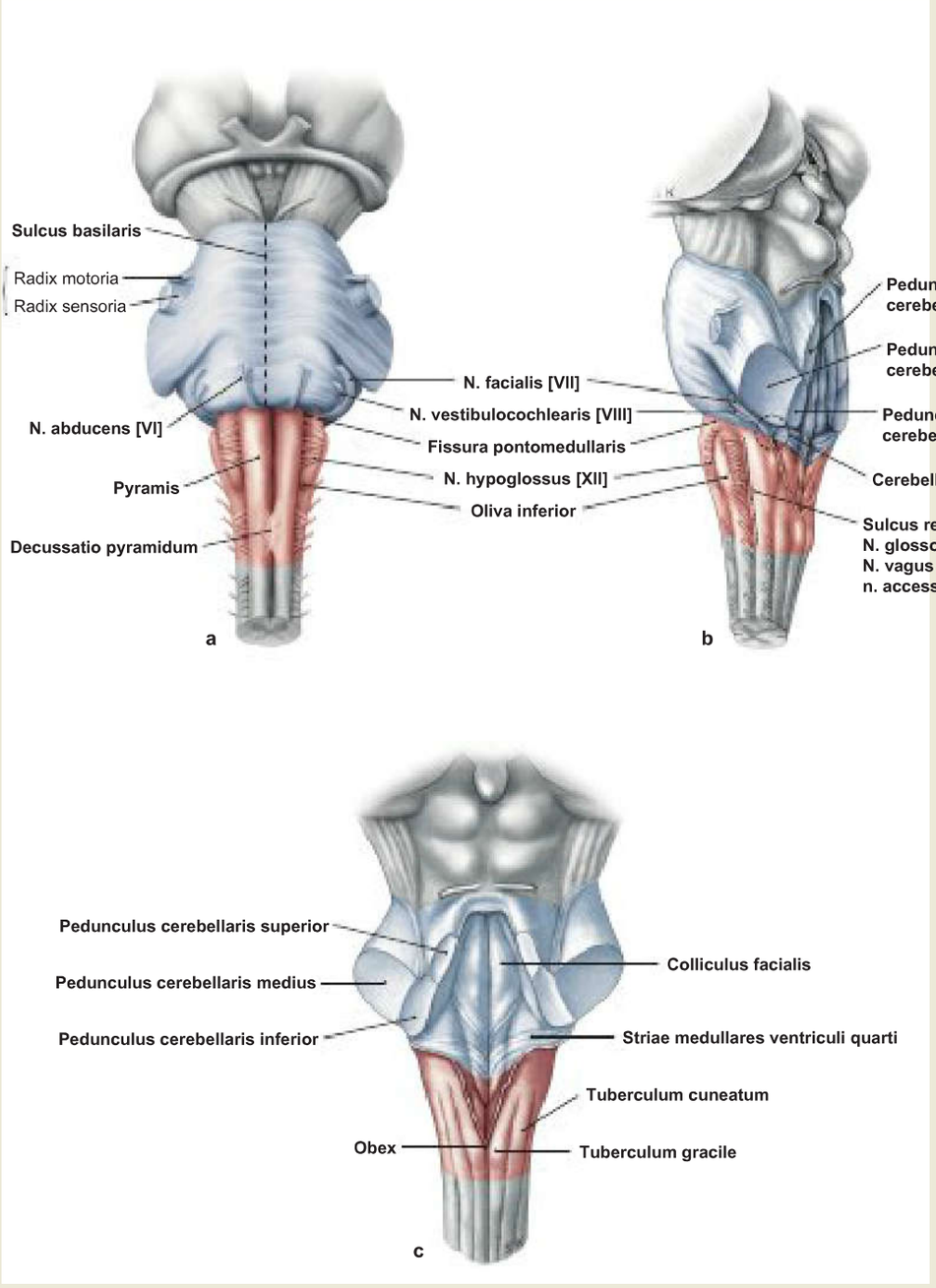

Fig. 12.111a to c Pons and Medulla oblongata; anterior view (→ Fig. 12.111a), lateral view (→ Fig. 12.111b), dorsal view (→ Fig. 12.111c). [L238]
The pons and Medulla oblongata belong together with the cerebellum to the rhombencephalon. The name is derived from the rhomboid fossa (Fossa rhomboidea). It represents the floor of the fourth ventricle and is bordered by the cerebellar peduncles (Pedunculi cerebellares), pons and Medulla oblongata. Within the Fossa rhomboidea, the Sulcus medianus, the Colliculus facialis (fibres of the N. facialis [VII]), and the Striae medullares ventriculi quarti can be distinguished as part of the central auditory pathway.

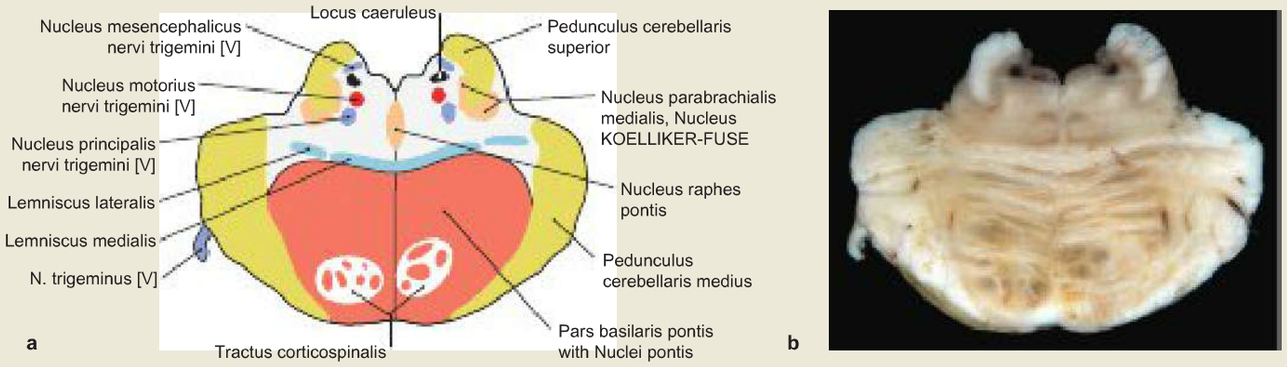

Fig. 12.112a and b Pons; cross-section through the rostral pons at the level of the exit of the N. trigeminus [V]; schematic drawing (→ Fig. 12.112a), anatomic specimen (→ Fig. 12.112b). a [L126], b [R247]
In the region of the Fossa rhomboidea, important **nuclei responsible for the regulation of the systemic circulation**, as well as the nuclei of the **cranial nerves** V to X (→ Fig. 12.127, → Fig. 12.128), and partly of the cranial nerves XI and XII, are located in the pons and medulla oblongata. The pons receives sensory information in particular from the auditory tube and the face and sends it to the cerebellum.

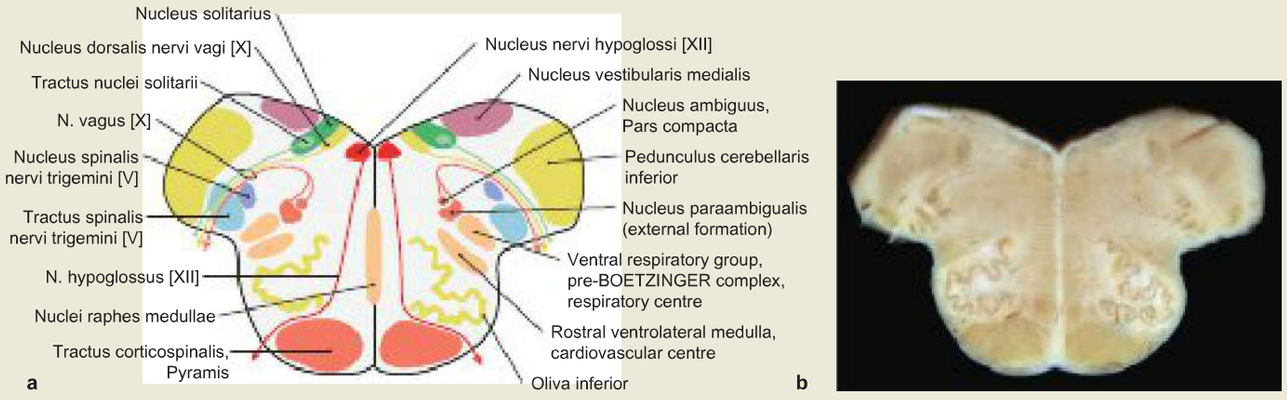

Fig. 12.113a and b Medulla oblongata; cross-section through the rostral Medulla oblongata at the level of the exit of the N. vagus [X]; schematic drawing (→ Fig. 12.113a), anatomic specimen (→ Fig. 12.113b). a [L126], b [R247]
In the Medulla oblongata, a functional distinction is made between three parts: Tegmentum, Pyramis and Oliva. The Tegmentum with the nuclei of the cranial nerves lies dorsally, the Pyramis and Oliva are located ventrally. The Medulla oblongata harbours important neuronal centres for the control of blood circulation, the respiratory centre, the vomiting centre and the centres for the sneezing, coughing, swallowing and sucking reflexes. In addition, the receptors for the regulation of acid-base homeostasis are found here (→ Table, on p. 339).

Clinical Remarks

Bulbar paralysis refers to a bilateral lesion of all motor nuclei of cranial nerves in the Medulla oblongata. This leads to paralysis of the lingual and pharyngeal muscles with subsequent atrophy, swallowing and speech disorders (slurred speech). A possible cause can be neurodegenerative disease of motor neurons such as the amyotrophic lateral sclerosis (ALS).

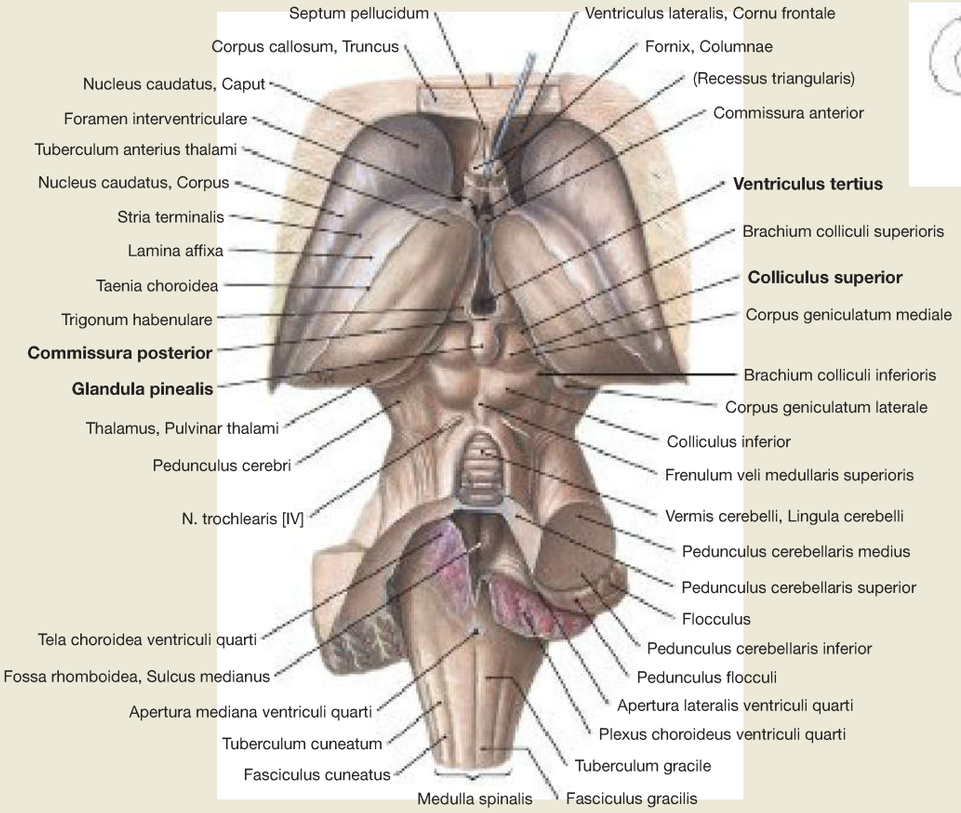

Fig. 12.114 Brain stem, Truncus encephali; posterior view from above; after removal of the Corpus callosum and major parts of the cerebellum, the Tela choroidea of the fourth ventricle was split in the middle and folded back to the right side. [L238]

Important functional **centres** (→ Table) are located in the brain stem.

Overview of the Functional Anatomy of the Brain Stem

Centre/System	Function/Reflex	Nuclei or Brain Region	Participating Afferent Cranial Nerves	Nuclei of Efferent Cranial Nerves or Spinal Cord
Eye/Vision	Pupillary reflex	Area pretectalis	N. opticus [II]	Nucleus accessorius nervi oculomotorii [III]
	Oculomotor function	Preoculomotor centres, Colliculi superiores	N. opticus [II]	Nucleus nervi oculomotorii [III], Nucleus nervi trochlearis [IV], Nucleus nervi abducentis [VI]
	Corneal reflex, eyelid closure		Nucleus principalis nervi trigemini [V]	Nucleus nervi facialis [VII]
Ear/Hearing	Directional hearing, head rotation to the sound source	Nucleus olivaris superior, Corpus trapezoideum, Colliculi inferiores	Nuclei cochleares [VIII]	Spinal cord (cervical anterior horn)
Balance/ Equilibrium	Posture, spatial orientation	Nucleus olivaris inferior, cerebellum	Nuclei vestibulares [VIII]	Spinal cord
Nose	Sneezing reflex	Respiratory centre, ventrolateral Medulla oblongata	Nucleus principalis nervi trigemini [V/2]	Nucleus ambiguus (IX, X), spinal cord (anterior horn)
Gastrointestinal Tract	Taste, saliva		Rostral part of the Nucleus tractus solitarii (VII, IX, X)	Nucleus salivatorius superior [VII] and Nucleus salivatorius inferior [IX]
	Swallowing	Swallowing centre, ventrolateral Medulla oblongata	Nucleus principalis nervi trigemini (V/2, V/3), medial Nucleus tractus solitarii (IX, X)	Nucleus motorius nervi trigemini [V/3], Nucleus nervi facialis [VII], Nucleus ambiguus (IX, X), Nucleus nervi hypoglossi [XII]
	Vomiting	Area postrema	Medial Nucleus tractus solitarii [X]	Nucleus dorsalis nervi vagi [X]
	Digestion (juices and peristalsis)		Medial Nucleus tractus solitarii [X]	Nucleus dorsalis nervi vagi [X]
Breathing/ Respiration	Respiratory reflexes (including lung expansion reflex, cough reflex)	Respiratory centre, ventrolateral Medulla oblongata	Lateral Nucleus tractus solitarii [X]	Nucleus ambiguus (IX, X), Nucleus nervi hypoglossi [XII], spinal cord (anterior horn)
Heart/Circulation	Circulatory reflexes (including baroreceptor and chemoreceptor reflexes)	Circulation centre, rostral ventrolateral Medulla oblongata (RVLM)	Dorsolateral Nucleus tractus solitarii (IX, X)	Nucleus ambiguus, external formation [X], sympathetic nervous system, spinal cord (lateral horn)

Cerebral Areas

Truncus encephali and Cerebellum

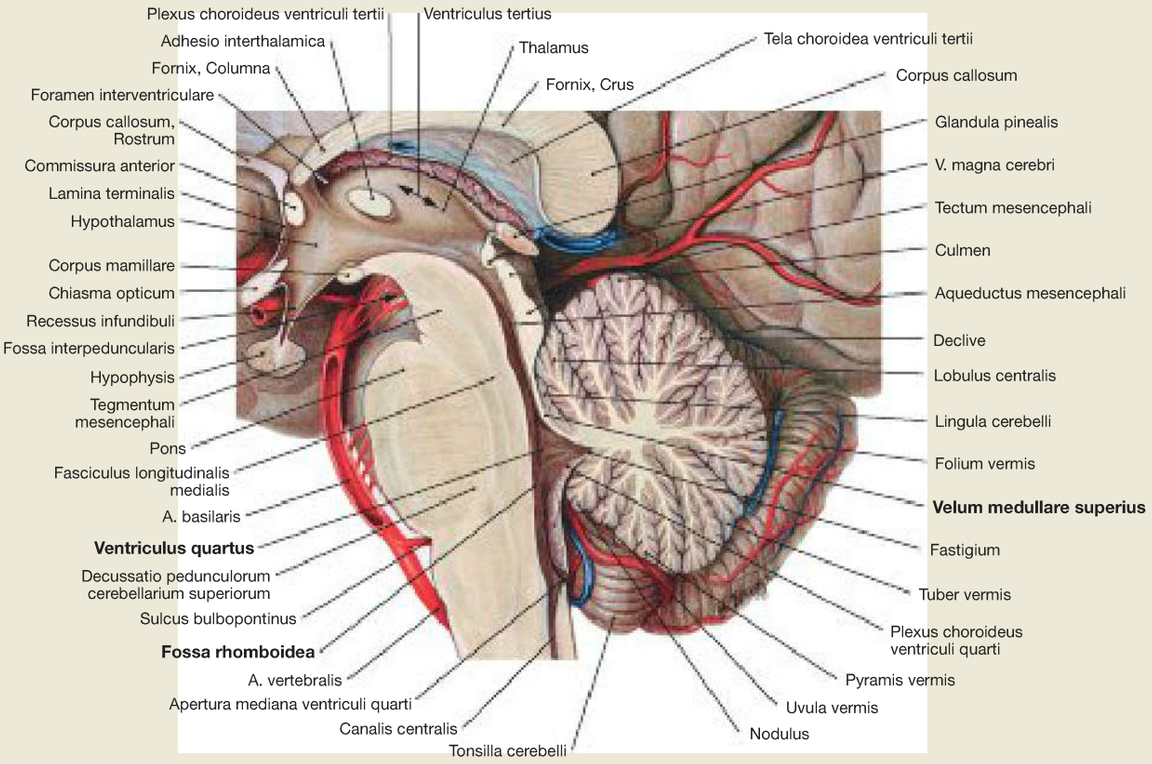

Fig. 12.115 Brain stem, Truncus encephali, with the fourth ventricle, Ventriculus quartus, and the cerebellum; median section.
A few, relatively small nuclear areas located in the brain stem use the serotonergic and other aminergic (e. g. dopaminergic, histaminergic and noradrenergic) systems, to reach large portions of the brain and spinal cord via highly ramified axon fibres (→ Table).
Apart from the brain stem, the median section reveals the characteristic structure of the so-called tree of life **(arbor vitae)** of the cerebellum created by distinct grooves (surface enlargement) of the cerebellar cortex.
The Fossa rhomboidea is located in front of the cerebellum and forms the floor of the fourth ventricle. Anterior to the ventricle lies the brain stem with mesencephalon, pons and Medulla oblongata, whereas the A. basilaris runs on the brain stem, and thus even further anteriorly. In the median section one can see how the posterior wall of the fourth ventricle continues as Velum medullare superius from the cerebellum to the quadrigeminal plate (Lamina tecti [Lamina quadrigemina]). The pineal gland (Glandula pinealis) and the Corpus callosum are located on top.

Monoaminergic Neurotransmitter Systems of the Brain Stem

Nuclei/Nuclear Area	Location in the Brain Stem	Neurotransmitter Used	Targets of Projections
Substantia nigra, Pars compacta	Border between Basis and Tegmentum mesencephali	Dopamine	Striatum
Area tegmentalis ventralis (ventral tegmental area, VTA)	Tegmentum mesencephali	Dopamine	Cerebral cortex, limbic system, Nucleus accumbens
Nucleus or Locus caeruleus	Part of the Formatio reticularis in the Tegmentum pontis	Noradrenaline	Cerebral cortex, limbic system, thalamus, hypothalamus, cerebellum
Raphe nuclei	Groups of Nuclei raphe from the mesencephalon up to the Medulla oblongata	Serotonin	CNS (whole)

Clinical Remarks

Affective disorders such as depression are common psychiatric disorders. Based on present knowledge, the noradrenergic projections of the Nucleus caeruleus, as well as the serotonergic projections of the Nuclei raphe play a role in this context. It is assumed that a lack of noradrenaline and/or serotonin in the synaptic gap may be the causal factor, since in many patients a significant improvement of their symptoms could be observed if the deficiency was antagonised by continuous medication with selective noradrenaline and/or selective serotonin re-uptake inhibitors.

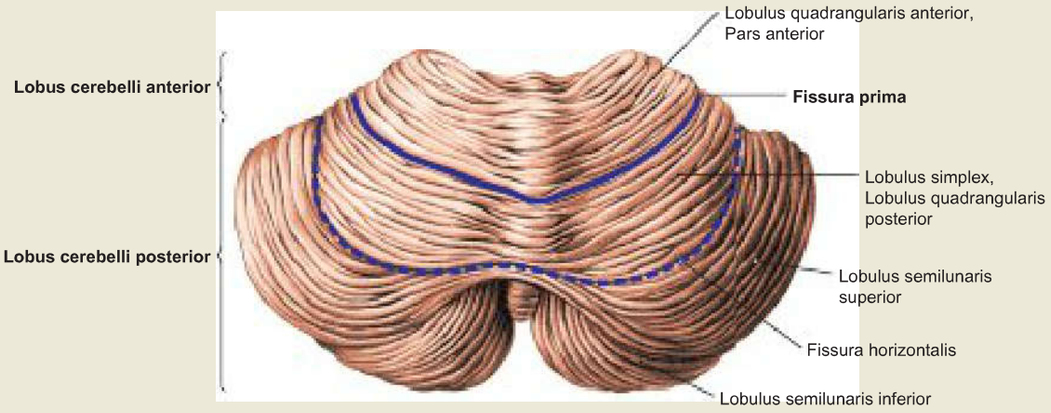

Fig. 12.116 Cerebellum; posterior view from above (superior surface). The cerebellum consists of the **vermis** (Vermis cerebelli) and two **hemispheres**. Of the vermis, the tuber, folium, declive and culmen are visible, as well as the Lobulus centralis and the Lingula cerebelli. The cerebellar hemispheres are divided into **three lobes** respectively (→ Fig. 12.122):

- Lobus cerebelli anterior
- Lobus cerebelli posterior
- Lobus flocculonodularis (Nodulus + Flocculus, → Fig. 12.118)

The lobes are subdivided into **lobules** such as the Lobulus quadrangularis anterior, the Lobulus quadrangularis posterior (Lobulus simplex) as well as the Lobuli semilunares superior and inferior.
The superior surface faces the Tentorium cerebelli. The Fissura prima and the Fissura horizontalis are clearly recognisable. The Fissura horizontalis is not a functional limitation, but forms a separating line between the superior and inferior surfaces.

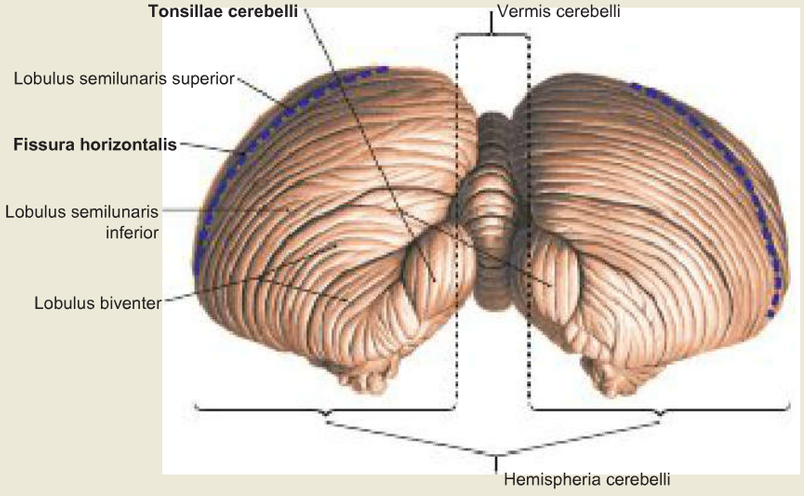

Fig. 12.117 Cerebellum; posterior view from below (inferior surface). The inferior surface lies opposite the Os occipitale and the Cisterna cerebellomedullaris. In this view, the vermis and the two cerebellar hemispheres are visible. Furthermore, one can see the paired tonsil of the cerebellum (Tonsilla cerebelli) as well as the Lobuli semilunares superior and inferior, which are separated by the Fissura horizontalis. The Lobulus biventer joins the Lobulus semilunaris inferior from below.

Clinical Remarks

With increased intracranial pressure (e.g. from a tumour or bleeding), the cerebellar tonsils, as the most caudal structures of the cerebellum, can become trapped between the bone and the Medulla oblongata in the Foramen magnum. The resulting compression of the Medulla oblongata can cause the failure of vital structures, such as the respiratory centre, which can be fatal. This **infratentorial herniation** is juxtaposed with the **supratentorial herniation** (herniation of the mesencephalon in the Incisura tentorii) with the possible consequence of midbrain syndrome (failure of the Formatio reticularis, as well as the corticobulbar and rubrospinal tracts). The latter precedes the infratentorial herniation.

Cerebellum

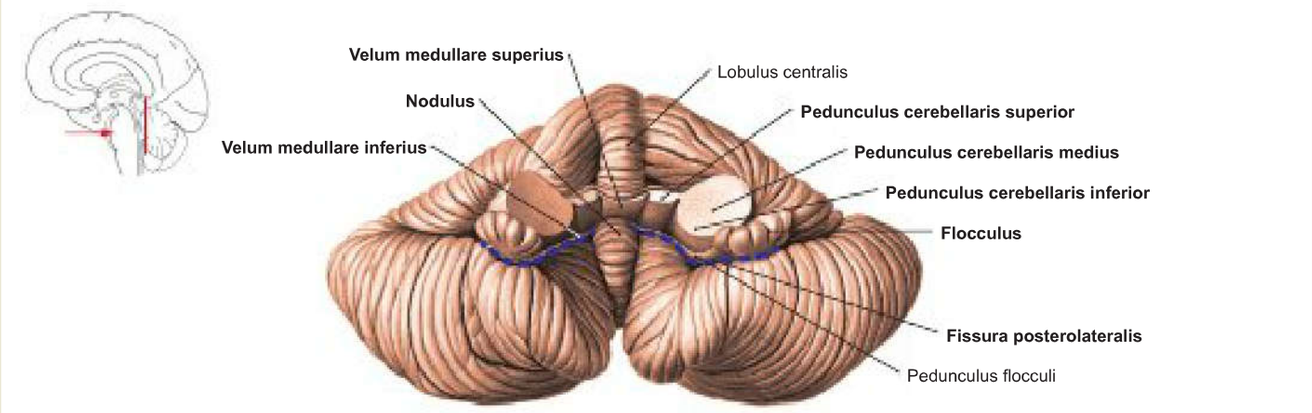

Fig. 12.118 Cerebellum; anterior view; after dissection of the cerebellar peduncles (anterior surface).
The anterior surface shows the cerebellar peduncles which connect the cerebellum to the brain stem: Pedunculi cerebellares superior, medius and inferior. The Velum medullare superius divides the vermis of cerebellum (Vermis cerebelli) and connects both cerebellar peduncles. The paired Velum medullare inferius located on the left and the right side of the Nodulus continues on both sides towards the Flocculus. The cerebellar hemispheres form the outer parts.

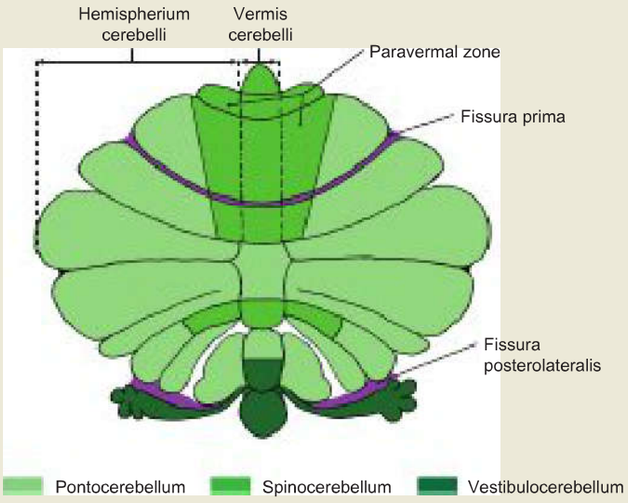

Fig. 12.119 Cerebellum; schematic, functional-anatomic segmentation of the extended cerebellar cortex. [R247]
Functionally, the cerebellum is divided into three parts:

- **Pontocerebellum** (coordination of precise voluntary motor function/system and speech muscles)
- **Spinocerebellum** (regulation of muscle tone, and together with the vestibulocerebellum, control of postural motor function/system)
- **Vestibulocerebellum** (control of the postural motor system = stabilisation of posture and gait, fine-tuning of eye movements, and coordination of both functions with the vestibular system = maintenance of balance)

Clinical Remarks

Typical sign of **damage to the pontocerebellum** is an intention or cerebral tremor when executing directed voluntary movements. This tremor in the extremities gradually increases, the closer the extremity approaches the target. The impaired muscular movement or coordination is associated with ataxias ('asynergies'), which manifest as dysmetria (also described as an inability to judge distance or scale) and dysdiadochokinesis (impaired ability to perform rapid, alternating movements).
Lesions of the spinocerebellum lead to disorders of coordinated movement sequences that are not easily corrected. The failed or severely impaired coordination of agonistic and antagonistic muscles results in ataxias of posture and gait (static and dynamic ataxias) as well as exaggerated and shortened movements (dysmetrias).

Lesions of the vestibulocerebellum are in particular associated with impaired equilibrium or balance. Only to a very limited extent are patients capable of using vestibular information to control their eye movements when moving the head, and their axial and limb muscles when standing, walking or sitting (trunk, gait, and postural ataxia; disorders of movement coordination). Insufficient motor coordination of the gaze (by the eye muscles) can lead, among others, to spontaneous nystagmus and involuntary saccadic (jerky) eye movements.

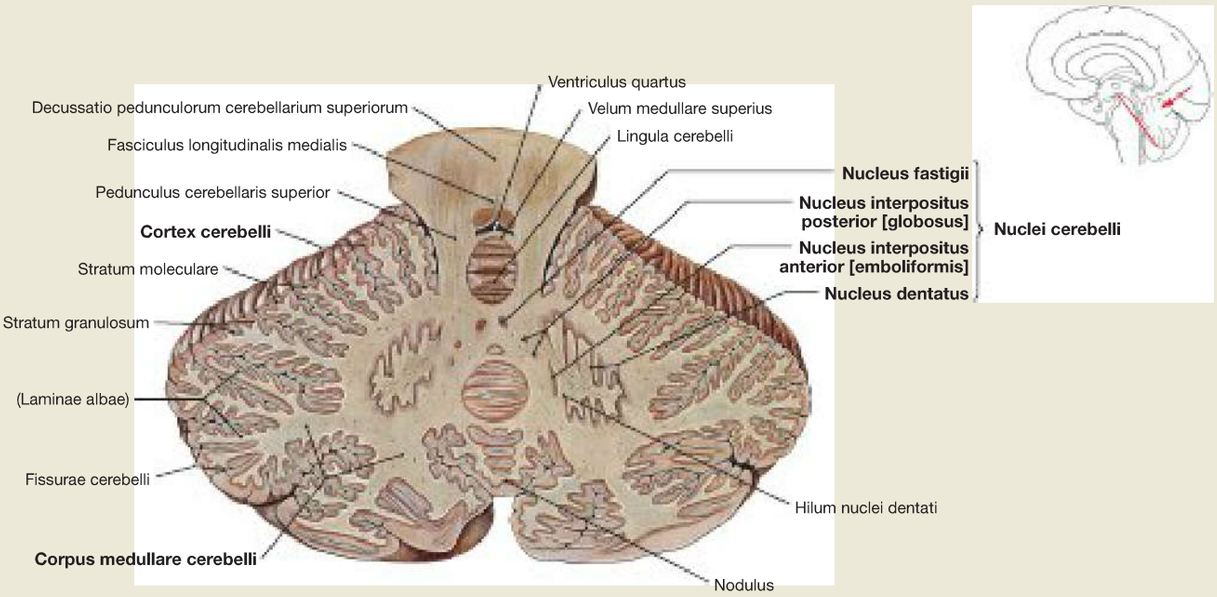

Fig. 12.120 Cerebellum with cerebellar nuclei, Nuclei cerebelli; flat cross-section through the upper cerebellar peduncles; posterior view. The cerebellum consists of the Corpus medullare cerebelli which surrounds the embedded cerebellar nuclei, as well as the **cerebellar cortex** (Cortex cerebelli). The flat cross-section reveals all four cerebellar nuclei in both hemispheres (pontocerebellum). The **Nucleus dentatus** ('tooth-like' nucleus) is U-shaped and jagged. The **Nucleus emboliformis** ('plug-like' nucleus) is located medially of the Nucleus dentatus and forms together with the further medially located **Nucleus globosus** ('ball-like' nucleus) the **Nucleus interpositus**. Both nuclei share many functional similarities and are connected to the paravermal zone and the vermis of the cerebellum (spinocerebellum). The right and left **Nucleus fastigii,** located in the semioval centre of the vermis, are functionally closely related to the cortex of the Lobus flocculonodularis (vestibulocerebellum). The cerebellar nuclei contain mainly multipolar nerve cells with efferent fibres projecting into other regions of the brain.

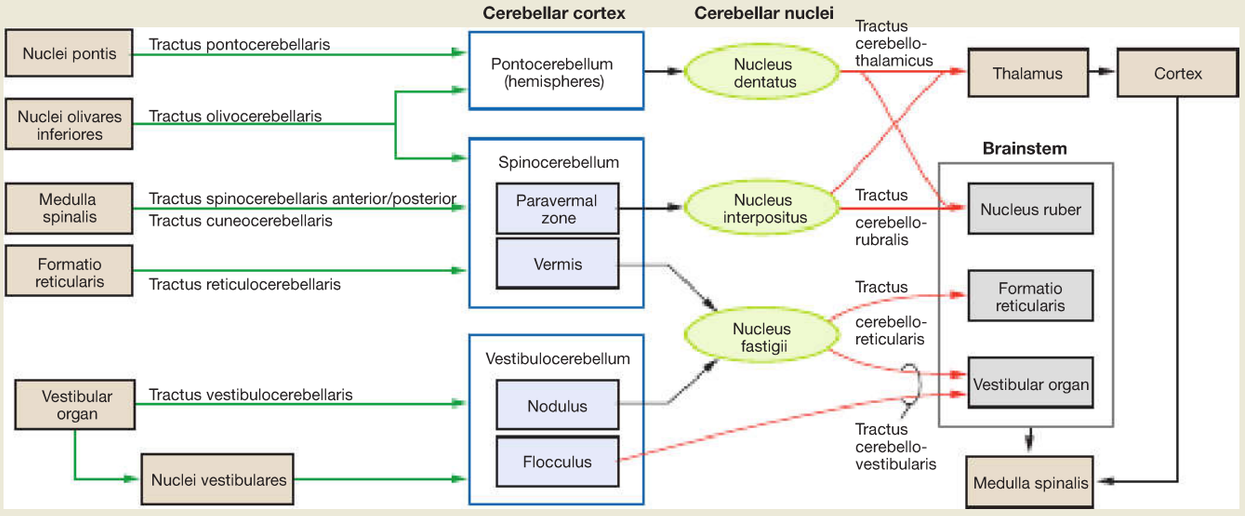

Fig. 12.121 Schematic representation of the cerebellar compartments with corresponding afferent and efferent connections. [R254]

Clinical Remarks

In the past, it was assumed that the cerebellum and its circuits had nothing to do with higher brain functions, such as e. g. social interaction and communication. Due to cerebellar malfunctions it has become evident now that this is not the case. The integrity of the PURKINJE's cells as typical cells of the cerebellum seems to play an important role. Postmortal dissections of brains showed a reduced number of PURKINJE's cells in certain cerebellar cortical areas of patients with **autism**.

Alcoholism **(chronic alcohol abuse)** can result in irreversible damage of the cerebellum, particularly in atrophy of the Vermis cerebelli. This pathological process leads to partial destruction of the nodulus (vestibulocerebellum), as well as of the vermis and paravermal zone (spinocerebellum). The patients can no longer coordinate their eye movements and suffer from balance disorders (stance and gait disorders with staggering and a tendency to fall).

Due to its integration into the chain 'cerebellum – Nucleus ruber – cerebellum – olive – cerebellum', **lesions of the Nucleus ruber** can cause the same symptoms as with cerebellar lesions, such as intention tremor and decreased muscle tone.

Cerebral Areas

Cerebellum

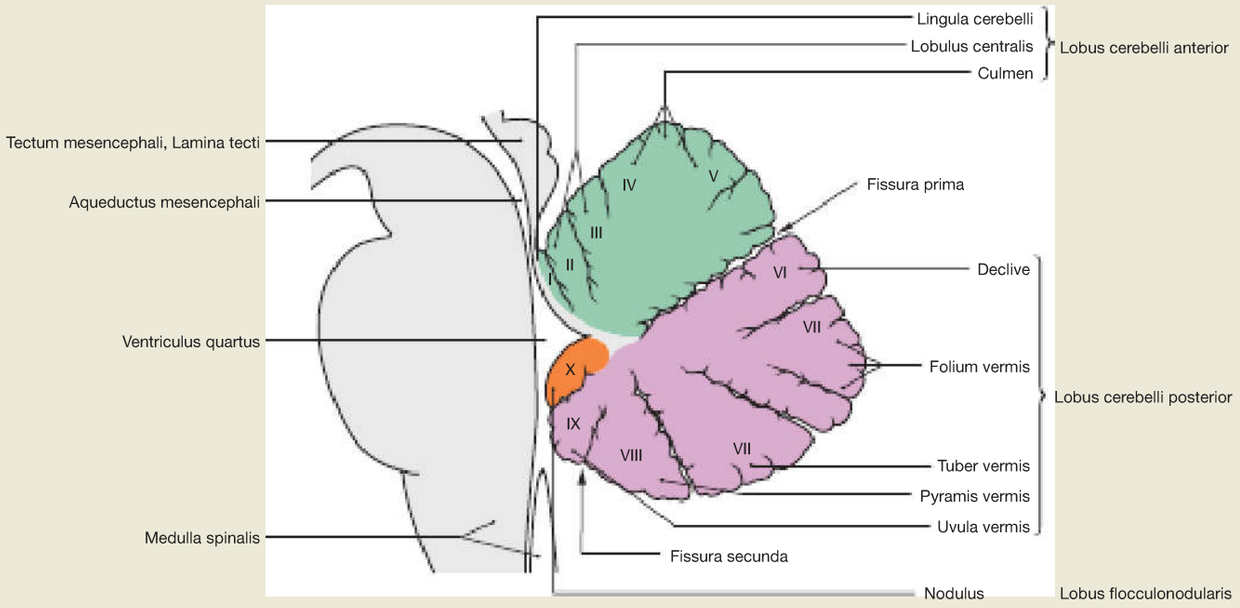

Fig. 12.122 Vermis of the cerebellum, Vermis cerebelli, parts I to X; median section; overview.
The Vermis cerebelli is the unpaired median part of the cerebellum, which connects the two cerebellar hemispheres (Hemispheria cerebelli).

Structure of the Vermis cerebelli (Roman numerals according to the classification of LARSELL)	
I	Lingula cerebelli
II, III	Lobus centralis
IV, V	Culmen
Fissura prima	
VI	Declive
VII A	Folium vermis
Fissura horizontalis	
VII B	Tuber vermis
VIII	Pyramis vermis
Fissura secunda	
IX	Uvula vermis
Fissura posterolateralis	
X	Nodulus

Overview

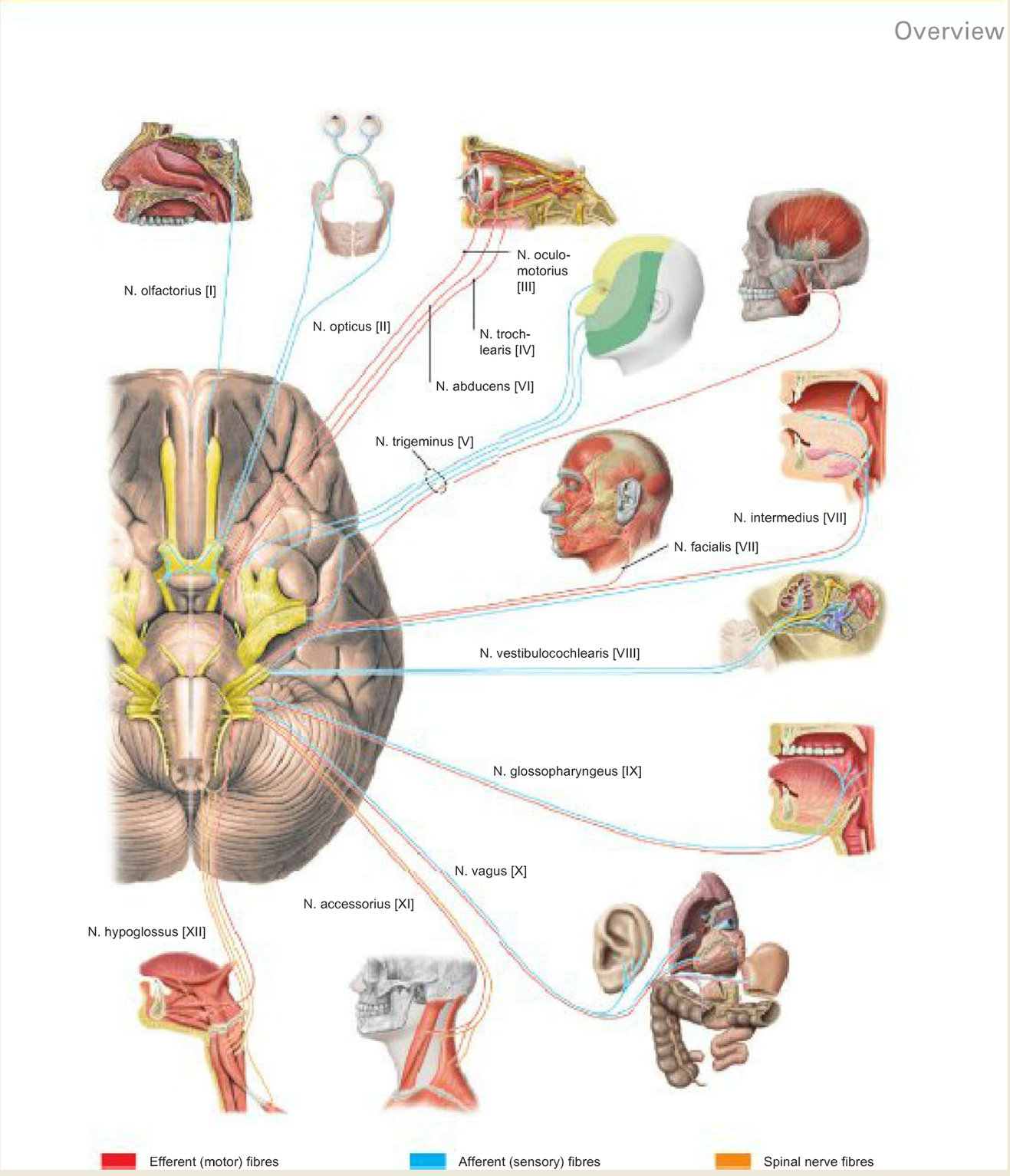

Fig. 12.123 Cranial nerves, Nn. craniales; functional overview of cerebrum, brain stem (Truncus encephali) and cerebellum; inferior view. [L127]

Twelve pairs of cranial nerves leaving the cranial base are numbered with Roman numerals (I–XII) in the order of their exit (from anterior to posterior). The first cranial nerve is formed by the Fila olfactoria, which are collectively named **N. olfactorius [I]**. The bipolar olfactory neurons (the sensory ganglion in the olfactory mucosa is unnamed) project via the fila into the Bulbus olfactorius, a part of the telencephalon that was relocated cranially during development. Therefore, the olfactory bulb represents the Nucleus terminationis of the N. olfactorius [I], with the exception that it is not located in the brain stem but further advanced on the Lamina cribrosa. Thus, the first cranial nerve differs from the others because its neurons are very short, and its terminal nucleus is not located in the brain stem. Another exception applies to the **N. opticus [II]**, which includes the third or even fourth neuron of the visual pathway, and in contrast to all other cranial nerves, the optic nerve is a protrusion of the diencephalon and not a peripheral nerve in the narrower sense.

→ T 56, 58

Overview

Overview of the Twelve Cranial Nerves and Their Most Important Innervation Sites [R254]
A more detailed description of the innervation sites of all cranial nerves follows on pages 352 –391.
GSA: general somatic afferent; GSE: general somatic efferent; GVA: general visceral afferent; GVE: general visceral efferent; SSA: special somatic afferent; SVA: special visceral afferent; SVE: special visceral efferent

Cranial Nerve	Qualities	Important Innervation Area
N. olfactorius [I]	SSA	Olfactory mucosa
N. opticus [II]	SSA	Retina
N. oculomotorius [III]	GSE, GVE	Eye muscles (intraocular, extraocular)
N. trochlearis [IV]	GSE	Extraocular muscles
N. trigeminus [V]	SVE, GSA	Muscles of mastication, facial skin
N. abducens [VI]	GSE	Extraocular muscles
N. facialis [VII]	GVE, SVE, SVA, GSA	Mimetic (facial) muscles, gustatory organ, glands
N. vestibulocochlearis [VIII]	SSA	Vestibular and hearing organ
N. glossopharyngeus [IX]	GVE, SVE, GSA, GVA, SVA	Pharyngeal muscles, parotid gland
N. vagus [X]	GVE, SVE, GSA, GVA, SVA	Pharyngeal muscles, larynx, internal organs
N. accessorius [XI]	SVE	M. trapezius and M. sternocleidomastoideus
N. hypoglossus [XII]	GSE	Muscles of the tongue

Overview of Cranial Nerves with Two or More Nuclei in the Brain Stem [R254]
The Nn. trochlearis [IV], abducens [VI], accessorius [XI] and hypoglossus [XII] each possess only one identically named nucleus and are therefore not mentioned here.

Nerve	Corresponding Nuclei
N. oculomotorius [III]	• Nucleus nervi oculomotorii • Nucleus accessorius nervi oculomotorii
N. trigeminus [V]	• Nucleus motorius nervi trigemini • Nucleus mesencephalicus nervi trigemini • Nucleus pontinus (sensorius principalis) nervi trigemini • Nucleus spinalis nervi trigemini
N. facialis [VII]	• Nucleus nervi facialis • Nucleus salivatorius superior • Nucleus spinalis nervi trigemini • Nuclei tractus solitarii
N. vestibulocochlearis [VIII]	• Nuclei vestibulares • Nuclei cochleares
N. glossopharyngeus [IX]	• Nucleus salivatorius inferior • Nucleus ambiguus • Nucleus spinalis nervi trigemini • Nuclei tractus solitarii
N. vagus [X]	• Nucleus dorsalis nervi vagi • Nucleus ambiguus • Nucleus spinalis nervi trigemini • Nuclei tractus solitarii

Overview of Nuclei with Areas Allocated to Two or More Cranial Nerves [R254]
All other nuclei can be ascribed to one cranial nerve respectively.

Nucleus	Corresponding Cranial Nerve
Nucleus ambiguus	• N. glossopharyngeus [IX] • N. vagus [X] • N. accessorius [XI] (Radix cranialis)
Nuclei tractus solitarii	• N. facialis [VII] • N. glossopharyngeus [IX] • N. vagus [X]
Nucleus spinalis nervi trigemini	• N. trigeminus [V] • N. facialis [VII] • N. glossopharyngeus [IX] • N. vagus [X]

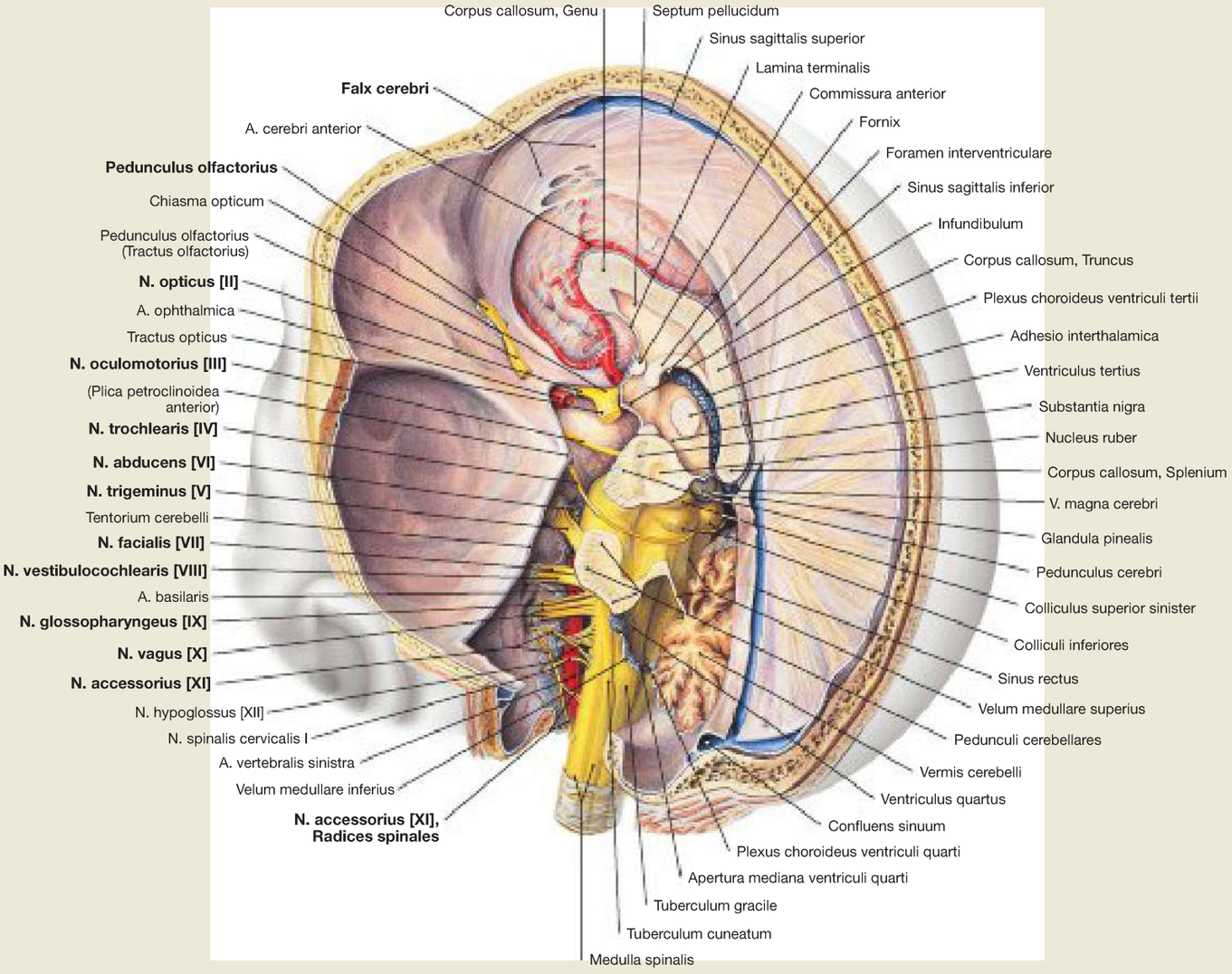

Fig. 12.124 Course of the cranial nerves, Nn. craniales, in the subarachnoid space; posterior superior view from the left side; after removal of the left cerebral and cerebellar hemispheres and of the Tentorium cerebelli.

The cranial nerves III to XII exit the brain stem according to their sequence in the cranial to caudal order. Some nerves exit as a bundle of nerve roots, which form the actual cranial nerve (IX–XII) later on. The N. trochlearis [IV] is the thinnest of all cranial nerves and the only one exiting the brain stem on the posterior aspect. The N. abducens [VI] has the longest intradural passage before its exit at the cranial base.

→ T 58

Characteristics of the Cranial Nerves Compared to Spinal Nerves	
Spinal Nerves	**Cranial Nerves**
Segmental arrangement	Without segmental arrangement
31 pairs of spinal nerves (mostly)	12 pairs of cranial nerves
Exiting the Medulla spinalis	Exiting the Truncus encephali
Passage through segmentally arranged Foramina intervertebralia	Passage through non-segmentally arranged openings in the cranial base
4 functional fibre qualities	7 functional fibre qualities
Target organs located primarily below the upper thoracic aperture	Target organs located primarily above the upper thoracic aperture

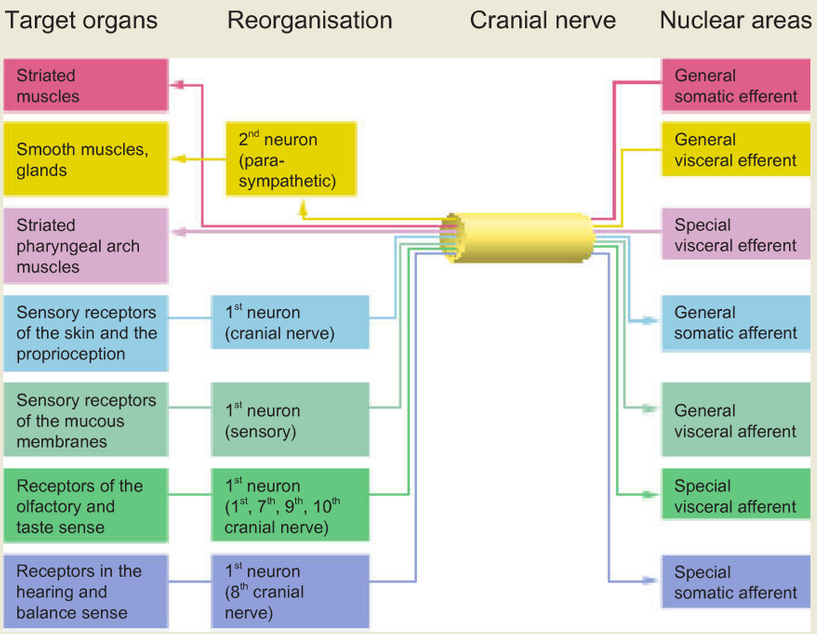

Fig. 12.125 Fibre qualities of the cranial nerves (nuclei); coloured presentation of the fibre qualities of the cranial nerves (nuclei) with possible circuits or relay stations, and the respective target organs. [L127]

Seven different fibre qualities of cranial nerves can be distinguished (→ Table), however not every cranial nerve contains all of these fibre qualities.

Fibre Qualities of Efferent and Afferent Nerve Fibres	
Fibre Quality	**Innervation**
Efferent Nerve Fibres	
General somatic efferent	Motor: skeletal muscles
General visceral efferent	Parasympathetic: glands, smooth muscles
Special visceral efferent	Brachiomotor: pharyngeal arch muscles
Afferent Nerve Fibres	
General somatic afferent	Proprioceptive (joints, muscles) and exteroceptive (sensitivity of the skin)
General visceral afferent	Enteroceptive (sensitivity of the mucosa; blood vessels)
Special visceral afferent	Smell and taste organ
Special somatic afferent	Sensory: vision, hearing and vestibular organ

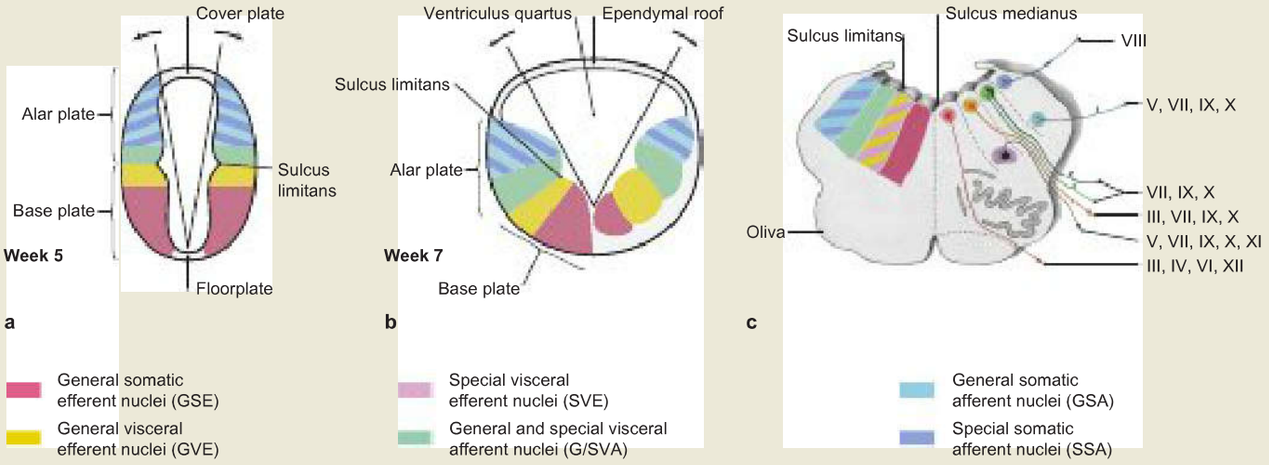

Fig. 12.126a to c Development of the rhombencephalon and mediolateral arrangement of the nuclei of the cranial nerves, according to their function. a, b [L126]
a The primary arrangement in the neural tube has a dorsoventral orientation (week 5 of development).
b This arrangement changes gradually with the enlargement of the Canalis centralis to the fourth ventricle (in week 7 of development), and becomes a mediolateral arrangement.
c The individual fibre qualities are assigned to the respective nuclei of the cranial nerves.

In the brain stem, nuclei with similar functions are arranged in columns on top of each other. Due to spatial restrictions, the nuclei form four longitudinal **nuclear columns** lying parallel to each other. In a medial to lateral direction this arrangement includes a somatic efferent, a visceral efferent, a visceral afferent, and a somatic afferent column of nuclei. Within the visceral efferent, the visceral afferent and the somatic afferent columns, a distinction is made between general and special afferent nuclei.

Assignment of the Most Important Cranial Nerves to the Respective Pharyngeal Arches and Corresponding Branchiogenic Muscles

Pharyngeal Arch	Nerve of the Pharyngeal Arch	Muscles
1st pharyngeal arch (mandibular arch)	N. trigeminus [V]; N. mandibularis [V/3]	• Muscles of mastication • M. mylohyoideus • Venter anterior musculi digastrici • M. tensor tympani • M. tensor veli palatini
2nd pharyngeal arch (hyoid arch)	N. facialis [VII]	• Mimetic muscles • M. stylohyoideus • Venter posterior musculi digastrici • M. stapedius
3rd pharyngeal arch	N. glossopharyngeus [IX]	• Pharyngeal muscles • M. stylopharyngeus • M. levator veli palatini
4th pharyngeal arch (laryngeal arch)	N. vagus [X] with N. laryngeus superior	• Laryngeal muscles • Pharyngeal muscles: M. cricothyroideus
5th pharyngeal arch	– regresses –	– regresses –
6th pharyngeal arch	N. vagus [X] with N. laryngeus inferior (N. recurrens)	• Inner laryngeal muscles • Upper oesophageal muscles

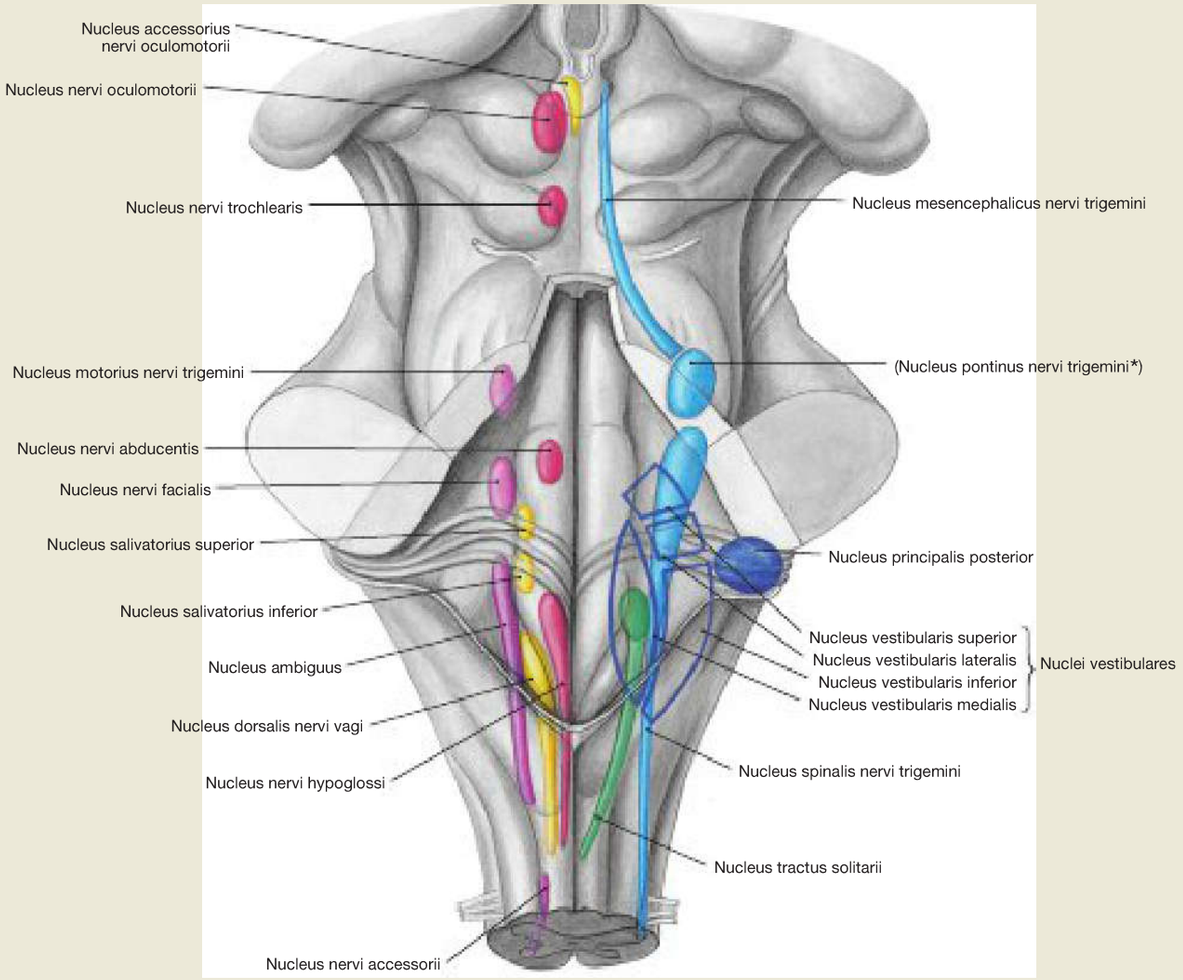

Fig. 12.127 Cranial nerves, Nn. craniales; topographical overview of the nuclei; posterior view.
With the exception of the cranial nerves I and II, all cranial nerves (III–XII) have nuclei located in the brain stem. The **nuclei** of the cranial nerves III and IV are located in the mesencephalon, the nuclei of the cranial nerves V to VII in the pons, and the nuclei of the cranial nerves VIII to XII in the Medulla oblongata.
It is easier to understand the arrangement of the nuclei of the cranial nerves if one keeps in mind their classification in functionally different nuclear columns (→ Fig. 12.126). On the left side the nuclei of origin (Nuclei originis) are presented, which contain the perikarya of the efferent neurons running towards the periphery. In the terminal nuclei (Nucleus terminationis) shown on the right side, the afferent fibres arriving from the periphery are synapsed onto the second neuron of the sensory tract.
* clinical term: Nucleus sensorius principalis nervi trigemini

→ T 57

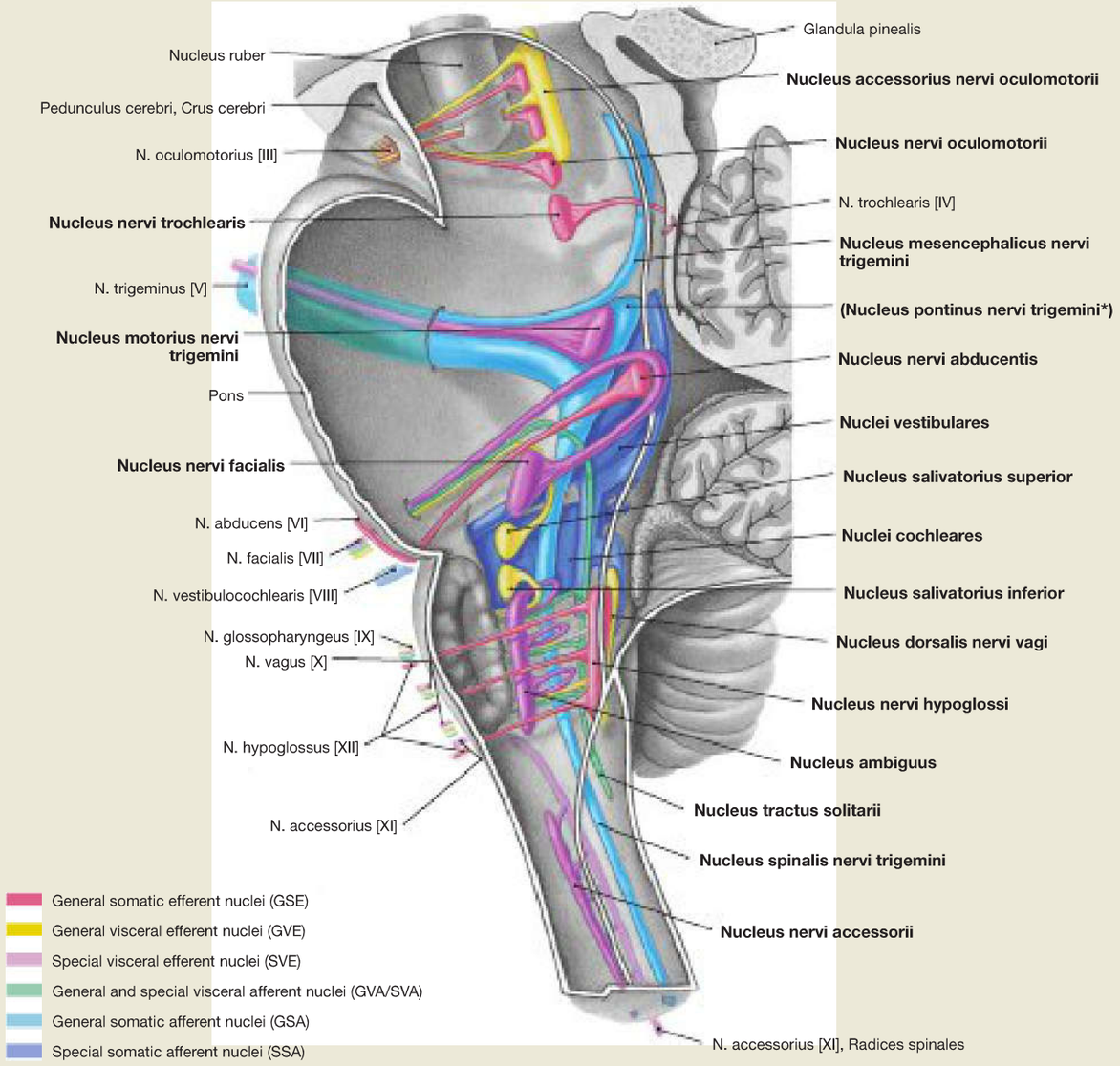

Fig. 12.128 Cranial nerves, Nn. craniales; topographical overview of the nuclei of the cranial nerves III to XII in the median plane. [L238]

The nuclei of origin (Nuclei originis) with the cell bodies of efferent or motor nerve fibres are divided into:

- general somatic efferent nuclei (Nuclei nervi oculomotorii [III, extraocular muscles], trochlearis [IV, M. obliquus superior], abducentis [VI, M. rectus lateralis] and hypoglossi [XII, muscles of the tongue])
- general visceral efferent nuclei (Nuclei accessorius nervi oculomotorii [III, M. sphincter pupillae and M. ciliaris], salivatorius superior [VII, Glandulae submandibularis, sublingualis, lacrimalis, nasales and palatinales], salivatorius inferior [IX, Glandula parotidea], dorsalis nervi vagi [X, viscera])
- special visceral efferent nuclei (Nuclei motorius nervi trigemini [V, muscles of mastication and of the floor of mouth], nervi facialis [VII, mimetic muscles], ambiguus [IX, X, Radix cranialis of XI, pharyngeal and laryngeal muscles], and Nucleus nervi accessorii [XI, Radix spinalis, shoulder muscles])

The terminal nuclei (Nuclei terminationis) as targets of afferent or sensory nerve fibres, are divided into:

- general visceral afferent nuclei (Nuclei tractus solitarii, Pars inferior [IX, X, sensory innervation of smooth muscles (viscera)])
- special visceral afferent nuclei (Nuclei tractus solitarii, Pars superior [VII, IX, X], taste fibres)
- general somatic afferent nuclei (Nuclei mesencephalicus nervi trigemini [V, proprioception in the muscles of mastication], pontinus (sensorius principalis) nervi trigemini [V, touch, vibration, position of temporomandibular joint], spinalis nervi trigemini [V, pain and temperature sensation in the head region])
- special somatic afferent nuclei (Nuclei vestibulares superior, lateralis, medialis and inferior [VIII, vestibular part, equilibrium], as well as Nuclei cochleares anterior and posterior [VIII, cochlear part, hearing])

* clinical term: Nucleus sensorius principalis nervi trigemini

→ T 57

N. olfactorius [I]

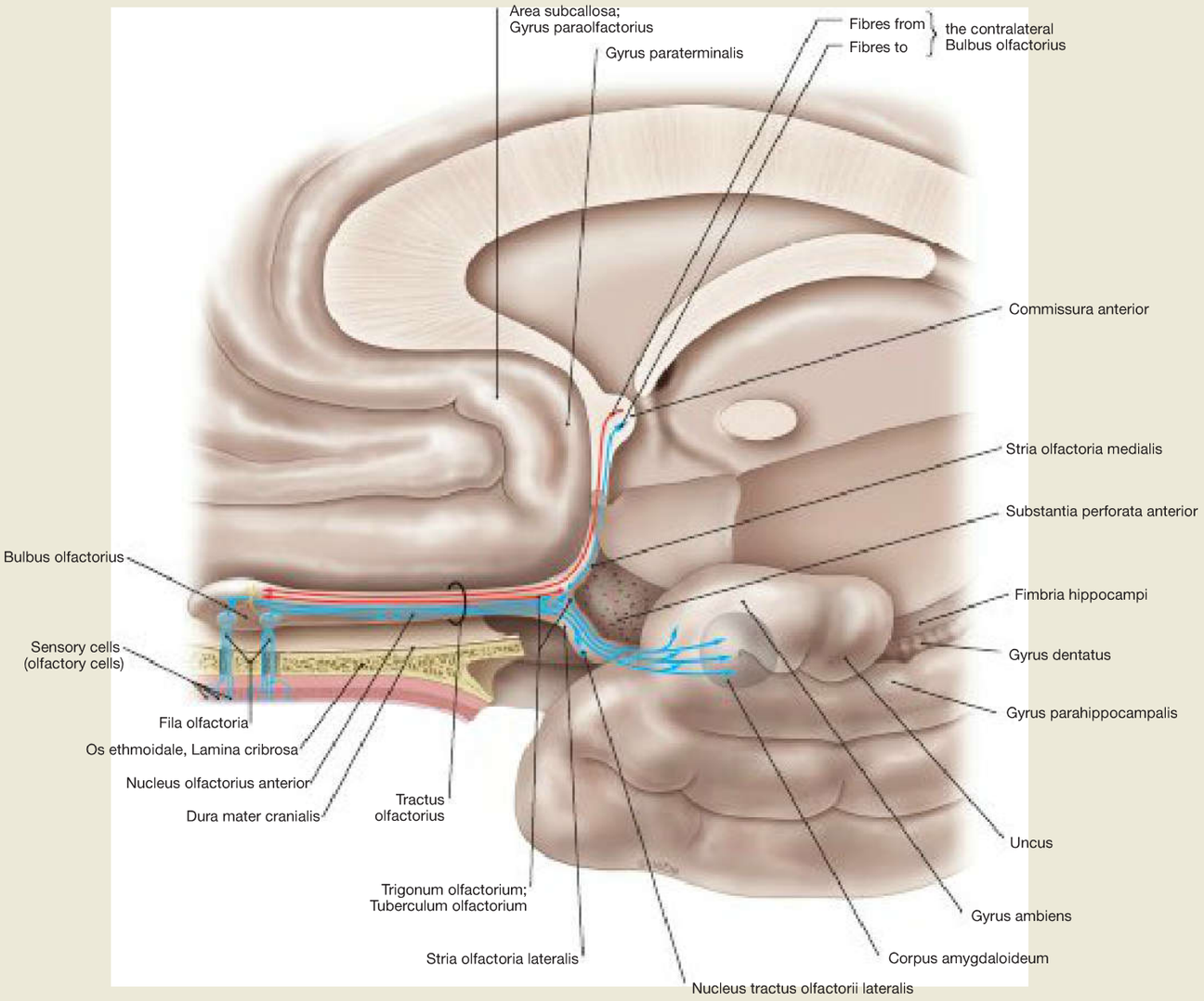

Fig. 12.129 N. olfactorius [I], with the olfactory nerves, Nn. olfactorii (Fila olfactoria), and the olfactory tract; view from the left side. [L238]

An area of 3 cm^2 of olfactory mucosa (Regio olfactoria) is located on both sides at the roof of the nasal cavity. It contains approximately 30 million receptor cells (olfactory sensory cells) which respond to chemical signals. These bipolar nerve cells (olfactory neurons, first neuron, SSA) are connected to the environment outside, and on the other hand they form the **Fila olfactoria** with their axons. Olfactory neurons have a short life span of 30–60 days and are replaced by neuronal stem cells throughout one's life. The Fila olfactoria in total are referred to as the N. olfactorius [I]. In each olfactory bulb, they converge onto approximately 1,000 **glomeruli.** From there, the olfactory information is transmitted to different areas of the cranial base and the temporal lobe (primary olfactory cortical areas). From here it is transferred via direct and indirect connections to secondary olfactory cortical areas and other regions of the brain, such as the hypothalamus. Here, the conscious perception of smell takes place and becomes associated with other sensory perceptions.

→ T 58a

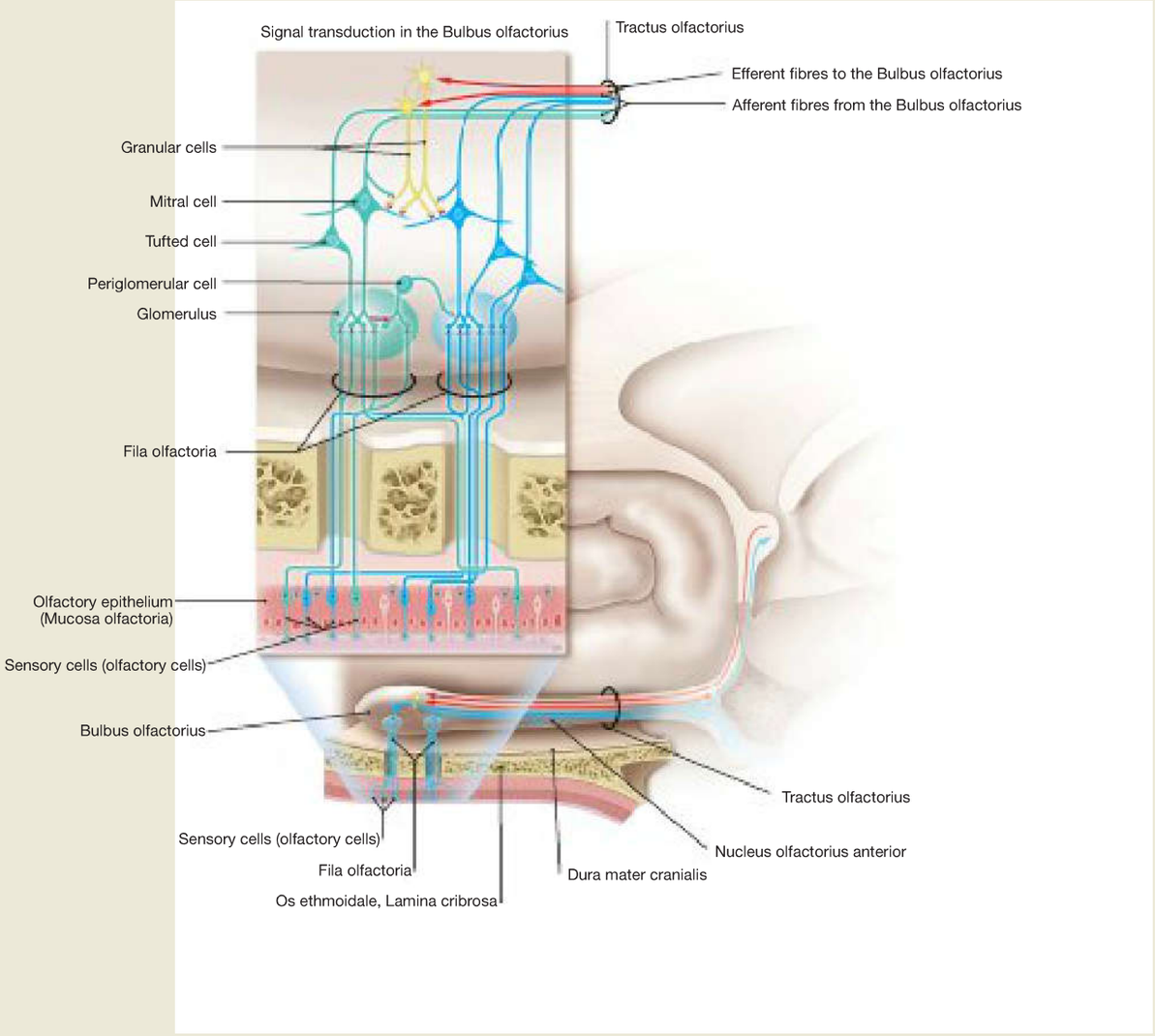

Fig. 12.130 Scheme of the projections and synaptic circuits of the Fila olfactoria; view from the left side. [L238]
In each bulbus, all Fila olfactoria converge in the olfactory bulb onto approximately 1,000 **glomeruli** (as shown in the figure for two Glomeruli) which collectively form the Tractus olfactorius. Via numerous synapses in the Glomeruli the signals are switched onto **mitral cells** (second neuron). The axons of all neurons possessing the identical olfactory receptor reach the exact Glomerulus that is specific to this one, out of the approximately 1,000 different olfactory receptors. Mitral cells of the olfactory bulb project to different areas at the cranial base and the temporal lobe (→ Fig. 12.129). Feedback mechanisms for a better discrimination of the stimuli act upon granular cells between the mitral cells.

Clinical Remarks

Viral infections, chronic sinusitis, airway obstruction due to congestion of the olfactory mucosa, e.g. allergic reaction, side effects of medication, brain tumours or head trauma with injury to the olfactory nerves along their passage through the Lamina cribrosa, can result in **hyposmia** (decreased perception of olfactory sensations) or **anosmia** (inability of perceiving olfactory sensations).

N. opticus [II]

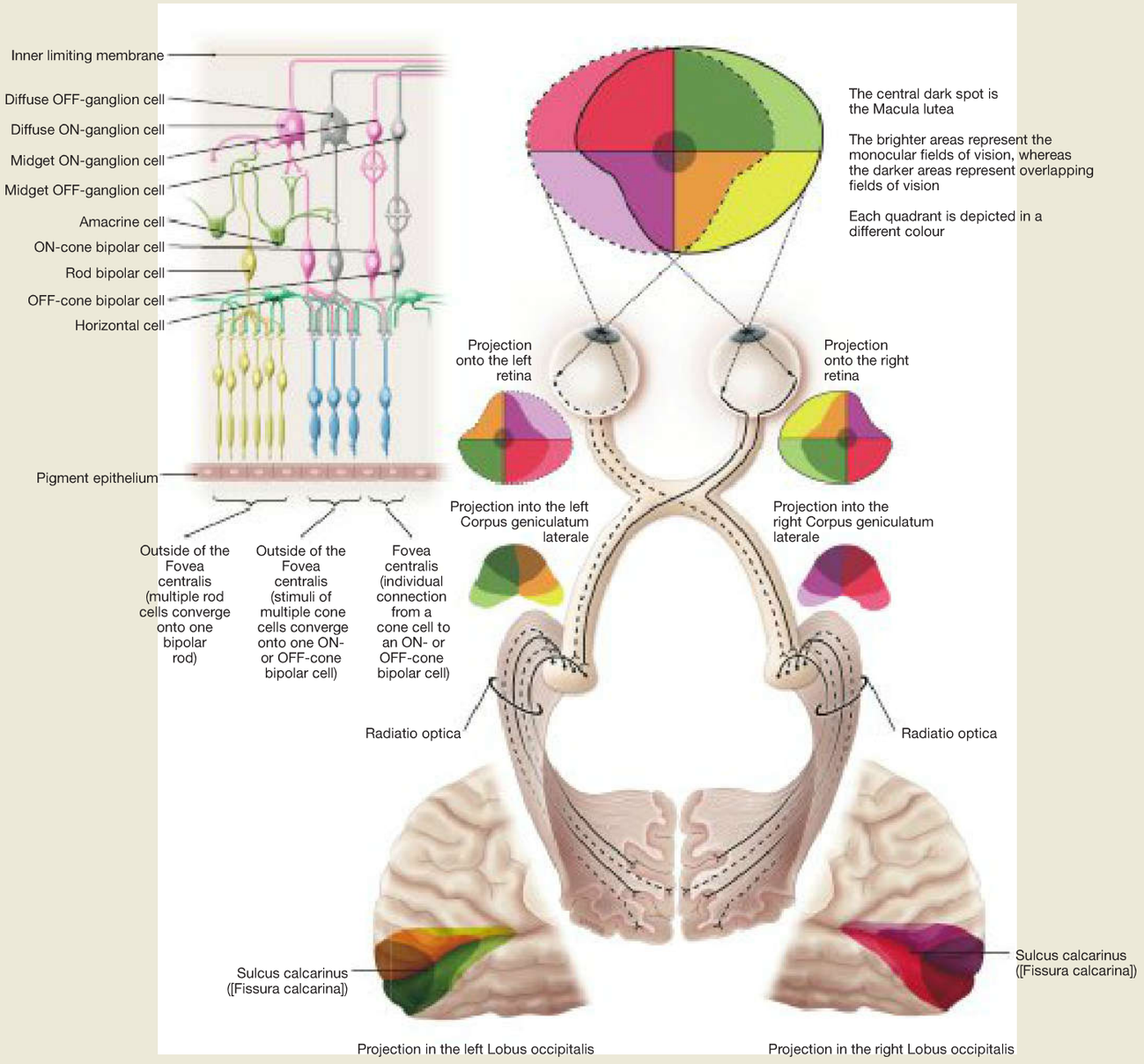

Fig. 12.131 Neuronal circuit in the retina and central visual tract; highly simplified schematic representation. [L238]
Cone cells (first neuron) send the information to **cone bipolar cells** (second neuron) and from here to a **ganglion cell** (third neuron). Horizontal and amacrine cells have a modifying effect on the transmission of information. The axons of the ganglionic cells join to form the N. opticus [II]. The illustrated circuitry of an **intraretinal chain** of three neurons only applies to cone cells (for rod cells → Fig. 9.84 and textbooks of histology). For the visual tract → Figs. 9.84–9.86.

→ T 58b

Clinical Remarks

A sudden, potentially reversible unilateral loss of vision can indicate an acute inflammation of the optic nerve **(neuritis of the optic nerve, retrobulbar neuritis).** The examining physician cannot see that the eye itself is poorly affected or not at all. The patient is also unable to see anything with the affected eye. In about one third of the cases, neuritis of the optic nerve is the first symptom of multiple sclerosis (MS), a relatively frequent autoimmune disease of the central nervous system.

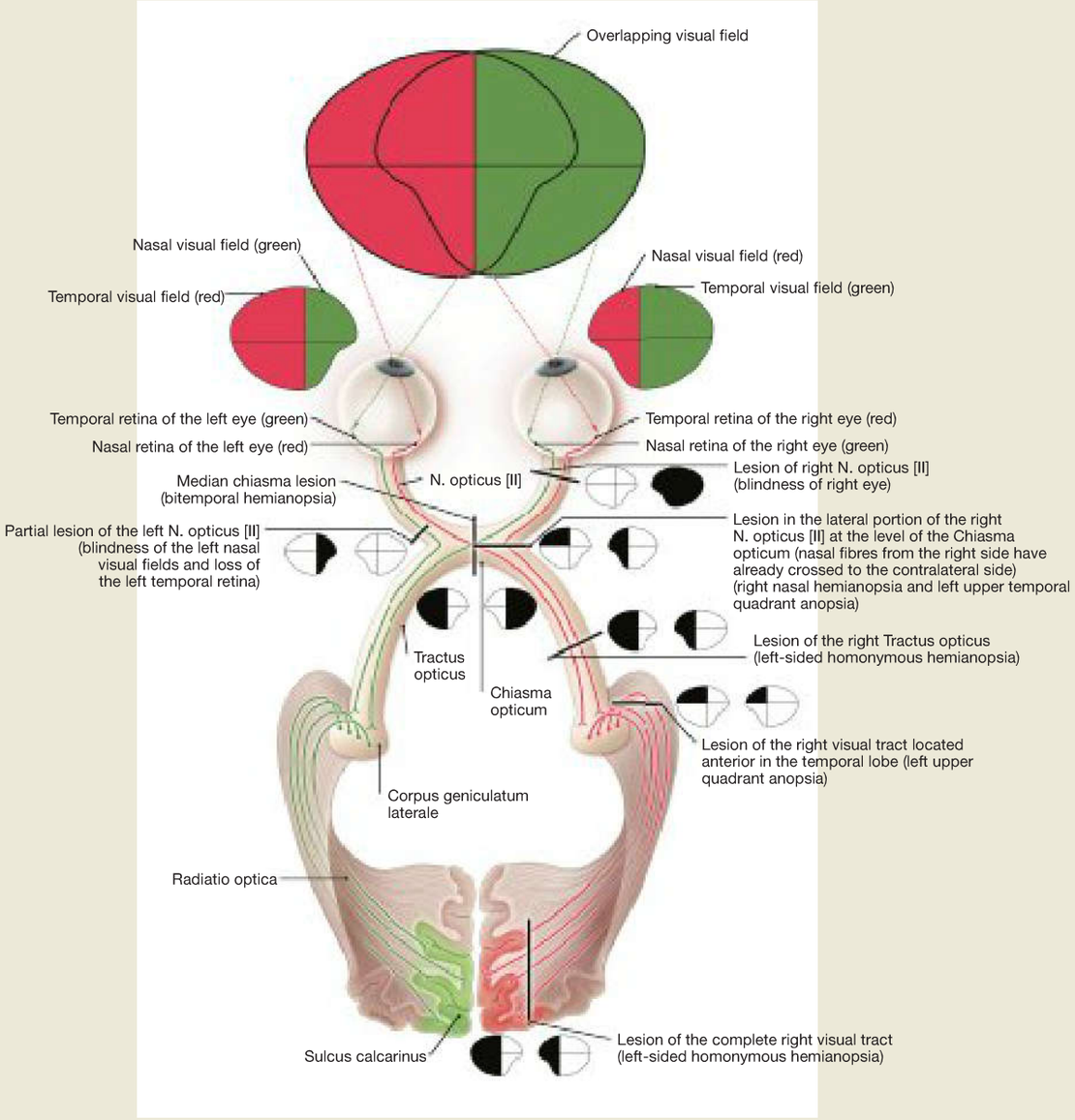

Fig. 12.132 N. opticus [II] and visual tract. [L238]
The visual tract starts within the retina. Here, the first three projection neurons and interneurons (horizontal and amacrine cells) of the visual tract can be found (→ Fig. 9.84).
Up to 40 **rod cells** transmit their signals to a **bipolar rod** which sends these signals indirectly via amacrine cells (as yet 20–50 different types of these cells are described in the literature) to a single **ganglion cell** (thus, the first four neurons of the rod cells can be found in the retina). The axons of ganglionic cells run in the N. opticus [II] to the **Chiasma opticum.** Here, the fibres from the nasal part of the retina cross to the opposite side (red). The fibres of the temporal part do not cross (green).
The chiasma is directly followed by the Tractus opticus, which contains fibres conveying information of the opposite (contralateral) half of the visual field. The majority of these fibres (Radix lateralis) is switched in the Corpus geniculatum laterale (CGL). Some fibres (Radix medialis) already branch off before reaching the CGL, and project into the Area pretectalis, the Colliculus superior and the hypothalamus. Via the **GRATIOLET's optic radiation** (Radiatio optica) the fibres from the Corpus geniculatum laterale pass in the region of the Sulcus calcarinus to the areas 17 and 18 of the cerebral cortex (Area striata).

Clinical Remarks

- Lesions of the N. opticus [II] which are located anterior to the Chiasma opticum, e.g. after a traumatic head injury, result in blindness of the affected eye (→ Fig. 12.132).
- Lateral lesions of the N. opticus [II] at the level of the Chiasma opticum (nasal fibres from the right side have already crossed to the opposite side), e.g. due to a tumour, result in a right nasal **hemianopsia** and **quadrant anopsia** of the left upper temporal quadrant (→ Fig. 12.132).
- Median lesions of the Chiasma opticum, mostly due to pituitary tumours, result in a bitemporal hemianopsia (→ Fig. 12.132).
- Lesions of the Tractus opticus (in the example on the right side), e.g. caused by a haemorrhage, result in a left-sided homonymous hemianopsia (→ Fig. 12.132).
- Lesions of the anterior part of the optic radiation located in the temporal lobe (in the example on the right side), e.g. due to ischemia, result in anopsia of the left upper quadrant (→ Fig. 12.132).
- Lesions of the entire optic radiation (in the example on the right side), e.g. caused by massive bleeding, result in a left-sided homonymous hemianopsia (→ Fig. 12.132).

N. oculomotorius [III], N. trochlearis [IV], N. abducens [VI]

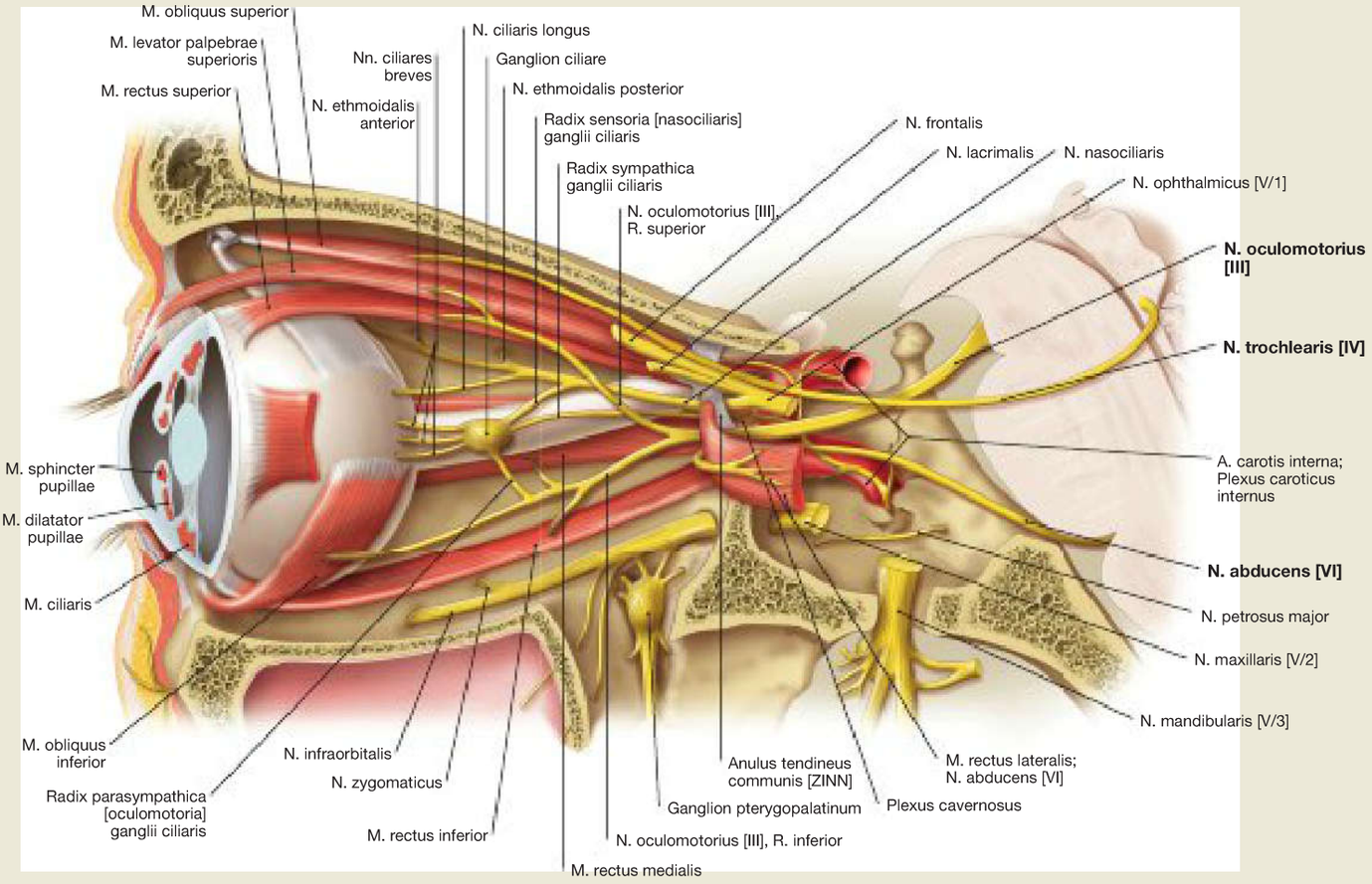

Fig. 12.133 N. oculomotorius [III], N. trochlearis [IV] and N. abducens [VI], left side; lateral view; the orbit has been opened, the orbital fat body removed, the M. rectus lateralis has been severed near its insertion and folded backwards. [L238]
The N. oculomotorius [III] innervates the extraocular muscles with the exception of the M. obliquus superior (N. trochlearis [IV]) and the M. rectus lateralis (N. abducens [VI]). The third cranial nerve [CN III] also supplies two intraocular muscles with its parasympathetic parts, the M. sphincter pupillae and M. ciliaris.

→ T 58c, d, f

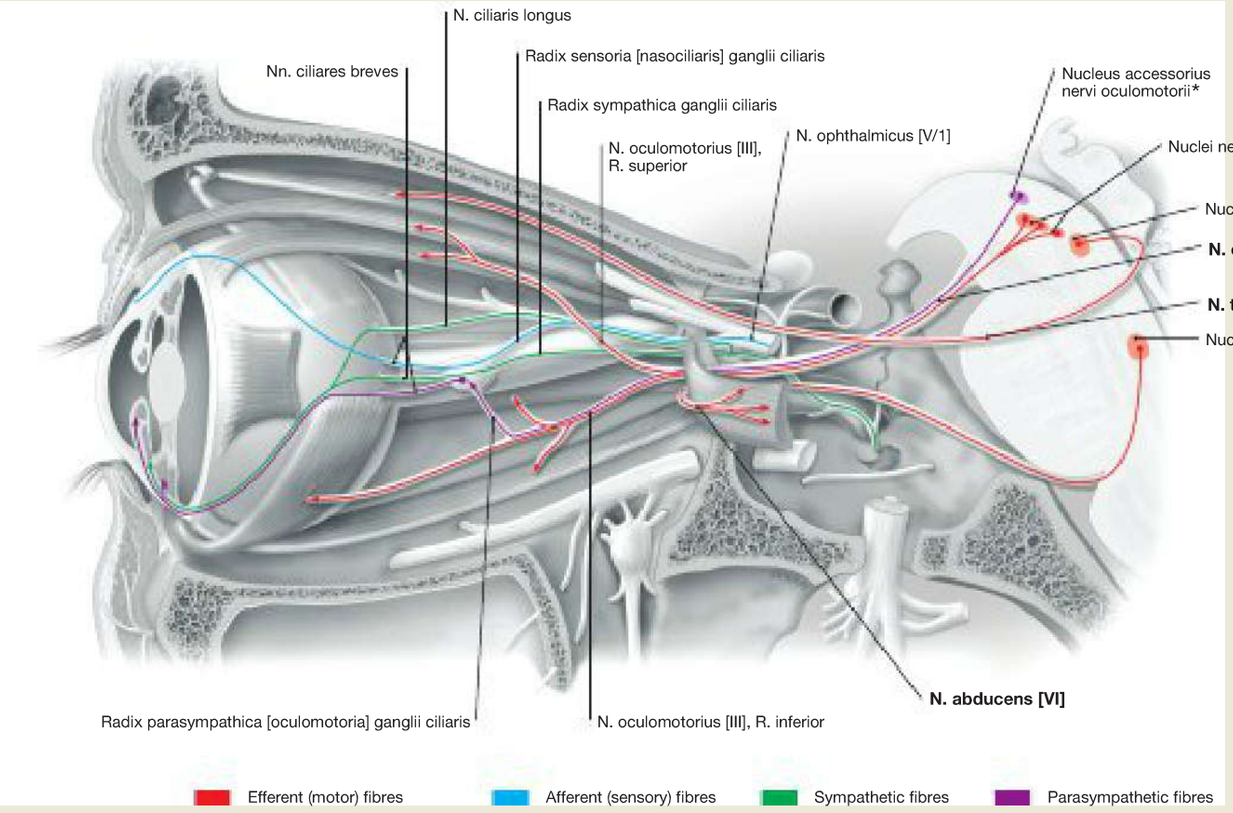

Fig. 12.134 Fibre qualities of the Nn. oculomotorius [III], trochlearis [IV] and abducens [VI], left side; lateral view. [L238]
The **N. oculomotorius [III]** contains motor fibres (GSE) of the Nucleus nervi oculomotorii which supply the major part of the extraocular muscles. Within the orbit, the nerve divides into two branches: its R. superior innervates the M. rectus superior and M. levator palpebrae superioris, and its R. inferior innervates the M. rectus medialis, M. rectus inferior and M. obliquus inferior. Parasympathetic fibres (GVE) originating from the Nucleus accessorius nervi oculomotorii (EDINGER-WESTPHAL) pass via the R. inferior and Radix parasympathica (oculomotoria) to the Ganglion ciliare. Here, the preganglionic parasympathetic fibres are switched to postganglionic fibres, which accompany the Nn. ciliares breves to the Bulbus oculi and pass through its wall to the M. ciliaris and M. sphincter pupillae.
The **N. trochlearis [IV]** contains motor fibres (GSE) of the Nucleus nervi trochlearis located in the brain stem which supply the M. obliquus superior.
The **N. abducens [VI]** contains motor fibres (GSE) of the Nucleus nervi abducentis which innervate the M. rectus lateralis.

* Nucleus EDINGER-WESTPHAL

Clinical Remarks

Lesions of individual cranial nerves supplying the extraocular muscles lead to paralysis of the corresponding eye muscles with deviations of the eyeballs. The direction and extent of such deviations depends on the predominant action of the still intact muscles (and thus the still intact nerves) against the paralysed muscles. For more details → Fig. 9.49.
Unilateral palsies of the abducent and oculomotor nerves in combination with sensory deficits of the first trigeminal branch (N. ophthalmicus [V/1]) indicate diseases of the Sinus cavernosus (**cavernous sinus syndrome;** cavernous sinus thrombosis, tumour, metastasis, aneurysm of the A. carotis interna, inflammatory infiltration). If an acute onset of the symptoms is combined with clinical signs of a drainage disorder such as venous congestion of the orbit, eyelid and conjunctival swelling, and protrusion of the eyeball, one has to think of a venous thrombosis and/or a fistula between the A. carotis interna and the Sinus cavernosus.

N. oculomotorius [III]

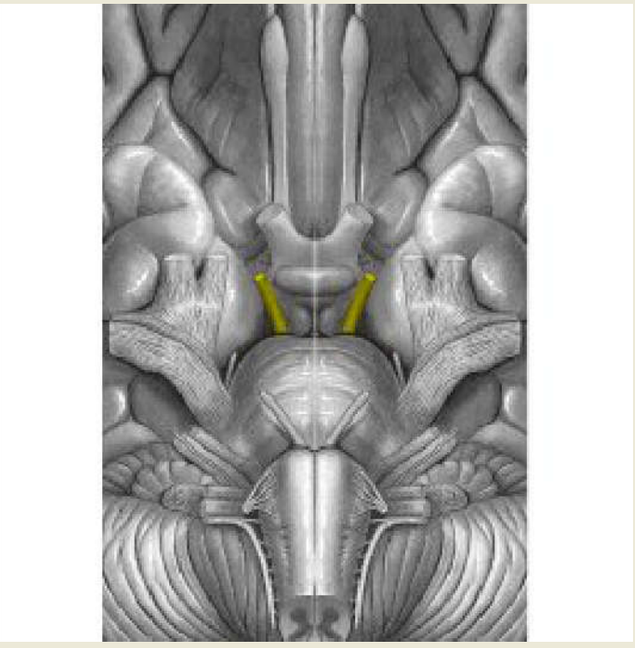

Fig. 12.135 Exit site of the N. oculomotorius [III] at the brain stem; inferior view. The third cranial nerve [CN III] exits directly above the pons.

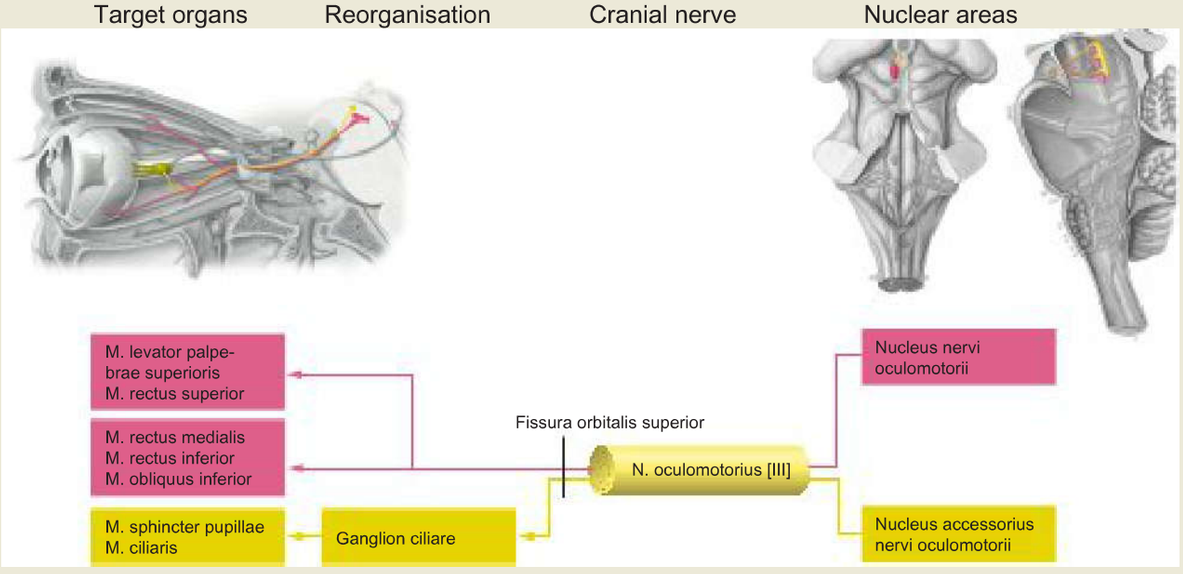

Fig. 12.136 Course, branches and fibre qualities of the N. oculomotorius [III]; lateral view. [L127] Compare → Fig. 12.134

Clinical Remarks

Complete **palsy of the oculomotor nerve** results in drooping of the eyelid **(ptosis)** across the visual axis caused by the failure of the M. levator palpebrae superioris. Paralysis of the Mm. rectus superior, rectus medialis, rectus inferior and obliquus inferior coincides with the turning of the **Bulbus oculi, which is directed outwards and downwards** (due to the contraction of the still intact Mm. rectus lateralis and obliquus superior). Because the M. sphincter pupillae is paralysed as well, the pupil is dilated **(mydriasis)** due to the outweighing action of the sympathetically innervated M. dilatator pupillae. In addition, due to the failure of the M. ciliaris the near-point accommodation of the eye does not function and due to the failure of the M. rectus medialis the convergence reaction on one side no longer works. The patient complains of double images, as soon as the affected eyelid is pulled up by the examiner or the patient himself.

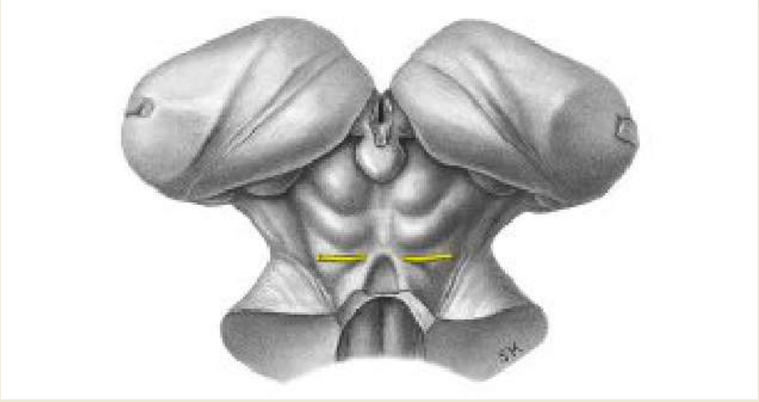

Fig. 12.137 Exit site of the N. trochlearis [IV] at the brain stem; dorsal view. [L238]

The fourth cranial nerve [CN IV] exits below the Colliculi inferiores.

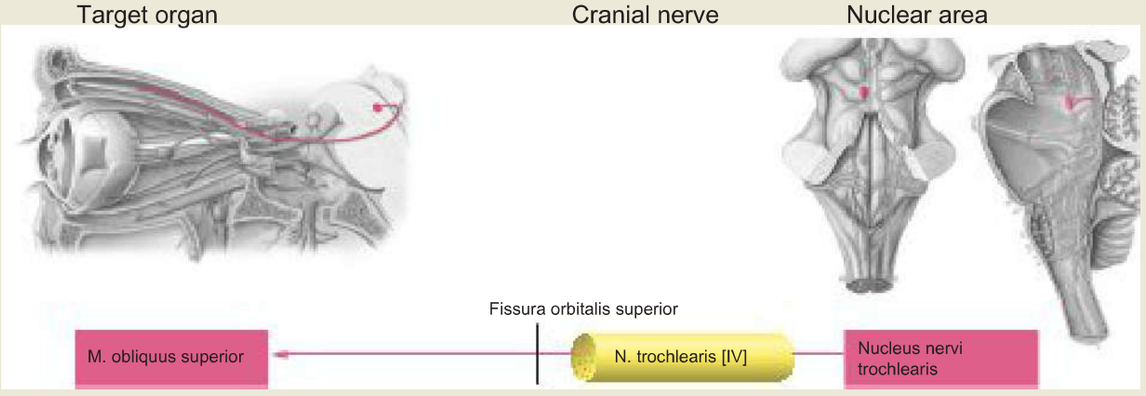

Fig. 12.138 Course, branches and fibre qualities of the N. trochlearis [IV]; lateral view. [L127] Compare → Fig. 12.134

Clinical Remarks

In the case of a **trochlear nerve palsy**, the failure of the M. obliquus superior and outweighing action of all other extraocular muscles result in the turning of the eyeball in a nasal superior direction. The patients report double images, especially when looking downwards nasally. They attempt to compensate for it by tilting their head to the healthy side.

N. trigeminus [V]

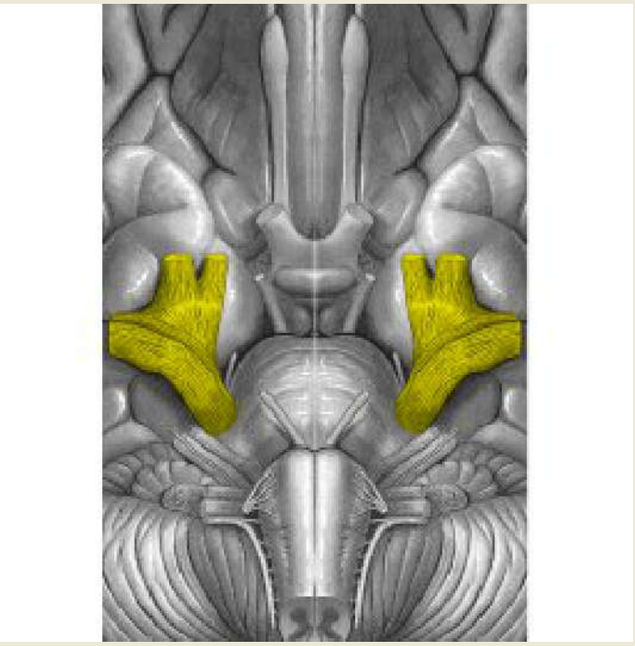

Fig. 12.139 Exit site of the N. trigeminus [V] at the brain stem; inferior view.
The fifth cranial nerve [CN V] exits on the outside of the pons.

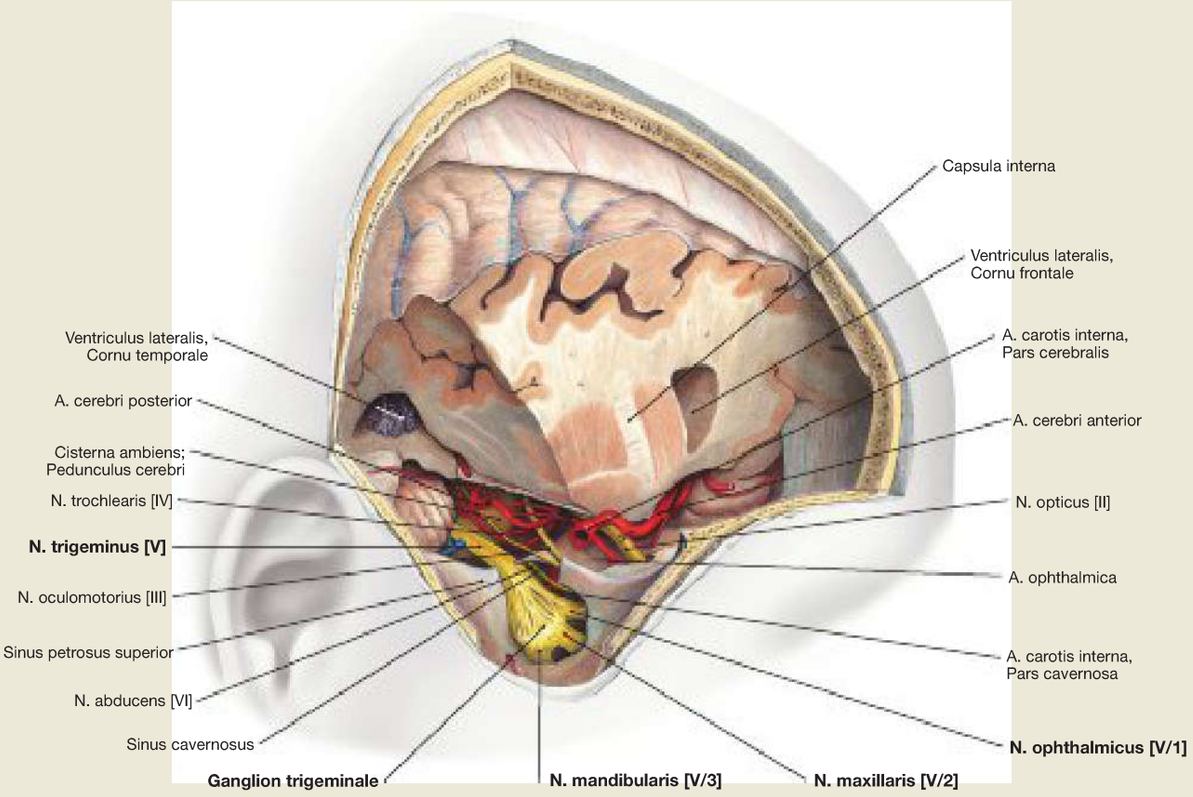

Fig. 12.140 Course of the N. trigeminus [V] in the middle cranial fossa, Fossa cranii media; view from the right side.
Large parts of the frontal and temporal lobes were removed to provide a free view onto the cranial base below. In addition, the Cavum trigeminale (MECKEL's cave) was opened. Located within is the **Ganglion trigeminale** (Ganglion semilunare, clinical term: Ganglion GASSERI), from which the three main branches of the N. trigeminus originate (N. ophthalmicus [V/1], N. maxillaris [V/2], N. mandibularis [V/3]). Besides the N. trigeminus [V], the passage of the N. opticus [II], N. oculomotorius [III] and N. trochlearis [IV] in this region of the cranial base are visible, as well as arteries branching off the Pars cerebralis of the A. carotis interna (A. ophthalmica, A. cerebri anterior).

→T 58

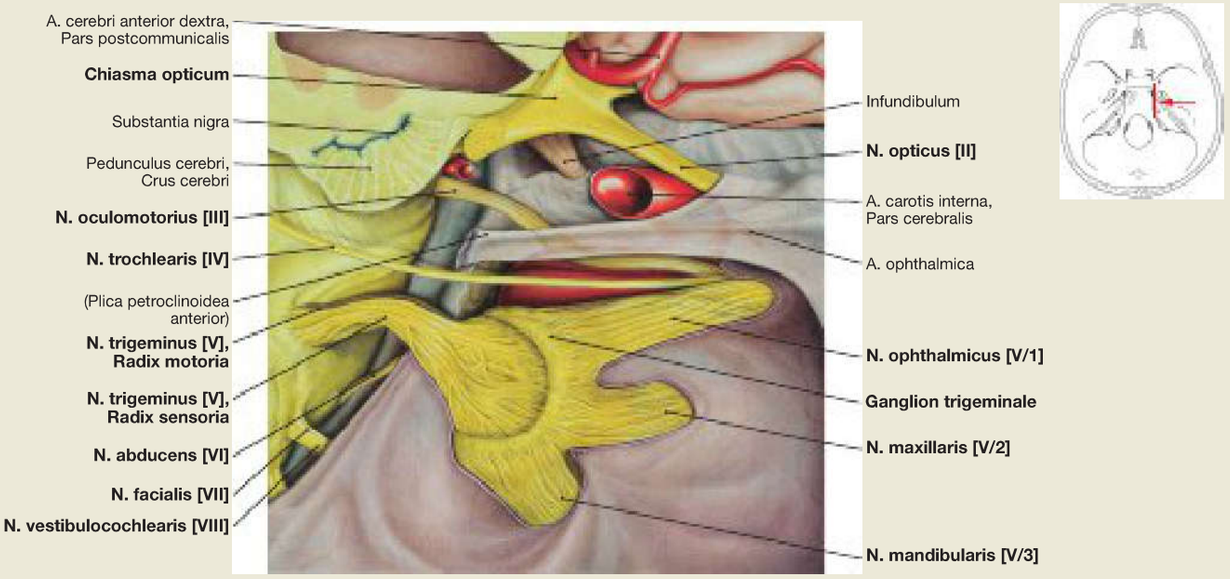

Fig. 12.141 Arteries and nerves in the region of the Sella turcica and Sinus cavernosus; view from the right side.
The Cavum trigeminale (MECKEL's cave) is opened after removal of the Dura mater cranialis and the Arachnoidea mater at this site. Thus, the Ganglion trigeminale (Ganglion semilunare, clinical term: Ganglion GASSERI) is visible with the bifurcation of the three trigeminal nerve branches. In addition, the course of the cranial nerves III, IV, and VI to VIII can be seen from their exit of the brain stem to their entrance at the cranial base. The Pars cavernosa of the A. carotis interna continues as Pars cerebralis and joins the N. opticus [II]. The Chiasma opticum is located above the stalk of the pituitary gland (Infundibulum).

→ T 58

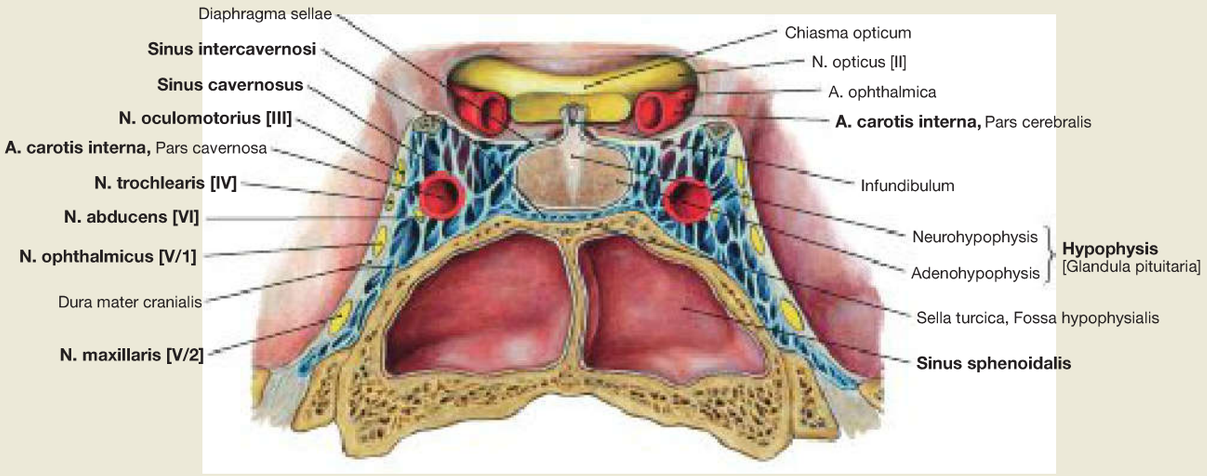

Fig. 12.142 Arteries and nerves in the region of the Sella turcica and Sinus cavernosus; frontal section; posterior view.
The N. ophthalmicus [V/1] and N. maxillaris [V/2] run together with the N. oculomotorius [III] and N. trochlearis [IV] in the wall of the Sinus cavernosus; the N. abducens [VI] and the A. carotis interna pass centrally through the Sinus cavernosus on both sides; the pituitary gland lies in the median line and is surrounded by the left and right Sinus cavernosus.

Clinical Remarks

Mechanical but also visual (bright light) or acoustic stimuli trigger the **corneal reflex** (eyelid closure reflex, orbicularis oculi reflex, or blink reflex, as an eye-protecting mechanism). This is a multisynaptic reflex, which can be missing in peripheral nerve lesions but also in the context of severe brain stem lesions. It is usually tested by touching the cornea with a cotton swab. Stimulating impulses reach the complex of the trigeminal nuclei via fibres of the N. ophthalmicus [V/1]. The polysynaptic reflex arch propagates via the Colliculi superiores, the Formatio reticularis and the nuclear complex of the N. facialis, which activates the M. orbicularis oculi with motor fibres and thus triggers the eyelid closure.

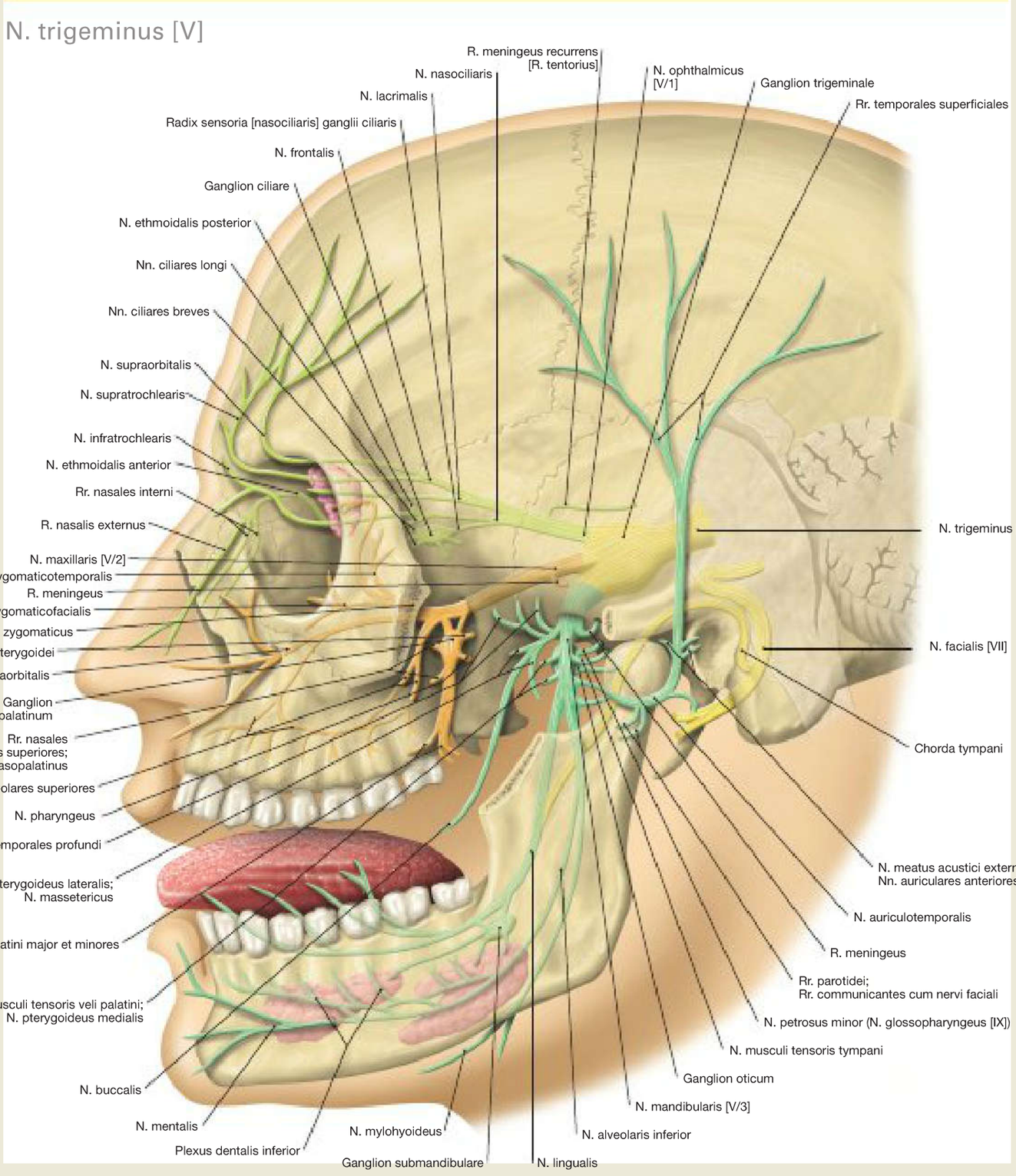

Fig. 12.143 N. trigeminus [V], left side; lateral view. [L127]
The trigeminal nerve [V] is the nerve of the first pharyngeal arch and composed of its three main branches: N. ophthalmicus [V/1] (light green), N. maxillaris [V/2] (orange) and N. mandibularis [V/3] (turquoise). It consists mainly of general somatic afferent fibres (GSA). These are completed by special visceral efferent (SVE) fibres.
The **N. ophthalmicus [V/1]** innervates the eye (including cornea and conjunctiva), the skin of the upper eyelid, forehead, back of the nose, as well as the nasal and paranasal mucous membranes. It is accompanied by parasympathetic fibres for the innervation of the lacrimal gland in its peripheral course.
The **N. maxillaris [V/2]** innervates the skin of the anterior temporal region and the upper cheek as well as the skin below the eye. In addition, it provides sensory innervation to the palate, the teeth and Gingiva of the upper jaw, and the mucosa of the Sinus maxillaris.
The **N. mandibularis [V/3]** innervates the muscles of mastication, and two muscles of the floor of the mouth (M. mylohyoideus, and Venter anterior of the M. digastricus), as well as the M. tensor veli palatini and M. tensor tympani. It contributes sensory branches to the skin of the posterior temporal region, of the cheeks, and the chin, and innervates the teeth and gingiva of the lower jaw. Its branches receive parasympathetic fibres for the innervation of the large salivary glands and taste fibres for the tongue, and also provide sensory innervation to the anterior two-thirds of the tongue.

→ T 58e

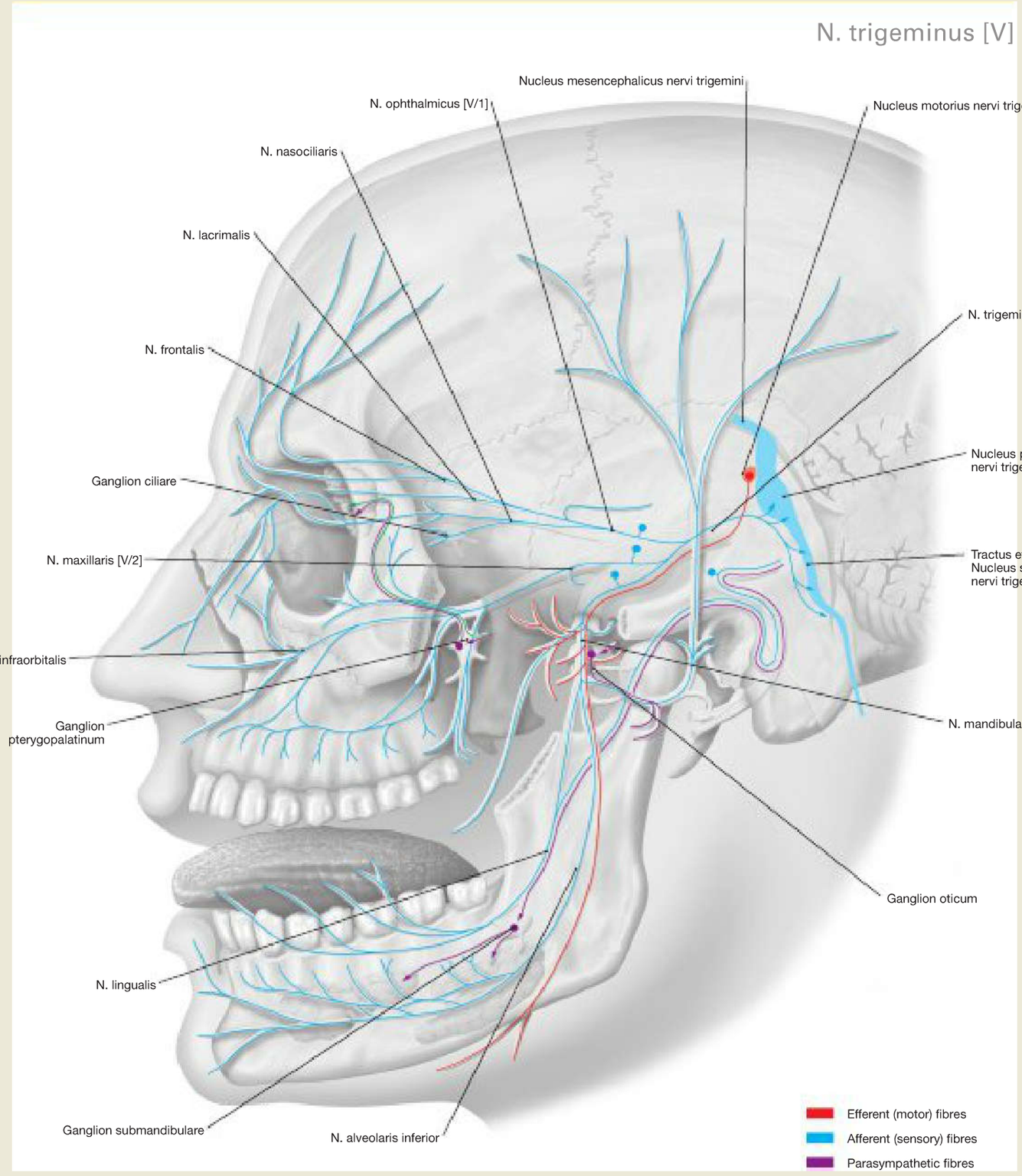

Fig. 12.144 Fibre qualities of the N. trigeminus [V], left side; lateral view. [L127]

Nuclei of origin and **terminal nuclei** of the N. trigeminus [V] are the Nucleus mesencephalicus nervi trigemini (somatosensory), the Nucleus pontinus (sensorius principalis) nervi trigemini (somatosensory), the Nucleus spinalis nervi trigemini (general somatic afferent, GSA), and the Nucleus motorius nervi trigemini (special visceral efferent, SVE).

The N. trigeminus [V] consists of a **Radix sensoria** (Portio major) and a **Radix motoria** (Portio minor). After exiting the pons, the nerve passes across the Clivus to the Ganglion trigeminale (Ganglion semilunare, clinical term: Ganglion GASSERI; contains pseudo-unipolar nerve cells for the transmission of protopathic and epicritic sensory stimuli to the Nuclei pontinus and spinalis nervi trigemini), and then divides into its three main branches, the N. ophthalmicus [V/1], N. maxillaris [V/2] and N. mandibularis [V/3].

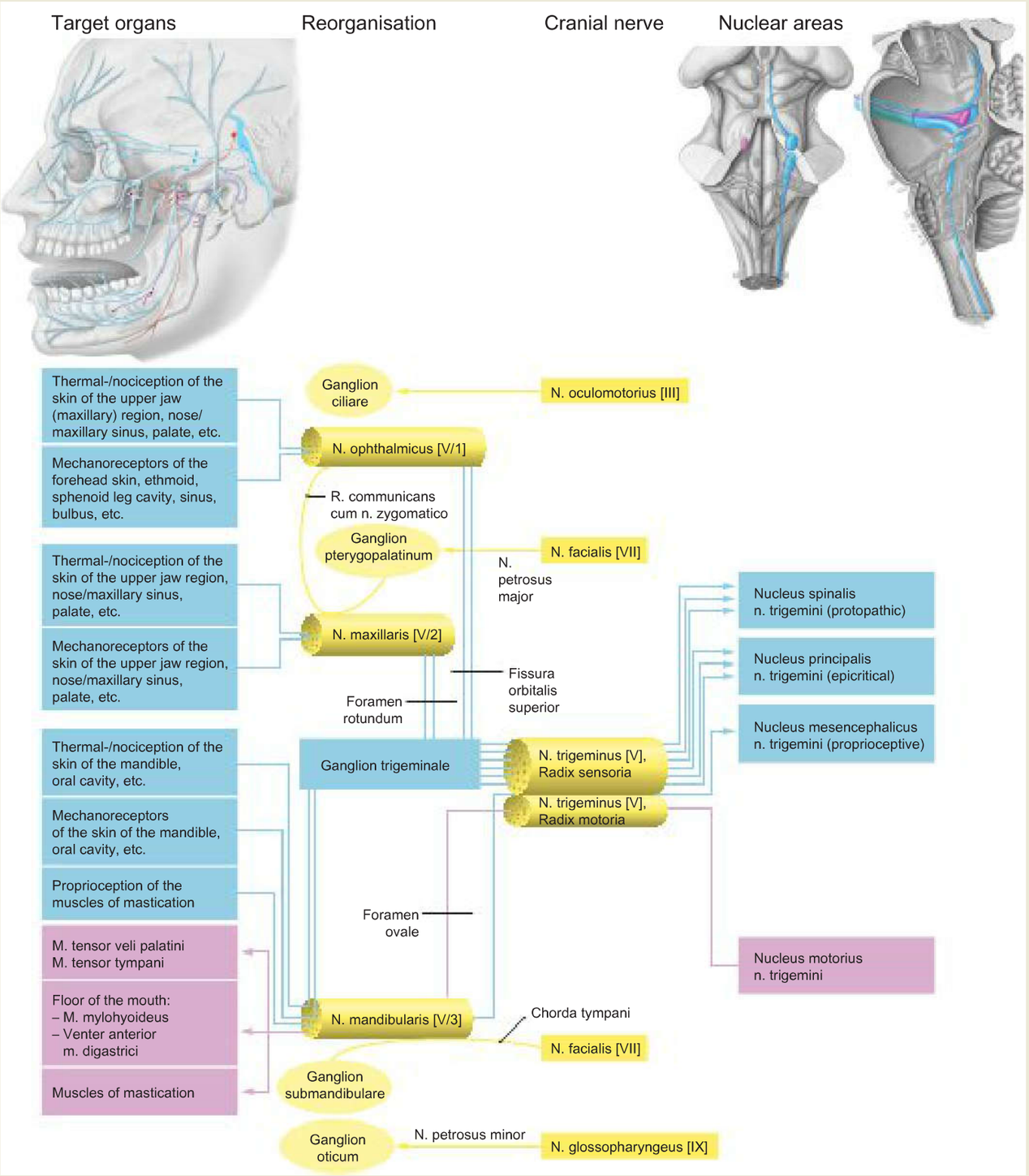

Fig. 12.145 Fibre qualities, cranial nuclei and target organs of the N. trigeminus [V]; lateral view. [L127]

Branches of the N. ophthalmicus [V/1] (Exclusively Somatic Afferent)		
Branch	**Minor Branches**	**Innervation Area**
R. meningeus recurrens [R. tentorius]		Parts of the meninges
N. frontalis	N. supraorbitalis	Skin of the forehead, and mucosa of the frontal sinus
	N. supratrochlearis	Skin and conjunctiva at the medial (nasal) angle of the eye
N. lacrimalis		Lacrimal gland (for the innervation of the excretory duct, it is joined by postganglionic parasympathetic fibres of the N. zygomaticus), skin and conjunctiva of the lateral (temporal) angle of the eye
N. nasociliaris	(→Table below)	Paranasal sinuses, anterior part of the nasal cavity, as well as the iris, Corpus ciliare, and cornea of the eye (→Table below)

Branches of the N. nasociliaris (from V/1)		
Branch	**Course**	**Innervation Area**
Radix sensoria ganglii ciliaris [R. communicans cum ganglio ciliari]	Contributes the sensory components to the Ganglion ciliare, from which the Nn. ciliares breves emerge	Eyeball and conjunctiva (together with the Nn. ciliares longi)
Nn. ciliares longi	Join the N. opticus and accompany the Nn. ciliares breves from the Ganglion ciliare to the Bulbus oculi; they also receive sympathetic fibres of the Plexus caroticus	Eyeball (Bulbus oculi) and conjunctiva; the sympathetic fibres innervate the M. dilatator pupillae
N. ethmoidalis posterior	Passes through the identically named foramen to the posterior ethmoidal cells and the sphenoidal sinus	Mucosa of the posterior ethmoidal cells and of the sphenoidal sinus
N. ethmoidalis anterior	Passes through the identically named foramen back into the anterior cranial fossa, and then through the Lamina cribrosa into the nasal cavity; ending with Rr. nasales externi in the skin of the dorsum of the nose	Mucosa of the anterior nasal cavity and of the anterior ethmoidal cells, skin of the dorsum of the nose
N. infratrochlearis	Below the trochlea to the medial angle of the eye	Skin of the medial angle of the eye

Branches of the N. maxillaris [V/2] (Exclusively Somatic Afferent)		
Branch	**Minor Branches**	**Innervation Area**
R. meningeus		Parts of the meninges
N. zygomaticus	R. zygomaticotemporalis	Skin in the temporal region
	R. zygomaticofacialis	Skin in the upper cheek region; for the innervation (of the excretory duct) of the lacrimal gland, its postganglionic parasympathetic fibres accompany the N. zygomaticus, which releases them to the N. lacrimalis
Rr. ganglionares ad ganglion pterygopalatinum	(→Table, on p. 366 above)	Contribute sensory fibres to the Ganglion pterygopalatinum; for the innervation of palate and nose (→ p. 366 above), they are joined by sympathetic and parasympathetic fibres to the Glandulae nasales and palatinae (special visceral efferent) as well as by taste fibres
N. infraorbitalis	Nn. alveolares superiores with Rr. alveolares superiores posteriores, medii and anteriores	Mucosa of the maxillary sinus, teeth and gingiva of the upper jaw
		Skin and conjunctiva of the lower eyelid, lateral cutaneous region of the nasal wings, skin of the upper lip and lateral cheek region between lower eyelid and upper lip

N. trigeminus [V]

Branches of the Rr. ganglionares ad Ganglion pterygopalatinum (from V/2)		
Branch	**Course**	**Innervation Area**
N. palatinus major	Via the Canalis palatinus major through the Foramen palatinum majus	Mucosa of the hard palate, Glandulae palatinae, taste buds of the palate
Nn. palatini minores	Leave the Canalis palatinus major through the Foramina palatina minora	Mucosa of the soft palate, Tonsilla palatina, Glandulae palatinae, taste buds of the palate
Rr. nasales posteriores superiores laterales et mediales	Pass through the Foramen spheno-palatinum into the nasal cavity, and provide the N. nasopalatinus which reaches the hard palate through the Canalis incisivus	Mucosa of the nasal conchae, of the nasal septum, and of the anterior part of the hard palate, upper incisors and gingiva, Glandulae nasales

Branches of the N. mandibularis [V/3] (Somatic Afferent and Visceral Efferent)		
Branch	**Minor Branches**	**Innervation Area**
R. meningeus		Parts of the meninges
N. massetericus		M. masseter
Nn. temporales profundi		M. temporalis
N. pterygoideus lateralis		M. pterygoideus lateralis
N. pterygoideus medialis		M. pterygoideus medialis
N. musculi tensoris veli palatini		M. tensor veli palatini
N. musculi tensoris tympani		M. tensor tympani
N. buccalis		Skin and mucosa of the cheek, and gingiva of the lower jaw
N. auriculotemporalis	Rr. parotidei	Joined by postganglionic parasympathetic fibres of the Ganglion oticum, they innervate the parotid gland
	Rr. communicantes cum nervo faciali	Joined by postganglionic parasympathetic fibres of the Ganglion oticum, they innervate the parotid gland
	N. meatus acustici externi	External auditory tube, tympanic membrane
	Nn. auriculares anteriores	Skin in front of the auricle
	Nn. temporales superficiales	Skin of the posterior temporal region
N. lingualis	Rr. isthmi faucium	Skin of the soft palate
	N. sublingualis	Mucosa of the floor of the mouth
		Sensory innervation of the anterior two-thirds of the tongue, taste fibres of the anterior two-thirds of the tongue in association with preganglionic parasympathetic fibres of the Chorda tympani for the innervation of the Ganglion submandibulare
N. alveolaris inferior		Teeth and gingiva of the lower jaw
	N. mylohyoideus	M. mylohyoideus and Venter anterior of the M. digastricus
	N. mentalis	Skin of the chin

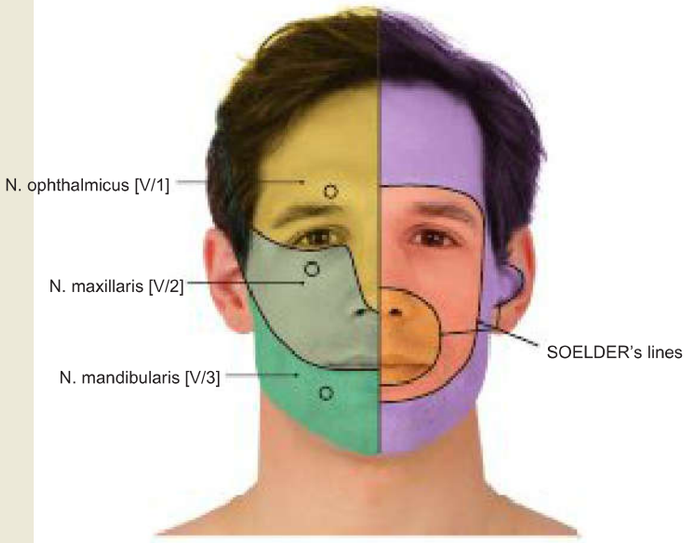

Fig. 12.146 Innervation areas of the facial skin, with nerve exits and protopathic sensibility. [J803]
In the right half of the face, the somatotopic segmentation of the protopathic sensibility is shown. In the left half of the face the innervation areas and exit sites of the three trigeminal nerve branches are indicated.

Clinical Remarks

Particularly in the context of circulatory disorders, **lesions of the N. trigeminus [V]** can occur. Usually only individual nuclei are affected selectively or partially, but rarely the entire N. trigeminus [V]. Such lesions may manifest, for example, as paralysis of the ipsilateral muscles of mastication or as a selective loss of epicritic sensitivity. Afferent fibres of the protopathic sensitivity reach the Nucleus spinalis nervi trigemini in a somatotopic order (→ Fig. 12.146). A defined segment of the Nucleus spinalis nervi trigemini innervates a concentric area of the facial skin. To assess the extent of a nuclear lesion, one can therefore test the protopathic sensibility along the concentric **SOELDER's lines.**

Fig. 12.147 Zoster ophthalmicus. [E943]
Patient with zoster ophthalmicus (viral infection of the skin in the innervation area of the first trigeminal branch with varicella zoster viruses, the so-called facial herpes zoster). The involvement of the superficial epithelium of the eye (cornea and conjunctiva) is particularly dangerous (risk of blindness) and painful. The marked redness of the conjunctiva and the narrowed lid of her left eye are clearly visible.

Clinical Remarks

Loss of sensibility in the innervation area of a trigeminal branch generally suggests a **peripheral lesion** of the nerve. Potential causes for lesions of the N. ophthalmicus [V/1] and the N. maxillaris [V/2] are a cavernous sinus thrombosis (→ p. 357), tumours and fractures of the cranial base. Sensory disturbances in the mandibular region or paralysis of the muscles of mastication do often have iatrogenic causes (by the dentist).
In the common and not yet completely understood **trigeminal neuralgia** (often thought to be caused by a pathological neurovascular contact between the A. superior cerebelli and the N. trigeminus [V] at its exit site from the brain stem), hypersensitivity of the N. trigeminus [V] results repetitively in acute, strong stabbing pain in the sensory innervation area of the affected trigeminal branch. Even the slightest touch of the corresponding exit sites (→ Fig. 12.146) can trigger extremely severe and stabbing pain attacks.
Neuralgia of the N. ophthalmicus [V/1] can occur as post-zoster neuralgia (after a varicella zoster virus infection of the first trigeminal branch, so-called **zoster ophthalmicus**; → Fig. 12.147).

N. abducens [VI]

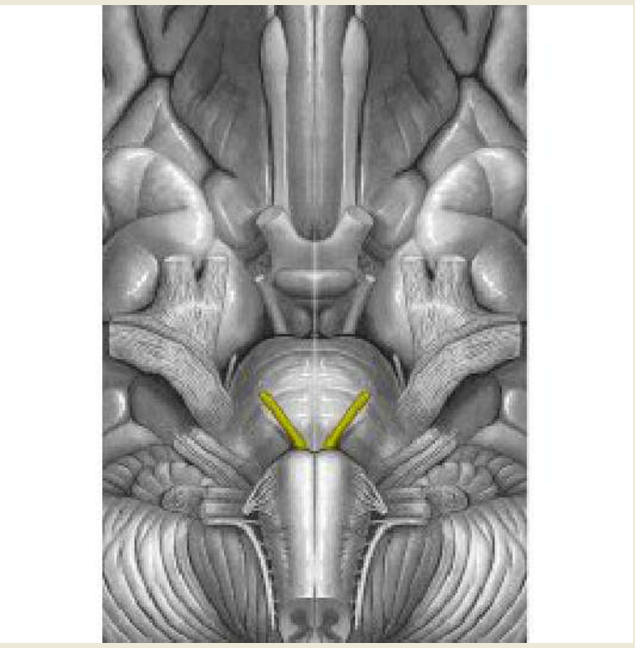

Fig. 12.148 Exit site of the N. abducens [VI] at the brain stem; inferior view. The sixth cranial nerve [CN VI] exits below the pons.

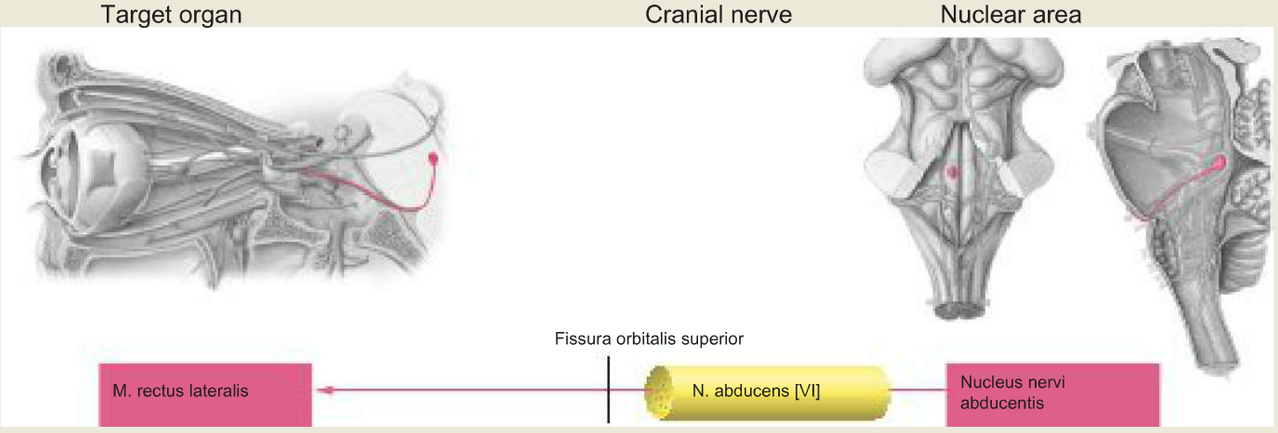

Fig. 12.149 Course, branches and fibre qualities of the N. abducens [VI]; lateral view. [L127] Compare → Fig. 12.134

Clinical Remarks

Sixth nerve palsy or palsy of the abducent nerve is particularly frequently due to the long extradural course of the N. abducens [VI] along the clivus (nerve lesion in the case of cranial base fractures) and on its passage through the Sinus cavernosus (cavernous Sinus thrombosis). If the patient is asked to look to the temporal side, the affected eyeball remains directed straight ahead, since the M. rectus lateralis is paralysed. The patient then sees double images.

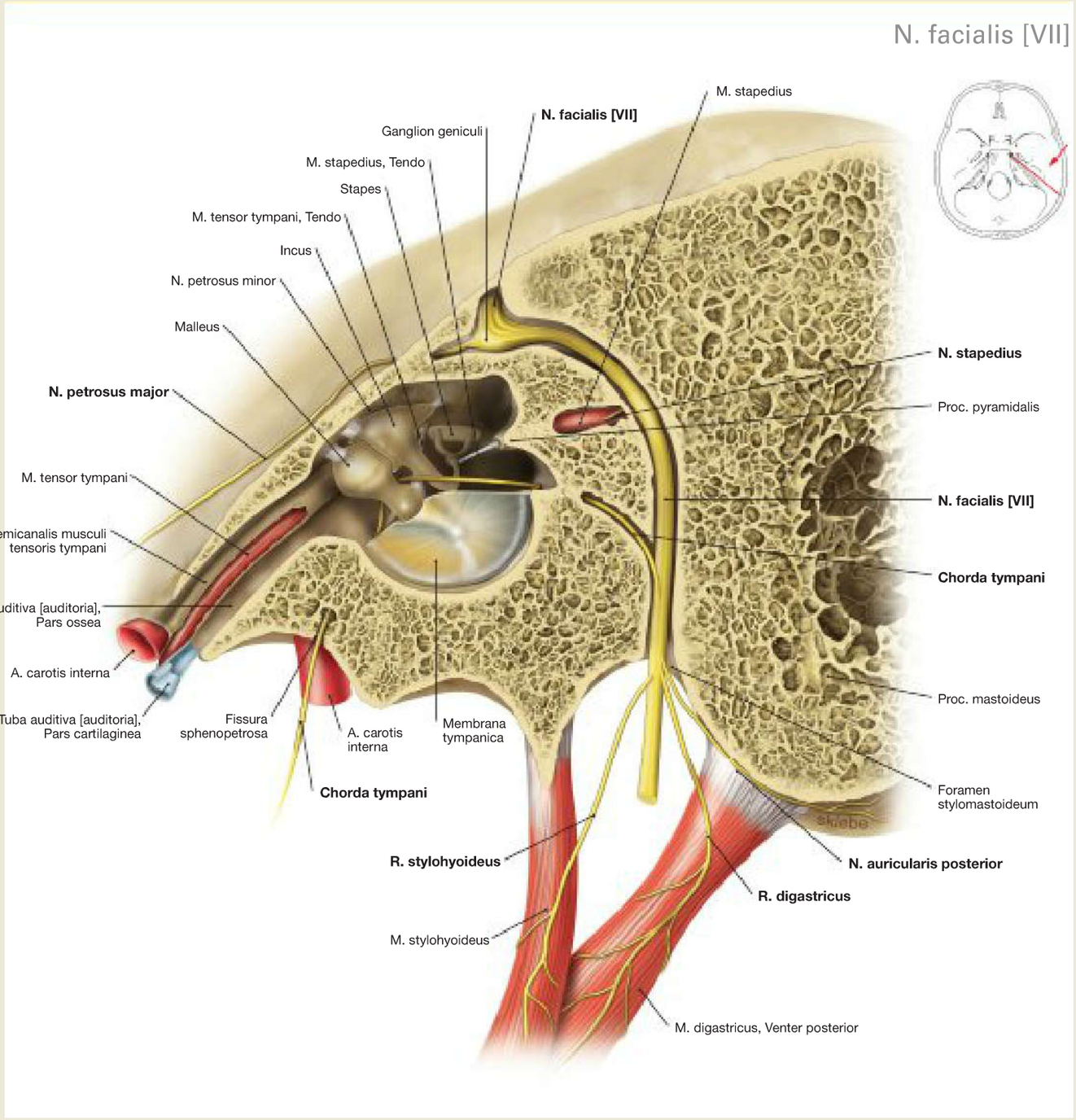

Fig. 12.150 Course of the N. facialis [VII]; vertical section through the Canalis facialis; view from the left side. [L238]
Approximately 1 cm after entering the petrous part of the temporal bone through the Porus acusticus internus (not shown), the N. facialis [VII] forms its external genu (Ganglion geniculi). The main stem of the nerve runs within a bony canal to the Foramen stylomastoideum. Along its way through the petrous bone, the N. facialis [VII] releases the N. petrosus major, N. stapedius, and the Chorda tympani (→ Table, on p. 373).

→ T 58g

Clinical Remarks

The close topographical relationship of the Canalis facialis to the tympanic cavity facilitates lesions of the N. facialis [VII] in the case of petrous bone fractures, or inflammations of the middle ear and mastoid, and during surgical interventions on the middle and inner ear. The symptoms depend on the location of the lesion. If the **lesion is located at or in front of the Ganglion geniculi,** it leads to paralysis all facial (mimetic) muscles. Furthermore, this results in failure of the M. stapedius (hyperacusis), taste disorders, and impaired secretions of the lacrimal, nasal and salivary glands.
If the **lesion is located below the bifurcation of the N. stapedius,** the taste sense and secretion functions controlled by the Chorda tympani will be impaired as well as the facial (mimetic) muscles. Due to its unprotected course between the Malleus and Incus, the **Chorda tympani** can also be damaged separately in the case of middle ear infections (→ p. 180), or during middle ear and inner ear surgery. The biggest problem in patients with peripheral facial palsy is a **lagophthalmus** (due to paralysis of the M. orbicularis oculi, the eye cannot be closed properly; → Fig. 12.155c), causing the cornea to dry out (leading to blindness, induced by the lack of blinking and reduced production of lacrimal fluid).

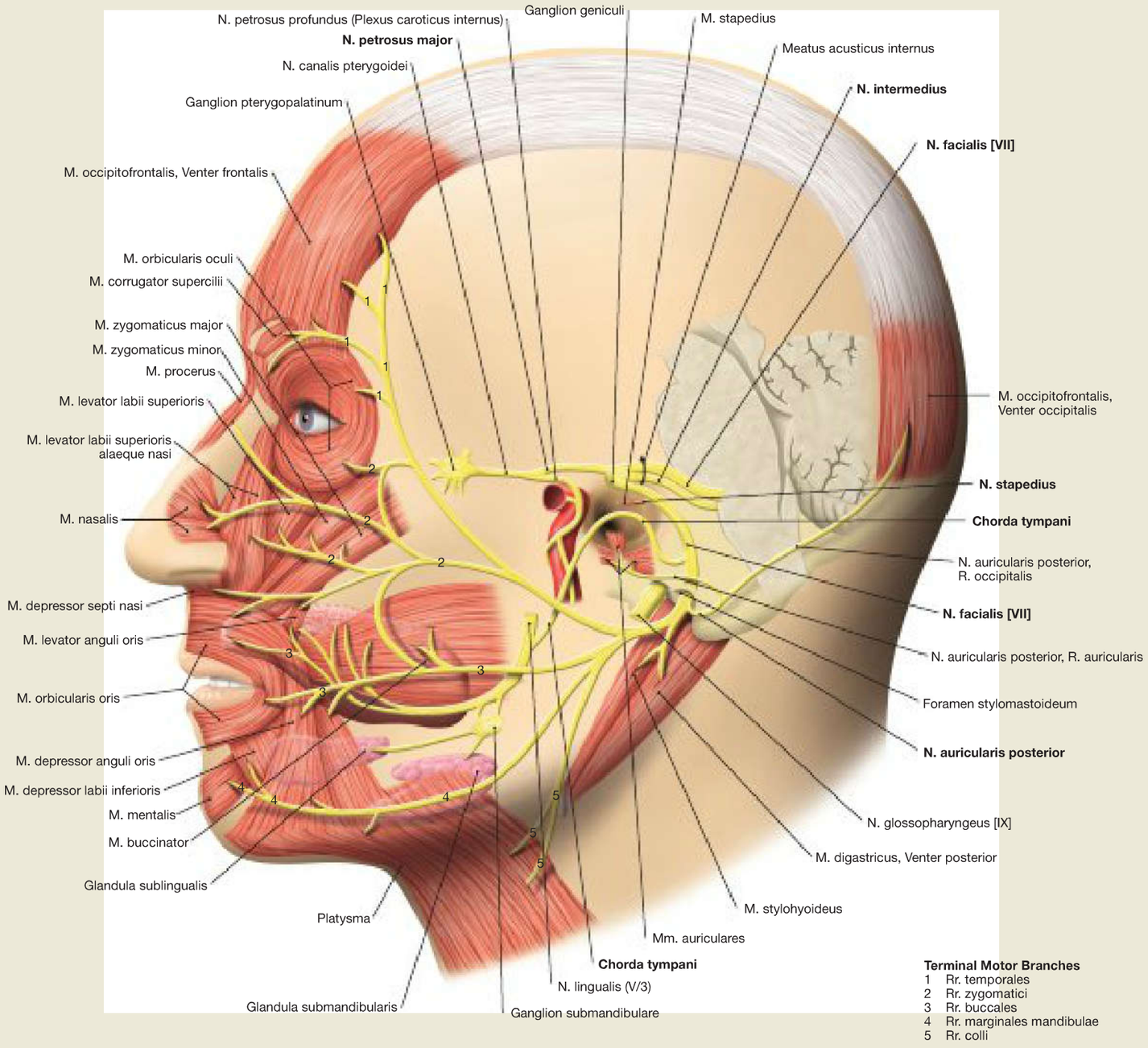

Fig. 12.151 N. facialis [VII], left side; lateral view. [L127]
The N. facialis [VII] exits at the cerebellopontine angle in conjunction with the N. intermedius (a part of the N. facialis [VII], often viewed as a separate nerve), and the N. vestibulocochlearis [VIII]. After a short distance the N. intermedius unites with the N. facialis [VII]. The N. facialis [VII] and N. vestibulocochlearis [VIII] run to the Pars petrosa of the Os temporale and enter the bone via the Porus and Meatus acusticus internus. After the Nn. cochlearis and vestibularis branch off, the N. facialis [VII] passes into the Canalis facialis (→ Fig. 12.159). There it turns in an almost right-angled, posterior inferior direction (external genu of the facial nerve; → Fig. 12.150). The Ganglion geniculi is located just prior to the location of the turn of N. facialis [VII]. Along its course in the Canalis facialis, the seventh cranial nerve [CN VII] provides several branches (→ Table, on p. 373). After leaving the cranial base through the Foramen stylomastoideum, it turns rostrally, provides other branches, and then enters the Glandula parotidea, where it divides into its motor terminal branches (Plexus intraparotideus; → Table, on p. 373).

→ T 58g

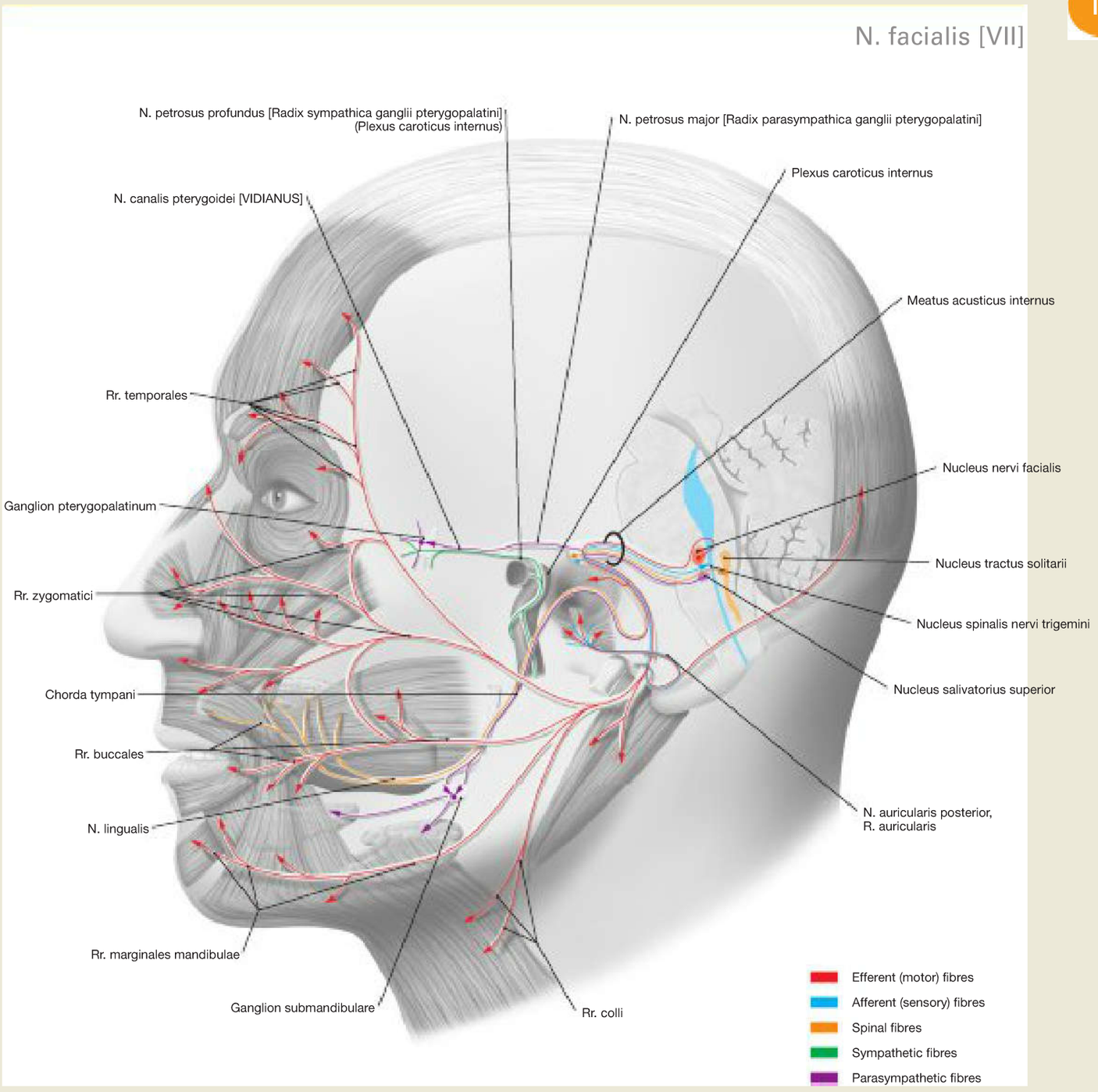

Fig. 12.152 Fibre qualities of the N. facialis [VII], left side; lateral view. [L127]

The N. facialis [VII] is the nerve of the second pharyngeal arch. It is a complex nerve with several different fibre qualities.

Its **motor fibres** (special visceral efferent, SVE) originate from the **Nucleus nervi facialis**. They run in a posterior arch around the Nucleus nervi abducentis (internal genu of the facial nerve). The upper part of the nucleus contains the neurons for the facial (mimetic) muscles of the forehead and eye, and the lower part of the nucleus harbours the neurons for the facial muscles below the eye. The upper nuclear portion has a double innervation from both hemispheres (→ Fig. 12.156). It therefore receives corticonuclear fibres from the ipsilateral and contralateral sides. The lower nuclear portion is only reached by corticonuclear fibres from the opposite (contralateral) side.

Preganglionic parasympathetic fibres originate from the **Nucleus salivatorius superior** (general visceral efferent, GVE). They run with the intermediate nerve across the N. facialis [VII], then pass via the N. petrosus major to the Ganglion pterygopalatinum, or join the Chorda tympani to continue within the N. lingualis (from V/3), and reach the Ganglion submandibulare. In these ganglia, the switching (synapsing) then takes place on the **postganglionic fibres.** The postganglionic fibres project into the lacrimal, nasal and palatine glands, as well as into the Glandula sublingualis and Glandula submandibularis (→ N. trigeminus [V], p. 365).

Special visceral afferent (SVA) fibres of the anterior two-thirds of the tongue which mediate taste sensations, project into the upper part of the **Nucleus tractus solitarii**. The fibres join the N. lingualis and pass to the N. facialis [VII] via the Chorda tympani and from here to the brain stem.

General somatic afferent fibres (GSA) from the posterior wall of the external acoustic meatus, and partially also from the region behind the ear, the auricle and the tympanic membrane join the N. vagus [X] (R. communicans cum nervo vago) for a short distance, but leave it already in the Pars petrosa to join the N. facialis [VII]. The perikarya of these fibres as well as the perikarya of the gustatory (taste) fibres are located in the Ganglion geniculi. They reach the Nucleus spinalis nervi trigemini via the intermediate part of the N. facialis [VII].

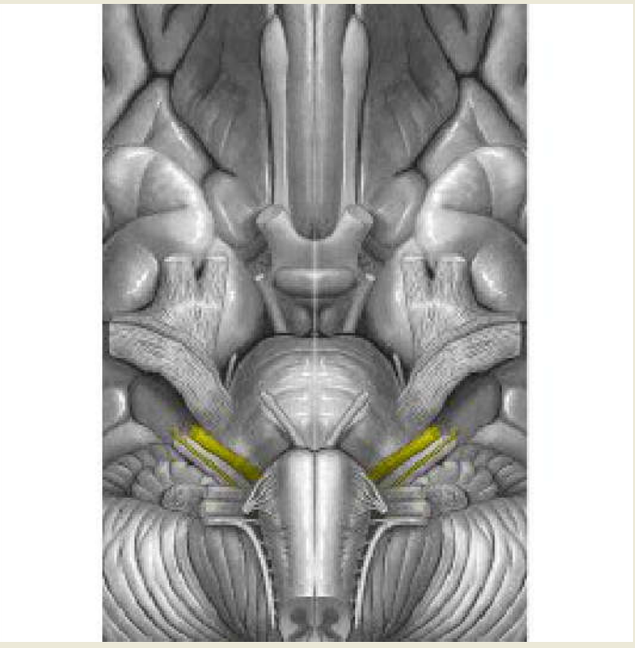

Fig. 12.153 Exit site of the N. facialis [VII] at the brain stem; inferior view.

The seventh cranial nerve [CN VII] exits at the cerebellopontine angle. Also, the N. intermedius located on the N. vestibulocochlearis [VIII] is highlighted in yellow.

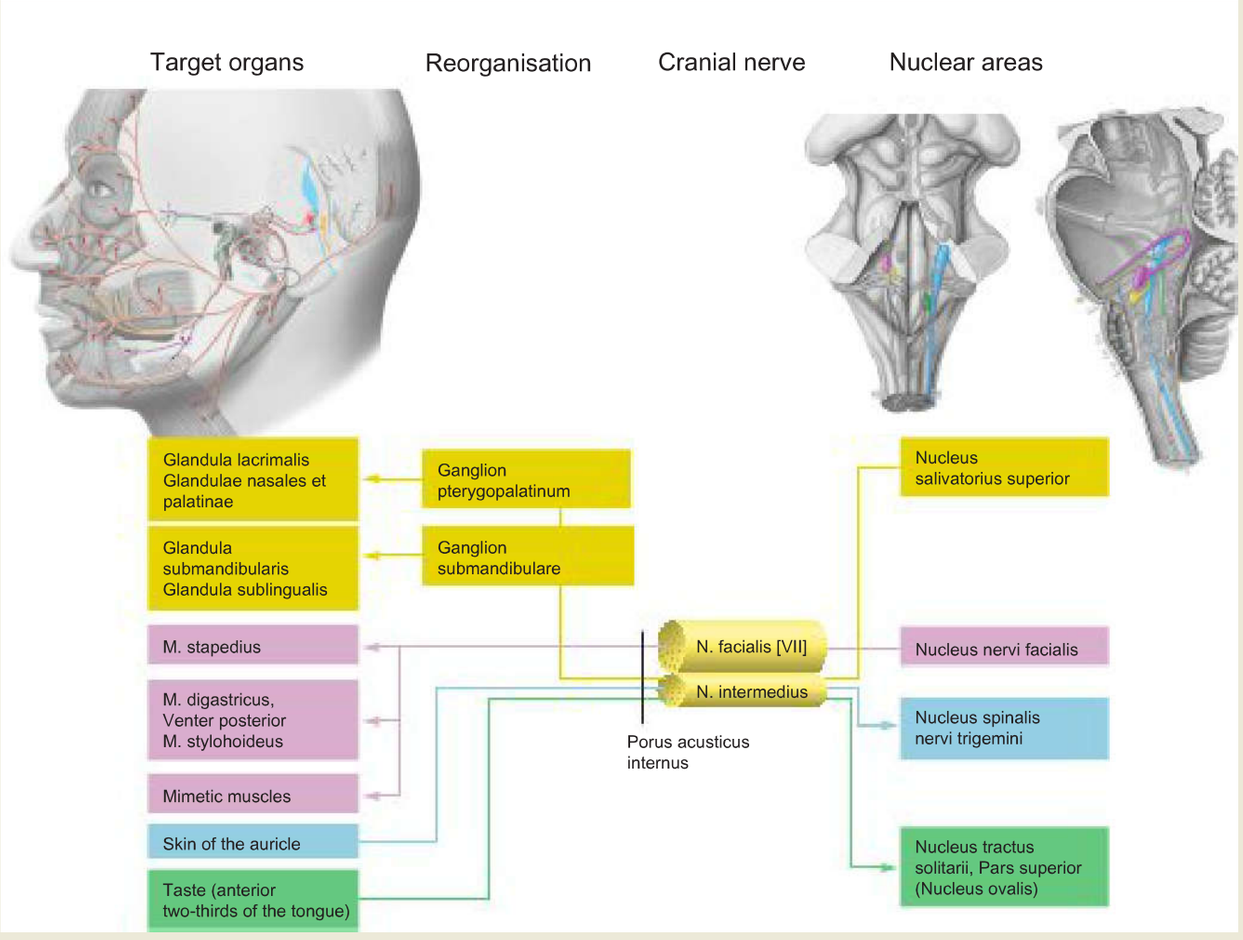

Fig. 12.154 Course, branches, fibre qualities, cranial nuclei and target organs of the N. facialis [VII]; lateral view. [L127]

Branches of the N. facialis [VII]

Branch	Course	Innervation Area
N. petrosus major [Radix parasympathica ganglii pterygopalatini]	Passes from the external genu of the facial nerve through the Canalis nervi petrosi majoris into the middle cranial fossa; enters the Canalis pterygoideus via the Foramen lacerum, in which it continues together with the sympathetic N. petrosus profundus as N. canalis pterygoidei to reach the Ganglion pterygopalatinum (switching of the parasympathetic fibres)	**GVE** (via branches of the N. maxillaris [V/2]): Glandulae lacrimalis, nasales, palatinae and pharyngeales **SVA** (via branches of the N. mandibularis [V/3]): taste buds of the palate
N. stapedius	Branches off in the lower part of the Canalis facialis	**SVE:** M. stapedius
Chorda tympani	Shortly before the distal end of the Canalis facialis it runs in the opposite direction within its own bony canal to the tympanic cavity, which it traverses without bony protection between the handle of the malleus and the long limb of the incus behind the tympanic membrane; joins the N. lingualis (from V/3) after passing through the Fissura petrotympanica	**GVE** (via the N. lingualis, switches in the Ganglion submandibulare): Glandulae submandibularis and sublingualis **SVA** (via N. lingualis): anterior two-thirds of the tongue
N. auricularis posterior	Branches off shortly after leaving the Canalis facialis	**SVE:** M. occipitofrontalis, ear muscles
Rr. digastricus and stylohyoideus	Small muscular branches	**SVE:** M. digastricus, Venter posterior, M. stylohyoideus
Plexus intraparotideus	The motor terminal branches to the facial (mimetic) muscles subdivide in the Glandula parotidea into a Pars temporofacialis and a Pars cervicofacialis, which in turn are fanned out in five terminal branches: Rr. temporales, Rr. zygomatici, Rr. buccales, Rr. marginales mandibulae, R. colli (or Rr. colli, → Fig. 8.94)	**SVE:** mimetic muscles including M. buccinator and platysma

Fig. 12.155a to e Peripheral paralysis of the N. facialis [VII], right side. [T887]
a Admission status of the patient. The skin creases in the right half of the face have disappeared (smoothed).
b If the patient raises his eyebrows upon request, only the left half of the forehead displays wrinkles (loss of function of the M. occipitofrontalis indicates a peripheral facial nerve palsy).
c When the patient is asked to shut both eyes, he cannot do this on the side of the damaged facial nerve (lagophthalmus). The eyeball automatically turns upwards when closing the eyes. Because the eyelids do not close properly on the affected side, the white sclera becomes visible (BELL's palsy).
d When the patient is asked to wrinkle his nose, he cannot do this on the right side of his face.
e When the patient is asked to whistle, no tone is produced but the air escapes through the lips on the paralysed side.

Clinical Remarks

A **supranuclear lesion** (lesion of corticonuclear fibres, e.g. due to an infarction in the Capsula interna) results in a **central facial palsy** (so-called lower facial palsy). But in contrast to an infranuclear lesion, and due to the double innervation of the mimetic muscles of the eye and forehead, only the lower contralateral (opposite) half of the face is affected by motor deficits (→ Fig. 12.156).
An **infranuclear lesion** (lesion site below the nucleus of the facial nerve), e.g. due to a malignant tumour of the parotid gland, results in failure of all motor terminal branches of the N. facialis [VII] on the same side **(peripheral facial palsy).**
An **acoustic neurinoma** (→ p. 377) is a tumour derived of SCHWANN's cells of the N. vestibulocochlearis [VIII] or the N. facialis [VII]. Sooner or later, this slow-growing benign tumour will displace and damage both nerves. This manifests as a peripheral palsy of the N. facialis [VII]. All topodiagnostic tests (→ p. 374) are negative. The diagnosis is confirmed by means of MRI or CT imaging.

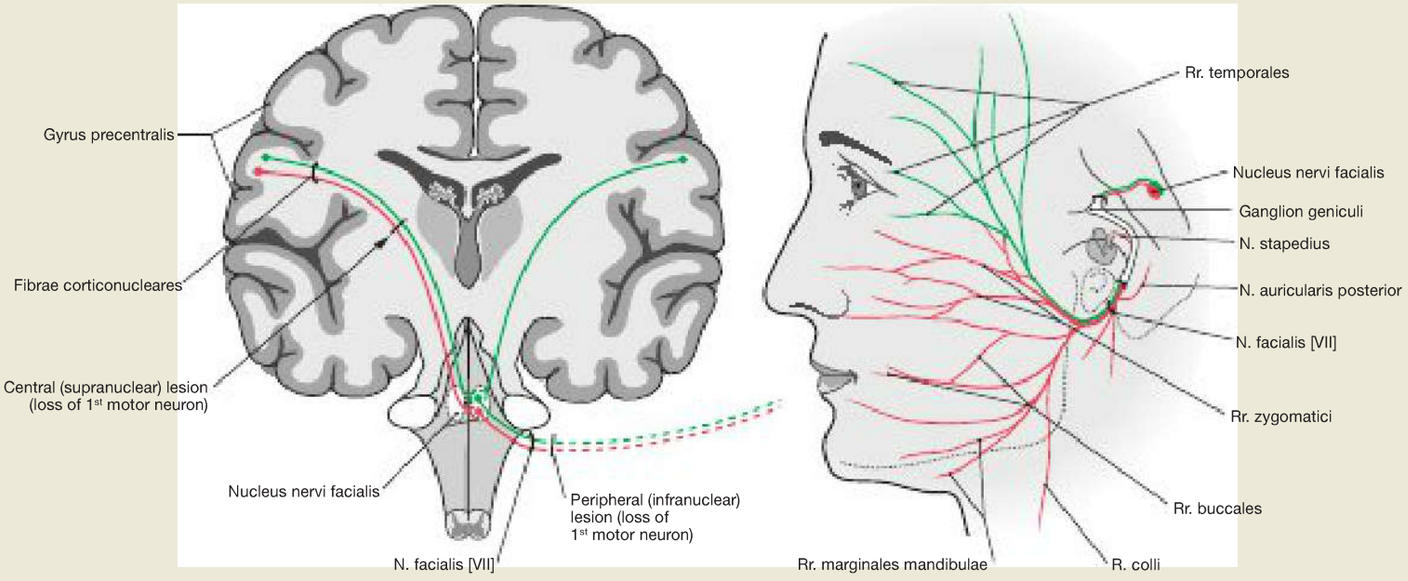

Fig. 12.156 Corticonuclear connections and peripheral course of the N. facialis [VII]. [L126]
On the left side, the central connections to the Nucleus nervi facialis are presented in simplified form. The corticonuclear tracts to the upper part of the nucleus (for Rr. temporales; green) come from both hemispheres. The tracts to the lower nuclear portion (for Rr. zygomatici, buccales, marginales mandibulae and R. colli; red) only come from the contralateral (opposite) hemisphere.
On the right side, the peripheral efferent fibres (SVE) derived from the upper and lower parts of the Nucleus nervi facialis are shown.

Clinical Remarks

Lesion site of peripheral facial palsy
With the advent of modern high-resolution imaging techniques, the classical topodiagnostic tests have largely lost their importance because of their usually unspecific and low-sensitive prognostic value in terms of the outcome and healing time of a facial palsy, as compared to electrodiagnostic procedures. Nevertheless, individual tests are assigned clinical relevance.

- The SCHIRMER's test provides information about the normal function of the lacrimal fluid production (→ Fig. 9.32).
- With the acoustic (stapedial) reflex test the function of the N. stapedius is determined.
- With gustometry (test of taste perception) the integrity of the Chorda tympani can be assessed.
- The mimetic muscles can be tested with electrical stimulation or excitability of the nerves.
- The conduction velocity on both sides can be compared by using electroneurography to find differences between the healthy and damaged sides.

Lesion Site	Topodiagnostic Tests	Cause of Lesion (Aetiology)
Below the nucleus/nuclear area in the brain stem	MRT, CT, SCHIRMER's test (of the function of the lacrimal gland)	e.g. acoustic neurinoma
After N. petrosus major has branched off	Stapedial reflex test	e.g. otitis media
After Chorda tympani has branched off	Gustometry (testing the taste perception)	e.g. otitis media
After passing through the Foramen stylomastoideum	Testing the motor function of facial muscles	e.g. malignant tumour of the parotid gland

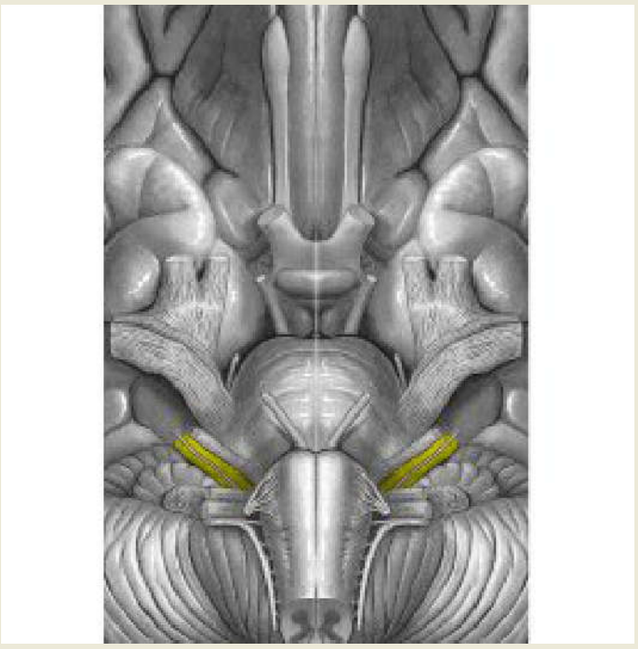

Fig. 12.157 Exit site of the N. vestibulocochlearis [VIII] at the brain stem; inferior view.
The eighth cranial nerve [CN VIII] exits at the cerebellopontine angle.

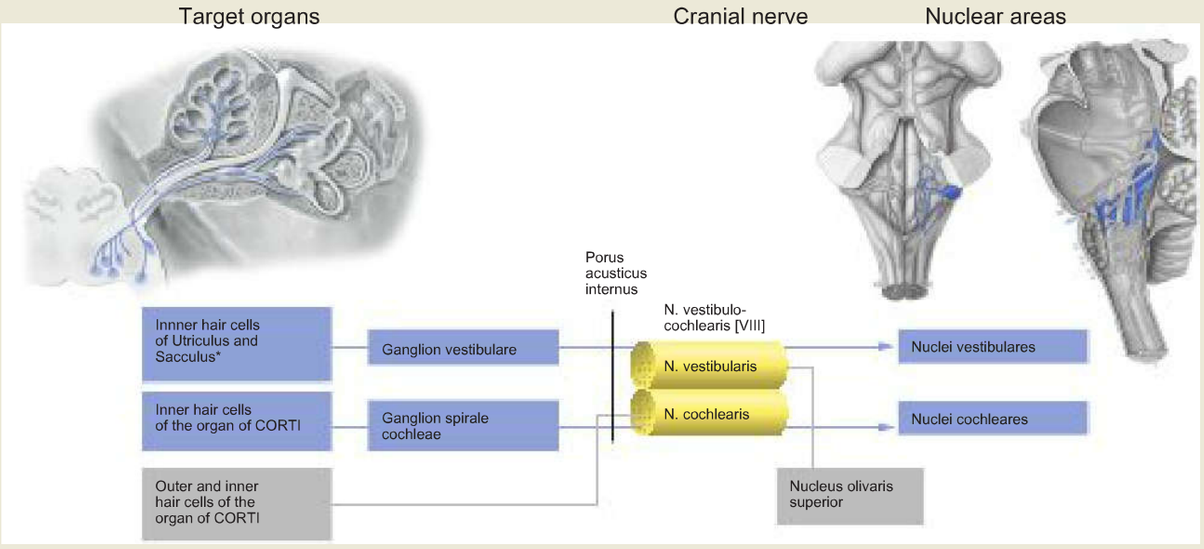

* and hair cells of the three arcades

Fig. 12.158 Course, branches and fibre qualities of the N. vestibulocochlearis [VIII]; lateral view. [L127]

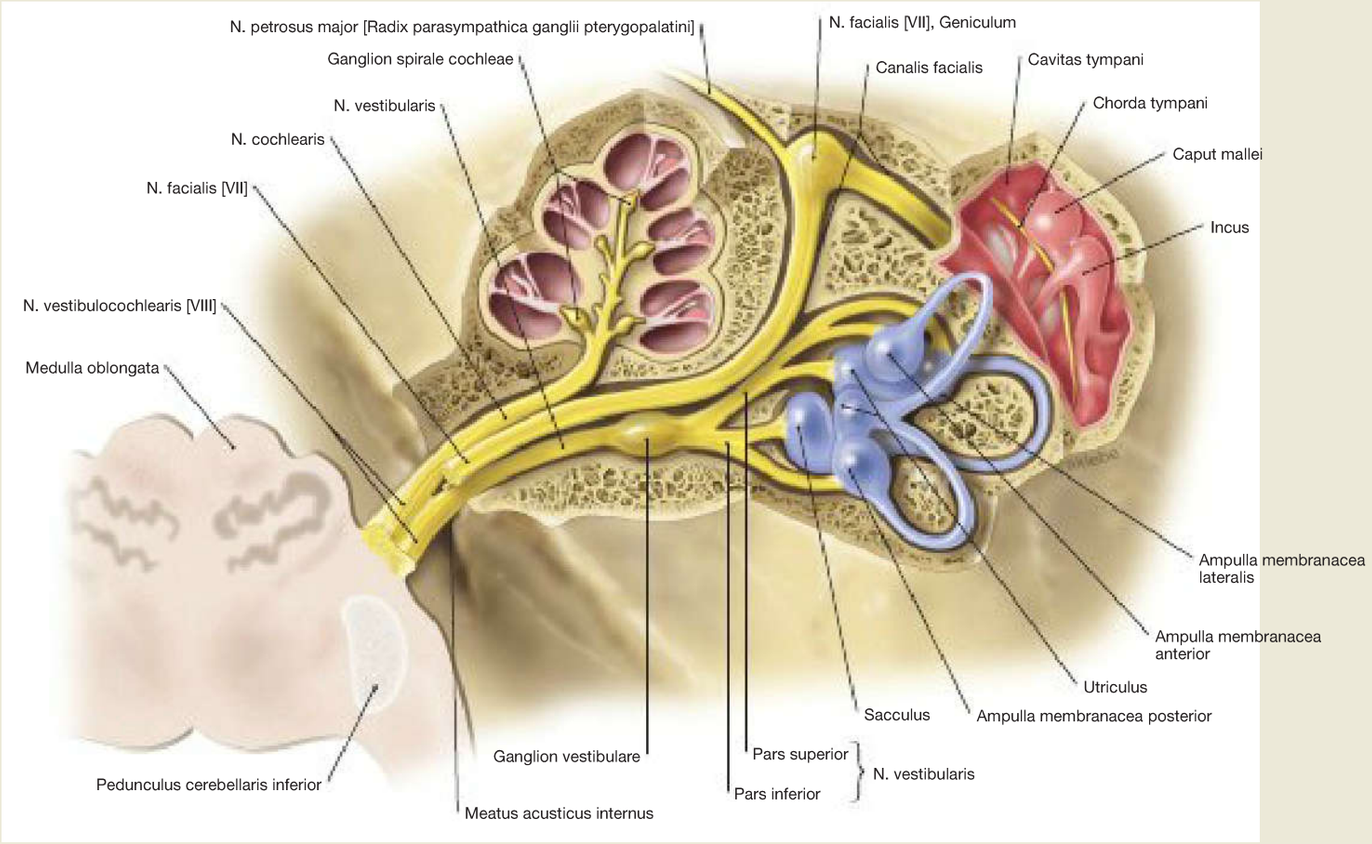

Fig. 12.159 N. vestibulocochlearis [VIII], course in the Pars petrosa of the Os temporale; superior view; Pars petrosa opened. [L238]

The nerve fibres of the **N. cochlearis** originate from the organ of CORTI in the cochlea. Their cell bodies (perikarya) are located in the Ganglion spirale cochleae within the modiolus (bipolar nerve cells). The central cell processes (axons) finally form the N. cochlearis. The vestibular organ also possesses bipolar neurons. Similar to the neurons of the auditory system, they receive sensory information from the hair cells. Their cell bodies lie in the Ganglion vestibulare which is located on the floor of the Meatus acusticus internus. The central processes of the neurons form the **N. vestibularis,** which unites with the N. cochlearis at the Meatus acusticus internus to form the N. vestibulocochlearis [VIII] (common clinical term: N. statoacusticus) and enters the brain stem at the cerebellopontine angle.

The course of the N. facialis [VII] in the Meatus acusticus internus and subsequently in the Canalis facialis is also shown here. In addition, the Ganglion geniculi, the branching-off N. petrosus major, and the course of the N. facialis [VII] in the wall of the tympanic cavity are visible. The Chorda tympani runs between the Malleus and the Incus.

→ T 58h

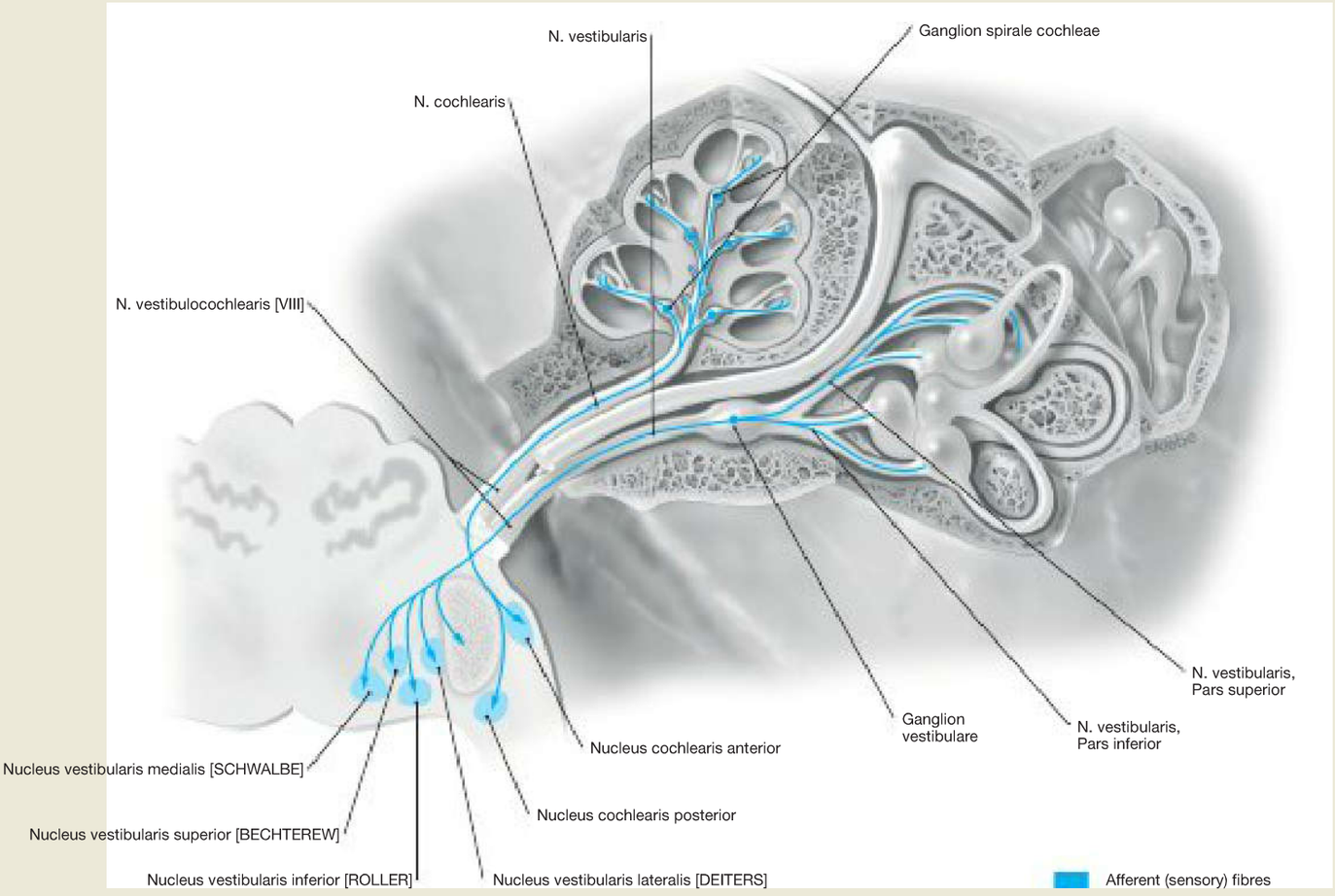

Fig. 12.160 Fibre qualities of the N. vestibulocochlearis [VIII]; superior view; Pars petrosa of the Os temporale opened. [L238]
The hair cells within the organ of CORTI and the hair cells of the semicircular canals as well as the Utriculi and Sacculi of the vestibular apparatus transmit sensory information to the special somatic afferent neuronal fibres (SSA). These fibres are the peripheral processes of bipolar neurons (first neuron of the auditory and vestibular tracts). The perikarya of these bipolar neurons lie in the Ganglion spirale cochleae or in the Ganglion vestibulare. The **central projections** of the **Ganglion spirale** merge to form the **N. cochlearis**, and course through the Meatus acusticus internus to reach the brain stem via the cerebellopontine angle. Here they connect to the Nuclei cochleares anterior and posterior. The **central projections of the first neuron of the vestibular tract** (SSA) unite to form the **N. vestibularis**, and also reach the Medulla oblongata via the cerebellopontine angle. They project here into the Nuclei vestibulares medialis (SCHWALBE), superior (BECHTEREW), inferior (ROLLER) and lateralis (DEITERS).

Clinical Remarks

Sudden hearing loss, ringing in the ears, balance disorder and vertigo may be first signs of an **acoustic neurinoma**. This is a benign tumour of connective and neural tissues, which derives mostly from SCHWANN's cells of the vestibular part of the N. vestibulocochlearis [VIII] **(schwannoma of the vestibular nerve)** and lies in the cerebellopontine angle or in the Meatus acusticus internus. In 5% of all cases, the acoustic neuroma occurs bilaterally. Due to the joint course with the N. facialis [VII], a peripheral facial palsy can occur.

N. glossopharyngeus [IX]

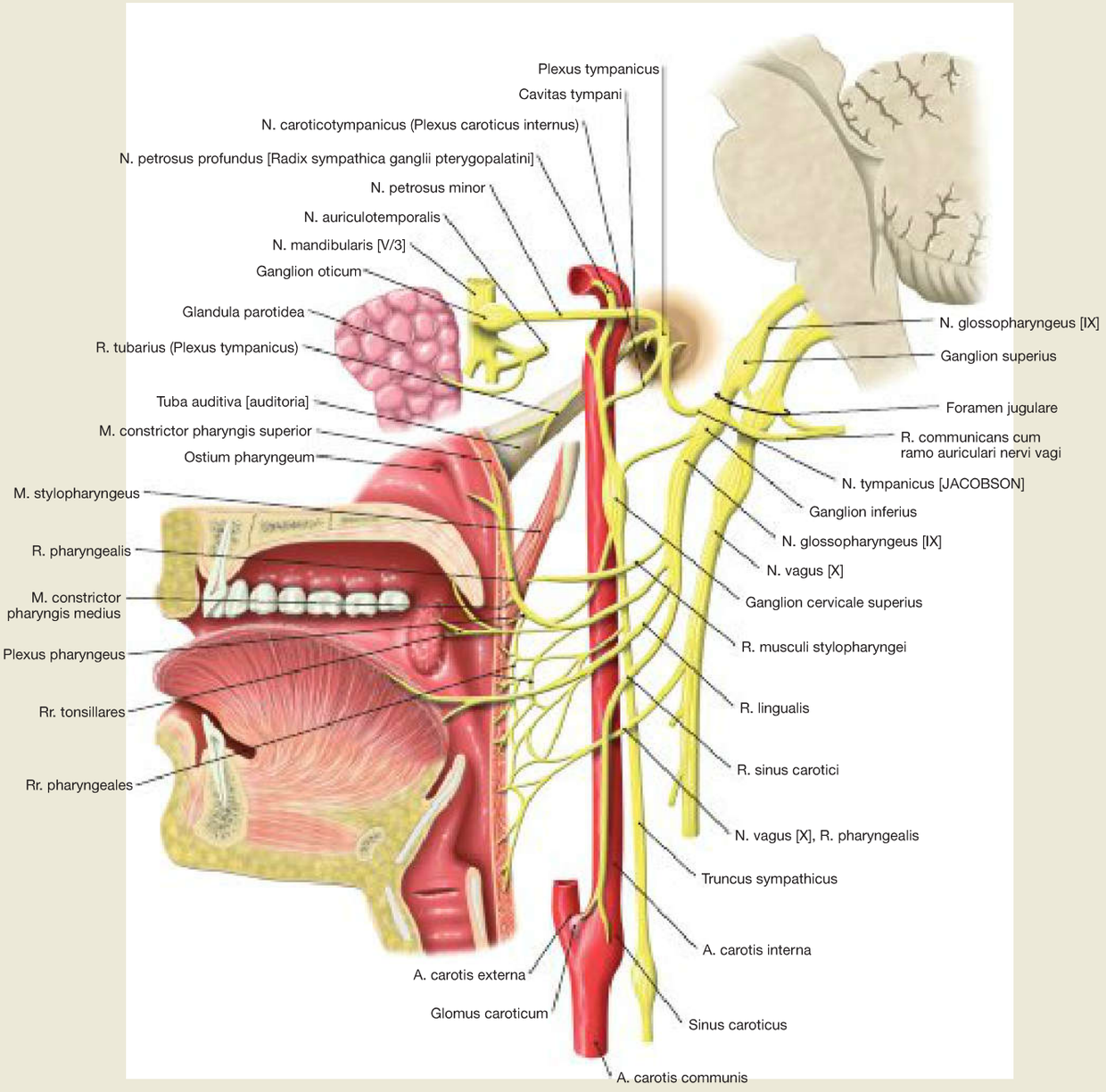

Fig. 12.161 N. glossopharyngeus [IX]; schematic median section; view from the left side. [L127]

The N. glossopharyngeus [IX] exits the brain stem together with the N. vagus [X], and the N. accessorius [XI] via the Sulcus retro-olivaris, and all three nerves pass through the Foramen jugulare at the cranial base. Within the foramen lies the smaller Ganglion superius of the N. glossopharyngeus, and directly below it the Ganglion inferius. Thereafter, the nerve runs between the V. jugularis interna and A. carotis interna downwards, and in an arch-like course it enters the root of the tongue from behind between the Mm. stylopharyngeus and styloglossus. Along its course it provides the **N. tympanicus**, which runs to the tympanic cavity, divides into the Plexus tympanicus of the mucosa, and subsequently leaves the tympanic cavity as **N. petrosus minor**. The N. petrosus minor accompanies the N. petrosus major on the anterior surface of the petrous bone, and passes through the Foramen lacerum to reach the Ganglion oticum. The N. glossopharyngeus [IX] innervates the parotid gland via this ganglion.

Additional **branches** are the R. musculi stylopharyngei to the M. stylopharyngeus and the Rr. pharyngeales to the Mm. constrictor pharyngis superior, palatoglossus and palatopharyngeus, as well as sensory fibres to the pharyngeal mucosa and to the Glandulae pharyngeales.

Together with the sympathetic trunk and the N. vagus [X], other fibres of the N. glossopharyngeus [IX] form the **Plexus pharyngeus,** which innervates the Mm. constrictor pharyngis inferior, levator veli palatini and uvulae.

The Rr. tonsillares supply the Tonsilla palatina and the mucosa of the Isthmus faucium, the Rr. linguales contain gustatory (taste) fibres for the posterior third of the tongue. The R. sinus carotici transmits the sensory input from mechanoreceptors and chemoreceptors of the Sinus caroticus and Glomus caroticum to the brain stem.

→ T 58i

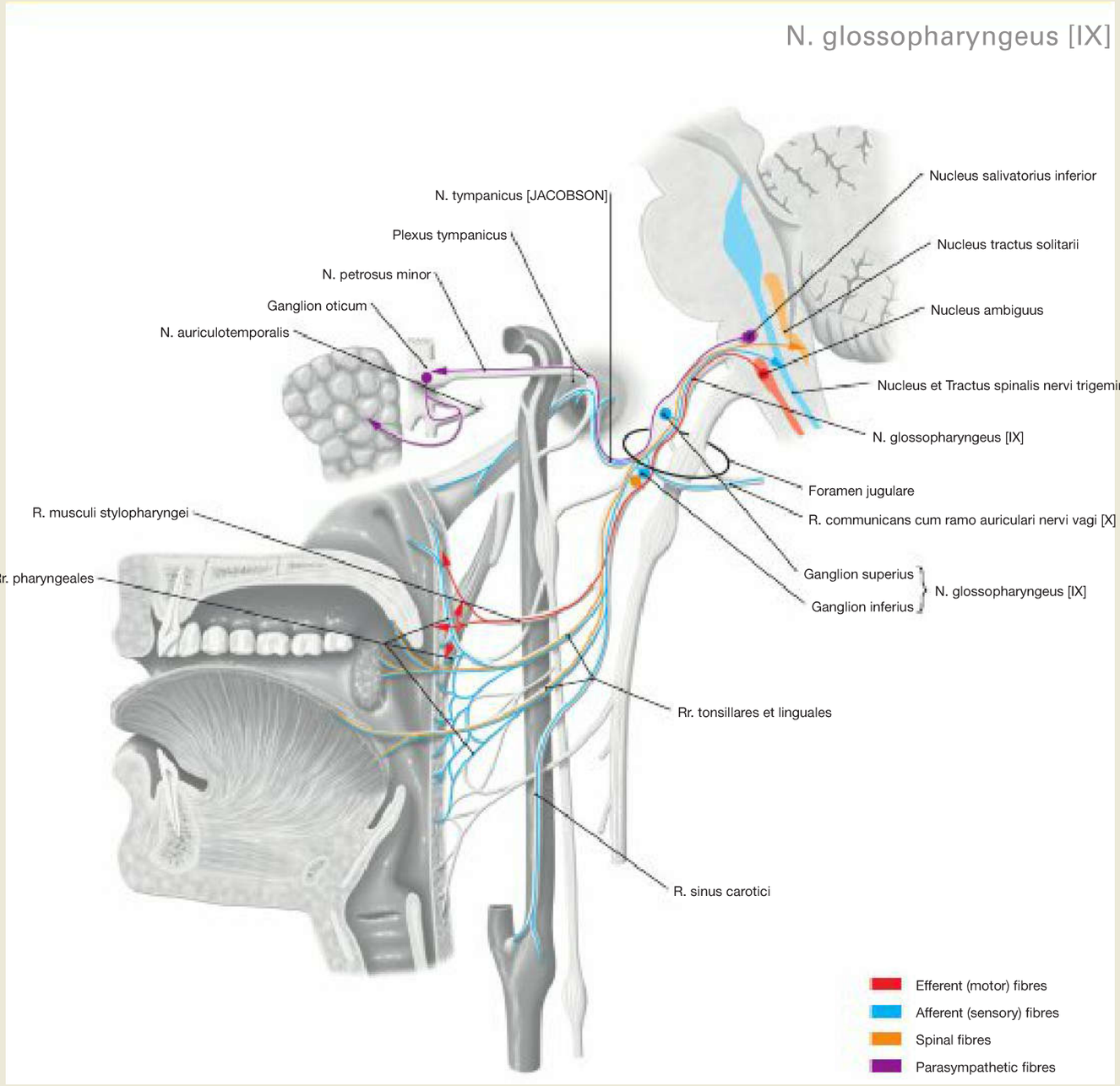

Fig. 12.162 Fibre qualities of the N. glossopharyngeus [IX]; schematic median section; view from the left side. [L127]
Motor fibres (SVE) of the N. glossopharyngeus [IX] originating from the Nucleus ambiguus innervate the pharyngeal muscles and the soft palate in conjunction with motor fibres of the N. vagus [X] (also derived from the Nucleus ambiguus, SVE).
Parasympathetic fibres (GVE) originating in the Nucleus salivatorius inferior, pass via the N. tympanicus, Plexus tympanicus and N. petrosus minor to the Ganglion oticum, where they are switched from preganglionic to postganglionic fibres. The **postganglionic** fibres join the N. auriculotemporalis (from V/3)) and the N. facialis [VII] to reach the Glandula parotidea. Further parasympathetic fibres (GVE) pass to the pharyngeal glands.
Numerous **general somatic afferent** fibres (GSA) that project to the Nucleus spinalis nervi trigemini come from the tympanic cavity, the pharyngeal mucosa, and from the posterior third of the tongue.
General visceral-afferent fibres (GVA) transmit the sensory input of mechanoreceptors in the Sinus caroticus (measuring blood pressure) and of chemoreceptors in the Glomus caroticum (measuring the partial pressure of O_2 and CO_2, and the pH in the blood). The impulses are transmitted to the brain stem. Here they lead to reflexive changes in the respiratory rate and blood pressure.
Special visceral afferent fibres (SVA) conduct taste sensations from the posterior third of the tongue to the Nucleus and Tractus solitarius.

Clinical Remarks

Lesions of the N. glossopharyngeus [IX] result in swallowing difficulties (paralysis of the M. constrictor pharyngis superior, lacking formation of the PASSAVANT's ridge), deviation of the Uvula to the healthy side (paralysis of the Mm. levator veli palatini, palatoglossus, palatopharyngeus and uvulae), impaired sensibility of the pharyngeal region (lack of gag reflex), absent taste sensations in the posterior third of the tongue, as well as impaired secretion of the Glandula parotidea. In most cases, the N. glossopharyngeus [IX] is not exclusively affected. Frequently, the Nn. vagus [X] and accessorius [XI] can also be damaged by fractures, aneurysms, tumours and thrombosis of cerebral blood vessels in the region of the Foramen jugulare.

N. glossopharyngeus [IX]

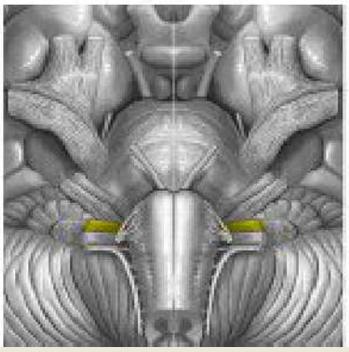

Fig. 12.163 Exit site of the N. glossopharyngeus [IX] at the brain stem; inferior view.
The ninth cranial nerve [CN IX] exits the Medulla oblongata via the Sulcus retroolivaris between the olive and the inferior cerebellar peduncle.

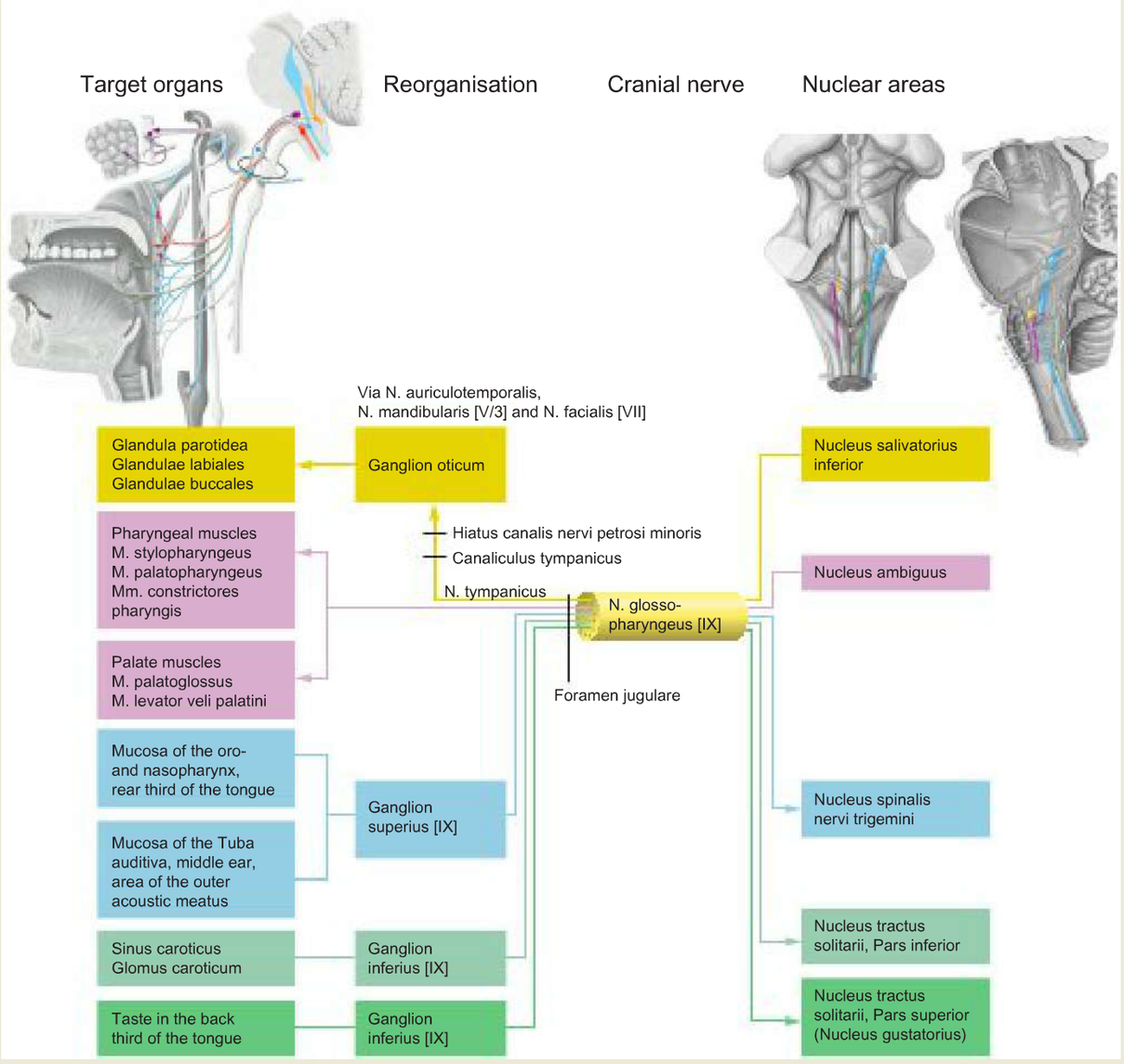

Fig. 12.164 Fibre qualities, cranial nuclei and target organs of the N. glossopharyngeus [IX]; lateral view. [L127]

Clinical Remarks

In the case of an aberrant course of the A. inferior anterior cerebelli, e. g. between the exits of the N. glossopharyngeus [IX] and the N. vagus [X], the arterial pulse can irritate the N. glossopharyngeus [IX]. This may cause unilateral sudden attacks of pain in the tongue, the soft palate or pharynx which result in drinking and swallowing problems **(glossopharyngeal neuralgia).** In rare cases, the N. vagus [X] can also be affected **(vagal neuralgia)** with reflex bradycardia or asystole (cardiac arrest).

N. vagus [X]

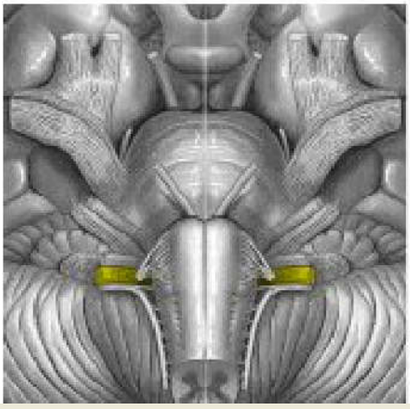

Fig. 12.165 Exit site of the N. vagus [X] at the brain stem; inferior view.
The tenth cranial nerve [CN X] exits via the Sulcus retroolivaris between the N. glossopharyngeus [IX] (cranial) and the N. accessorius [XI] (caudal).

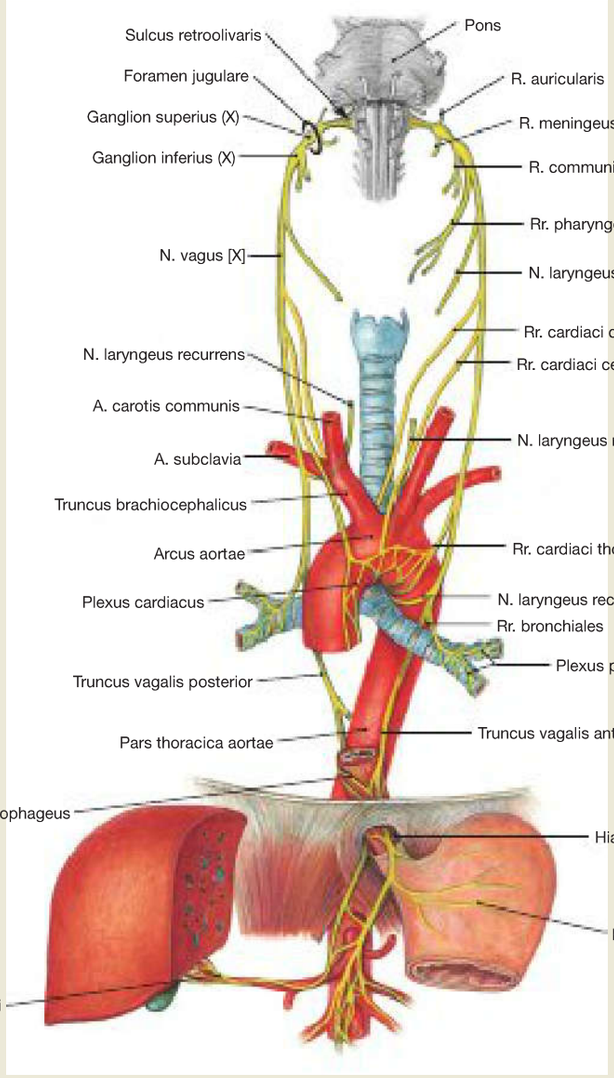

Fig. 12.166 N. vagus [X]; both nerve branches; anterior view.
The figure illustrates the slightly different pathways of the left and right Nn. vagi, as well as the course of the two nerve branches before the transition into the abdominal cavity.

→ T 58j

Clinical Remarks

Complete **lesions of the N. vagus [X]** occur most often near the Foramen jugulare. Frequently, the N. glossopharyngeus [IX] and the N. accessorius [XI] are also affected. Depending on the lesion site, the symptoms include swallowing difficulties and deviation of the uvula to the healthy side (damage of the Plexus pharyngeus), sensory deficits in the region of the pharynx and epiglottis (lack of gag reflex, gustatory impairment), hoarseness (paralysis of laryngeal muscles), tachycardia and arrhythmia (innervation of the heart). Unilateral lesions scarcely restrict the autonomic functions. Bilateral lesions, however, can cause severe respiratory and circulatory problems, and can even be lethal in some patients.

N. vagus [X]

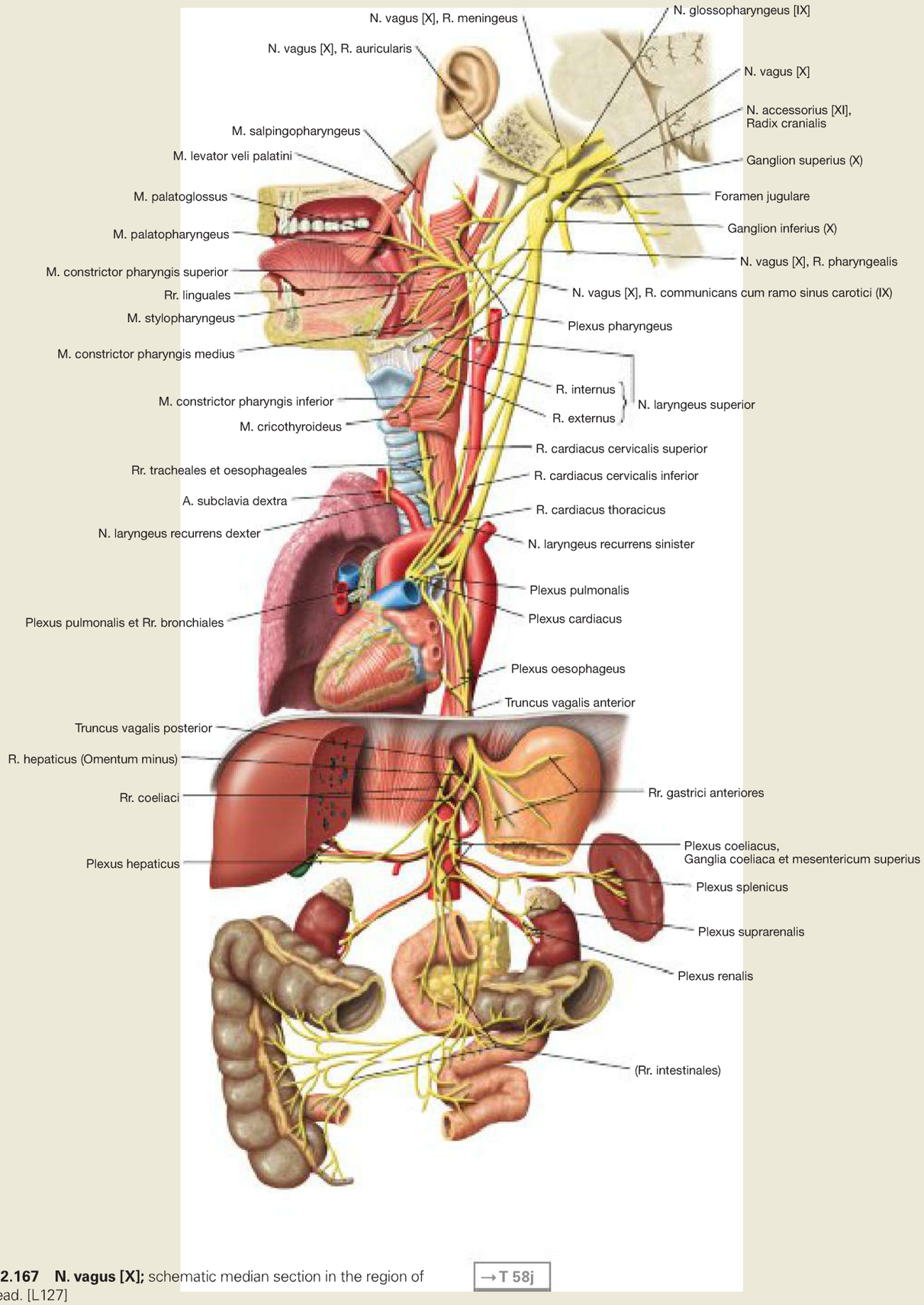

Fig. 12.167 N. vagus [X]; schematic median section in the region of the head. [L127]

→ T 58j

For a detailed description of the course of the N. vagus [X] → p. 384.

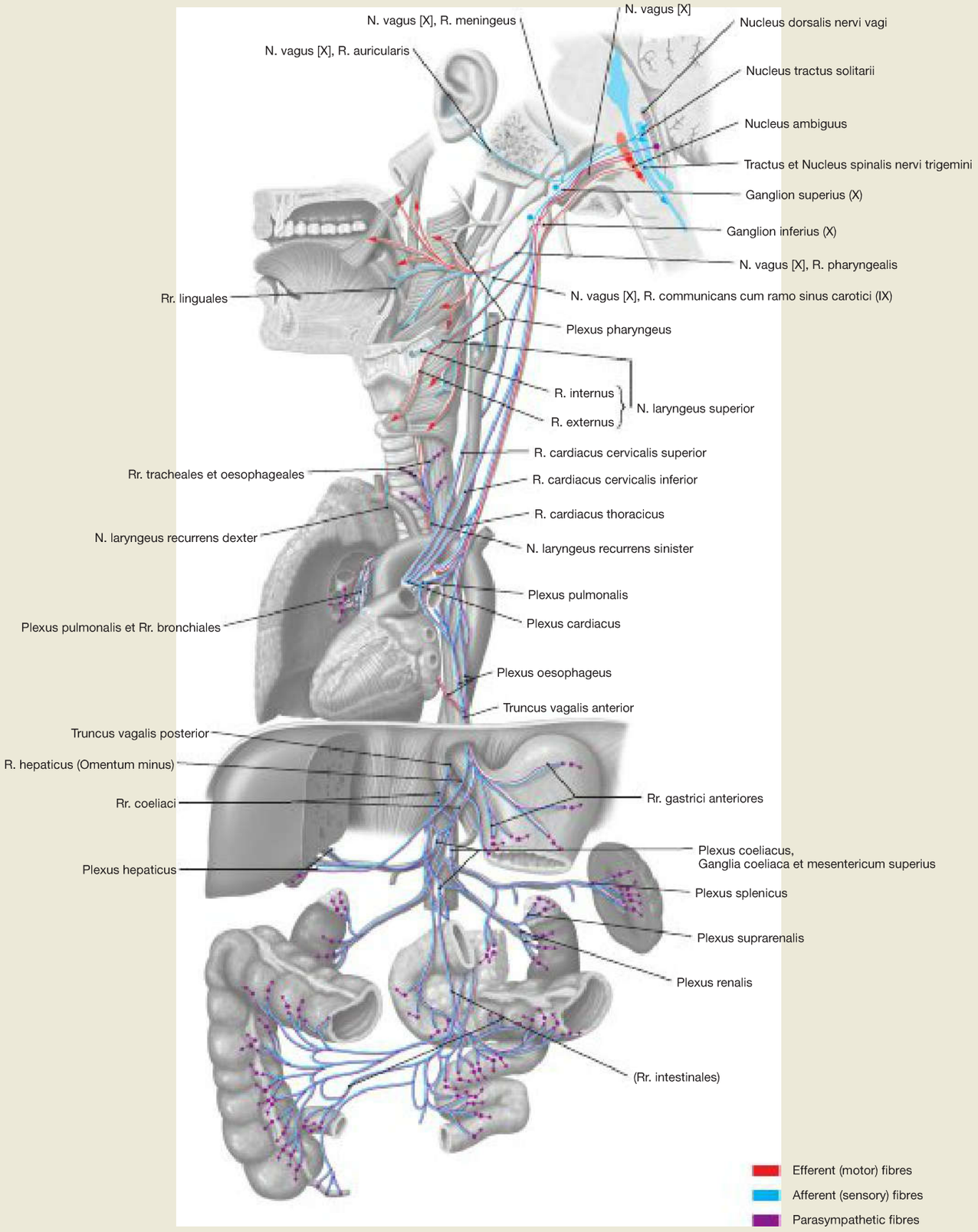

Fig. 12.168 Fibre qualities of the N. vagus [X]; schematic median section in the region of the head. [L127]
For a detailed description of the fibre qualities of the N. vagus [X] → p. 384.

N. vagus [X]

N. vagus [X] → Fig. 12.167
Together with the N. glossopharyngeus [IX] and the N. accessorius [XI], the N. vagus [X] exits the brain stem via the Sulcus retroolivaris and crosses the cranial base through the Foramen jugulare. The **Ganglion superius** is located in the Foramen jugulare, from which the R. meningeus branches off and returns to the posterior cranial fossa for the sensory innervation of the meninges. The R. auricularis branches off as well, which innervates the outer wall of the acoustic meatus. The **Ganglion inferius** is located just below the Foramen jugulare.
The N. vagus [X] crosses the neck and the thoracic cavity, and enters the abdominal cavity. Along its course the N. vagus [X] gradually loses its appearance as a coherent nerve. At the level of the oesophagus, two distinct trunks (Trunci vagales anterior and posterior) can still be discerned, but from the stomach downwards the fibres are more widely branched and form multiple **plexuses** before reaching the liver, pancreas, spleen, kidneys, adrenal glands, small intestine, and colon. The fibres of the N. vagus [X] terminate at the level of the left colic flexure (CANNON-BOEHM's point).
On its **cervical passage,** the N. vagus [X] provides the Rr. pharyngeales, which together with the N. glossopharyngeus [IX] and sympathetic fibres form the **Plexus pharyngeus** (motor innervation of the Mm. constrictores pharyngis medius and inferior, levator veli palatini, uvulae [SVE], parasympathetic innervation of the Glandulae pharyngeales [AVE], and sensory innervation of the pharyngeal mucosa [GVA]). Additional branches are the R. lingualis (taste fibres of the root of the tongue and epiglottis, SVA), the N. laryngeus superior (motor innervation of the Mm. cricothyroideus and constrictor pharyngis inferior with the R. externus, and with the R. internus sensory innervation of the laryngeal mucosa above the vocal folds), and the Rr. cardiaci cervicales superiores and inferiores joining the Plexus cardiacus of the heart (also responsible for the regulation of the blood pressure).
In the **thoracic part** of the N. vagus [X], the N. laryngeus recurrens branches off. On the left side this nerve loops around the aortic arch, and on the right side around the A. subclavia, and projects back cranially to the larynx. There it innervates all laryngeal muscles (with the exception of the M. cricothyroideus) and the mucosa below the vocal folds. Additionally, the Rr. cardiaci thoracici to the Plexus cardiacus branch off in the thoracic part. The Rr. bronchiales join the Plexus pulmonalis and innervate the muscles and glands of the bronchial tree. The tension of the lungs is continuously monitored by the N. vagus [X], and the respiration will be reflexively adjusted.
On the right and left sides, the N. vagus [X] forms a wide-meshed plexus (Plexus oesophagus) around the middle part of the oesophagus, from which finally the two vagal trunks emerge, the Truncus vagalis anterior (in particular fibres of the left N. vagus [X]) and the Truncus vagalis posterior (in particular fibres of the right N. vagus [X]). Both Trunci vagales pass with the oesophagus through the diaphragm into the **abdominal cavity.** From the stomach onwards, the Trunci branch out progressively and form numerous plexuses before reaching the abovementioned abdominal organs.

Fibre qualities of the N. vagus [X] → Fig. 12.168 and Fig. 12.169
Parasympathetic fibres (GVE) of the N. vagus [X] originate from the Nucleus dorsalis nervi vagi in the Medulla oblongata, and innervate glands and smooth muscles of the viscera.
General visceral afferent fibres (GVA) of the same organs project into the Nucleus dorsalis nervi vagi and the Nucleus tractus solitarii.
Special visceral efferent fibres (SVE) originate from the Nucleus ambiguus and innervate the striated muscles of the palate, pharynx, larynx, and oesophagus.
General visceral afferent fibres (GVA) of the mucosa of the same structures project into the Nucleus dorsalis nervi vagi and the Nuclei tractus solitarii.
General somatic afferent fibres (GSA) of the external acoustic meatus and the meninges of the posterior cranial fossa project into the Nucleus spinalis nervi trigemini.
Gustatory fibres (SVA) of the root of the tongue and the epiglottis join the Nucleus tractus solitarii.

N. vagus [X]	
Nuclei (quality)	• Nucleus ambiguus (SVE) • Nucleus tractus solitarii (SVA, GVA) • Nucleus spinalis nervi trigemini (GSA) • Nucleus dorsalis nervi vagi (GVE, GVA)
Exit site at the brain	• Medulla oblongata: Sulcus retroolivaris
Location in the subarachnoid space	• Cisterna basalis
Passage through the cranial base	• Foramen jugulare
Areas of supply	**Motor:** • Pharyngeal muscles (caudal part), M. levator veli palatini, M. uvulae • Laryngeal muscles **Specific sensory:** • Root of the tongue **Sensory:** • Dura of the Fossa cranialis posterior • Meatus acusticus externus (sickle-shaped deep part) • Membrana tympani (outer surface) **Parasympathetic:** • Cervical, thoracic and abdominal organs up to the CANNON-BOEHM's point

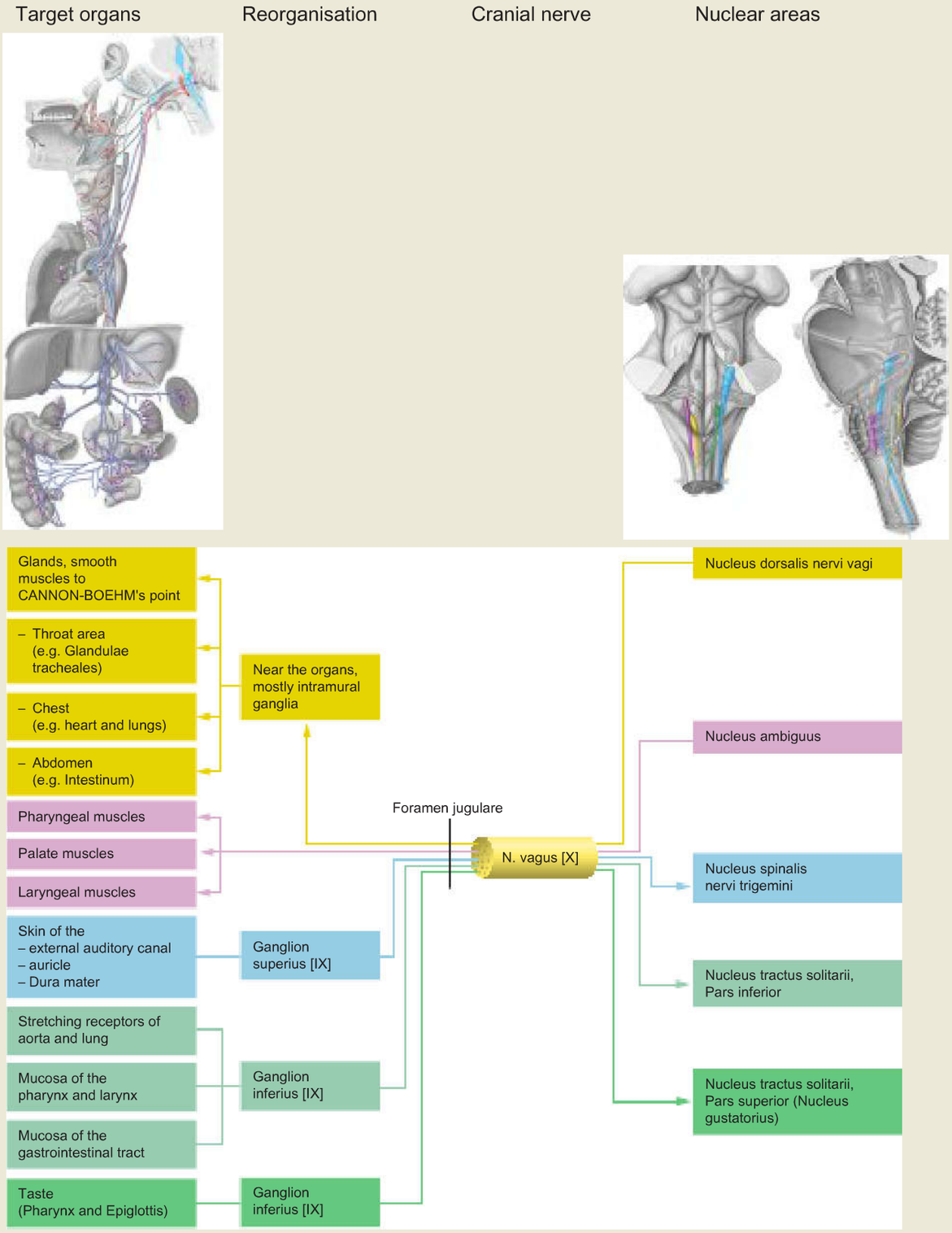

Fig. 12.169 Fibre qualities, cranial nuclei and target organs of the N. vagus [X]; lateral view. [L127]

N. accessorius [XI]

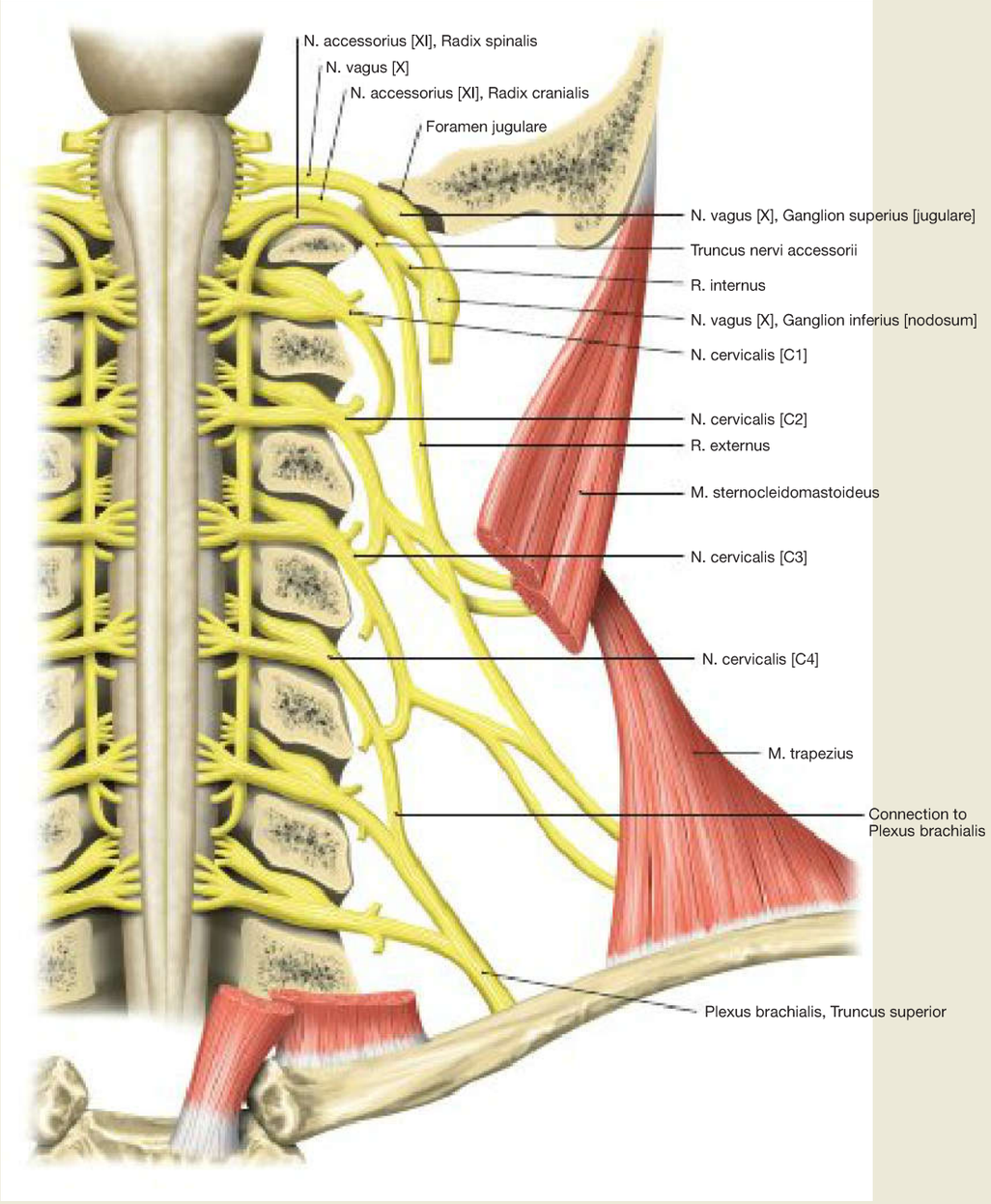

Fig. 12.170 N. accessorius [XI]; anterior view; the vertebral canal and skull are opened. [L127]

The N. accessorius [XI] exits the brain stem in the Sulcus retroolivaris together with the N. glossopharyngeus [IX] and the N. vagus [X], and all three cranial nerves cross the cranial base through the Foramen jugulare. Its fibres originate from two roots. The **Radix cranialis** of the N. accessorius [XI] originates from the Nucleus ambiguus in the Medulla oblongata. At the level of the Foramen jugulare it joins the **Radix spinalis** of the N. accessorius [XI], which consists of fibres originating from the segment between the anterior and posterior roots of the cervical spine. However, it is under discussion whether the N. accessorius [XI] is actually a true cranial nerve, because its spinal nuclear area (Nucleus nervi accessorii) lies in cells of the anterior horn of the cervical spinal cord, while the cranial nuclear area can be assigned to the basal section of the Nucleus ambiguus and thus to the N. vagus [X]. Accordingly, the fibres derived from C1–7 are defined as **Radix spinalis nervi accessorii**, and the fibres originating from the Nucleus ambiguus as **Radix cranialis nervi accessorii.** The current textbook knowledge states that the fibres of the Radix cranialis form the R. internus and converge on the N. vagus [X] inferior to the Foramen jugulare (according to newer findings which require further analysis, the N. accessorius [XI] has no cranial root and no connection to the N. vagus [X]). The Radix cranialis participates in the innervation of the pharyngeal and laryngeal muscles and, strictly speaking, is not a part of the N. accessorius [XI]. The fibres of the Radix spinalis run caudally to the M. sternocleidomastoideus which they innervate, and then pass through the lateral cervical triangle to the anterior margin of the M. trapezius, which they also innervate.

→ T 58k

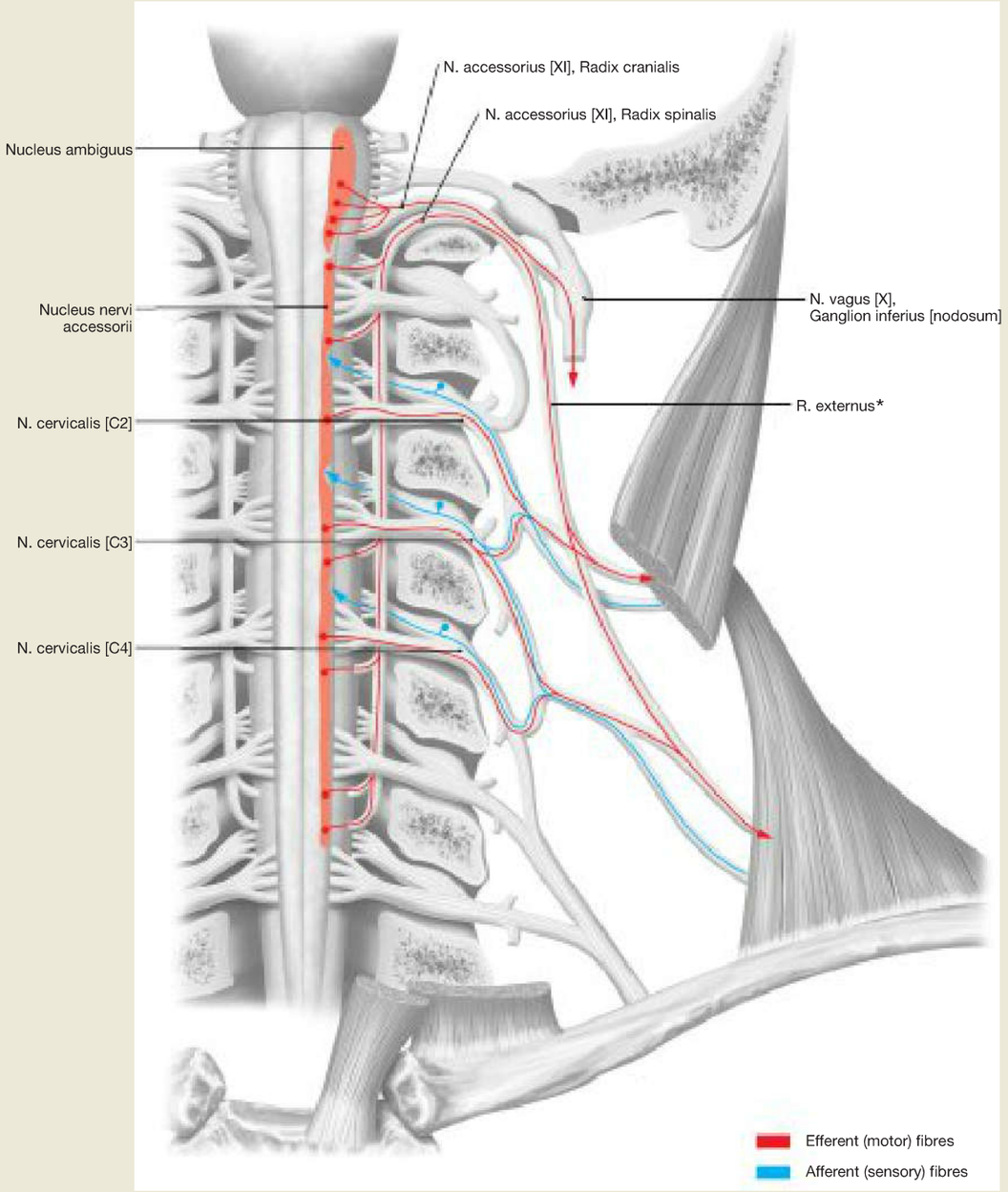

Fig. 12.171 Fibre qualities of the N. accessorius [XI]; anterior view, the vertebral canal and skull are opened. [L127]

The N. accessorius [XI] innervates the M. sternocleidomastoideus and M. trapezius. Its nuclear area is the Nucleus nervi accessorii, from which **special visceral efferent** fibres (SVE) emerge.

* to M. sternocleidomastoideus and M. trapezius

Clinical Remarks

Lesions of the N. accessorius [XI] occur frequently due to its relatively superficial course in the lateral triangle of the neck. Particularly common are iatrogenic lesions (caused by the doctor, e.g. after lymph node extirpation) or traumatic lesions following neck injuries. If the N. accessorius [XI] was damaged superior to the M. sternocleidomastoideus, the patient cannot turn his head to the healthy side (paralysis of the M. sternocleidomastoideus). In addition, he is no longer able to raise the arm above the horizontal plane (insufficient arm elevation due to paralysis of the M. trapezius). But in most cases the lesion site is located below the outlet of the nerve branches to the M. sternocleidomastoideus in the lateral cervical triangle. The consequences are a shoulder depression and difficulties in raising the arm above the horizontal plane.

N. accessorius [XI]

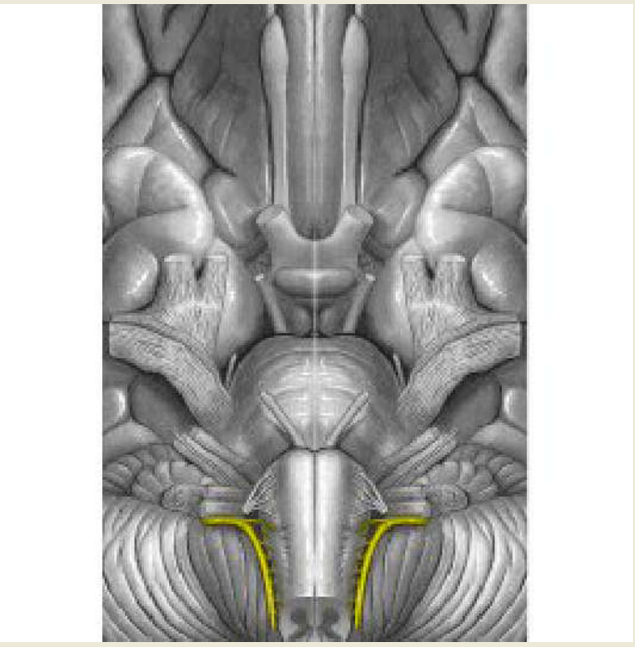

Fig. 12.172 Exit site of the N. accessorius [XI] at the brain stem; inferior view.

The 11th cranial nerve [CN XI] exits the brain stem on the ventral side, dorsally of the olive.

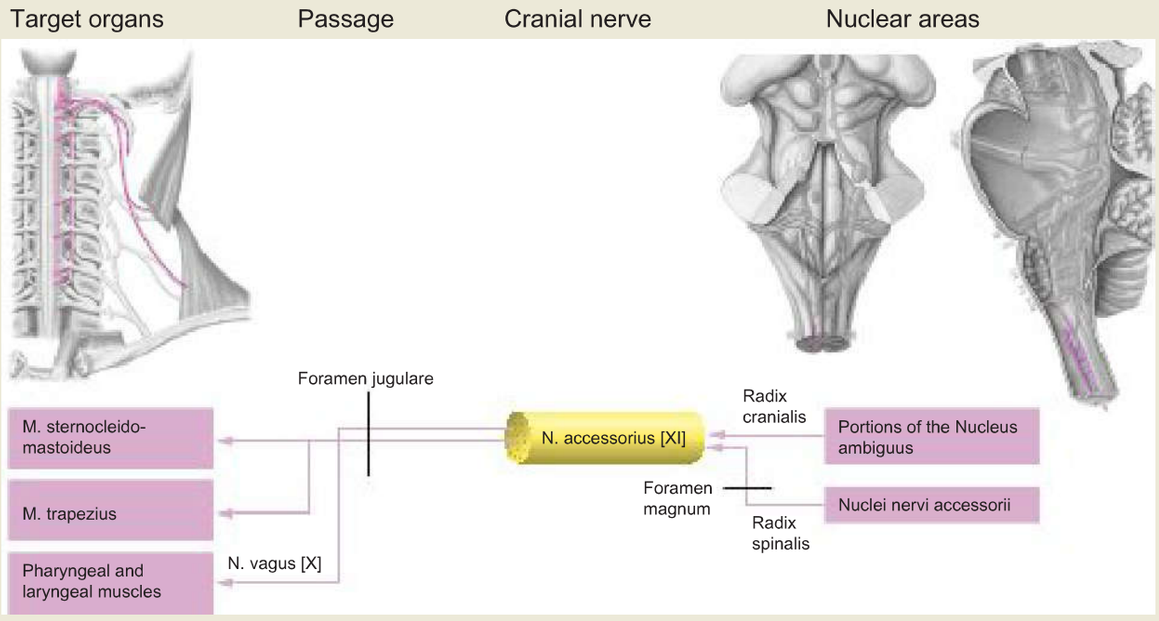

Fig. 12.173 Fibre qualities, cranial nuclei and target organs of the N. accessorius [XI]; anterior view, the vertebral canal and skull are opened. [L127]

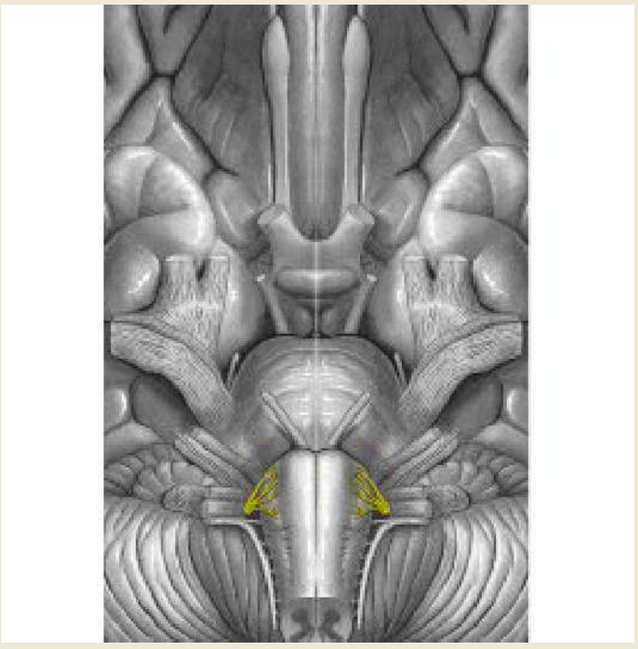

Fig. 12.174 Exit site of the N. hypoglossus [XII] at the brain stem; inferior view.

The 12th cranial nerve [CN XII] exits the brain stem on the ventral side in the Sulcus anterolateralis between the olive and the pyramid (Sulcus preolivaris).

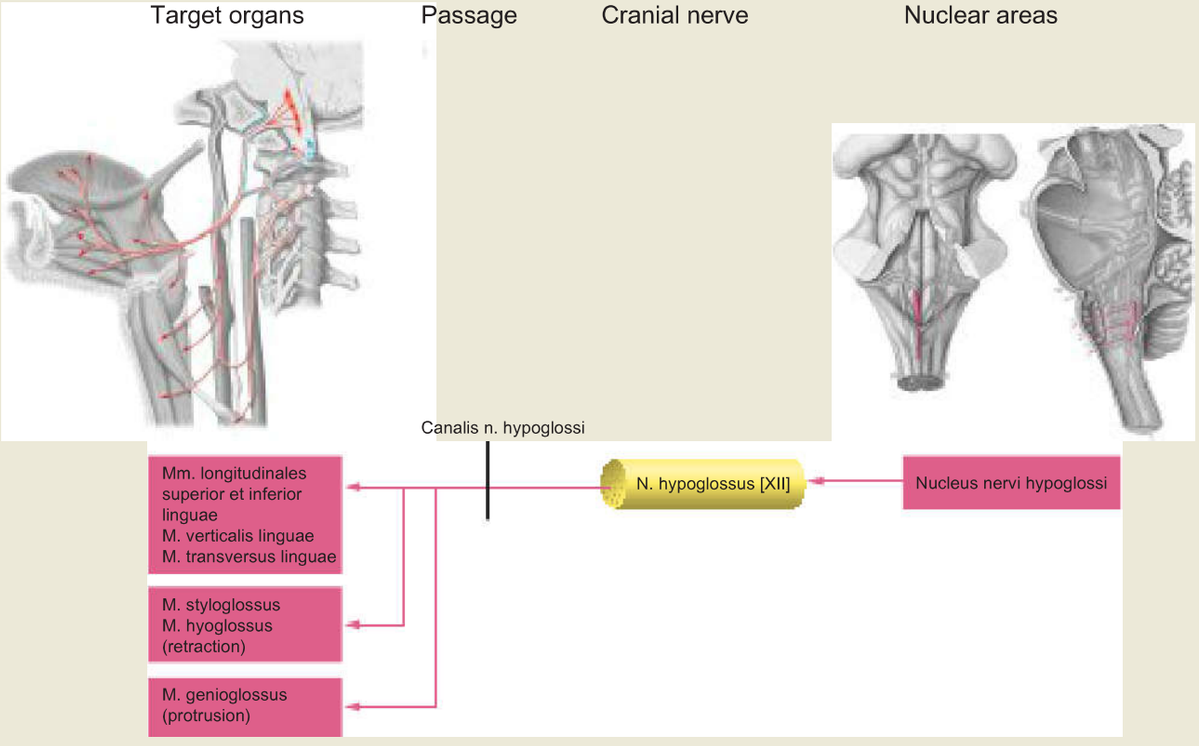

Fig. 12.175 Fibre qualities, cranial nuclei and target organs of the N. hypoglossus [XII]; view from the left side. [L127]

N. hypoglossus [XII]

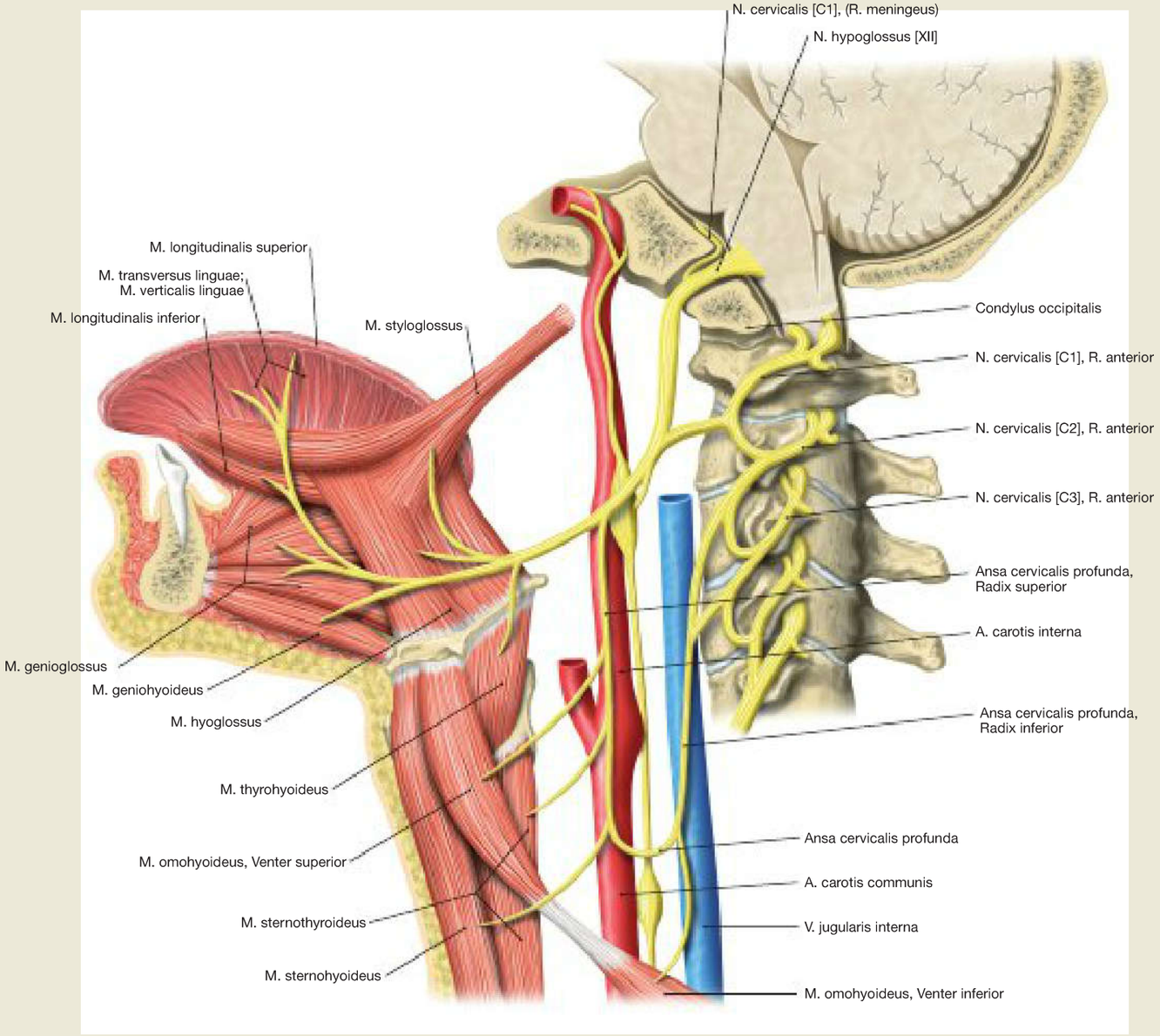

Fig. 12.176 N. hypoglossus [XII]; schematic median section; view from the left side. [L127]
The fibres of the N. hypoglossus [XII] originate from the Nucleus nervi hypoglossi in the Medulla oblongata, and form several small bundles when exiting between the pyramid and the olive in the Sulcus anterolateralis. Then the fibres join the N. hypoglossus [XII], which passes through the **Canalis nervi hypoglossi.** Inferior to the cranial base, fibres of the spinal nerves C1 and C2 join the N. hypoglossus [XII] to accompany it over a short distance, before leaving it again. With other fibres originating from C2 and C3, they form the **Ansa cervicalis profunda** and, in addition, innervate the M. geniohyoideus. Posterior to the N. vagus [X], the N. hypoglossus [XII] passes caudally in the neurovascular bundle behind the pharynx, and then turns rostrally and medially in a right-angled arch of 90°. Passing along the upper margin of the Trigonum caroticum, it crosses the bifurcation of the A. carotis externa at the exit point of the A. lingualis, and enters between the M. hyoglossus and M. mylohyoideus to reach the tongue; it completely innervates the internal muscles of the tongue, as well as the Mm. styloglossus, hyoglossus and genioglossus.

→ T 58I

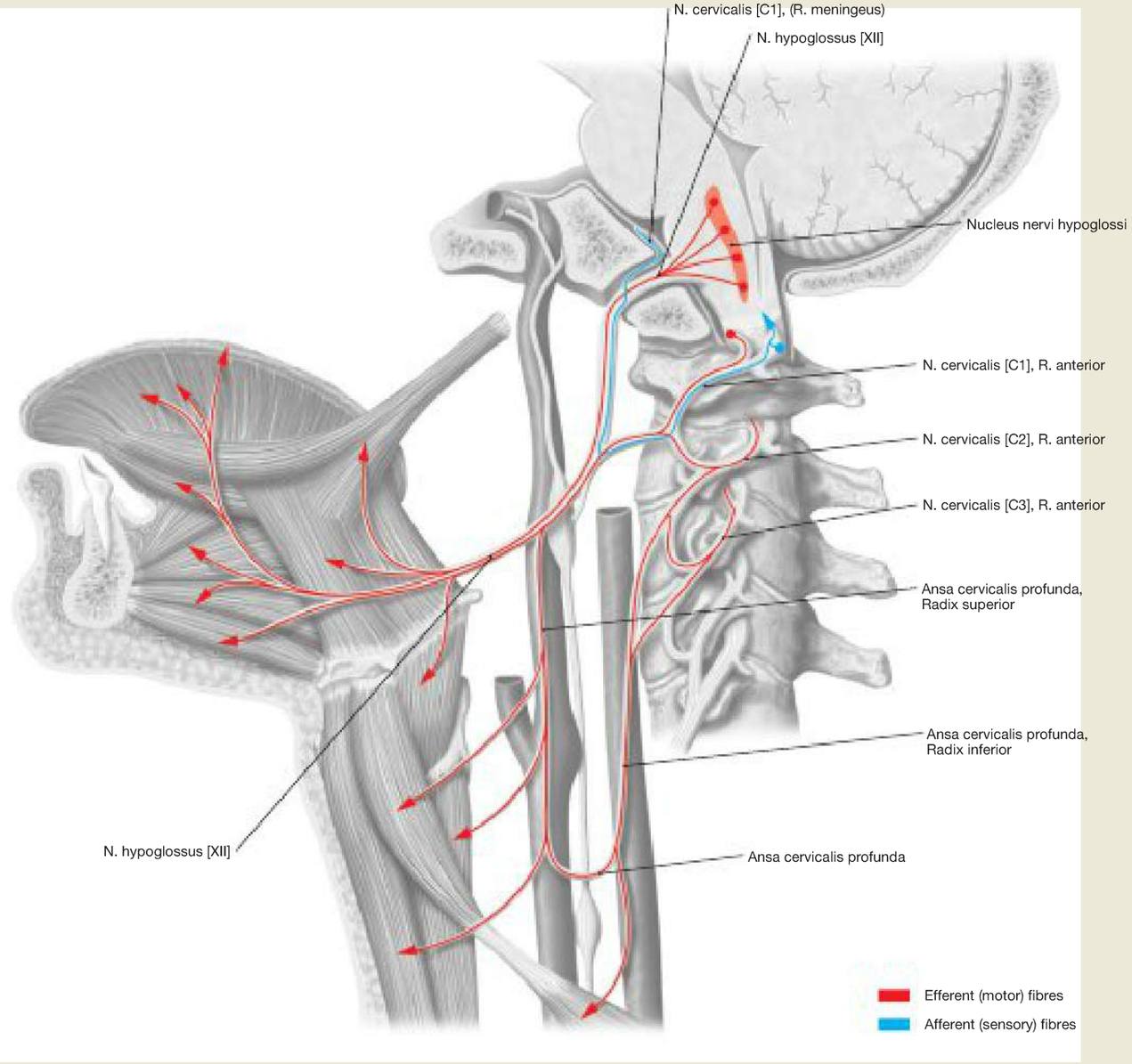

Fig. 12.177 Fibre qualities of the N. hypoglossus [XII]; schematic median section; view from the left side. [L127]
The N. hypoglossus [XII] consists of **general somatic efferent** fibres (GSE) from the Nucleus nervi hypoglossi, which innervate the internal muscles of the tongue, as well as the Mm. styloglossus, hyoglossus and genioglossus.

Clinical Remarks

Unilateral peripheral **lesions of the N. hypoglossus [XII]** or its cranial nucleus, e. g. due to a fracture of the cranial base, cause a deviation of the tongue to the affected side because the lingual muscles that are still intact on the opposite side will push the tongue to the paralysed side. If the paralysis persists over a longer period, the signs of muscle atrophy are visible on the paretic side. In the case of a peristent paralysis of lingual muscles it leads to dysphagia (difficulty in swallowing) and dysarthria (poor articulation). In the case of a supranuclear lesion, the contralateral lingual muscles are paralysed, because the paretic site in the brain is located on the side of the half of the tongue which is still intact. Due to the close paramedian relationship of the hypoglossal nuclei, their bilateral damage in the brain stem occurs frequently.

Spinal Cord Segments

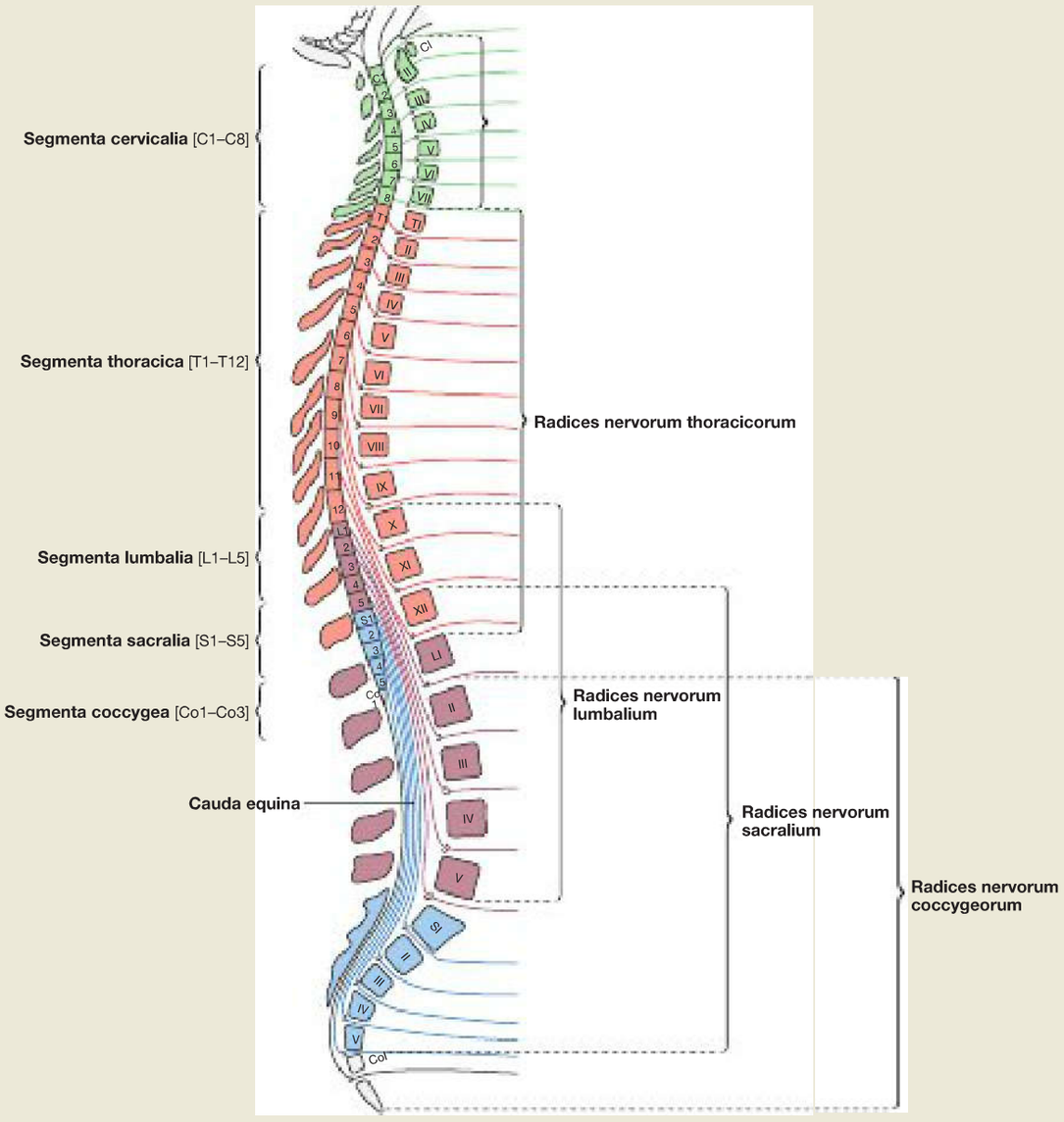

Fig. 12.178 Spinal cord segments, Segmenta medullae spinalis; schematic median section; view from the left side; regional segments highlighted by different colours. [L126]
The spinal cord is composed of eight cervical segments (Segmenta cervicalia [C1–C8]), 12 thoracic segments (Segmenta thoracica [T1–T12]), five lumbar segments (Segmenta lumbalia [L1–L5]), five sacral segments (Segmenta sacralia [S1–S5]) and one to three coccygeal segments (Segmenta coccygea [Co1–Co3]). In the adult, the spinal cord extends only to the level of the lumbar vertebrae LI–LII.
The segmental spinal nerve roots (Radices nervorum) pass through their corresponding Foramina intervertebralia. Due to the faster growth of the vertebral canal, the spinal cord ends much higher above the level of the foramen belonging to the corresponding spinal nerve root, therefore the course of the spinal nerve roots in the vertebral canal gets increasingly longer in the cranial to caudal direction. Below the lumbar vertebrae LI–LII, the spinal nerve roots in the vertebral canal are arranged as the so-called horse tail (Cauda equina).

Clinical Remarks

Any kind of narrowing or constriction of the vertebral canal results in disorders of the corresponding segmental neurons. Tumours or median disc prolapses occurring below the spinal cord segment S3 can result in a **conus medullaris syndrome** (lesion of spinal cord segments S3–Co3) or a **cauda equina syndrome** (lesion of spinal nerve roots in the Cauda equina). The symptoms are sensory deficiencies (saddle anaesthesia), flaccid paralysis, incontinence and impotence.

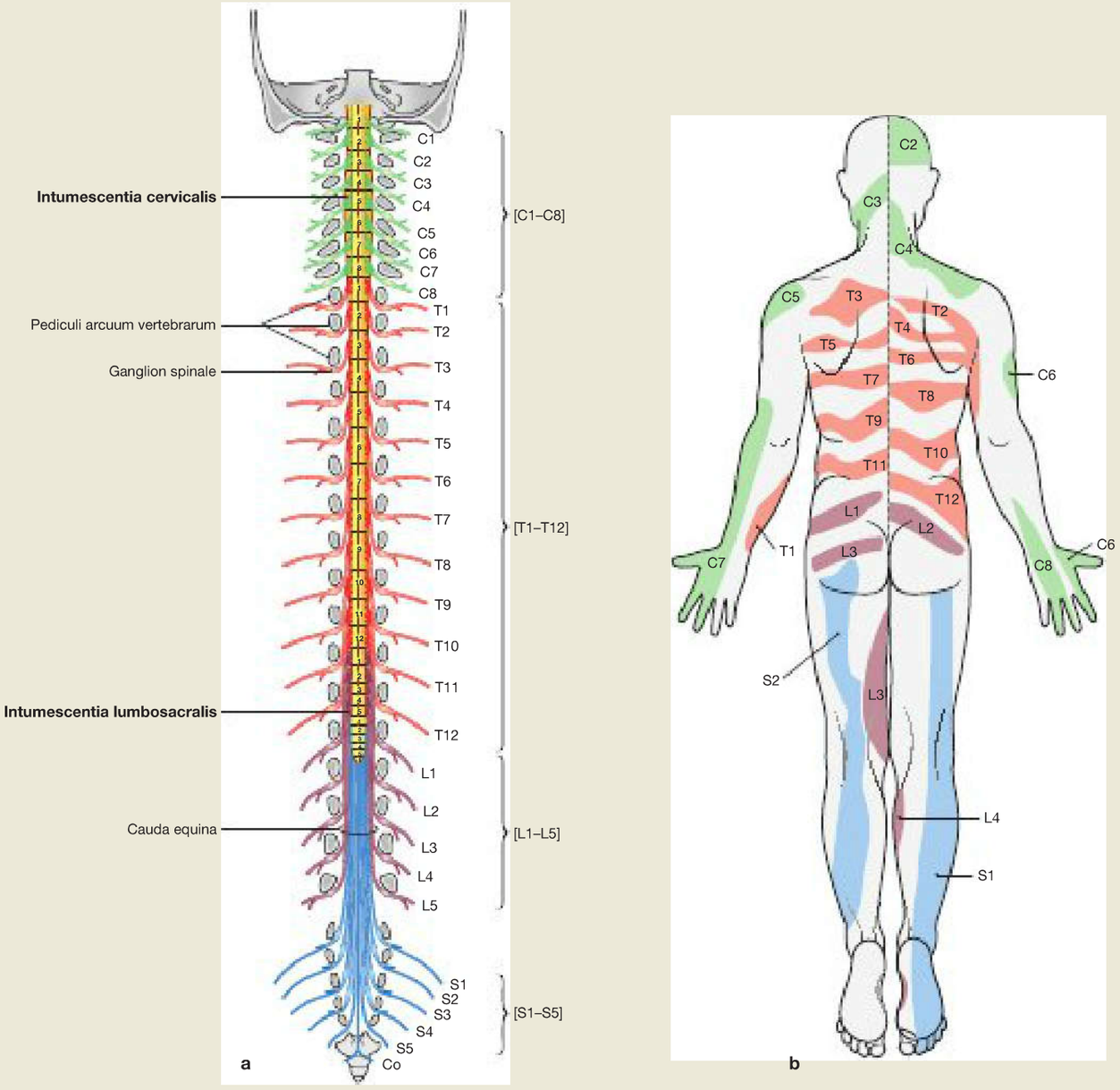

Fig. 12.179a and b Spinal cord segments, Segmenta medullae spinalis, and corresponding dermatomes; a schematic frontal section, ventral view; **b** schematic representation of the dermatomes innervated by the corresponding spinal cord segments. [L126]
Due to its slower growth during the development, the spinal cord is considerably shorter than the vertebral column; therefore the spinal nerve roots get increasingly longer in the cranial to caudal direction and increasingly oblique towards the lateral direction. In adults, the spinal cord ends approximately at the level of LI–LII (ranging from TXII to LII/LIII). Therefore, the Radices anteriores and posteriores lie in higher segments of the vertebral column than the exit site of the corresponding spinal nerve leaving the vertebral canal. Below the Conus medullaris, the Radices anteriores and posteriores of the lumbar, sacral and coccygeal nerves are bundled and pass caudally to reach their exit sites (foramina) out of the vertebral canal. This collection of nerve roots is named the Cauda equina. On the right side **(b),** the skin areas (dermatomes) of the back are shown, which receive their autonomic innervation from the sensory fibres of the spinal nerves of the corresponding spinal cord segments (spinal nerve roots).

Clinical Remarks

Referred pain is defined as a misinterpretation of visceral pain by the brain. In this case the visceral pain is not perceived at the site of its origin, but projected into distant skin areas **(HEAD's zones)**. Referred pain is usually the result of nociceptive input (pain information) originating from a region such as the intestines, which are provided with only a small amount of afferent sensory fibres. These fibres converge at the same spinal cord levels together with afferent fibres of a particular skin area (dermatome), which has a large amount of afferent sensory fibres. Therefore the brain locates the visceral pain in the corresponding region of the skin. A typical example is the referred pain felt in the left arm with angina pectoris or myocardial infarction.

Spinal Cord Segments

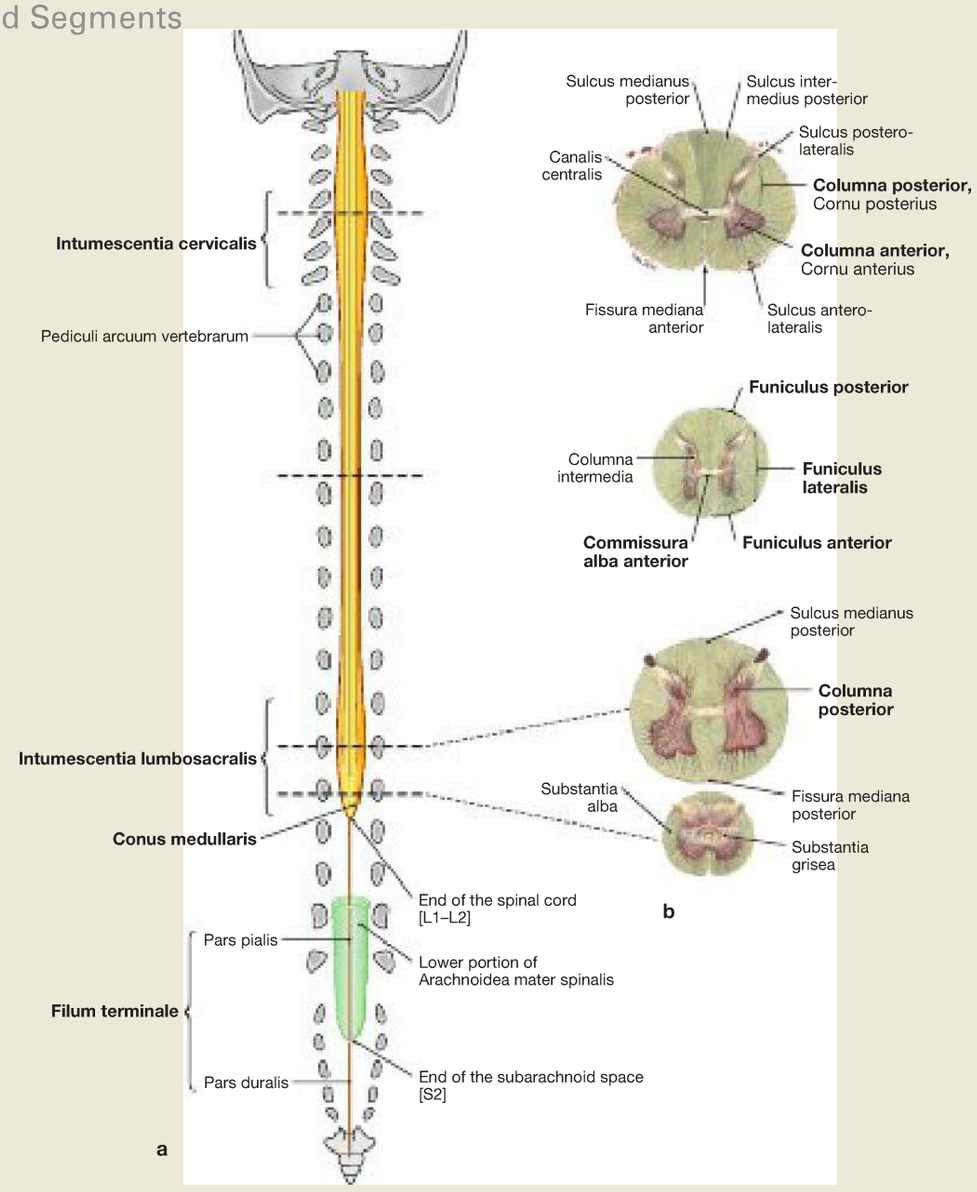

Fig. 12.180a and b Spinal cord, Medulla spinalis, segments and cross-sections; ventral view (→ Fig.12.180a); cross-sections (→ Fig.12.180b) at the level of the dotted lines in the Pars cervicalis, Pars thoracica, Pars lumbalis and Pars sacralis. (a [L126])
The spinal cord is the part of the CNS located in the upper two-thirds of the vertebral canal. In adults, it extends from the Foramen magnum to approximately the level of LI/LII. In newborns, the spinal cord extends to the level of LIII or even LIV. The distal end is cone-shaped (Conus medullaris). Attached to the **Conus medullaris** is a fine network of connective tissue (Filum terminale) which comprises parts of the Pia mater and continues caudally in the vertebral canal. The spinal cord has increased diameters in the region of the spinal nerve roots supplying the limbs. The upper (cervical) enlargement (**Intumescentia cervicalis,** C5–T1) contains neurons for the innervation of the upper limbs; the lower (lumbosacral) enlargement **(Intumescentia lumbosacralis)** lies at the level of the spinal nerve roots L1–S3 and provides the innervation of the lower limbs. The cross-sections of the Medulla spinalis show the typical distribution pattern of the grey and the white matter. In contrast to the brain, the butterfly-shaped Substantia grisea of the spinal cord lies in the centre, and is enveloped by the Substantia alba.

The Clinically Most Often Examined Spinal Cord Segments, Segmenta medullae spinalis, and Their Indicator Muscles

Spinal Cord Segment	Indicator Muscle	Dermatome
C5	M. deltoideus	Lateral upper arm and shoulder region
C6	M. biceps brachii; M. brachioradialis	Thumb; thenar region
C7	M. triceps brachii	Middle finger
C8	Mm. interossei of the hand	Digitus minimus; hypothenar region
L3	M. quadriceps femoris; M. iliopsoas	Knee, medial aspect
L4	M. tibialis anterior	Lower leg, medial aspect
L5	M. extensor hallucis longus	Big toe region
S1	M. triceps surae	Foot and leg region, lateral aspect

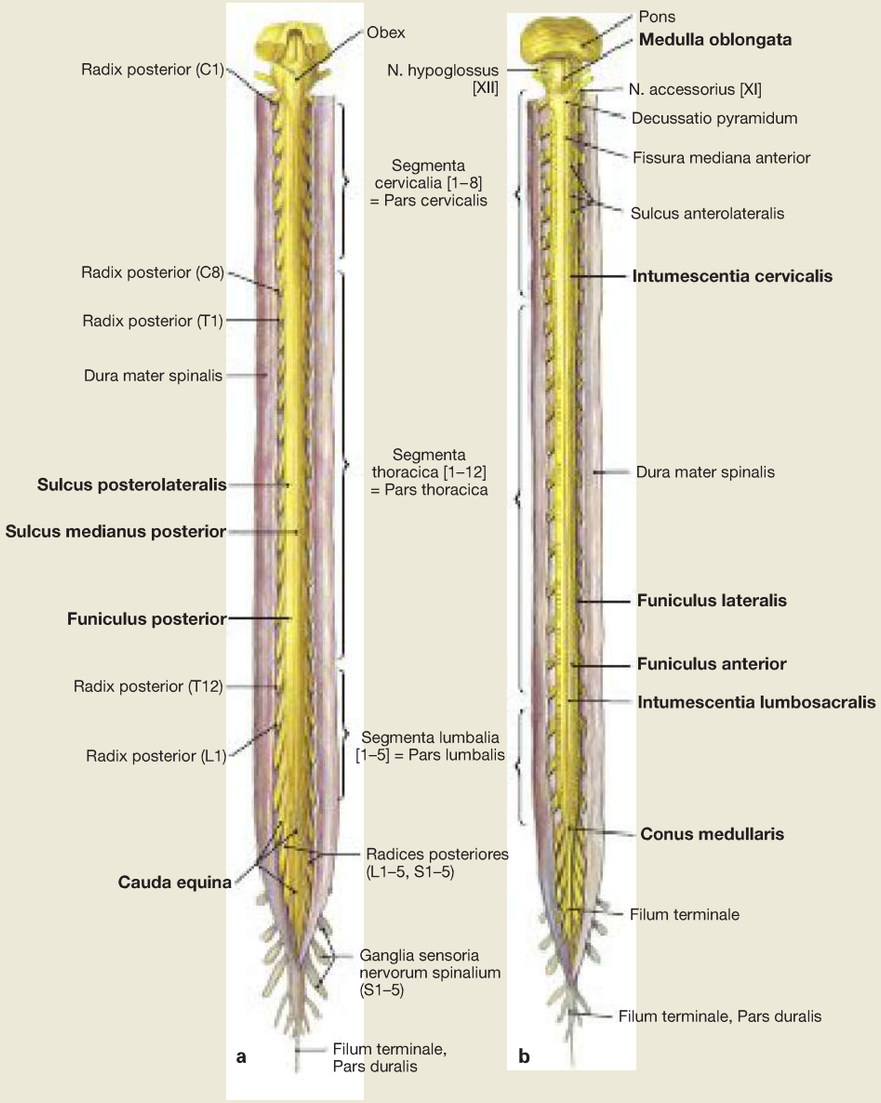

Fig. 12.181a and b Spinal cord, Medulla spinalis, and spinal nerves, Nn. spinales, after opening the vertebral canal and the dural sac; dorsal view (→ Fig.12.181a), ventral view (→ Fig.12.180b). The spinal cord is shaped like a sword and has a diameter of 1–1.5 cm. It connects caudally to the Medulla oblongata of the brain stem. In the cervical and lumbar regions it is enlarged to form the Intumescentia cervicalis (C5–T1) and the Intumescentia lumbosacralis (L2–S3). Multiple neurons and nerve fibres are located here which mainly supply the innervation of the limbs. The Conus medullaris forms the caudal tip of the spinal cord.

The surface of the spinal cord is characterised by **longitudinal grooves**. These are the Fissura mediana anterior in the midline of the ventral side and the Sulcus medianus posterior on the dorsal side. On both sides, the Funiculus anterior runs laterally of the Fissura mediana anterior. Then the Sulcus ventrolateralis follows, separating the Funiculus anterior from the Funiculus lateralis. The Funiculi posteriores lie dorsally on the right and left sides of the Sulcus medianus posterior, and are separated from the Funiculi laterales by the Sulci posterolaterales.

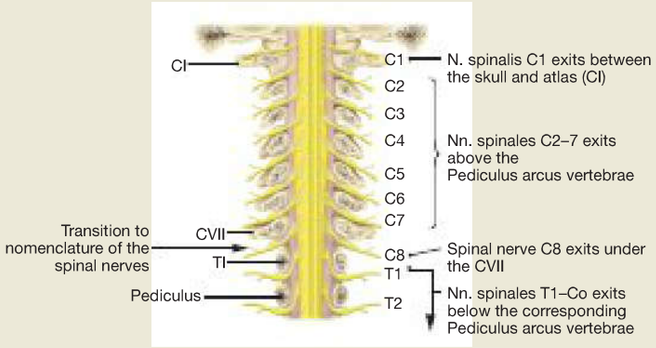

Fig. 12.182 Nomenclature of the spinal nerves. [L284]
In contrast to the other spinal cord segments, the number of spinal cord segments in the cervical spine is not identical with the number of the vertebrae. In the **cervical spine** there are eight cervical cord segments as opposed to only seven cervical vertebrae. The first pair of cervical nerves exits between the skull and the atlas (CI). The subsequent pairs of spinal nerves C2–C7 exit **above** the respective corresponding Pediculus arcus vertebrae. At the transition from the seventh cervical vertebra to the first thoracic vertebra, the nomenclature changes since the eighth spinal nerve exits below the seventh cervical vertebra. The next pairs of spinal nerves T1–Co that follow will then always exit **inferior** to the corresponding vertebral arch.

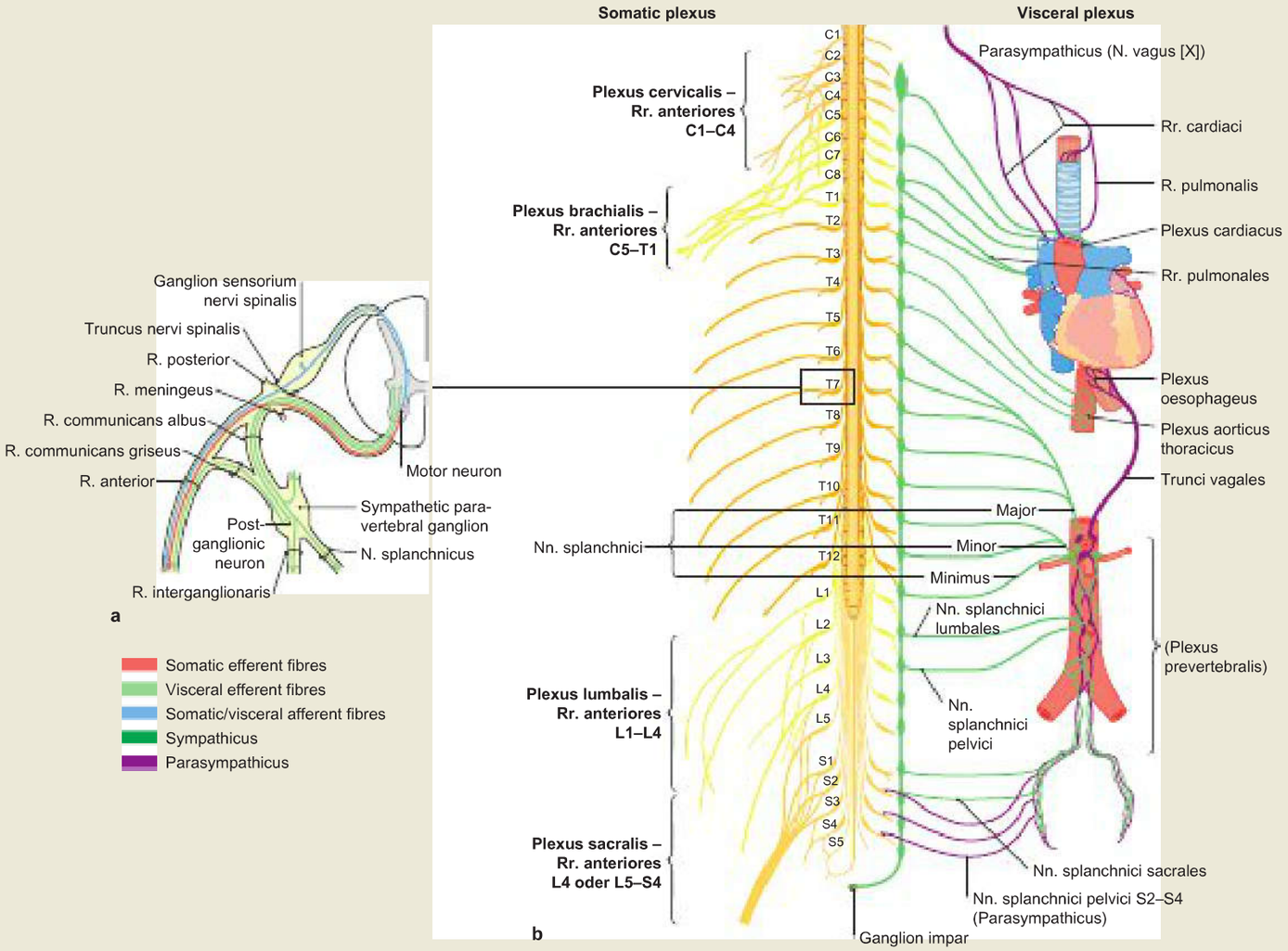

Fig. 12.183a and b Spinal nerve and nerve plexuses.
a Structure and bifurcation of a thoracic spinal nerve.
b Somatic (left part of the illustration) and autonomic (right part) nerve plexuses. [L126]

Spinal nerves consist of the Fila radicularia of the anterior and posterior nerve roots, which leave the spinal cord as **Radix anterior** (Radix motoria, axons of the motor neurons) at the Sulcus anterolateralis, or enter it dorsally as **Radix posterior** (Radix sensoria, axons of the pseudo-unipolar nerve cells of the spinal ganglion, Ganglion sensorium nervi spinalis, located in the area of the Foramen intervertebrale). The fibres of the Radices anterior and posterior unite to form the trunk of the spinal nerve, which therefore contains mixed fibre qualities (somatomotor, somatosensory, autonomic). The trunk of the spinal nerve divides immediately into its terminal branches: **R. meningeus, R. posterior, R. anterior,** and in the thoracolumbar region into the **R. communicans albus** connected to the sympathetic trunk, and the **R. communicans griseus** for the transmission of sympathetic impulses.

Nerve plexuses (b) can be somatic (shown on the left side) or visceral (right side) and consist of fibres of different qualities and levels. Nerves originating from the plexuses supply various target tissues and organs. Enteric nerve plexuses can generate reflex activities independent of the CNS.

The large **somatic plexuses** emerge from the Rr. anteriores of the spinal nerves: Plexus cervicalis (C1–C4), Plexus brachialis (C5–T1), Plexus lumbalis (L1–L4), Plexus sacralis (L4–S4) and Plexus coccygeus (S5–Co). With the exception of the spinal nerve T1, all thoracic spinal nerves have Rr. anteriores, which are independent branches and do not participate in the formation of a plexus.

The **visceral nerve plexuses** develop together with the viscera, and normally contain efferent (sympathetic and parasympathetic) and afferent parts. The visceral plexuses include the Plexus cardiacus and Plexus pulmonalis in the thorax, as well as the Plexus prevertebralis anterior the aorta in the abdomen, which extends caudally to the lateral pelvic walls. The Plexus prevertebralis projects efferent fibres to all abdominal and pelvic organs, and receives afferences from the same organs.

Clinical Remarks

Irritation or lesions of individual nerve roots are collectively defined as **radiculopathy**. The most common cause is a mediolateral disc prolapse (→ Fig. 12.193). Very often, the segments C4–C7 of the cervical spine and L4/L5 and L5/S1 of the lumbosacral transition are affected. Patients complain typically of sensory dysfunctions, muscle weakness or even paralysis. The isomuscular reflexes are weakened.

Clinically a very precise distinction has to be made between radicular and peripheral lesions. Radicular disorders manifest with signs according to the segmental organisation of the spinal cord. Distal lesions in relation to the plexuses manifest according to the innervation pattern of the affected peripheral nerves.

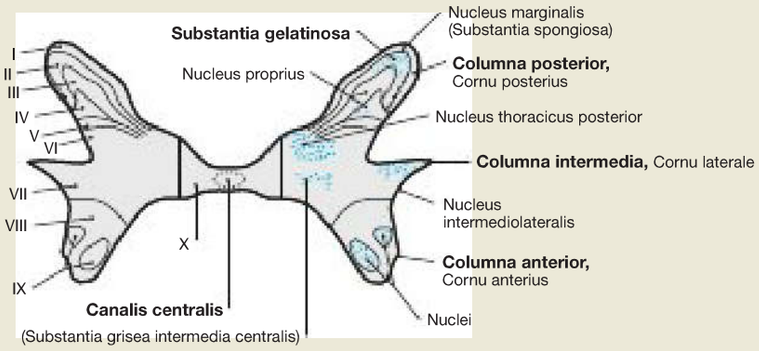

Fig. 12.184 Spinal cord, Medulla spinalis; laminar organisation of the grey matter with respect to its cytoarchitecture (according to REXED, 1952) exemplified on a thoracic segment (T10).
On the histological level (cytoarchitecture), the grey matter (Substantia grisea) is divided into a number of **layers** (Laminae) which are numbered I to X in the dorsal to ventral order (formation and number of the layers vary in different segments of the spinal cord). In addition, various **nuclei** of nerves are defined. However, these nuclei may extend onto several cytoarchitectural neuronal layers. The division into nuclei or nuclear areas is based on functional aspects.

The **posterior horns** (Laminae I–VI: Nucleus thoracicus posterior [STILLING-CLARKE's column], Nucleus proprius, Substantia gelatinosa) contain relais neurons for the transmission of afferent sensory input (stimuli of cutaneous receptors, deep sensibility, pain perception from the periphery), which are relayed and transmitted from here. The **lateral horns** (Lamina VII) harbour neurons (Nucleus intermediolateralis) for autonomic efferences. The **anterior horns** (Columna anterior, Cornu anterius; Laminae VIII, IX) contain efferent neurons (somatic efferent root cells) for the muscles.

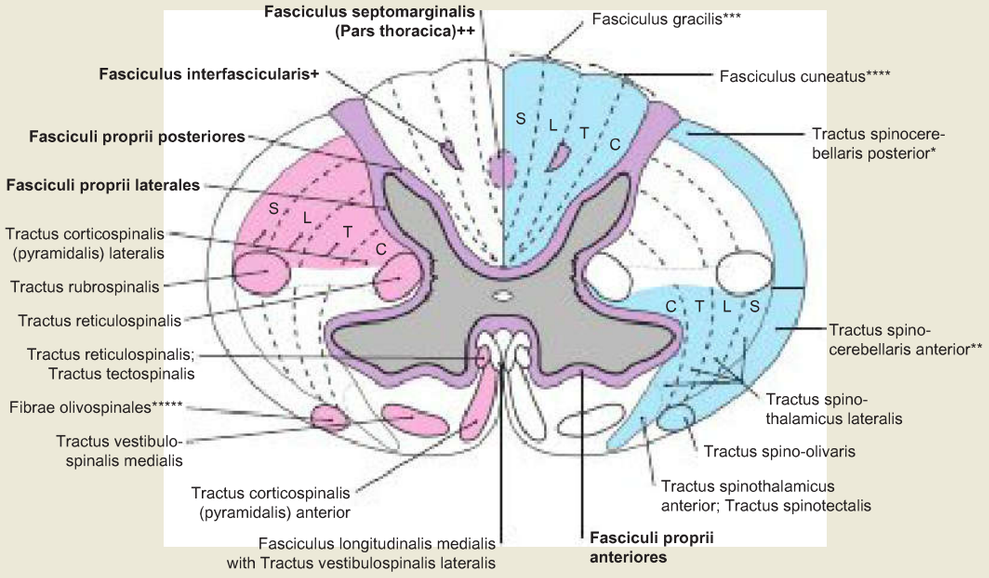

Fig. 12.185 Spinal cord, Medulla spinalis; schematic organisation of the white matter exemplified by a lower cervical segment.
Afferent (= ascending) tracts are highlighted in blue, and efferent (= descending) tracts in red. [L238]
The regions indicated with + and ++ are passed by descending collateral tracts of the posterior funiculi.

*	clinical term: FLECHSIG's tract
**	clinical term: GOWERS' tract
***	clinical term: GOLL's tract
****	clinical term: BURDACH's tract
*****	The existence of these fibres has not yet been evidenced conclusively.
+	SCHULTZE's comma tract (Pars cervicalis)
++	oval bundle of FLECHSIG (Pars thoracica)

Clinical Remarks

Due to a consistent immunisation/vaccination program (initially with the vaccine of living micro-organisms and since 1998 with dead vaccine), the infectious disease of **poliomyelitis** (infantile paralysis) is now considered as largely eradicated in the Western industrialised nations. Infection with the polio virus leads to an isolated destruction of α-motor neurons (second neuron of the motor tract system). This results in flaccid muscle paralysis and loss of isomuscular reflexes with preserved sensitivity. The first motor neuron in the Gyrus precentralis is intact, but the motor neurons of the spinal cord and the motor nuclei of the cranial nerves are damaged by the endemic polio virus. In 95 % of all cases the infection is asymptomatic, in 5 % it results in poliomyelitis.

Tracts of the Spinal Cord

Efferent and Afferent Tracts of the Neuronal Pathways in the Substantia alba of the Spinal Cord		
Type	**Tracts/Systems**	**Tractus/Fasciculi**
Descending (Efferent) Tract Systems		
Autonomic fibres		
Motor nerve fibres	Pyramidal tracts	• Tractus corticospinalis lateralis • Tractus corticospinalis anterior
	Extrapyramidal tracts	• Lateral tract: Tractus rubrospinalis • Medial tracts: – Tractus tectospinalis – Tractus reticulospinalis – Tractus vestibulospinales medialis et lateralis
Ascending (Afferent) Tract Systems		
Proprioceptive fibres	Posterior funiculus system	• Fasciculus gracilis • Fasciculus cuneatus
Pain-conducting fibres	Spinothalamic system	• Tractus spinothalamicus lateralis • Tractus spinothalamicus anterior • Tractus spinoreticularis • Tractus spinotectalis
	Spinocerebellar system	• Tractus spinocerebellaris posterior • Tractus spinocerebellaris anterior • Tractus spinocerebellaris superior • Tractus spinoolivaris

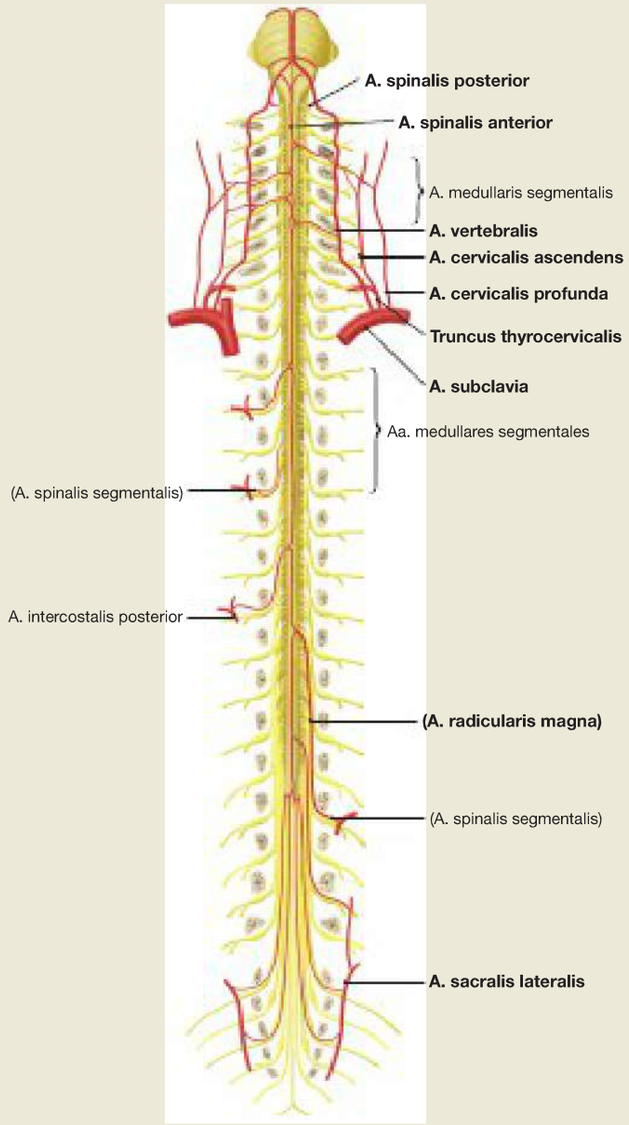

Fig. 12.186 Arteries of the spinal cord, Medulla spinalis; ventral view; not all segmental spinal arteries are shown. [L284]

The arterial blood supply of the spinal cord is fed by three sources:

- **A. subclavia** (cervical segment) via the A. spinalis anterior and Rr. radiculares anteriores and posteriores from the Aa. vertebralis, cervicalis ascendens and cervicalis profunda
- **Aorta thoracica** (thoracic segment) via the A. intercostalis suprema and Aa. intercostales posteriores
- **Aorta abdominalis** (lumbosacral segment) via the Aa. lumbales

The A. iliaca interna supplies the Cauda equina via the A. iliolumbalis and A. sacralis lateralis. All of these arteries provide Rr. spinales. The largest R. spinalis is the **A. radicularis magna** (ADAMKIEWICZ), which emerges between T8 and L3: in 50% of all cases at the level of T9/T10, in 75% of all cases on the left side. Additional radiculomedullary arteries exist in 43% of all cases.

Clinical Remarks

Occlusions of the A. spinalis anterior (supply area → Fig.12.188) can be caused by thrombosis, tumours, etc., and can lead to an **anterior spinal artery syndrome** in the supply area. As this leads to a lesion of the anterior horns at the level of the occlusion, the result is a flaccid paralysis of the muscles and muscular parts innervated by the affected segment of the spinal cord. Simultaneously, the tracts in the Funiculus anterolateralis become dysfunctional. In regions of the body which are innervated by spinal cord segments below the arterial occlusion, spastic paraparesis, loss of pain and temperature perception (but preservation of touch) will occur, as well as micturition and defecation disorders and sexual dysfunctions.

Any blockage of the blood supply via the largest anterior radicular branches (A. radicularis magna, artery of ADAMKIEWICZ) leads to a **greater radicular artery syndrome.** Depending on the level of the blockage, this results in symptoms of paraplegia in the lower thoracic or upper lumbar regions with complete loss of function of the caudally located spinal cord.

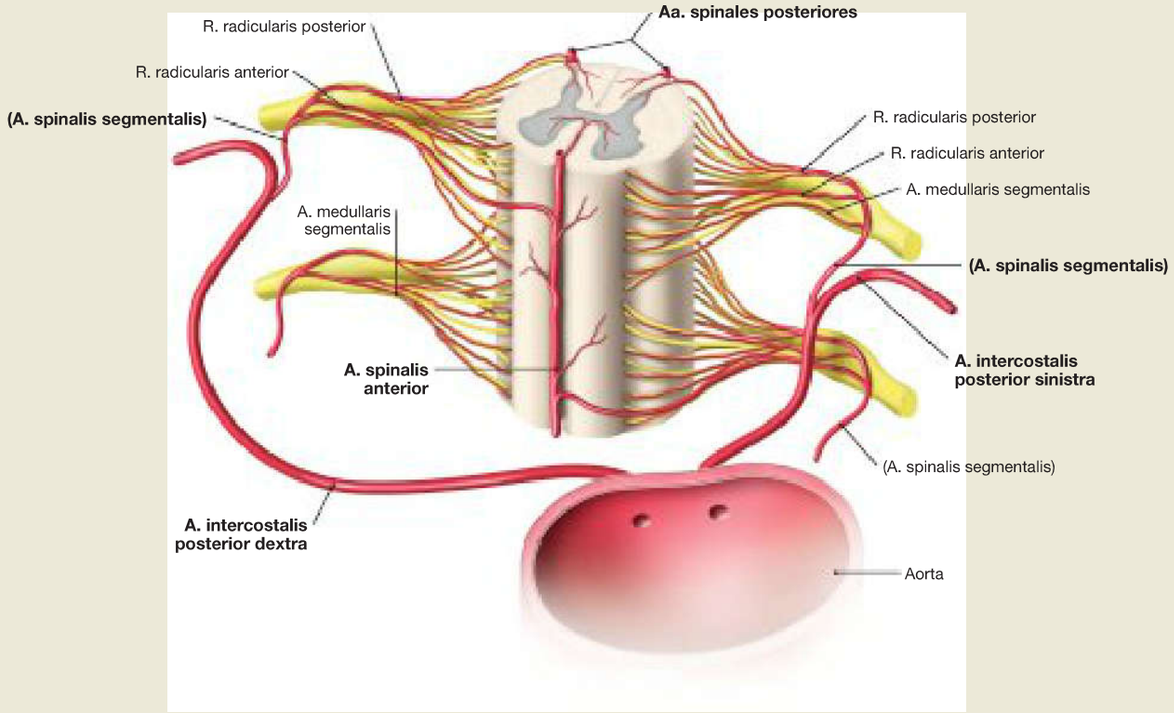

Fig. 12.187 Segmental arterial blood supply of the spinal cord; oblique ventral view [L275]
The blood supply of the spinal cord is provided by the **A. spinalis anterior** and the **Aa. spinales posteriores,** which originate in the cervical region and are arranged longitudinally along the spinal cord. Additional contributors are feeder arteries (spinal segmental arteries from the Aa. vertebrales, the deep cervical arteries, the Aa. intercostales and Aa. lumbales), which enter the vertebral canal via the Foramina intervertebralia and divide into **Rr. radiculares anteriores and posteriores** at the level of each spinal cord plane. The Rr. radiculares anteriores and posteriores follow the spinal nerves and supply them with blood. On different planes, segmental **Aa. medullares** branch off the spinal segmental arteries, which project to and anastomose with the longitudinal arteries.

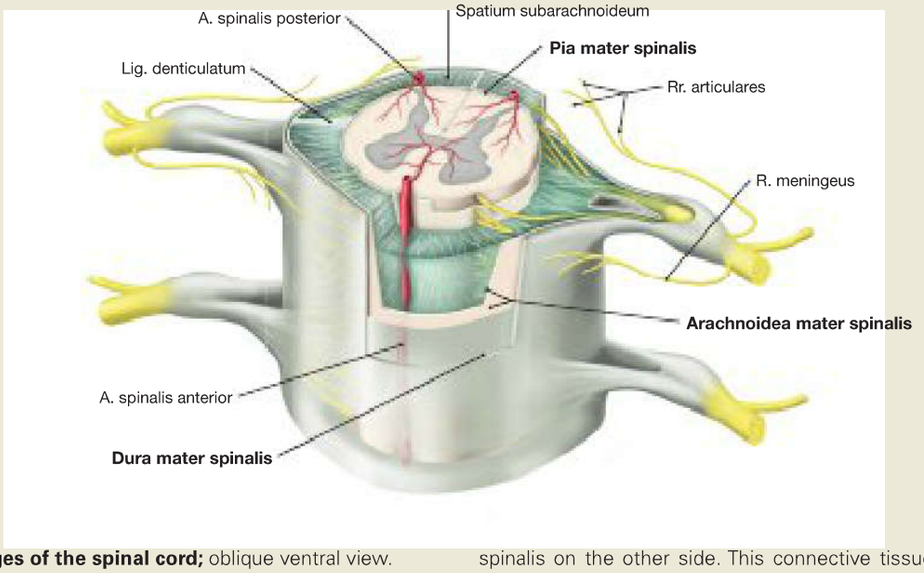

Fig. 12.188 Meninges of the spinal cord; oblique ventral view. [L275]
Like the brain, the spinal cord is also surrounded by the three meninges, which provide its protection and suspension within the vertebral canal.
The **Dura mater spinalis** is the strongest and most external membrane. The laterally exiting spinal nerves and their roots are surrounded by tubular dural sheaths which radiate into and fuse with the neural sheath (epineurium) of the spinal nerves. The spinal arachnoid follows on the inside of the dura. It is separated from the Pia mater spinalis by the subarachnoid space which is filled with cerebrospinal fluid (CSF, Liquor cerebrospinalis). Delicate trabeculations (Trabeculae arachnoideae, not shown) connect the arachnoid mater of one side with the Pia mater spinalis on the other side. This connective tissue also surrounds the blood vessels located within the subarachnoid space.
The **Pia mater spinalis** is a highly vascularised membrane and tightly attached to the surface of the spinal cord, which it surrounds. It extends deeply into the Fissura mediana anterior, envelops the Radices posteriores and anteriores of the spinal nerves like a sheath, and accompanies them on their way through the subarachnoid space. At the exit or entry sites of the Radices, the Pia mater spinalis transitions into the **Arachnoidea mater spinalis**. Extensions of the Pia mater spinalis continue laterally on both sides of the spinal cord as Ligg. denticulata to the spinal arachnoid and Dura mater. They serve to attach the spinal cord in the centre of the subarachnoid space.

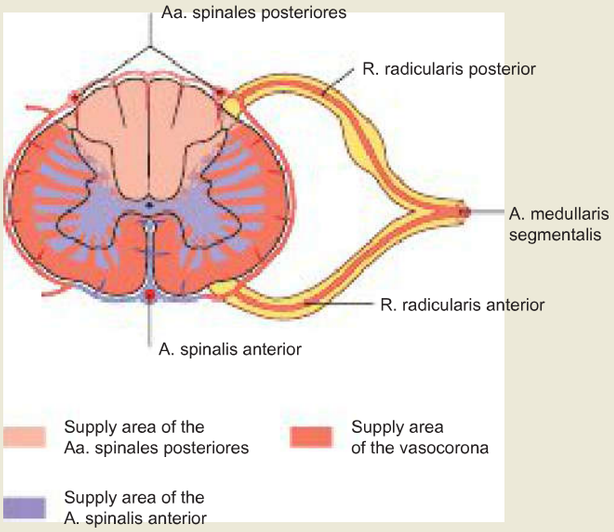

Fig. 12.189 Innervation areas of the spinal cord; cross-section. [L126]
The blood supply of the spinal cord is divided into the areas of the A. spinalis anterior, the Aa. spinales posteriores and the vasocorona.

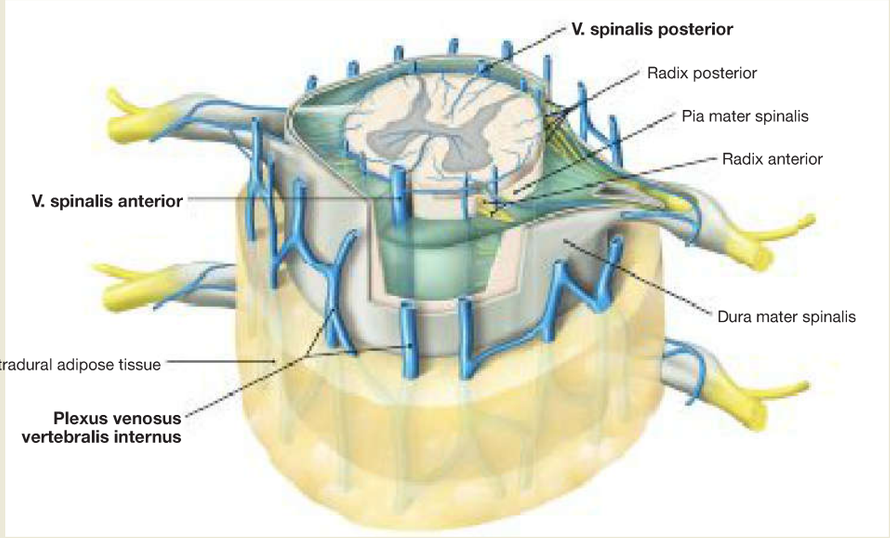

Fig. 12.190 Veins of the vertebral canal, Canalis vertebralis; oblique ventral view. [L275]
The veins draining the spinal cord form for the most part longitudinally arranged vascular trunks. On both sides, two pairs of longitudinal veins are located around the exit or entry sites of the Radix anterior and Radix posterior out of or into the spinal cord, respectively. In addition, the **V. spinalis anterior** runs along the Fissura mediana anterior, and the **V. spinalis posterior** along the Sulcus medianus posterior. These veins drain blood into the **Plexus venosus vertebralis internus** in the epidural space of the vertebral canal. This venous plexus communicates via segmentally arranged veins with the large venous trunks of the body, such as the azygos system, and also with the intracranial veins.

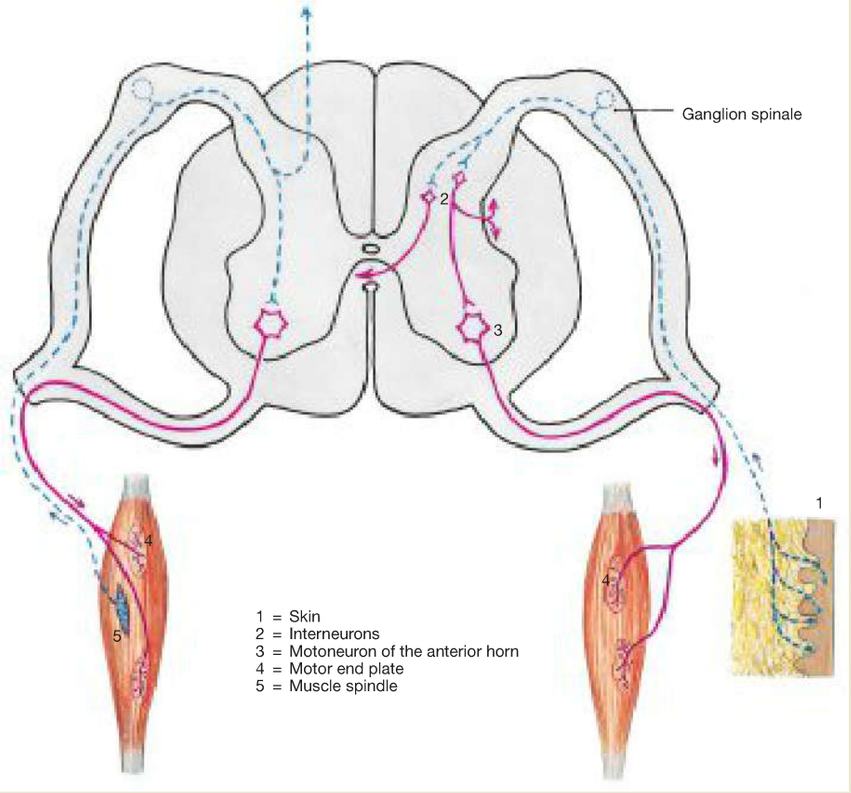

Fig. 12.191 Reflexes of the spinal cord, Medulla spinalis.
The spinal cord is linked to supraspinal centres via a **system or apparatus of connections**, and has an **independent system or apparatus of spinal reflex loops,** which bypass the brain. Spinal reflexes are needed, for example, to maintain a constant muscle tonus during different activities or to protect against harmful stimuli (e.g. the withdrawal reflex when an extremity is exposed to extreme heat).
Due to the connectivity and complexity, two different **types of reflex-circuitry** are distinguished: monosynaptic (proprioceptive) and polysynaptic reflexes. In particular, the polysynaptic reflexes can be modified by supraspinal centres.
Left side of the illustration: 'local' reflex circuitry (monosynaptic, bineuronal, proprioceptive reflex; a typical stretch reflex, e.g. patellar or knee jerk, ACHILLES tendon or ankle jerk reflexes, etc.).
Right side of the illustration: complex reflex circuitry (polysynaptic, polyneuronal reflex; typical flexor or withdrawal reflexes are initiated by cutaneous receptors, e.g. abdominal, cremaster, plantar reflexes, etc.).

Somatic Monosynaptic and Polysynaptic Reflexes with Corresponding Spinal Cord Segments (for Clinical Neurological Diagnostic Tests)

Reflex	Triggering Stimulation	Reflex Response	Spinal Cord Segments
Monosynaptic reflexes			
Biceps tendon reflex	Tapping the biceps tendon	Contraction of the M. biceps brachii (flexion in the elbow joint, supination)	C6 (C5–C6)
Triceps tendon reflex	Tapping the triceps tendon	Contraction of the M. triceps brachii (extension in the elbow joint)	C7 (C6–C8)
Patellar tendon/knee jerk reflex	Tapping the Lig. patellae	Contraction of the M. quadriceps femoris (extension in the knee joint)	L3 (L2–L4)
ACHILLES tendon/ankle jerk reflex	Tapping the ACHILLES tendon	Contraction of the M. triceps surae (plantar flexion of the foot)	S1 (L5–S2)
Polysynaptic reflexes			
Cremaster reflex	Stroking the skin of the medial thigh	Contraction of the M. cremaster (pulls the testicle towards the body)	L1–L2
Abdominal (wall/skin) reflex	Stroking the skin of the lateral abdominal wall	Contraction of ipsilateral abdominal muscles (e. g. M. obliquus externus abdominis)	T6–T12
Anal reflex	Stroking the anal skin	Contraction of the M. sphincter ani externus	S3–S5

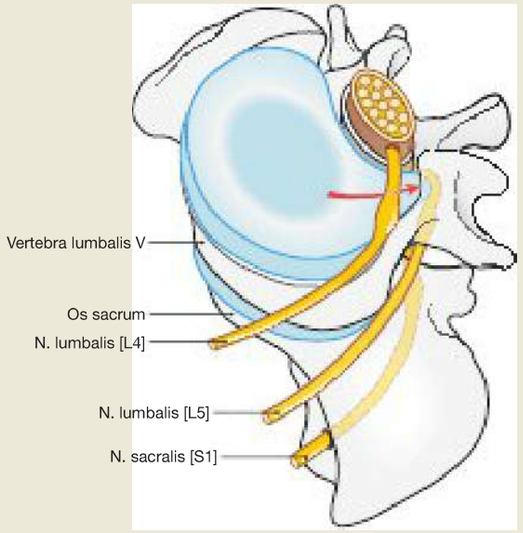

Fig. 12.192 Schematic drawing of a mediolateral herniation of the intervertebral disc between the fourth and fifth lumbar vertebrae; lateroventral superior view. [L126]
This disc prolapse ('slipped disc') results in compression of the spinal nerve root L5 exiting in the segment below; the more medially located spinal nerve root L4 exiting in the same segment, however, remains unaffected.

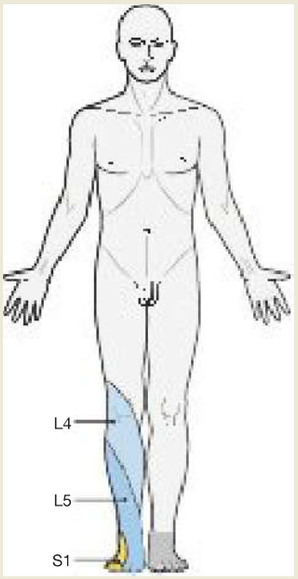

Fig. 12.193 Dysfunctional cutaneous innervation due to lesions (palsy) of some frequently affected spinal nerves. [L126]
Most often the spinal nerves L4, L5, and S1 are affected by disc prolapses.

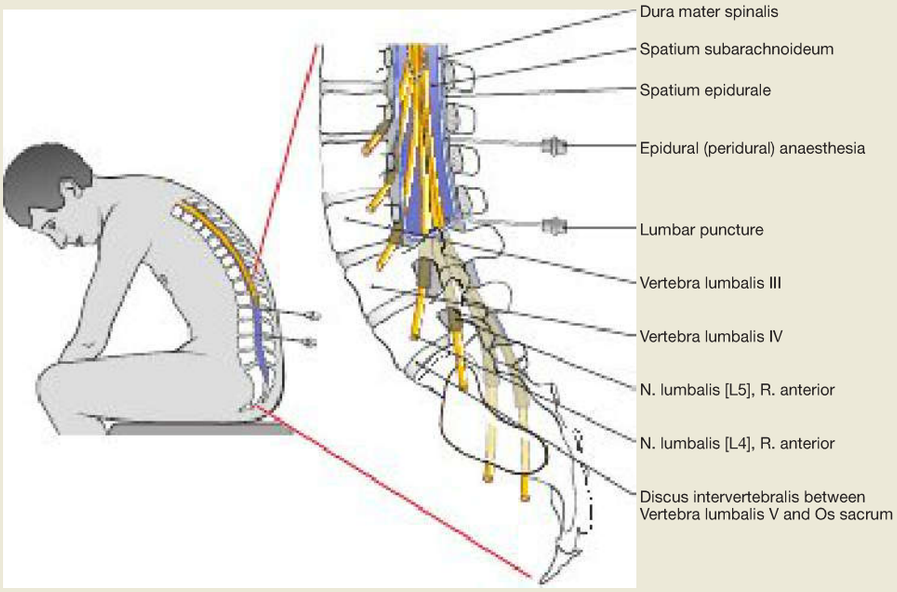

Fig. 12.194 Epidural (peridural) anaesthesia and spinal anaesthesia. [L126]
Anaesthetics are injected into the epidural space (epidural or peridural anaesthesia) to selectively anaesthetise individual spinal nerves. The local adipose tissue restricts the diffusion of the anaesthetic into other spinal cord segments.
In contrast to epidural anaesthesia, in **spinal anaesthesia** the anaesthetics are applied into the subarachnoid space. The drug mixes with the cerebrospinal fluid (CSF), but follows the g-force, and thus sinks beneath the injection site (in an upright sitting patient), so that only the nerve branches passing below the injection site will be anaesthetised.
For a **lumbar puncture** (in this case the back should be maximally flexed) the needle is usually inserted between the spinous processes of the lumbar vertebrae III and IV or IV and V. Then the needle is advanced carefully until it has penetrated the Dura mater spinalis, and the tip of the needle lies within the subarachnoid space. Now CSF can be taken for diagnostic purposes or an anaesthetic can be applied.

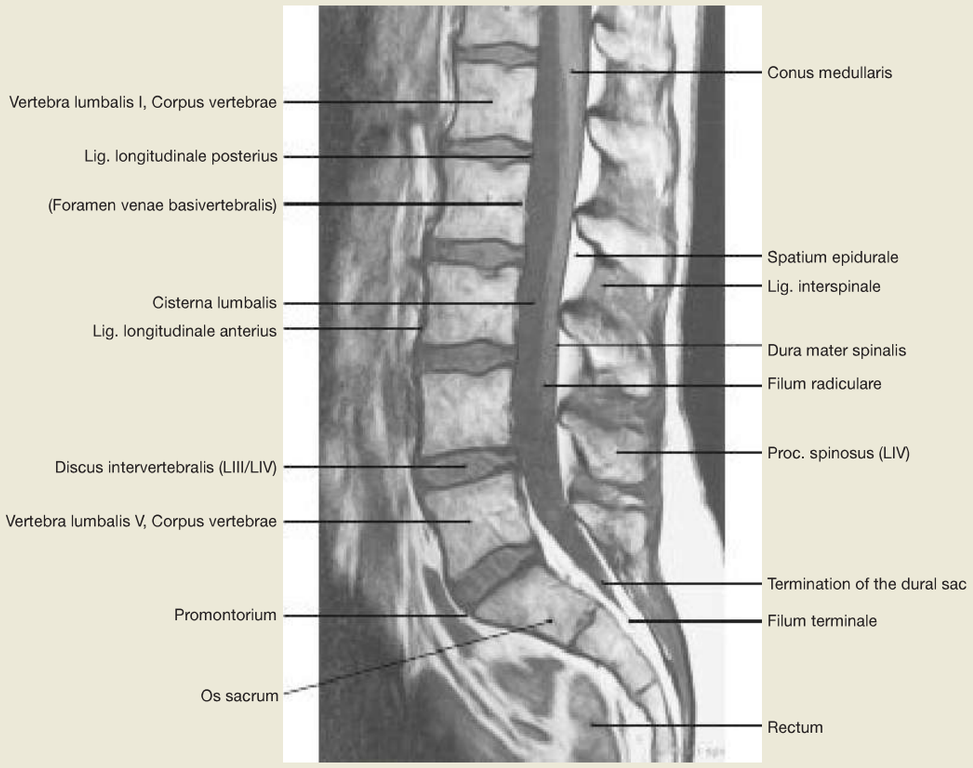

Fig. 12.195 Lumbar spine; magnetic resonance imaging (MRI) scan of the lumbar and lower thoracic parts of the vertebral column, median section, T1-weighted. [R316-007]

It is clearly visible that the spinal cord ends at the level of LI/LII, and that the Cauda equina only partially fills the vertebral canal.

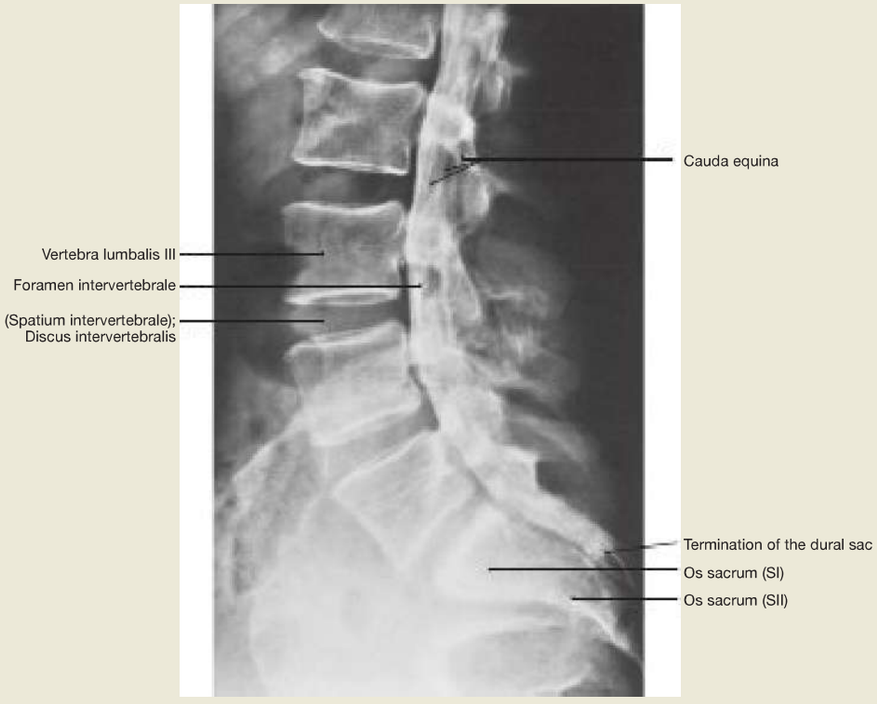

Fig. 12.196 Myelography of the lumbosacral transition zone; X-ray image in lateral beam projection. [R316-007]

The contrast medium was distributed in the subarachnoid space. The distal end of the dural sac (CSF space, subarachnoid space) is at the level of the second sacral vertebra (SII).

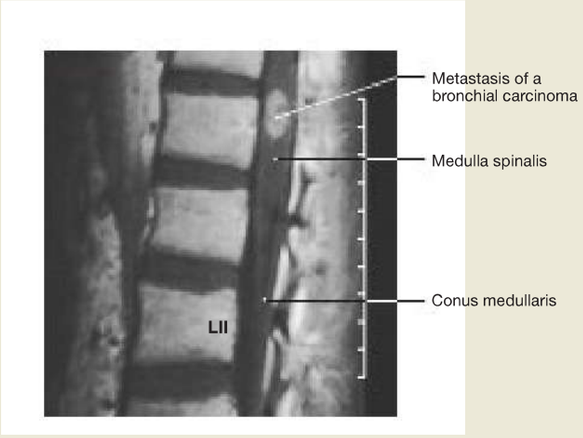

Fig. 12.197 Vertebral canal, Canalis vertebralis, with spinal cord, Medulla spinalis; magnetic resonance imaging (MRI) scan of the lower thoracic and upper lumbar parts of the vertebral column, median section; paraplegia due to a spinal tumour. [R317]

In this MRI scan, the tumour presents as a white mass against the surrounding spinal cord. It is a metastasis of a known bronchial carcinoma. The patient was admitted with complete paraplegia of the lower limbs and a complete loss of all sensory functions below the dermatome L2.

Clinical Remarks

Damage or compression of the spinal cord can be caused by intramedullary (→ Fig. 12.198) or extramedullary tumours, medial disc prolapses, dorsal spondylophytes, or due to an accident. A complete **paraplegia** results in the loss of all qualities of sensory, motor and autonomic functions below the lesion site. At the beginning a flaccid paralysis develops below the lesion site (spinal shock), which over time converts into a spastic paralysis.

The **BROWN-SÉQUARD's syndrome** is defined as a spinal hemiplegia with spastic paresis below the lesion site, and dissociative sensory dysfunctions combined with a loss of proprioception (deep sensibility; dorsal tracts) on the affected side and a loss in pain and temperature sensation on the contralateral side (lateral tracts; → Fig. 12.211).

Pyramidal Tract

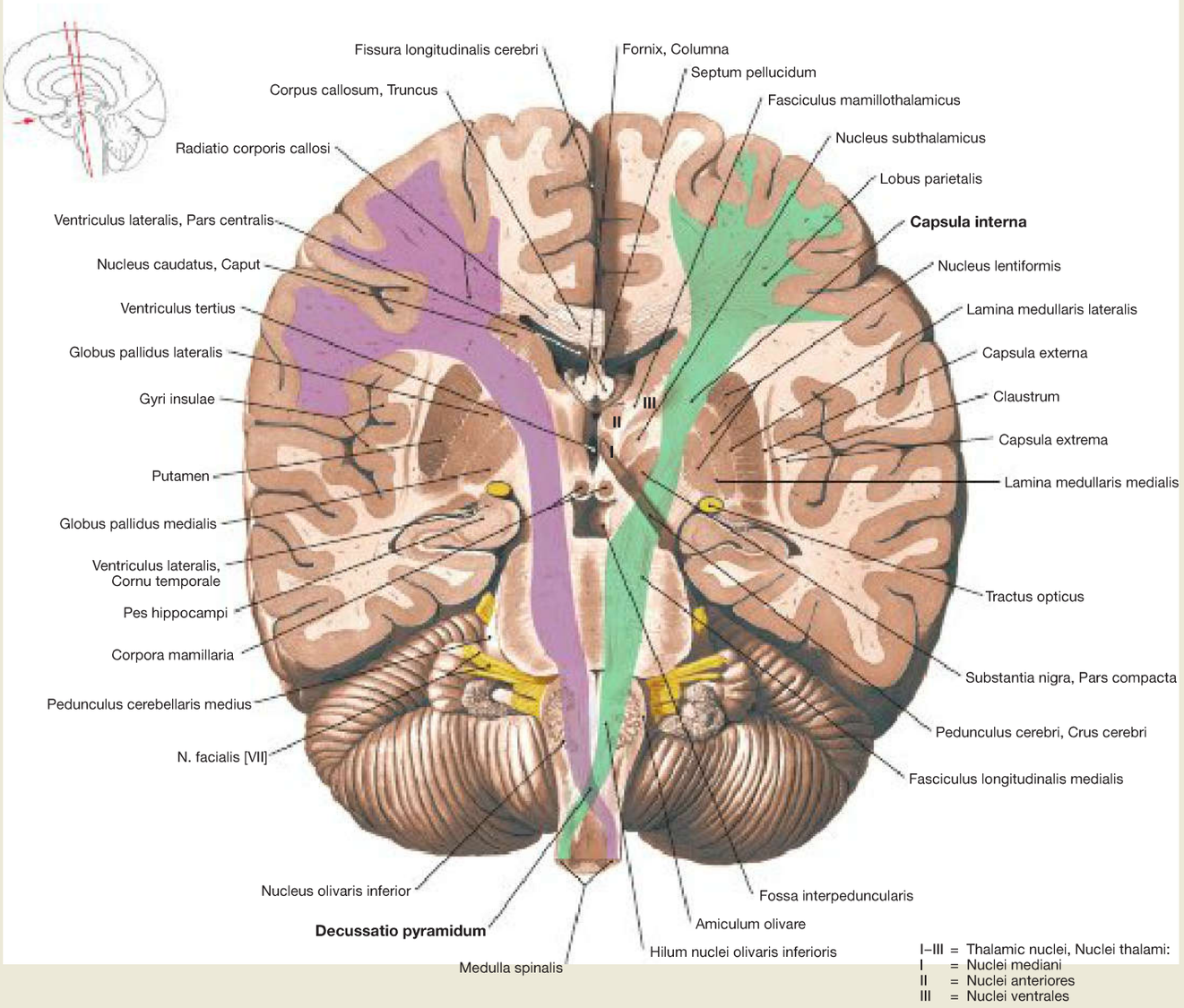

Fig. 12.198 Pyramidal tract, Tractus pyramidalis, and basal ganglia, Nuclei basales; oblique staggered section through the posterior limb of the internal capsule, the cerebral peduncles, and the Medulla oblongata; anterior view; pyramidal tracts highlighted in colours, right tract: pink, left tract: green.
The pyramidal tract transmits motor impulses from the motor cortex to the motor efferent nuclei of the cranial nerves (Fibrae corticonucleares) and the motor neurons in the anterior horn of the spinal cord (Fibrae corticospinales).

The fibres **originate** in the Gyrus precentralis, in secondary motor fields, and in somatosensory cortical areas. They **converge** in the Corona radiata, and in somatotopic arrangement they pass through the Genu and Crus posterius of the Capsula interna (→ Fig. 12.201). Along their way they pass through the **Crura cerebri** in the mesencephalon. In the brain stem, the Fibrae corticonucleares leave the pyramidal tract at different levels. In the decussation of the pyramids **(Decussatio pyramidum)**, the major part of the remaining fibres (Fibrae corticospinales) cross to the opposite side, whereas a smaller fraction continues on the ipsilateral side downwards and crosses to the opposite side only within the spinal cord.

Clinical Remarks

Lesions of the pyramidal tract initially result in a flaccid paralysis of the muscles on the contralateral side, although the propagation of action potentials in the peripheral nervous system and in the muscles is still intact. In particular, the fine motor skills of the hand and foot are affected. Gross movements of the proximal limbs and of the torso are usually quite still perfectly. In the context of the lesion, primitive reflexes, which are normally blocked by the pyramidal tract, return. These reflexes can be triggered in healthy children up to the age of two years, as the nerve fibres of the pyramidal tract are not yet completely myelinated. For example, the **BABINSKI's reflex** can be triggered again (stroking the lateral sole of the foot leads to dorsiflexion of the big toe).
With time, patients with a lesion of the pyramidal tract develop an increased muscular tonus and extensor reflexes, but weakened flexor reflexes. This syndrome of spastic paralysis, however, is caused by an additional lesion of the reticulospinal (extrapyramidal) tracts.

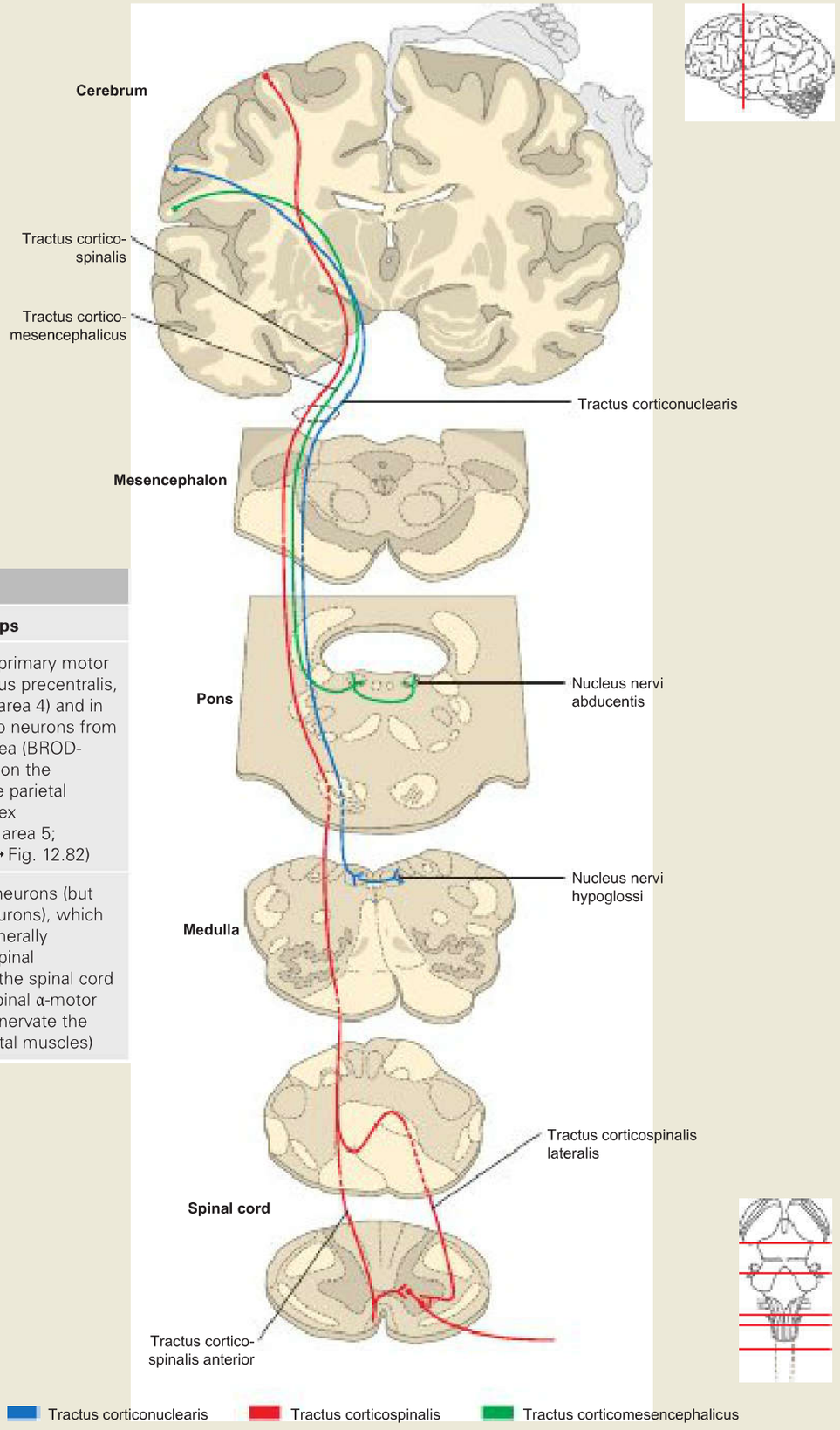

Pyramidal System	
Neuronal Chain	**Neuronal Groups**
First neuron	Neurons of the primary motor cortex, M1 (Gyrus precentralis, BRODMANN's area 4) and in some cases also neurons from the premotor area (BRODMANN's area 6 on the convexity) or the parietal association cortex (BRODMANN's area 5; → Fig. 12.208, → Fig. 12.82)
Second or third neuron	Spinal α-motor neurons (but also γ-motor neurons), which are however generally innervated via spinal interneurons in the spinal cord segment (the spinal α-motor neurons then innervate the peripheral skeletal muscles)

Fig. 12.199 Parts and course of the pyramidal tract; schematic drawing. [L127]
The Tractus corticospinalis (red) passes through the Capsula interna and forms the Tractus corticospinales anterior and lateralis at the level of the pyramids. The Tractus corticonuclearis ends crossed and uncrossed at the motor nuclei of the cranial nerves. The Tractus corticomesencephalicus (green) includes fibres from the central visual field, which end at the motor nuclei of the cranial nerves III, IV and VI (e. g. the Nucleus nervi abducentis, as shown here).

Internal Capsule

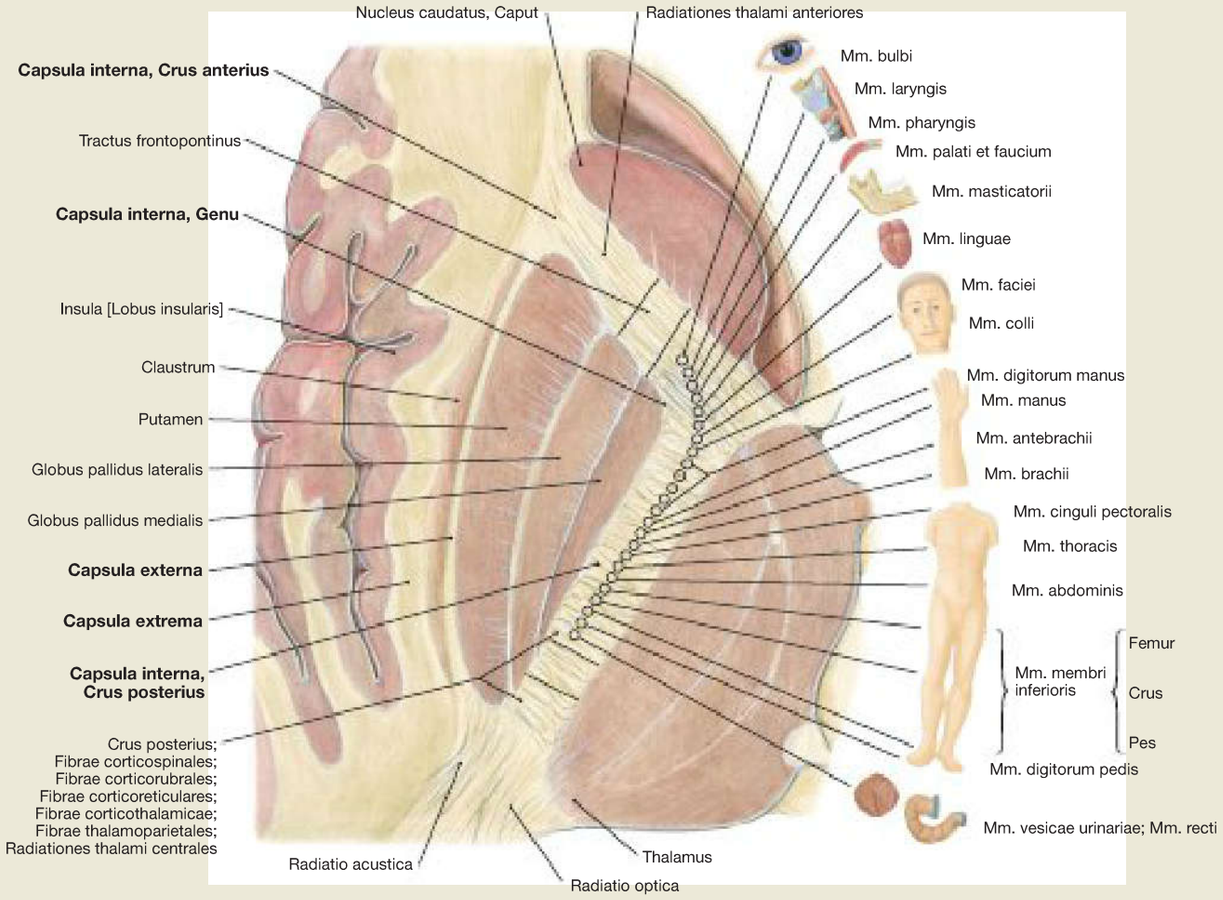

Fig. 12.200 Internal capsule, Capsula interna; structure and functions.
The Capsula interna is a structure of high clinical relevance because almost all **cortical projection tracts** are concentrated here in a small space. The Capsula interna is confined by the Nucleus caudatus medially anterior and by the Thalamus medially posterior, and by the Globus pallidus and the Putamen laterally. In the horizontal section, the Capsula interna appears angled. A distinction is made between the anterior limb (Crus anterius), the 'knee-like' genu and the posterior limb (Crus posterius) of the Capsula interna. Within the Capsula interna, the descending tracts are arranged **somatotopically**. The corticonuclear fibres run in the genu, and the corticospinal fibres passing in the Crus posterius towards the upper limb, torso and lower limb have a somatotopic arrangement (from anterior to posterior).

Tracts and Arterial Blood Supply of the Capsula interna

Location	Tracts (Analogous to the clinical usage of the terms, Fibrae and Tractus are synonyms here.)	Blood Supply
Anterior limb (Crus anterius)	• Tractus frontopontinus (from the frontal lobe to pons) • Radiatio thalami anterior (from the thalamus to the frontal cortex)	Aa. centrales anteromediales (from the A. cerebri anterior)
Genu	• Tractus corticonuclearis (part of the pyramidal tract)	Aa. centrales anterolaterales (from the A. cerebri media) = Aa. lenticulostriatae
Posterior limb (Crus posterius)	• Tractus corticospinalis • Tractus corticorubralis and Tractus corticoreticularis • Radiatio centralis thalami (from rostral thalamic nuclei to the motor cortex) • Radiatio thalami posterior (from the Corpus geniculatum laterale and further thalamic nuclei to the Lobus parietalis and Lobus occipitalis) • Tractus parietotemporopontinae and Tractus occipitopontinus (from the Lobus temporalis or Lobus occipitalis to the Pons) • Radiatio optica (optic/visual radiation; from the Corpus geniculatum laterale to the Lobus occipitalis) • Radiatio acustica (acoustic radiation; from the Corpus geniculatum mediale to the Lobus temporalis)	Rr. capsulae internae (from the A. choroidea anterior)

Clinical Remarks

The blood vessels supplying the Capsula interna are terminal arteries. **Vascular occlusions** and **mass bleeding** after rupture of a blood vessel (especially Aa. centrales anterolaterales) with capsular haemorrhage are not rare. Secondary to the destruction of the tracts, a **stroke** (apoplexy) can occur. Its severity depends on the location (lesion site) in the Capsula interna. Common symptoms are a contralateral paralysis (hemiplegia), sensory deficits, and failure of the contralateral half of the visual field (hemianopsia).

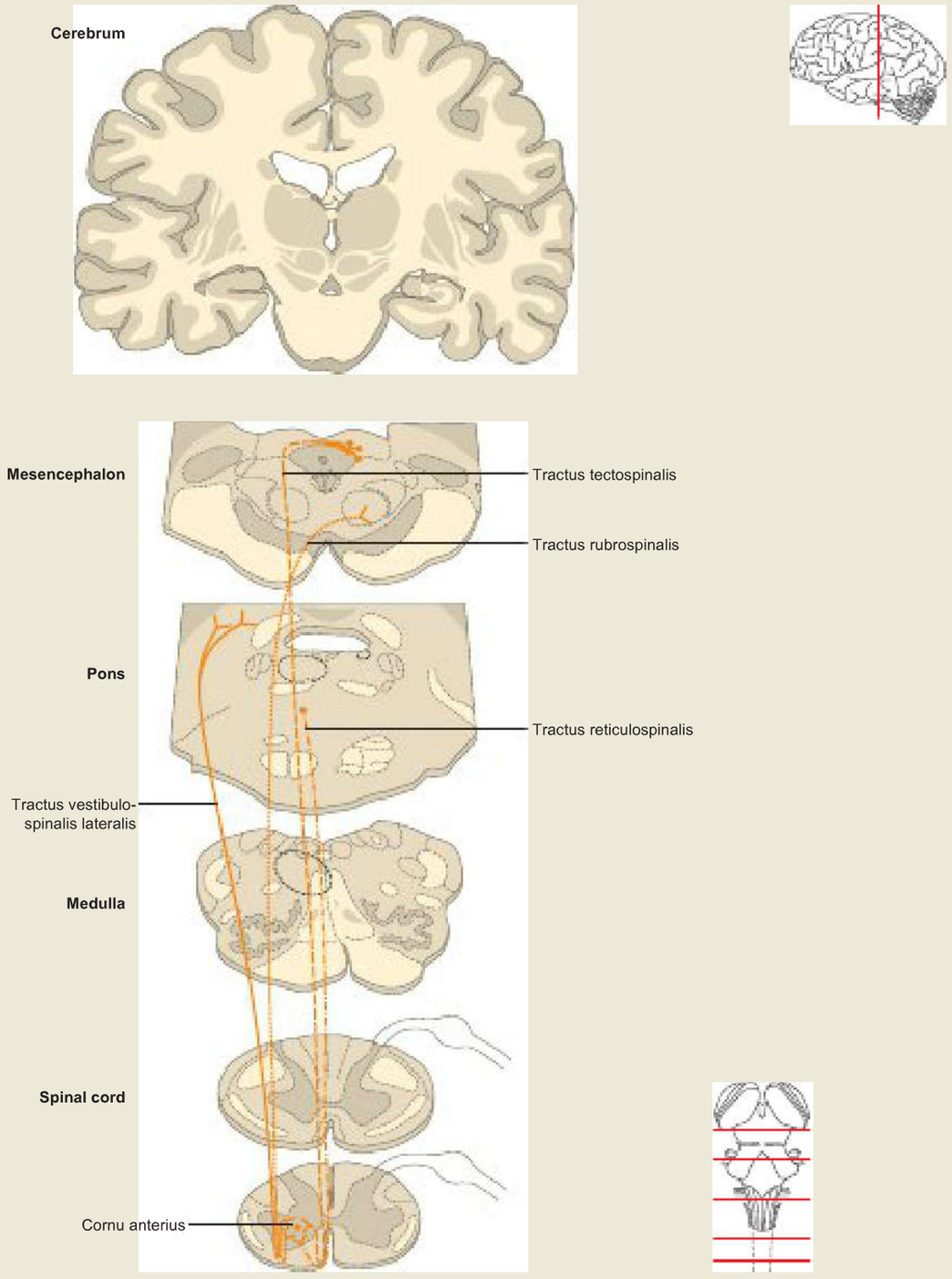

Fig. 12.201 Extrapyramidal motor system (EPMS); schematic drawing. [L127]
Regarding phylogenetic aspects, the extrapyramidal motor system (EPMS) is older than the pyramidal system; it consists of descending fibre systems that originate in different nuclear areas of the brain stem. They run crossed or uncrossed in the anterolateral column of the spinal cord. Nuclei or nuclear areas are the Formatio reticularis (Tractus reticulospinalis), Nucleus ruber (Tractus rubrospinalis), Tectum (Colliculi superiores, Tractus tectospinalis) and the Nuclei vestibulares lateralis and medialis (Tractus vestibulospinalis). The nuclei or nuclear areas receive primary afferent impulses from the cerebellum and the cortex, and are closely connected to the basal ganglia (especially to the Striatum). They play a role in the control of conscious and unconscious movements by coordinating the processes ('fluency') of motions, guiding the mostly involuntary movements, and maintaining the muscle tone and balance. The Tractus reticulospinalis, Tractus vestibulospinalis and Tractus tectospinalis are functional-anatomical components of the medial system for the innervation of the axial-skeletal and leg muscles (including stance or postural motility); in contrast, the Tractus rubrospinalis belongs to the lateral system that mainly mediates the movement patterns of arms and hands via the innervation of the upper limbs.

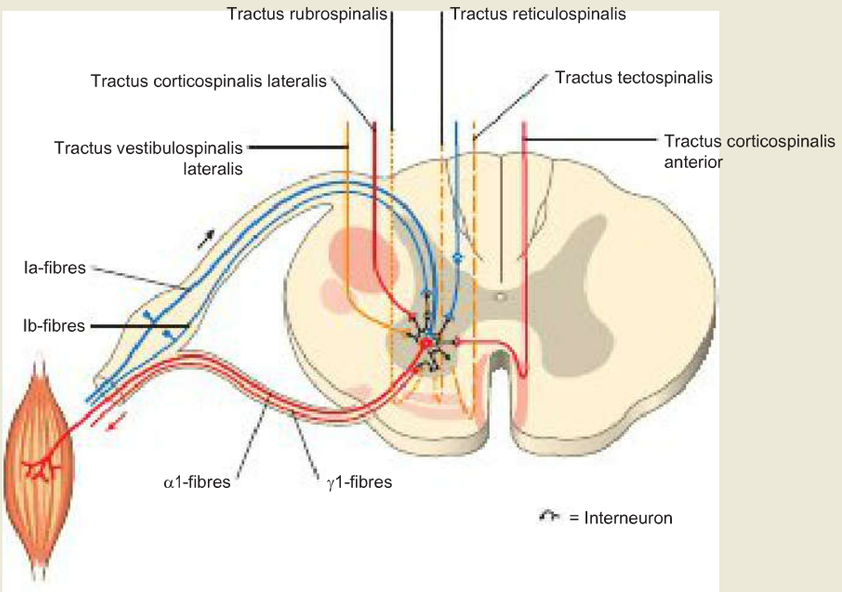

Fig. 12.202 Final motor pathway and motor unit; schematic drawing. [L127]
The α- and γ-motor neurons in the spinal cord are innervated (mostly via interneurons) by various tracts of the pyramidal and extrapyramidal systems. Individual motor neurons (nerve cells of the anterior horn) with their axons and the muscle fibres innervated by them are referred to as a **motor unit.** Via afferent fibres, the motor neurons also receive information of the corresponding muscle fibres (e. g. via stretch receptors).

Clinical Remarks

Lesions of the motor unit lead to a **flaccid paralysis.** This is associated with decreased gross motor strength, muscular hypotonia or atonia, hyporeflexia or areflexia, and muscle atrophy.
If central motor tracts are damaged, a **spastic paralysis** will develop. This is associated with a reduction in strength and fine motor skills, increased spastic tone, increased stretch reflexes, attenuated multisynaptic reflexes and occurrence of **pathological reflexes** (e. g. BABINSKI's reflex, OPPENHEIM's sign), while the muscles remain initially unchanged. Lesions of the central tracts cause a flaccid paralysis in the beginning, because the stretch reflexes are suppressed. But soon a spastic paralysis will develop.
Positive **BABINSKI's reflex**: stroking the lateral sole of the foot triggers a dorsal movement of the big toe with simultaneous plantar movement of the other toes (this is a physiological reflex in newborns, which disappears in the course of the early neuronal maturation).
Positive **OPPENHEIM's sign**: identical movements of the toes as in the BABINSKI's reflex test, but after stroking the anterior tibia.

In the case of neurodegenerative diseases (affecting the motor neurons), a distinction is made in English-speaking countries between **'upper motor neuron disease'** and **'lower motor neuron disease'**. As stated above, lesions of the first motor neuron result in a spastic paralysis (e. g. due to a stroke, multiple sclerosis, traumatic brain injury). Exceptions are isolated lesions of the first motor neuron causing a flaccid paralysis. Lesions of the second motor neuron result in a flaccid paralysis (e. g. associated with **poliomyelitis, GUILLAIN-BARRÉ's syndrome,** nerve plexus or peripheral nerve lesions). Sometimes with this disease, both motor neurons are damaged (e.g. **amyotrophic lateral sclerosis** which manifests with a mixed picture of spastic and flaccid paralysis). Diseases of central areas which play a decisive role in the motor pathways can also lead to striking pathologies (e. g. **PARKINSON's disease, HUNTINGTON's disease, hemiballism**).

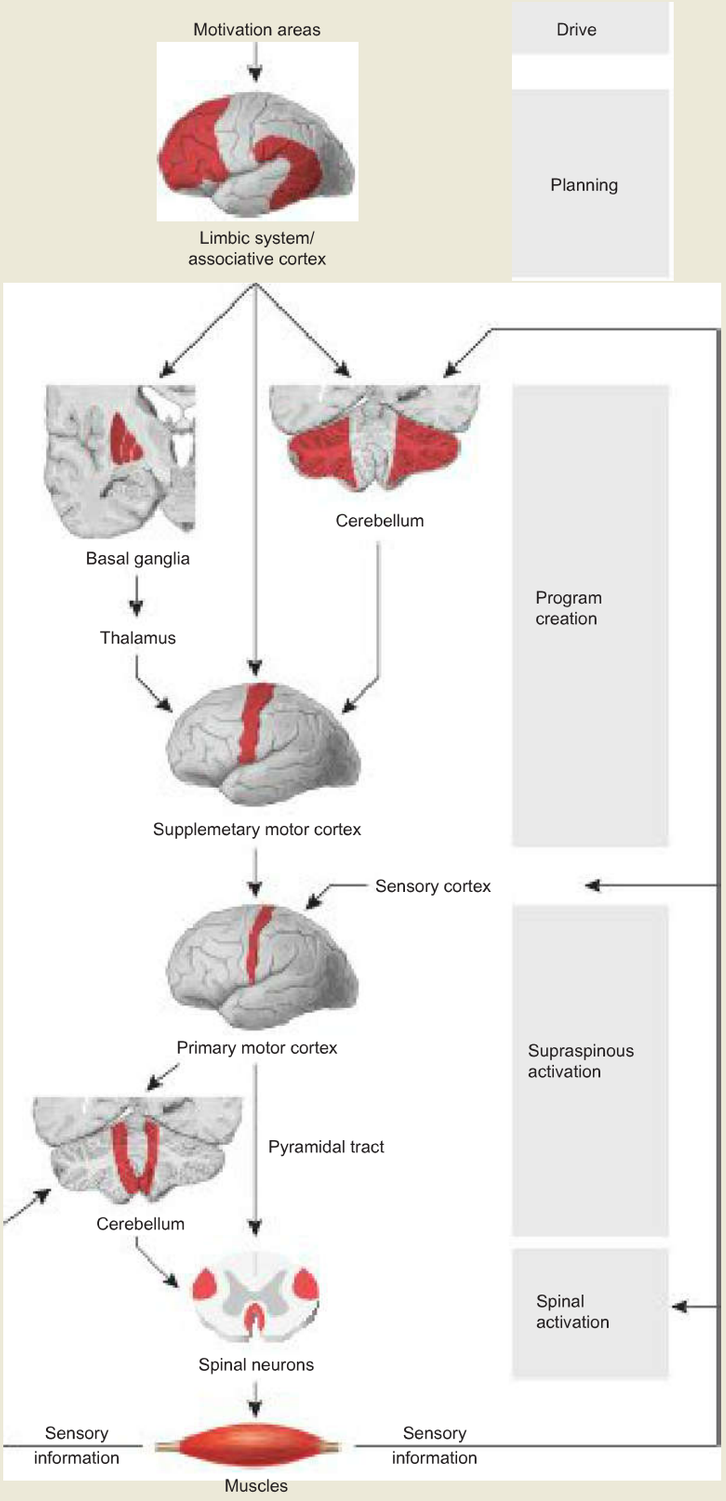

Fig. 12.203 Planning and realisation of voluntary movements; schematic drawing. [L127]
The structures shown in the diagram work closely together when carrying out controlled, voluntary movements. This is a sequence of tightly coupled processes in a given time, so that they are perceived as a single process.

Somatosensory System

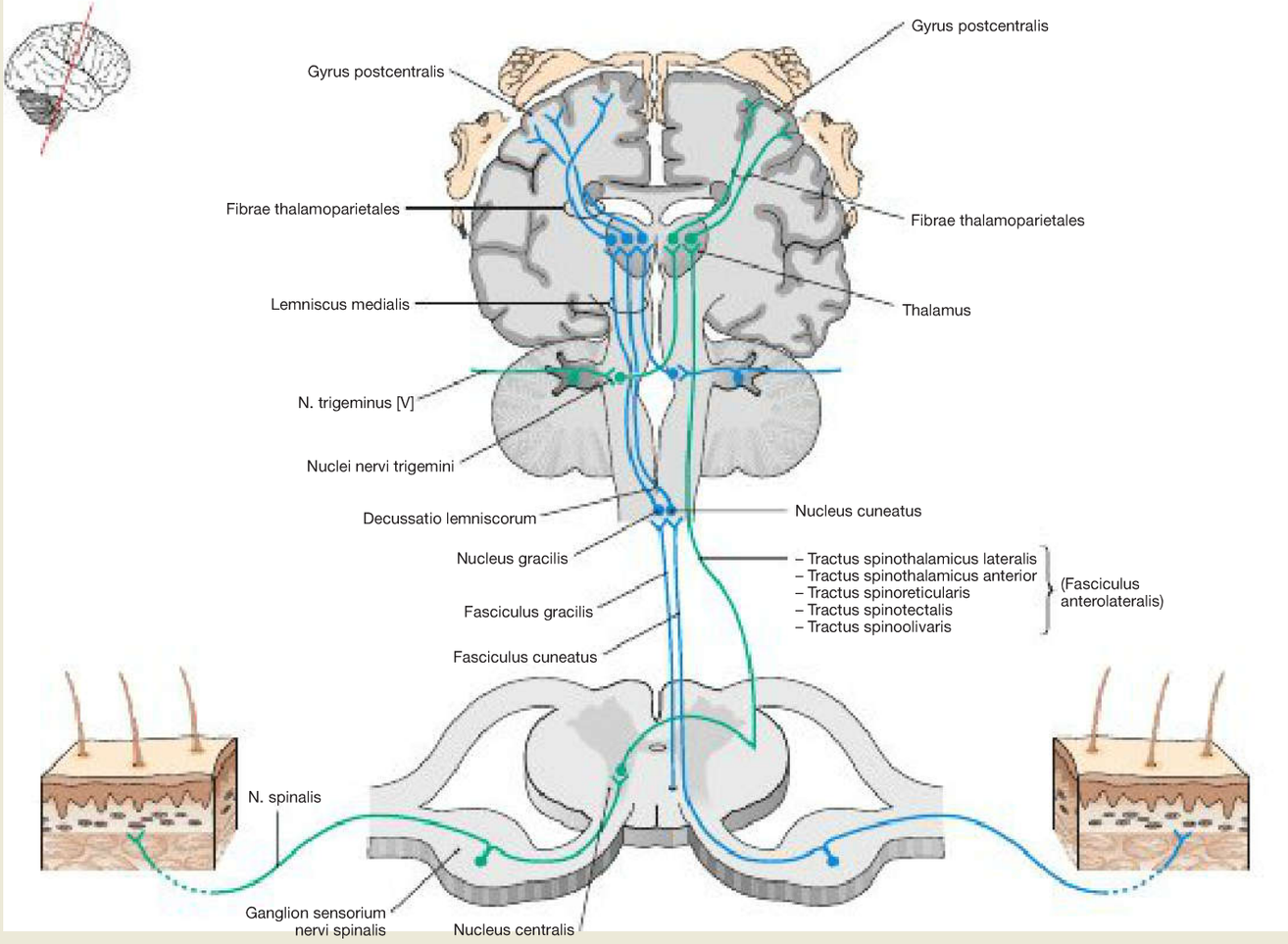

Fig. 12.204 Conduction of epicritic sensibility and pathway of the Funiculus posterior (blue), the spinal afferent and the trigeminal afferent tracts; pathway of pain/temperature and neospinothalamic tracts (green).
Circuitry of epicritic sensibility (somatosensory system; → Table), and circuitry of **protopathic sensibility** (nociceptive pathway, for the perception of pain, temperature and pressure sensations):

- **first neuron** (uncrossed): from receptors (exteroceptors) in the skin and mucosa etc. to the posterior horn, Laminae I to V (root cells, perikarya in the spinal ganglia)
- **second neuron** (crossed, some fibres possibly uncrossed): from the posterior horn to the Thalamus, into the Formatio reticularis and to the Tectum mesencephali (Tractus spinothalamici anterior and lateralis, Tractus spinoreticularis, Tractus spinotectalis; perikarya in the dorsal column)
- **third neuron** (uncrossed): from the Thalamus among others to the cerebral cortex, particularly to the Gyrus postcentralis (thalamocortical fibres, perikarya in the Thalamus)

Somatosensory System	
Neuronal Chain	**Location**
First neuron	Perikarya of pseudo-unipolar cells in the Ganglion spinale or Ganglion trigeminale
Second neuron	• in the Cornu posterius
	• in the Nucleus cuneatus or Nucleus gracilis of the Medulla oblongata
	• in the Nucleus dorsalis thalami
	• in the Nucleus spinalis nervi trigemini
Third neuron	Perikarya in the contralateral Nucleus ventralis posterolateralis of the Thalamus
Fourth neuron	Primary somatosensory cortex: Gyrus postcentralis and Lobulus paracentralis
Fifth neuron	Secondary somatosensory cortex: Operculum parietale

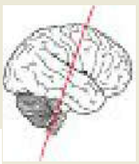

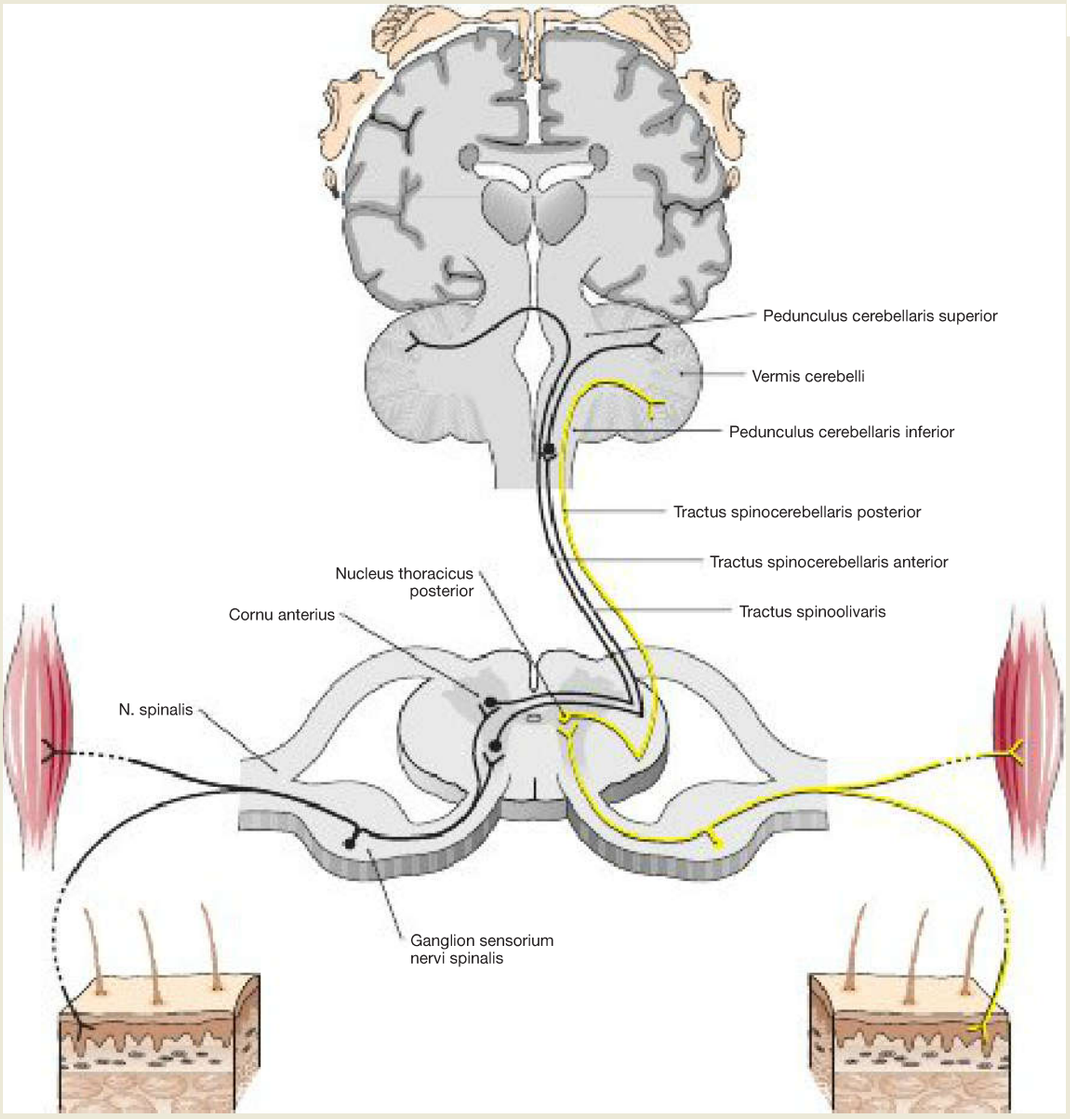

Fig. 12.205 Pathway of unconscious deep sensibility (= proprioception; afferent tract). Anterior spinocerebellar tract (Tractus spinocerebellaris anterior, black) and posterior spinocerebellar tract (Tractus spinocerebellaris posterior, yellow).
The posture of the body, motion and force vectors are perceived by the proprioception (deep sensibility). The **anterior spinocerebellar tract** (Tractus spinocerebellaris anterior, black) serves as the pathway of the unconscious deep sensibility (unconscious, but precise spatial differentiation as a prerequisite for the movement coordination by the cerebellum):

- **first neuron** (uncrossed): from proprioceptive receptors in muscles, tendons and the connective tissue to the nuclei in the Zona intermedia and the anterior (ventral) column (root cells, perikarya in the spinal ganglia).
- **second neuron** (double-crossed): from the anterior horn as Tractus spinocerebellaris anterior within the anterolateral tract, and via the Pedunculus cerebellaris superior to the cerebellum (cells of the tract, perikarya in the Zona intermedia and the anterior horn).

Another pathway of the unconscious deep sensibility or proprioception is the **posterior spinocerebellar tract** (Tractus spinocerebellaris posterior, yellow):

- **first neuron** (uncrossed): from the end organs (proprioceptive receptors) in muscles, tendons, and the connective tissue to the nuclei of the posterior (dorsal) column and to the Nucleus thoracicus (root cells, perikarya in the spinal ganglia).
- **second neuron** (uncrossed): from the posterior horn and the Nucleus thoracicus as Tractus spinocerebellaris posterior within the lateral tract, and via the Pedunculus cerebellaris inferior to the cerebellum (cells of the tract, perikarya in the Nucleus thoracicus and at the base of the posterior column)

Somatosensory System

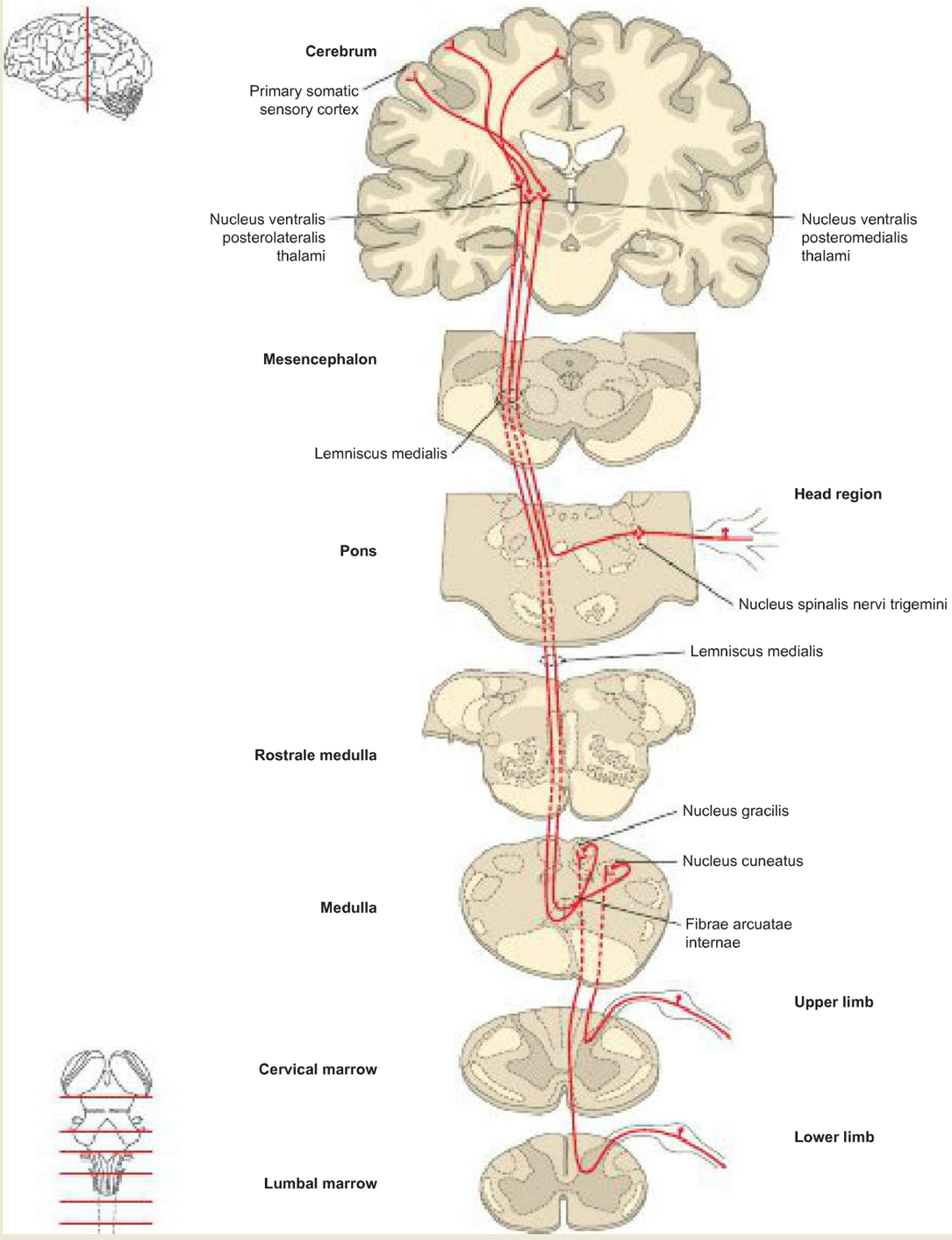

Fig. 12.206 Pathway of the epicritic sensibility: spinal afferent tracts of the Funiculus posterior as well as trigeminal afferent tracts into the head region. [L127]
The system of the posterior tracts is characterised by the fact that the fibres are neither switched nor crossed to the opposite side, but run in the ipsilateral Funiculus posterior to the cranial Nuclei cuneatus and gracilis. Only after being relayed within the two nuclear areas of the Medulla oblongata, the axons (of the second neuron) cross as **Fibrae arcuatae internae** in the Decussatio lemnisci medialis onto the opposite side. Along the rest of its pathway as the Tractus bulbothalamicus within the **Lemniscus medialis** to the Nucleus ventralis posterolateralis in the Thalamus, during the re-switching and along the pathway as thalamocortical fibres (Fibrae thalamoparietales) through the Crus posterius of the Capsula interna and up to the primary somatosensory cortical areas (Gyrus postcentralis of the parietal lobe), the somatotopic arrangement (somatotopy) remains unchanged (→ Table, on p. 408). The first relay station of the N. trigeminus [V] lies in the **Nucleus spinalis nervi trigemini** in the pons. The fibres join the Tractus bulbothalamicus within the Lemniscus medialis and are switched in the **Nucleus ventralis posteromedialis** of the Thalamus before they reach their respective cortical areas as thalamocortical fibres. Here too, the somatotopy remains unchanged along the length of its pathway.

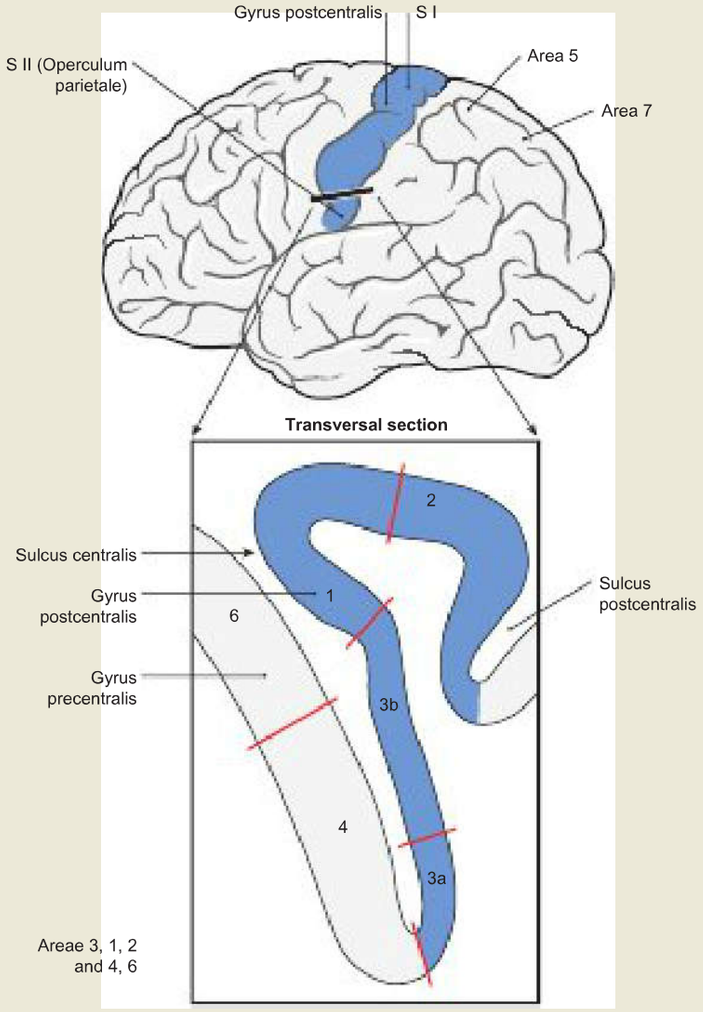

Fig. 12.207 Primary somatosensory cortical area (S I: BRODMANN's areas 3, 1, 2), secondary somatosensory cortical area in the Operculum parietale (S II), and somatosensory association cortex (BRODMANN's areas 5 and 7) of the Lobus parietalis. [L126]

In the primary somatosensory cortex, apart from the primary perception of sensations, an initial subjective perception also takes place. However, the essential interpretation of the somatosensory information only succeeds in the secondary somatosensory cortex. This small area is the Operculum parietale located in the Sulcus lateralis (Fissura SYLVII). Here, stimuli from both body halves (via the Corpus callosum) are united. From the secondary somatosensory cortical areas, the fibres continue to the somatosensory association areas (postparietal cortex, BRODMANN's areas 5 and 7), as well as to the insular region and to the limbic system. In the association areas, the afferent somatosensory stimuli are processed with visual stimuli, and via efferent fibres to the precentral region influence motor control.

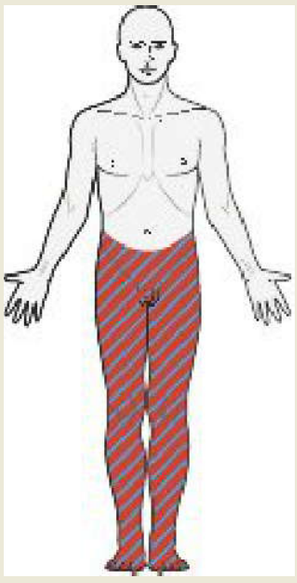

Fig. 12.208 Complete paraplegia at the level of the 11th thoracic segment. [L126]
This leads to a loss of all the motor and sensory functions in the marked (hatched) area.

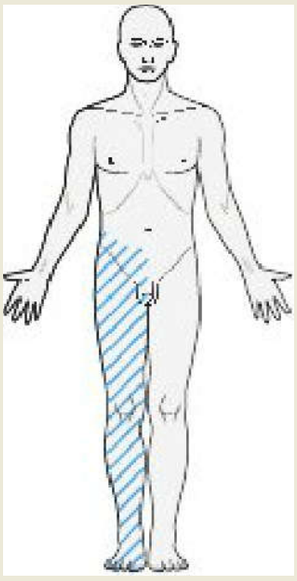

Fig. 12.209 Lesion of the tracts of the right Funiculus posterior at the level of the 11th thoracic segment. [L126]
This results in loss of fine tactile sensation and of postural and vibration sense (the function of gross touch sensation, however, remains intact).

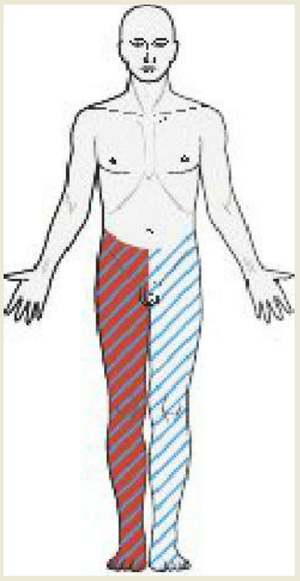

Fig. 12.210 Hemiplegia (BROWN-SÉQUARD) due to a right-sided (hemilateral) disruption of the spinal cord at the level of the 11th thoracic segment. [L126]
On the right side (homolateral), this results in a loss of motor function, initially of a flaccid type, and later in a spastic paralysis. Furthermore, this is combined with a loss of fine tactile sensation of postural and vibration sense (the function of gross touch sensation, however, remains intact). On the left side (contralateral), the result is a loss of pain and temperature sensation (→ Fig. 12.204).

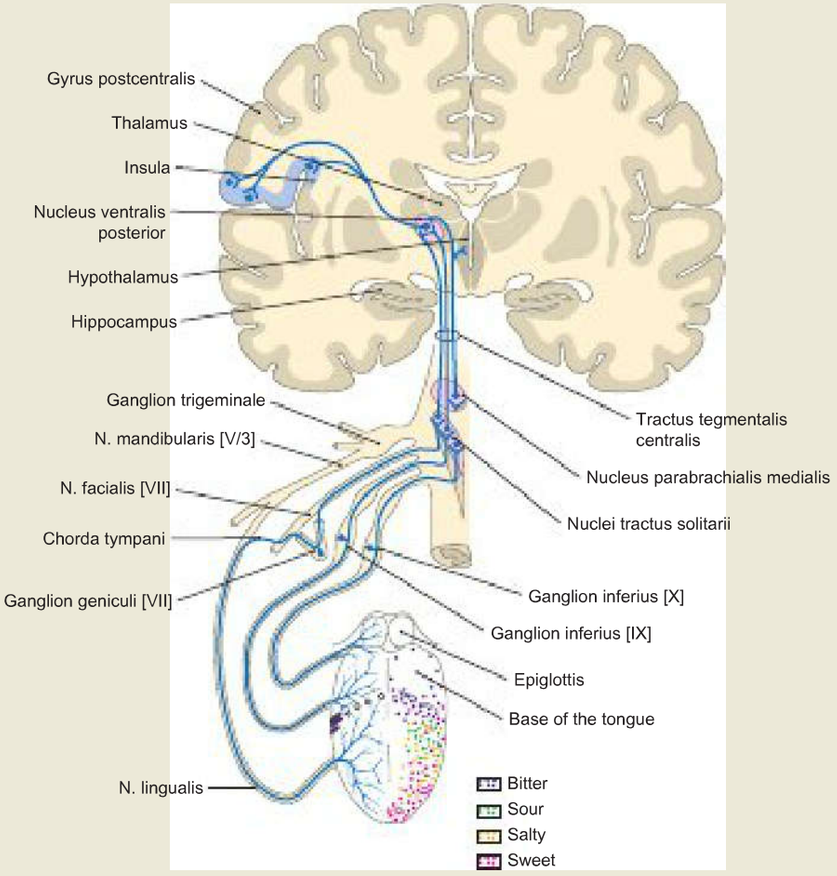

Fig. 12.211 Tongue with epiglottis and gustatory (taste) system. [L127]

Approximately 2,000 **taste buds (Caliculi gustatorii)** can be found on the human tongue (in the **Papillae vallatae, fungiformes and foliatae**), the soft palate and the epiglottis. Each taste bud consists of different cell types. The actual receptor cells are epithelial cells, which perceive the five primary taste categories (→ Fig. 8.167) – sweet, sour, salty, bitter, umami – (the sixth could possibly also be oily). The sensory cells of taste form synapses with axonal plexuses located on the basal side of the taste buds. These are sometimes referred to as **secondary sensory cells,** since the sensory cells do not depolarise, but their action potential arises only at the synapse with the first afferent neuron. Corresponding to their location, the information is transmitted to the **Nucleus tractus solitarii** in the Medulla oblongata:

- from the anterior two-thirds of the tongue via the N. facialis [VII] (Pars intermedia)
- from the posterior third of the tongue and the soft palate via the N. glossopharyngeus [IX]
- from the epiglottis and the soft palate via the N. vagus [X]

Corresponding to the respective nerves, the perikarya of the first neuron are located in the **Ganglion geniculi [VII],** in the **Ganglion inferius [IX]** (Ganglion petrosum) or in the **Ganglion inferius [X]** (Ganglion nodosum).

In the **Pars gustatoria (Nucleus gustatorius) of the brain stem,** the fibres are relayed onto the second neuron. The axons of the second neuron pass within the ipsilateral **Tractus tegmentalis centralis** (accompanying the Lemniscus medialis) to the **Nucleus ventralis posteromedialis of the thalamus,** where they are switched onto the third neuron. As thalamocortical fibres, they pass to the strictly somatotopically arranged (corresponding to the position of the homunculus) inferior parts of the Gyrus postcentralis, as well as to **anterior regions of the insular cortex** of the temporal lobe and the Operculum of the frontal lobe. These are the areas of conscious taste perception. Some axons pass directly from the thalamus or indirectly from the Nucleus tractus solitarii via the **Nucleus parabrachialis medialis** to the Hypothalamus and the Amygdala (which influences on autonomic body functions such as appetite, saturation, link with emotions).

Clinical Remarks

Since the excitation threshold for the action potential of taste receptors increases with age, the perception of taste sensations is age-dependent. Deficiency or complete loss of the taste sense is referred to as **hypogeusia** or **ageusia,** respectively. A common secondary cortical area of the gustatory and olfactory pathways in the orbital-frontal cortex shows the close functional relationship of taste and smell.

Nociceptive System

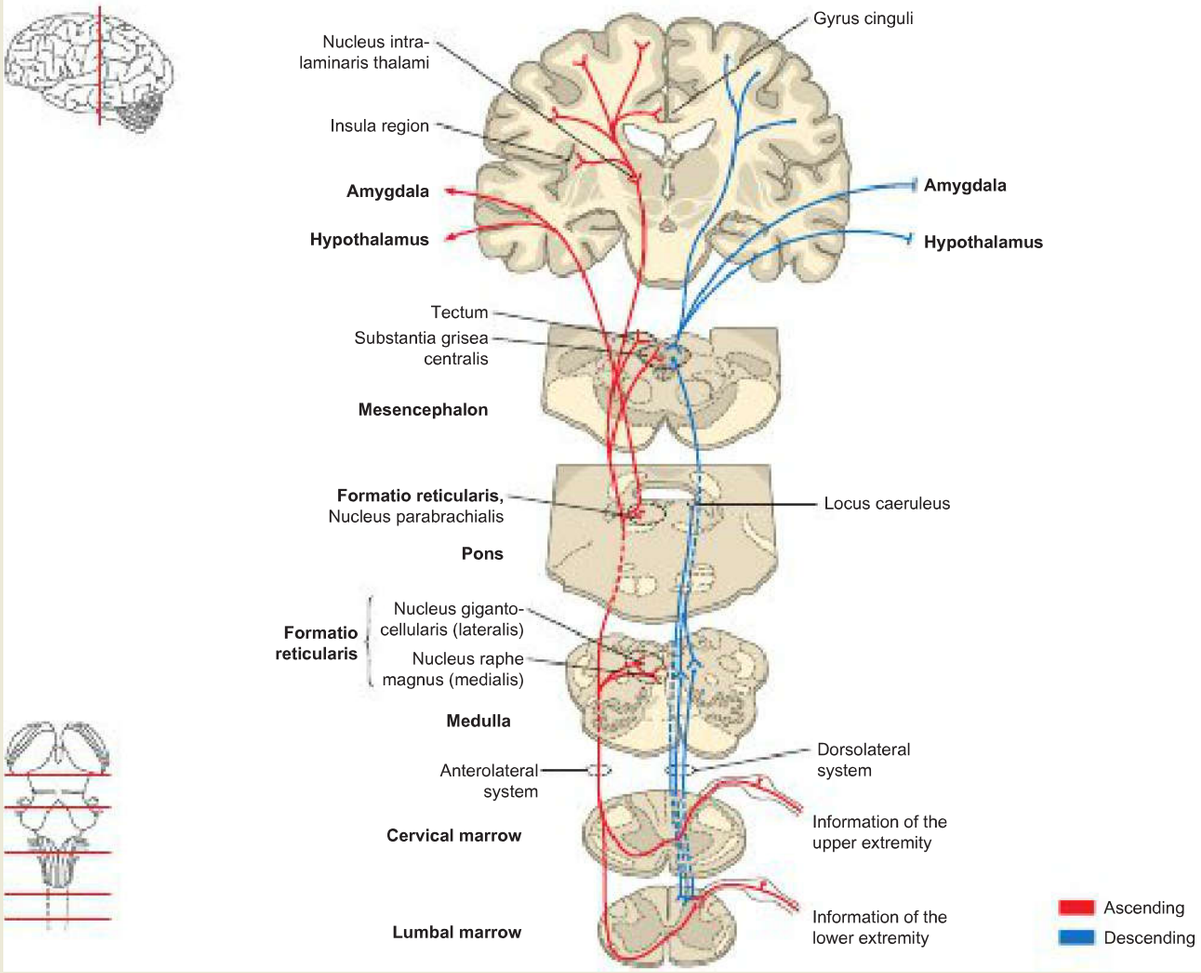

Fig. 12.212 Ascending tracts of the pain pathway in the Tractus paleospinothalamicus (illustrated in the left half) and descending tracts of pain modulating fibres (right half); simplified illustration. [L127]

The perception of pain sensations is highly subjective and determined by a complex neuronal processing and modulation of pain. A distinction is made between **acute and chronic pain, peripherally induced pain** (superficial somatic pain sensations by nociceptive receptors in the skin and muscles; deep somatic pain from joints and tendons; visceral pain due to chemical stimuli, tension of visceral organs or spasms of visceral smooth muscles), and **centrally mediated pain** (thalamic pain, psychosomatic pain, referred spinal pain).

Pain is essential for the survival and the integrity of the body. A distinction is made between three ascending tracts of the pain pathway:

- archispinothalamic tract (→ Table): runs mainly in the Fasciculi proprii of the spinal cord, conveys visceral, emotional and autonomic pain reactions via collateral fibre tracts to the hypothalamus and limbic system
- paleospinothalamic tract (→ Fig. 12.212): dull, slow, somatic and deep pain sensations, often associated with autonomic (vegetative) reactions
- neospinothalamic tract: sharp 'first' and fast somatic pain sensations from the skin and muscles of the upper and lower limbs

The central neurons end in the Cornu posterius (Lamina I) (→ Fig. 12.184 and → Fig. 12.185), and after the switching and crossing of the fibres in the Commissura anterior, the Tractus spinothalamicus lateralis continues to the thalamus. With a maintained somatotopic arrangement, the input is transmitted via thalamocortical fibres to the sensory cortex (Gyrus postcentralis), where pain will be consciously located. From the head and neck, the transmission continues via the Ganglion trigeminale to the Nucleus spinalis nervi trigemini in the Medulla oblongata, and via the contralateral Tractus trigeminothalamicus within the Lemniscus medialis to the Nucleus ventralis posteromedialis of the thalamus. From here the fibres pass to the corresponding brain regions of the Gyrus postcentralis.

Stations of the Nociceptive System

Neuronal Chain	Neuronal Groups
First neuron	Perikarya of pseudo-unipolar cells in the Ganglion spinale or Ganglion trigeminale
Second neuron	Within the Cornu posterius (Laminae II, IV–VIII) or Nucleus spinalis nervi trigemini
Third neuron	Perikarya of the Thalamus: Ipsilateral Nucleus ventralis posterolateralis (for the Tractus spinothalamicus) Contralateral Nucleus ventralis posteromedialis (for the Tractus trigeminothalamicus) Perikarya of intralaminar nuclei
Fourth neuron	Primary somatosensory cortex: Gyrus postcentralis Hypothalamus, limbic system Brain stem (Substantia grisea centralis, Tectum, Formatio reticularis)

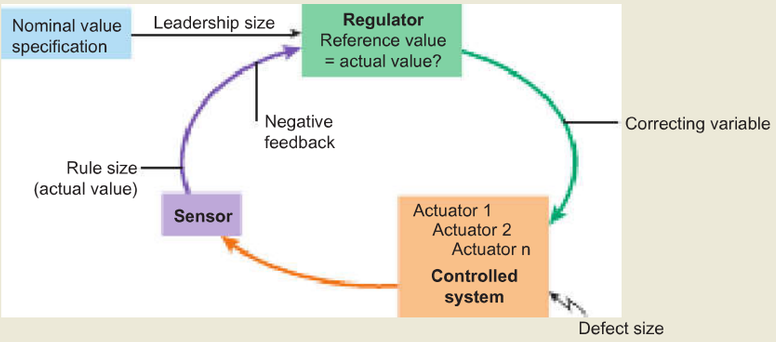

Fig. 12.213 Homeostatic feedback loop; schematic drawing. [L127]
A constant (steady) state of the body's internal milieu has to be maintained **(homeostasis).** For this purpose, the actual value is measured by a **sensor** (e. g. chemoreceptor), and this information is transmitted to a **regulator** (e. g. the respiratory centre in the brain stem). The regulator compares the actual value with the physiological nominal value, and by using appropriate **actuators** (e. g. respiratory drive) counteracts the measured difference, to equilibrate the actual and nominal values. This type of regulation is referred to as **negative feedback.**

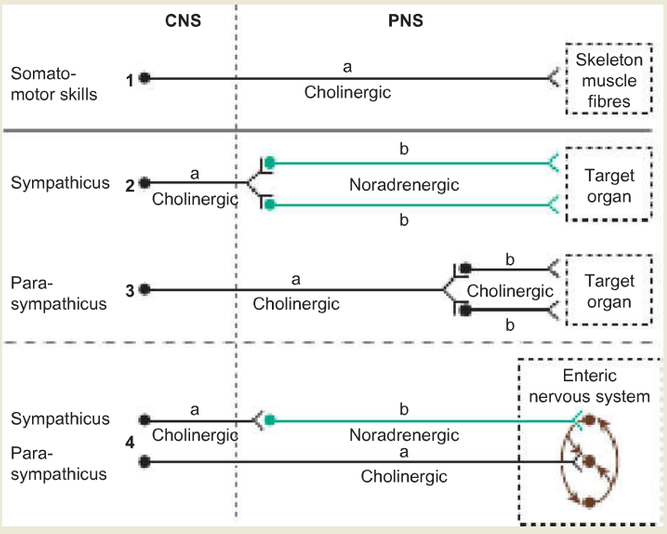

Fig. 12.214 Circuitry of the peripheral motor innervation in the somatic and autonomic nervous systems. 1 = somatic motor neuron, 2 = visceral motor neuron of the sympathetic nervous system, 3 = visceral motor neuron of the parasympathetic nervous system, 4 = visceral motor neurons and their impact on the enteric nervous system; a = first neuron, b = second neuron. [L141]
The somatic motor innervation of skeletal muscle fibres is provided directly (without circuitry) via the axons of α-motor neurons of the spinal cord. In contrast, the visceral motor axons are switched at least once in an autonomic ganglion (exception: medulla of the suprarenal gland). In the case of the sympathicus and parasympathicus, the first neuron **(preganglionic neuron)** lies in the central nervous system (brain stem or spinal cord). The corresponding axon **(preganglionic axon)** passes to an autonomic ganglion. There it is relayed onto the second neuron (postganglionic neuron). The latter continues to the target organ.

Clinical Remarks

The body's response to **negative stress (distress)** is a reinforced activation of the sympathetic nervous system and increased tension. Long-lasting stress situations may cause a persistent hyperactivity of the sympathetic nervous system. This is associated with an increased release of 'stress hormones' such as glucocorticoids (e. g. cortisol) and catecholamines (e. g. adrenaline). This is accompanied by dysfunctional autonomic symptoms such as increased heart rate and blood pressure (hypertension), cardiac dysrhythmias, irritability and restlessness and is felt and perceived as additional stress by the patient. If the distress continues (sympathetic hyperactivity and excessive secretion of stress hormones over a long period of time), this can cause a **physical and mental fatigue (burn-out)**.

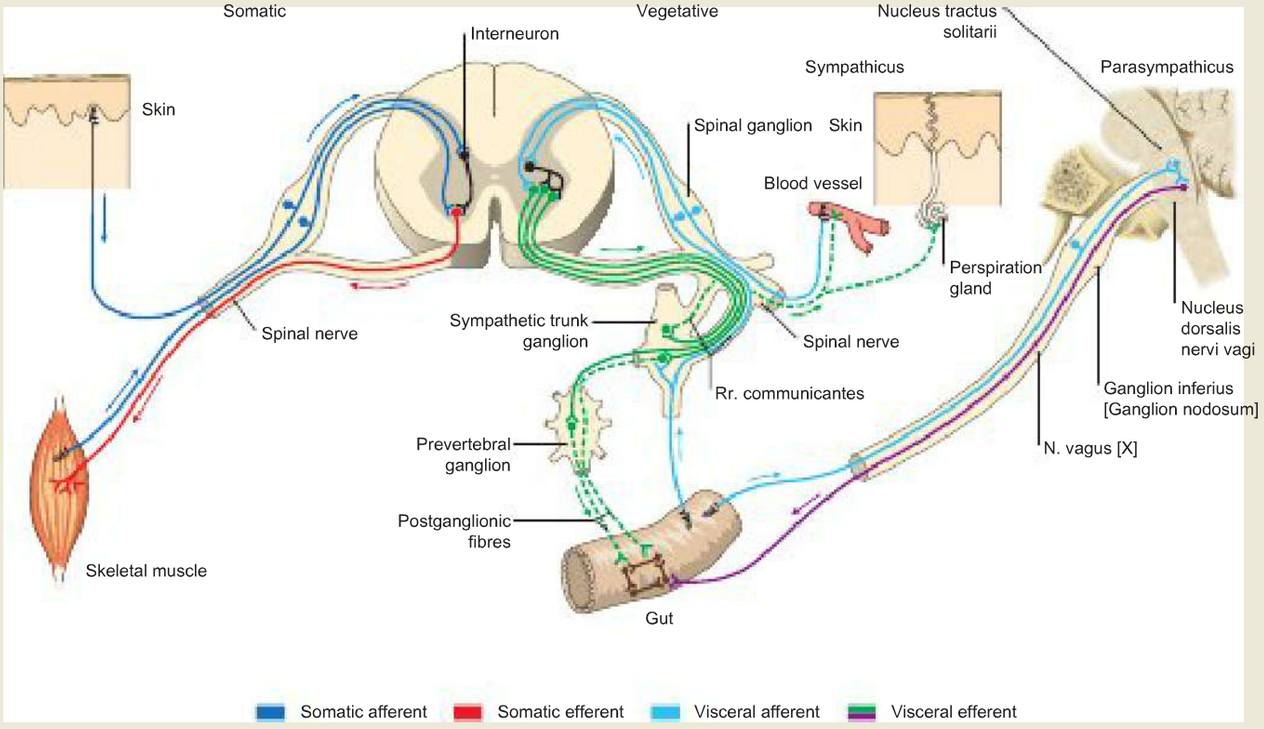

Fig. 12.215 Organisation of the somatic nervous system as compared to the autonomic nervous system (spinal cord and PNS); schematic drawing. [L127]
In the somatic nervous system (left side), afferent information is transmitted directly via the processes of the spinal ganglionic cells (monosynaptic reflex arch) or indirectly to the α-motor neurons of the anterior horn.
In the case of the sympathicus (right side), visceral afferent information is passed in a first step via spinal ganglionic cells to interneurons of the spinal cord. Via one or more relay stations, the information arrives finally in visceral efferent neurons of the lateral horn. From here, preganglionic visceral efferent axons (green, solid line) continue to the paravertebral ganglia of the spinal cord or the prevertebral ganglia near the aorta. After switching in the ganglia, the postganglionic axons (green, dotted line) reach their target organ. In the case of the parasympathicus (N. vagus [X] is given in the example) visceral afferent information is transmitted via the Ganglion inferius [Ganglion nodosum] of the N. vagus [X] to the Nucleus tractus solitarii in the brain stem, and then relayed onto the Nucleus dorsalis nervi vagi. The visceral motor fibres pass back into the body's periphery via the N. vagus [X] (vasovagal reflex arch).

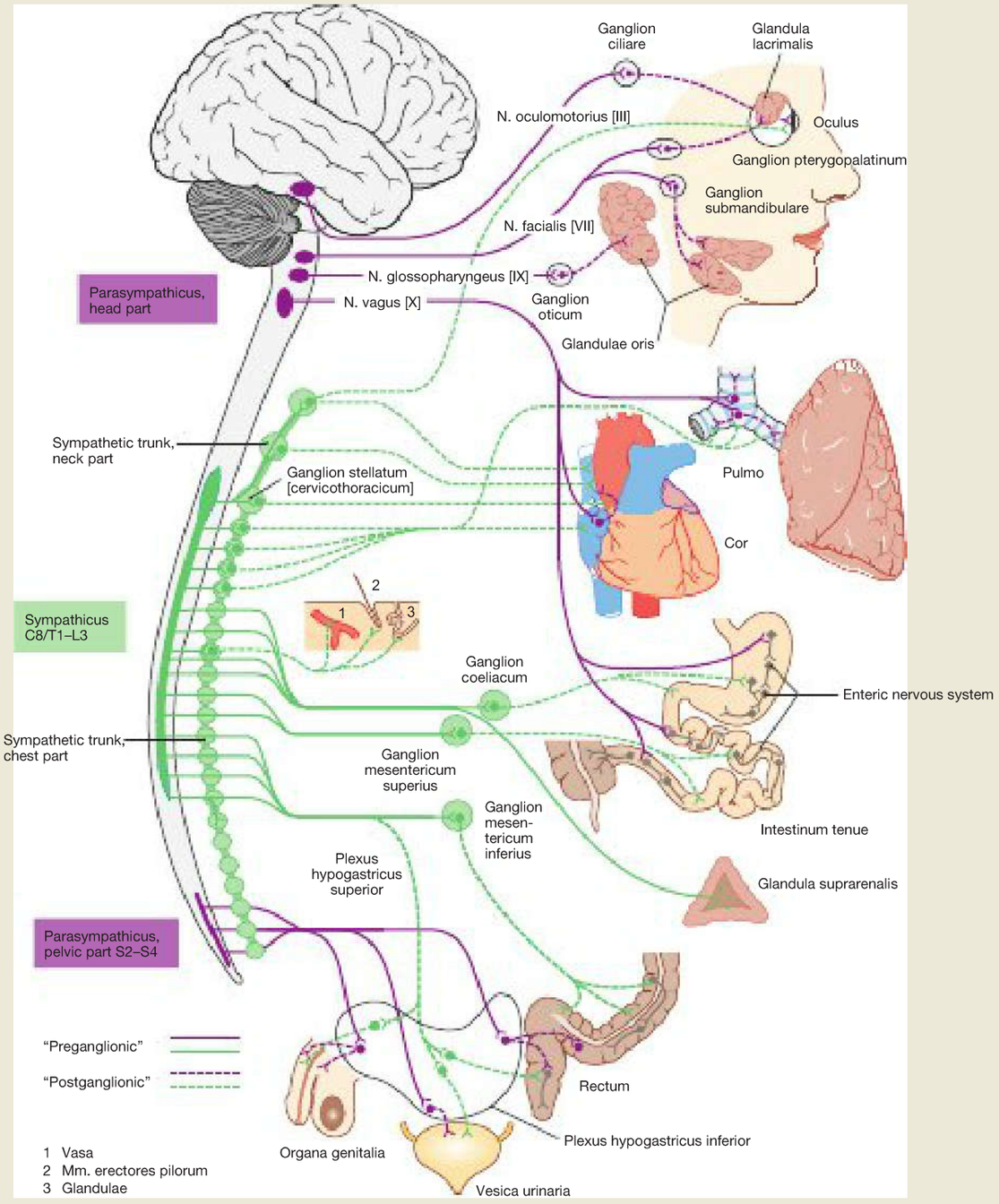

Fig. 12.216 Autonomic nervous system (sympathicus and parasympathicus). [L106/L126]
The autonomic nervous system comprises the sympathetic (green), the parasympathetic (purple), and the enteric nervous system.
The neurons of the **sympathicus** are located in the lateral horn of the thoracolumbar segment of the spinal cord. Their axons project to the ganglia of the sympathetic trunk and of the digestive tract. Here they are switched onto postganglionic neurons which project to the target organs. The sympathetic excitation serves to mobilise the body for activity, and in emergency situations. The sympathetic nervous system also comprises the medulla of the adrenal gland, which can release adrenaline and noradrenaline.
The nuclear areas of the **parasympathicus** are located in the brain stem and the sacral spinal cord. The axons project onto ganglia adjacent to the target organs, which are found in the head, thorax and abdominal cavity. Here they are switched onto postganglionic neurons, which reach the target organs via short axons. The parasympathetic nervous system plays an important role in the intake and processing (digestion) of food, as well as in sexual arousal, and forms a counterpart of the sympathicus.
The **enteric nervous system** regulates the intestines (intestinal activity), and is modulated by sympathetic and parasympathetic influences.

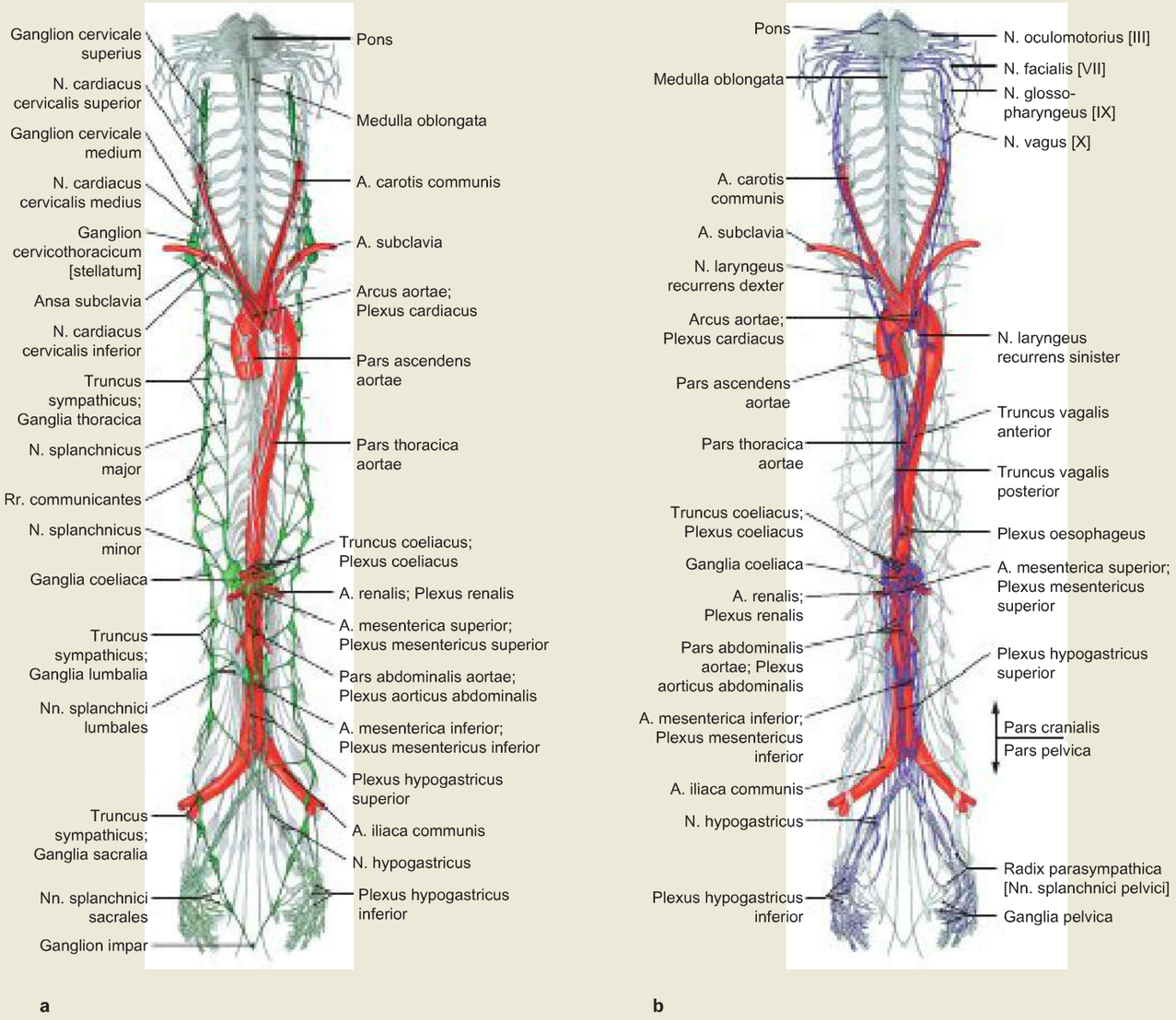

Fig. 12.217a and b Sympathicus and parasympathicus.
Semischematic representations of the sympathicus (→ Fig. 12.217a) and the parasympathicus (→ Fig. 12.217b) in a topographic-anatomical context.
Sympathetic axons exit the spinal cord with the Nn. spinales, pass to ganglia in the sympathetic trunk, and finally accompany blood vessels or nerves to their target organs. Parasympathetic axons in the head region pass with cranial nerves to the parasympathetic ganglia and from there to their target organs in the head. The thoracic and abdominal organs are mainly innervated by the N. vagus [X]. Only the last section of the intestines and the pelvic organs receive their parasympathetic innervation from the sacral spinal cord.

Autonomic Nervous System, Overview of the Functions

Cranial Parasympathicus (Cranial Nerves III, VII, IX)			
Cranial Nerve	**First Neuron**	**Second Neuron**	**Target Organs**
N. oculomotorius [III]	Nucleus accessorius nervi oculomotorii (EDINGER-WESTPHAL)	Ganglion ciliare	• M. ciliaris • M. sphincter pupillae
N. facialis [VII]	Nucleus salivatorius superior	Ganglion pterygopalatinum	• Glandula lacrimalis • Mucous membranes
		Ganglion submandibulare	• Glandula submandibularis • Glandula sublingualis • Mucous membranes
N. glossopharyngeus [IX]	Nucleus salivatorius inferior	Ganglion oticum	• Glandula parotidea • Mucous membranes

Parasympathicus			
Cranial Nerve	**First Neuron**	**Second Neuron**	**Target Organs**
Cranial Parasympathicus			
N. vagus [X]	Nucleus ambiguus (external formation)	Intramural ganglia	Cervical viscera, heart and lungs
	Nucleus dorsalis nervi vagi	Intramural ganglia	Intra-abdominal glands
		Ganglia of the enteric nervous system	Intestines
Sacral Parasympathicus			
Sacral parasympathicus		Ganglia pelvica	Genitalia
		Intramural ganglia	Distal colon, rectum, urinary bladder, ureter (parts)

Visceral Sensory Afferent Fibres/Impulses to the Brain Stem			
Nerve	**Ganglion**	**Central Nucleus**	**Origin (in Organs)**
N. glossopharyngeus [IX]	Ganglion inferius	Nucleus tractus solitarii	• Glomus caroticum • Sinus caroticus
N. vagus [X]	Ganglion inferius [Ganglion nodosum]	Nucleus tractus solitarii	• Glomera in the neck and thoracic region • Thoracic viscera • Gastrointestinal tract

Nuclear Areas of the Hypothalamus and their Function in Homeostasis		
Area	**Nuclear Area**	**Function**
Area hypothalamica anterior	Nucleus suprachiasmaticus	Circadian rhythm
	Nuclei preoptici	Regulation of the gonadotropin release in the anterior pituitary gland (adenohypophysis)
	Nucleus supraopticus	ADH, oxytocin secretion
	Nucleus paraventricularis	ADH, oxytocin secretion, food intake; regulation of stress hormone secretion via CRH
Area hypothalamica intermedia	Nucleus infundibularis [arcuatus], periventricular nerve cells	Control of the anterior pituitary gland (adenohypophysis); food intake (nutritional) behaviour
	Nucleus ventromedialis hypothalami, Nucleus dorsomedialis hypothalami	Regulation of food and fluid intake behaviour
Area hypothalamica posterior	Nucleus hypothalamicus posterior, Corpora mamillaria	Thermal regulation, autonomic control
Area hypothalamica lateralis		Food intake behaviour

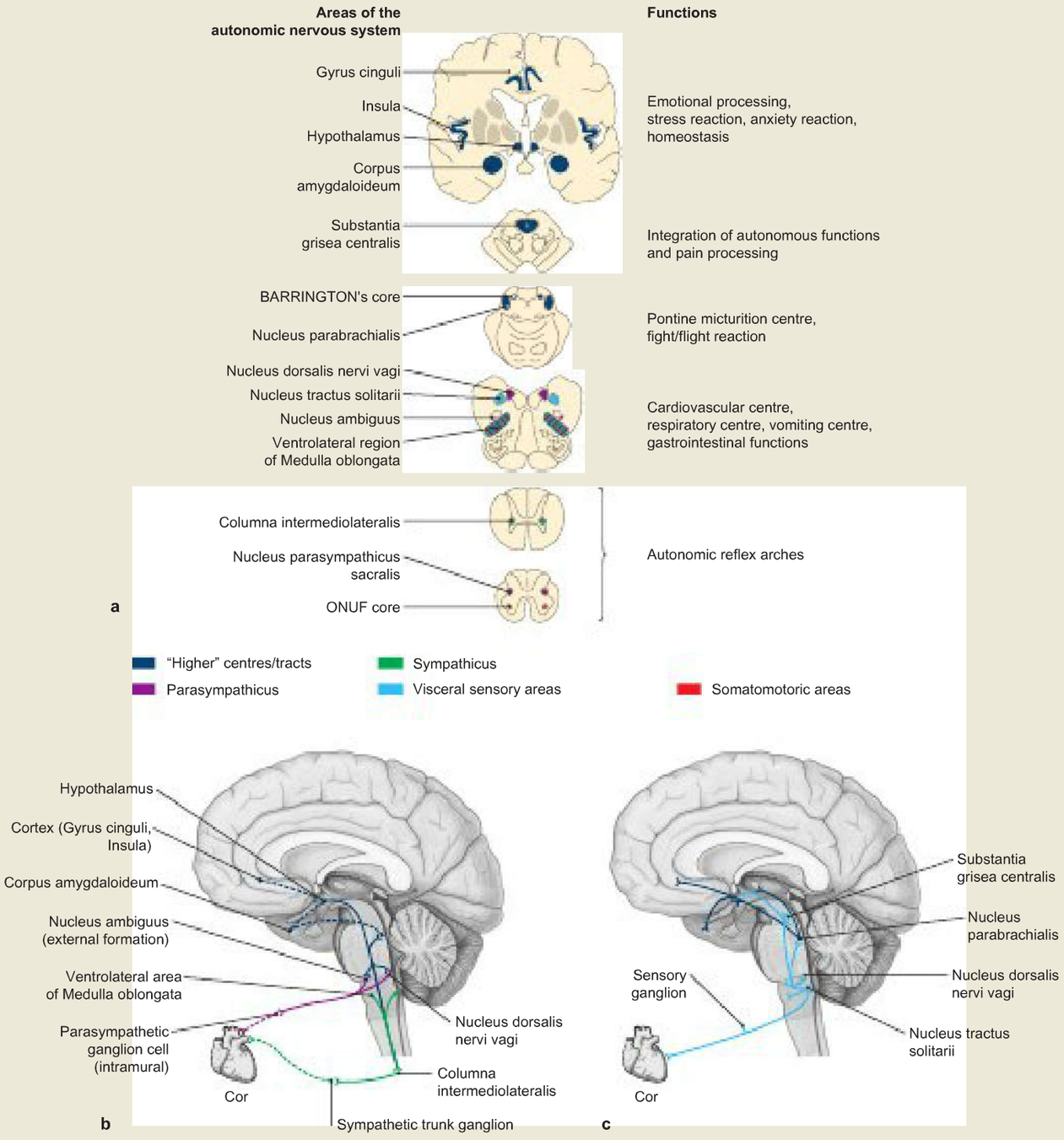

Fig. 12.218a to c Central autonomic brain regions and nuclear areas. [L127]
Nuclei and neuronal groups, which are involved in the central control of the autonomic nervous system and are closely interconnected, are located on different levels of the CNS.
a Autonomic nerve cells are located in the spinal cord, as well as in the brain stem, the diencephalon and the frontal lobe. Up to the level of the lower brain stem, it is possible to track the differences between sympathetic and parasympathetic neurons; but the two parts can no longer be clearly distinguished in the levels above.
b Example of the interaction between visceral motor neurons in the control of internal organs. Neurons in the hypothalamus, as the most significant autonomic relay station in the central nervous system, and neurons in the nuclear areas of the brain stem reach the autonomic centres in the Medulla oblongata or in the spinal cord directly with their axons or via an intermediary neuronal chain. From here, the preganglionic parasympathetic axons pass via the cranial nerves (N. vagus [X] is given in the example) to their target organs. Via descending fibres, the same centres can also influence sympathetic neurons in the lateral horn of the spinal cord. In this way, the autonomic nervous system is controlled in two directions.
c Example of visceral sensory afferent fibres/impulses to the central nuclear areas. Visceral sensory information is transmitted to the brain via the Nucleus tractus solitarii. In the Nucleus tractus solitarii, the fibres are switched and pass either directly to centres in the lower brain stem (autonomic reflex arches at the level of the brain stem) or via ascending neuronal chains to more centrally located regions of the brain.

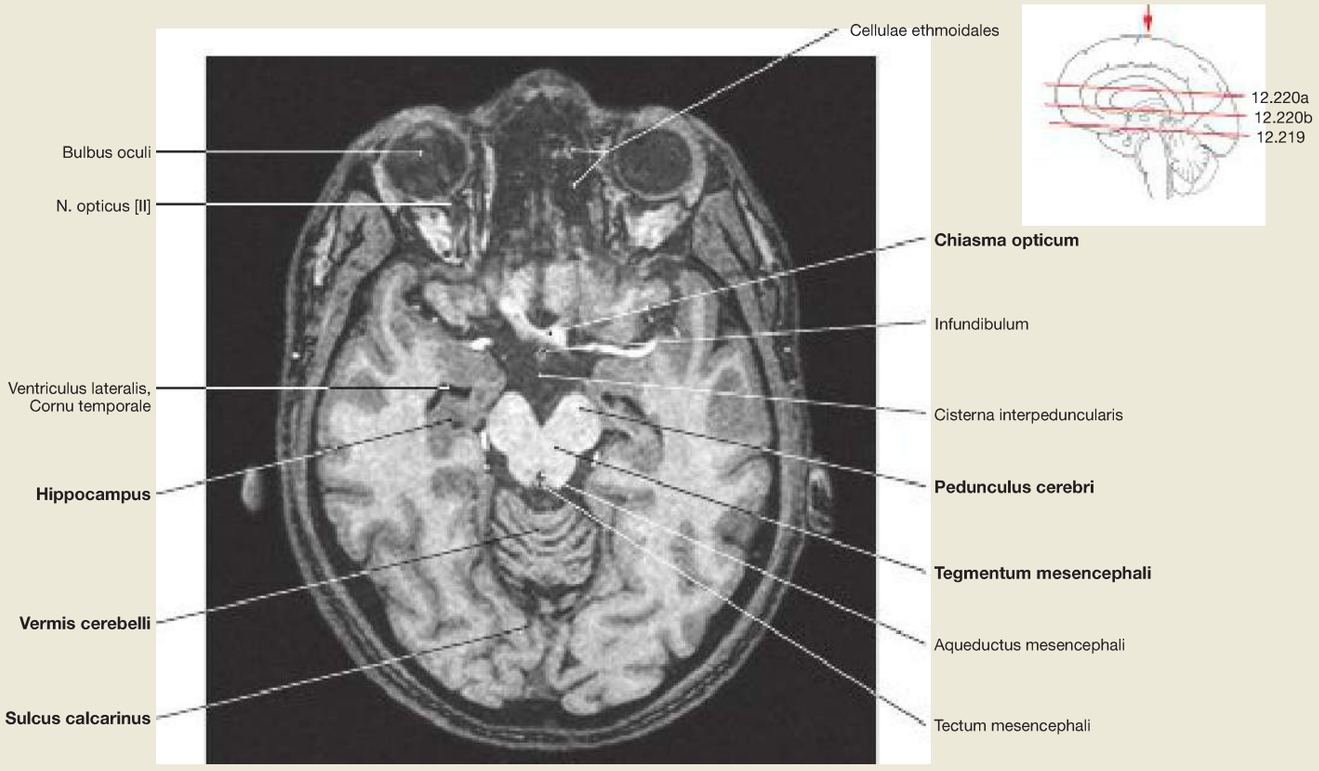

Fig. 12.219 Brain, Encephalon; magnetic resonance imaging (MRI) scan, horizontal section at the level of the mesencephalon and the temporal horns of the lateral ventricles; superior view. [T906]

The Chiasma opticum and Pedunculi cerebri of the mesencephalon are visible. The cerebellar vermis (Vermis cerebelli) also lies in this sectional plane. In the occipital lobe, the Sulcus calcarinus can be seen.

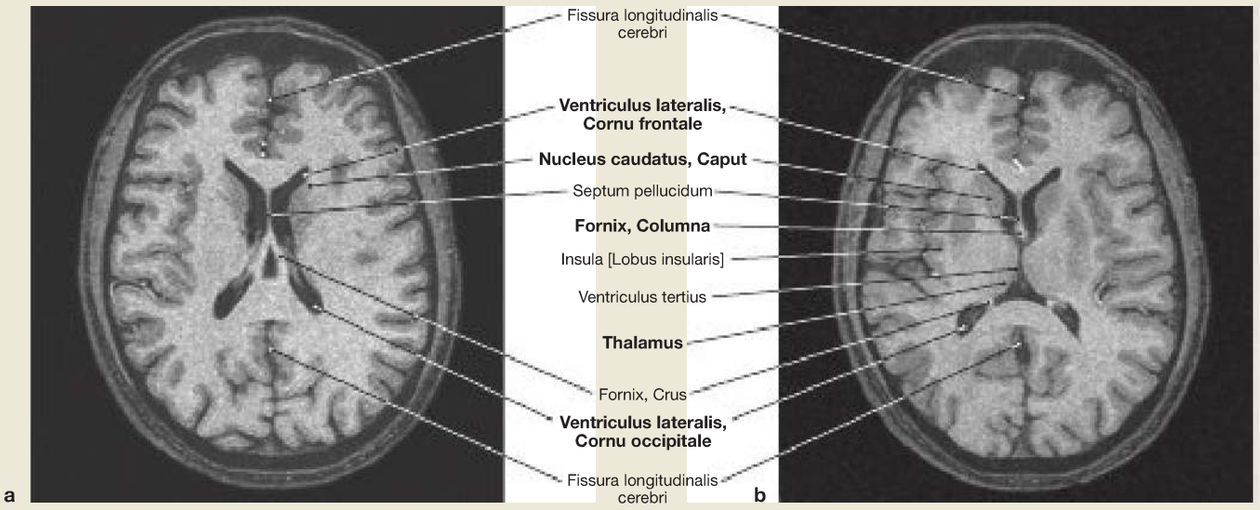

Fig. 12.220a and b Brain, Encephalon. [T906]
a Magnetic resonance imaging (MRI) scan, horizontal section at the level of the floor of the central parts of the lateral ventricles; superior view.
The Cornua frontale and occipitale, the Septum pellucidum and the Crus of Fornix are visible here. On the left side, the Lobus insularis can also be identified.

b Magnetic resonance imaging (MRI) scan, horizontal section at the level of the third ventricle and the temporal horns of the lateral ventricles; superior view.
In addition to the Lobi insulares and the structures mentioned in **a**, the thalamus and the Columna of the Fornix are visible.

Brain, MRI

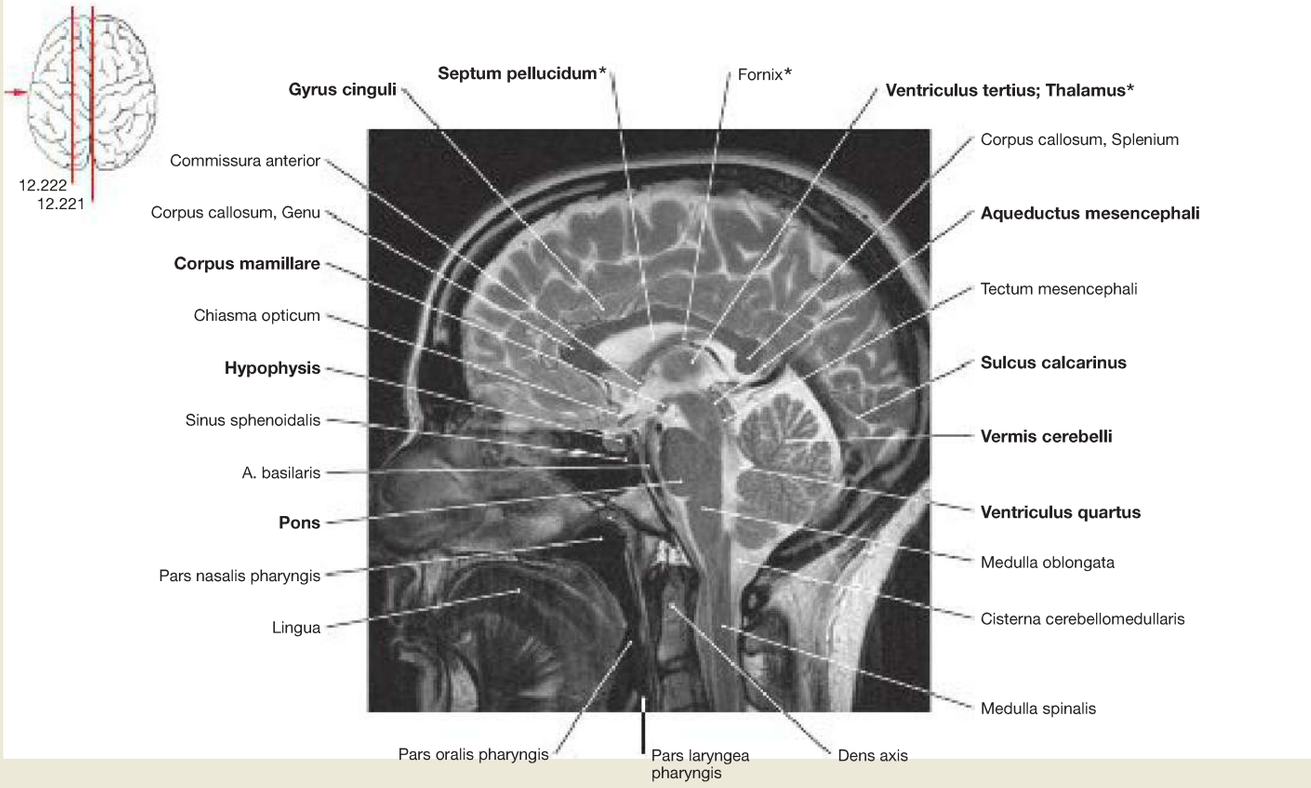

Fig. 12.221 Brain, Encephalon; magnetic resonance imaging (MRI) scan, median section.
This MRI scan shows the clearly delineated total of all brain structures, such as the Gyrus cinguli, Septum pellucidum, third ventricle, Thalamus, Aqueductus mesencephali, Corpus mamillare, Hypothalamus, Hypophysis (pituitary gland), Mesencephalon, Pons, Cerebellum, and Medulla oblongata.
The structures marked with a star (*) appear partly falsified due to the 'partial volume effect'.

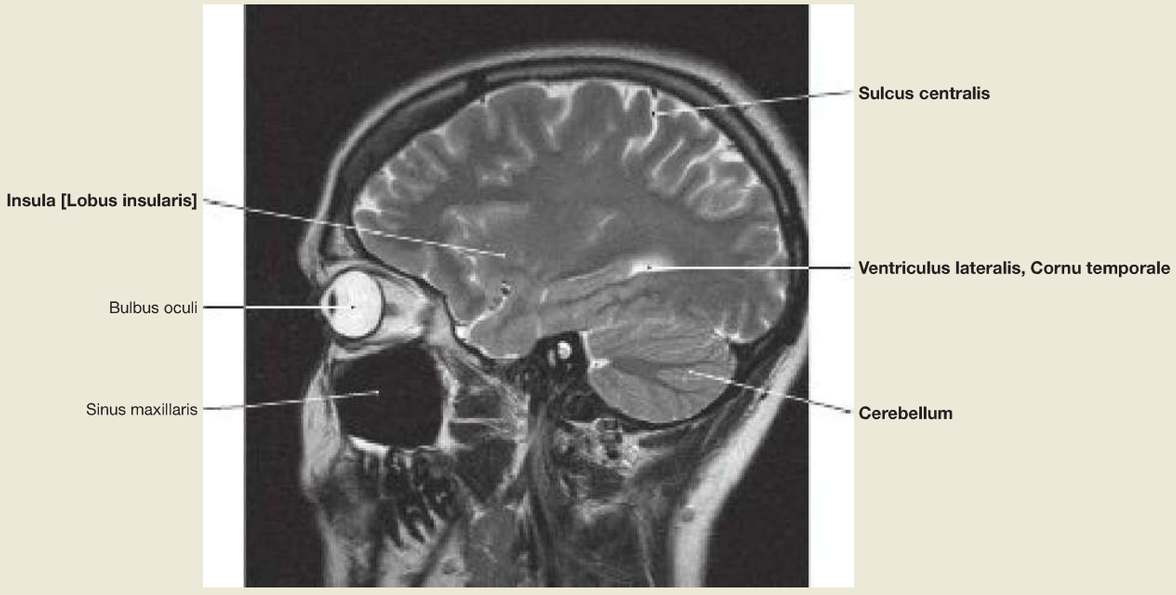

Fig. 12.222 Brain, Encephalon; magnetic resonance imaging (MRI) scan, sagittal section at the level of the mesencephalon and the temporal horns of the lateral ventricles; view from the left side.
The sagittal section displays the Cerebellum and the Sulcus centralis. Also a small part of the Cornu temporale of the lateral ventricle lies in this sectional plane.

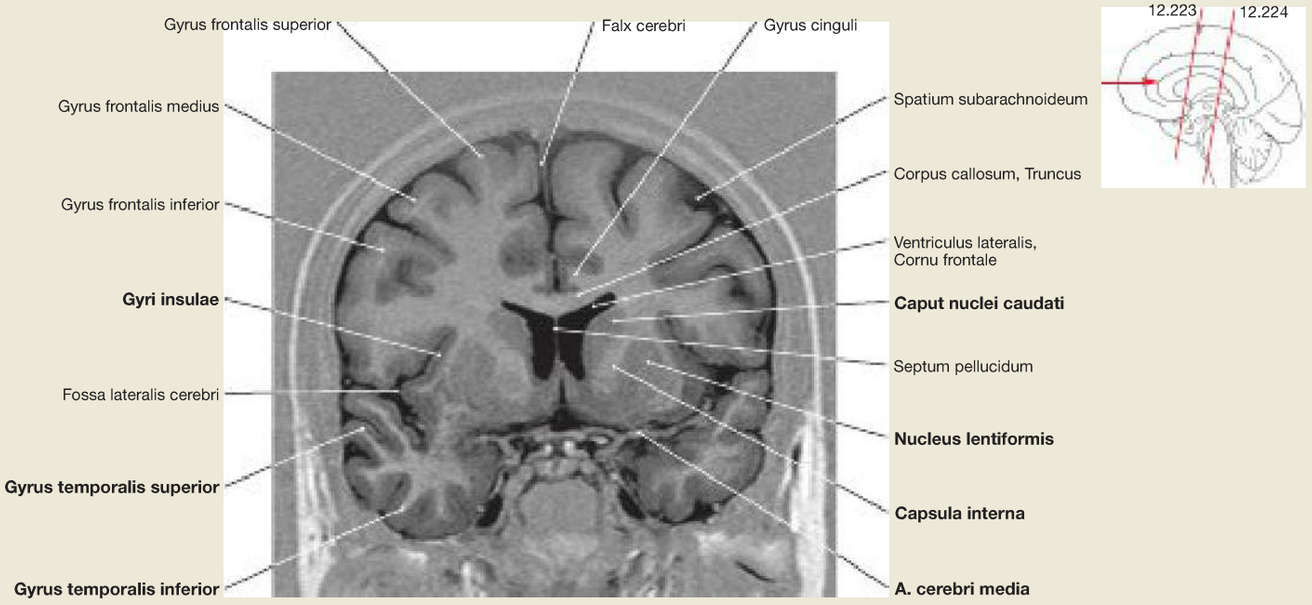

Fig. 12.223 Brain, Encephalon; magnetic resonance imaging (MRI) scan, frontal section at the level of the anterior part of the third ventricle; anterior view. [T906]
On the right side, the course of the A. cerebri media towards the Sulcus lateralis can be recognised. On both sides, the large gyri of the Lobus frontalis and Lobus temporalis are visible. With this imaging technique, the Nucleus caudatus, the Capsula interna and the Nucleus lentiformis can be distinguished in the region of the nuclei of the telencephalon.

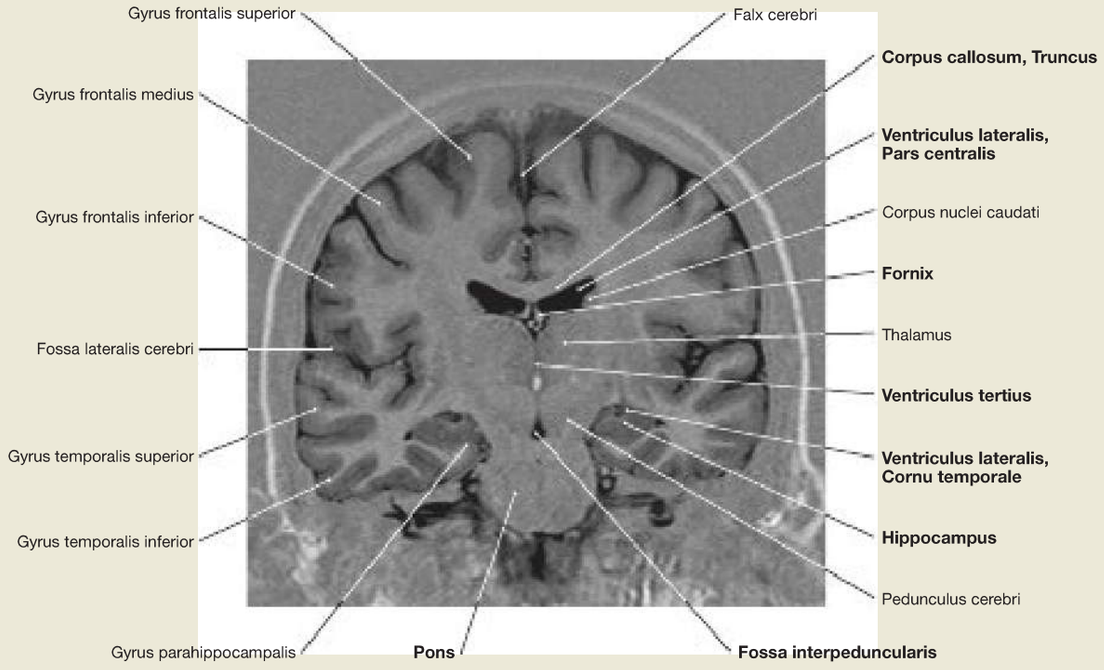

Fig. 12.224 Brain, Encephalon; magnetic resonance imaging (MRI) scan, frontal section at the level of the thalamus; anterior view. [T906]
This scan shows the Cornu temporale of the lateral ventricles and the Hippocampus. Further cranial, the Pars centralis of the lateral ventricles is cut. In the midline from cranial to caudal, the Truncus corporis callosi, the Fornix, the third ventricle, the Fossa interpeduncularis of the brain stem and the Pons can be distinguished.

Brain, Frontal Sections

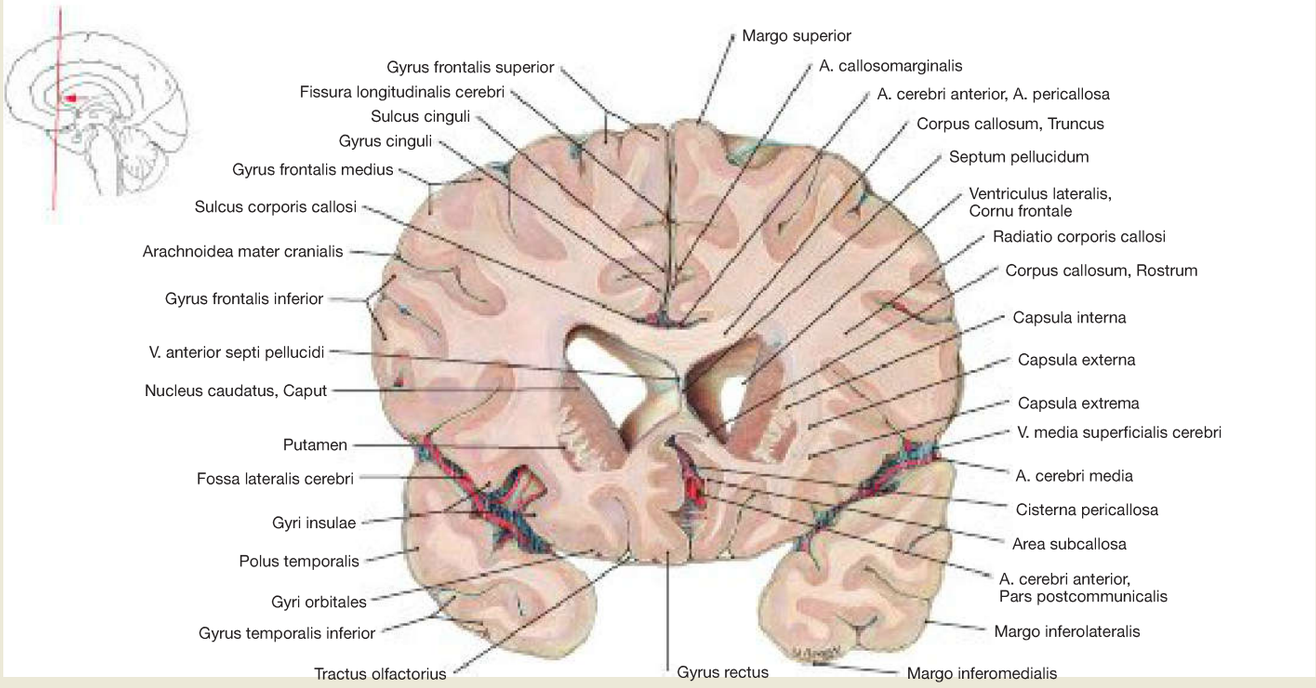

Fig. 12.225 Brain, Encephalon; frontal section at the level of the anterior parts of the frontal horns of the Ventriculi laterales; posterior view.

The two Ventriculi laterales are visible and the Corpus callosum above them, and the Caput of the Nucleus caudatus and the Putamen, which are located laterally of the Ventriculi laterales.

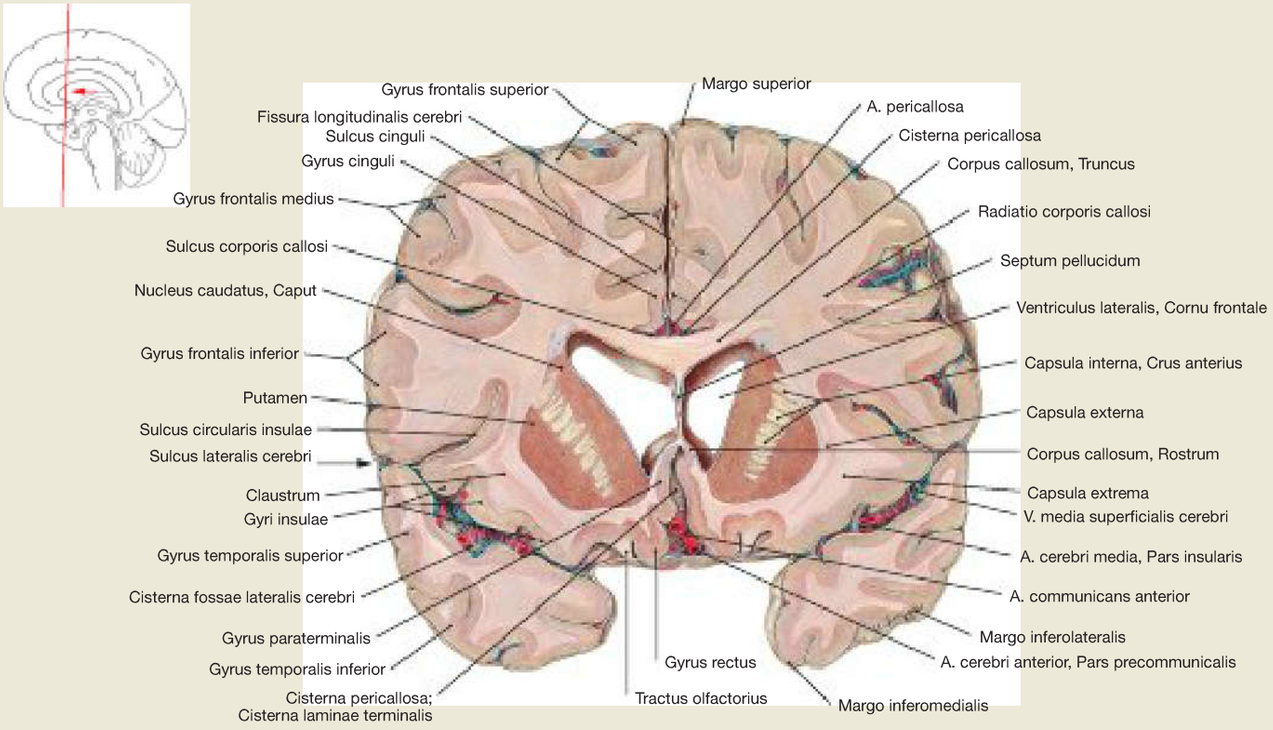

Fig. 12.226 Brain, Encephalon; frontal section at the level of the posterior parts of the frontal horns of the Ventriculi laterales; posterior view.

The truncus of the Corpus callosum can be seen above the Ventriculi laterales, whereas the Caput of the Nucleus caudatus, the Putamen and the Crus anterius of the Capsula interna in between are visible laterally of the Ventriculi laterales.

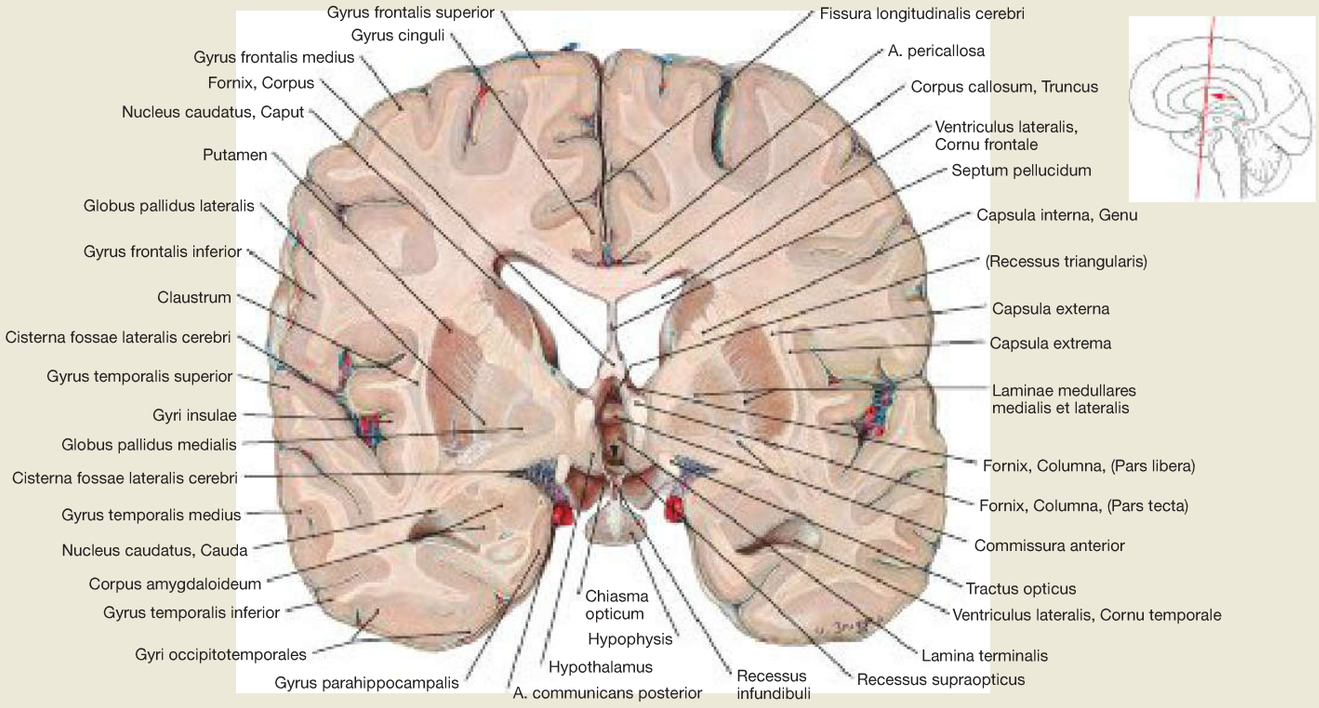

Fig. 12.227 Brain, Encephalon; frontal section at the level of the Foramina interventricularia; posterior view.

The sectional plane cuts directly through the pituitary gland. Below the Ventriculi laterales, the Caput of the Nucleus caudatus, the Capsula interna, the Globus pallidus, the Putamen, the Claustrum and several Gyri insulae are visible.

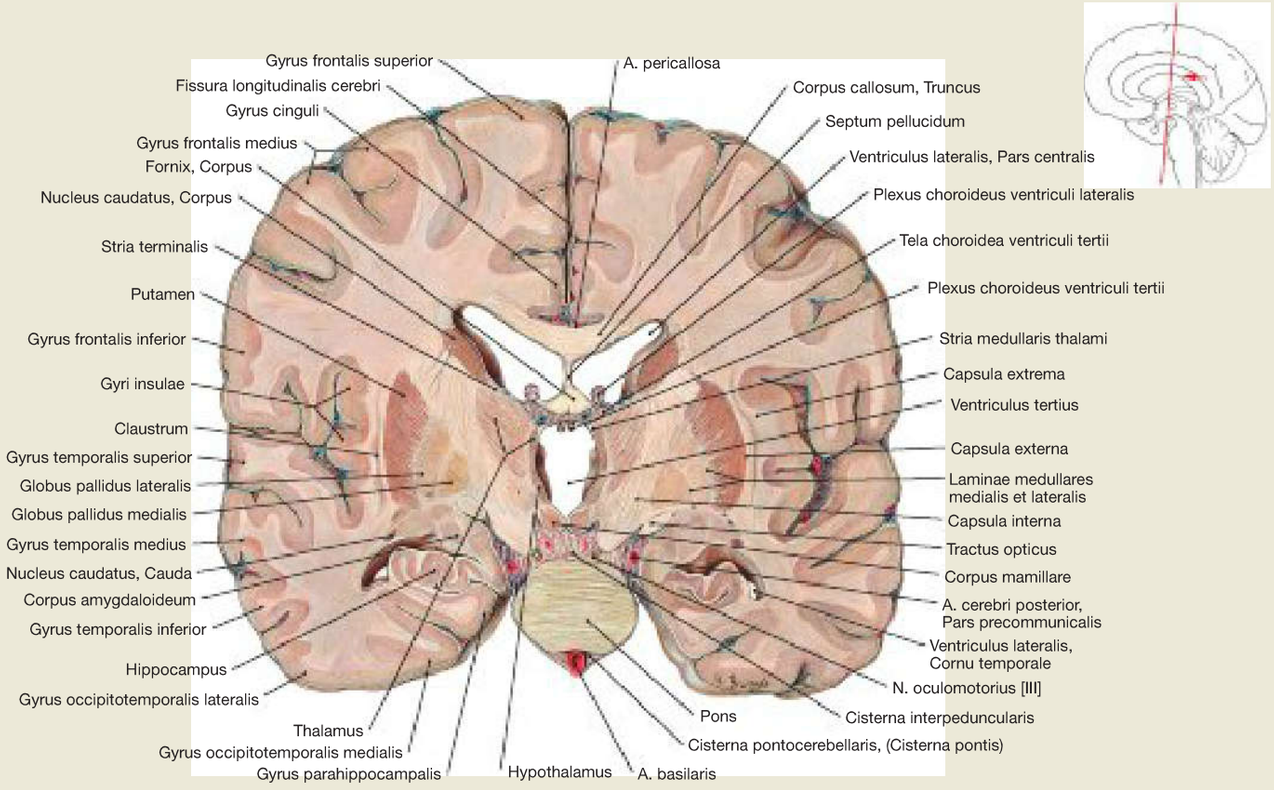

Fig. 12.228 Brain, Encephalon; frontal section at the level of the Corpora mamillaria; posterior view.

At the level of the Corpora mamillaria, the lumen of the Ventriculus tertius is visible below the Ventriculi laterales. Lateral thereof from inside to outside lie the Thalamus, Capsula interna, Globus pallidus, Putamen, Capsula externa, Claustrum, Capsula extrema and Gyri insulae.

Brain, Frontal Sections

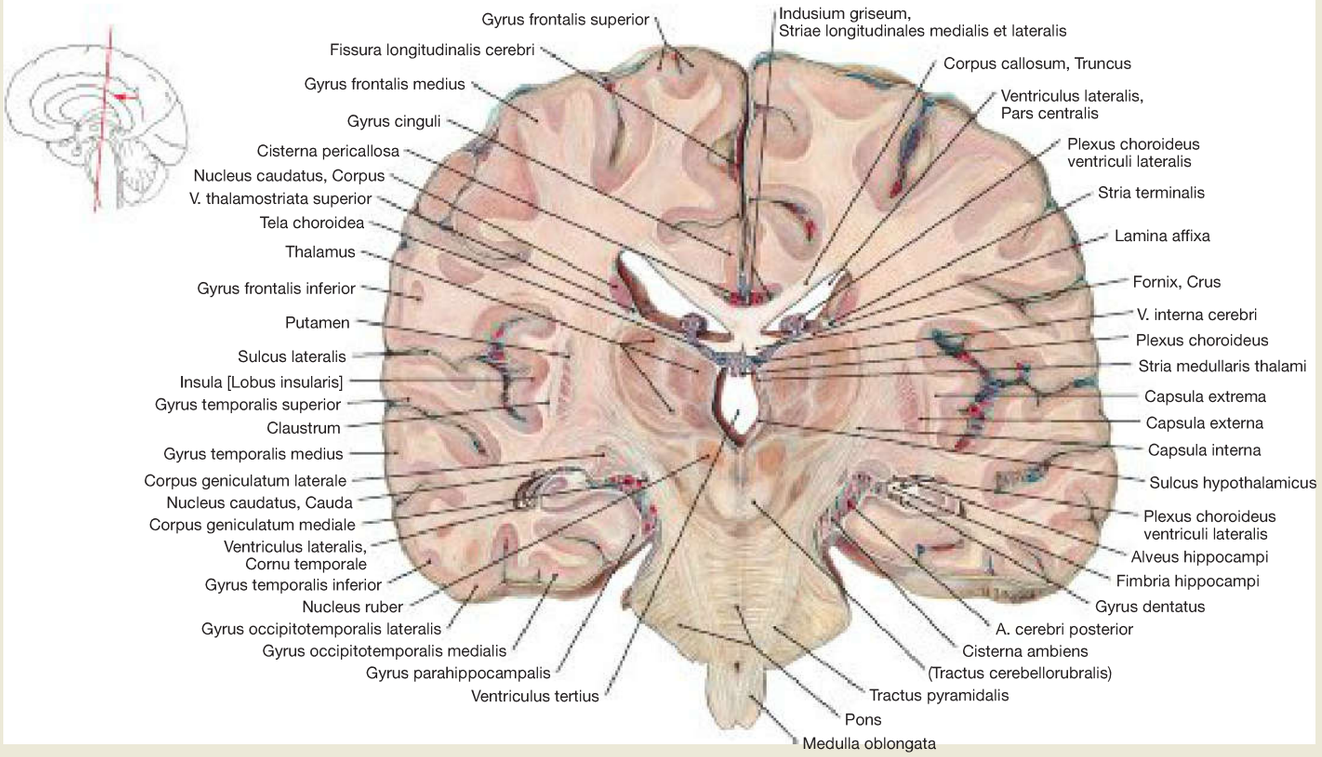

Fig. 12.229 Brain, Encephalon; frontal section through the centre of the third ventricle; posterior view.

At this level, the left and right thalami are often cross-connected by the Adhesio interthalamica. Below the thalamus, the Nucleus ruber is clearly discernible. In the brain stem, the Tractus pyramidalis appears as a prominent structure of the pons.

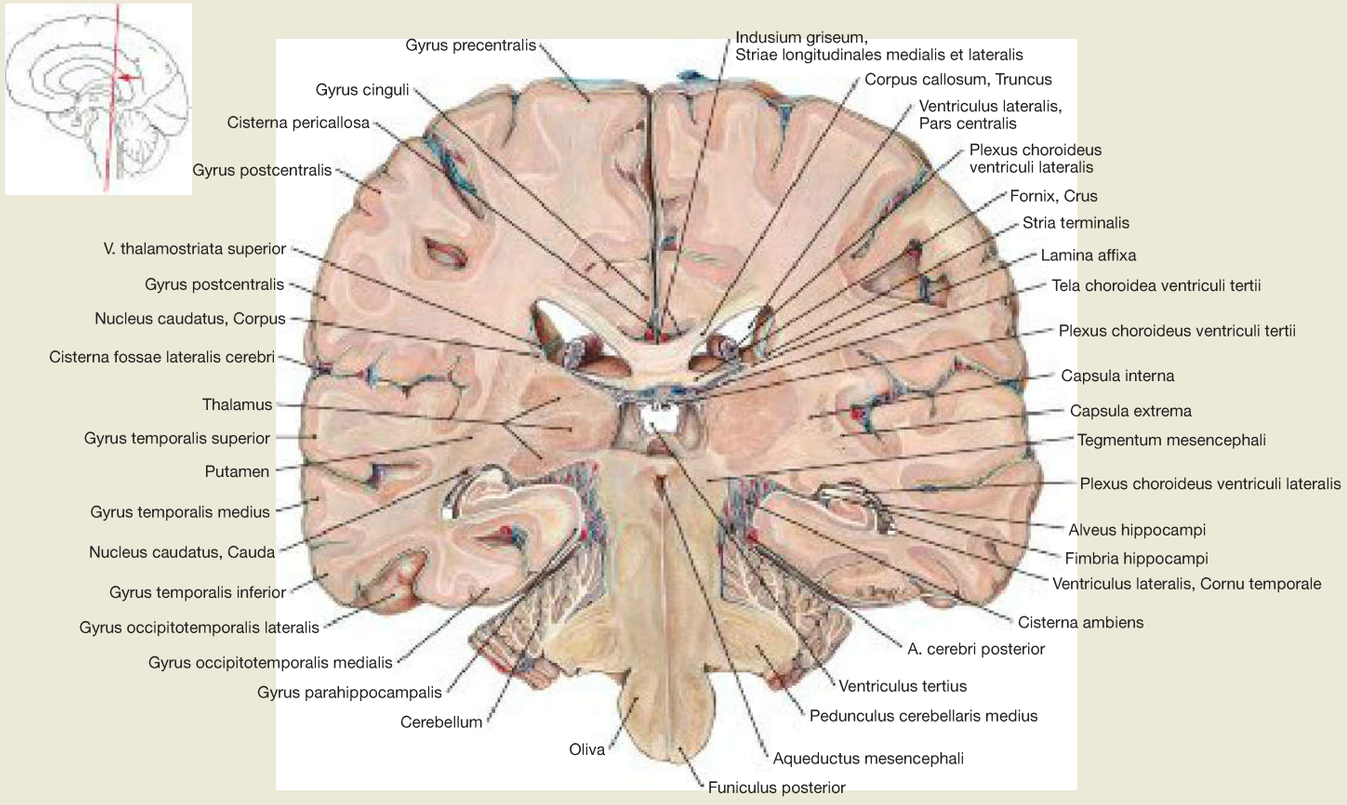

Fig. 12.230 Brain, Encephalon; frontal section at the level of the posterior wall of the third ventricle; posterior view.

Inferior to the Ventriculi laterales, a number of thalamic nuclei can be recognised, and further caudally the occipital part of the hippocampus is visible. In this sectional plane, the brain stem is cut at the level of the Aqueductus mesencephali.

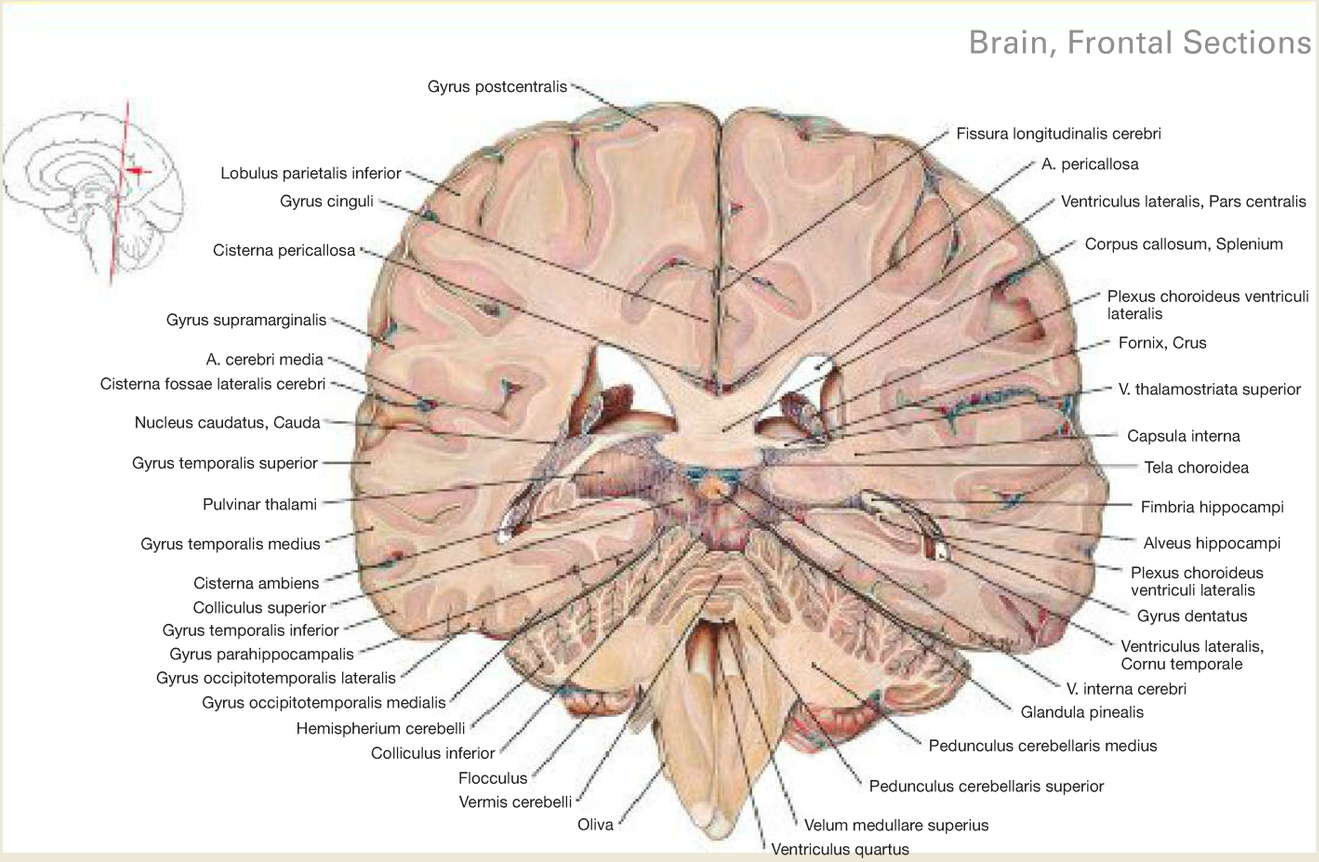

Fig. 12.231 Brain, Encephalon; frontal section at the level of the pineal gland and of the fourth ventricle; posterior view.

The Splenium of the Corpus callosum and the Glandula pinealis are displayed in the centre of the image, with the laterally located Colliculi superiores and the Pulvinar thalami. Laterally and slightly above the Ventriculus quartus, the Pedunculi cerebellares superiores are visible in the brain stem.

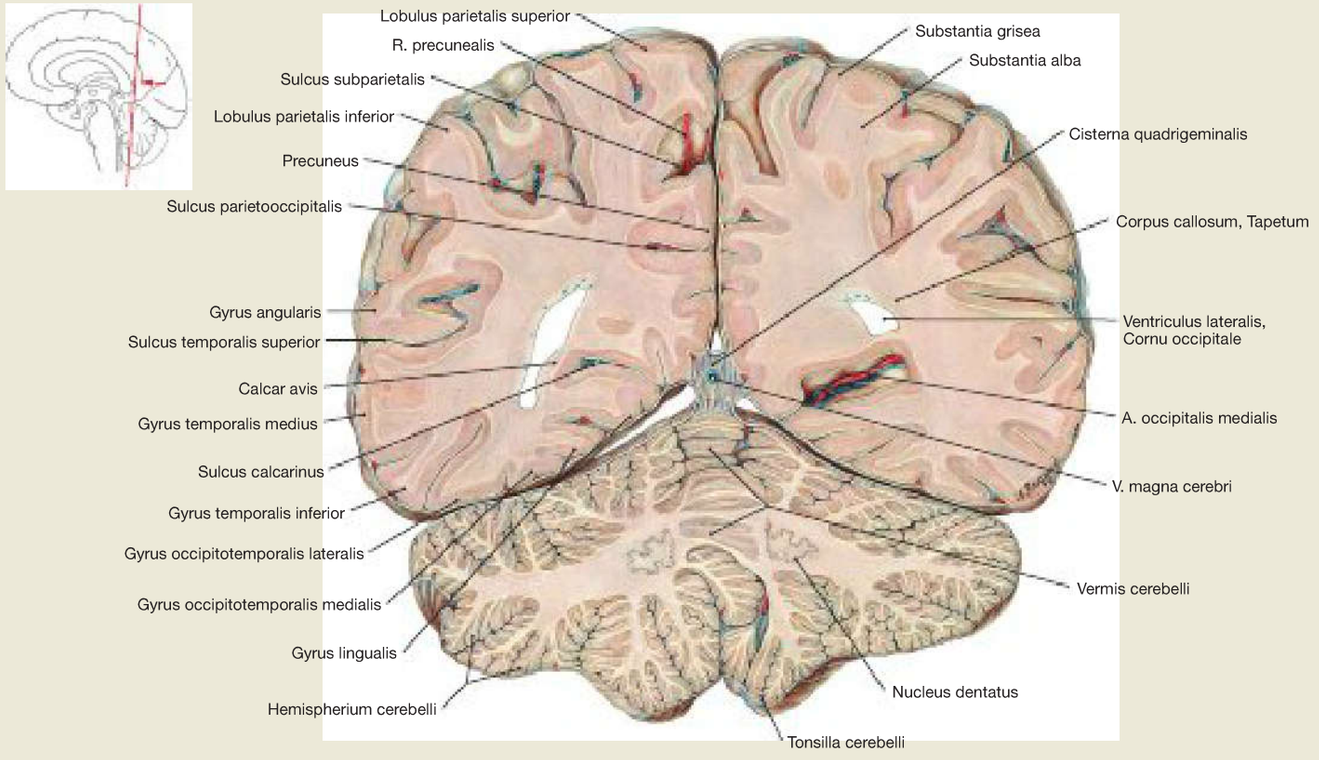

Fig. 12.232 Brain, Encephalon; frontal section at the level of the posterior horns of the Ventriculi laterales; posterior view.

The Nucleus dentatus and large parts of the Vermis cerebelli are visible in the cerebellum.

Brain, Horizontal Sections

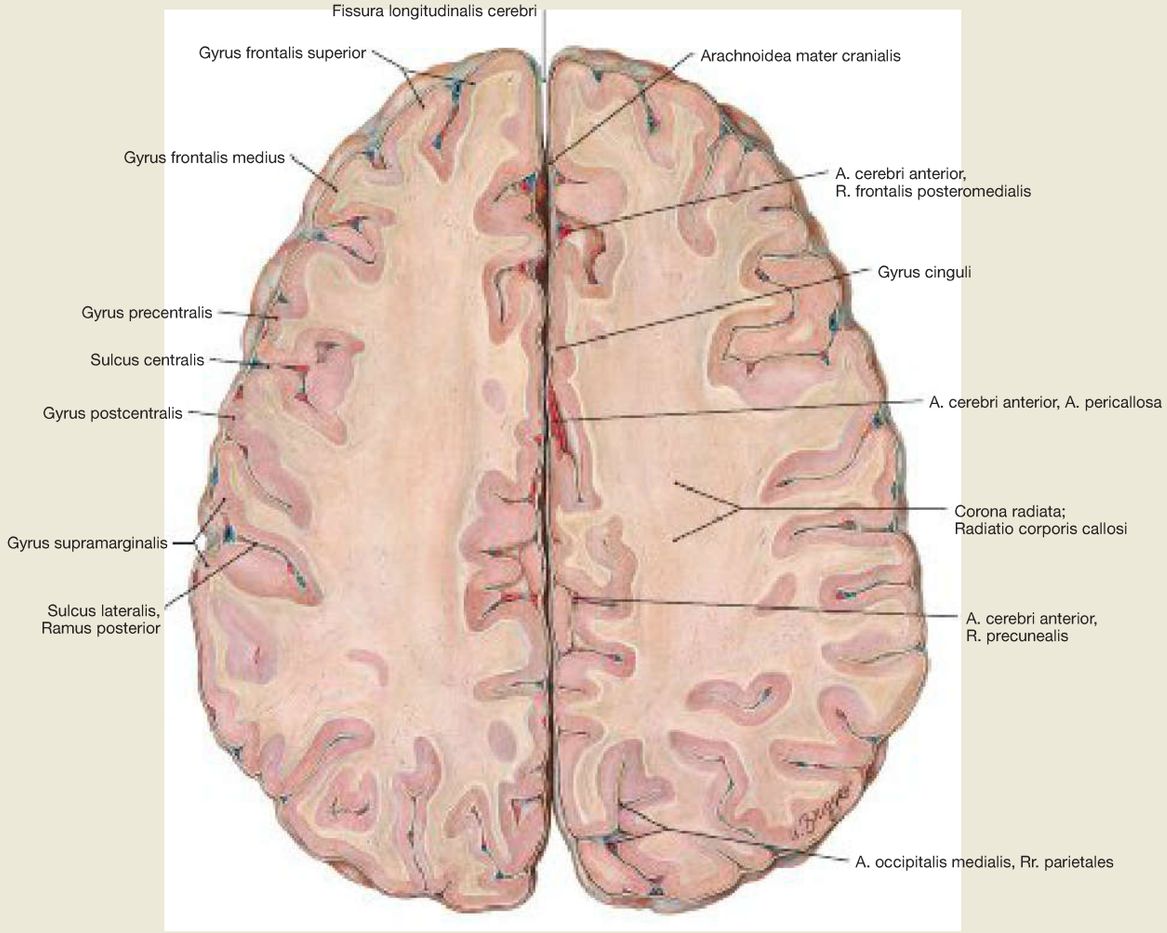

Fig. 12.233 Brain, Encephalon; horizontal section just above the Corpus callosum; superior view.
The sectional plane lies directly above the Corpus callosum. At this level, the nuclei are not yet visible. In the broad band of white matter, fibre tracts projecting from the thalamus to the cortex (Corona radiata) mix with commissural fibres of the Corpus callosum, connecting the two hemispheres (Radiatio corporis callosi). In addition, there are tracts converging downwards onto the Capsula interna (not shown here; → Fig. 12.31 and → Fig. 12.32). Due to the age-related atrophy of the brain, the subarachnoid space appears enlarged or wider (→ Fig. 12.234 to → Fig. 12.243).

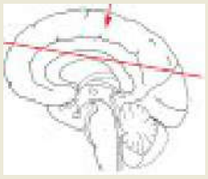

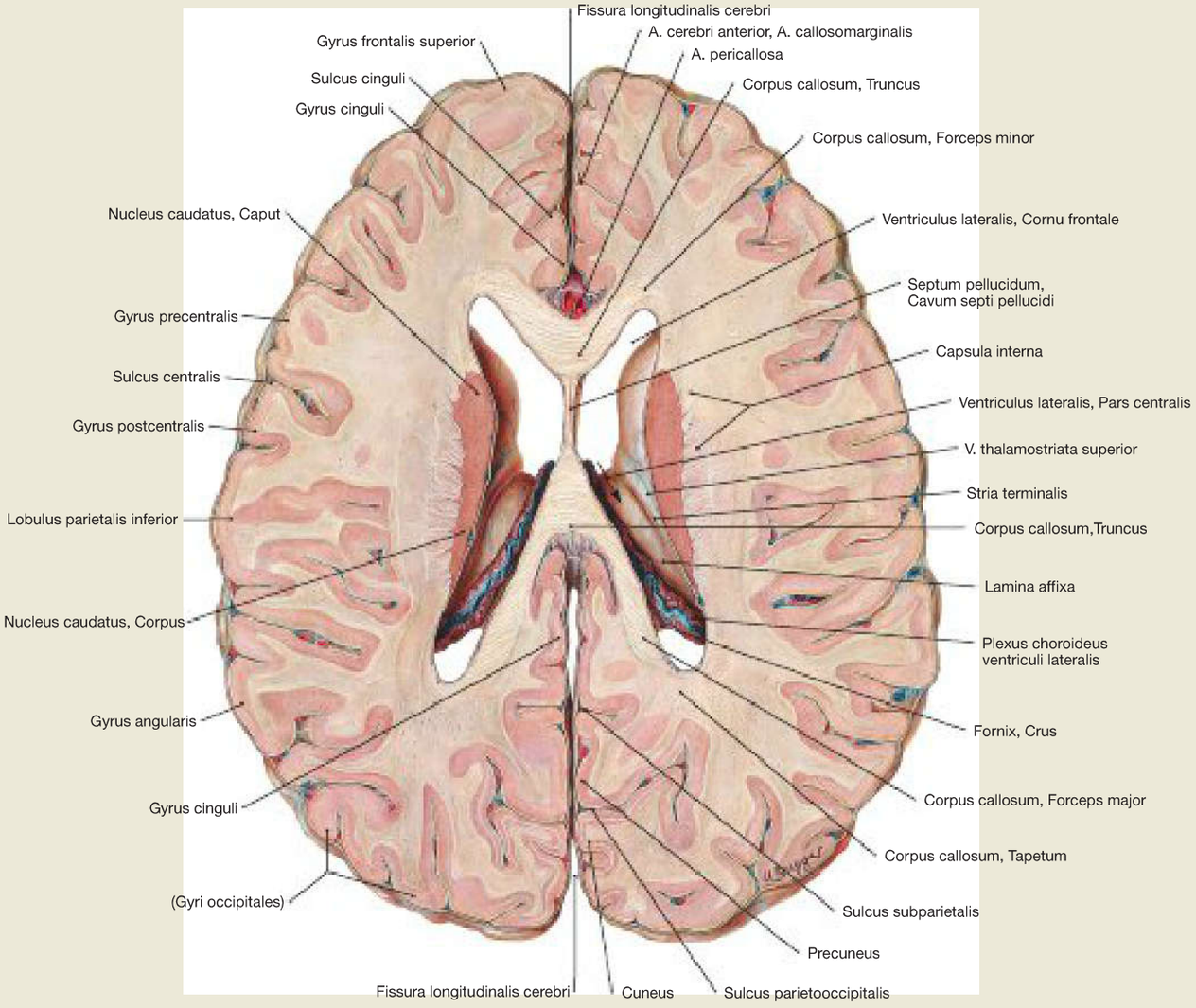

Fig. 12.234 Brain, Encephalon; horizontal section at the level of the central part of the Ventriculi laterales; superior view.
The Septum pellucidum extends between the body and fornix (not visible here) of the Corpus callosum and separates the Ventriculi laterales. The Caput and Corpus of the Nucleus caudatus are sectioned laterally of the Ventriculi laterales in this plane, and the Capsula interna is located even further laterally.

Brain, Horizontal Sections

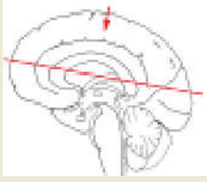

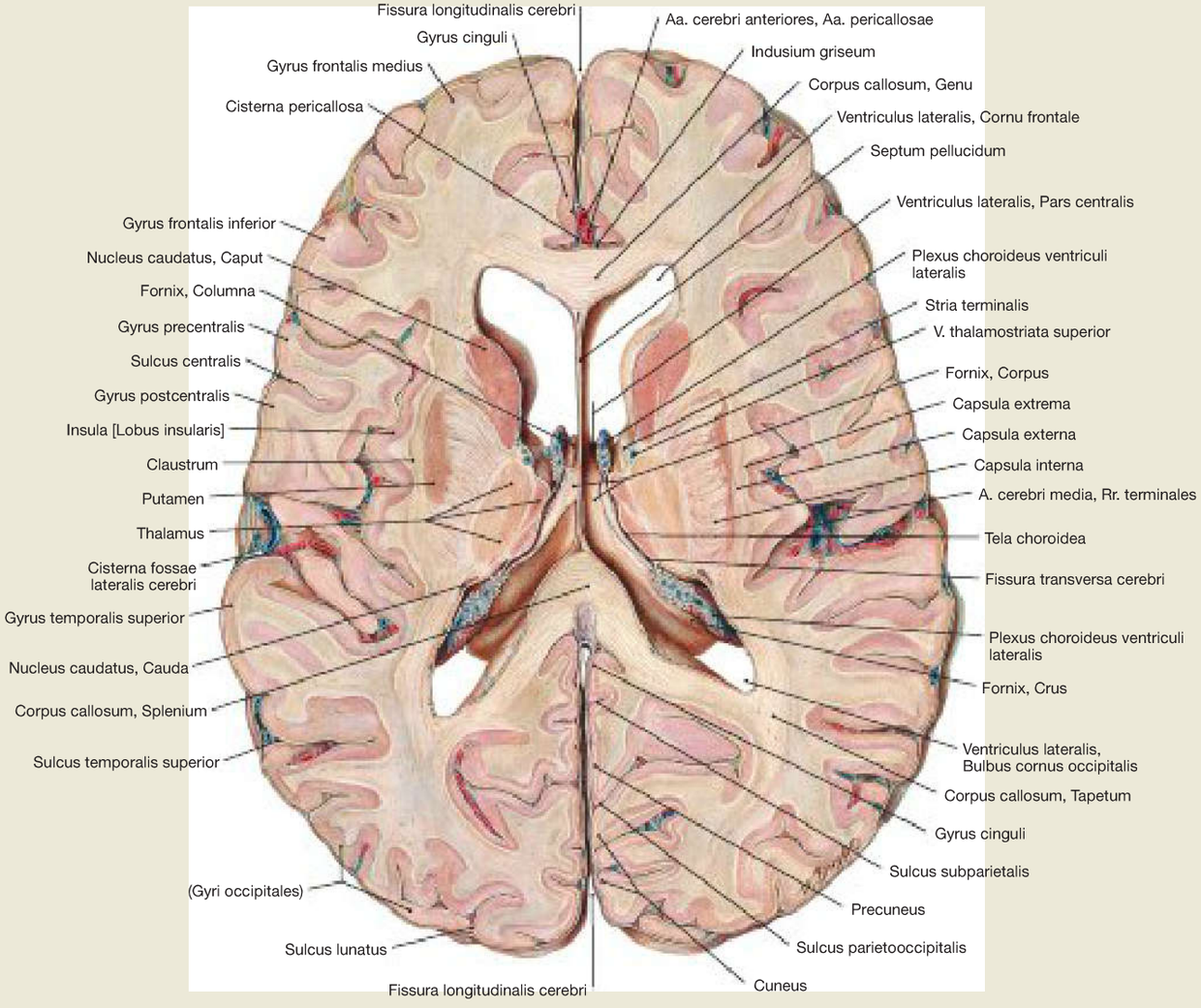

Fig. 12.235 Brain, Encephalon; horizontal section at the level of the floor of the central part of the Ventriculi laterales; superior view.
This central section shows parts of the thalamus cut laterally of the Ventriculi laterales. Anterior and posterior to the thalamus, the Caput and Cauda of the Nucleus caudatus are visible. Lateral to the thalamus, the Capsula interna, Putamen, Capsula externa, Claustrum, Capsula extrema and Gyri insulae are arranged medial to lateral. The genu of the Corpus callosum locates to the anterior midline, and the splenium is visible in the posterior midline.

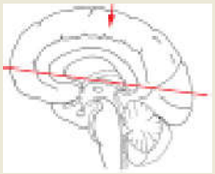

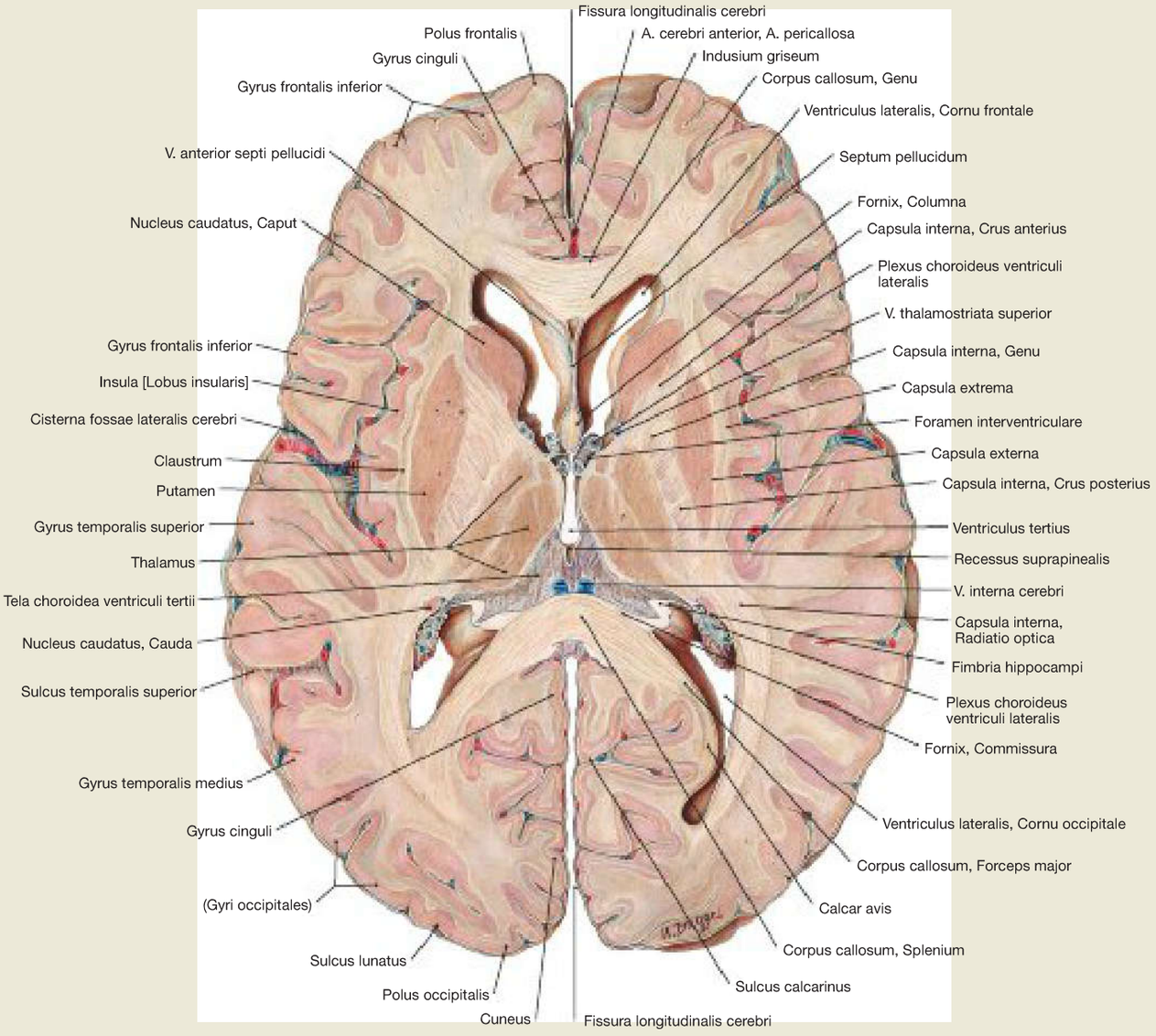

Fig. 12.236 Brain, Encephalon; horizontal section at the level of the upper part of the Ventriculus tertius; superior view.
The Ventriculus tertius lies in the central part of the image, and the Ventriculi laterales, as well as the genu and Splenium of the Corpus callosum are visible anterior and posterior of the Ventriculus tertius. Caput and Cauda of the Nucleus caudatus, Thalamus, Putamen, and Claustrum constitute the cerebral nuclei. The Capsula interna with its characteristic genu is located between the large nuclei. In addition, the Radiatio optica of the Capsula interna can be seen.

Brain, Horizontal Sections

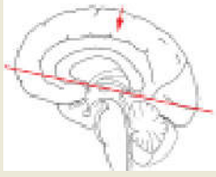

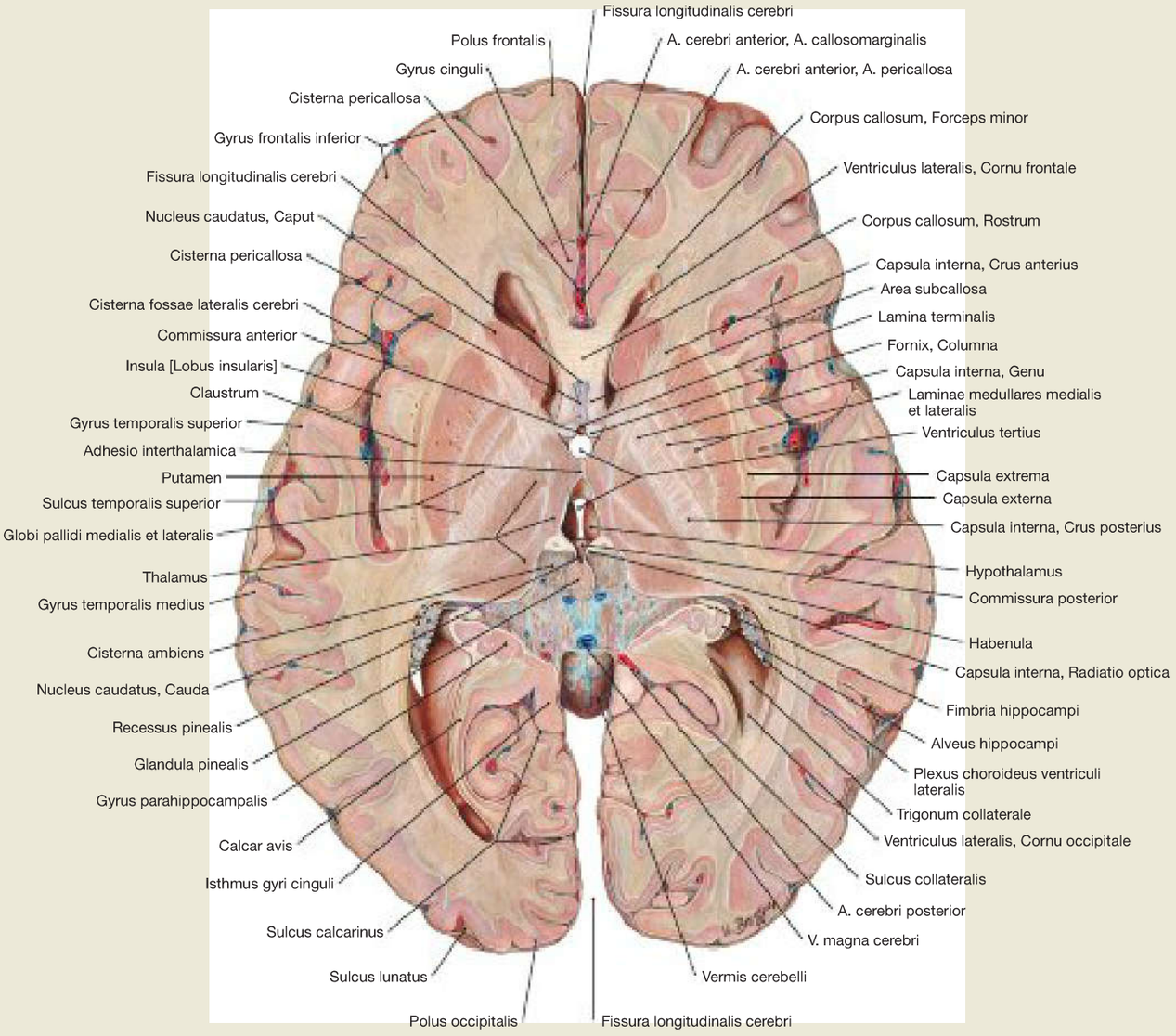

Fig. 12.237 Brain, Encephalon; horizontal section through the centre of the Ventriculus tertius at the level of the Adhesio interthalamica; superior view.

The sectional plane cuts directly through the Glandula pinealis and the Adhesio interthalamica. Lateral thereof lie the Thalamus, Capsula interna, Globus pallidus, Putamen, Capsula externa, Claustrum, Capsula extrema and Lobus insularis. The Fimbria hippocampi, the Alveus hippocampi and the Gyrus parahippocampalis are also discernible.

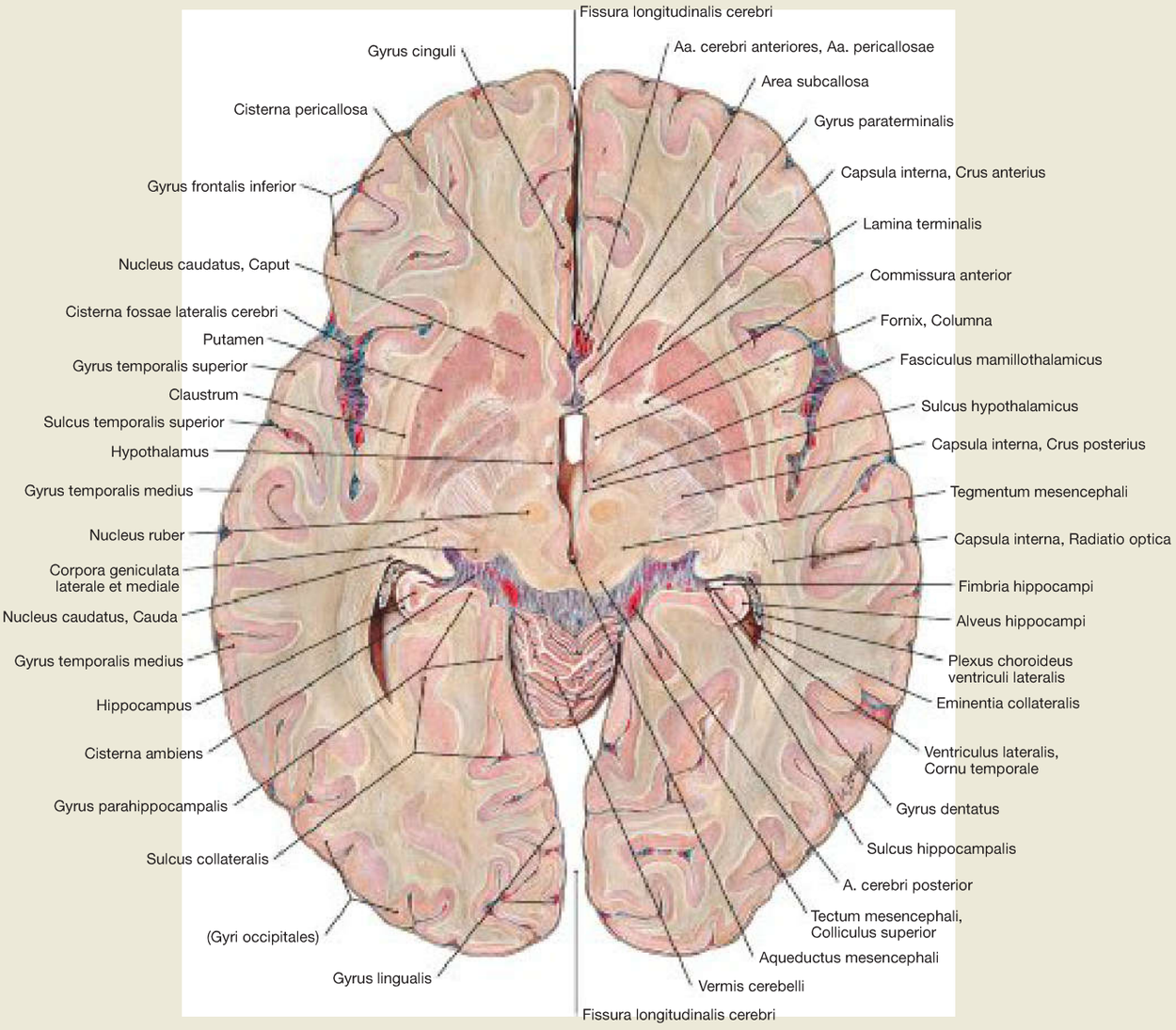

Fig. 12.238 Brain, Encephalon; horizontal section through the Ventriculus tertius, at the level of the opening of the Aqueductus mesencephali; superior view.
Due to its reddish colour, the Nucleus ruber is a prominent structure in the sectional plane. The close relationship of the Nucleus caudatus and Putamen also becomes obvious. The Crus anterius of the Capsula interna runs between the two structures. The sectional plane is located at the level of the transition from the Ventriculus tertius to the Aqueductus mesencephali. Both structures are displayed. The upper rim of the Vermis cerebelli is also visible in this sectional plane.

Brain, Horizontal Sections

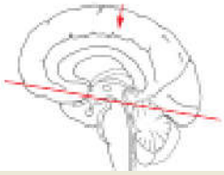

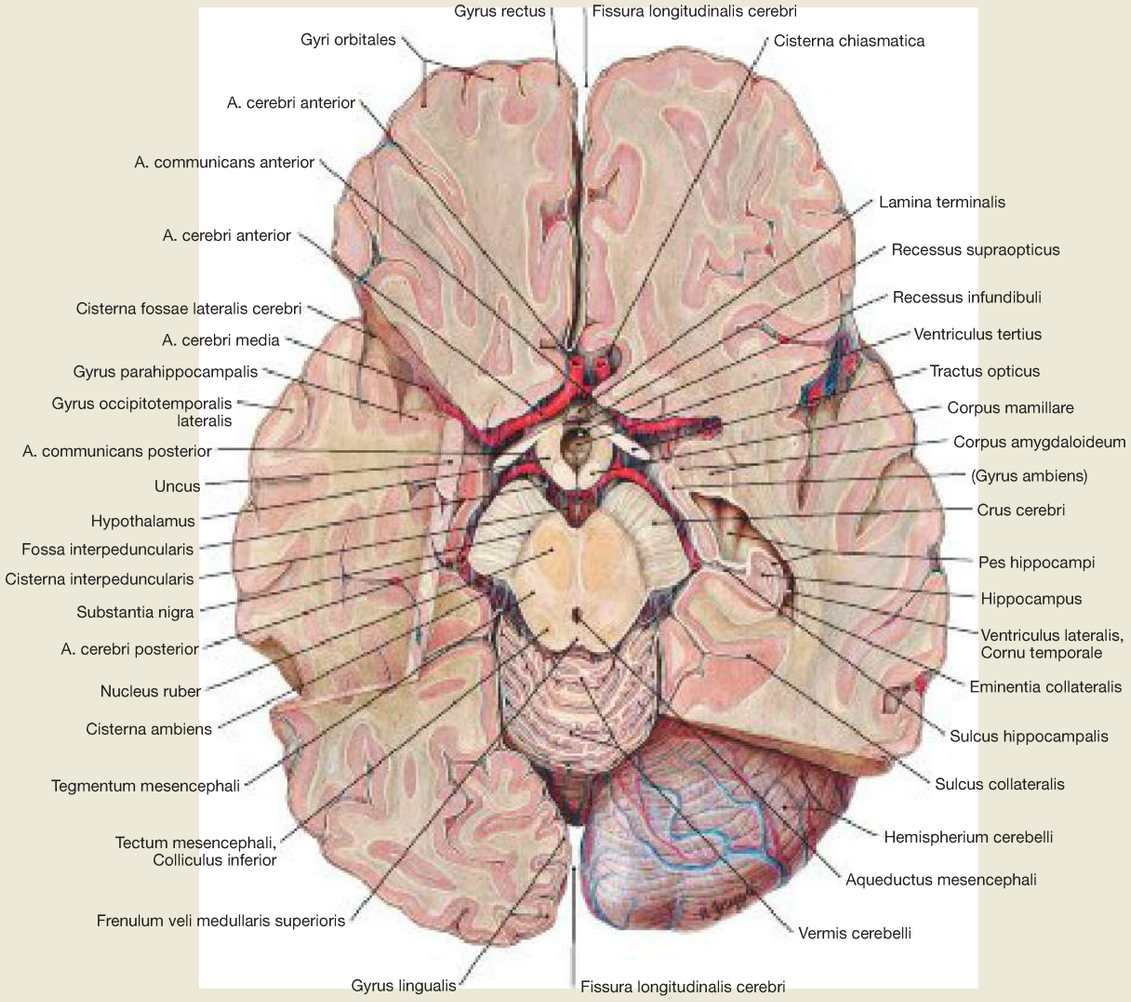

Fig. 12.239 Brain, Encephalon; staggered horizontal section through the floor of the Ventriculus tertius at the level of the Corpora mamillaria; superior view.
The sectional plane is laid through the Tractus optici, the Hypothalami, the Corpora mamillaria, the Crura cerebri, the Nuclei rubri and the Colliculi inferiores of the Tectum mesencephali. On the right side, the hippocampus is visible, on the left side sectioned parts of the grey and white matter of the temporal and occipital lobes are shown. After removal of the occipital pole on the right side, the Hemispherium cerebelli is freely exposed.

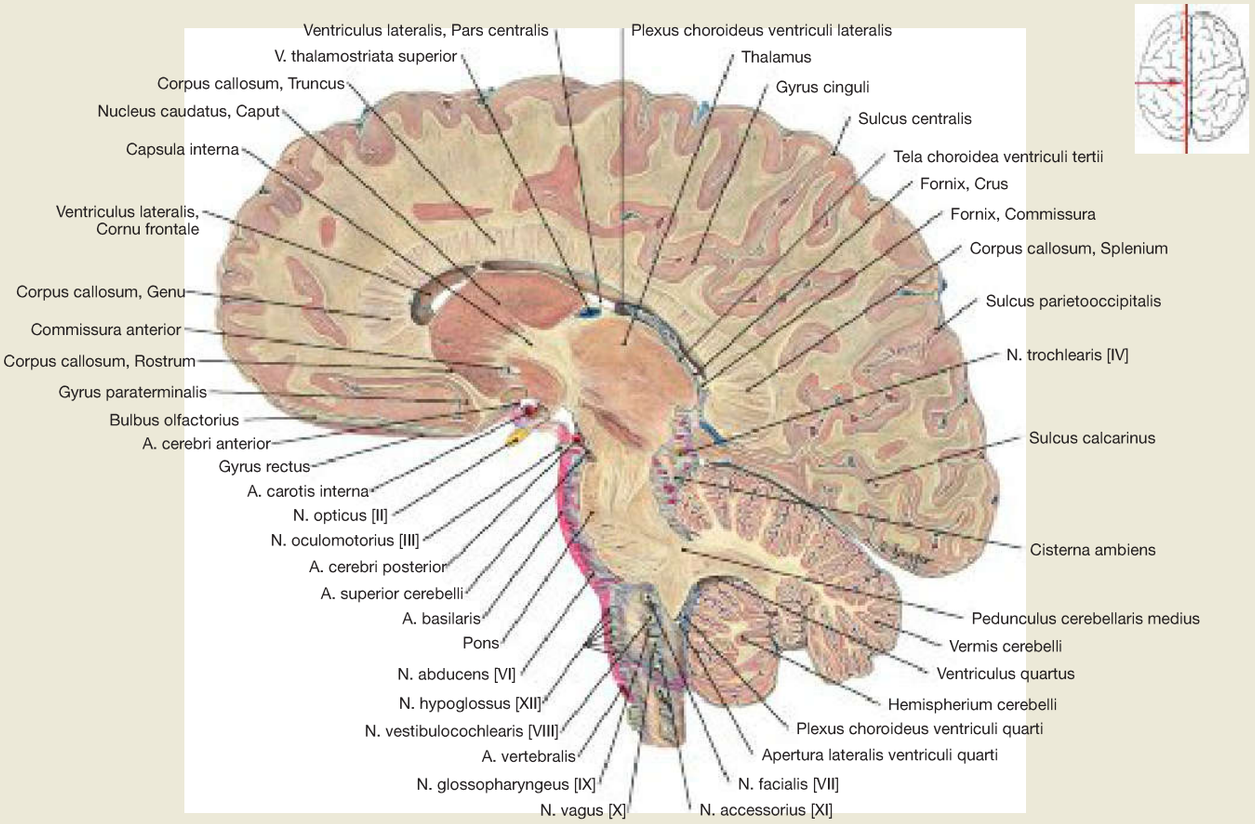

Fig. 12.240 Brain, Encephalon; sagittal section through the left hemisphere at the level of the Caput of the Nucleus caudatus; view from the left side.
The paramedian section shows the entire rostro-occipital dimension of the Corpus callosum. The Ventriculus lateralis is located beneath it, and further below, the Nucleus caudatus, Thalamus, Capsula interna and N. opticus [II] follow. The A. basilaris runs in front of the brain stem. The Pedunculus cerebellaris medius marks the transition from the pons to the cerebellum.

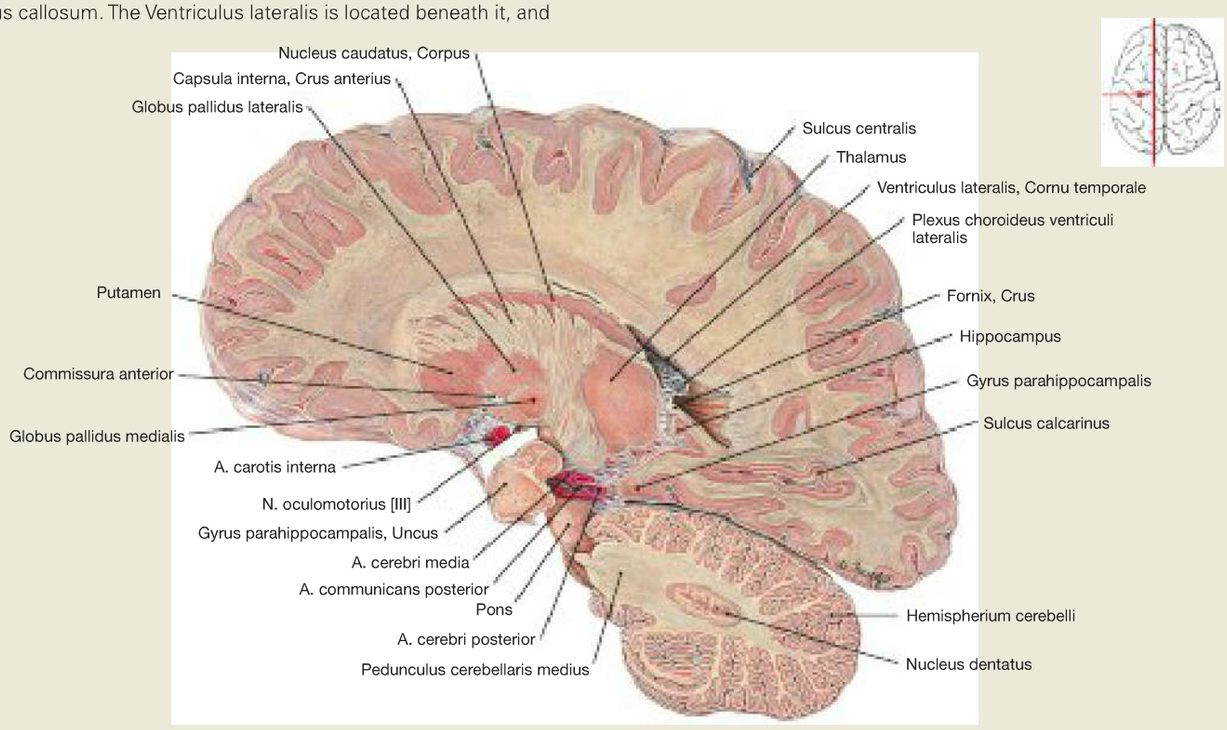

Fig. 12.241 Brain, Encephalon; sagittal section through the left hemisphere at the level of the Corpus of the Nucleus caudatus; view from the left side.

Apart from the Corpus of the Nucleus caudatus, the Crus anterius of the Capsula interna, the Thalamus, the Putamen, the Globus pallidus and the Uncus of the Gyrus parahippocampalis are sectioned in this plane. In the cerebellum, the sectional plane cuts the Nucleus dentatus.

Sections

Brain, Sagittal Sections

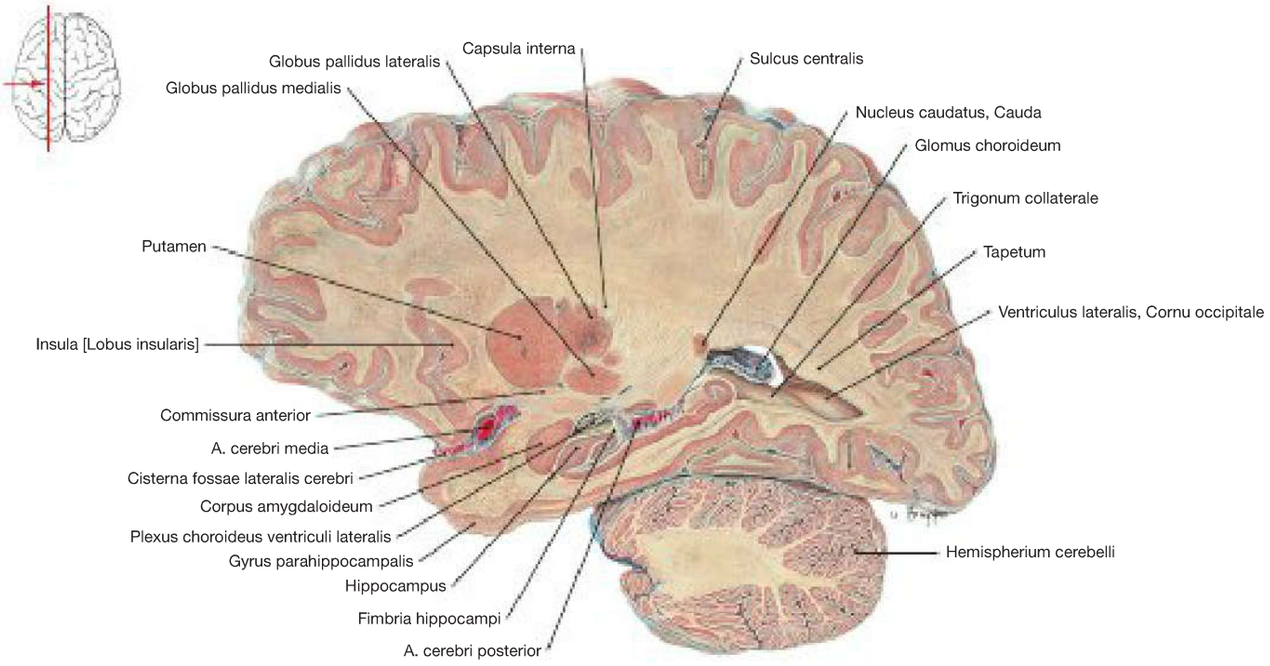

Fig. 12.242 Brain, Encephalon; sagittal section through the left hemisphere at the level of the Corpus amygdaloideum; view from the left side.
In this section, the Hippocampus, the Fimbria hippocampi, and the Cauda of the Nucleus caudatus are located behind the Corpus amygdaloideum. In addition, the Putamen, the Globus pallidus, and the Capsula interna are visible. The inferior part of this section shows the Hemispherium cerebelli.

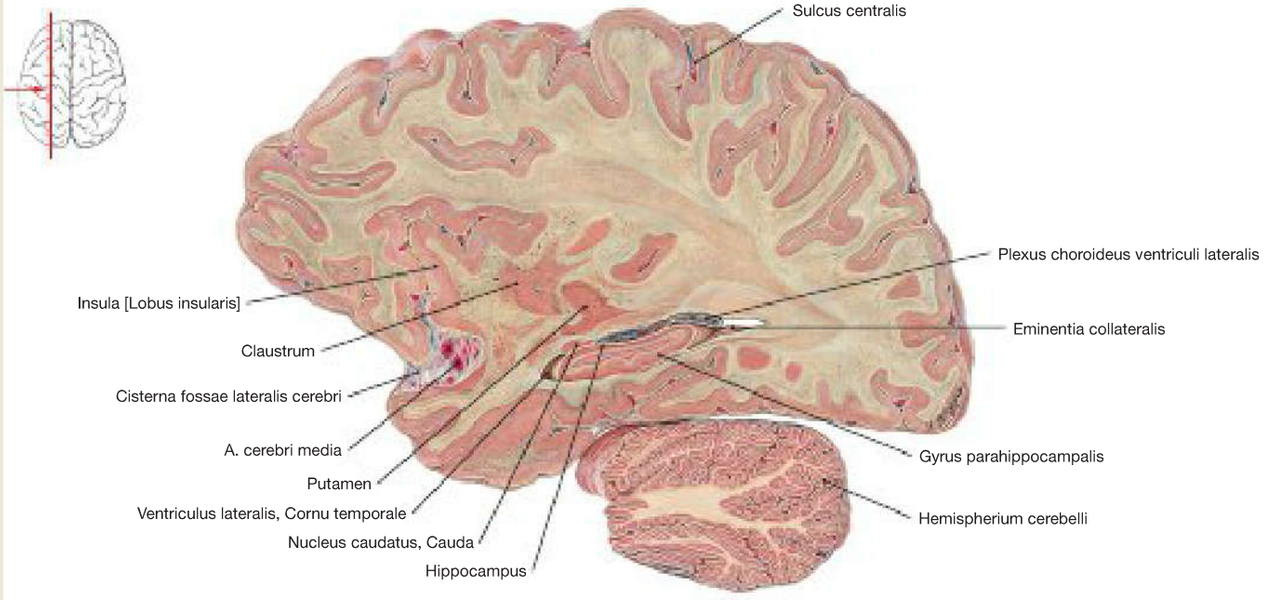

Fig. 12.243 Brain, Encephalon; sagittal section through the left hemisphere at the level of the apex of the Cornu temporale of the Ventriculus lateralis; view from the left side.
The lateral section shows the Lobus insularis. In addition, the Hippocampus with the Gyrus parahippocampalis, the Claustrum, and the Putamen are visible.

Practice Exam Questions

To check that you are completely familiar with the content of this chapter, practice questions from an oral anatomy exam are listed here.

Explain the development of the nervous system:

- From which embryotic layer do the CNS and PNS develop?
- From which tissue/structure does the CNS differentiate?
- From which tissue/structure does the PNS differentiate?
- Describe the development of the mesencephalon.
- How does the pituitary gland develop?
- What develops from the prosencephalon?
- From which tissue/structure do the internal cerebrospinal fluid (CSF) spaces differentiate?
- Explain the development of the spinal cord.

Describe the organisation of the nervous system:

- Which parts form the brain?
- How are the morphological and the functional structures of the nervous system organised?
- Which lobes does the telencephalon have? Please show them.
- Describe the boundaries of the diencephalon; which parts are assigned to it?
- Describe the function of the thalamus.
- How is the grey matter distributed in the brain and in the spinal cord?
- What are the functions of the hypothalamus?
- Which parts belong to the Truncus encephali?
- Name the most important fibre systems of the CNS.

Describe the structure of the meninges:

- Where is the Dura mater attached on the skull? What structures are the Tentorium cerebelli, and the Falx cerebri?
- How are the meninges supplied with blood?
- What is the Spatium subarachnoideum?
- Which nerves are involved in the innervation of the meninges?
- What is meant by bridging veins?
- How do epidural, subdural and subarachnoid hemorrhages differ from each other?

Explain the structure of the ventricular system:

- What are the internal cerebrospinal fluid (CSF) spaces?
- Describe the flow of cerebrospinal fluid.
- Where is the CSF produced?
- What is the BOCHDALEK's flower basket?
- Which structures form the walls of the lateral ventricles?
- Where are physiological constrictions ('bottlenecks') in the cerebrospinal fluid (CSF) system?
- Where does the cerebrospinal fluid resorption take place?
- How much cerebrospinal fluid is produced and reabsorbed each day?
- Where are enlargements of the external cerebrospinal fluid spaces?
- Where is a cerebrospinal fluid tap typically taken? Why there?
- What are the circumventricular organs?
- What are tanycytes, and where do they occur?

Explain the course of the cerebral blood vessels:

- Make a sketch of the typical Circulus arteriosus cerebri (WILLIS).
- Describe the course of the Aa. cerebri anterior, media and posterior.
- Name the terminal arteries provided by the A. basilaris or its branches.
- Which segments does the A. carotis interna have?
- A patient presents with a hemiparalysis of the leg. Which cerebral artery will cause the blood flow/circulatory disorder?
- Which segments does the A. vertebralis have?
- What is an aneurysm? Where do aneurysms most frequently occur?
- Describe the blood supply of the cerebellum.
- Which cerebral artery is responsible, along with its branches, for the blood supply to the Capsula interna? What are the supplying blood vessels called?
- Which blood vessels supply the spinal cord?
- What signifies the A. radicularis magna, and where is it typically located? Why is it of major clinical importance to know this artery?
- Show the innervation area of the Aa. cerebri posterior, media and anterior.
- How is the venous blood drained from the brain surface?
- Where are intracranial veins connected with extracranial veins? Where are the venous connections between the cerebral skull (neurocranium) and the facial skull (viscerocranium)?
- What are the names of the deep cerebral veins? Show them.

Describe the structure of the telencephalon:

- How can the telencephalon be divided?
- Which fibre systems are found in the telencephalon?
- Show and name functional cortical areas of the cerebral hemispheres.
- Where is the primary auditory cortex located, and where is the secondary?
- What is the insula? Show it.
- What is the hippocampus formation? Where is it?
- Which structures are connected to the hippocampus? Name connections of the hippocampus formation.
- What is called the PAPEZ circuit?
- What is meant by the cortical olfactory centre?
- To what structure do the Gyrus ambiens and the Gyrus semilunaris belong?
- Where is the Area prepiriformis?
- What are the basal ganglia? Show the corresponding nuclear areas.
- How do the basal ganglia communicate with each other?
- What is the cause of PARKINSON's disease? How does the disease manifest itself? What is its anatomic-pathological correlation?

Explain the structure of the diencephalon:

- Which levels does the diencephalon have?
- Which structures are part of the epithalamus? Show them.
- Describe afferent and efferent connections of the thalamus.
- Explain a thalamic nucleus and its associated cortical projection.
- Which regions belong to the hypothalamus?
- Which important hypothalamic nuclei and neuronal connections do you know?

- Name the hormones of the anterior pituitary gland (adenohypophysis) and of the posterior pituitary gland (neurohypophysis).
- What is described as acromegaly? What can be the cause?

Explain the structure of Mesencephalon, Pons and Medulla oblongata:

- Where is the mesencephalon located? What structures are part of the mesencephalon? Show them.
- Label horizontal sections through the mesencephalon, pons and Medulla oblongata.
- Which nuclei of cranial nerves are located in the mesencephalon, which in the pons and which in the Medulla oblongata?
- Which functional systems are harboured in the brain stem?
- Where is the rhomboid fossa? Show it.
- What is meant by brain stem reflexes?

Explain the structure of the cerebellum:

- Describe the structure of the cerebellum.
- Which cerebellar nuclei do you know? Show them.
- Which afferent and efferent connections does the cerebellum have?
- What is the main function of the cerebellum?
- Explain the blood supply of the cerebellum.

Explain the nuclear areas, course, fibre qualities, target organs and functions of the twelve cranial nerve pairs:

- Where do the individual cranial nerves or their branches pass through the cranial base?
- Where does the nuclear area of the individual cranial nerves lie?
- Describe the deficits of the individual cranial nerves.
- Which cranial nerves have parasympathetic fibres?

Explain the structure of the spinal cord:

- What is meant with Intumescentia?
- At which level does the spinal cord end?
- How is the spinal cord attached in the vertebral canal?
- In which segments of the spinal cord can you find parts of the sympathicus, and in which segments parts of the parasympathicus?
- How is the grey matter arranged in the spinal cord, and how is the white matter arranged?
- How is the unconscious proprioception interconnected?
- What is the epidural space? What is inside it?
- Which reflexes are interconnected at the level of the spinal cord?
- What is the difference between a monosynaptic and a polysynaptic reflex?

Explain the somatic motor system:

- Name and show cortical areas that are involved in the coordination of motor functions.
- Describe the pathway of the pyramidal tract. Which fibres/tracts form the pyramidal tract?
- Explain the functional structure of the Capsula interna.
- What is the extrapyramidal motor system (EPMS)?
- What is meant by the motor end plate and the motor unit?
- How is a voluntary movement planned and executed?

Explain the somatosensory system:

- Describe the pathway of the epicritic sensibility of the spinal afferent system of the posterior funiculus and of the trigeminal afferent system for the head region.
- Describe the pathway of the unconscious proprioception (deep sensibility).
- Describe the BROWN-SÉQUARD's syndrome in hemisection of the spinal cord at the level of, e.g. T11.

Explain the olfactory, gustatory and nociceptive systems:

- Describe the stations of the olfactory tract.
- Explain the gustatory (taste) pathway and its interconnections.
- Explain the neuronal chain of the nociceptive system.
- Which ascending and descending tracts belong to the nociceptive system?

Explain the autonomic nervous system:

- Where are the sympathicus and parasympathicus located?
- How is the autonomic nervous system organised?
- Describe the interconnections, including the respective neurotransmitters.
- Explain the cranial parasympathetic system.
- Explain the sacral parasympathetic system.
- What is the sympathetic trunk?
- Name central autonomic regions and nuclear areas in the brain.

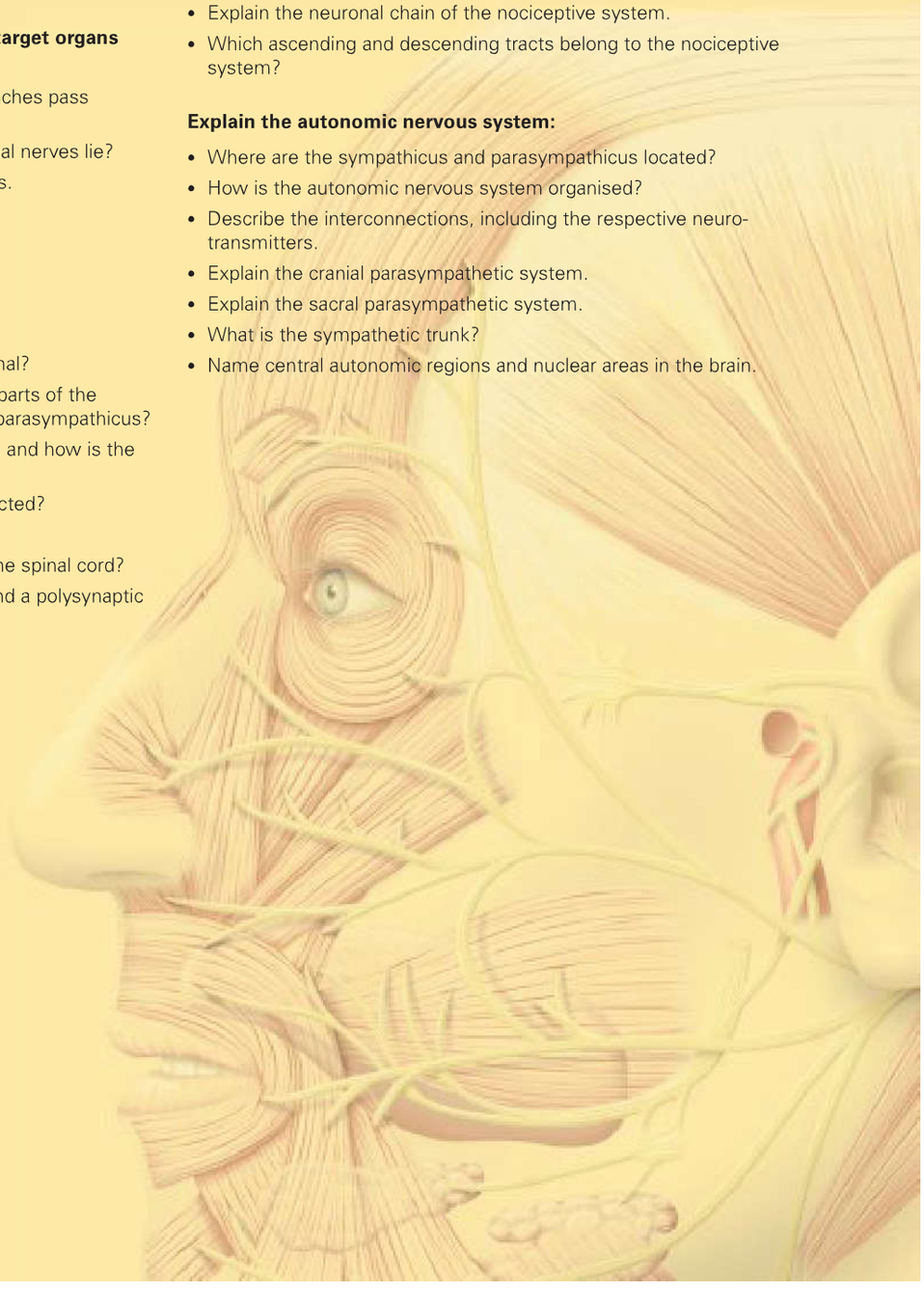

You will find these in the 16th edition

Volume 1 General Anatomy and Musculoskeletal System

1 General Anatomy

Anatomical Planes and Positions → Surface Anatomy → Development → Musculoskeletal System → Neurovascular Pathways → Imaging Methods → Skin and its Appendages

2 Trunk

Surface Anatomy → Development → Skeleton → Imaging Methods → Muscles → Neurovascular Pathways → Topography, Dorsal Trunk Wall → Female Breast → Topography, Ventral Trunk Wall

3 Upper Limb

Surface Anatomy → Development → Skeleton → Imaging Methods → Muscles → Neurovascular Pathways → Topography → Cross-Sectional Images

4 Lower Limb

Surface Anatomy → Skeleton → Imaging Methods → Muscles → Neurovascular Pathways → Topography → Cross-Sectional Images

Volume 2 Internal Organs

5 Organs of the Chest Cavity

Topography → Heart → Lung → Oesophagus → Cross-Sectional Images

6 Organs of the Abdominal Cavity

Development → Topography → Stomach → Intestines → Liver and Gallbladder → Pancreas → Spleen → Neurovascular Pathways → Cross-Sectional Images

7 Retroperitoneal Space and Pelvic Cavity

Topography → Kidney and Adrenal Gland → Urinary System → Rectum and Anal Canal → Genitalia → Cross-Sectional Images

Volume 3 Head, Neck and Neuroanatomy

8 Head

Overview → Skeleton and Joints → Muscles → Topography → Neurovascular Pathways → Nose → Mouth and Oral Cavity → Salivary Glands

9 Eye

Development → Skeleton → Eyelids → Lacrimal Apparatus → Muscles of the Eye → Topography → Eyeball → Visual Pathway

10 Ear

Overview → Outer Ear → Middle Ear → Auditory Tube → Inner Ear → Hearing and Equilibrium

11 Neck

Muscles → Pharynx → Larynx → Thyroid Gland → Topography

12 Brain and Spinal Cord

Development → General Principles → Brain → Meninges and Blood Supply → Cerebral Areas → Cranial Nerves → Spinal Cord → Sections

Tables

Tables of Muscles, Joints and Nerves

Head → Neck → Trunk → Upper Limb → Lower Limb → Cranial Nerves

Appendix

Picture Credits 444

Index 445

Picture Credits

Reference to the source for each figure in this work is given at the end of each caption in square brackets. All figures and graphics without a reference © Elsevier GmbH, Munich.
The editors sincerely thank all clinical colleagues that made ultrasound, computed tomographic and magnetic resonance images as well as endoscopic and intraoperative pictures available.

E282 Kanski, J.: Clinical Ophthalmology: A Systemtic Approach. 5th Ed., Butterworth-Heinemann, 2003
E347-09 Moore, K.L./Persaud, T.V.N./Torchia, M.G.: The Developing Human. 9th Ed., Elsevier/Saunders 2013
E402 Drake, R.L./Vogl, A. W./Mitchell A.W.M./Tibbitts, R.M./Richardson, P.E.: Gray's Anatomy for Students. 1st Ed., Elsevier/Churchill Livingstone, 2005
E460 Drake, R.L./Vogl, A. W./Mitchell A.W.M./Tibbitts, R.M./Richardson, P.E.: Gray's Atlas of Anatomy. 1st Ed., Elsevier/Churchill Livingstone, 2008
E838 Mitchell, B./Sharma, R.: Embryology. An Illustrated Colour Text. Elsevier/Churchill Livingstone, 1st Ed., 2005
E943 Kanski, J.: Clinical Ophthalmology: A Systemic Approach. 6th Ed., Butterworth-Heinemann, 2007
F885 Senger, M./Stoffels, HJ./Angelov DN: Topography, syntopy and morphology of the human otic ganglion: A cadaver study. Ann Anat 2014;196(5):327–35
G159 Forbes, A. et al.: Atlas of Clinical Gastroenterology. 3rd Ed., Mosby 2004
G198 Mettler, F.: Essentials of Radiology. 2nd Ed., Saunders 2005
G210 Standring, S.: Gray's Anatomy. 40th Ed., Elsevier/Churchill Livingstone, 2008
G617 Folkerth, R.D./Lidov H.: Neuropathology, Elsevier 2012
J803 Biederbick & Rumpf, Adelsdorf
L106 Henriette Rintelen, Velbert
L107 Michael Budowick, USA
L126 Dr. med. Katja Dalkowski, Erlangen
L127 Jörg Mair, München
L131 Stefan Dangl, München
L141 Stefan Elsberger, Planegg
L157 Susanne Adler, Lübeck
L238 Sonja Klebe, Löhne
L240 Horst Ruß, München
L266 Stephan Winkler, München
L271 Matthias Korff, München
L275 Martin Hoffmann, Neu-Ulm
L280 Johannes Habla, München
L281 Luitgard Kellner, München
L284 Marie Davidis, München
L285 Anne-Katrin Hermanns, „Ankats Art", Maastricht, NL
M502 Prof. Dr. med O. Trentz, Zürich
M519 Prof. Dr. med. G. A. Wanner, Zürich
M526 Prof. Dr. med. T.H.K. Schiedeck, Ludwigsburg
O548 Prof. Dr. med. Andreas Franke, Kardiologie, Klinikum Region Hannover
O892 PD Dr. med. habil. L. Mirow, Landkreis Mittweida Krankenhaus GmbH
P319 Frau Dr. med. Berit Jordan, Uniklinik Halle
P320 Prof. Dr. med. Frank Hanisch, Uniklinik Halle
R132 Classen, M./Diehl, V./Kochsiek, K.: Innere Medizin. 5. A., Elsevier/Urban & Fischer, 2003
R170 Welsch, U.: Sobotta Lehrbuch der Histologie. 2. A., Elsevier/Urban & Fischer, 2006
R235 Böcker, W./Denk, H./Heitz, P./Moch, H.: Pathologie. 4. A., Elsevier/Urban & Fischer, München 2008
R236 Classen, M./Diehl, V./Kochsiek, K.: Innere Medizin. 6. A., Elsevier/Urban & Fischer, 2009
R242 Franzen, A.: Kurzlehrbuch Hals-Nasen-Ohren-Heilkunde. 3. A., Elsevier/Urban & Fischer, 2007
R247 Deller, T./Sebestény, T.: Fotoatlas Neuroanatomie. 1. A., Elsevier/Urban & Fischer, 2007
R252 Welsch, U.: Sobotta: Atlas Histologie: 7. A., Elsevier/Urban & Fischer, 2005
R254 Garzorz, N.: Basics Neuroanatomie. 1. A., Elsevier/Urban & Fischer, 2009
R316-007 Wicke, L.: Atlas der Röntgenanatomie. 7. A., Elsevier/Urban & Fischer, 2005
R317 Trepel, M.: Neuroanatomie. 5. A., Elsevier/ Urban & Fischer, 2011
R331 Fleckenstein, P./Tranum-Jensen, J.: Röntgenanatomie. Elsevier/Urban & Fischer, 2004
R349 Raschke, M. J./Stange, R.: Alterstraumatologie – Prophylaxe, Therapie und Rehabilitation. 1. A., Elsevier/Urban & Fischer, 2009
S002-7 Lippert, H.: Lehrbuch Anatomie. 7. A., Urban & Fischer, 2006
S008-3 Kauffmann, G. W./Moser, E./Sauer, R.: Radiologie. 3. A., Elsevier/Urban & Fischer, 2006
S010-2-16 Benninghoff, A./Drenckhahn, D.: Anatomie. 16. A. Band 2, Urban & Schwarzenberg, 2004
S010-1-17 Benninghoff, A./Drenckhahn, D.: Anatomie. 17. A., Band 1, Elsevier/Urban & Fischer, 2008
T534 Prof. Dr. med. Matthias Sitzer, Klinik für Neurologie, Klinikum Herford
T127 Prof. Dr. med. Dr. Peter Scriba, München
T719 Prof. Dr. med. Norbert Kleinsasser, HNO-Klinik, Universität Würzburg
T720 PD Dr. med. Hannes Kutta, Universitätsklinikum Hamburg-Eppendorf
T786 Dr. med. Stephanie Lescher/Prof. Dr. med. Joachim Berkefeld, Institut für Neuroradiologie, Klinikum der Goethe Universität Frankfurt
T832 PD Dr. med. Frank Berger, Institut für Klinische Radiologie der LMU München
T863 Dr. med. C. Markus, Uniklinik Würzburg
T867 Prof. Dr. med. Gerd Geerling, Düsseldorf
T872 Prof. Dr. med. M. Uder, Erlangen
T882 Prof. Dr. med. Christopher Bohr, Erlangen
T884 Dr. med. dent. Tobias Wicklein, Erlangen
T887 Prof. Dr. med Stephan Zierz, Uniklinik Halle
T890 Prof. Dr. med. Jakob Altaras†, Zentrum Radiologie, Universität Gießen
T891 Prof. Dr. med. Hartmut Brückmann/PD Dr. med. Jennifer Linn, Neuroradiologie, Institut für radiologische Diagnostik, Universität München
T892 Prof. Dr. med. Werner Daniel, Abteilung Kardiologie, Universität Erlangen
T893 Prof. Dr. med. Michael Galanski/Dr. Schäfer, Abteilung Diagnostische Radiologie, Med. Hochschule Hannover
T894 Prof. Dr. med. Michael Gebel, Abteilung Gastroenterologie und Hepatologie, Med. Hochschule Hannover
T895 Dr. Gabriele Greeven, St.-Elisabeth-Krankenhaus, Neuwied
T896 Prof. Dr. med. Dr. rer. nat. Matthias Hoffmann/Prof. Dr. med. Hüseyin Bektas, Klinik für Viszeral- und Transplantationschirurgie, Med. Hochschule Hannover
T897 Prof. Dr. med. Jens Hohlfeld, Klinik für Pneumologie, Med. Hochschule Hannover
T898 Prof. Dr. med. Udo Jonas, Urologie, Med. Hochschule Hannover
T899 Prof. Dr. med. Anselm Kampik/Prof. Dr. med. Arthur Müller, Augenklinik, Universität München
T900 PD Dr. med. Tim Kirchhoff/Dr. med. Jürgen Weidemann, Abteilung Diagnostische Radiologie, Med. Hochschule Hannover
T901 Dr. Meyer, Abteilung Gastroenterologie und Hepatologie, Med. Hochschule Hannover
T902 Prof. Pfeifer, Radiologie Innenstadt, Institut für radiologische Diagnostik, Universität München
T903 Prof. Dr. med. Kurt Possinger/Prof. Dr. med. Ulrich Bick, Medizinische Klinik und Poliklinik II mit Schwerpunkt Onkologie und Hämatologie, Charité Campus Mitte, Berlin
T904 Prof. Dr. Alfred Ravelli†, ehem. Institut für Anatomie, Universität Innsbruck
T905 Prof. Dr. med. Dr. med. dent. Rudolf H. Reich, Klinik für Mund-Kiefer-Gesichtschirurgie, Universität Bonn
T906 Prof. Dr. med. Maximilian Reiser/Dr. Wagner, Institut für radiologische Diagnostik, Universität München
T907 Dr. Scheibe, Chirurgische Abteilung, Rosmann-Krankenhaus Breisach
T908 Prof. Dr. med. Georg F. W. Scheumann, Klinik für Viszeral- und Transplantationschirurgie, Med. Hochschule Hannover
T909 Prof. Dr. med. Helmut Schillinger, Frauenklinik, Universität Freiburg
T910 Prof. Dr. med. Dr. med. dent. Henning Schliephake, Mund-Kiefer-Gesichtschirurgie, Universität Göttingen
T911 Prof. Dr. med. Hans Walter Schlößer, Zentrum Frauenheilkunde, Med. Hochschule Hannover
T912 cand. med. Carsten Schröder, Kronshagen
T916 Prof. Dr. med. Thomas J. Vogl, Radiologische Poliklinik, Universität München
T917 Prof. Witt, Klinik für Neurochirurgie, Universität München

A

Abdominal (wall/skin) reflex 402
Abducens nerve [VI]
– palsy 143, 357, 367
– – diplopia (double images) 141
Abduction, temporomandibular joint 44
Ablatio/Amotio retinae (retinal detachment) 129, 154, 158, 160
ABR (auditory brainstem response) 195
ACA (anterior cerebral artery) 296, 307
Accessory lacrimal gland 132
Accommodation 163
Accommodation reflex 163
Acetylsalicylic acid, temperature-sensitive neurons, increased sensitivity 293
ACHILLES tendon reflex (ankle jerk reflex) 402
ACom (anterior communicating artery) 307
Acoustic impedance 170
Acoustic neurinoma (vestibular schwannoma) 187, 373, 377
Acoustic shock, tinnitus 192
Acoustically evoked potentials (AEP) 195
Acromegaly 334
Acromion 205, 242
ACTH (corticotropin) 334
Acute dacryoadenitis, narrowed eyelids 137
Acute oedema of the pharynx 232
Acute otitis media 167
Acute pain 418
ADAMKIEWICZ'artery (A. radicularis magna) 399
Adduction, temporomandibular joint 44
Adenectomy 219
Adenohypophysis 277, 298, 329, 333, 361
– hormones 334
Adenoids 219
ADH (antidiuretic hormone, vasopressin) 423
– deficiency 334
Adhesio interthalamica 287, 290, 292, 302, 327, 331, 340, 347, 436
Aditus
– ad antrum mastoideum 177
– laryngis 103, 219, 232
– orbitalis 134–135
Adrenaline 419
AEP (acoustically evoked potentials) 195
Aequator lentis 154, 157
Age-related macular degeneration (AMD) 158
Ageusia 417
Agger nasi 78
Agnosia 319
AICA (anterior inferior cerebellar artery) 307, 310
Air conduction of the ear 170
AJCC -classification, lymph node metastases of the neck 251
Ala
– cristae galli 16
– lobuli centralis 43
– major (Os sphenoidale) 10, 16, 18, 22, 31–36, 38, 54, 74, 96, 126–127, 136, 141, 143, 150, 183
– minor (Os sphenoidale) 10, 32–36, 38, 74, 126
– nasi 68–69
– vomeris 18, 28
Alar cartilage, nose 68
Alcohol abuse
– atrophy of the vermis of cerebellum 343
– destruction of the mammillary body 323
Alexia, cerebral infarction/apoplexy 303
Alexithymia 281
Altitude sickness 312
Alveoli dentales 27, 33, 105
Alveus hippocampi 289, 291, 324, 430–431, 436–437
ALZHEIMER's disease 294, 320, 325
– hippocampus 320
Amacrine cells, retina 354
Amaurosis
– cortical blindness 161
– fugax 303
Amaurotic pupillary rigidity 163
Amiculum olivare 406
Amnesia 323
Ampulla
– canaliculi lacrimalis 131, 139
– membranacea
– – anterior 189, 191, 376
– – lateralis 189, 191, 376
– – posterior 189, 191, 376
– ossea
– – anterior 188
– – lateralis 188
– – posterior 188
Amygdala 418
Amyotrophic lateral sclerosis (ALS) 338, 410
Anal reflex 402
Anastomosis of ansa of GALEN (ansa GALENI) 232
Anencephaly 260, 269
Angle-closure glaucoma 156
Angulus
– iridocornealis 154
– mandibulae 10, 38–39, 41, 55
– oculi
– – lateralis 128, 132
– – medialis 128–129, 132
– oris 82
– scalenovertebralis 254
– sphenoidalis 10
Anophthalmia 125
Anosmia 81, 353
– nasal septum deviation 76
Ansa
– cervicalis 61, 243, 246, 252
– – profunda 108, 242–246, 248–249, 390–391
– – superficialis 241
– GALENI (anastomosis of GALEN) 232
– subclavia 253–254
Anterior cervical region 202–203
– vessels and nerves 240, 242
Anterior choroid artery syndrome 304
Anterior communicating artery syndrome 298
Anterior cranial base 18, 30
Anterior cranial fossa 16, 151
Anterior lateral fontanelle 23
Anterior scalene hiatus 206
Anterior spinal artery syndrome 399
Anterior spinocerebellar tract 413
Anterior triangle of the neck 202
Anterolateral system, paleospinothalamic system 418
Antidiuretic hormone (ADH, vasopressin) 423
– deficiency 334
Antihelix 171
Antitragus 171
Antrum mastoideum 177–178
Antrum curette 79
Anulus
– fibrocartilagineus 173, 175–176, 179–180
– iridis major/minor 156
– tendineus communis (anulus of ZINN) 141, 143–144, 356
– tympanicus 22, 28
Anxiety disorders 324
Aorta 400
– abdominalis/thoracica *See* Pars abdominalis/thoracica aortae
Apertura
– canaliculi
– – cochleae 37
– – vestibuli 37
– externa canalis carotici 19–20, 37, 100, 183, 298
– interna canalis
– – carotici 21, 298
– – optici 17
– lateralis ventriculi quarti (foramen of LUSCHKA) 278, 286–287, 339–340, 439
– mediana ventriculi quarti (foramen of MAGENDIE) 282, 286–287, 347
– piriformis 9, 22, 30
Apertura
– sinus
– – frontalis 29, 70
– – sphenoidalis 29, 34, 70, 74
– thoracis superior 249
Apex
– cuspidis 88
– linguae 102, 106–107
– nasi 68
– partis petrosae 37, 187, 300
– radicis dentis 88
Aphasia, apoplexy 303
Aphonia 226
Aponeurosis
– linguae 103
– palatina 100, 183
– stylopharyngea 217
Apoplexy (cerebral infarction, stroke) 302–303, 308, 408
Apparatus lacrimalis 138–140
Aqueductus
– mesencephali (canal of SILVIUS) 262–263, 275, 277, 279, 286–287, 292, 302, 329, 332, 336, 340, 344, 425–426, 430, 437–438
– vestibuli 187
Arachnoidea mater (arachnoid) 262, 282, 284–285
– cranialis 267, 283–285, 300, 428, 432
– spinalis 394, 400
Arbor vitae 340
Archicerebellum 262
Archicortex, structures 325
Archispinothalamic tract 418
Arcuate fibres 280
Arcus
– alveolaris (Mandibula) 38–39
– aortae 253, 381, 422
– cartilaginis cricoideae 204, 213, 221–225, 229, 234
– dentalis
– – mandibularis [inferior] 86–87
– – maxillaris [superior] 86–87
– palatoglossus 85, 98, 101–102
– palatopharyngeus 85, 98, 101, 213, 216
– palpebralis
– – inferior 134, 147
– – superior 134, 147
– superciliaris 9, 26
– venosus jugularis 204, 241, 248
– zygomaticus 9, 11, 18–19, 31, 40, 42, 45, 52–54, 75, 94
Area
– cochlearis 187–188, 190
– entorhinalis 325
– hypothalamica 333
– – anterior 423
– – intermedia 423
– – lateralis 333, 423
– – posterior 333, 423
– nervi facialis 187
– postrema 278, 293, 339
– preoptica 333
– prepiriformis 325
– pretectalis 163, 339
– striata 160, 163
– subcallosa 277, 301, 329, 352, 428, 436–437
– tegmentalis ventralis (VTA) 336, 340
– vestibularis inferior/superior 187
Arteria(-ae)
– alveolaris
– – inferior 58–62, 76, 95, 108, 114, 217
– – superior
– – – anterior 59, 62, 95, 97
– – – posterior 59, 62, 95, 97
– angularis 56–62, 134
– auricularis
– – posterior 56–58, 61–62, 171, 240, 243
– – profunda 59, 62
– axillaris 245, 247
– basilaris 285, 295–297, 299–302, 305, 307, 329, 340, 347, 426, 429, 439
– – supply area 308–310
– buccalis 58–62

Index

Arteria(-ae)
– callosomarginalis 295, 306, 313, 428, 433, 436–437
– canalis pterygoidei 59, 97, 298
– caroticotympanicae 298
– carotis
–– communis 53, 61–62, 66–67, 108, 204, 206–207, 215–216, 236, 242–245, 247–250, 253–254, 295, 297, 378, 381, 390, 422
––– level of the bifurcation 252
–– externa 58–60, 62, 95, 109, 171, 215, 220, 242–245, 252, 295, 297, 356, 378
––– branches 62
––– supply area 134
–– interna 55, 58, 60, 62, 97, 111, 118, 137, 144–148, 150, 160, 176–177, 180–182, 184–186, 215–217, 220, 244–245, 285, 295–307, 309, 360–361, 369, 378, 390, 439
––– arteriosclerotic changes 298, 303
––– parts/segments 298
––– supply area 134, 308–309
– centralis(-es)
–– anterolaterales 299, 306–307, 408
––– occlusions 306
–– anteromediales 299, 306–307, 408
–– longa (HEUBNER's artery) 298–299, 306
–– posterolaterales 299, 305–307
–– posteromediales 299, 305–307
–– retinae 76, 124, 145, 147, 155, 160
––– occlusion 144, 153
– cerebri
–– anterior 295–299, 301–304, 306–308, 347, 360–361, 428, 432–439
––– supply area 308–309
–– inferior 305
–– media 295–301, 303–308, 408, 427–428, 431, 434, 438–440
––– supply area 308–309
–– posterior 160, 295–297, 299–302, 304–305, 307, 329, 360, 429–430, 436–440
––– supply area 308–310
– cervicalis
–– ascendens 243–245, 247, 254, 399
–– profunda 247, 253–254, 399
–– superficialis 243–244, 247, 254
– choroidea
–– anterior 160, 290, 298–299, 301, 304, 306–307, 309
–– posterior 299, 304–305
––– lateralis 290, 305
––– medialis 290, 305
– ciliaris(-es) 148, 160
–– anterior 147, 155
–– posteriores
––– breves 145, 155
––– longae 145, 147, 155
– cochlearis 190
– communicans
–– anterior 296–297, 299–302, 306–307, 428, 438
–– posterior 295–301, 305, 307, 429, 438–439
– conjunctivales
–– anteriores 147, 155
–– posteriores 147
– dorsalis
–– nasi 60, 145, 147–148
–– scapulae 244, 254
– episclerales 147, 155
– ethmoidalis
–– anterior 79, 145–149
–– posterior 79, 145, 147–149
– facialis 56–62, 76, 110, 113, 134, 204, 215, 244–245, 248–249, 252
–– branches 62
– frontobasalis 303
–– lateralis 301
–– medialis 301, 304
– hyaloidea 100, 124–125, 154
– hypophysialis
–– inferior 298
–– superior 298–299

Arteria(-ae)
– iliaca communis 422
– inferior
–– anterior cerebelli 290, 295–297, 299–301, 305, 307
––– supply area 310
–– posterior cerebelli 247, 290, 295–297, 299–301, 305, 307
––– circulatory disorders 301
––– supply area 310
– infraorbitalis 57, 59, 61–62, 95, 97, 130, 134, 149, 153
– infratrochlearis 134
– intercostalis
–– posterior 247, 399–400
––– prima 247
––– secunda 247
–– suprema 247, 254
– labialis
–– inferior 57, 62
–– superior 57, 62, 79
– labyrinthi 190, 299–301, 305
–– thrombotic occlusion 190
– lacrimalis 136, 145–148
– laryngea
–– inferior 232, 244
–– superior 62, 107, 115, 200, 212, 216, 232–233, 242–244, 252, 254
– lenticulostriatae 408
– lingualis 58, 60–62, 76, 108–109, 113, 115, 215, 243, 252
–– branches 62, 109
– masseterica 58–60, 62
– maxillaris 58–62, 95, 97
–– branches 59, 62
–– variations of the course 59
– medullaris segmentalis 247, 399–401
– meningea
–– media 59, 61–62, 117, 146, 288, 300
–– posterior 62, 215, 300
– mentalis 58
– mesenterica
–– inferior 422
–– superior 422
– nasales posteriores laterales 62, 79
– nasopalatina 62, 79
– occipitalis 56, 58, 61–62, 108, 111, 216, 240–242, 244–245
–– branches 62
–– medialis 431–432
– ophthalmica 144–150, 152–153, 160, 295–300, 305, 307, 347, 360–361
–– branches 147
– palatina(-ae)
–– ascendens 61–62, 215, 232
–– descendens 59, 62, 97, 101
–– major 62, 79, 97–98
–– minores 62
– palpebrales
–– laterales 147
–– mediales 147
– parietalis posterior 303, 313
– pericallosa 302, 306, 428–429, 431–437
– pericardiacophrenica 254
– pharyngea ascendens 62, 215
– pontis 299, 305
–– circulatory disorders 305
– prefrontalis 303
– profunda linguae 62, 109
– pterygomeningea 59
– radicularis magna (artery of ADAMKIEWICZ) 399
– renalis 422
– sacralis lateralis 399
– scapularis descendens 247
– sphenopalatina 59, 61–62, 79, 97
– spinalis
–– anterior 247, 299, 301, 305, 399–401
––– supply area 310
–– posterior 247, 299, 305, 399–401
–– segmentalis 399–400
– spiralis modioli 190
– striata medialis distalis 299, 306

Arteria(-ae)
– stylomastoidea 62
– subclavia 206, 216, 238, 242–245, 247, 249, 253–254, 297, 381–382, 399, 422
–– proximal high-grade stenosis 244
– sublingualis 61–62, 109, 115
– submentalis 59, 61–62, 113, 243–245
– sulci
–– centralis 303, 313
–– postcentralis 303, 313
–– precentralis 303, 313
– superior cerebelli 296–297, 299–301, 305, 307, 439
––– supply area 310
– supraorbitalis 57, 134, 145–148, 153
– suprascapularis 242, 244–245, 247, 254
– supratrochlearis 57–59, 134, 145, 147–148
– temporalis
–– media 59, 61–62
–– profunda
––– anterior 59, 62
––– posterior 59, 61–62
–– superficialis 53, 56–59, 61–62, 134, 171
––– branches 62
– thoracica interna 244–245, 247, 253–254
– thoracoacromialis 245
– thyroidea
–– inferior 215–216, 232, 236, 238, 244–245, 247, 254
–– superior 62, 113, 213, 215, 238, 242–245, 249, 252, 254
– transversa
–– colli 242–245, 247, 249
–– faciei 56, 59, 62, 134
– tympanica
–– anterior 59, 62
–– inferior 62
–– posterior 62, 175
–– superior 62
– vertebralis 111, 236, 244, 247, 253–254, 285, 295–297, 299–302, 305, 307, 340, 399, 439
–– branches 247
–– supply area 308–309
–– variations 247
– vestibularis anterior 190
– zygomaticoorbitalis 56, 58–59, 62
Arteriola
– macularis inferior/superior 158
– medialis retinae 158
– nasalis
– nasalis retinae inferior/superior 158
– temporalis retinae inferior/superior 158
Arteriosclerotic changes in the vascular wall of the carotid artery 298, 303
Arthrosis
– cricoarytenoid joint 224
– temporomandibular joint 44
Articulatio(-nes)
– atlantoaxialis lateralis 206
– cricoarytenoidea 221–223, 233
– cricothyroidea 222, 224, 227
– incudomallearis 174–175
– incudostapedialis 174–175
– ossiculorum auditus 175
– temporomandibularis 11, 40–46, 52–54, 60, 64
Arytenoid cartilage 221
Arytenoid subluxation 223
Association cortex 319, 411, 415
Association fibres 280–281
Ataxia 43, 323, 342
– asynergies 342
– lesions of the thalamic nuclei 331
Atlas 206
Atrium meatus medii 78
Auditory brainstem response (ABR) 195
Auditory cortex 195, 319
Auditory ossicles 166, 168, 170, 174–175, 191
– development 168
– differentiation 168
– ossification mode 24

Auditory pathway 195
– neuronal stations 195
– peripheral segments 194
Auditory tube (EUSTACHIAN tube) 179, 184–185
– development 168
Auricle (Auricula) 170–172
– arteries 171
– cartilage 172
– development 168
– dysplasia 169
– malformations 169
– perichondritis 172
– rudimentary (microtis) 169
– sensory innervation 171
Auricular hillocks 168
Auris 170
– interna 168, 170, 186, 190, 1865
– media 170, 182, 191
Autism 320, 343
Autonomic head ganglia 116
Autonomic nervous system (visceral/vegetative nervous system) 270, 421
– circuitry 419
– organisation 420
Axillary region 245
Axis
– externus bulbi 154–155
– internus bulbi 154–155
– lentis 157
– opticus 154

B

BABINSKI's reflex 410
– lesions of the pyramidal tract 406
Balance disorders, lesions of the vestibulocerebellum 342
BARRINGTON, nucleus of 424
Basal ganglia 326, 328, 406, 411
Basal lamina 192
Basal plate 263–264, 268
– rhombencephalon 349
Base of the tongue 102
Basic lamellae, paranasal sinuses 78
Basis
– cochleae 188
– cranii
– – externa 18–20, 211
– – interna 16–17, 21, 300
– mandibulae 38
– stapedis 174
BECHTEREW, nucleus of (Ncl. vestibularis superior) 191, 350, 377
BELL's phenomenon, facial paralysis 3, 64, 130, 373
BENNET's angle 44
BERNOULLI, principle of 230
BETZ' giant cells, isocortex 317
Biceps tendon reflex 402
BICHAT's fat pad (fat pad of the cheek, Corpus adiposum buccae) 52, 60, 110
– cancer cachexia 53
Bifurcatio carotidis 62
Bilaminar zone (Art. temporomandibularis) 42–43, 45
Bipolar cells of the retina 162
Bitemporal hemianopsia 161, 355
BLANDIN, gland of (Glandula lingualis anterior) 103, 116
Bleeding, scalp 49
Blepharitis 133
Blind spot (Discus nervi optici) 154, 158, 294
Blindness 160
Blink reflex 361
Blood circulation, Medulla oblongata 338
Blood-brain barrier 293–294
Blood-CSF barrier 290, 293
Blow-out fracture 127
– coronary CT 123
BÖTTCHER's cells, organ of CORTI 192
Bolus death 213
Bone conduction of the ear 170
Bony labyrinth 187–190
Bony skull
– meninges 282
– of a newborn 22, 28, 31
BOWMAN's membrane (Lamina limitans anterior) 154
Brachiofacial hemiplegia (BROWN-SÉQUARD's syndrome) 303
Brachiofacial paralysis 308
Brachium colliculi
– inferioris 195, 278, 335–336, 339
– superioris 160, 278, 335, 339
Brain 160, 284–285
– age-related atrophy, lesions of the bridging veins 313
– arterial circle 299–300
– arteries 301, 304
– atrophy 274
– central arteries 306
– deep veins 314
– development 261–264, 266
– developmental defects 267
– frontal section 428–432
– horizontal section 433–438
– ischaemia tolerance 295
– magnetic resonance imaging (MRI) 425–427
– medial surface 302
– sagittal section 439–440
– superficial arteries 313
– superficial veins 313
– veins 304
– ventricles 286
– vesicles 124
Brain abscess, otitis media 176
Brain aneurysms 298
– rupture 299
Brain stem 278, 302, 339–340, 343
– arterial blood supply 310
– circulatory disorders, paralysis of the muscles of the soft palate 104
– development 266
– functional anatomy 339
– monoaminergic neurotransmitter system 340
– visceral afferent sensory fibres 423
Brain vesicles
– cervical flexure (Flexura cervicalis) 261
– midbrain (Flexura mesencephalica) 261
– primary 261
– secondary 261
Branchiogenic muscles 349
Break-up time (tear scope test) 133
Bregma 12
Bridging veins 258, 313
– injuries 313
BROCA's aphasia 319
BROCA's centre (motor language centre) 319
BROCA's diagonal band 325
BRODMANN area 1 415
BRODMANN area 2 415
BRODMANN area 3 415
BRODMANN area 4 407
BRODMANN area 5 407, 415
BRODMANN area 6 407
BRODMANN area 7 196, 415
BRODMANN area 41 195
BRODMANN areas 318
Brow fat prolapse 8
BROWN-SÉQUARD's syndrome (hemiplegia) 405, 416
BROYLE's tendon (tendon of the vocal ligament) 223, 233
BRUDZINSKI's sign 288
BRÜCKE's muscle (M. ciliaris) 156
Bucca 82, 85
Buccal glands 111
Bulbar paralysis 338
Bulbus
– cornus posterioris (Ventriculus lateralis) 434
– inferior venae jugularis 215–216, 243
Bulbus
– oculi 135, 141, 148, 150, 153–155, 159–160, 425–426
– – dimensions 155
– – testing the main viewing directions 142
– olfactorius 72, 81, 264–265, 275, 285, 301, 322–323, 325, 347, 352–353, 439
– superior venae jugularis 215–216, 311
Bulla ethmoidalis 71, 74, 77, 79
BURDACH's tract (Fasciculus cuneatus) 339, 397, 412
Burn-out syndrome 419
Bursa infrahyoidea 224, 229, 234

C

CAJAL-RETZIUS's cells, isocortex 317
Calcar avis 289–291, 322, 431, 435–436
Callosotomy, epilepsy 281
Calvaria 14–15, 283
– bend fractures 15
– diploic canals 312
– fractures 315
– veins 312
Camera
– anterior bulbi 154, 156, 159
– articularis
– – inferior/superior (Art. temporomandibularis) 42
– posterior bulbi 154, 156
– postrema (vitrea) bulbi 154, 159
CAMPER's plane, jaw 11
Canaliculus
– lacrimalis inferior/superior 131, 138–139
– mastoideus 18, 20
– – content 20
– posterius (Labyrinthus osseus) 187
Canalis(-es)
– caroticus 17–19, 37, 100, 176–179, 183, 185, 187, 300
– – content 20–21
– centralis 279, 282, 286–287, 302, 340, 394, 397
– condylaris 16, 18–21
– – content 20–21
– diploici 312
– incisivus 14, 28–29, 69–70
– infraorbitalis 32–33, 36, 94, 126
– mandibulae 93–94
– musculotubarius 37
– nasolacrimalis 30, 77, 126
– nervi
– – facialis 177–180, 187, 191, 376
– – hypoglossi 14, 16–21, 41, 300, 390
– – – content 20–21
– opticus 16–17, 21, 32, 35, 37, 126, 144, 146, 149–150, 159, 300
– – content 21
– – neurovascular pathways 144
– palatinus major 33, 96
– palatovaginalis 96
– pterygoideus (VIDIAN canal) 33–34, 38, 96
– radicis dentis 88
– semicircularis(-es) 170, 190
– – anterior 186–190
– – lateralis 179, 182, 186–189
– – posterior 186–189
– spiralis
– – cochleae 187
– – modioli 187
– vertebralis 401, 405
Cancer cachexia, BICHAT's fat pad 53
Candida albicans, oral mucosa 83
CANNON-BÖHM's point 384
Capsula
– articularis
– – (Art. temporomandibularis) 41–42, 52–55, 60
– – cricothyroidea 222, 225–226
– externa 279, 281, 327, 329, 406, 408, 428–430, 434–436
– extrema 279, 281, 327, 406, 408, 428–430, 434–436

Index

Capsula
– interna 279, 281, 289–290, 304, 306, 309, 326–327, 329, 331–332, 360, 406, 408, 427–431, 433–437, 439–440
– – blood supply 306, 408
– – haemorrhages 308, 408
– – infarction 373
– – tracts 265, 408
– – vascular occlusion 408
– lentis 157
Caput
– hippocampi 321
– inferius (M. pterygoideus lateralis) 42, 45, 54–55, 64
– mallei 174, 176, 179, 376
– mandibulae 38–39, 43, 54–55, 64, 172
– nuclei caudati 290–292, 309, 321, 326–327, 339, 406, 408, 425, 427–429, 433–437, 439
– stapedis 174, 179
– succedaneum (scalp swelling) 49
– superius (M. pterygoideus lateralis) 42, 45, 54–55, 64
Carotid arterial system 301
Carotid bifurcation, vascular changes 295
Carotid loops 220
– peritonsillar abscess 220
– tonsillectomy 220
Carotid sheath 207
Carotid sinus syndrome 252, 295
Carotid siphon 298
Cartilage-free area of the nose 69
Cartilage of the auditory tube 100, 183
Cartilago(-ines)
– alaris(-es)
– – major 68–69
– – minores 69
– arytenoidea 221–226, 228, 233
– auriculae 111
– corniculata (SANTORINI's cartilages) 221–222, 224, 226–229
– cricoidea 115, 204, 218, 221, 223, 226–228, 235, 254
– cuneiformis 226, 228
– epiglottica 103, 213, 221–224, 229, 235
– laryngis 222, 224
– nasi 69
– – accessoriae 68
– – lateralis 68–69, 111
– septi nasi 68–69, 72, 77
– thyroidea 103, 107, 115, 204, 212–213, 216, 218, 221–229, 232–235, 237, 254
– tracheales 212, 218, 222–223, 225–226, 228–229, 235–236
– triticea 222, 226, 228, 234
– tubae auditivae [auditoriae] 100, 183–185, 216
Caruncula
– lacrimalis 128, 138–139
– sublingualis 112, 114–115
Cataracta senilis 157
Catecholamine 419
Cauda
– equina 393, 395, 404
– helicis 172
– hippocampi 321
– nuclei caudati 279, 290, 292, 326–327, 429–431, 434–437, 440
Cauda equina syndrome 392
Cavernosus sinus syndrome 357
Cavernosus sinus thrombosis, abducens nerve palsy 367
Cavitas
– conchae 171
– coronae 88
– dentis 88
– infraglottica 229, 235
– nasi 29, 36, 41, 70, 72, 75, 77–79, 111, 151, 159, 219
– oris 84–85, 98, 213
– – propria 83–85, 101
– pharyngis 233
– tympani 118, 169–170, 172–173, 175–180, 187, 376, 378
Cavum septi pellucidi 290–292, 433
Cellulae
– ethmoidales 31, 36, 73–74, 76–77, 127, 140, 143, 150–151, 153, 159, 425
– – anteriores 74–75, 130
– – posteriores 74–75
– mastoideae 177–178, 182, 184
– pneumaticae 185
– tympanicae 177, 187
Cementum 88
Cenenzephalocele 267
Central analgesic (pain) therapy 335
Central auditory pathway 195
Central autonomic brain regions 424
– nuclear areas 424
Central canal 268
Central cerebral arteries 306
Central facial palsy 3, 64, 373
Central midface fractures, LE-FORT's classification 9
Central venous thrombosis 153
Central vomiting (emesis), neuroleptic drugs 293
Centrally mediated pain 418
Centrum ciliospinale 163
Cephalhaematoma 49
Cerebellar compartment, afferent and efferent connections 343
Cerebellar cortex 41, 343
– structure, LARSELL's classification 344
Cerebellar nuclei 343
Cerebellar tent (Tentorium cerebelli) 283
Cerebellopontine angle 337
– tumour 377
Cerebellum 263–266, 271, 278, 286, 308–309, 339–343, 411, 426, 430
– arterial supply 310
– cerebral cortex 343
– development 262
– paravermal zone 342–343
Cerebral arteries 307
– clinical (radiological) names 296
– MR angiography 296–297
– supply areas 308–310
Cerebral hernia (Hernia cerebri, encephalocele) 267
Cerebral infarction (apoplexy, stroke) 303, 408
Cerebral nerves 345, 349–350
– characteristics 347
– course
– – in the middle cranial fossa 360
– – in the subarachnoid space 347
– innervation areas 346
– nuclei of origin 351
– overview of the nuclei 350
– pharyngeal arches 349
– terminal nuclei 351
Cerebral veins, deep 314
Cerebrum 160, 271, 274, 407, 409
– convolutions 273–276
– functional cortical areas 319
– grooves 273–276
– lobes 272
Cerumen (ear wax) 173
– obturans 173
Cervical fat compartment 48
Cervical flexure, primary brain vesicle 261
Cervix dentis 88
Chalazion (stye) 133
Cheek fat compartment 48
Chemoreceptor reflex 339
Chiasma opticum 141, 144, 160, 264–265, 275, 277, 287, 298, 301–302, 308–309, 322, 325, 329, 332, 340, 347, 355, 361, 425–426, 429
– median lesion 355
Chin fat compartment 48
Choana 19, 28, 41, 219
Cholesteatoma 193
Chorda
– dorsalis 260, 264
– tympani 61, 89, 116–117, 175–177, 179–182, 191, 362, 364, 369–371, 373, 376, 417
– – damage 369
Chorda tympani
– – loss of function 181
Choreatic hyperkinesia 328
Choroid 154
Choroid/choroidal vessels 304
Choroidea 124–125, 154–156
Chronic pain 418
Chylous fistula 251
Ciliae 128, 132, 152
Ciliary body 156
Cingulum 280–281, 324
– lesions 324
Circadian rhythm 423
Circle of WILLIS (Circulus arteriosus cerebri) 285, 295, 299–300
Circulation centre 339
Circulatory reflexes 339
Circulus arteriosus
– cerebri (circle of WILLIS) 285, 295, 299–300
– – aneurysms 298
– iridis major/minor 155
Circumventricular organs 293
Cisterna(-ae)
– ambiens 285, 360, 430–431, 436–439
– arachnoideae 282
– basalis 384
– cerebellomedullaris 282, 285, 287, 426
– chiasmatica 285, 287, 438
– fossae lateralis cerebri 285, 428–431, 434–438, 440
– interpeduncularis 285, 287, 329, 425, 429, 438
– laminae terminalis 428
– lumbalis 404
– pericallosa 287, 428, 430–431, 434, 436–437
– pontis 429
– pontocerebellaris 285, 287, 429
– quadrigeminalis 431
CLAUDIUS' cells, organ of CORTI 192
Claustrum 279, 326–327, 329, 406, 408, 428–430, 434–437, 440
Clavicula 204–205, 208–209, 242, 245, 247, 249
Clivus 16–17, 29, 35, 41
CNS (central nervous system) 260–440
– directions/positions 271
– grey matter 279
– white matter 278
Cochlea 166, 169–170, 182, 186–188, 190–191
– basal vortex 182
Cochlear labyrinth (Labyrinthus cochlearis) 170
Colliculus 221
– facialis 278, 287, 337
– inferior 195, 263, 271, 278, 332, 335, 339, 347, 431, 438
– superior 160, 263, 271, 275, 278–279, 332, 335–336, 339, 347, 431, 437
Collum 248–249, 253
– mallei 174, 180
– mandibulae 39–40
– – fracture 44
Columella 69
Columna
– anterior (Medulla spinalis) 394, 397
– fornicis 290–292, 305, 309, 322–323, 339–340, 406, 425, 434–437
– intermedia (Medulla spinalis) 394, 397
– intermediolateralis 424
– posterior (Medulla spinalis) 394, 397
Coma 271
Commissura
– alba anterior 394
– anterior 223, 231, 265, 276–277, 280–281, 287, 292, 302, 309, 323–324, 329, 339–340, 347, 352, 426, 429, 436–437, 439–440
– colliculi inferioris 195
– fornicis 265, 281, 322–323, 435
– habenularum 265, 280, 292, 329
– hippocampi 265
– lateralis palpebrarum 128, 132

Commissura
– medialis palpebrarum 128, 132
– posterior 265, 277, 280–281, 292, 302, 329, 339, 436
Commissural tracts 280–281
– hetero-/homotopic fibres 280
Complete paraplegia 416
Complete pupillary rigidity 163
Computed tomography (CT)
– chronic sinusitis 77
– eye 159
– head 294
– inner ear 182
– meningioma 259
– middle ear 182
– parapharyngeal abscess 208
– thyroglossal cyst 237
Concha
– auriculae 171
– bullosa 77
– nasalis
– – inferior 9, 29–30, 36, 70–74, 76, 79, 138, 219
– – media 10, 29, 36, 71–74, 76–77, 79, 111, 138, 153
– – superior 29, 69–70, 74, 79
– sphenoidalis 34
Conductive hearing loss 174
Condylus occipitalis 11, 18–19, 183, 212, 390
Cone (bipolar) cells of the retina 160, 162, 354
Confabulations 323
Confluens sinuum 283, 287, 311–312, 347
Congenital deafness 169
Coniotomy 204, 234
Conjunctiva 132
Conjunctivitis 128
Conus
– elasticus 223–224, 228–229, 235
– medullaris 394–395, 404
Conus medullaris syndrome 392
Convergence reaction 163
Cor, Innervation 421
Cornea 125, 152, 154, 156
– radius of curvature 155
– refractive index 155
Corneal reflex 339, 361
Corneal transplant 154
Cornu
– ammonis 322, 324
– anterius (Medulla spinalis) 279, 394, 397, 413
– frontale (Ventriculus lateralis) 286–287, 289–292, 304, 321–322, 326–327, 339, 360, 425, 427–429, 433–436, 439
– inferius (Cartilago thyroidea) 221–222, 225–226, 232
– laterale (Medulla spinalis) 397
– majus (Os hyoideum) 55, 61, 84, 104–107, 114, 210, 212, 222, 225–226, 228, 232, 234
– minus (Os hyoideum) 84, 104–107, 222, 225, 228, 234
– occipitale (Ventriculus lateralis) 267, 286–287, 289–291, 322, 326, 331, 425, 431, 435–436, 440
– posterius (Medulla spinalis) 279, 394, 397, 418
– superius (Cartilago thyroidea) 216, 221–222, 224–228, 232, 234
– temporale (Ventriculus lateralis) 286–287, 289, 291, 321, 327, 360, 406, 425–427, 429–431, 437–440
Corona
– ciliaris 156
– clinica dentis 88
– radiata 281, 432
Corpus(-ora)
– adiposum
– – buccae (BICHAT's fat pad) 52, 60, 110
– – orbitae 76, 141, 144, 146, 152–153, 159
– – preepiglotticum 213, 222, 224, 226, 229
– amygdaloideum 279, 322–323, 326–327, 352, 424, 429, 438, 440
– callosum 265, 272, 275–276, 279–281, 289–292, 302, 305, 308–309, 321–323, 326, 329, 339–340, 347, 406, 426–431, 433–436, 439
Corpus(-ora) callosum
– – agenesis 281
– cavernosum (Saccus lacrimalis) 138
– ciliare 154, 156, 159, 163
– fornicis 277, 291, 302, 322–323, 329, 429, 434
– geniculatum
– – laterale 160–161, 163, 277–278, 281, 305, 332, 335, 339, 355, 408, 430, 437
– – mediale 195, 277–278, 305, 332, 335, 339, 408, 430, 437
– hippocampi 321
– incudis 174, 176, 179
– linguae 102, 106
– mamillare 264–265, 275, 277, 279, 302, 320, 322–324, 329, 332, 335, 340, 406, 423, 426, 429, 438
– – destruction, memory loss 323
– mandibulae 10, 38–39, 104
– maxillae 27, 126
– medullare cerebelli 343
– nuclei caudati 279, 289–292, 327, 332, 339, 427, 429–430, 433, 439
– ossis
– – hyoidei 84, 104–106, 225, 234
– – sphenoidalis 29, 33, 37–38, 41, 126
– pineale 265, 271
– striatum 265, 309
– trapezoideum 195, 339
– vertebrae 404
– vitreum 154, 159
Cortex 343
– cerebelli 343
– cerebri 265, 283, 330
– lentis 157
– primary grooves 318
CORTI, organ of (Organum spirale) 166, 192
– BÖTTCHER's cells 192
– CLAUDIUS' cells 192
– HENSEN's cells 192
– inner border cells 192
– inner hair cells 192, 194, 377
– inner phalangeal cells 192
– interdental cells 192
– outer border cells 192
– outer hair cells 192, 194
– outer phalangeal cells 192
– outer pillar cells 192
– tympanic amorphous substance 192
Cortical amaurosis 161
Cortical blindness 161, 319
– cortical amaurosis 161
Cortical projection tracts 408
Corticoliberin (CRH) 334
Corticotropin (ACTH) 334
Cortisol 419
Costoclavicular syndrome 253
Cough reflex 339
Cranial base 18–19, 211
– external surface 18
– – foramina (contents) 20
– fractures 12, 20
– internal surface 17, 21
– – foramina (contents) 21
– – vessels and nerves, passageways 300
– outer surface 19–20
– – foramina (contents) 20
Cranial bones 9–14
– ossification mode 24
Cranial nerves 266, 270, 345-392
– nuclei 348–349
– – fibres qualities 348–349
– pons 338
Craniopharyngeoma 219
Craniostenosis 29
Craniosynostosis 25
Cranium 9, 28, 31
– bifidum 267
– of a newborn 22
Cremaster reflex 402
CRH (corticoliberin) 334
Cricoarytenoid joint
– arthrosis 224
– rheumatoid arthritis 224
Cricoid cartilage 221
Crista
– ampullaris 193
– arcuata 221
– conchalis 31
– ethmoidalis 29, 31, 70
– fenestrae cochleae 188
– frontalis 15–16
– galli 14, 16, 28–29, 36, 74, 77, 283
– infratemporalis 18, 34, 54
– lacrimalis
– – anterior 27, 32, 37, 126
– – posterior 32, 37, 126
– nasalis 9, 14, 30, 72
– occipitalis
– – externa 19
– – interna 16, 35
– sphenoidalis 28, 34
– supramastoidea 36
– transversa 187–188
– vestibuli 188
– zygomaticoalveolaris 27, 31
Crow's feet 8
Crus(-ra)
– anterius
– – (Capsula interna) 281, 309, 327, 332, 408, 428, 435–437, 439
– – – blood supply 306
– – (Stapes) 174, 179
– antihelicis 171
– breve (Incus) 174, 179
– cerebri 263, 277, 332, 335–336, 351, 361, 406, 438
– fornicis 289–291, 321–323, 425, 430–431, 433–434, 439
– helicis 171
– laterale (Cartilago alaris major) 68–69
– longum (Incus) 173–174, 179–180
– mediale (Cartilago alaris major) 68–69
– membranaceum
– – commune 189
– – simplex 189
– osseum
– – commune 187–188
– – simplex 188
– posterius
– – (Capsula interna) 281, 309, 327, 332, 408, 435–437
– – – blood supply 306
– – (Stapes) 174, 179
Cryptae tonsillares 102
CSF (cerebrospinal fluid) 289
– circulation 287
– cisterns 285
– fistula 282
– obstructions of the circulation 294
– – computed tomography (CT) 294
Culmen 340–341, 344
Cuneus 272, 276, 323, 433–435
Cupula 193
– cochleae 187–188
– pleurae 254
CUSHING's syndrome 334
Cuspis dentis 88
Cutis, scalp 59
Cyclopia 125
Cymba conchae 171

D

Dacryoadenitis 137, 140
– acute, narrowed eyelids 137
Dacryocystitis 140
Dacryolithiasis 111
Dacryostenosis 140
– persistent membrane of HASNER 140
Deciduous teeth 89
– dental formula 89
– upper jaw 92
Declive 340–341, 344
Decussatio
– lemniscorum 412

Index

Decussatio
– pedunculorum cerebellarium superiorum 340, 343
– pyramidum 278, 337, 395, 406
Deep cerebral veins 314
DEITERS' nucleus (Ncl. vestibularis lateralis) 191, 350, 377
Dens(-tes)
– axis 426
– caninus 86–91, 93–94, 98, 112
– decidui 22, 89, 92–93
– extractus 105
– incisivus(-i) 86–91, 93–94, 98, 112
– molaris(-es) 36, 76, 86–91, 93–94, 98, 112
– – (serotinus) 86–87, 90–91, 98, 112
– permanentes 90–93
– premolaris(-es) 86–87, 90–91, 93–94, 98, 112
Dental arch 86–87
– occlusion position 86
Dental crown 88
Dental fluorosis 91
Dental formula 89
Dental neck 88
Dental pulp 88
Dental root 88
Dentinum 88
Depression 324
– hippocampus 320
Dermatomes, spinal cord segments 393
DESCEMET's membrane (Lamina limitans posterior) 154
Descending abscess, neck 208
Desmodontium 88
Déviation conjuguée 319
Diabetes insipidus 334
Diabetic retinopathia 153
Diaphragma
– oris 104, 108
– sellae 283, 298–299, 361
Diarthrosis 222
Diastases of cranial bones 12
Diencephalon 261, 264, 266, 271–272, 277, 290, 302, 329
– development 266
– structures 277
Digitationes hippocampi 321–322
Diploë (Calvaria) 15, 59, 283, 288
Diplopia (double vision)
– damage
– – of the abducens nerve 141, 367
– – of the oculomotor nerve 142
– – of the trochlear nerve 141, 359
Directional hearing 339
Disc prolapse (herniated intravertebral disc)
– mediolateral 403
– radiculopathy 396
Discus
– articularis (Art. temporomandibularis) 42–43, 45–46, 54–55, 64
– intervertebralis 403–404
– nervi optici (blind spot) 154, 158, 294
Distal 87–88
Distress 419
Dizziness 197
– ROMBERG's test 197
– UNTERBERGER's step test 197
Dopamine (prolactostatin) 334, 340
Dorsolateral medulla oblongata syndrome 301
Dorsolateral system, paleospinothalamic tract 418
Dorsum
– linguae 85, 98, 101–102, 106, 216
– nasi 68
– sellae 14, 16–17, 28, 38, 41
Double vison *See* Diplopia
Drive disorders 324
Dry eye syndrome 97
– veins 145
Dry mouth syndrome 112
Ductuli excretorii (Gl. lacrimalis) 138
Ductus
– cochlearis 189–192
– endolymphaticus 189–190
– lymphaticus dexter 67, 250
– nasofrontalis 74
– nasolacrimalis 74, 77, 138–139
– parotideus (STENSEN's/STENON's duct) 52–53, 56, 60, 110, 112–113, 212, 217
– reuniens 189
– semicircularis(-es) 169, 190
– – anterior 186, 189
– – lateralis 179, 186, 189
– – posterior 186, 189
– sublingualis(-es)
– – major 114–115
– – minores 114–115
– submandibularis (WHARTON's duct) 76, 112–115
– thoracicus 200, 250, 254
– thyroglossus 237
– – cyst 237
– utriculosaccularis 189
Dura mater 189, 282, 288
– cranialis 76, 144, 185, 267, 283, 288, 298, 300, 313, 352–353, 361
– spinalis 213, 395, 400–401, 403–404
Dural sac 404
– opening 395
Dural septa 283
Dysarthria 391
Dysdiadochokinesis 342
Dysmetria 342
Dysostosis mandibulofacialis (FRANCESCHETTI's syndrome) 169
Dysphagia, hypoglossal nerve lesion 391
Dysphonia 226, 301

E

Ear 165–198
– development 168
– fistulas, location 237
Ectoderm, oral cavity 264
Ectropion 51, 133
EDINGER-WESTPHAL nucleus (Ncl. accessorius nervi oculomotorii) 116, 147, 163, 336, 339, 346, 350–351, 357–358, 423
Electromyography (EMG) 180
Electroneuro(no)graphy (ENG/ENoG), facial palsy 180, 374
Emesis (central vomiting), neuroleptic drugs 293
Eminentia
– arcuata 14, 37
– articularis (Art. temporomandibularis) 40, 45
– collateralis 289, 437–438, 440
– cruciformis 35
– mediana 264
– pyramidalis 177, 179–180
Enamel defects
– tetracyclines 91
– vitamin D deficiency (rickets) 91
Enamelum 88
Encephalocele (cerebral hernia) 267
Encephalocystocele 267
Encephalon 261, 266, 270, 284–285, 313, 425–433, 435, 437–440
Endolymph 193
Endonasal sinus surgery 71
β-endorphins 334
Endoscopy, nasopharynx 219
Endotracheal extubation 223
Endotracheal intubation 223
Enophthalmus, blow-out fracture 127
Enteric nervous system 419, 421
Entorhinal cortex 320, 324
Ependymal roof
– of the rhombencephalon 349
– of the third ventricle 264–265
Ependymum 291
Epicritic sensibility 414
– neurons 412
Epidural anaesthesia 282, 403
Epidural haematoma 15, 315
Epiglottis 84, 101–102, 216, 218, 226, 228, 231–232, 417
– acute bacterial infection 232
– cartilage 221
– position at rest and when swallowing 229
Epilarynx 230
Epilepsy, callosotomy/split brain 281
Epiphora 51, 133, 140
Epiphysis (Corpus pineale) 265
Epithalamus 264, 277, 329
Epithelium anterius 154
Epitympanon 175
ERB's point (Punctum nervosum) 56, 241
Ethmoidal bone 30
Ethmoidal cells 151
– inflammation 32
– infraorbital (HALLER's cells) 77–78
– topography 77
– variants 77–78
EUSTACHIAN tube (Tuba auditiva [auditoria]) 169–170, 173, 176–177, 179, 181, 183–185, 190, 369, 378
– development 168
Excavatio disci 154
Exophthalmus
– GRAVES` syndrome 239
– hyperthyroidism 239
External acoustic meatus 170, 172
Extraocular muscles 141, 143, 159
– function 142
– innervation 142
– lesions of supplying cranial nerves 357
Extrapyramidal motor system (EPMS) 409
Extrapyramidal tracts 398
Extrinsic muscles of the tongue 106–107
Eye cup 124, 261
Eye cup stalk 124
Eye muscle paralysis 143
– orbital apex syndrome 144
Eye (Oculus) 128–129
– arteries 145
– computed tomography 159
– development 100, 124–125, 154
– developmental defects 125
– dry eye syndrome 97
– MRI 159
– nerves 150
– palpebral height/width 129
– proportions 129
– refractive index of the entire eye 155
– skin regions 129
– surface, structures 132
– ultrasound examination 159
Eye socket (Orbita) 32, 126, 152–153
– arteries 145–149
– entrance/opening 134–135
– – arteries, veins and nerves 134
– floor 31, 127
– frontal section 153
– horizontal section 150
– lateral wall 33, 126
– medial wall 37, 126
– nerves 146–150
– topography 151
– veins 145
Eyeball (Bulbus oculi) 154, 159
– blood vessels 155
– dimensions 155
Eyelid
– acute dacryoadenitis 137
– oculomotor paralysis 128
– tightening 128
– widening 128
– – facial palsy 128
Eyelids 132
– *See also* Palpebra

F

Face
– ageing 8
– cleft formation 98
– morphometry and proportions 6, 10
– planes of reference 11
– subcutaneous fat compartments 47–48
– tension lines 7
Face lifting 58
– SMAS (superficial muscular aponeurotic system) 48
Facial area, inflammations, phlebitis/venous sinus thrombosis 63
Facial diagnostic 180
Facial muscles 51–53, 60, 130, 212
– parylysis, testing of the motor function 374
Facial palsy 3, 64
– BELL's phenomenon 3, 64, 130, 373
– electroneurography 374
– SCHIRMER's test 374
– stapedial reflex test 374
– testing of the mimetic muscles 374
– tightening of the eyelids 128
Facial portion of the head 218
Facial region, spread of germs, sinus thrombosis 145
Facial skin, innervation areas 367
Facies
– anterior
– – (Iris) 154
– – (Lens) 156–157
– – (Maxilla) 27
– – palpebrae 132
– – partis petrosae 16, 37
– articularis
– – (Art. temporomandibularis) 54
– – arytenoidea cricoideae 221
– – (Incus) 174
– – (Malleus) 174
– – (Os temporale) 36, 40
– – thyroidea 221, 223, 226
– cerebralis
– – (Os sphenoidale) 38
– – (Os temporale) 37
– contactus (Dens molaris) 88
– distalis (Dens molaris) 88
– externa
– – (Os frontale) 26
– – (Os parietale) 53
– inferior linguae 103, 107, 112
– infratemporalis (Maxilla) 27
– interna
– – (Os frontale) 33
– – (Squama frontalis) 28
– lateralis
– – cerebri 303
– – (Os zygomaticum) 9
– lingualis (Dens molaris) 88
– maxillaris (Os sphenoidale) 34
– medialis hemispherii cerebri 302
– mesialis (Dens molaris) 88
– nasalis (Maxilla) 31, 70
– orbitalis
– – (Ala major ossis sphenoidalis) 10, 32–34, 126
– – (Maxilla) 27, 126–127
– – (Os frontale) 126–127
– – (Os sphenoidale) 74
– – (Os temporale) 26
– – (Os zygomaticum) 9, 32, 126
– posterior
– – (Cornea) 156
– – (Iris) 154, 156
– – (Lens) 154, 157
– – palpebrae 132
– – partis petrosae 37
– temporalis
– – (Ala major ossis sphenoidalis) 34, 183
– – (Os frontale) 53
– – (Os temporale) 26, 36
– vestibularis (Dens molaris) 88
Falx
– cerebri 283, 304, 306, 347, 427
– cerebri (cerebral crescent) 283
Fascia
– cervicalis 51–52, 60, 110, 113, 204, 207–209, 213, 218, 235–236
– dentata 320, 322
– masseterica 110, 113, 209, 217
– oesophagea 207
– parotidea 51, 110, 208, 217
– pharyngobasilaris 210–212, 216
– temporalis 52
Fasciculus(-i)
– anterolateralis 412
– arcuatus 281
– ciliaris 130
– cuneatus (BURDACH's tract) 278, 339, 397–398, 412
– gracilis (GOLL's tract) 278, 339, 397–398, 412
– infraorbitalis 130
– interfascicularis (SCHULTZE's comma tract) 397
– longitudinalis
– – inferior 280–281
– – medialis 197, 340, 343, 397, 406
– – superior 280–281
– mamillotegmentalis 333
– mamillothalamicus 323, 333, 406, 437
– medialis (Plexus brachialis) 245
– muscularis accessorius 210
– proprii
– – anteriores 397
– – laterales 397
– – posteriores 397
– septomarginalis (oval bundle of FLECHSIG) 397
– thalamocorticales 281
– uncinatus 280–281
Fastigium 287, 340
Fenestra
– cochleae 177–178, 188–189, 192
– vestibuli 176–178, 187–188, 192
Fever, acetylsalicylic acid 293
Fibrae
– arcuatae cerebri 280
– – internae 414
– circulares (M. ciliaris) 154
– corticonucleares 332, 374
– corticoreticulares 332, 408
– corticorubrales 332, 408
– corticospinales 281, 332, 408
– corticothalamicae 332, 408
– meridionales (M. ciliaris) 154
– olivospinales 397
– parietooccipitopontinae 332
– postcommissurales 324
– precommissurales 324
– thalamoparietales 332, 408, 412, 414
– zonulares 156
α_1-fibres 410
Filum(-a)
– olfactoria 72, 81, 352
– – projections and synaptic connections 353
– radicularia 404
– terminale 394–395, 404
Fimbria hippocampi 289, 291, 320–324, 327, 352, 430–431, 435–437, 440
Final motor pathway 410
First molar tooth 88
Fissura(-ae)
– calcarina 354
– cerebelli 343
– hippocampalis 325
– horizontalis (Cerebellum) 43, 336, 341, 344
– infraorbitalis 96
– longitudinalis
– – cerebri 272, 274–275, 279, 284, 290, 309, 406, 425, 428–438
– – superior 265
– mediana
– – anterior 268, 279, 395
– – posterior 278, 394
Fissura(-ae)
– orbitalis
– – inferior 9, 18–20, 31–32, 36, 96–97, 126–127, 136, 141, 144
– – – content 20
– – superior 9, 16–17, 21, 32, 34–36, 38, 126, 143–144, 300
– – – content 21
– petrooccipitalis 16
– petrosquamosa 16, 36, 40
– petrotympanica (GLASERIAN fissure) 36–37, 40
– pontomedullaris 337
– posterolateralis 43, 342, 344
– prima (Cerebellum) 43, 262, 341–342, 344
– pterygoidea 38
– pterygomaxillaris 126
– secunda (Cerebellum) 43, 344
– sphenopetrosa 17, 19–21, 40, 181, 185, 299, 369
– – content 20–21
– transversa cerebri 434
– tympanomastoidea 36
– tympanosquamosa 40
FLECHSIG, oval bundle of (Fasciculus septomarginalis) 397
FLECHSIG's tract (Tractus spinocerebellaris posterior) 343, 397–398, 413
Flexura
– cervicalis 261
– mesencephalica 261
Flocculus 43, 339, 342–343, 431
Floor of the mouth
– compartments 108
– muscles 105
– spreading abscesses 108
Fluorapatite 92
Fluorescence angiography, ocular fundus 158
Folic acid deficiency during pregnancy, uvula bifida 98
Folium vermis 340–341, 344
Follicle-stimulating hormone (FSH) 334
Fontanelle(s) 23
– paranasal sinuses 78
Fonticulus
– anterior 22–23, 31
– mastoideus 22–23, 28
– posterior 22–23, 28, 31
– – defect 267
– sphenoidalis 22–23
Food intake (nutritional) behaviour 423
Foramen(-ina)
– alveolaria 27, 31, 96
– apicis dentis 88
– caecum 16, 80
– – linguae 101–103, 237
– cribrosa 14, 16, 21, 28–30, 69, 127, 300
– ethmoidale
– – anterius 32, 37, 126
– – posterius 32, 37, 126
– frontalis 126
– incisivum(-a) 18–20, 30–31
– – content 20
– infraorbitale 10, 22, 27, 32, 75, 126
– interventriculare (foramen of MONRO) 265–266, 282, 286–287, 290–292, 302, 311, 314, 323, 329, 339–340, 347, 435
– intervertebrale 404
– jugulare 16–21, 186–187, 215, 300, 378–379, 381–382, 384, 386
– – content 20–21
– lacerum 16–21, 183, 186–187, 300
– – content 20–21
– linguale 39
– magnum 16–18, 20–21, 28, 35, 300
– – content 20–21
– – defects 267
– mandibulae 38–39, 87, 105
– mastoideum 13–14, 16, 18, 20, 36–37
– mentale 10–11, 22, 38–39, 60, 86–87, 93–94, 105
– of LUSCHKA (Apertura lateralis ventriculi quarti) 278, 286–287, 339–340, 439

Foramen(-ina)
– of MAGENDIE (Apertura mediana ventriculi quarti) 282, 286–287, 347
– of MONRO (Foramen interventriculare) 265–266, 282, 286–287, 290–292, 302, 311, 314, 323, 329, 339–340, 347, 435
– ovale 16–21, 31, 35, 183, 186–187, 300
– – content 20–21
– palatinum(-a)
– – majus 18–20, 30, 87, 98
– – – content 20
– – minora 19–20, 30
– – – content 20
– parietale 12–14
– rotundum 16–17, 21, 33–35, 38, 96, 300
– – content 20–21
– singulare 187
– sphenopalatinum 29, 37, 70, 81, 96, 126
– spinosum 16–21, 31, 35, 186, 300
– – content 20–21
– stylomastoideum 18–20, 37, 178, 180–181, 369–370
– – content 20
– supraorbitale 9, 22, 126–127
– venae basivertebralis 404
– zygomaticofaciale 9, 31–32, 126
– zygomaticoorbitale 33, 126, 136
Forceps
– major 280
– minor 280, 433, 435–436
Forebrain, development 265
FOREL's axis 271
Formatio reticularis 343, 418
Fornix 276–277, 281, 289–292, 302, 322–324, 326, 329, 339–340, 347, 406, 425–427, 429–431, 433–437, 439
– conjunctivae
– – inferior 128, 138, 152
– – superior 138, 152
– fibre connections 323
– sacci lacrimalis 131, 138
Fossa
– canina 27
– cerebellaris 17, 35
– condylaris 19
– cranii
– – anterior 17, 151
– – media 17, 176, 182
– – posterior 17, 182, 384
– digastrica 38–39
– glandulae lacrimalis 30, 126–127, 140
– hypophysialis 16, 28, 35, 41, 298, 361
– incisiva 18–20, 30, 69
– incudis 177, 179
– infraorbitalis 141
– infratemporalis 19, 31
– interpeduncularis 263, 275, 278–279, 320, 340, 406, 427, 438
– jugularis 18, 37
– lateralis cerebri 272, 275–276, 289, 427–428
– mandibularis 19, 36–37, 40, 43, 45–46, 54–55, 100, 183
– omotracheale (musculare) 4
– pterygoidea 14, 38, 69
– pterygopalatina 31, 33, 37, 96–97, 126
– – arteries 97
– – veins 97
– retromolaris 38
– rhomboidea 278–279, 339–340
– sacci lacrimalis 11, 31, 33, 37, 126–127, 131
– scaphoidea 38
– subarcuata 16, 37
– supraclavicularis
– – major (Trigonum omoclaviculare) 4
– – minor 4, 209
– supratonsillaris 85, 101
– temporalis 151
– triangularis 171
Fossula(-ae)
– fenestrae
– – cochleae 177–178, 180, 188
– – vestibuli 178

Fossula(-ae)
– petrosa 18, 37
– tonsillares 102
Fovea
– centralis 154, 158, 162, 354
– oblonga 221
– pterygoidea 38
– sublingualis 38–39
– submandibularis 38–39
– superior sulci limitantis 278
– triangularis 221
– trochlearis 126
Foveola(-ae) 158
– granulares 15
– suprameatalis 36
FRANCESCHETTI's syndrome (dysostosis mandibulofacialis) 169
FRANKFORT horizontal plane (line) (Linea horizontalis auriculoorbitalis) 11, 315
Frenulum
– labii
– – inferioris 83, 85
– – superioris 85
– linguae 103, 107, 112
– veli medullaris superioris 339, 438
FRENZEL's glasses, nystagmus test 197
FREY's syndrome (gustatory sweating), tumours of the parotid gland 110
Frons 9
Frontal bone 9, 26, 30
Frontal eye field 319
Frontal lobe 272
Frontal sinus 151
– development 73
Frontal suture 31
FSH (follicle-stimulating hormone) 334
Fundus
– meatus acustici interni 187
– oculi 158, 294
Fungal infections of the oral mucosa 83
Funiculus
– anterior (Medulla spinalis) 394–395
– lateralis (Medulla spinalis) 394–395
– posterior (Medulla spinalis) 394–395, 430

G

Gag reflex 104
– lack of 381
– – lesion of the N. vagus [X] 381
Galea aponeurotica 51–53, 56–57, 59–60, 76, 283, 288
GALEN, anastomosis of (Ansa GALENI) 232
GALEN, vein of (V. magna cerebri) 160, 287, 290, 292, 302, 304, 311–312, 314, 340, 347, 431, 436
Ganglion cells of the retina 160, 162, 354–355
Ganglion(-ia)
– cervicale
– – inferius 200, 254
– – medium 200, 215–216, 245, 253–254, 422
– – superius 97, 163, 215–216, 245, 330, 378, 422
– cervicothoracicum [stellatum] 215–216, 253, 421–422
– ciliare 116, 147–148, 150, 163, 356, 358, 362–364, 421, 423
– coeliaca 382–383, 421–422
– geniculi 97, 118, 180–181, 186, 191, 369–370, 374, 417
– – lesion 369
– impar 396, 422
– inferius
– – (N. glossopharyngeus [IX]) 182, 215, 378–380, 385, 417, 423
– – [nodosum] (N. vagus [X]) 215–216, 381–384, 386–387, 417, 420, 423
– lumbalia 422
– mesentericum
– – inferius 421
– – superius 382–383, 421

Ganglion(-ia)
– oticum 116–117, 362–364, 378–380, 421, 423
– pelvica 422–423
– pterygopalatinum 96–97, 116, 118, 137, 150, 356, 362–364, 370–372, 421, 423
– sacralia 422
– sensorium nervi spinalis 282, 395–396, 412–413
– spinale 393, 412
– spirale cochleae 191, 194–195, 375–377
– stellatum [cervicothoracicum] 215–216, 253, 421–422
– sublinguale 116
– submandibulare 61, 108, 113, 115–116, 362–364, 370–372, 421, 423
– superius
– – (N. glossopharyngeus [IX]) 378–380, 385
– – (N. vagus [X]) 215, 381–384, 386
– sympathicum accessorium 245
– thoracica 422
– trigeminale (Ganglion semilunare, GASSERIAN ganglion) 95, 118, 146–147, 180, 185, 299, 360–363, 412, 417
– vestibulare 186, 191, 194, 196, 375–377
GASSERIAN ganglion (Ganglion trigeminale, Ganglion semilunare) 95, 118, 146–147, 180, 185, 299, 360–363, 412, 417
Gaze palsy, blow-out fracture 127
General somatic afferent fibres (GSA) 349, 351, 371
– N. glossopharyngeus [IX] 379
– N. vagus [X] 384
General somatic efferent fibres (GSE) 349, 351, 371
– N. hypoglossus [XII] 391
– N. vagus [X] 384
General visceral afferent fibres (GVA), N. vagus [X] 384
General visceral efferent fibres (GVE) 349, 351, 384
– N. glossopharyngeus [IX] 379
– N. vagus [X] 384
Geniculum nervi facialis 376
Genu
– capsulae internae 281, 309, 327, 332, 408, 429, 435–436
– – blood supply 306
– corporis callosi 276, 280–281, 290–292, 302, 323, 426, 434–435, 439
German horizontal line (Linea horizontalis auriculoorbitalis) 315
GH (growth hormone) 334
– overproduction 334
GHRH (growth hormone releasing hormone, somatoliberin) 334
Gigantism 334
Gingiva 83, 85, 87, 112, 114
– marginalis mandibulae/maxillae 83
– propria maxillae 83
– sensory innervation 99
Glabella 9, 26, 68
Glandula(-ae)
– buccales 82, 111
– labiales 82, 84, 111
– lacrimalis 76, 97, 116, 122, 135–138, 141, 145–148, 150, 153, 421
– laryngealis 228, 233
– lingualis(-es) 103, 111, 115–116
– – anterior (gland of BLANDIN-NUHN) 103, 116
– molares 111
– nasales 72, 116
– palatinae 98, 111, 116
– parathyroidea
– – inferior 210, 216, 232, 235–236, 238
– – superior 210, 232, 238
– parotidea 11, 60, 64, 67, 110–111, 113, 116, 172, 204–205, 208, 210, 217, 240, 248–249, 252, 378
– – accessoria 52, 110, 113
– – swelling 53
– pharyngeales 210

Glandula(-ae)
– pinealis 277–278, 290, 292–293, 302, 309, 326, 329–330, 335–336, 339–340, 347, 351, 431, 436
– pituitaria [Hypophysis] 298
– salivariae
– – majores 111, 115
– – minores 111
– – oris 111, 421
– sublingualis 11, 61, 76, 83, 108–109, 113–116, 370
– submandibularis 52, 108, 111, 113–116, 204, 210, 242–243, 248, 252, 370
– – abscess formation in the fascial compartment 252
– suprarenalis 421
– tarsales (MEIBOMIAN glands) 131–132
– thyroidea 67, 204–205, 207, 210, 215, 218, 232, 234–239, 243–244, 249, 251
GLASERIAN fissure (Fissura petrotympanica) 36–37, 40
Glasgow Coma Scale 271
Glaucoma 156, 158
– papilloedema 158
Globus pallidus 309, 326, 329–330
– lateralis 279, 327–329, 406, 408, 429, 436, 439–440
– medialis 279, 327–329, 406, 408, 429, 436, 439–440
Glomerulus, Fila olfactoria 353
Glomus
– caroticum 378
– – chemoreceptors 295
– choroideum 291, 304, 440
Glossopharyngeal neuralgia 380
Glottis (glottic space, transglottic space) 230, 233
– during opening and closing 223
– oedema 228
Glucocorticoids 419
Gnathion 9
GnRH (gonadotropin releasing hormone) 334
GOLL's tract (Fasciculus gracilis) 278, 339, 397–398, 412
GOWERS' tract (Tractus spinocerebellaris anterior) 343, 397–398, 413
Granular cells
– isocortex 317
– olfactory nerves 353
Granular layer, isocortex 317
Granulationes arachnoideae (PACCHIONIAN granulations) 258, 282–284, 287–288, 313
GRATIOLET's radiation (Radiatio optica) 160–161, 327, 332, 354–355, 408, 435–437
– lesions 161
GRAVES' disease 152, 239
– orbitopathy 239
Greater radicular artery syndrome 399
Grey matter, CNS 279
Grey senile cataract 157
Growth hormone (GH, somatotropic hormone, STH) 334
GSA (general somatic afferent fibres) 346, 348–349, 351, 371
– N. glossopharyngeus [IX] 379
– N. vagus [X] 384
GSA (general somatic efferent fibres) 346, 348–349, 351
– N. hypoglossus [XII] 391
GUILLAIN-BARRÉ's syndrome 410
Gustatory impairment 381
– lesions of the N. vagus [X] 381
Gustatory pathway 417
Gustatory sweating (FREY's syndrome), tumours of the parotid gland 110
Gustometry, facial palsy 374
GVA (general visceral afferent fibres) 346, 348–349, 351, 384
– N. glossopharyngeus [IX] 379
– N. vagus [X] 384
GVE (general visceral efferent fibres) 346, 348–349, 351, 371
– N. facialis [VII] 373
GVE (general visceral efferent fibres)
– N. vagus [X] 384
Gyrification (surface enlargement), telencephalon 266
Gyrus(-i)
– ambiens 325, 352, 438
– angularis 273–274, 276, 431, 433
– cerebral hemispheres 272
– cerebri 273–276, 283
– cinguli 272, 275–276, 279, 281, 291, 320, 322, 418, 424, 426–437, 439
– dentatus 291, 320–324, 352, 430–431, 437
– fasciolaris 322–323
– frontalis
– – inferior 273, 276, 319, 427–430, 434–437
– – medius 273–274, 276, 427–430, 432, 434
– – superior 273–274, 276, 427–430, 432–433
– insulae 279, 327, 406, 427–429
– intralimbicus 321, 325
– lingualis 275, 431, 437–438
– occipitales 433–435, 437
– occipitofrontalis
– – lateralis 430
– – medialis 430
– occipitotemporalis
– – lateralis 275–276, 320, 429–431, 438
– – medialis 275–276, 291, 320, 429–431
– orbitales 159, 275–276, 428, 438
– pallidus lateralis 429
– parahippocampalis 28, 272, 275–276, 291, 320–323, 352, 427, 429–431, 436–440
– paraolfactorius 352
– paraterminalis 276–277, 329, 428, 437, 439
– postcentralis 273–274, 276, 319, 412, 415, 417–418, 430–434
– precentralis 273–274, 276, 281, 319, 374, 406, 415, 430, 432–434
– – arteries 308
– preterminalis 352
– rectus 275, 322, 428, 438–439
– semilunaris 321, 325
– submarginalis 273
– supramarginalis 274, 276, 431–432
– temporalis(-es)
– – inferior 273, 275–276, 320, 427–431
– – medius 273, 276, 429–431, 435–437
– – superior 273, 276, 427–431, 434–437
– – transversi (HESCHL's transverse convolutions) 195, 319
– uncinatus *See* Uncus

H

Habenula 436
Hair cells, organ of CORTI 192, 194, 377
HALLER's cells (infraorbital cells) 77–78
Hamulus
– laminae spiralis 188
– pterygoideus 14, 18, 28–29, 31, 33–34, 37–38, 41, 55, 60, 69, 84, 98–100, 183–184, 212
Hard palate 30, 98
– sensory innervation of the mucous membrane 99
Harelip (cleft formation) 98
HASNER's membrane, persistent, dacryostenosis 140
HASNER's valve (Plica lacrimalis) 74, 138
Head
– arteries 59, 61
– computed tomography (CT) 294
– DOPPLER ultrasound examination 305
– drainage of the compartments 251
– facial portion 218
– frontal portion 76
– inner arteries 295
– innervation of the glands 116
– lymph nodes 66, 250
– nerves 56–61
– of a newborn 218–219
– regions 4–5, 9, 56–61
Head
– sensory innervation of the skin 65, 242
– superficial lymph vessels 66, 250
– veins 311
– vessels 56–58, 60
HEAD's zones 393
Hearing sense 348
Helicotrema 189
Helix 171
Hemianopsia 161, 355, 408
– lesions of the thalamic nuclei 331
Hemiataxia 301
Hemiballism 328, 410
Hemilaryngectomy 221
Hemiplegia (BROWN-SÉQUARD's syndrome) 306, 405, 408, 416
– apoplexy 303
– brachiofacial 303
Hemispherium cerebelli 285, 301, 310, 336, 341–342, 431, 438–440
HENSEN's cells, organ of CORTI 192
Hernia
– cerebri (cerebral hernia, encephalocele) 267
– of the tonsilla cerebri 315
Herniated intravertebral disc (disc prolapse), radiculopathy 396, 403
HESCHL's transverse convolutions (Gyri temporales transversi) 195, 319
HEUBNER's artery (A. centralis longa) 298–299, 306
Hiatus
– canalis nervi petrosi majoris/minoris 300
– maxillaris 29, 70, 78
– oesophageus 381
– semilunaris 29, 70–71, 74, 78–79
– – inferior/superior 77
Hilum nuclei
– dentati 343
– olivaris inferioris 406
Hindbrain 263
Hippocampus 279, 289–291, 321–324, 417, 425, 427, 429, 437–440
– functional cortical areas 320–321
– opened lateral ventricle 321
– precommissuralis 321
– proprius 320
– retrocommissuralis 321
– supracommissuralis 321
Hippocampus formation 323
– connections 324
– development 320
Hoarseness, lesion of the N. vagus [X] 381
Homeostasis 419
Homeostatic negative feedback 419
Homonymous hemianopsia 161, 355
Hordeolum (stye) 133
Horizontal cells of the retina 162, 354
Hormones of the adenohypophysis/neurohypophysis 334
HORNER's muscle (M. orbicularis oculi) 51–53, 60, 130–132, 138–140, 152, 370
– paralysis 51
HORNER's syndrome 301
HUNTINGTON's disease 328, 410
Hydrocephalus
– computed tomography (CT) 294
– e vacuo, externus/internus 294
Hydrops cochleae 190
Hyoid arch, cranial nerves 349
Hyoid bone 104–105, 222–224
Hypaesthesia, cerebral infarction 303
Hyperacusis 179
Hyperkinesia, choreatic 328
Hyperparathyroidism 236
Hyperthyroidism 239
– GRAVES' disease 152
Hypogeusia 417
Hypophyseal pouch 264
Hypophysis (Glandula pituitaria, pituitary gland) 144, 277, 285, 298–300, 302, 340, 361, 426, 429
– development 264
– pharyngeal 219

Hyposmia 353
– nasal septum deviation 76
Hypothalamus 264–265, 271, 277, 279, 302, 324, 329, 333, 340, 417–418, 424, 429, 436–438
– afferent and efferent fibres 334
– nuclei
– – of the chiasmatic or anterior group 333
– – of the intermediary or middle group 333
– – of the posterior group 333
– parts 332
Hypothyroidism 239
Hypotympanon 175

I

ICA (internal carotid artery) 296, 307
Impressio(-nes)
– gyrorum 16
– trigeminalis 177–178
Impression fracture of the skull 12
Incisor tooth 88
Incisura
– anterior 171
– frontalis 26, 32, 126
– interarytenoidea 231–232
– intertragica 171
– jugularis 35
– lacrimalis 27, 126
– mandibulae 38, 46
– mastoidea 13, 19, 36–37
– nasalis (Maxilla) 27
– parietalis 36–37
– preoccipitalis 272–273, 276
– pterygoidea 34, 38
– sphenopalatina 31
– supraorbitalis 26, 30, 127
– tentorii 283
– thyroidea
– – inferior 221
– – superior 221–222, 224–225
– tympanica 180
Incus 168, 170, 173–174, 179–182, 192, 369, 376
Indusium griseum 317, 321, 323, 430, 434–435
Inferior nasal concha 30, 72
Infiltrative anaesthesia, teeth 95
Infrahyoid muscles 204–205
Infraorbital ethmoidal cells (HALLER's cells) 77–78
Infratentorial herniation 335, 341
Infundibulum 266, 275, 298, 302, 347, 361, 425
– ethmoidale 77–78
– hypophysis 264–265, 277, 332, 361
Inion 13
Inner border cells of the organ of CORTI 192
Inner capsule 332, 408
– somatotopic arrangement 408
Inner ear 166, 168–170, 186
– blood supply 190
– computed tomography 182
– innervation 190
Inner granular layer, isocortex 317
Inner hair cells of the organ of CORTI 192, 194, 377
Inner phalangeal cells of the organ of CORTI 192
Inner pillar cells of the organ of CORTI 192
Inner pyramidal layer of the isocortex 317
Inner subarachnoid spaces 287
Inner tongue muscles 103
Insula [Lobus insularis] 266, 289–291, 301, 303, 306, 309, 327, 408, 417, 424–426, 430, 434–436, 440
Insular cortex, anterior region 417
Interdental cells, organ of CORTI 192
Intermediate zone
– of the spinal cord 268
– of the temporomandibular joint 43
Internal acoustic meatus 187
Internal jugular vein *See* Vena jugularis interna
Interneurons 410, 420
Interscalene block of the brachial plexus 253
Intestinum tenue, Innervation 421
Intracerebral bleeding 316
Intraretinal chain of neurons 354
Intubation granuloma of the Plica vocalis 231
Intumescentia
– cervicalis 393–395
– lumbosacralis 393–395
Iridocorneal angle 156
Iris 128, 154, 156, 163
Ischaemia tolerance, brain 295
Isocortex 320
– lamination 317
Isolated cleft palate 98
Isthmus
– faucium 84–85, 98
– glandulae thyroideae 213, 229, 234, 236, 248
– gyri 321
– – callosi 321
– – cinguli 275–276, 320, 436

J

JACOBSON's nerve (N. tympanicus) 116, 179, 182, 378–380
Jaw
– cleft formation 98
– planes of references 11
Jowl fat compartment 48
Jugular pulse 63
Jugum(-a)
– alveolaria 27, 86
– sphenoidale 35

K

Keratitis 51, 154
Keratoconus 154
KERNIG's sign 288
Keystone area of the nose 69
KILLIAN's muscle (Pars fundiformis of the Pars cricopharyngea) 210
KILLIAN's triangle 210
– pharyngeal diverticulum 210

L

LABBÉ, anastomosis of 311
LABBÉ, vein of (V. anastomotica inferior) 313
Labiomental fold 8, 82
Labium
– inferius oris 82, 84, 101, 103
– superius oris 82, 84, 101
Labyrinthitis 193
– otitis media 176
Labyrinthus
– cochlearis 170
– ethmoidalis 30, 127
– membranaceus 189–190
– osseus 187–188, 190
– vestibularis 170
Lacertus musculi recti lateralis 143
Lacrimal apparatus 138–140
Lacrimal canaliculi 131
Lacrimal ducts, dimensions 139
Lacrimal gland 132, 135
– anastomosis 116
– connective tissue capsule 135
– inflammation 137
– innervation 136–137, 150
Lacrimal points 130
Lacrimal sac 131
– inflammation 140
Lacunae laterales 258, 283, 288, 313
Lacus lacrimalis 128, 138
Lagophthalmus 51, 130, 133, 369
LAIMER's triangle 210
Lambda 12
Lamina
– affixa 290–291, 304, 321, 339, 430, 433
– alba (Cerebellum) 343
– basilaris 191
– cartilaginis cricoideae 213, 221–224, 229, 233
– choroidocapillaris 155
– cribrosa
– – (Os ethmoidale) 14, 16–17, 28–30, 36, 69, 127, 352–353
– – – content 21
– – sclerae 154
– dextra (Cartilago thyroidea) 221–222
– externa (Calvaria) 15, 59, 283, 288
– granularis externa/interna (Isocortex) 317
– horizontalis (Os palatinum) 18, 28–31, 70, 183
– interna (Calvaria) 15, 59, 283, 288
– lateralis
– – (Cartilago tubae auditivae [auditoriae]) 100, 183, 185
– – (Proc. pterygoideus ossis sphenoidalis) 14, 18, 28, 30, 34, 37–38, 41, 60, 99–100, 183, 212
– limitans
– – anterior (BOWMAN's membrane) 154
– – posterior (DESCEMET's membrane) 154
– medialis
– – (Cartilago tubae auditivae [auditoriae]) 100, 183, 185
– – (Proc. pterygoideus ossis sphenoidalis) 14, 18, 28–30, 34, 38, 41, 60, 70, 84, 99–100, 183
– medullaris
– – lateralis 327, 406, 429, 436
– – medialis 327, 331, 406, 429, 436
– membranacea (Tuba auditiva [auditoriae]) 183–184
– modioli 187–188
– molecularis (Isocortex) 317
– orbitalis (Os ethmoidale) 31–32, 36–37, 73, 126–127
– papyracea (Os ethmoidale) 36
– perpendicularis
– – (Os ethmoidale) 14, 28, 30, 36, 41, 69, 72, 127
– – (Os palatinum) 29, 31, 70, 96
– pretrachealis (Fascia cervicalis) 204, 207–209, 213, 235–236
– prevertebralis (Fascia cervicalis) 207–208, 213, 217, 236
– profunda (Fascia temporalis) 52
– pyramidalis externa/interna (Isocortex) 317
– sinistra (Cartilago thyroidea) 221, 225
– spiralis
– – ossea 187–188, 191–192
– – secundaria 187–188
– superficialis
– – (Fascia cervicalis) 51–52, 60, 110, 113, 207–209, 213, 218, 236
– – (Fascia temporalis) 52
– tecti 278, 344
– terminalis 265, 277, 302, 323, 329, 340, 347, 429, 436–438
– vasculosa (Uvea) 155
Language centres
– motor centre (BROCA's centre) 319
– sensory centre (WERNICKE's centre) 319
Large fontanelle 23
Large salivary glands 111
LARSELL's classification, structure of the cerebellar cortex 344
Laryngeal cartilage 222, 224
Laryngeal muscles 225–227
– paralysis 238, 381
Laryngeal skeleton, fractures 221
Laryngomalacia 221
Laryngopharynx 213
Laryngoscopy 231
Larynx 213, 222–224, 228–230, 232–233, 235, 251

Larynx
– acute oedema of the entrance 232
– arteries and nerves 232
– compartments 230
– cross-section 233
– determining the spreading of tumour cells 230
– frontal section 235
– lymph nodes and lymph vessels 251
– midsagittal section 229
– squamous cell carcinoma 229
– supraglottic carcinoma 201
Lateral cervical region 202–203
– vessels and nerves 240–245
Lateral neck cysts 236–237
Lateral temporal cheek fat compartment 48
Lateral ventricles 265, 286, 289–292
– temporal horn 291
– topography 289
Laterotrusion, temporomandibular joint 44
LE FORT fractures 9
Leg paralysis 308
Lemniscus
– lateralis 195, 336, 338
– medialis 336, 338, 412, 414
Lens 125, 154, 156–157, 159
– development 124
– luxation, MARFAN's syndrome 156
– placode 124
– refractive index 155
– vesicle 124
Leptomeninx 282
Leukoplakia
– oral mucosa 83
– tongue 104
LH (luteinising hormone) 334
Ligamentum(-a)
– anulare(-ia) 222, 224
– – stapediale 175
– cricoarytenoideum 222–224
– – posterius 221
– cricopharyngeum 222–224
– cricothyroideum medianum [conicum] 204, 213, 218, 222–225, 229, 234, 254
– cricotracheale 222, 235
– denticulatum 282, 400
– hyoepiglotticum 213, 218, 224, 226, 229
– incudis
– – posterius 175, 179
– – superius 175, 179
– interspinale 404
– laterale (Art. temporomandibularis) 41–42, 52–53
– longitudinale
– – anterius 253, 404
– – posterius 404
– mallei
– – anterius 175
– – laterale 175–176
– – superius 175–176, 179
– mediale (Art. temporomandibularis) 60
– ossiculorum auditus 175
– palpebrale
– – laterale 122, 134–135
– – mediale 52, 60, 122, 130–131, 134–135, 138, 140
– petrolinguale 296
– pterygospinale 41
– sphenomandibulare 41, 55, 60–61, 84, 210
– spirale 191–192
– stylohyoideum 84, 105, 107, 205, 209–210, 212
– stylomandibulare 41, 60, 84, 210
– suspensorium bulbi (LOCKWOOD's ligament) 153
– thyroepiglotticum 213, 222–224, 229
– thyrohyoideum
– – laterale 222, 225
– – medianum 204, 213, 218, 222–225, 229, 234
– vestibulare 224, 228, 235
– vocale 221, 223–225, 227–228, 233, 235
Limbic system 323, 411, 418
Limbus
– anterior palpebrae 128, 132
– corneae 154
– GIACOMINI (ligament of the uncus) 321, 325
– posterior palpebrae 128, 132
– spiralis 192
Limen
– insulae 272
– nasi 72
Linea
– arcuata
– – inferior 228, 235
– – superior 228, 235
– frontomentalis 68
– horizontalis
– – auriculoorbitalis (FRANKFORT horizontal plane/line) 11, 315
– – supraorbitalis 315
– mylohyoidea 38–39, 41
– nuchalis
– – inferior 13, 18–19
– – superior 13, 18
– obliqua
– – (Cartilago thyroidea) 221
– – (Mandibula) 38
– temporalis
– – inferior 11–12, 53
– – superior 11–12
Lingua 75–76, 84, 101–103, 106, 108–109, 112, 115, 426
Lingual 87
Lingual gland 101
Lingula
– cerebelli 339–341, 343–344
– mandibulae 38–39
– sphenoidalis 16, 35, 38
Lip-jaw-palate cleft 98
Lobulus
– auriculae 171
– biventer 43, 341
– centralis 340–342
– flocculonodularis 342
– gracilis 43
– paracentralis 276, 412
– parietalis
– – inferior 273–274, 276, 431, 433
– – superior 273–274, 276, 431
– quadrangularis
– – anterior 43, 341
– – posterior 43, 341
– semilunaris
– – inferior 43, 341
– – superior 43, 341
– simplex 43, 341
Lobus(-i)
– anterior hypophysis 264
– centralis 344
– cerebelli
– – anterior 262, 341, 344
– – posterior 262, 341, 344
– cerebri 272
– dexter (Gl. thyroidea) 115, 210, 234
– flocculonodularis 262, 341, 343–344
– frontalis 159, 265–266, 272, 286, 321
– insularis [Insula] 266, 289–291, 301, 303, 306, 309, 327, 408, 417, 424–426, 430, 434–436, 440
– limbicus 272
– occipitalis 20, 161, 265–267, 272, 286, 321, 323
– parietalis 265–266, 272, 286, 406, 415
– – inferior 431
– posterior hypophysis 264
– pyramidalis 115, 234, 237
– sinister (Gl. thyroidea) 204–205, 210, 234, 236
– temporalis 159, 266, 272, 286, 321
Local infiltrative anaesthesia of the lower jaw 95
Lock jaw 55
Locked-in syndrome 305
LOCKWOOD's ligament (Lig. suspensorium bulbi) 153
Locus
– caeruleus 340, 418
– KIESSELBACHI 79–80
– – nasal bleeding (epistaxis) 79
Long association fibres 280
Loss of consciousness, tongue slips into the pharynx 106
Lower dental arch 86
Lower eyelid, fat prolapse 8
Lower jaw 10, 38–39, 86, 93, 105
– dental arch 87
– infiltrative anaesthesia 95
– of an old man 39
– of a five-year-old child 93
– – panoramic X-ray image 94
– of a newborn 39
– without wisdom teeth, panoramic X-ray image 94
Lower motor disease 410
Lower nasal passage 74
Lower tracheotomy 204
Lumbal puncture 403
Lumbar spine, magnetic resonance imaging (MRI) 404
Lumbosacral transition zone, myelography 404
Lung
– expansion reflex 339
– innervation 421
Luteinising hormone (LH) 334
Lymph node metastases of the neck, AJCC classification 251

M

Macula
– cribrosa media/superior 188
– flava
– – anterior 223, 231
– – posterior 223, 231, 233
– lutea (yellow spot) 154, 158
– sacculi 193
– utriculi 193
Magnetic resonance imaging (MRI)
– brain 425–427
– eye 159
– lumbar spine 404
– vertebral canal 405
MALASSEZ, epithelial cell residues 91
Malleus 168, 170, 174, 180–182, 192, 369
Mandibula 9–10, 22, 28, 38–39, 42, 45, 54, 61, 84, 86, 93–94, 103, 105–108, 205, 208–210
– fractures 39
– of five-year-old child 93
Mandibular dental arch 87
Mandibular salivary gland 111, 113–114
– orifice of the excretory duct 112
Mandibulofacial dysostosis (FRANCESCHETTI's syndrome) 169
Manubrium
– mallei 173–176, 179–180
– sterni 247
MARFAN's syndrome, lens luxation 156
Marginal zone of the spinal cord 268
Margo
– ciliaris (Lens) 156
– frontalis (Os sphenoidale) 35
– gingivalis 88
– inferolateralis hemispherii cerebri 276, 428
– inferomedialis hemispherii cerebri 276, 428
– infraorbitalis 10, 27, 126
– lacrimalis (Maxilla) 27, 31
– lambdoideus (Os occipitale) 35
– lateralis (Orbita) 126
– linguae 102
– mastoideus (Os occipitale) 35
– medialis (Orbita) 126
– occipitalis (Os temporale) 36–37
– parietalis
– – (Os sphenoidale) 38
– – (Os temporale) 26, 36–37
– pupillaris 156
– sphenoidalis (Os temporale) 36–37

Index

Margo
– squamosus (Os sphenoidale) 35, 38
– superior
– – hemispherii cerebri 276, 428
– – partis petrosae 16, 37, 75
– supraorbitalis
– – (Orbita) 126–127
– – (Os frontale) 9, 30
– – (Os temporale) 26
– zygomaticus (Os sphenoidale) 34
Marionette fold (mentolabial fold) 8
Mass bleeding
– apoplexy 303
– Capsula interna 408
Masticatory muscles 52–53, 55, 60, 111
Mastoiditis 178
– Otitis media 176
Maxilla 9–11, 18, 22, 27–31, 36–37, 40, 42, 45, 69, 72–74, 86, 92–94, 96, 101, 111, 126–127, 138–140, 152, 213, 218
– *See also* Upper jaw
Maxillary dental arch 87
Maxillary odontogenic sinusitis 77
Maxillary sinus 30, 151
– development 73
– inflammation 77
– odontogenic inflammation 32
MCA (middle cerebral artery) 296, 307
Meatus
– acusticus
– – externus 18, 20, 36–37, 43, 46, 53, 94, 168–170, 172–173, 176–177, 180, 182, 192, 384
– – internus 14, 94, 182, 187, 190–191, 370–371, 376
– – – content 21
– nasi
– – inferior 29, 36, 70, 72–73, 111, 138
– – medius 29, 70
– – superior 153
MECKEL's cartilage 24
Medial cheek fat compartment 48
Medial palpebral ligament 131
Median cranial gap 267
Median neck cyst 236
Mediotrusion, temporomandibular joint 44
Medulla
– oblongata 191, 197, 262–263, 266, 271, 278, 285–286, 300, 302, 310, 337–338, 376, 395, 407, 409, 422, 426, 430
– – arterial supply 310
– – development 262
– – rostral 195
– – rostroventrolateral (RVLM) 338–339
– – ventrolateral region 424
– spinalis 266, 270–271, 339, 343–344, 347, 394–395, 397, 399, 402, 405–406, 426
MEIBOMIAN's glands (Gll. tarsales) 131–132
Melanotropin (α-MSH) 334
Melatonin 334
– circadian rhythm 330
– pinealocytes 330
Membrana
– basilaris 192
– limitans externa/interna 268
– quadrangularis 228, 235
– stapedialis 175, 179
– tectoria 192
– thyrohyoidea 107, 115, 212, 222–226, 228, 232, 234, 254
– tympanica 169–170, 172–173, 175–176, 179, 181, 190, 192, 369
– vestibularis (REISSNER's membrane) 191
Membranous labyrinth 189–190
– development 168
Memory function, corpora mamillaria 323
Meninges 283, 400
– topographic relationships 282
Meningioma 259, 288
– computed tomography (CT) 259
Meningism 288
Meningitis 288
– Otitis media 176
Meningocele 267, 269
Meningoencephalocele 267
Meningohydroencephalocele 267
MENIÈRE's disease 190
Mental and physical fatigue (burn-out) 419
Mentolabial fold (marionette fold) 8
Mesencephalon 160, 197, 261–264, 266, 271–272, 277–278, 310, 320, 335–336, 407, 409, 418
– arterial blood supply 195, 310
– infratentorial/supratentorial herniation 341
Mesial 87–88
Mesotympanon 175
Metathalamus 277
Metencephalon 261, 266, 271
MEYNERT's axis 271
Microcephaly 25
Microtia 169
Midbrain 262–264, 278, 335–336
– infratentorial/supratentorial herniation 341
Midbrain syndrome 335, 341
Middle cheek fat compartment 48
Middle cranial base 18–19
– anterior portion 18, 30
– Sinus durae matris 312
Middle cranial fossa 16
Middle ear 166, 169–170, 191
– computed tomography (CT) 182
– development 168
Middle nasal passage 74
Miosis (pupil constriction) 163
Mitral cells
– Fila olfactoria 353
– of the olfactory nerves 353
Modiolus cochleae 187, 191
Molar teeth 90
Molecular layer, isocortex 317
Monoaminergic neurotransmitter systems, brain stem 340
Monosynaptic (proprioceptive) reflexes of the spinal cord 402
Mood disorders 340
MORGAGNI, ventricle of (Ventriculus laryngis) 103, 228–231, 233, 235
Motion programs, planning 328
Motor language centre (BROCA's centre) 319
Motor neurons 268
– α-motoneurons 406, 419
– γ-motoneurons 406
Mouth smear 83
Movement coordination 413
Mucosa
– olfactoria 353
– oralis 83
Mucosal wave of the vocal folds 230
MÜLLER's muscle (M. ciliaris) 156
Multiform layer of the isocortex 317
Multisynaptic reflexes of the spinal cord 402
Muscle stiffness, PARKINSON's disease 327
Muscle tone, regulation 342
Musculus(-i)
– antitragicus 172
– arytenoideus 227, 232
– – obliquus 216, 226, 228, 233
– – transversus 216, 218, 226, 228–229, 233
– auricularis(-es) 172, 370
– – anterior 51, 172
– – posterior 51, 172
– – superior 51, 172
– biceps brachii 394
– brachioradialis 394
– buccinator 52–53, 58, 60, 76, 82–85, 98, 110, 212, 370
– bulbi 141–143, 159
– chondroglossus 106–107
– ciliaris 116, 154, 156, 356, 358
– – (Fibrae circulares, MÜLLER's muscle) 156
– colli 204–205
– constrictor(-es) pharyngis 107, 184, 210
– – inferior 53, 100, 107, 113, 115, 205, 210, 215, 218, 233, 245, 382
– – medius 100, 106–107, 210, 212, 215, 218, 220, 233, 382
Musculus(-i) constrictor(-es) pharyngis
– – superior 61, 98, 100–101, 106–108, 210, 212, 215–218, 220, 382
– – – paralysis 379
– corrugator supercilii 52–53, 60, 130, 370
– cricoarytenoideus
– – lateralis 226–228, 235
– – posterior 216, 226–228, 232–233
– cricothyroideus 115, 204, 212, 225–226, 228, 234–235, 382
– deltoideus 205, 242, 244–245, 394
– depressor
– – anguli oris 47, 51–53, 60, 110, 370
– – labii inferioris 47, 51–53, 60, 82, 370
– – septi nasi 60, 130, 370
– – supercilii 51–53, 60, 130
– digastricus 52–53, 66–67, 76, 84, 104–105, 113–115, 180–181, 202, 204–205, 209–210, 212, 215, 217, 220, 242–244, 248–252, 369–370
– dilatator pupillae 156, 163, 356
– epicranius 51–53, 60, 152, 240
– extensor hallucis longus 394
– faciei 51–53, 60, 130, 212
– genioglossus 55, 61, 76, 83–84, 103, 105–109, 113–115, 213, 218, 390
– geniohyoideus 55, 61, 76, 83–84, 103, 105–108, 113–114, 213, 218, 246, 390
– helicis major/minor 172
– hyoglossus 61, 84, 104, 106–109, 113–115, 204, 212, 248–249, 252, 390
– iliopsoas 394
– infrahyoidei 207
– infraorbitalis 130
– interosseus(-i) (Manus) 394
– laryngis 226–227
– levator(-es)
– – anguli oris 52–53, 60, 82, 130, 370
– – labii superioris 51–53, 60, 82, 130, 370
– – – alaeque nasi 51–53, 60, 130, 212, 370
– – palpebrae superioris 76, 122, 135–136, 141, 143–149, 152–153, 159, 356, 358
– – – – paralysis, ptosis 141
– – pharyngis 210
– – scapulae 66–67, 202–206, 240–241, 244, 250
– – veli palatini 84, 100, 183–185, 210, 212, 382
– linguae 103, 107
– – externi 106–107
– – interni 103
– longitudinalis
– – inferior 103, 106–107, 390
– – superior 103, 390
– longus
– – capitis 84, 204, 206, 217, 253–254
– – colli 206, 236, 253–254
– masseter 52–56, 60, 110, 113, 204–205, 209, 217
– masticatorii 52–53, 55, 60, 111
– mentalis 51–53, 60, 82, 370
– mylohyoideus 55, 67, 76, 83–84, 103–105, 108, 113–115, 204–205, 209, 212–213, 218, 243–244, 248–249, 252
– nasalis 47, 51–53, 60, 130, 370
– obliquus
– – auriculae 172
– – inferior 122, 135–136, 138–139, 141–143, 145, 149, 152, 356, 358
– – superior 76, 122, 135–136, 141–149, 153, 159, 356, 359
– occipitofrontalis 51–53, 60, 130, 240, 370
– omohyoideus 55, 66, 115, 202, 204–205, 209, 241–244, 246, 248–251, 390
– orbicularis
– – oculi (HORNER's muscle) 47, 51–53, 60, 130–132, 138–140, 152, 370
– – – paralysis 51
– – oris 51–53, 58, 60, 82, 84, 130, 212, 218, 370
– – – paralysis 51
– orbitalis 143
– palati 98

Musculus(-i)
– palatoglossus 98, 100–102, 106–107, 184, 217, 382
– palatopharyngeus 98, 100–102, 184, 216–217, 382
– pectoralis
– – major 205, 248–249
– – minor 245
– pharyngis 210, 212
– posticus (M. cricoarytenoideus posterior) 216, 226, 228, 232–233
– procerus 51–52, 60, 130, 370
– pterygoideus
– – lateralis 42–43, 45, 54–55, 59, 61, 64, 84, 111, 210
– – medialis 54–55, 60, 84, 114, 210
– quadriceps femoris 394
– rectus
– – capitis anterior/lateralis 206
– – inferior 76, 122, 135–136, 141–145, 149, 152–153, 159, 356, 358
– – lateralis 76, 122, 135–136, 141–150, 153, 159, 197, 356, 367
– – medialis 76, 141–144, 148–150, 153, 159, 197, 356, 358
– – superior 76, 141–149, 152–153, 159, 356, 358
– risorius 51–52, 60, 82, 110
– salpingopharyngeus 100, 184, 216, 382
– scalenus(-i) 206–207
– – anterior 66–67, 204–206, 242–243, 245, 250, 253–254
– – medius 66–67, 204–206, 250, 253–254
– – posterior 66, 205–206, 250, 253–254
– semispinalis capitis 51, 205
– sphincter pupillae 116, 154, 156, 356, 358
– splenius
– – capitis 51, 66–67, 205, 241–242, 244, 250
– – cervicis 204
– stapedius 175, 177, 179–181, 369–370
– sternocleidomastoideus 51–53, 58, 60, 66–67, 110, 202–205, 207–209, 217, 236–237, 240–244, 246, 248–250, 252, 386
– – paralysis 387
– sternohyoideus 55, 107, 115, 204–205, 208–209, 236, 242, 246, 249, 390
– sternothyroideus 115, 204–205, 213, 236, 242, 245–246, 390
– styloglossus 106–109, 113, 115, 209–210, 212, 217, 390
– stylohyoideus 53, 84, 104–105, 113, 115, 180–181, 202, 204–205, 209–210, 212, 217, 220, 243, 248, 252, 369–370
– stylopharyngeus 106–108, 205, 210, 212, 215, 217, 378, 382
– suprahyoidei 104–105
– tarsalis superior 131
– temporalis 43, 53–55, 61, 111
– temporoparietalis 51–52, 60
– tensor
– – tympani 173, 175–177, 179–181, 184–185, 369
– – veli palatini 84, 100, 183–185, 212, 216
– thyroarytenoideus 226–228, 233, 235
– thyroepiglotticus 235
– thyrohyoideus 55, 107, 113, 115, 204–205, 212, 220, 238, 249, 390
– tibialis anterior 394
– tragicus 172
– transversus
– – auriculae 172
– – linguae 103, 390
– trapezius 51, 58, 66–67, 202–205, 207–208, 240–241, 243, 248, 250, 386
– triceps
– – brachii 394
– – surae 394
– uvulae 98, 100, 183–184, 216
– verticalis linguae 103, 390
– vocalis 227–228, 233, 235
– zygomaticus
– – major 51–52, 60, 82, 110, 130, 370
– – minor 51–52, 60, 130, 212, 370
Mydriasis (pupil dilatation) 163
– paralysis of the oculomotor nerve 358
Myelencephalon 261
– vesicles 262
Myelocele 269
Myelography, lumbosacral transition zone 404
Myeloschisis 269

N

Naris 82
Nasal bleeding (epistaxis), plexus of KIESSELBACH 79
Nasal bone (Os nasale) 9, 30
– fractures 10
Nasal cavity 79, 151
– arteries 79
– innervation 81
– lateral wall 29, 72
– transnasal endoscopy 78
– veins 80
Nasal septum 69
– bony portion 28, 68
– cartilaginous portion 68
– deviation 28
– haematoma 69
Nasal skeleton 68–69
Nasal visual field 355
Nasion 9, 68
Nasolabial fat compartment 48
Nasolabial fold 8, 68, 82
Nasopharynx 100, 213
– closure during swallowing 100
– endoscopy 219
Neck 24, 199, 201–255
– anterior cervical regions 202–203
– – vessels and nerves 240, 242
– cervical fasciae 207–208
– cysts 236–237
– deep lymph nodes 67
– descending abscess 208
– drainage of the compartments 251
– fasciae 207, 209
– fistulas 236–237
– intravenous accesss 248
– lateral cervical region 202–203
– – vessels and nerves 242–245
– lesion of the N. hypoglossus [XII] 252
– localisation 237
– lymph node metastases 237
– – AJCC classification 251
– lymph nodes 66, 250
– muscles 204–205
– of a newborn 218
– organ fascia 207
– posterior triangle 202
– prevertebral and paravertebral structures 254
– regions 4–5, 9, 56–57
– sensory innervation of the skin 65, 241–242
– superficial lymph vessels 66, 250
– superficial muscles 202–203
– veins 248
– vessels and nerves 56–57, 249, 253
– X-ray in anteroposterior beam projection 253
Neck dissection 208
– lesion of the N. accessorius [XI] 240
Neocerebellum 262
Neocortex 317
– lamination 317
Neospinothalamic tract 418
Nervous system, organisation 270
Nervus(-i)
– abducens [VI] 55, 142, 144, 146–149, 153, 180, 278, 285, 298–301, 337, 345, 347, 351, 356, 360–361, 367–368, 439
– – course 368
– – exit from the brain stem 368
– – fibre qualities 346, 357, 368
– – innervation areas 346
– accessorius [XI] 66, 180, 215–216, 240–246, 249–250, 252, 278, 285, 300–301, 305, 345, 347, 351, 382, 386–387, 395, 439
Nervus(i) accessorius [XI]
– – exit from the brain stem 388
– – fibre qualities 346, 387–388
– – innervation areas 346
– – lesion during neck dissection 240
– – lesions 387
– – nuclei 388
– – target organs 388
– alveolaris(-es)
– – inferior 55, 58–61, 76, 95, 108, 114, 117, 217, 362–363, 366
– – superior(-es) 59, 81
– – – anterior(-es) 96, 118
– – – medius/medii 96, 118
– – – posterior(-es) 96, 118
– ampullaris(-es)
– – anterior 189
– – lateralis 189
– – posterior 189
– angularis 134
– auricularis(-es)
– – anteriores 362, 366
– – magnus 56–57, 171, 240–241, 246
– – posterior 58, 61, 64, 181–182, 240, 243, 369–371, 373–374
– auriculotemporalis 56–58, 60–61, 65, 116, 134, 171, 241, 362, 366, 378–379
– buccalis 57–61, 65, 117, 362, 366
– canalis pterygoidei [VIDIAN canal] 97, 118, 137, 182, 362, 370–371
– cardiacus cervicalis
– – inferior 254, 422
– – medius 215, 245, 254, 422
– – superior 215, 245, 422
– caroticotympanicus 182, 378
– caroticus internus 97, 215
– central palsy 3, 64, 373
– cervicalis 108, 243–244, 278, 386–387, 390–391
– ciliares
– – breves 116, 148, 163, 356–357, 362
– – longi 148, 356–357, 362, 365
– cochlearis 186, 189–191, 194, 375–377
– craniales 266, 270, 345–392
– ethmoidalis
– – anterior 58, 81, 148–149, 356, 362, 365
– – posterior 148–149, 356, 362, 365
– facialis [VII] 57–58, 60–61, 64, 113, 116, 118, 134, 137, 171, 177, 179–182, 186, 190–191, 217, 241–242, 278, 285, 300–301, 305, 337, 345, 347, 349, 351, 361–362, 364, 369–370, 374, 376, 406, 417, 421–423, 439
– – branches 372–373
– – corticonuclear connections 374
– – course 181, 369, 372, 374
– – exit from the brain stem 372
– – fibre qualities 346, 371–372
– – GVE and SVA/SVE 100, 373
– – infranuclear lesion 373–374
– – innervation areas 346
– – lesions 130
– – nuclei 346
– – peripheral palsy 64, 373
– – supranuclear lesion 373
– – terminal branches 64
– frontalis 144, 146, 152–153, 300, 356, 362–363, 365
– glossopharyngeus [IX] 101–102, 108–109, 116, 118, 180, 182, 214–217, 232, 278, 285, 300–301, 305, 337, 345, 347, 349, 351, 362, 364, 370, 378–379, 382, 417, 421–423, 439
– – branches 378
– – exit from the brain stem 380
– – fibre qualities 346, 379–380
– – innervation areas 346
– – lesions 379
– – nuclei 346, 380
– – target organs 380
– hypoglossus [XII] 53, 61, 108–109, 113–115, 215–217, 243–246, 248–249, 252, 278, 300–301, 337–338, 345, 347, 351, 390–391, 395, 439
– – exit from the brain stem 389
– – fibre qualities 346, 389, 391

Index

Nervus(-i) hypoglossus [XII]
– – innervation areas 346
– – lesions 109, 252, 391
– – – cervical lymph node metastases 252
– – nuclei 389
– – target organs 389
– infraorbitalis 53, 57–58, 60–61, 65, 76, 81, 95–96, 99, 118, 130, 134–136, 138, 143, 149, 152–153, 356, 362–363, 365
– infratrochlearis 58, 61, 65, 134, 148–149, 362, 365
– intercostobrachialis 245
– intermedius 118, 285, 345, 370, 372
– jugularis 215
– lacrimalis 65, 97, 134, 136–137, 144, 146–148, 150, 153, 300, 356, 362–363, 365
– laryngeus
– – inferior 349
– – recurrens 216, 232, 236, 238, 245, 249, 254, 381–383, 422
– – superior 102, 107, 109, 115, 200, 212, 215–216, 232–233, 244, 252, 254, 349, 381, 383
– – – lesions 232
– lingualis 55, 59–61, 95, 102, 108–109, 113–117, 249, 362–363, 366, 370–371
– mandibularis [V/3] 60–61, 65, 95–96, 102, 116, 137, 146–147, 149, 185, 242, 299–300, 349, 356, 360–363, 367, 378, 417
– – branches 60–61, 366
– massetericus 58–61, 362, 366
– maxillaris [V/2] 65, 81, 95–96, 116, 118, 137, 146–147, 149–150, 180, 214, 242, 298–300, 356, 360–364, 367
– – branches 365
– meatus acustici externi 61, 362, 366
– mentalis 57–58, 60, 65, 95, 362, 366
– musculi tensoris
– – tympani 117, 362, 366
– – veli palatini 117, 362, 366
– mylohyoideus 59–61, 243–245, 252, 362, 366
– nasociliaris 144, 146–148, 153, 300, 356, 362–363, 365
– – branches 365
– nasopalatinus 81, 99, 362
– occipitalis
– – major 56, 58, 65, 240–242, 245–246
– – minor 56, 58, 171, 240–243, 245–246
– oculomotorius [III] 55, 116, 142–144, 146–149, 153, 163, 180, 266, 278, 285, 298–301, 305, 335–336, 345, 347, 351, 356–357, 360–361, 421–423, 429, 439
– – exit from the brain stem 358
– – fibre qualities 346, 357–358
– – innervation areas 346
– – nuclei 346
– olfactorii [I] 72, 81, 300, 345, 352–353
– – fibre qualities 346
– – innervation areas 346
– ophthalmicus [V/1] 65, 95–96, 116, 118, 137, 144, 146–149, 180, 242, 298–299, 356–357, 360–364, 367
– – branches 365
– – course 146
– opticus [II] 55, 76, 78, 118, 136, 141, 143–150, 152–154, 159–161, 163, 264, 277, 283, 285, 298–301, 305, 322–323, 332, 339, 361, 425
– palatinus(-i)
– – major 81, 96, 98–99, 362, 366
– – minores 96, 99, 362, 366
– petrosus
– – major 97, 116, 118, 137, 179–182, 186, 191, 300, 364, 369–371, 373, 376
– – minor 117–118, 181–182, 300, 362, 369, 378–379
– – profundus 97, 118, 137, 370–371, 378
– pharyngeus 96, 362
– phrenicus 243–246, 249, 253–254
– – accessorius 253–254
– pterygoideus
– – lateralis 60–61, 362, 366
– – medialis 60, 117, 185, 362, 366

Nervus(-i)
– saccularis 189
– spinalis 412–413
– splanchnicus(-i)
– – lumbales 396, 422
– – major 396, 422
– – minimus 396
– – minor 396, 422
– – pelvici 396, 422
– – sacrales 396, 422
– stapedius 181, 369–370, 373–374
– – lesion 369
– sublingualis 109, 115, 366
– supraclaviculares 241
– – intermedii 240–241, 246
– – laterales 240–241, 246
– – mediales 240–241, 246
– supraorbitalis 57–58, 60, 65, 134–135, 137, 146–147, 153, 362, 365
– suprascapularis 245
– supratrochlearis 57–58, 61, 65, 134–135, 146–147, 362, 365
– temporales
– – profundi 61, 362, 366
– – superficiales 366
– thoracicus longus 245
– thoracodorsalis 245
– transversus colli 240–241, 246
– trigeminus [V] 55, 61, 95, 116, 118, 137, 146–149, 180, 242, 278, 285, 301, 305, 314, 336–338, 345, 347, 349, 351, 360–364, 412
– – branches 65, 365
– – exit from the brain stem 360, 368
– – fibre qualities 346, 363–364
– – innervation areas 346
– – lesions 367
– – neuralgia 367
– – nuclei 346, 363–364, 367
– – protopatic sensibility 367
– – target organs 364
– – terminal nuclei 363
– trochlearis [IV] 55, 142, 144, 146–148, 153, 278, 298–300, 305, 335, 339, 345, 347, 351, 355–357, 360–361, 439
– – branches 359
– – course 359
– – exit from the brain stem 359
– – fibre qualities 346, 357, 359
– – innervation areas 346
– – lesion 355
– tympanicus (JACOBSON's nerve) 116, 179, 182, 378–380
– utricularis 189
– utriculoampullaris 189
– vagus [X] 53, 61, 102, 109, 118, 171, 180, 182, 200, 207, 214–217, 236, 238, 242–245, 249, 252, 254, 278, 285, 300–301, 305, 337–338, 345, 347, 349, 351, 378, 381–384, 386–387, 396, 417, 420–423, 439
– – abdominal part 384
– – branches 232, 381
– – cervical part 384
– – cranial nuclei 346
– – exit from the brain stem 381
– – exit site on the brain stem 384
– – fibre qualities 346, 383, 385
– – innervation areas 346, 384
– – lesions 381
– – location in the subarachnoid space 384
– – thoracic part 384
– vestibularis 186, 189–191, 193–194, 375–377
– vestibulocochlearis [VIII] 170, 180, 186, 189–192, 195, 278, 285, 300–301, 305, 345, 347, 351, 361, 372, 439
– – branches 375
– – course 194, 375–377
– – exit from the brain stem 375
– – fibre qualities 191, 194, 346, 375, 377
– – innervation areas 346
– – nuclei 191, 346
– zygomaticofacialis 65
– zygomaticotemporalis 65, 137

Nervus(-i)
– zygomaticus 58, 96–97, 136–137, 149–150, 153, 356, 362, 365
Neural canal 268
Neural crests 260
Neural folds 260
Neural grooves 260, 268
Neural tube 124, 260, 268
Neuritis of the optic nerve 354
Neurocranium, ossification 24
Neurodegenerative diseases 325
Neuroepithelial cells 268
Neurofibrae
– associationes 280
– commissurales 280
– projectiones 281
Neurohypophysis 277, 293, 298, 329, 333, 361
– development 264
– hormones 334
Neuroleptic drugs, central vomiting (emesis) 293
Neurons
– epicritic sensibility 412
– protopathic sensibility 412
Neuroporus rostralis 260
Nociceptive system, stations 418
Nodules of the vocal folds 231
Nodulus
– cerebelli 262, 340, 342–344
– elasticus
– – anterior 223, 225, 227, 231
– – posterior 223, 225, 227, 231, 233
Nodus(-i) lymphoideus(-i)
– accessorii 250
– buccinatorius 66, 250
– capitis 66
– cervicales
– – anteriores 250
– – – profundi 67
– – laterales 66–67, 241, 250
– – – profundi 251
– – – – inferiores 66–67, 250
– – – – superiores 66–67, 250
– – – superficiales 66, 241, 250
– faciales 66, 250
– infraauriculares 66
– infrahyoidei 250
– intraglandulares 66
– jugulodigastricus 66, 250
– juguloomohyoideus 66, 250
– linguales 66
– malaris 66
– mandibularis 66
– mastoidei 66, 250
– nasolabialis 66
– occipitales 66, 250
– paratracheales 250–251
– parotidei
– – profundi 66–67
– – superficiales 66, 250
– preauriculares 66
– prelaryngei 250–251
– pretracheales 250–251
– profundi 250
– retropharyngeales 67, 250
– submandibulares 66, 113, 250–251
– submentales 66–67, 113, 250–251
– supraclaviculares 250
– thyroidei 67, 250
Non-pyramidal cells of the isocortex 317
Non-specific thalamic nuclei, damage 331
Noradrenaline 340
Nose
– bony structures of the lateral wall 70–71
– cartilage 68–69
– cartilage-free area 69
– fractures 10
– keystone area 69
– lateral wall 74
– – basic lamellae 71
– major/minor alar cartilage 68
– soft/weak triangle 69

Nose
– supratip area 69
– triangular cartilage 68
Nose tip 68
– cartilage 68
Nucleus(-i)
– accessorius nervi oculomotorii [III] (EDINGER-WESTPHAL nucleus) 116, 147, 163, 336, 339, 346, 350–351, 357, 423
– ambiguus 338–339, 346, 350–351, 379–380, 383–385, 387–388, 423–424
– anterior(-es)
– – hypothalami 333
– – thalami 324, 331
– arcuatus [infundibularis] 333, 423
– basales 406
– caeruleus 330, 340
– caudatus 265, 279, 289–292, 306, 309, 321, 326–328, 332, 339, 406, 408, 425, 428–431, 434–437, 439–440
– centralis (Medulla spinalis) 412
– centromedianus (Thalamus) 331
– cerebelli 343
– cochlearis(-es) 194, 346, 351, 375
– – anterior 191, 195, 377
– – posterior 191, 195, 377
– commissurae posterioris 281
– corporis
– – geniculati lateralis/medialis 331
– – mamillaris 333
– cuneatus 412, 414
– dentatus 262, 343, 431, 439
– dorsalis(-es)
– – hypothalami 333
– – nervi vagi [X] 338–339, 346, 350–351, 383–385, 420, 423–424
– – thalami 331, 412
– dorsomedialis areae hypothalamicae intermediae 333, 423
– fastigii 343
– gigantocellularis (medialis) 418
– gracilis 412, 414
– gustatorius 380, 385, 417
– hypothalamicus posterior 423
– infundibularis [arcuatus] 333, 423
– intermediolateralis 330, 397
– interpositus 343
– – anterior [emboliformis] 343
– – posterior [globosus] 343
– interstitiales hypothalami anteriores 333
– intralaminaris thalami 418
– KOELLIKER-FUSE 338
– lemnisci laterales 195
– lentiformis 406, 427
– lentis 157
– mamillaris lateralis 333
– marginalis (Medulla spinalis) 397
– mediales
– – corporis trapezoidei 194
– – thalami 331
– mediani thalami 331
– mesencephalicus nervi trigemini [V] 263, 336, 338, 346, 350–351, 363–364
– metathalami 331
– motorius nervi trigemini [V] 338–339, 346, 350–351, 363–364
– nervi
– – abducentis [VI] 197, 339, 350–351, 357, 367, 371, 407
– – accessorii [XI] 350–351, 387–388
– – facialis [VII] 339, 346, 350–351, 371–372, 374
– – hypoglossi [XII] 338–339, 350–351, 389, 391, 407
– – oculomotorii [III] 197, 263, 336, 339, 346, 350–351, 357–358
– – trigemini [V] 330, 412
– – trochlearis [IV] 263, 339, 350–351, 357, 359
– olfactorius anterior 352–353
– olivaris
– – inferior 279, 343, 406
– – superior 194–195, 339, 375

Nucleus(-i)
– ovalis 372
– paraambigualis 338
– parabrachialis 418, 424
– – medialis 338, 417
– parafascicularis (Thalamus) 331
– parasympathicus sacralis 424
– paraventricularis 330, 333, 423
– periolivares 194
– periventricularis posterior/ventralis 333
– pontinus (Ncl. sensorius principalis) nervi trigemini [V] 346, 350–351, 363
– pontis 279, 338, 343
– posterior
– – hypothalami 333
– – thalami 331
– – ventrolateralis thalami 196
– preopticus 333, 423
– – medianus 333
– principalis nervi trigemini [V] 338–339, 364
– – posterior 350
– proprius (Medulla spinalis) 397
– pulvinares (Thalamus) 331
– raphes dorsalis 336
– – magnus medialis 418
– – pontis 338
– – posterior 330
– reticularis thalami 330–331
– ruber 263, 277, 279, 332–333, 336, 343, 347, 351, 430, 437–438
– – lesions 343
– salivatorius
– – inferior 116, 339, 346, 351, 379–380, 423
– – superior 116, 339, 346, 350–351, 371–372, 423
– sensorius principalis (Ncl. pontinus) nervi trigemini [V] 346, 350–351, 363
– solitarius 338, 384
– spinalis nervi
– – trigemini [V] 338, 346, 350–351, 363–364, 371–372, 379–380, 383, 385, 412, 414, 418
– – vagi [X] 384
– subthalamicus 327–329, 406
– – lesions 328
– suprachiasmaticus 330, 333, 423
– supraopticus 333, 423
– tegmentales 330, 333
– thoracicus posterior 397, 413
– tractus
– – olfactorii lateralis 352
– – solitarii 339, 346, 350–351, 371–372, 379–380, 383, 385, 417, 420, 423–424
– tuberales laterales [infundibulares] 333
– tuberomamillaris 333
– ventralis
– – anterior thalami 331
– – intermedius thalami 331
– – posterior thalami 417
– – posterolateralis thalami 331, 412, 414, 418
– – posteromedialis thalami 331, 414, 417–418
– ventrolaterales thalami 331
– ventromedialis areae hypothalamicae intermediae 333, 423
– vestibularis(-es) 194, 339, 346, 350–351, 375
– – inferior (ROLLER's nucleus) 191, 196, 350, 377
– – lateralis (DEITERS' nucleus) 191, 196, 350, 377
– – medialis (SCHWALBE's nucleus) 191, 197, 338, 350, 377
– – superior (BECHTEREW's nucleus) 191, 196, 350, 377
NUEL's space 192
Nystagmus 301
– Frenzel's glasses 197
– test 197

O

Obex 278, 337, 395
Occipital 271
Occipital lobe 272
Occiput 12
– *See also* Os occipitale
Occlusal plane of the plane 11
Ocular fundus 158, 294
– fluorescence angiography 158
– ophthalmoscopy 158
Oculomotor function 339
Oculomotor nerve palsy 142, 357–358
– diplopia 142
– tightening of the eyelids 128
Oculus 128–129, 145, 150
Oesophageal speech 201
Oesophagus 207, 210, 212–213, 215–216, 219, 236, 254
OFF-cone bipolar cells of the retina 162, 354
OFF-ganglion cells of the retina 162, 354
Olfactory cells 353
Olfactory epithelium 353
Olfactory mucosa 353
Olfactory nerves 352
– glomeruli 353
– granular cells 353
– mitral cells 353
– periglomerular cells 353
Olfactory sensory cells 352
Olfactory tract 352
Oliva 278, 430–431
– inferior 337–338
Olivocochlear efferent fibres 194
ON-cone bipolar cells of the retina 162, 354
ON-ganglion cells of the retina 354
ÓNODO-GRÜNWALD's cells 78
ONUF's nucleus 424
Open-angle glaucoma 156
Operculum
– frontale 266, 273
– laterale 415
– parietale 273, 415
– temporale 266
Ophthalmopathy, hyperthyroidism 239
Ophthalmoplegia, orbital apex syndrome 144
Ophthalmoscopy of the ocular fundus 158
OPPENHEIM's reflex 410
Optic cup (ophthalmic cup) 124, 261
Optic stalk 124
Optic tract 354
– blood supply 160
Optic vesicles 124
Optical axis 143
– abduction/adduction 142
– elevation/depression 142
Ora serrata 154–155
Oral cavity 84–85, 98, 213
– ectoderm 264
– frontal section 83
Oral mucosa 83
– fungal infections 83
– leukoplakia 83
– precancerous sores 83
Oral region 82, 104
– muscles 82
Orbicularis oculi reflex 361
Orbiculus ciliaris 154, 156
Orbita 9, 32, 73, 75, 94, 126, 145–150, 152
– axis 143
– frontal section 153
– horizontal section 150
– lower level 149, 152
– middle level 148, 152
– roof 127
– superior level 146, 152
Orbital apex syndrome 144
Orbital floor 31, 127
– fracture 127
Orbital hernia, blow-out fracture 127
Organum
– juxtaorale 52
– spirale 191–192

Index

Organum
– subcommissurale 293
– vasculosum laminae terminalis 293
– vestibulare 191
Oropharyngeal isthmus (Isthmus faucium) 85
Oropharynx 100, 208, 213
– closure when swallowing 100
Os(-sa)
– cranii 9–14
– ethmoidale 10, 14, 28–32, 36–37, 41, 69, 72–73, 126–127, 140, 144, 153, 352–353
– frontale 9, 11, 22, 26, 30–31, 33, 36–37, 53, 126–127, 136, 143, 152–153
– hyoideum 53, 55, 61, 84, 94, 103–108, 110, 114–115, 202, 204–205, 208, 210, 212–213, 218, 220, 222–226, 228–229, 232, 234–235, 237, 249, 252, 254
– incae 13
– incisivum 28, 30
– interparietale 13
– lacrimale 10–11, 28–29, 31, 37, 70, 126–127, 140, 144
– nasale 9, 11, 22, 28–30, 32, 37, 68–70, 126–127, 130, 140
– occipitale 13, 18, 22, 28–29, 31, 35, 267
– palatinum 14, 18, 28–32, 36–37, 70, 74, 96, 126–127, 144, 183
– parietale 10–13, 22, 28, 31, 33, 53, 283
– sacrum 404
– sphenoidale 10–11, 16, 18, 22, 28–29, 31–35, 37–38, 40–41, 74, 96, 126–127, 136, 141, 143, 150, 183
– suturalia 13
– temporale 11, 13–14, 16, 18, 22, 28, 33, 36–37, 41, 46, 54, 170, 180, 182–183
– zygomaticum 9, 11, 22, 31–33, 36, 40, 42, 45, 54, 96, 126–127, 153
Ossicula auditus 168, 170, 174–175
Osteomeatal complex 71, 77–78
Ostium
– pharyngeum tubae auditivae 72, 183, 213, 216, 219, 378
– tympanicum tubae auditivae 177–179
Otic placode 168
Otic vesicle 168
Otitis externa 170
Otitis media 167, 173, 176
Otoliquorrhoea 282
Otosclerosis 174
Outer border cells of the organ of CORTI 192
Outer brain prolapse 267
Outer ear 166, 169
Outer granular layer, isocortex 317
Outer hair cells of the organ of CORTI 192, 194
Outer laryngeal muscles 225
Outer nose
– aesthetic angles 68
– orientation points 68
Outer phalangeal cells of the organ of CORTI 192
Outer pyramidal layer, isocortex 317
Oval window (Fenestra vestibuli) 178
Oxycephaly 25
Oxytocin 423

P

PACCHIONIAN granulations (Granulationes arachnoideae) 258, 282–284, 287–288
Pachymeninx 282
Pain conducting fibres 398, 418
– paleospinothalamic system 418
Palate
– arterial blood supply 99
– cleft formation 98, 185
– development 99
– muscles 98
– – paralysis, circulatory disorders of the brain stem 104
– nerves 99
Palatinal 87
Palatine arches 98
Palatine tonsil 101
– blood and nerve supply 101
– infection 101
– recurrent infection 101
Palatum
– durum 19, 30, 84–85, 94, 98, 184
– molle [Velum palatinum] 55, 84, 94, 96, 98, 100–101, 184, 213, 218–219
Paleocerebellum 262
Paleocortex 317
– structures 325
Paleospinothalamic system/tract 418
– anterolateral system 418
– dorsolateral system 418
– pain modulating fibres 418
Pallidum *See* Globus pallidus
Palliothalamus 331
Pallium 265
Palpebra
– inferior 128, 131–132, 136, 152, 159
– superior 128, 131–132, 136, 152, 159
Palpebral ligaments 134–135
Palpebromalar pit 8
Palpepral fissure, width 129
PANCOAST's tumour 249
Panniculus adiposus 51
Panoramic X-ray image
– upper and lower jaw of a five-year-old child 94
– – without wisdom teeth 94
PAPEZ's circuit 324
Papilla(-ae)
– ductus parotidei 112
– filiformes 102
– foliatae 101–102, 106–107, 417
– fungiformes 102, 417
– gingivalis [interdentalis] 83
– incisiva 98
– lacrimalis 138
– – inferior 128
– – superior 128, 138
– nervi optici 158
– vallatae 101–102, 106, 232, 417
Papilloedema 158
– glaucoma 158
– retinal detachment 158
Paralysis, damage of the thalamic nuclei 331
Paralytic ectropion 51, 133
Paralytic squint, lesion of the N. abducens [VI] and N. trochlearis [IV] 141
Paranasal sinuses 73
– aplasia 76
– basic lamellae 78
– clinical terms 78
– fontanelle 78
– orifice 74
– topography 77
– X-ray image 75
Parapharyngeal (peripharyngeal) abscess 208
– computed tomography 208
Parapharyngeal space, vessels and nerves 216
Paraplegia 405, 416
Parasubiculum 320
Parasympathicus 419–422
– cranial part 423
– pelvic part 421
– sacral part 423
Paravermal zone of the cerebellum 342–343
Paravertebral ganglion of the sympathetic trunk 396
Paries
– caroticus (Cavitas tympani) 176–177
– inferior orbitae 31, 127, 159
– jugularis (Cavitas tympani) 176–177
– labyrinthicus (Cavitas tympani) 176–178
– lateralis
– – (Cellulae ethmoidales) 159
– – orbitae 33, 126
– mastoideus (Cavitas tympani) 176–177
– medialis
– – (Cellulae ethmoidales) 159
– – orbitae 37, 126
Paries
– membranaceus
– – (Cavitas tympani) 176, 179
– – (Trachea) 216, 224, 226, 229, 236
– posterior (Meatus acusticus externus) 173
– superior
– – (Cellulae ethmoidales) 159
– – orbitae 127
– tegmentalis (Cavitas tympani) 176–177
Parietal lobe 272
Parietoinsular cortex 196
PARKINSON's disease 325, 327, 410
Parodontopathies 92
Parodontosis 92
Parotid gland 110–111
– FREY's syndrome (gustatory sweating) 110
– orifice of the excretory duct 112
– tumours, peripheral facial injury 110
Parotitis epidemica (mumps) 53, 110
Pars
– abdominalis aortae (Aorta abdominalis) 399, 422
– alveolaris (Mandibula) 38
– ambiens (A. cerebri posterior) 296
– anterior
– – (Commissura anterior) 280, 323
– – (Dorsum linguae) 102
– – (Lobulus quadrangularis anterior) 341
– aryepiglottica 395
– – (M. arytaenoideus obliquus) 226
– – (M. arytenoideus obliquus) 226
– ascendens aortae (Aorta ascendens) 249, 422
– atlantica (A. vertebralis) 247, 296, 305
– basilaris
– – mesencephali 263
– – (Os occipitale) 18, 35
– – pontis 338
– buccopharyngea (M. constrictor pharyngis superior) 210, 212
– calcarina (A. cerebri posterior) 296
– canalis (N. opticus) 144
– cartilaginea (Tuba auditiva [auditoria]) 181, 183, 369
– cavernosa (A. carotis interna) 186, 295–300, 360–361
– centralis (Ventriculus lateralis) 286–287, 289–291, 326–327, 406, 427, 429–431, 433–434, 439
– ceratopharyngea (M. constrictor pharyngis medius) 106–107, 210, 212
– cerebralis (A. carotis interna) 144, 295–300, 360–361
– cervicalis
– – (A. carotis interna) 295–298, 395
– – – variations in the course 220
– – (Parasympathicus) 422
– chondropharyngea (M. constrictor pharyngis medius) 106–107, 210, 212
– ciliaris retinae 154, 156
– cochlearis (N. vestibulocochlearis [VIII]) 195
– compacta (Substantia nigra) 328, 336, 338, 340, 406
– cricopharyngea (M. constrictor pharyngis inferior) 210, 212
– cuneiformis vomeris 28
– cupularis (Cavitas tympani) 176
– descendens aortae (Aorta descendens) 216
– distalis (Adenohypophysis) 334
– duralis (Filum terminale) 395
– externa (M. thyroarytenoideus) 227–228, 235
– fibrocartilaginea 172
– flaccida 173
– fundiformis (Pars cricopharyngea, KILLIAN's muscle) 210
– glossopharyngea (M. constrictor pharyngis superior) 98, 106–107, 210, 212
– gustatoria (Ncl. tractus solitarii) 417
– horizontalis
– – (Canaliculus lacrimalis inferior) 139
– – (Canaliculus lacrimalis superior) 131, 139
– inferior
– – (N. vestibularis) 191, 376–377

Pars inferior
– – (Ncl. tractus solitarii) 380
– – (Orbita) 73
– infraclavicularis (Plexus brachialis) 245
– infundibularis [tuberalis] (Adenohypophysis) 264
– insularis (A. cerebri media) 296, 301, 428
– intercartilaginea (Rima glottidis) 231, 233
– intermedia (Adenohypophysis) 264, 334
– intermembranacea (Rima glottidis) 231, 233
– intermuscularis (A. maxillaris) 59
– interna (M. thyroarytenoideus) 227–228
– intracranialis
– – (A. vertebralis) 247, 296, 305
– – (N. opticus) 144
– iridica retinae 156
– labialis (M. orbicularis oris) 60, 82, 212, 218
– lacrimalis (M. orbicularis oculi) 130–131, 140
– laryngea pharyngis (Hypopharynx, Laryngopharynx) 214, 426
– lateralis
– – (M. pterygoideus medialis) 54
– – (Os occipitale) 22, 28, 35
– libera (Columna fornicis) 323, 429
– lumbalis (Medulla spinalis) 395
– mandibularis (A. maxillaris) 62
– marginalis (M. orbicularis oris) 60, 130
– medialis (M. pterygoideus medialis) 54
– mylopharyngea (M. constrictor pharyngis superior) 210, 212
– nasalis
– – (Os temporale) 26
– – pharyngis (Epipharynx, Nasopharynx) 214, 426
– nervosa hypophysis 264
– obliqua
– – (M cricothyroideus) 226
– – (M. arytenoideus) 227, 232
– – (M. cricothyroideus) 212, 225–226
– opercularis
– – (A. cerebri media) 296
– – (Gyrus frontalis inferior) 273, 276, 319
– optica retinae 154
– oralis pharyngis (Mesopharynx, Oropharynx) 85, 214, 426
– orbitalis
– – (Gl. lacrimalis) 135–136, 141, 146–148
– – (Gyrus frontalis inferior) 273, 276
– – (M. orbicularis oculi) 51–52, 60, 130–131
– – (N. opticus) 144
– – (Os frontale) 9, 26, 36, 126
– ossea (Tuba auditiva) 172, 181, 183, 185, 369
– palpebralis
– – (Gl. lacrimalis) 135–136
– – (M. orbicularis oculi) 51–52, 60, 130–132
– pelvica (Parasympathicus) 422
– petrosa
– – (A. carotis interna) 295–298
– – (Os temporale) 16, 22, 28, 36, 180, 183
– plana (Corpus ciliare) 156
– plicata (Corpus ciliare) 156
– postcommunicalis
– – (A. cerebri anterior) 296, 300, 302, 361, 428
– – (A. cerebri posterior) 300–301
– posterior
– – (Commissura anterior) 280, 323
– – (Dorsum linguae) 102, 216
– precommunicalis
– – (A. cerebri anterior) 296, 300–301, 306, 428
– – (A. cerebri posterior) 296, 300–301, 429
– prevertebralis (A. vertebralis) 244–245, 247, 296, 305
– profunda
– – (Glandula parotidea) 111
– – (M. masseter) 53–54
– pterygoidea (A. maxillaris) 62
– pterygopharyngea (M. constrictor pharyngis superior) 210, 212
– quadrigeminalis (A. cerebri posterior) 296
– recta (M. cricothyroideus) 212, 225–226, 234

Pars
– reticularis (Substantia nigra) 328, 332, 336
– retromandibularis (A. maxillaris) 59
– sphenoidalis (A. cerebri media) 296, 301
– sphenopalatina (A. maxillaris) 59
– squamosa (Os temporale) 11, 14, 16, 22, 28, 33, 36–37
– sternocostalis (M. pectoralis major) 205
– superficialis
– – (Gl. parotidea) 110–111, 217
– – (M. masseter) 53–54
– superior
– – (N. vestibularis) 191, 376–377
– – (Ncl. tractus solitarii) 380, 385
– supraclavicularis (Plexus brachialis) 66, 204, 242, 249–250
– supratarsalis (Palpebra superior) 128
– tarsalis (Palpebra superior) 128
– tecta (Columna fornicis) 323, 429
– tensa (Membrana tympani) 173
– terminalis (A. cerebri media) 296
– thoracica
– – aortae (Aorta thoracica) 381, 399, 422
– – (Medulla spinalis) 395
– thyroepiglottica 226
– – (M. thyroarytenoideus) 226, 235
– thyropharyngea (M. constrictor pharyngis inferior) 107, 210, 212
– transversa
– – (M. arytenoideus) 227, 232
– – (M. constrictor pharyngis inferior) 210
– transversaria (A. vertebralis) 247, 253, 296, 305
– triangularis (Gyrus frontalis inferior) 276
– tuberalis (Adenohypophysis) 264, 334
– tympanica (Os temporale) 28, 36
– vertebralis (A. vertebralis) 296
– verticalis
– – (Canaliculus lacrimalis inferior) 139
– – (Canaliculus lacrimalis superior) 131, 139
PASSAVANT's ridge 379
Patellar tendon reflex 401–402
PCA (posterior cerebral artery) 296, 307
PCom (posterior communicating artery) 307
Pediculus arcus vertebrae 393–394
Pedunculus(-i)
– cerebellaris(-es) 347
– – inferior 278–279, 337–339, 342, 376, 413
– – medius 278, 281, 337–339, 342, 406, 430–431, 439
– – superior 263, 278, 337–339, 342–343, 413, 431
– cerebri 160, 275, 277–279, 281, 332, 335, 339, 347, 351, 360–361, 406, 425, 427
– flocculi 339, 342
Pericranium 52–53, 59
Peridural anaesthesia (PDA) 282, 403
Periglomerular cells of the olfactory nerves 353
Periodontium 88
Periorbita 141, 143–144, 152–153
Periorbital region 134
Peripheral facial palsy 3, 57, 64, 373
– acoustic neurinoma 377
– intraparotid branches, lesions 57
– lagophthalmus 369
– lesion site 374
Peripheral induced pain 418
Peripheral motor innervation, circuitry 419
Perirhinal cortex 324
Peritonsillar abscess of the carotid loop 220
Permanent canine tooth 88
Permanent tooth/teeth 90–92
– arrangement 88
– development 91
– form 88
– innervation 95
– local infiltrative anaesthesia 95
– orientation rules 88
– vascular supply 95
Personality changes, lesions of the thalmic nuclei 331
Pes hippocampi 291, 322–323, 406, 438
Petiolus epiglottidis 221–223
Phalangeal cells of the organ of CORTI 192
Pharyngeal arches
– cranial nerves 349
– remnants 237
Pharyngeal diverticulum 210
Pharyngeal hypophysis 219
Pharyngeal isthmus (Isthmus faucium) 98
Pharyngeal lymphoid ring (WALDEYER-Rachenring) 101
Pharyngeal membrane 264
Pharyngeal muscles 107, 210, 212
– constrictors 107, 210, 212
– levators 210, 212
Pharyngeal space, vessels and nerves 215
Pharyngeal tonsil 101
Pharyngo-oesophageal diverticula 210
Pharynx 213–216, 224
– levels 214
– sensory innervation 214
– vessels and nerves 215–216
PHILIPPE-GOMBAULT, triangle of (Fasciculus interfascicularis) 397
Philtrum 82
Phlebitis, inflammation of the facial area 63
Photoreceptor cells of the retina 160, 162
Physical and mental fatigue (burn-out) 419
Pia mater 282
– cranialis 283, 285, 300
– spinalis 400
PICA (posterior inferior cerebellar artery) 307
– supply area 310
Pillar cells of the organ of CORTI 192
Pineal gland (Corpus pineale) 265
– circuit for controlling 330
Pinealocytes, melatonin 330
Pituitary gland (Glandula pituitaria, Hypophysis) 144, 277, 285, 298–300, 302, 334, 340, 361, 426, 429
– development 264
Plagiocephaly 25
Plantar reflex 402
Platysma 47, 51, 55, 60, 76, 83, 85, 108, 110, 113, 202–203, 207, 209, 212, 236, 240–241, 244, 370
Pleura parietalis 253
Plexus
– aorticus
– – abdominalis 422
– – thoracicus 396
– basilaris 283, 329
– brachialis 66, 204, 241–243, 245, 249–250, 253, 270, 386, 396
– – interscalene block 253
– cardiacus 381–383, 396, 422
– caroticus
– – communis 215–216
– – internus 97, 118, 137, 177, 182, 300, 356, 370–371, 378
– cavernosus 72, 111, 356
– cervicalis 56, 65, 242, 244, 270, 396
– – sensory and motor branches 246
– choroideus 262, 265, 282, 289–290, 304, 430
– – ventriculi
– – – lateralis 160, 287, 290–291, 321, 326, 429–431, 433–437, 439–440
– – – quarti 287, 293, 301, 310, 339–340, 347, 439
– – – tertii 277, 287, 290–293, 302, 329, 340, 347, 429–430
– coeliacus 382–383, 422
– dentalis
– – inferior 60, 95, 362
– – superior 95, 118
– hepaticus 382–383
– hypogastricus
– – inferior 421–422
– – superior 421–422
– intraparotideus 57, 370, 373
– lumbalis 396
– lumbosacralis 270

Plexus
– mesentericus
– – inferior/superior 422
– oesophageus 381–383, 396, 422
– pharyngeus 109, 214, 378, 382–384
– prevertebralis 396
– pterygoideus 60, 63, 95, 97, 311
– pulmonalis 381–383
– renalis 382–383, 422
– sacralis 396
– splenicus 382–383
– suprarenalis 382–383
– thyroideus impar 236, 249, 254
– tympanicus 118, 177, 182, 378–379
– venosus
– – canalis nervi hypoglossi 311
– – caroticus internus 185, 311
– – foraminis ovalis 311–312
– – pharyngeus 233
– – pterygoideus 145
– – vertebralis internus 401
Plica(-ae)
– aryepiglottica 216, 231
– ciliares 156
– fimbriata 103, 107, 112, 115
– glossoepiglottica 102
– – lateralis 102
– – mediana 102
– interarytenoidea (Rima glottidis) 231
– iridis 156
– lacrimalis (HASNER's valve) 74, 138
– mallearis
– – anterior 173, 176, 179–180
– – posterior 173, 179–180
– – superior 173
– nervi laryngei superioris 216
– palatinae transversae 98
– petroclinoidea anterior 347, 361
– salpingopalatina 213
– salpingopharyngea 101, 213, 216
– semilunaris conjunctivae 128–129, 138
– sublingualis 112, 114–115
– triangularis 102
– vestibularis 213, 228–229, 231, 233, 235
– vocalis 213, 228–229, 231, 233, 235
– – intubation granuloma 231
– – polyps 231
– – squamous cell carcinoma 231
PNS (peripheral nervous system) 270
Poliomyelitis 397, 410
Polus
– anterior
– – bulbi 154
– – lentis 154, 157
– frontalis 272–275, 323, 327, 435–436
– occipitalis 272–275, 323, 435–436
– posterior
– – bulbi 154
– – lentis 154, 157
– temporalis 272–273, 275, 289, 320, 322, 428
Polyposis nasi, endonasal sinus surgery 71
Polyps of the vocal folds 231
Polysynaptic reflexes of the spinal cord 402
Pons 195, 197, 262–263, 265–266, 271, 277–279, 281, 286, 302, 310, 329, 335–338, 340, 351, 381, 395, 407, 409, 422, 426–427, 430, 439
– arterial blood supply 310
– cranial nuclei 338
– development 262
– regulation of the systemic circulation 338
Pontocerebellum 342–344
– lesions 342
Porus acusticus
– externus 11, 19, 40–42, 45
– internus 14, 16–17, 21, 37, 186, 194, 300
– – content 21
Posterior cranial base 16, 19
Posterior cranial fossa 17
– arteries 305
Posterior fasciculus system 398, 412
– lesions 416
Posterior lateral fontanelle 23
Posterior parietal association cortex 319
Posterior scalene hiatus 206
Posterior spinocerebellar tract 413
Posterior triangle of the neck 202
Postganglionic fibres 420
Postganglionic neuron 419
Postural ataxia 342
Postural motor function 342
Posture 339
Post-zoster neuralgia 367
Preauricular skin adnexa 169
Pre-BÖTZINGER complex 301, 338
Precancerous lesion
– of the oral mucosa 83
– of the tongue 104
Precuneus 276, 431, 433–434
Prefrontal association cortex 319
Preganglionic axon 419
Preganglionic neuron 419
Premolar teeth 90
Premotor cortex 319
Preoculomotor centres 339
Presbyopia 157
Presubiculum 320, 324
Prevertebral ganglia 420
Prevertebral muscles 206
Primary auditory cortex 195, 319
Primary brain vesicles 261
Primary motor cortex 411
Primary palate 99
Primary somatomotor cortex 319
Primary somatosensory cortex 319, 412, 414–415
Primary visual cortex 319
– lesion 319
Primitive oral cavity (Stomadeum) 264
Processus(-us)
– alveolaris (Maxilla) 10, 27, 36–37, 73–74
– anterior (Malleus) 174
– ciliaris 156
– clinoideus
– – anterior 16, 38, 300
– – medius 299
– – posterior 16, 38, 300
– cochleariformis 176–179
– condylaris (Mandibula) 38–42, 45–46, 75, 94, 111
– coronoideus (Mandibula) 38–42, 45–46, 75, 111
– ethmoidalis (Concha nasalis inferior) 29, 70
– frontalis (Maxilla) 9–10, 22, 27–28, 31, 69, 75, 126, 138–139
– intrajugularis 35, 37
– jugularis 35
– lateralis (Malleus) 174, 180
– lenticularis (Incus) 174, 179–180
– mastoideus 11, 13, 18–19, 36–37, 45, 111, 170, 176–177, 180–181, 206, 212, 215, 369
– muscularis
– – (Cartilago arytenoidea) 221, 224
– – (Cartilago cricoidea) 221
– orbitalis (Os palatinum) 31–32, 37, 126–127
– palatinus (Maxilla) 14, 18, 28–31, 36, 69, 72–74
– posterior (Cartilago septi nasi) 69
– pterygoideus
– – (Os sphenoidale) 18, 28–31, 33–34, 37–38, 40, 60, 84, 96, 99–100, 126, 183, 212
– – (Os temporale) 41, 100
– pyramidalis (Os palatinum) 18, 30–31, 126, 181, 369
– spinosus 404
– styloideus (Os temporale) 11, 13–14, 18, 36–37, 40–42, 45, 53, 60, 84, 107, 111, 170, 176–177, 209–210, 212, 215
– temporalis (Os zygomaticum) 54
– uncinatus (Os ethmoidale) 29, 70–71, 77–79
– vaginalis (Os sphenoidale) 38
– vocalis (Cartilago arytenoidea) 221, 223–225, 233
– zygomaticus
– – (Maxilla) 18, 27, 30, 37
Processus(-us) zygomaticus
– – (Os frontale) 9, 30, 126–127
– – (Os temporale) 18, 26, 36–37, 41, 54
Projection fibres 281
Projection tracts 281, 408
Prolactin 334
Prolactostatin (dopamine) 334
Prominentia
– canalis
– – nervi facialis 177
– – semicircularis lateralis 177
– laryngea 221, 234, 248
– mallearis 173
Promontorium 176–180, 182, 404
Proprioception 348
Proprioceptive fibres 398
Proprioceptive (monosynaptic) reflexes of the spinal cord 402
Prosencephalon 261, 266
Protopathic sensibility
– N. trigeminus [V] 367
– neurons 412
Protrusion, temporomandibular joint 44
Protuberantia
– mentalis 10–11, 38, 105
– occipitalis
– – externa 13–14, 19, 242
– – interna 16, 35
Pseudo-unipolar ganglion cells 412
Pterygopalatine fossa 31
– access 31
Ptosis 128
– paralysis
– – of the M. levator palpebrae superioris 141
– – of the oculomotor nerve 358
Pulpa
– coronalis 88
– dentis 88
– radicularis 88
Pulvinar thalami 314, 332, 335, 339, 431
Punctum
– lacrimale 128, 130, 138–139
– – inferius 129
– – superius 129
– nervosum (ERB's point) 56, 241
Pupillary reflex 163, 339
Pupils 128, 156
– amaurotic pupillary rigidity 163
– complete pupillary rigidity 163
– constriction (miosis) 163
– dilation (mydriasis) 163
– distance 155
– reflectory pupillary rigidity 163
PURKINJE's cells, reduced number, autism 343
Purulent middle ear infection 173
Putamen 265, 279, 306, 309, 326–329, 406, 408, 428–430, 434–437, 439–440
Pyramidal cells/layer of the isocortex 317
Pyramidal tract 398, 406, 411
– lesions 406
– parts and pathways 407
Pyramis 278–279, 281, 337–338
– vermis 340, 344

Q

Quadrant anopsia 355

R

Rachischisis 269
Radiatio
– acustica 195, 332, 408
– corporis callosi 280, 406, 428, 432
– optica (GRATIOLET's radiation) 160–161, 163, 327, 332, 354–355, 408, 435–437
– – lesions 161
– thalami 332
– – anterior 332, 408

Radiatio thalami
– – centralis 408
– – posterior 332, 408
Radiculopathy, disc prolapse 396
Radii lentis 157
Radix(-ces)
– anterior [motoria] (N. spinalis) 396, 401
– clinica 88
– cranialis
– – (N. accessorius [XI]) 382, 386–388
– – (N. trigeminus [V]) 337
– dentis 88
– facialis (N. canalis pterygoidei) 182
– inferior (Ansa cervicalis) 243, 246, 390–391
– lateralis (Tractus opticus) 160
– linguae 102–103, 106, 114, 184, 229, 232
– motoria (N. trigeminus [V]) 118, 278, 337, 361, 363–364
– nervorum
– – cervicalium 392
– – coccygeorum 392
– – lumbalium 392
– – sacralium 392
– – thoracicorum 392
– parasympathica
– – (Ganglion pterygopalatinum) 373, 376
– – (N. petrosus major) 118
– – (Nn. splanchnici pelvici) 422
– – [oculomotoria] (Ganglion ciliare) 116, 148, 356
– posterior (N. spinalis) 395–396, 401
– sensoria
– – (N. trigeminus [V]) 148, 278, 337, 361, 363–364
– – [nasociliaris] ganglii ciliaris 356–357, 362, 365
– spinalis (N. accessorius [XI]) 347, 351, 386–388
– superior
– – (Ansa cervicalis) 108, 243, 245–246, 248–249, 252, 390–391
– – (Plexus cervicalis) 242
– sympathica
– – ciliaris 356–357
– – ganglii pterygopalatini 371, 378
– – (N. petrosus profundus) 117–118
Ramus(-i)
– acromialis (A. suprascapularis) 244
– alveolares superiores
– – anteriores 99
– – medii 95, 99, 362
– – posteriores 59, 61, 99
– anastomoticus cum a. meningea media (A. lacrimalis) 147
– anterior
– – (N. auricularis magnus) 240
– – (N. cervicalis) 242–244, 390–391
– – (N. spinalis) 396
– – (Sulcus lateralis) 273
– articulares (N. spinalis) 400
– ascendens (Sulcus lateralis) 273
– auricularis(-es)
– – (A. auricularis posterior) 62, 171
– – anteriores (A. temporalis superficialis) 57, 62, 171
– – (N. auricularis posterior) 370–371
– – (N. vagus [X]) 57, 61, 182, 215, 381–383
– basales tentorii (A. carotis interna) 298
– bronchiales (N. vagus [X]) 381–383
– buccales (N. facialis [VII]) 56–57, 64, 370–371, 374
– calcarinus (A. cerebri posterior) 160, 305
– capsulae internae 408
– cardiaci
– – cervicales
– – – inferiores (N. vagus [X]) 381–383, 396
– – – medii (N. vagus [X]) 254, 396
– – – superiores (N. vagus [X]) 215–216, 245, 254, 381–383, 396
– – thoracici (N. vagus [X]) 381–383
– cervicofacialis (N. auricularis posterior) 64
– choroideus
– – posterior (A. choroidea anterior) 304

Ramus(-i) choroideus
– – ventriculi quarti (A. inferior posterior cerebelli) 247
– coeliaci (N. vagus [X]) 382–383
– colli (N. facialis [VII]) 56, 64, 113, 241–242, 370–371, 374
– communicans(-tes)
– – albus (N. spinalis) 396
– – cum
– – – ganglio ciliari (N. nasociliaris) 365
– – – nervo
– – – – auriculotemporali 117
– – – – canalis pterygoidei 117
– – – – faciali 116, 241, 362, 366
– – – – glossopharyngeo 381
– – – – zygomatico 136–137, 150, 364
– – – ramo
– – – – auriculari nervi vagi 378–379
– – – – sinus carotici 382–383
– – griseus (N. spinalis) 396
– – (Truncus sympathicus) 245, 254
– cricothyroideus
– – (A. thyroidea superior) 62, 213, 254
– – (V. thyroidea superior) 213
– cutaneus anterior pectoralis (N. intercostalis) 248
– dentales
– – (A. alveolaris inferior) 59
– – (A. alveolaris superior posterior) 59, 62
– descendens (A. occipitalis) 62
– digastricus (N. facialis [VII]) 58, 61, 180–181, 369, 373
– diploicus (A. supraorbitalis) 147
– dorsales
– – (A. intercostalis suprema) 247
– – linguae (A. lingualis) 62, 101, 109
– externus
– – (N. accessorius [XI]) 215–216
– – (N. laryngeus superior) 200, 215, 254, 382–383
– – (N. vagus [X]) 386–387
– frontalis
– – (A. meningea media) 288, 315
– – (A. temporalis superficialis) 55–58, 62
– – posteromedialis (A. cerebri anterior) 432
– – (V. temporalis superficialis) 56
– ganglionares
– – ad ganglion pterygopalatinum 96, 118, 365–366
– – trigeminales (A. carotis interna) 298
– gastrici anteriores (N. vagus [X]) 381–383
– glandularis(-es)
– – (A. thyroidea inferior) 244
– – (A. thyroidea superior) 62
– – anterior (A. thyroidea superior) 254
– – posterior (A. thyroidea superior) 254
– gyri angularis (A. cerebri media) 303, 313
– hepaticus(-i) (N. vagus [X]) 381–383
– hyoideus (A. lingualis) 109
– inferior(-es)
– – (N. oculomotorius [III]) 142–144, 148–149, 153, 356
– – (N. transversus colli) 240
– infrahyoideus (A. thyroidea superior) 62, 242
– interganglionaris
– – (N. spinalis) 396
– – (Truncus sympathicus) 253
– internus
– – (N. accessorius [XI]) 215–216
– – (N. laryngeus superior) 109, 200, 215, 232–233, 254, 382–383
– – (N. vagus [X]) 386
– intestinales (N. vagus [X]) 382–383
– isthmi faucium (N. lingualis) 366
– labiales superiores (N. infraorbitalis) 99
– lateralis
– – (N. supraorbitalis) 57–58, 60, 134–135, 146–147
– – nasi (A. facialis) 57, 62
– linguales
– – (N. glossopharyngeus [IX]) 102, 232, 378–379
– – (N. vagus [X]) 382–383

Ramus(-i)
– mandibulae 10, 38–42, 45, 53, 60, 64, 84, 105, 209
– marginalis mandibularis (N. facialis [VII]) 56–57, 64, 252, 370–371, 374
– mastoideus (A. occipitalis) 62, 245
– medialis (N. supraorbitalis) 57–58, 60, 134–135, 146–147
– medullares
– – laterales (A. spinalis anterior) 247
– – mediales (A. spinalis anterior) 247
– meningeus
– – (A. carotis interna) 298
– – (A. cerebri posterior) 300
– – (A. occipitalis) 62
– – (A. ophthalmica) 144
– – (A. vertebralis) 247
– – anterior (A. ethmoidalis anterior) 146–149
– – (N. cervicalis) 390–391
– – (N. mandibularis [V/3]) 146, 366
– – (N. maxillaris [V/2]) 362, 365
– – (N. spinalis) 396, 400
– – (N. trigeminus [V]) 362
– – (N. vagus [X]) 381–383
– – recurrens
– – – (A. ophthalmica) 144–145, 147
– – – (N. ophthalmicus) 362, 365
– mentalis (A. alveolaris inferior) 59, 62
– musculares
– – (A. vertebralis) 247
– – (N. pterygoideus medialis) 185
– musculi stylopharyngei (N. glossopharyngeus [IX]) 378–379
– mylohyoideus (A. alveolaris inferior) 59
– nasalis(-es)
– – anteriores laterales (A. ethmoidalis anterior) 147
– – externus
– – – (A. ethmoidalis anterior) 79
– – – (N. ethmoidalis anterior) 58, 81, 362
– – – (N. trigeminus [V]) 65
– – interni
– – – (N. ethmoidalis anterior) 362
– – – (N. infraorbitalis) 81
– – posteriores
– – – inferiores (N. palatinus major) 81
– – – superiores 96, 362
– – – – laterales 81, 366
– – – – mediales 366
– occipitalis
– – (A. auricularis posterior) 62
– – (A. occipitalis) 62
– – (N. auricularis posterior) 370
– oesophageales
– – (A. thyroidea inferior) 244
– – (N. laryngeus recurrens) 232
– – (N. vagus [X]) 382–383
– orbitales (N. maxillaris [V/2]) 96
– paracentrales 313
– parietalis
– – (A. meningea media) 288, 315
– – (A. occipitalis medialis) 432
– – (A. temporalis superficialis) 56–59, 61–62
– – (V. temporalis superficialis) 56
– parietooccipitalis
– – (A. cerebri posterior) 305
– – (A. occipitalis medialis) 313
– parotideus(-i)
– – (A. auricularis posterior) 62
– – (A. temporalis superficialis) 62
– – (N. auriculotemporalis) 366
– – (N. facialis [VII]) 116
– – (N. trigeminus [V]) 362
– perforantes
– – (A. auricularis posterior) 171
– – (A. thoracica interna) 248
– – (V. thoracica interna) 248
– peridentales
– – (A. alveolaris inferior) 59
– – (A. alveolaris superior posterior) 59, 62
– – (A. infraorbitalis) 59
– pharyngealis(-es)/pharyngeus(-i)
– – (A. canalis pterygoidei) 97

Ramus(-i) pharyngealis(-es)/pharyngeus(-i)
– – (A. pharyngea ascendens) 62
– – (A. thyroidea inferior) 244
– – (Aa. palatinae minores) 62
– – (N. glossopharyngeus [IX]) 215, 378–379
– – (N. vagus [X]) 215, 378, 381–383
– posterior(-es)
– – (N. auricularis magnus) 240
– – (N. spinalis) 396
– – (Nn. cervicales) 242
– – (Sulcus lateralis) 273, 432
– precunealis (A. pericallosa) 313, 431–432
– profundus (A. transversa colli) 242–244
– pterygoidei (A. maxillaris) 59, 62
– pulmonales (N. vagus [X]) 396
– radicularis(-es)
– – (A. vertebralis) 247
– – anterior(-es)
– – – (A. ethmoidalis anterior) 147
– – – (A. medullaris segmentalis) 401
– – – (Nn. intercostales) 400
– – – (Nn. lumbales) 400
– – posterior(-es)
– – – (A. medullaris segmentalis) 401
– – – (Nn. intercostales) 400
– – – (Nn. lumbales) 400
– septalis
– – (A. ethmoidalis posterior) 79
– – anterior (A. ethmoidalis anterior) 79
– – (N. ethmoidalis anterior) 81
– – posterior (A. sphenopalatina) 62, 79
– septi nasi (A. labialis superior) 62, 79
– sinus carotici (N. glossopharyngeus [IX]) 378–379
– spinales
– – (A. cervicalis ascendens) 244
– – (A. intercostalis suprema) 247
– – (A. vertebralis) 247
– sternocleidomastoideus
– – (A. occipitalis) 62, 108, 244
– – (A. thyroidea superior) 62, 243
– stylohyoideus (N. facialis [VII]) 58, 180–181, 369, 373
– superficialis (A. transversa colli) 242–243, 245
– superior(-es)
– – (N. oculomotorius [III]) 142, 144, 147–148, 153, 356–357
– – (N. transversus colli) 240
– suprahyoideus (A. lingualis) 109, 242
– temporalis(-es)
– – (A. cerebri posterior) 305
– – anterior (A. cerebri media) 303
– – medius (A. cerebri media) 303
– – (N. facialis [VII]) 64, 370–371, 374
– – posterior (A. cerebri media) 303
– – superficialis (N. trigeminus [V]) 362
– temporofacialis (N. auricularis posterior) 64
– tentorius
– – (N. ophthalmicus [V/1]) 362, 365
– – (N. trochlearis [IV]) 146
– terminales
– – inferiores (A. cerebri media) 303, 434
– – superiores (A. cerebri media) 303, 434
– tonsillae cerebelli (A. inferior posterior cerebelli) 247
– tonsillaris(-es)
– – (A. facialis) 62
– – (A. palatina ascendens) 101, 232
– – (A. palatina descendens) 101
– – (A. pharyngea ascendens) 101
– – (N. glossopharyngeus [IX]) 101–102, 232, 378–379
– – (Nn. palatini minores) 101
– tracheales
– – (A. laryngea inferior) 232
– – (A. thyroidea inferior) 244
– – (N. vagus [X]) 382–383
– tubarius (N. glossopharyngeus [IX]) 378
– ventralis nervi spinalis 270
– zygomatici (N. facialis [VII]) 56–57, 64, 134, 370–371, 374
– zygomaticofacialis (N. maxillaris [V/2]) 56–58, 96, 362, 365

Ramus(-i)
– zygomaticotemporalis (N. facialis [VII]) 56–58, 96–97, 365
Ranula 112
Raphe
– mylohyoidea 104–105
– palati 85, 98–99
– palpebralis lateralis 128
– pharyngis 210, 212
– pterygomandibularis 59, 61, 84, 98, 212, 217
Raphe nuclei 340
RATHKE's pouch 219, 264
Recessus
– cochlearis 188
– ellipticus 188
– epitympanicus 173, 175–176, 179
– frontalis 78
– hypotympanicus 175
– infundibuli 287, 292, 329, 340, 429, 438
– lateralis ventriculi quarti 287
– meatus acustici inferioris 172
– membranae tympanicae
– – anterior 173
– – superior 173, 176
– pharyngeus (fossa of ROSENMÜLLER) 72, 185, 216
– pinealis 287, 292, 329, 436
– piriformis 216, 231, 233
– sphenoethmoidalis 74
– sphericus 188
– supraopticus 287, 292, 329, 429, 438
– supraorbitalis 76
– suprapinealis 287, 292, 329, 435
– triangularis 292, 339, 429
– tubotympanicus 168
Rectum 421
Referred pain 393
Reflectory pupillary rigidity 163
Reflexes
– mono-/polysynaptic 402
– pathological 410
– vasovagal 252, 295
Refractive index, cornea/lens 155
Regio
– auricularis 4–5
– axillaris 245
– buccalis 4, 9
– capitis 4–5, 9
– cervicalis
– – anterior 4, 202–203, 240, 242
– – lateralis 4–5, 9, 202–203, 240–245
– – posterior 4–5, 202
– colli 4–5, 9
– entorhinalis 324
– frontalis 4
– infraorbitalis 4, 9
– infratemporalis 4
– mastoidea 4–5
– mentalis 4, 9
– nasalis 4
– nuchae 5
– occipitalis 4–5
– oralis 4, 9, 82
– orbitalis 4
– parietalis 4–5
– parotideomasseterica 4–5, 9
– preoptica 324
– sternocleidomastoidea 4–5, 9
– temporalis 4–5
– zygomatica 4, 9
Regulator of the homeostatic feedback loop 419
REICHERT's cartilage 24
REINKE's oedema 228
REINKE's space 228, 230, 235
REISSNER's membrane (Membrana vestibuli) 191
Respiratory centre 338–339
Respiratory nuclei, ventral group of the medulla oblongata 338
Respiratory reflexes 339
Reticulum trabeculare 154, 156
Retina 154–155, 162–163, 330, 354
– amacrine cells 354
– blood vessels 158
– cone (bipolar) cells 354
– ganglionic cells 354–355
– horizontal cells 354
– inner limiting layer 354
– inversion 160
– neural epithelium 124, 154
– neuronal arrangements 162, 354
– OFF-cone bipolar cells 354
– OFF-ganglionic cells 354
– ON-cone bipolar cells 354
– ON-ganglionic cells 354
– pigment epithelium 124, 154
– rod (bipolar) cells 354–355
Retinaculum laterale/mediale 153
Retinal detachment (Ablatio/Amotio retinae) 154, 158, 160
– papilloedema 158
Retroarticular veins cushions 43
Retroarticular venous pad 43
Retrobulbar neuritis 354
Retropharyngeal abscess 208
Retrusion of the temporomandibular joint 44
Rheumatoid arthritis, cricoarytenoid joint 224
Rhinoliquorrhoea 81, 282
Rhombencephalon 261, 263–264, 266
– development 349
Rigor, PARKINSON's disease 327
Rima
– glottidis 231, 233, 235
– oris 82
– palpebrarum 128, 132
– vestibuli 235
RIOLAN, muscle of (Pars palpebralis, M. orbicularis oculi) 132
Rod (bipolar) cells of the retina 160, 162, 354–355
ROLANDO, fissure/sulcus of (Sulcus centralis cerebri) 266, 272–274, 276, 286, 302, 308, 318, 426, 432–434, 439–440
ROLLER's nucleus (Ncl. vestibularis inferior) 191, 350, 377
ROMBERG's test, dizziness 197
Roofplate 263–264, 268, 349
Root of the tongue 102
– arteries and nerves 232
ROSENMÜLLER, fossa of (Recessus pharyngeus) 72, 185, 216
ROSENTHAL's vein (V. basilaris) 311, 314
Rostral 271
Rostral mesencephalon 195
Rostral pons 195
Rostral ventrolateral medulla (RVLM) 338–339
Rostrum
– corporis callosi 276, 280, 290–291, 302, 323, 340, 428, 436, 439
– sphenoidale 38
Round window (Fenestra cochleae) 178
Ructus voice 201

S

Saccadic (jerky) eye movements 43, 342
Sacculus
– laryngis 233, 235
– vestibularis 166, 169, 189, 376
Saccus
– endolymphaticus 169, 189
– lacrimalis 122, 130–131, 134–135, 138–140
Saddle anaesthesia, cauda equina syndrome 392
Sagittal suture 12, 31
Salivary glands 111, 115
– inflammation 112
– large/small 111
– malformations of the excretory ducts 112
SANTORINI's cartilages (Cartilagines corniculata) 221–222, 224, 226–229
SCA (superior cerebellar artery) 307
– supply areas 310

Scala
– tympani 187–189, 191–192
– vestibuli 187–189, 191–192
Scalene hiatus 206, 245, 253
Scalenus anticus syndrome 253
Scalp 49
– bleedings 49
– swelling (Caput succedaneum) 49
Scalping injury 49
Scapha 171–172
Scaphocephaly 25
SCHAFFER's collaterals 324
SCHIRMER's test 133, 180
– peripheral facial palsy 374
Schizophrenia 324
– hippocampus 320
SCHLEMM's canal (Sinus venosus sclerae) 154–156
SCHULTZE's comma tract (Fasciculus interfascicularis) 397
SCHWALBE's nucleus (Ncl. vestibularis medialis) 191, 350, 377
Scintigraphy, thyroid gland 239
Sclera 152–156
– development 124
– radius of curvature 155
Second deciduous tooth 88
Secondary auditory cortex 319
Secondary brain vesicles 261
Secondary palate 99
Secondary somatomotor cortex 319
Secondary somatosensory cortex 319, 412, 415
Secondary visual cortex 319
Segmenta
– cervicalia 392, 395
– coccygea 392
– lumbalia 392, 395
– medullae spinalis 392–393
– sacralia 392
– thoracica 392, 395
Sella turcica 14, 35, 70, 72, 74, 264, 298, 361
– arteries and nerves 361
Semicanalis
– musculi tensoris tympani 177, 179, 181, 185, 369
– tubae auditivae 100, 179, 183–185, 187
Semicircular canals 166, 193
– hair cells 377
Senile cataract 157
Senile ectropion (Ectropium atonicum) 51, 133
Sense
– of smell 348
– of taste 348
Sensor of the homeostatic feedback loop 419
Sensorineural hearing impairment 193
Sensory cells (olfactory cells) 352–353
Sensory cortex 411
Sensory disturbances
– blow-out fracture 127
– lesions of the thalamic nuclei 331
Sensory language centre (WERNICKE's centre) 319
Sensory receptors 348
Septal haematoma 69
Septal nuclei 324
Septum
– canalis musculotubarii 177, 179, 185
– lacrimale 131, 140
– linguae 103, 107, 115
– medianum dorsale 268
– nasi 69, 73, 75–77, 84, 94, 219
– – osseum 10, 22, 28, 41
– orbitale 134–135, 140, 152
– pellucidum 276, 290–292, 302, 306, 323, 326, 339, 347, 406, 425–429, 433–435
Septum deviation 28, 76
Seromucotympanon 175
Serotonin 340
SERRE's body 91
Short association fibres 280
Shoulder depression, lesion of the N. accessorius [XI] 387
SHRAPNELL's membrane 173
Sialoliths 112, 114
SILVIUS, aqueduct of (Aqueductus mesencephali) 262–263, 275, 277, 279, 286–287, 292, 302, 329, 332, 336, 340, 344, 425–426, 430, 437–438
Sinus
– caroticus 378
– cavernosus 144–145, 283, 298–299, 311–312, 360–361
– – arteries and nerves 361
– – thrombosis 145
– durae matris 282–283, 311–312
– – course 311
– – projection onto the cranial base 312
– frontalis 14, 28–29, 36, 69–70, 73–76, 151, 159
– – development 73
– infraorbitalis 130
– intercavernosi 283, 298, 312, 361
– marginalis 283, 311–312
– maxillaris 30–31, 33, 36, 73–77, 94, 111, 118, 126, 130, 138–139, 141, 151–153, 159, 426
– – development 73
– – opening 74
– occipitalis 283, 300, 311–312
– paranasales 75
– petrosus
– – inferior 283, 311–312
– – superior 283, 311–312, 360
– posterior (Cavum tympani) 177
– rectus 283, 287, 311–312, 347
– sacci lacrimalis superior 139
– sagittalis
– – inferior 283, 304, 311–312, 347
– – superior 76, 258, 283, 287–288, 304, 311–313, 347
– sigmoideus 215–216, 283, 300, 311–312
– sphenoidalis 14, 28–29, 33–34, 41, 69–70, 72–75, 78, 150, 159, 184, 298, 361, 426
– – sinusitis/tumours 149
– – surgery 74
– sphenoparietalis 283, 311–312
– transversus 180, 215–216, 283, 311–312
– tympani 177, 179
– venosus sclerae (SCHLEMM's canal) 154–156
Sinusitis 75, 149
– computed tomography (CT) 77
– maxillaris 32, 77
Siphon caroticum 295, 305
Skull 9
– base 211
– bend fractures 15
– blow-out fracture, coronary CT 12, 123
– development, malformations of the median gap 267
– fractures 12
– – lesion of the A. meningea media 315
– meninges 282
– split fractures 12
Small fontanelle 23
Small salivary glands 111
SMAS (superficial muscular aponeurotic system) 48
Smell disorders, ALZHEIMER's or PARKINSON's disease 325
SÖLDER's lines 367
Soft palate 98
– muscles 100, 184
– sensory innervation of the mucous membrane 99
Soft triangle of the nose 58
Somatic (animalic) nervous system 270
– circuitry 419
– organisation 420
Somatic motor innervation 419
Somatic nerve plexuses 396
Somatic nervous system
– circuitry 419
– organisation 420
Somatoliberin (GHRH) 334
Somatomotor cortex 319
Somatosensoric innervation, skeletal muscles 419
Somatosensory association cortex 415
Somatosensory cortex 319, 412, 415
Somatotopic arrangement of the internal capsule 408
Somatotropic hormone (STH, growth hormone, GH) 334
Somnolence 271
Sopor 271
Sound conduction 192
– migrating waves 192
Spastic paralysis 410
Spatial differentiation 413
Spatial orientation 339
Spatium(-a)
– epidurale 282, 403–404
– episclerale 152
– intervaginale subarachnoidale 154
– lateropharyngeum [parapharyngeum] 108, 215–217
– – passageways 211
– oesophagotracheale 213, 229
– perichoroideum (Retina) 154
– peripharyngeum 217
– retrooesophageum 213
– retropharyngeum 213, 217
– subarachnoideum 48, 282–283, 287, 300, 400, 403, 427
– sublinguale 108
– submandibulare 108
– suprasternale 209, 236
– zonularia 156
Special somatic afferent fibres (SSA) 349, 351
– N. vestibulocochlearis [VIII] 377
Special visceral afferent fibres (SVA) 349, 351
– N. glossopharyngeus [IX] 379
– N. vagus [X] 384
Special visceral efferent fibres (SVE) 349, 351, 371, 384
– N. accessorius [XI] 387
– N. vagus [X] 384
Specific thalamic nuclei, lesion 331
Sphenoid/sphenoidal bone 34–35, 38
Spina(-ae)
– bifida aperta, cystica or occulta 269
– mentalis 38–39
– – superior 105
– nasalis 26
– – anterior 10–11, 27, 29–31, 69–70
– – posterior 18, 28–31, 70
– ossis sphenoidalis 16, 18, 31, 34, 38, 41, 183
– palatinae 30
– suprameatica 36
– tympanica major/minor 180
Spinal afferent tracts 412
Spinal anaesthesia 403
Spinal cord 395, 407, 409
– afferent tract 398, 414
– arteries 399
– compression 405
– cytoarchitecture 397
– development 268
– directions and positions 271
– efferent tract 398
– grey/white matter 268, 397
– innervation areas 401
– laminar structure 397
– lesions 405
– longitudinal grooves 395
– meninges 268, 400
– mono-/polysynaptic reflexes 402
– nuclei 397
– reflexes 402
– segmental arterial supply 400
– segments 392–393
– – and corresponding dermatomes 393
– – clinically examined 394
– – indicator muscles 394
– system or apparatus of connections 402
– tracts 412

Index

Spinal ganglia, development 268
Spinal nerves 268, 395
– characteristics 347
– lesions, dysfunctional cutaneous innervation 403
– nomenclature 395
Spinal reflex loop 402
Spinocerebellar system 398
Spinocerebellum 342–344
– lesions 342
Spinothalamic system 398
Spiral canal of cochlea 187
Splenium corporis callosi 275–276, 280–281, 291, 302, 322–323, 347, 426, 431, 434–435, 439
Split-brain patients 281
Split skull fractures 12
Spontaneous nystagmus 43, 342
Squama
– frontalis 9, 26, 28, 30–31, 33, 126–127
– occipitalis 13–14, 22, 28, 31, 35
Squamous cell carcinoma
– larynx 229
– Plica vocalis 231
– supraglottic 201
SSA (specific somatic afferent fibres) 346, 348–349, 351
– N. vestibulocochlearis 377
Stapedial reflex test, facial palsy 374
Stapes 168, 170, 173–174, 176, 180–181, 189, 192, 369
STENON's or STENSEN's duct (Ductus parotideus) 52–53, 56, 60, 110, 112–113, 212, 217
STH (somototropic hormone/growth hormone, GH) 334
Stomadeum (primitive oral cavity) 264
Stratum
– granulare 320, 324
– granulosum (Cerebellum) 343
– inferius, bilaminar zone 45
– lacunosum-moleculare 320, 324, 343
– nervosum (Retina) 154
– oriens 320, 324
– pigmentosum (Retina) 154
– pyramidale 320, 324
– radiatum 320, 324
– superius, bilaminar zone 45
Stress hormones 419
Stria(-ae)
– longitudinalis
– – lateralis 321, 323, 430
– – medialis 321, 323–324, 430
– mallearis 173
– medullaris(-es)
– – thalami 277, 329, 333, 429–430
– – ventriculi quarti 278, 287, 337
– olfactoria
– – lateralis 325, 352
– – medialis 325, 352
– terminalis 290–292, 321, 339, 429–430, 433–434
Striatum 317, 326, 328
Stroke (apoplexy, cerebral infarction) 302–303, 308, 408
Struma 238
– multinodosa 239
Strumectomy, paralysis of the laryngeal muscles 238
Stye (Hordeolum) 133
Subarachnoidal haematoma 299, 316
Subarachnoidal space 48, 282, 394
– course of the cranial nerves 347
Subclavian steal syndrome 244
Subcortical nuclei 326
– neuronal circuits 328
Subdural haematoma 313, 316
Subepithelial venous plexus of the tongue 109
Subglottic pressure 230
Subglottis (subglottic space) 230
Subiculum 320, 324
– promontorii 177–178
Sublingual salivary gland 111, 113–114
Submental fat compartment 48
Substantia
– alba 279, 283, 291, 431
– – fibre systems 281
– – (Medulla spinalis) 394
– gelatinosa 397
– grisea 279, 291, 431
– – centralis 332, 336, 418, 424
– – intermedia centralis 397
– – (Medulla spinalis) 394
– lentis 157
– nigra 263, 275, 277, 279, 328, 330, 332, 336, 340, 347, 361, 406, 438
– perforata
– – anterior 277, 332, 352
– – posterior 275, 277, 301, 320, 335–336
Subthalamus 277, 329
Sulcus(-i)
– alaris 68
– anterolateralis (Medulla spinalis) 394–395
– arteriae
– – meningeae mediae 15
– – subclaviae 254
– – temporalis mediae 36
– arteriosus
– – (Os sphenoidale) 38
– – (Os temporale) 14–16, 37
– basilaris 278, 337
– breves insulae 272
– bulbopontinus 278, 340
– calcarinus 160–161, 272, 275, 281, 302, 308, 318–319, 321–323, 354–355, 425–426, 431, 435–436, 439
– caroticus 16, 35, 38, 300
– centralis
– – cerebri (fissure/sulcus of ROLANDO) 266, 272–274, 276, 286, 302, 308, 318, 415, 426, 432–434, 439–440
– – insulae 272
– cerebri 273–275
– cinguli 272, 274, 318, 323, 428, 433
– circularis insulae 272, 428
– collateralis 272, 275, 291, 320–321, 325, 436–438
– corporis callosi 281, 321, 428
– epithalmicus 264
– frontalis inferior 274
– hippocampalis 272, 275, 291, 320–322, 437–438
– hypothalamicus 264, 277, 292, 302, 329, 430, 437
– infraorbitalis 27, 31–32, 37, 126–127
– intermedius posterior 278, 394
– intraparietalis 273–274, 276
– intrarhinalis 321, 325
– lacrimalis 31, 126
– lateralis cerebri (SYLVIAN fissure/sulcus) 266, 272–273, 276, 286, 308–309, 318, 335, 415, 428, 430, 432
– limitans 264, 268, 278, 349
– longae insulae 272
– lunatus 273, 434–436
– medianus
– – linguae 102
– – posterior medullae
– – – oblongatae 278–279, 287, 339, 395
– – – spinalis 279, 394–395
– – (Rhombencephalon) 349
– mylohyoideus 38–39, 41
– nervi petrosi
– – majoris 16, 187
– – minoris 16
– occipitotemporalis 275
– of the cerebral hemispheres 272
– olfactorius 78, 275
– orbitales 275
– palatini 30
– palpebralis superior 128
– palpebronasalis 128
– parietooccipitalis 272–274, 276, 281, 302, 308, 318, 323, 431, 433–434, 439
– postcentralis 274, 415
– posterolateralis 278, 384, 394–395
– precentralis 273–274
Sulcus(-i)
– prechiasmaticus 35, 299
– promontorii 177–178
– retroolivaris 337, 381
– rhinalis 321
– sclerae 128
– semianularis 321, 325
– sinus
– – petrosi
– – – inferioris 16, 187
– – – superioris 16
– – sagittalis superioris 15–16
– – sigmoidei 14, 16–17, 35, 37, 186–187, 300
– – transversi 14, 16–17, 35
– spiralis internus 192
– subparietalis 431, 433–434
– temporalis
– – inferior 273, 275
– – superior 273, 431, 434–437
– terminalis 216
– – linguae 102
– tubae auditivae 19, 38
– tympanicus 177
– venosi 15
Supercilium 128, 152
Supplementary motor cortex 319, 411
Supraglottic squamous cell carcinoma 201
Supraglottis (supraglottic space) 230
Suprahyoidal muscles 104–105, 205
Supranuclear lesions of the facial nerve 373
Supratentorial herniation 341
Sutura
– coronalis 10–12, 14–15, 22, 31, 312
– ethmoidolacrimalis 37
– frontalis 22, 28, 31
– frontolacrimalis 10–11
– frontomaxillaris 32, 69
– frontonasalis 9, 69
– frontozygomatica 10–11, 75
– incisiva 30
– intermaxillaris 10
– internasalis 9
– lacrimomaxillaris 11
– lambdoidea 11–15, 22, 31
– nasomaxillaris 10–11, 69
– occipitalis transversa 13, 28
– occipitomastoidea 11, 13, 16
– palatina
– – mediana 18, 30
– – transversa 18, 30–31, 69
– parietomastoidea 11, 13
– sagittalis 12–13, 31, 283, 312
– sphenofrontalis 10–11, 16, 33
– sphenoparietalis 10
– sphenosquamosa 11, 16, 40
– sphenozygomatica 10–11, 136
– squamosa 11, 13–14
– temporozygomatica 11
– vomeromaxillaris 69
– zygomaticofrontalis 32
– zygomaticomaxillaris 10–11, 27, 31–32, 36, 127
SVA (special visceral afferent fibres) 346, 348–349, 351
– N. facialis [VII] 373
– N. glossopharyngeus [IX] 379
– N. vagus [X] 384
SVE (special visceral efferent fibres) 346, 348–349, 351, 371, 384
– N. accessorius [XI] 387
– N. facialis [VII] 373
– N. vagus [X] 384
Swallowed foreign bodies 213
Swallowing centre 339
Swallowing problems 380
Swallowing reflex 104
SYLVIAN fissure/sulcus (Sulcus lateralis cerebri) 266, 272–273, 276, 286, 308–309, 318, 335, 415, 428, 430, 432
SYLVIUS, aqueduct of (Aqueductus mesencephali) 287
Sympathetic trunk ganglia 420, 424
Sympathicus (sympathetic system) 419–422

Symphysis mandibulae 22, 39
Synchondrosis
– petrooccipitalis 187, 210
– sphenopetrosa 186–187
Syncope 295
Syndesmoses 222
Systema nervosum 270
Systemic circulation, nuclei 338

T

Taenia
– choroidea 292, 321, 339
– fornicis 290, 321, 323
– thalami 290, 292
Tapetum 280, 431, 433–434, 440
Tarsus 134–135
– inferior 132, 135, 152
– superior 132, 135, 152
Taste buds 417
Taste fibres, N. vagus [X] 384
Tear film
– break-up time 133
– components 132
Tear trough 8
Tectum mesencephali 160, 263, 275, 302, 305, 329, 336, 340, 344, 418, 425–426, 437–438
Tegmentum mesencephali 263, 275, 277, 332, 340, 425, 430, 437–438
Tela choroidea 262, 430–431, 434
– ventriculi
– – quarti 339
– – tertii 290–292, 302, 304, 329, 340, 429–430, 435, 439
Telencephalic vesicles 263–264
Telencephalon 195, 261, 266, 271, 290
– areas supplied by the cerebral arteries 309
– gyrification (surface enlargement) 266
– hemispheres 266
– – development 266
– nuclei 326
– – lesions 306
– parts 317
Temporal bone 36–37, 182
– of a newborn 36
Temporal fossa 151
Temporal lobe 272
Temporal lobe epilepsy 320
– drug therapy resistant 324
Temporal lobe herniation 315
Temporal visual field 355
Temporomandibular joint 40–43, 45, 54, 64
– abduction 44
– adduction 44
– arthrosis 44
– dormant condyle and oscillating condyle 44
– laterotrusion 44
– mediotrusion 44
– movements 44
– protrusion 44
– retrusion 44
– rotational axis 44
– X-ray image 46
Tendo intermedius (M. digastricus) 104–105, 252
TENON's capsule (Vagina bulbi) 152
Tension lines of the face 7
Tentorium cerebelli 282–283, 304, 315, 347
Tetracyclines, enamal defects 91
Thalamic nuclei 331
Thalamic pain 331
Thalamic radiation 332
Thalamus 264–266, 271, 276–277, 279, 290, 292, 302, 309, 314, 321, 323, 326–329, 332, 339, 343, 408, 411–412, 425–427, 429–430, 434–436, 439
– afferent and efferent connections 330
– cortical projection 331
– dorsalis 329–330
– gateway to consciousness 330
– ventralis 329
Thalamus
– vestibularis inferior 196
Thermal nystagmus test 197
Thermal regulation 423
Thorax, transition zone to the upper limb, vessels and nerves 253
Thrombophlebitis, Otitis media 176
Thrombosis, Sinus durae matris 312
Thyroglossal fistula/cyste 237
– computed tomography (CT) 237
Thyroid cartilage 221
Thyroid gland 235–236
– arteries 238
– development 237
– diffuse and focal alterations 239
– enlargement 239
– location 234
– lymph nodes and lymph vessels 251
– scintigraphy 239
– surgery 236
– ultrasound image 239
– veins 238
Thyroidectomy, paralysis of the laryngeal muscles 238
Thyroid-stimulating hormone (TSH) 334
Thyroliberin (TRH) 334
Tinnitus 192
Tongue 101–103, 106, 417
– blood vessels 108–109, 115
– chemical burns and scalding 104
– extrinsic muscles 106–107
– glands 111
– inner muscles 103
– innervation 102, 109
– leukoplakia 104
– muscles 103, 107
– nerves 108–109, 115
– precancerous conditions 104
– subepithelial venous plexus 109
– taste qualities 102
Tonsilla
– cerebelli 43, 340–341, 431
– – herniation 315
– lingualis 101–102, 213
– palatina 85, 98, 100–102, 107, 184, 213, 216–217, 232, 237
– pharyngea 72, 84, 101, 184, 213, 216, 218–219
– tubariae 101
Tonsillectomy 101
– carotid loop 220
Tooth/teeth
– dental crown 88
– dental formula 89
– dental neck 88
– loss after mandibular fractures 39
– permanent 90–92
– root tip 88
– sockets 27
Torus
– levatorius 213, 216, 219
– mandibularis 38
– tubarius 72, 84, 213, 216, 219
Trabeculae arachnoideae 282
Trachea 204, 207, 210, 213, 216, 219, 224, 226, 229, 232, 234–236, 245, 251
– lymph nodes and lymph vessels 251
– surgical access 204
Tracheotomy 204
Tractus
– bulbothalamicus 414
– cerebellaris 343
– cerebelloreticularis 343
– cerebellorubralis 430
– cerebellothalamicus 343
– cerebellovestibularis 343
– corticomesencephalicus 407
– corticonuclearis 281, 407–408
– corticopontinus 281
– corticoreticularis 408
– corticorubralis 408
– corticospinalis 281, 338, 407–408
– – anterior 397–398, 407, 410
Tractus corticospinalis
– – lateralis 397–398, 407, 410
– – (pyramidalis) 397
– cuneocerebellaris 343
– frontopontinus 332, 408
– hypothalamohypophysialis 333
– nuclei solitarii 338
– occipitopontinus 408
– olfactorius 72, 275, 285, 301, 322–323, 325, 347, 352–353, 428
– olivocerebellaris 343
– opticus 144, 160, 277–279, 281, 320, 322, 332, 335, 406, 429, 438
– paraventriculohypophysialis 333
– parietotemporopontinus 408
– perforans 324
– pontocerebellaris 343
– pyramidalis 281, 406, 430
– reticulocerebellaris 343
– reticulospinalis 397–398, 409–410
– retinohypothalamicus 330
– rubrospinalis 397–398, 409–410
– spinalis nervi trigemini [V] 338, 363, 379, 383
– spinocerebellaris
– – anterior (GOWERS' tract) 343, 397–398, 413
– – posterior (FLECHSIG's tract) 343, 397–398, 413
– – superior 398
– spinoolivaris 397–398, 412–413
– spinoreticularis 398, 412
– spinotectalis 397–398, 412
– spinothalamicus 418
– – anterior 397–398, 412
– – lateralis 397–398, 412
– spiralis foraminosus 187
– supraopticohypophysialis 333
– tectospinalis 397–398, 409–410
– tegmentalis centralis 417
– trigeminothalamicus 418
– vestibularis inferior 196
– vestibulocerebellaris 343
– vestibulospinalis
– – lateralis 196, 398, 409–410
– – medialis 397–398
Tragus 11, 171
Transentorhinal cortex 324
Transglottic space (glottic space, Glottis) 230
Transnasal endoscopy 79
Tremor, PARKINSON's disease 327
TRH (thyroliberin) 334
Triangular cartilage, nasal skeleton 68
Triceps tendon reflex 402
Trigeminal afferent system 412, 414
Trigeminal afferent tracts 412, 414
Trigeminal neuralgia 367
Trigonum
– caroticum 4, 9, 202
– cervicale anterius/posterius 202
– collaterale 289–291, 322, 436, 440
– habenulare 339
– lemnisci lateralis 335
– musculare [omotracheale] 4, 9, 202
– nervi
– – hypoglossi 278
– – vagi 278
– olfactorium 275, 277, 322, 332, 352
– omoclaviculare (Fossa supraclavicularis major) 4, 209
– omotracheale (musculare) 9
– retromolare 38
– submandibulare 4, 9, 202
– – vessels and nerves 252
– submentale 4, 9, 202
Trismus 55
Trochlea musculi obliqui superioris 135
Trochlear nerve palsy 143, 359
– diplopia 141
TROLARD's anastomosis 311
TROLARD's vein [V. anastomotica superior] 258, 313
Truncothalamus 331

Truncus(-i)
– brachiocephalicus 206, 216, 247, 253, 381
– coeliacus 422
– corporis callosi 276, 279–281, 289, 302, 322–323, 339, 347, 406, 427–430, 433, 439
– costocervicalis 247
– – branches 247
– encephali 278, 302, 308, 339–340
– inferior (Plexus brachialis) 253
– jugularis 254
– lymphaticus
– – bronchomediastinalis 254
– – subclavius 254
– medius (Plexus brachialis) 253
– nervi
– – accessorii 216, 386
– – spinalis 282, 396
– superior (Plexus brachialis) 242–243, 253, 386
– sympathicus 97, 215–217, 245, 253–254, 378, 421–422
– thyrocervicalis 216, 238, 244–245, 247, 253, 399
– – branches 244
– vagalis 396
– – anterior 381–383, 422
– – posterior 381–383, 422
TSH (thyroid-stimulating hormone) 334
Tuba auditiva [auditoria] (EUSTACHIAN tube, Tuba EUSTACHII) 100, 169–170, 173, 176–177, 179, 181, 183–185, 190, 369, 378
– inflammation 183
– occlusion 175
Tuber
– cinereum 160, 275, 277, 320, 332
– frontale 12, 22, 26
– maxillae 27, 96
– parietale 11–12, 22, 31
– vermis 340–341, 344
Tuberculum
– anterius thalami 339
– articulare
– – (Art. temporomandibularis) 45
– – (Os temporale) 19, 36–37, 40, 43, 46, 54, 94, 171
– caroticum 206, 254
– corniculatum 213, 216, 229, 231
– cuneatum 278, 339, 347
– cuneiforme 213, 216, 228–229, 231
– dentis 88
– epiglotticum 228
– gracile 278, 337, 339, 347
– jugulare 35
– labii superioris 82
– mentale 38, 105
– olfactorium 325, 352
– pharyngeum 18
– sellae 16, 35
– thyroideum inferius/superius 221
Tuberositas
– masseterica 38, 41
– pterygoidea 38–39, 41
Tufted cells, Fila olfactoria 353
Tunica
– conjunctiva
– – bulbi 128, 154
– – palpebrarum 128, 132
– mucosa
– – linguae 103
– – oris 87, 106–107
– – tubae auditivae 185
Tympanic amorphous substance, organ of CORTI 192
Tympanic cavity 170, 176–177, 179–180
– development 168
– lateral wall 179
– levels 175
– medial wall 177–178
– recessus 173
– topographic relationships 176
Tympanic membrane (Membrana tympanica) 170, 173
– development 168
Tympanic membrane (Membrana tympanica)
– perforation, otitis media 176
– quadrants 173
Tympanostomy tubes 173

U

Ultrasound image
– eye 159
– head 305
– thyroid gland 239
Umbo
– mallei 184
– membranae tympanicae 173, 176
Unconscious deep sensibility 413
Uncus (Gyrus uncinatus) 272, 275–276, 321–323, 352, 438–439
UNTERBERGER's step test, dizziness 197
Upper dental arch 86
Upper eyelid 132
– ectropionised 128
Upper jaw 10, 27, 31, 86, 93
– *See also* Maxilla
– deciduous teeth 92
– dental arch 87
– of a five-year-old child 93
– – panoramic X-ray image 94
– permanent teeth 92
– tooth sockets 27
– wisdom teeths 86
– without wisdom teeths, panoramic X-ray 94
Upper motor disease 410
Upper nasal passage 74
Upper thoracic aperture
– paravertebral/prevertebral structures 254
– vessels and nerves 249
Upper tracheotomy 204
Utriculus 166, 169, 182, 189, 191, 193, 376
Uvula 101, 184
– bifida 98
– palatina 84–85, 98
– vermis 340, 344

V

VA (vertebral artery) 296, 307
Vagal neuralgia 380
Vagina
– bulbi (TENON's capsule) 152
– carotica 207–208
– externa
– – (Anulus tendineus communis) 144
– – nervi optici 143, 152, 154
– interna (Anulus tendineus communis) 144
– processus styloidei 37
Vallecula epiglottica 102, 232
Vas(-a)
– infraorbitalis 135
– infratrochlearia 135
– lymphatica superficialia, head/neck 250
– sanguinea retinae 158
– spirale 192
– supraorbitalia 135
– supratrochlearia 135
Vasopressin (antidiuretic hormone, ADH) 423
– deficiency 334
Vasovagal reflexes 252, 295
Velum
– medullare
– – inferius 278, 342, 347
– – superius 278, 329, 340, 342–343, 347, 431
– palatinum [Palatum molle] 55, 84–85, 94, 96, 98, 100–101, 184, 213, 218–219
Vena(-ae)
– alveolaris
– – inferior 76, 95, 108, 217
– – superior
– – – anterior 95
– – – posterior 95, 97
Vena(-ae)
– anastomotica
– – inferior (LABBÉ's vein) 313
– – superior 313
– angularis 56, 63, 134, 145, 311
– anterior
– – cerebri 314
– – septi pellucidi 304, 314, 428, 435
– aqueductus
– – cochleae 190
– – vestibuli 190
– auricularis posterior 240–242
– axillaris 245, 248
– basalis (ROSENTHAL's vein) 311, 314
– brachiocephalica 67, 206, 216, 244–245, 249, 253–254
– cava superior 206, 216, 249, 253
– – tributaries 249
– centralis retinae 76, 155
– – thrombosis 153
– cephalica 245, 248–249
– cerebri 304
– cervicalis
– – profunda 63, 253–254
– – superficialis 248
– choroidea inferior/superior 314
– – superior 314
– ciliaris anterior 155
– comitans nervi hypoglossi 63, 115
– conjunctivalis anterior 155
– diploicae 283, 312
– – frontales 63, 312
– – occipitales 63, 312
– – temporales
– – – anteriores 63, 312
– – – posteriores 63, 312
– dorsalis linguae 108
– emissaria(-ae) 95
– – condylaris 311
– – frontalis 311
– – mastoidea 63, 311
– – occipitalis 311
– – parietalis 63, 283, 311
– – passageways through the skull 311
– – spreading of bacteria 311
– episcleralis 155
– ethmoidalis anterior/posterior 80
– facialis 56–58, 60, 63, 76, 95, 97, 110, 113, 134, 145, 241–243, 248–249, 252, 311
– frontales (Vv. superiores cerebri) 258, 313
– infraorbitalis 95, 97, 130, 134, 145, 153
– infratrochlearis 134
– interna cerebri 290, 292, 311, 314, 430–431, 435
– jugularis
– – anterior 204, 236, 241, 248–249
– – externa 57, 63, 95, 113, 209, 240–245, 248–249, 252
– – interna 53, 63, 66–67, 95, 108, 176, 184, 204, 207, 215, 217, 236, 242–245, 248–252, 254, 311, 390
– – – thrombosis, otitis media 176
– labialis
– – inferior 63
– – superior 63, 80
– labyrinthi 190
– laryngea superior 107, 115, 212, 216, 233
– lateralis ventriculi lateralis 314
– lingualis 76, 108–109
– magna cerebri (vein of GALEN) 160, 283, 287, 290, 292, 302, 304, 311–312, 314, 340, 347, 431, 436
– – tributaries 314
– maxillaris 60, 63, 95
– media
– – profunda cerebri 314
– – superficialis cerebri 313, 428
– meningea media 288
– nasofrontalis 63, 145
– occipitalis 56, 63, 240–242, 248–249, 311, 313
– ophthalmica
– – inferior 144–145, 311

Vena(-ae) ophthalmica
– – superior 144–145, 153, 300, 311–312
– palatina descendens 97
– palpebrales inferiores/superiores 134
– parietales 284, 313
– pharyngeae 63, 215
– profunda(-ae)
– – cerebri 314
– – faciei 60
– – linguae 108
– retromandibularis 56–58, 60, 63, 95, 217, 241–244, 248–249, 311
– scalae
– – tympani 190
– – vestibuli 190
– septi pellucidi 314
– sphenopalatina 80, 97
– spinalis anterior/posterior 401
– subclavia 67, 204, 206, 216, 243, 249, 254
– sublingualis 108–109, 113, 115
– submentalis 58, 60, 63, 113, 243, 248
– superiores cerebri 258, 283–284, 311, 313
– supraorbitalis 134, 145
– supratrochlearis 63, 134, 145
– temporalis
– – media 58, 60
– – superficialis 56–57, 60, 63, 134
– thalamostriata 314, 433
– – superior 289–292, 304, 311, 314, 321, 430–431, 434–435, 439
– thoracica interna 249, 253–254
– thoracoacromialis 248
– thoracoepigastricae 245
– thymicae 249
– thyroidea
– – inferior 238, 245, 248–249
– – media 238, 249
– – superior 63, 113, 213, 238, 243, 245, 248–249
– transversa
– – colli 241, 248–249
– – faciei 134
– vertebralis 236, 253–254
– vestibulares 190
– vorticosa 145, 155
Venous sinus thrombosis 312
– inflammation of the facial area 63
Venous sinuses 283
Venter
– anterior (M. digastricus) 52–53, 66–67, 76, 104–105, 113–115, 202, 204–205, 209, 212, 242–244, 248–250, 252
– frontalis (M. occipitofrontalis) 51–53, 60, 130, 370
– inferior (M. omohyoideus) 66, 204–205, 209, 241–244, 246, 248, 250, 390
– occipitalis (M. occipitofrontalis) 51–53, 240, 370
– posterior (M. digastricus) 53, 104–105, 113, 180–181, 202, 204–205, 209–210, 212, 215, 220, 243, 369–370
– superior (M. omohyoideus) 66, 115, 202, 205, 209, 242–243, 246, 250, 390
Ventricular zone, spinal cord 268
Ventriculus(-i)
– encephali 286–287
– laryngis (ventricle of MORGAGNI) 103, 228–231, 233, 235
– lateralis 267, 286–287, 289–292, 304, 309, 321–322, 326–327, 329, 331, 360, 406, 425–431, 433–440
– quartus 261–262, 286–287, 289, 302, 310, 340, 343–344, 347, 349, 426, 431, 439
– Rhombencephalon 349
– tertius 261, 265, 277, 282, 286–287, 289–290, 292, 302, 327, 329, 339, 347, 406, 425–427, 429–430, 435–436, 438
– – boundaries 292
– – ependymal roof 265
Ventrolateral medulla 424
Venula
– macularis inferior/superior 158
– medialis retinae 158
– nasalis retinae inferior/superior 158
– temporalis retinae inferior/superior 158
Vermis cerebelli 290–291, 310, 336, 339, 341–344, 347, 413, 425–426, 431, 436–439
– atrophy due to chronic alcohol abuse 343
– parts 344
Vertebra prominens, palpable point 5
Vertebral arterial system 301
– circulatory disorders, WALLENBERG's syndrome 301
Vertebral canal
– magnetic resonance imaging (MRI) 405
– meninges 282
– opening 395
– veins 401
– with spinal cord 405
Vertex 12
– corneae 154
Vertical gaze palsy, blow-out fracture 127
Vertical linear acceleration 193
Vesica urinaria, innervation 421
Vestibular 87
Vestibular labyrinth 189
Vestibular organ (Labyrinthus vestibularis) 166, 170, 191, 343
Vestibular schwannoma (acoustic neurinoma) 187, 373, 377
Vestibular system, afferent/efferent fibres 196
Vestibular tract 377
Vestibulocerebellum 342–344
– lesions, equilibrium or balance disorders 342
Vestibulo-ocular reflex 197
Vestibulum
– labyrinthi 188, 190
– laryngis 229–230, 235
– nasi 72
– oris 83, 85, 101, 103
– – sensory innervation of the mucous membrane 99
Vibrissae 84
VIDIAN canal (Canalis pterygoideus) 33–34, 38, 96
VIDIAN nerve (N. canalis pterygoidei) 97, 137, 182, 362, 370–371
Viewing directions, testing 142
Visceral motor neurons 419
Visceral nerve plexuses 396
Viscerocranium 36
– frontal section 74
– ossification mode 24
Visual agnosia 319
Visual cortex 319
Visual field 355
– classification 161
– failure of the contrallateral half (hemianopsia) 408
Visual pathway 161
Visual sensory afferent fibres, brain stem 423
Vitamin D deficiency (rickets), enamel defects 91
Vitrectomy 153
Vitreous bleedings 153
Vitreous body 125, 154
Vocal folds 225, 227, 233
– during opening and closing phase 230
– nodules 231
– polyps 231
Vocal ligament (BROYLE's tendon) 223, 225, 227, 233
Voluntary movements, planning and realisation 411
Vomer 9–10, 14, 18, 28, 36, 41, 69, 72, 74, 99

W

WALDEYER's tonsillar ring (pharyngeal lymphoid ring) 101, 213
WALLENBERG's syndrome 258
– circulatory disorders in the vertebral arterial-system 301
WERNICKE-KORSAKOFF syndrome 323
WERNICKE's aphasia 319
WERNICKE's centre (sensory language centre) 319
WHARTON's duct (Ductus submandibularis) 76, 112–115
White matter
– of the CNS 279
– of the spinal cord 268
WILLIS, circle of (Circulus arteriosus cerebri) 285, 295, 299–300
Wisdom tooth/teeth 86, 93
X-ray image
– neck 253
– paranasal sinuses 75
– temporomandibular joint 46
Yellow spot (Macula lutea) 158

Z

ZENKER's diverticulum 210
– KILLIAN's triangle 210
ZINN, anulus of (Anulus tendineus communis) 114, 141, 143–144, 356
Zona incerta 329
Zonula ciliaris 154, 156
Zoster ophthalmicus 367

Sobotta

Discover your Personal Digital Ancillary Content at e-Sobotta

NOTE:
The atlas cannot be returned once panel is scratched off.

How to Register:

1. Gently scratch off the surface of the sticker above to reveal your personal, non-transferable PIN.
2. Access your e-Sobotta content at **www.sobotta.com**, by first registering to create a digital bookshelf. Follow the simple registration instructions on the page.
3. Once you have created your digital bookshelf, redeem your ancillary content with your personal PIN printed above.
4. On future visits you will simply need to log-in to access your redeemed content.

Your e-Sobotta ancillary content enables you to systematically deepen and test your knowledge for all anatomical structures present within this atlas. Access world-class anatomy content digitally, wherever you are, whenever you choose.

Important Note:
Access to, and use of, content through the website is for individual, non-commercial use only and non-transferable. The license and access to the online version operates strictly on the basis of a single user per PIN.

The sharing of login credentials is strictly prohibited, and any attempt to do so will invalidate the access. Access may not be shared, resold, or otherwise circulated.

Full Terms and Conditions of use are available upon registration, and access will be subject to your acceptance of these terms of use. Access is granted for the lifespan of **www.sobotta.com** and terminates on its end of service, as this is a non-binding offer.

Library and institutional access and use are strictly prohibited. For information on products and services available for institutional access, please contact **lizenzen@elsevier.com**.

ELSEVIER

The Sobotta Anatomy Coloring Book

Take the fun approach to anatomy:

- Facilitate in-depth learning through active engagement with anatomical structures
- Reinforce anatomical understanding by actively reasserting relevant knowledge
- Understand anatomy beyond the cramming of structures with Clinical Remarks

1st Edition

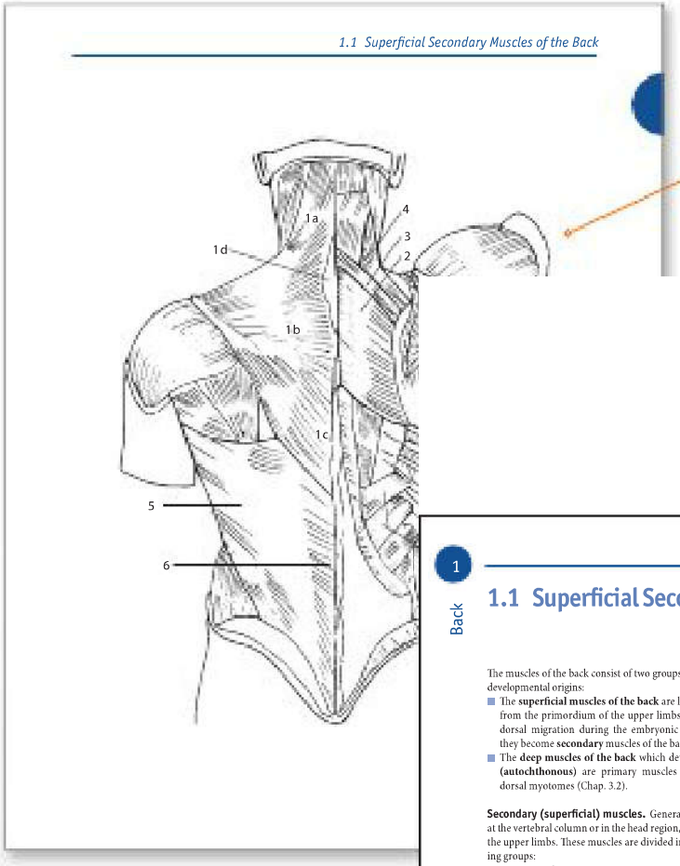

Anatomical Sketch: outlines of 150 anatomical images, based on high-end, detailed Sobotta anatomical illustrations, to practice upon

Condensed Know-How: concise structure-related information to reinforce visual recognition and to highlight critical information

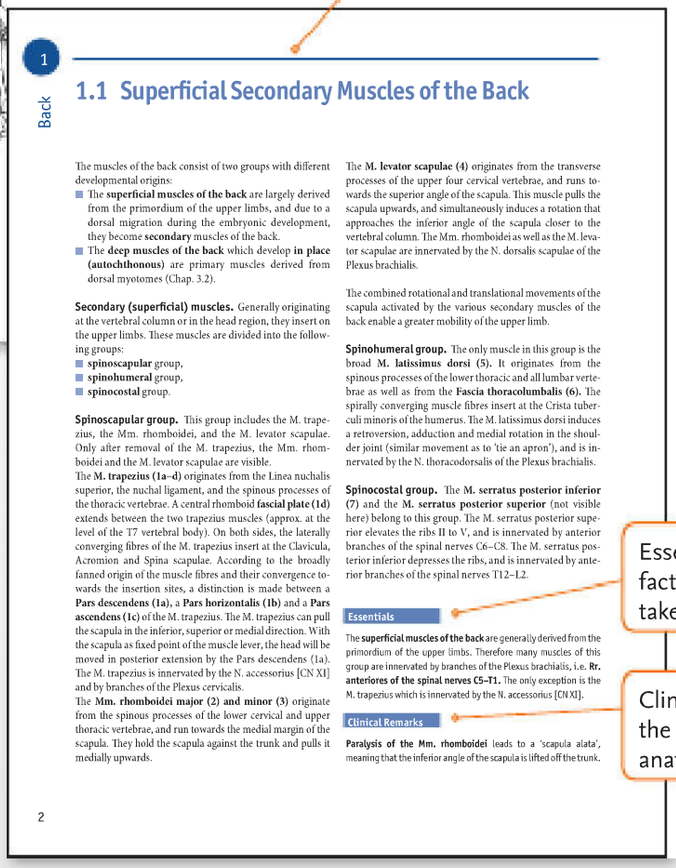

1 Back

1.1 Superficial Secondary Muscles of the Back

The muscles of the back consist of two groups with different developmental origins:

- The **superficial muscles of the back** are largely derived from the primordium of the upper limbs, and due to a dorsal migration during the embryonic development, they become **secondary** muscles of the back.
- The **deep muscles of the back** which develop **in place (autochthonous)** are primary muscles derived from dorsal myotomes (Chap. 3.2).

Secondary (superficial) muscles. Generally originating at the vertebral column or in the head region, they insert on the upper limbs. These muscles are divided into the following groups:

- **spinoscapular** group,
- **spinohumeral** group,
- **spinocostal** group.

Spinoscapular group. This group includes the M. trapezius, the Mm. rhomboidei, and the M. levator scapulae. Only after removal of the M. trapezius, the Mm. rhomboidei and the M. levator scapulae are visible.

The **M. trapezius (1a–d)** originates from the Linea nuchalis superior, the nuchal ligament, and the spinous processes of the thoracic vertebrae. A central rhomboid **fascial plate (1d)** extends between the two trapezius muscles (approx. at the level of the T7 vertebral body). On both sides, the laterally converging fibres of the M. trapezius insert at the Clavicula, Acromion and Spina scapulae. According to the broadly fanned origin of the muscle fibres and their convergence towards the insertion sites, a distinction is made between a **Pars descendens (1a)**, a **Pars horizontalis (1b)** and a **Pars ascendens (1c)** of the M. trapezius. The M. trapezius can pull the scapula in the inferior, superior or medial direction. With the scapula as fixed point of the muscle lever, the head will be moved in posterior extension by the Pars descendens (1a). The M. trapezius is innervated by the N. accessorius [CN XI] and by branches of the Plexus cervicalis.

The **Mm. rhomboidei major (2) and minor (3)** originate from the spinous processes of the lower cervical and upper thoracic vertebrae, and run towards the medial margin of the scapula. They hold the scapula against the trunk and pulls it medially upwards.

The **M. levator scapulae (4)** originates from the transverse processes of the upper four cervical vertebrae, and runs towards the superior angle of the scapula. This muscle pulls the scapula upwards, and simultaneously induces a rotation that approaches the inferior angle of the scapula closer to the vertebral column. The Mm. rhomboidei as well as the M. levator scapulae are innervated by the N. dorsalis scapulae of the Plexus brachialis.

The combined rotational and translational movements of the scapula activated by the various secondary muscles of the back enable a greater mobility of the upper limb.

Spinohumeral group. The only muscle in this group is the broad **M. latissimus dorsi (5).** It originates from the spinous processes of the lower thoracic and all lumbar vertebrae as well as from the **Fascia thoracolumbalis (6).** The spirally converging muscle fibres insert at the Crista tuberculi minoris of the humerus. The M. latissimus dorsi induces a retroversion, adduction and medial rotation in the shoulder joint (similar movement as to 'tie an apron'), and is innervated by the N. thoracodorsalis of the Plexus brachialis.

Spinocostal group. The **M. serratus posterior inferior (7)** and the **M. serratus posterior superior** (not visible here) belong to this group. The M. serratus posterior superior elevates the ribs II to V, and is innervated by anterior branches of the spinal nerves C6–C8. The M. serratus posterior inferior depresses the ribs, and is innervated by anterior branches of the spinal nerves T12–L2.

Essentials

The **superficial muscles of the back** are generally derived from the primordium of the upper limbs. Therefore many muscles of this group are innervated by branches of the Plexus brachialis, i.e. **Rr. anteriores of the spinal nerves C5–T1.** The only exception is the M. trapezius which is innervated by the N. accessorius [CN XI].

Clinical Remarks

Paralysis of the Mm. rhomboidei leads to a 'scapula alata', meaning that the inferior angle of the scapula is lifted off the trunk.

2

Essentials: focus on the key facts needed to avoid mistakes and for regular recall

Clinical Remarks: demonstrate the practical application of anatomy in clinical practice

Coming 2019

Build, Review and Test your Anatomy Knowledge

www.elsevier.com

ELSEVIER

The Sobotta Study Loop

The **Sobotta Study Loop** guides you through each chapter, introducing you to the relevant content as you go. The initial introductory page gives you an insight into the individual chapters and highlights their most important themes.

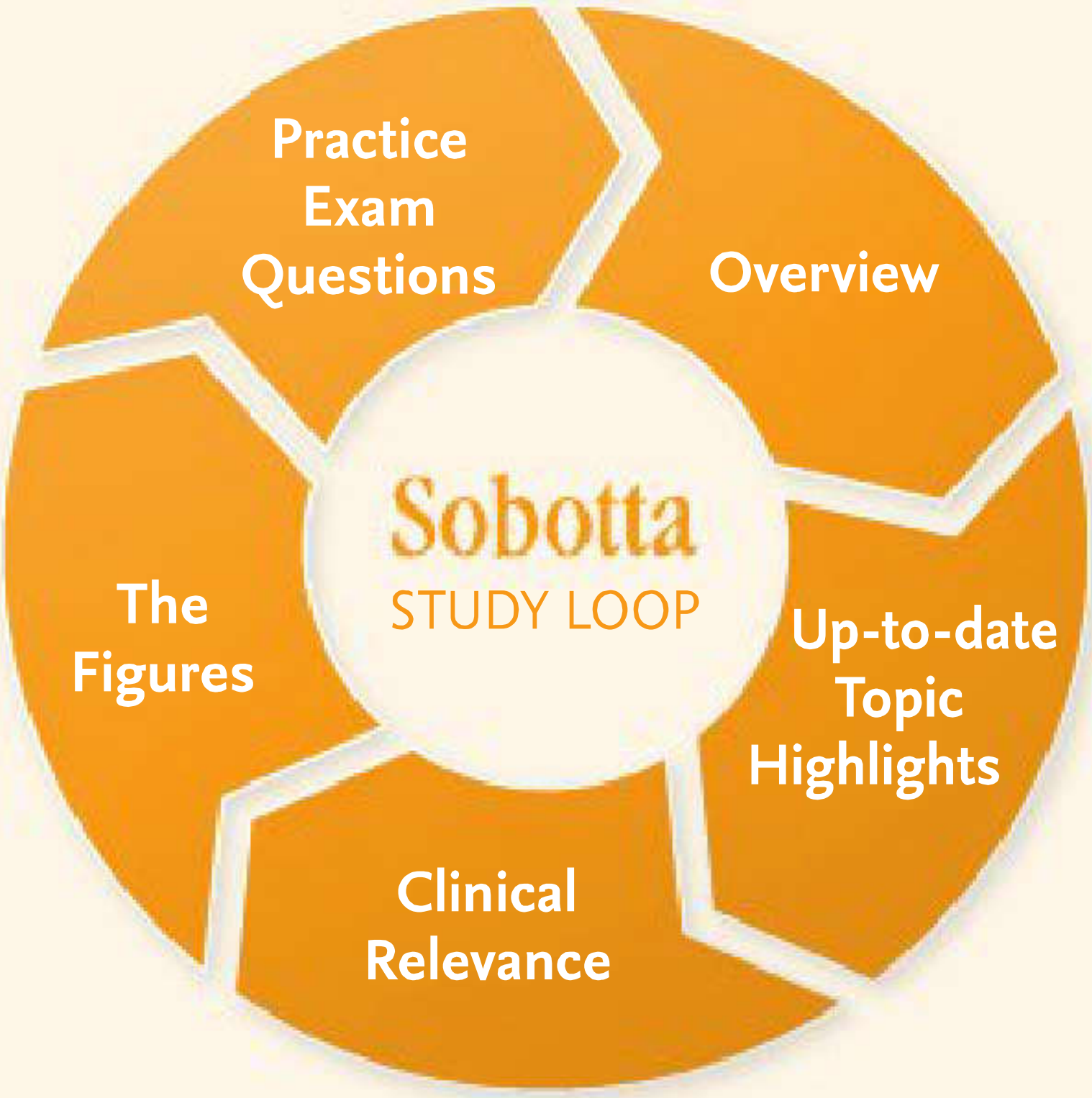

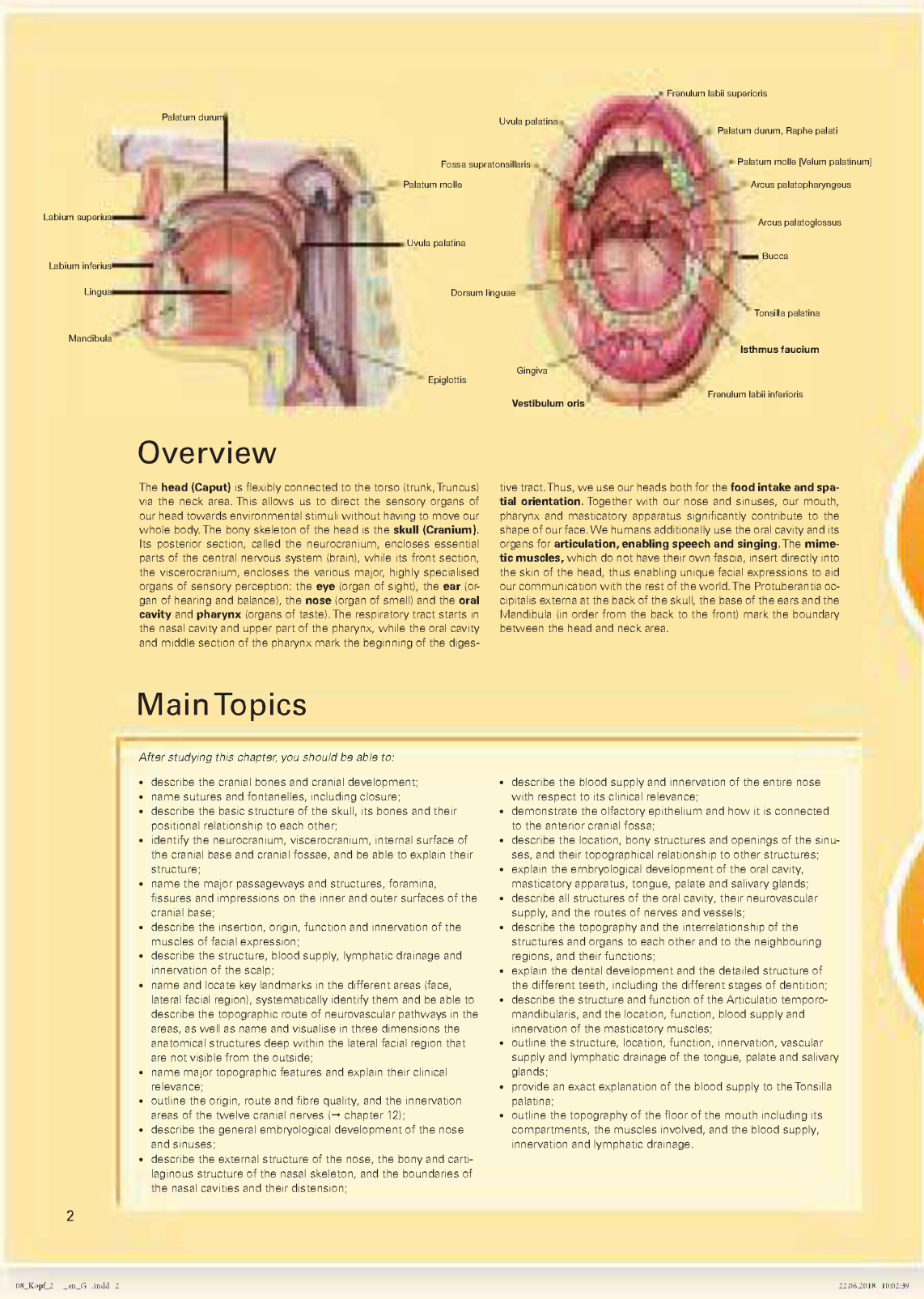

Overview

The **head (Caput)** is flexibly connected to the torso (trunk, Truncus) via the neck area. This allows us to direct the sensory organs of our head towards environmental stimuli without having to move our whole body. The bony skeleton of the head is the **skull (Cranium)**. Its posterior section, called the neurocranium, encloses essential parts of the central nervous system (brain), while its front section, the viscerocranium, encloses the various major, highly specialised organs of sensory perception: the **eye** (organ of sight), the **ear** (organ of hearing and balance), the **nose** (organ of smell) and the **oral cavity** and **pharynx** (organs of taste). The respiratory tract starts in the nasal cavity and upper part of the pharynx, while the oral cavity and middle section of the pharynx mark the beginning of the digestive tract. Thus, we use our heads both for the **food intake and spatial orientation**. Together with our nose and sinuses, our mouth, pharynx and masticatory apparatus significantly contribute to the shape of our face. We humans additionally use the oral cavity and its organs for **articulation, enabling speech and singing**. The **mimetic muscles**, which do not have their own fascia, insert directly into the skin of the head, thus enabling unique facial expressions to aid our communication with the rest of the world. The Protuberantia occipitalis externa at the back of the skull, the base of the ears and the Mandibula (in order from the back to the front) mark the boundary between the head and neck area.

Main Topics

After studying this chapter, you should be able to:

- describe the cranial bones and cranial development;
- name sutures and fontanelles, including closure;
- describe the basic structure of the skull, its bones and their positional relationship to each other;
- identify the neurocranium, viscerocranium, internal surface of the cranial base and cranial fossae, and be able to explain their structure;
- name the major passageways and structures, foramina, fissures and impressions on the inner and outer surfaces of the cranial base;
- describe the insertion, origin, function and innervation of the muscles of facial expression;
- describe the structure, blood supply, lymphatic drainage and innervation of the scalp;
- name and locate key landmarks in the different areas (face, lateral facial region), systematically identify them and be able to describe the topographic route of neurovascular pathways in the areas, as well as name and visualise in three dimensions the anatomical structures deep within the lateral facial region that are not visible from the outside;
- name major topographic features and explain their clinical relevance;
- outline the origin, route and fibre quality, and the innervation areas of the twelve cranial nerves (→ chapter 12);
- describe the general embryological development of the nose and sinuses;
- describe the external structure of the nose, the bony and cartilaginous structure of the nasal skeleton, and the boundaries of the nasal cavities and their distension;
- describe the blood supply and innervation of the entire nose with respect to its clinical relevance;
- demonstrate the olfactory epithelium and how it is connected to the anterior cranial fossa;
- describe the location, bony structures and openings of the sinuses, and their topographical relationship to other structures;
- explain the embryological development of the oral cavity, masticatory apparatus, tongue, palate and salivary glands;
- describe all structures of the oral cavity, their neurovascular supply, and the routes of nerves and vessels;
- describe the topography and the interrelationship of the structures and organs to each other and to the neighbouring regions, and their functions;
- explain the dental development and the detailed structure of the different teeth, including the different stages of dentition;
- describe the structure and function of the Articulatio temporomandibularis, and the location, function, blood supply and innervation of the masticatory muscles;
- outline the structure, location, function, innervation, vascular supply and lymphatic drainage of the tongue, palate and salivary glands;
- provide an exact explanation of the blood supply to the Tonsilla palatina;
- outline the topography of the floor of the mouth including its compartments, the muscles involved, and the blood supply, innervation and lymphatic drainage.

2

08_Kopf_2 _en_G .indd 2 22.06.2018 10:02:39

Overview

The chapter's core topics clearly presented – crucial anatomical information is highlighted.

Focused Topic Highlights

Enable interconnected competencies – via explaining anatomical content in context, thus indicating clear study objectives.

Actual clinical cases showcase practical application of the anatomical knowledge gained beyond the lecture hall.

Clinical Relevance

Useful hints and tips for your dissection course

Each case report includes:
- A Case Study
- Examination Results
- Diagnostic Procedure
- Diagnosis
- Treatment
- Dissection Lab Tips
- In the Clinic

Clinical Relevance

In order not to lose reference to future everyday clinical life with so many anatomical details, the following describes a typical case that shows why the content of this chapter is so important.

Facial Paralysis

Case Study
In the summer, a 22-year-old trainee visits his GP stating that for several days now he has had increasing problems moving the right side of his face and has had problems when trying to drink. In addition, saliva has been constantly dripping from the corner of his mouth. He also has the feeling that he hears more loudly on the right side. Otherwise, the patient appears to be healthy. He did not have any recent fever, headaches, painful limbs, a bout of flu or a tick bite. His medical history is normal. The young man is not on any medication and does not take drugs. He only drinks alcohol occasionally and in moderate limits; he does not smoke. His family medical history is also normal.

Result of Examination
The first impression of the patient's face as he comes into the examination room immediately indicates facial paralysis as a diagnosis. The right side of his face is visibly 'drooping' (→ Fig. a). The nasolabial fold on the right side has disappeared. When requested, the patient cannot frown, smile or whistle a tune, nor blow out his cheek on the right side. His attempts to close his eyes result in lagophthalmos (his right eye remains open) and in BELL's phenomenon.

BELL's phenomenon: the eyeball automatically turns upwards when closing the eyelid. As the lid cannot be closed, only the white sclera of the eye remains visible.

The doctor tests the facial nerve sensitivity by brushing the patient's cheek; however, this is intact. Because the patient cannot frown on the affected side, the doctor comes to a preliminary diagnosis: idiopathic (no identified cause) peripheral (infranuclear) facial paralysis.

People with central facial paralysis can still wrinkle their foreheads.

The GP refers the patient to an ENT specialist.

The ENT specialist also notes a complete right-sided peripheral facial paralysis. The patient's auricle and facial soft tissue are normal, and his ear canal and eardrum show no signs of irritation on either side. His parotid saliva shows no signs of irritation. The palpation of neck and face gives no indication of any tumour or infection.

Diagnostic Procedure
The ENT specialist conducts an audiometry, which shows no evidence of hearing loss. To exclude other more serious causes (e. g. a tumour), he orders a cranial MRI, blood tests, an electroneurography (ENoG) and an electromyography (EMG). The blood test results are all normal; therefore zoster oticus, a herpes simplex infection and borreliosis can all be ruled out. The ENoG and EMG reveal no signs of major nerve damage. After examination by a neurologist, neurological symptoms can also be ruled out. The MRI shows a slight swelling of the N. facialis [VII] inside the bony canal.

Diagnosis
Idiopathic, right-sided peripheral facial paralysis.

In up to 70% of all cases a peripheral facial paralysis is idiopathic.

Treatment
An outpatient treatment with cortisone infusion quickly shows results; the facial movements have already begun to return to normal by the third day. The forehead branch is the only part of the nerve still not working at this stage.

Further Development
An outpatient follow-up examination four weeks later confirms that his facial movements are perfectly symmetrical again.

Dissection Lab
Look out for the following branches of the N. facialis: N. petrosus major, Chorda tympani and N. stapedius.

Back in the Clinic
Although the patient's facial (mimetic) muscles are becoming increasingly mobile during his cortisone treatment, he has noticed that his right eye always waters when he is eating, so he goes to visit his GP again. The doctor tells him that this so-called crocodile tears syndrome is also referred to as gustatory hyperlacrimation. This harmless irritation syndrome occasionally occurs in the regenerative processes after a facial paralysis. Affected patients experience increased lacrimation (shedding of tears) on one side when eating. Because the regenerating parasympathetic gustatory nerve fibres are growing into the lacrimal gland (Glandula lacrimalis), this results in faulty misconnection and misrouting of the nerve fibres. If the patient suffers with strong subjective symptoms, Botox injections can be attempted as a treatment option.

Fig. a Left: patient as seen during examination; centre: patient when asked to wrinkle his forehead; right: patient when asked to close an eye. [T887]

3

08_Kopf_2 _en_G .indd 3 22.06.2018 11:16:26

A common theme runs through each chapter, from the surface to the detail. Clinical hints and teaching tables help you to understand and classify. Captions explain the relationships between the depicted anatomical structures. Individual structures that are relevant for tests and examinations are highlighted in bold.

The Figures

Important anatomical structures are highlighted to help you focus on the essential knowledge first.

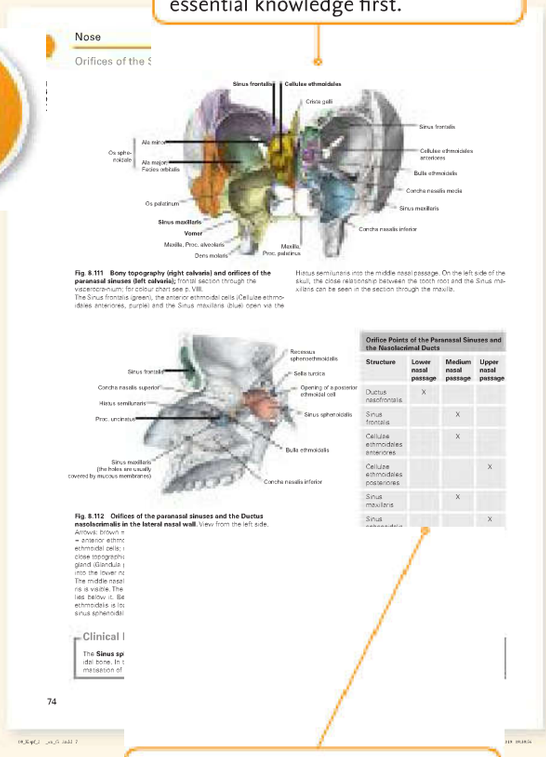

Sobotta's quick regional anatomical reference on every page aids quick orientation and helps you find your way around the chapters and their topics.

An orientation sketch points you to the current view or section depicted in the anatomical figure at a glance.

Clearly arranged tables enable you to memorise knowledge in a structured and contextualised approach.

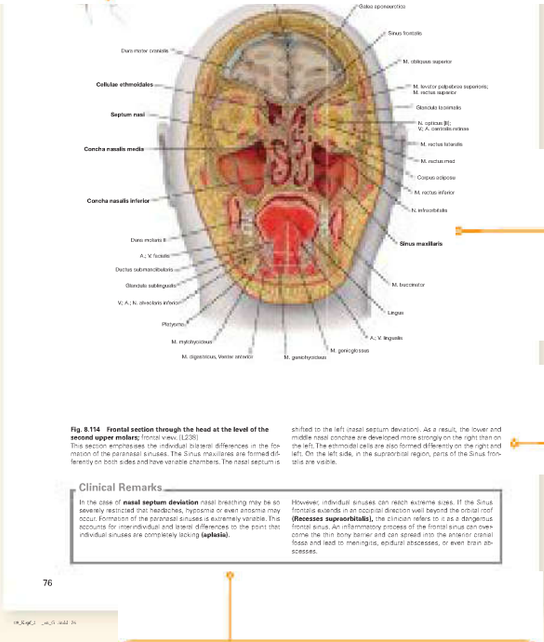

Various types of images are used in the atlas:

- realistic and detailed anatomical illustrations for a deeper insight
- schematic drawings highlighting functional relationships
- photos showcasing surface anatomy
- in-depth medical imaging scans

Each figure has a detailed caption which highlights the most important structures and the systematic and topographical relationships.

Clinical Remarks present a typical clinical case and symptoms relevant to the depicted condition or illness. This acts as an aide-mémoire contextualising the displayed structure.

Practice Exam Questions

Every chapter closes with a sampling of typical oral exam questions enabling you to test your knowledge gained within the chapter.